Study smart with Student Consult

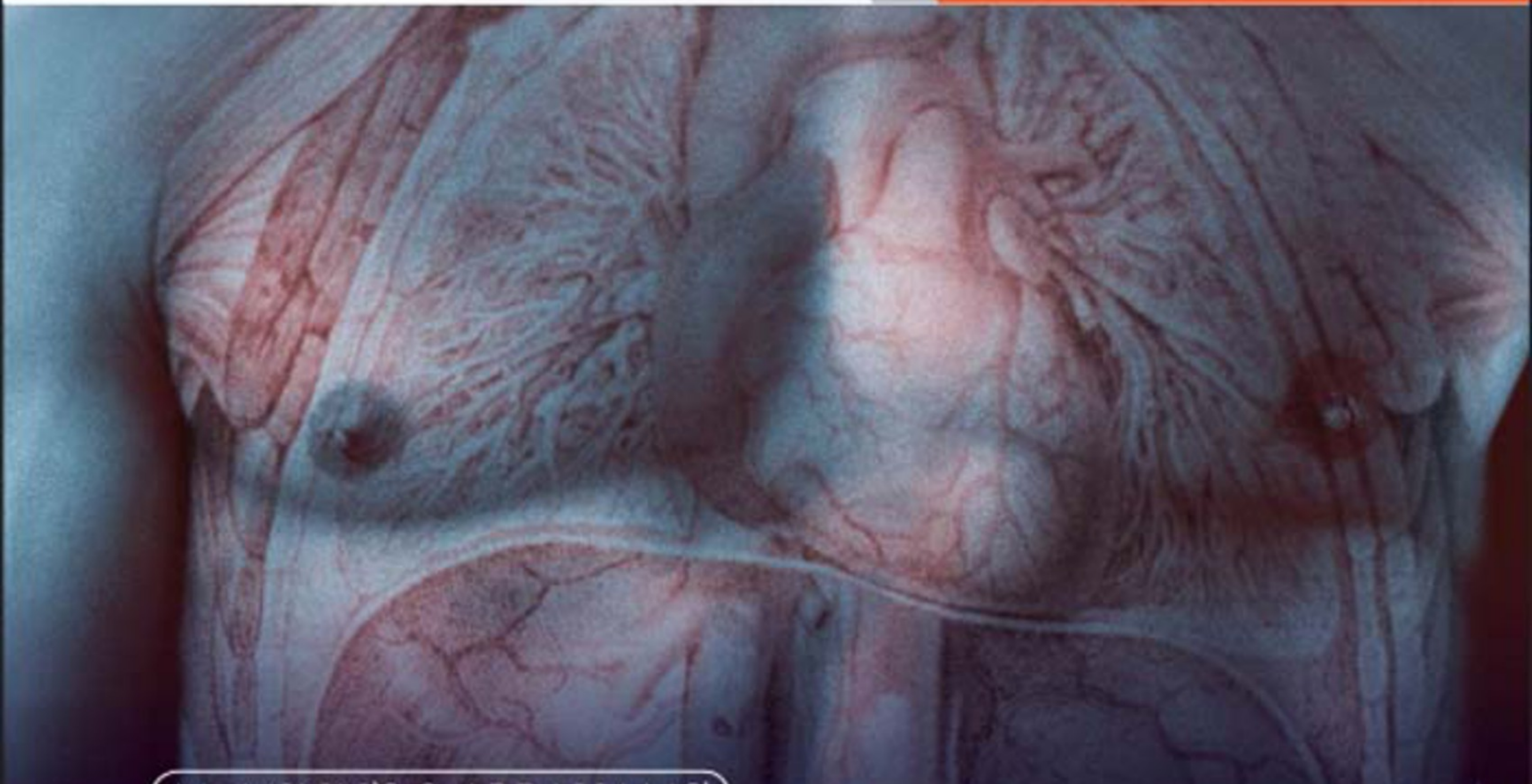

McMINN'S & ABRAHAMS'

CLINICAL ATLAS OF HUMAN ANATOMY

SEVENTH EDITION

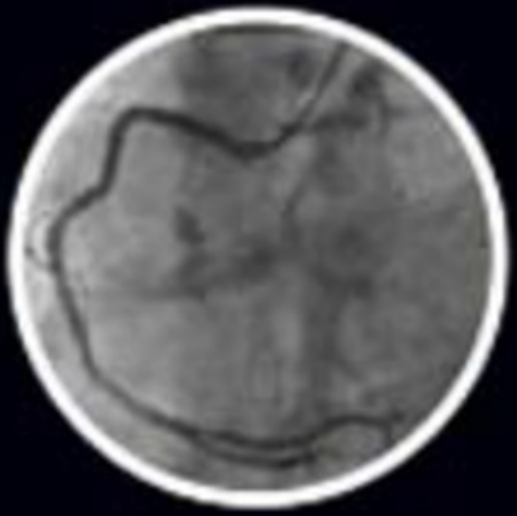

PETER H. ABRAHAMS
JONATHAN D. SPRATT
MARIOS LOUKAS
ALBERT N. VAN SCHOOR

MOSBY
ELSEVIER

Study smart with

Student Consult

Searchable full text online

Register and activate this title today at studentconsult.com

- **Access the full text online**
- **Download images**
- Add your own **notes and bookmarks**
- Search across all the **Student Consult** resources you own online in one place

Activation Code

ALREADY REGISTERED?

1. Go to studentconsult.com; Sign in
2. Click the “Activate Another Book” button
3. Gently scratch off the surface of the sticker with the edge of a coin to reveal your Pin code
4. Enter it into the “Pin code” box; select the title you’ve activated from the drop-down menu
5. Click the “Activate Book” button

FIRST-TIME USER?

1. ***REGISTER***
   - Go to studentconsult.com; click “Register Now”
   - Fill in your user information and click “Activate your account”
2. ***ACTIVATE YOUR BOOK***
   - Click the “Activate Another Book” button
   - Gently scratch off the surface of the sticker with the edge of a coin to reveal your Pin code
   - Enter it into the “Pin code” box; select the title you’ve activated from the drop-down menu
   - Click the “Activate Book” button

Access to, and online use of, content through the Student Consult website is for individual use only; library and institutional access and use are strictly prohibited. For information on products and services available for institutional access, please contact our Account Support Center at (+1) 877-857-1047. Important note: Purchase of this product includes access to the online version of this edition for use exclusively by the individual purchaser from the launch of the site. This license and access to the online version operates strictly on the basis of a single user per PIN number. The sharing of passwords is strictly prohibited, and any attempt to do so will invalidate the password. Access may not be shared, resold, or otherwise circulated, and will terminate 12 months after publication of the next edition of this product. Full details and terms of use are available upon registration, and access will be subject to your acceptance of these terms of use.

For technical assistance: email online.help@elsevier.com
call 800-401-9962 (inside the US) / call +1-314-995-3200 (outside the US)

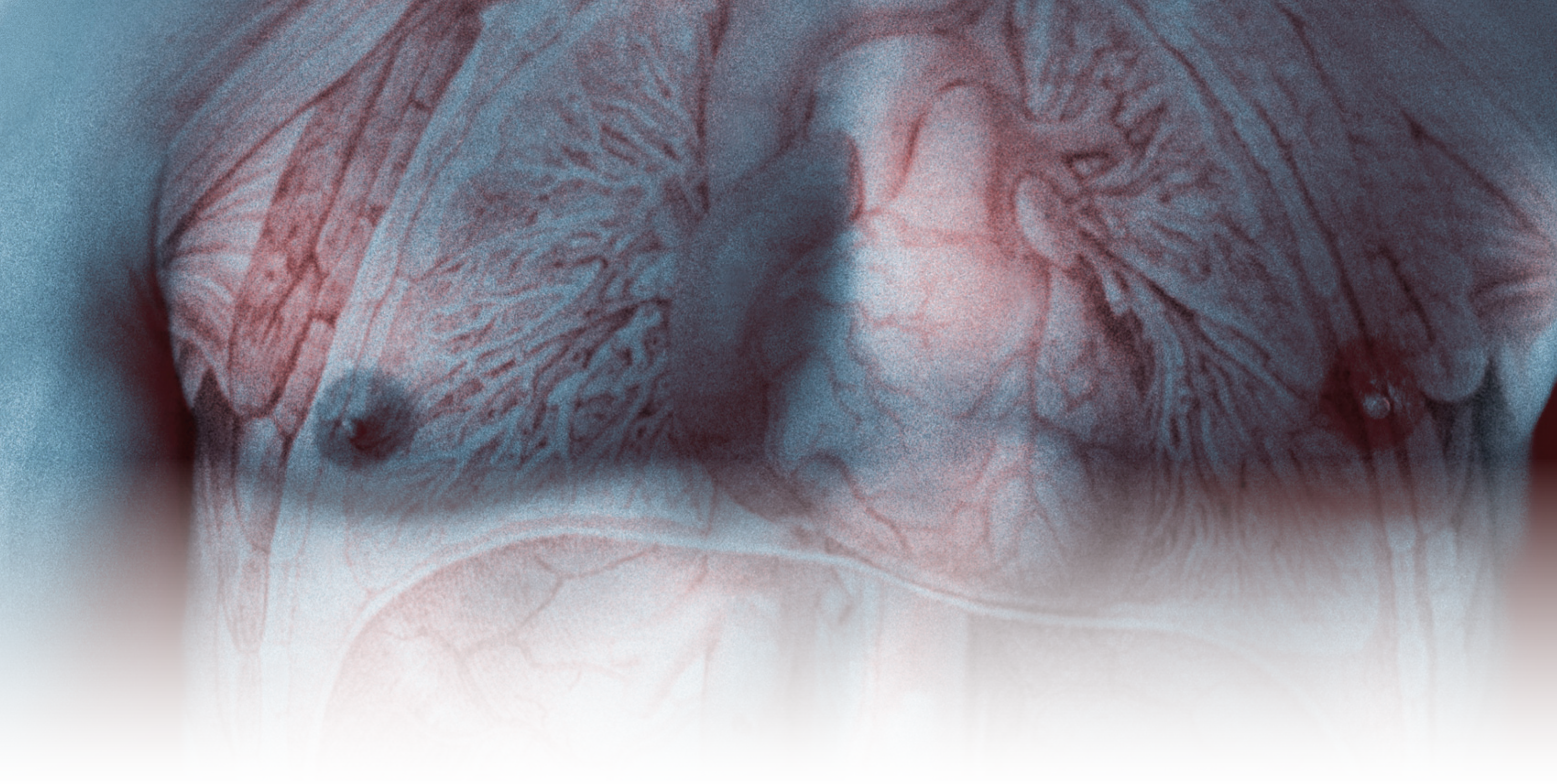

mcminn & ABRAHAMS'

CLINICAL ATLAS OF HUMAN ANATOMY

SEVENTH EDITION

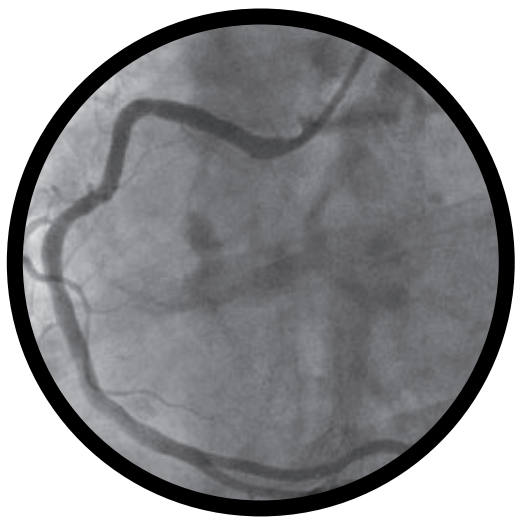

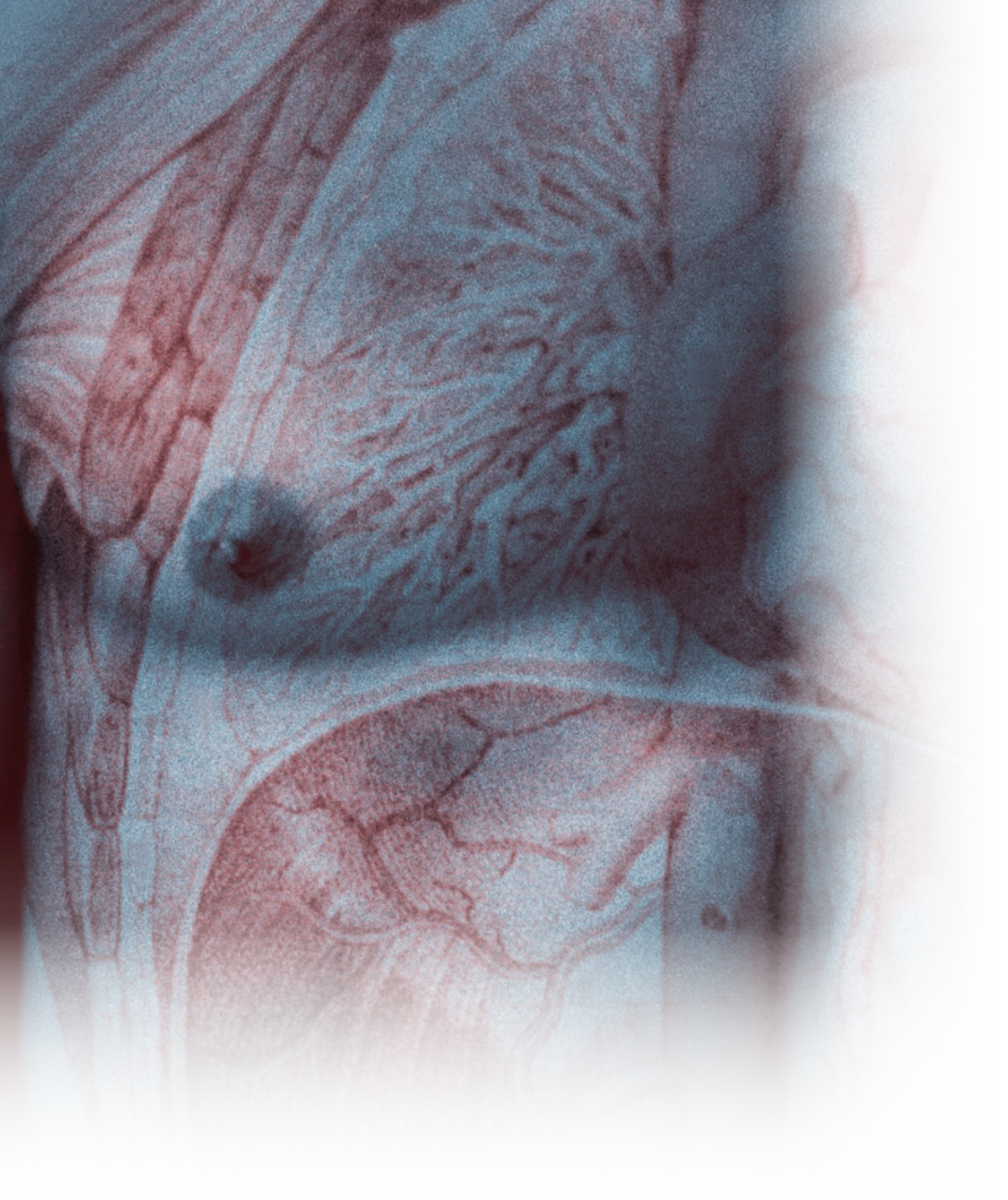

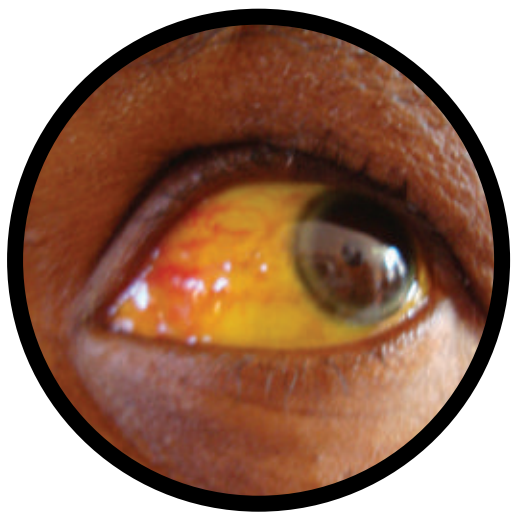

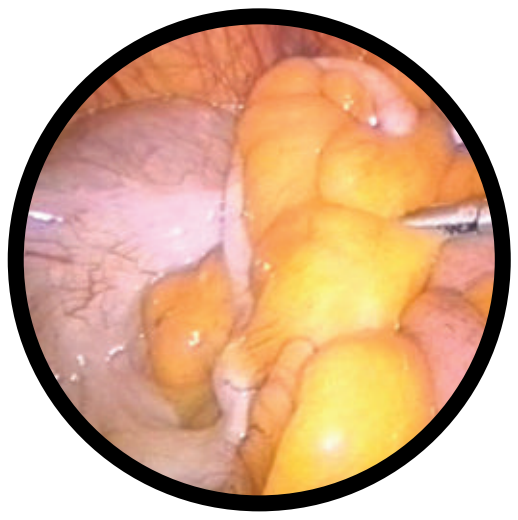

Content Strategist: Madelene Hyde
Content Development Specialists: Rachael Harrison, Sharon Nash
Publishing Services Manager: Patricia Tannian
Senior Project Manager: Sarah Wunderly
Design: Russell Purdy
Illustration Manager: Jennifer Rose
Illustrator: Oxford Designers & Illustrators

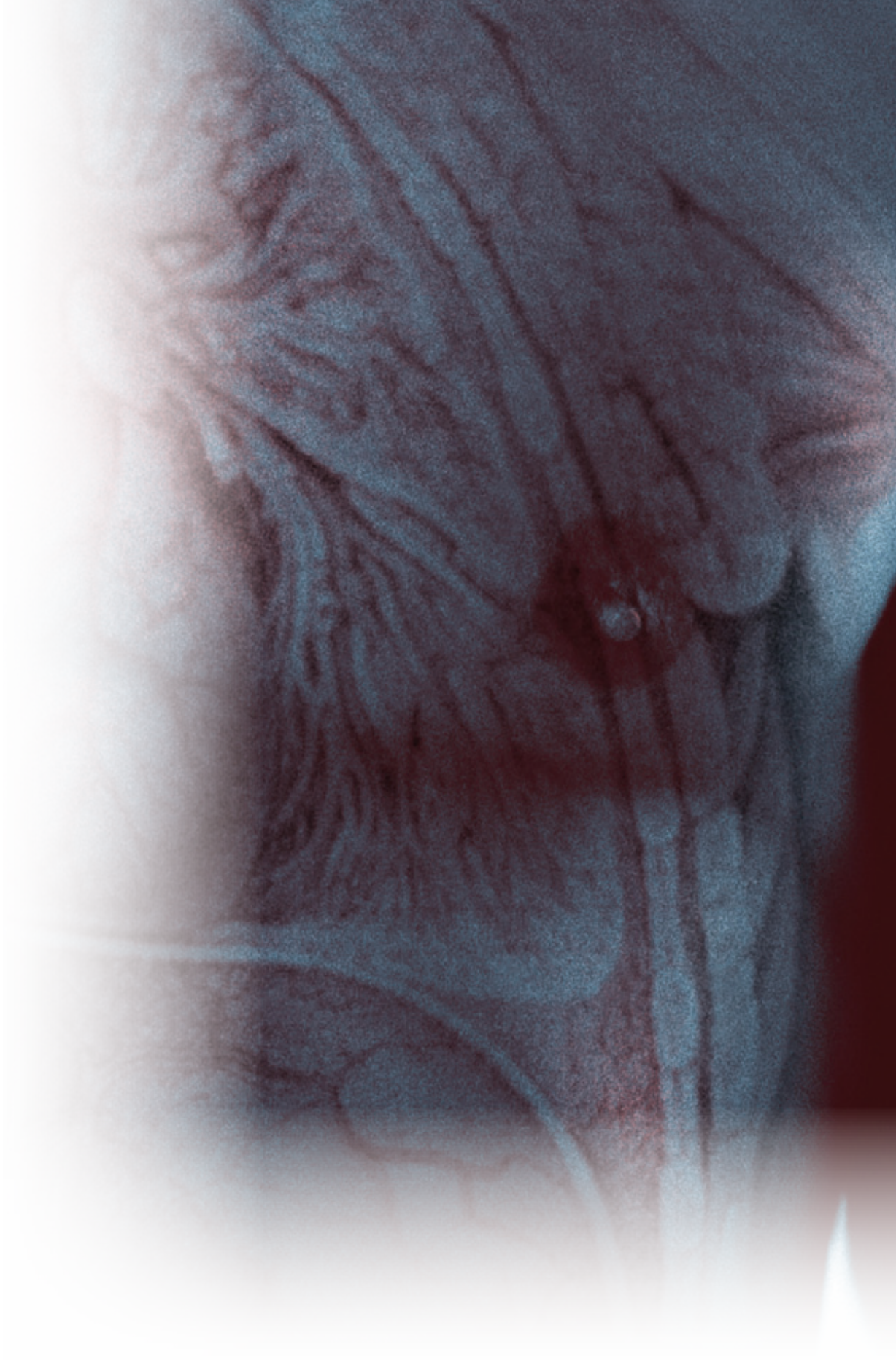

McMinn & Abrahams'

Clinical Atlas of Human Anatomy

SEVENTH EDITION

Peter H. Abrahams, MB BS, FRCS (Ed), FRCR, DO (Hon) FHEA
Professor of Clinical Anatomy, Warwick Medical School, UK
Professor of Clinical Anatomy, St. George's University, Grenada, W.I.
National Teaching Fellow 2011, UK
Life Fellow, Girton College, Cambridge, UK
Examiner, MRCS, Royal Colleges of Surgeons (UK)
Family Practitioner, Brent, London, UK

Jonathan D. Spratt, MA (Cantab), FRCS (Eng), FRCS (Glasg), FRCR
Consultant Clinical Radiologist, University Hospital of North Durham, UK
Examiner in Anatomy, Royal College of Radiologists, UK
Visiting Fellow in Radiological Anatomy, University of Northumbria, UK
Visiting Professor of Anatomy, St. George's Medical School, Grenada, W.I.

Marios Loukas, MD, PhD
Professor and Chair, Department of Anatomical Sciences
Dean of Research, School of Medicine
St. George's University, Grenada, W.I.

Albert-Neels van Schoor, BSc MedSci, BSc (Hons), MSc, PhD
Senior Lecturer, Department of Anatomy, School of Medicine, Faculty of Health Sciences
University of Pretoria, Pretoria, Gauteng, South Africa

For additional online content visit studentconsult.com

ELSEVIER
MOSBY

ELSEVIER
MOSBY

© 2013, Elsevier Limited. All rights reserved.

First edition 1977 by Wolfe Publishing
Second edition 1988 by Wolfe Publishing
Third edition 1993 by Mosby-Wolfe, an imprint of Times Mirror International Publishers Ltd
Fourth edition 1998 by Mosby, an imprint of Mosby International Ltd
Fifth edition 2003 by Elsevier Science Ltd
Sixth edition 2008 by Elsevier Ltd

The right of Peter H. Abrahams, Jonathan D. Spratt, Marios Loukas and Albert N. Van Schoor to be identified as author of this work has been asserted by him in accordance with the Copyright, Designs and Patents Act 1988.

All photographs taken by Ralph Hutchings, photographer for Imagingbody.com, remain in his sole copyright.

No part of this publication may be reproduced or transmitted in any form or by any means, electronic or mechanical, including photocopying, recording, or any information storage and retrieval system, without permission in writing from the publisher. Details on how to seek permission, further information about the Publisher's permissions policies and our arrangements with organizations such as the Copyright Clearance Center and the Copyright Licensing Agency, can be found at our website: www.elsevier.com/permissions.
This book and the individual contributions contained in it are protected under copyright by the Publisher (other than as may be noted herein).

Notices

Knowledge and best practice in this field are constantly changing. As new research and experience broaden our understanding, changes in research methods, professional practices, or medical treatment may become necessary.

Practitioners and researchers must always rely on their own experience and knowledge in evaluating and using any information, methods, compounds, or experiments described herein. In using such information or methods they should be mindful of their own safety and the safety of others, including parties for whom they have a professional responsibility.

With respect to any drug or pharmaceutical products identified, readers are advised to check the most current information provided (i) on procedures featured or (ii) by the manufacturer of each product to be administered, to verify the recommended dose or formula, the method and duration of administration, and contraindications. It is the responsibility of practitioners, relying on their own experience and knowledge of their patients, to make diagnoses, to determine dosages and the best treatment for each individual patient, and to take all appropriate safety precautions.

To the fullest extent of the law, neither the Publisher nor the authors, contributors, or editors, assume any liability for any injury and/or damage to persons or property as a matter of products liability, negligence or otherwise, or from any use or operation of any methods, products, instructions, or ideas contained in the material herein.

British Library Cataloguing in Publication Data
A catalogue record for this book is available from the British Library

ISBN: 978-0723-43697-3
International edition: 978-0723-43698-0

Working together to grow
libraries in developing countries
www.elsevier.com | www.bookaid.org | www.sabre.org
ELSEVIER BOOK AID International Sabre Foundation

Printed in China

Last digit is the print number: 9 8 7 6 5 4 3 2 1

Dedication and Preface

"To all our long-suffering spouses and children who rarely see us enough and to our international students who see us too much!"

As with most academic literature, there is a large element of truth to the often misquoted "If I have seen further it is by standing on ye sholders of Giants" as written by Sir Isaac Newton to Robert Hooke in 1676. In our case it is not only the giants of our own discipline of anatomy and especially its clinical branch; this atlas has also benefited from a real contribution from our students, colleagues, teachers and mentors.

This new seventh edition of McMinn and Abrahams' *Clinical Atlas of Human Anatomy* is the culmination of 40 years' work by a huge team. The first three editions of this seminal colour atlas were authored by Professor Bob McMinn, Ralph Hutchings and Bari Logan, and the last four editions have been the results of a combined academic endeavour of the now departed "giants" Professors John Pegington (University College London), Sandy Marks (University of Massachusetts, USA) and Hanno Boon (Pretoria, South Africa) working with myself (PHA). For previous dedications see the sixth edition dedication online (www.studentconsult.com).

In the autumn of 2012 we heard the sad news of Bob McMinn's passing at the age of 88. Following in his father's footsteps Bob, graduated from Glasgow University in medicine in 1947. His main academic career was in London, first as Professor at Kings College, London and then as the William Collins Professor at the Royal College of Surgeons of England. Along the way Bob not only gained an MD but a PhD as well in the field of wound healing and tissue repair. However, it is for this revolutionary *McMinn's Colour Atlas of Human Anatomy,* first produced in 1977, that Bob's name is known worldwide. Not only will this seventh edition bring sales to over 2 million in some 30 languages, including Latin, Korean, Chinese, Japanese and most European languages, but this book is also very popular with the art world – something of which he was most proud.

As a founding member of the British Association of Clinical Anatomists and past secretary of the Anatomical Society of Great Britain, Bob was one of my mentors (PHA) and a truly kind, warm-hearted and generous gentleman, whose invitation to work with him on the third edition in 1989 changed my own academic direction and pointed me to the "light" of clinical anatomy. I shall always remember the BACA/AACA

Cambridge meeting in 2000 when Bob, the true Scot, arrived for his presentation as only a Scot can!

This new edition is authored by PHA and Jonathan Spratt, a Director of Radiology at Durham who worked on the sixth edition, and to replace the lost multi-talented giants of clinical anatomy we have transfused some new young anatomical blood.

First we have Professor Marios Loukas MD, PhD, Chair of Department of Anatomical Sciences and Dean of Research, at St. George's University, Grenada, West Indies, who for the last decade has made anatomical waves with his amazing energy and prolific academic output. PHA has known Marios since he was a first-year medical student in Poland and noted his potential even 15 years ago. He is now an internationally recognised and published author and brings to this new edition his wide European education in Greece, Poland and

Germany, as well as his postgraduate experience in Harvard and the Caribbean.

To add to this truly global academic input we also welcome Dr. Albert Van Schoor, anatomist from Pretoria and Honorary Secretary of the Anatomical Society of Southern Africa (ASSA), who is truly following in the footsteps of his own mentor, Professor Hanno Boon. Albert's passion for both teaching and clinically applied research – his PhD was on clinical anatomy of practical procedures in children – was instilled in him by Professor Boon. His African experience and connections with physicians have brought us illustrations from the developing world that often are unavailable in Western culture. Gross pathologies seen in the tropics are vividly illustrated on our web pages.

We, all the authors both old and new, have essentially followed the pattern of Bob McMinn's original work to produce an atlas of the human body aimed at health professionals but have moved the emphasis to correlating the "real" human body dissections directly with clinical practice such as radiology, endoscopy or clinical problems, both in the atlas itself and especially in the clinical vignettes on the website. To this end we have included and done the following:

- Added 100+ new dissections including lymphatics
- Added 100+ radiological images (MR and CT) correlated with dissections
- Added 300+ radiological images for the clinical vignettes on the web
- Increased the clinical anatomy case vignettes to nearly 500 – all now on the web with full download ability as jpeg files onto any student's notes.
- Increased the images on the web to 2000+ which include clinical cases operative images, radiological techniques, endoscopy, etc.
- Added a new video section of 200+ 3D rotations and video loops (mainly 64-slice CT scan reconstructions and angiography) to help students appreciate the anatomical three-dimensional relationships (thanks especially to Dr. Richard Wellings, University Hospitals Coventry and Warwickshire, for most of this collection).

We hope that teachers, especially those in less developed parts of the world, will now be stimulated to give presentations with the latest technology to help their students learn anatomy in all its 3D glory. These video loops are marked by the video icon shown in the key below on the relevant page in the atlas and are all to be found in the 3D files on the web filed under anatomical structures (e.g., arteries, veins, brain, thorax). We hope this latest technology will excite all students in their study of the human body.

For additional electronic content look out for the below icons:

Go online to view 200+ 3D rotations and video loops

Go online to view 2000+ clinical cases

PHA
JS
ML
AVS

Acknowledgements

Dissections

Heartfelt thanks to all our **donors and their families** for their ultimate donation for the benefit of mankind and future generations of medical knowledge. This supreme gift to mankind educates and enriches the human experience for generations to come, for today's medical students are tomorrow's clinicians and professors.

The production of this atlas and accompanying web site has been a huge team effort over 5 years and has involved prosectors and professors, teachers and students from four continents but especially from England, South Africa, the United States and the West Indies. We, the four authors, would like to thank all those who worked with us to deliver this new exciting clinical atlas and accompanying web site.

Prosection preparation

Daniële Cavanagh, Franci Dorfling, Heinrich Hesse, Professor Greg Lebona , Lané Prigge, Soné du Plessis, all from the University of Limpopo, Medunsa Campus, South Africa

Nkhensani Mogale, University of Johannesburg, South Africa

Rene Human-Baron, Elsabè Smit, University of Pretoria, South Africa

Theofanis Kollias, Elizabeth Hogan, Mohammed Irfan Ali and faculty Drs. Kathleen Bubb , Deon Forester, and Ewarld Marshall, Department of Anatomical Sciences, St. George's University School of Medicine, Grenada, West Indies.

Many of the new dissections were carried out at the second Hanno Boon Masterclass in Grenada in July of 2011. Those contributing their skills and in honouring the international memory of Professor Hanno Boon (R.I.P.) were Vicky Cottrell, Paul Danse, Maira du Plessis, Alison Tucker, Richard Tunstall, George Salter, Shane Tubbs and the following Warwick University Medical students in the UK—Ross Bannon, Matthew Boissaud-Cooke, Michael Brown, Edward Dawton, Sarah Diaper, Zara Eagle, Elizabeth Jane Harris, Morag Harris, Daniel Lin, Riwa Meshaka, Rob Neave, Charlotte Oakley, Chris Parry, Alison Rangedara, Farah Sadrudin, Jon Senior, Catherine Tart, Adam Walsh, Melanie Whitehead, John Williams, Katie Wooding, Dr. James Chambers.

The second Hanno Boon memorial dissection masterclass participants, Grenada, 2011.

Photographic, technical and research

Laura Jane van Schoor (Laura Jane Photography, South Africa) and Joanna Loukas (Department of Anatomical Sciences, St. George's University) for their photographic skills.

Marius Loots, Gert Lewis, and Samuel Ngobeni (Department of Anatomy, University of Pretoria, South Africa) for technical assistance.

Carslon Dominique, Rodon Marast, Christopher Belgrave, Ryan Jacobs, Nadica Thomas-Dominique, Jacqueline Hope, Salisha Thomas and Yvonne James of the Department of Anatomical Sciences at St. Georges University, for their technical and lab assistance.

The following research fellows of the Department of Anatomical Sciences at St. Georges University for their contribution—Drs. Asma Mian, Irfan Chaudhry, Philip Veith, Amit Sharma, Edward Sorenson, Matthew Prekupec and Christa Blaak.

All the mistakes, though hopefully very few, are ours but the following individuals have kept the errors to a minimum with

their proof reading skills and expert knowledge: Eng-Tat Ang, PT, PhD; James Chambers, MBChB, BSc(Hons); Sundeep Singh Deol MSc, PhD, MD; Petrut Gogalniceanu, BSc, Med, MRCS; Ruth Joplin, PhD; David A. Magezi MA(Cantab), BM BCh (Oxon), PhD (Notts); David Metcalfe, BSc(Hons), LLB(Hons), MRCS; Barry S Mitchell, BSc, PhD, MSc, FSB, FHEA; Tom Paterson BSc(Hons)Anatomy, MBChB Glasgow; Jamie Roebuck BSc, MBChB, FHEA; R. Subbu, MBChB, MRCS, BSci(HONS); Kapil Sugand, BSc, MBBS; Richard Tunstall, BMedSci, PhD, PGCLTHE, FHEA; Tom Turmezei, MA, MPhil, BMBCh, FRCR; Anne Waddingham, BSc, LCGI.

Clinical, operative, endoscopic, ultrasound, other imaging modalities and videos cases (see also the sixth edition clinical cases acknowledgements on the web page).

Drs. Elias Abdulah MD, Chrystal Antoine MD, Nicole Avril MD, Prof. Danny Burns MD, PhD, Melissa Brandford MD, Katusha Cornwall MD, Adegberno Fakoya MD, Nicole George MD, Prof. Robbie Hage MD, PhD, DLO, MBA, ENT Surgeon, Kennard Philip MD, and Kazzara Raeburn MD, Department of Anatomical Sciences, St. George's University, Grenada, West Indies; Prof. Kitt Shaffer MD, PhD, Department of Radiology, Boston University, Boston Massachusetts, United States; Dr. Robert Ward MD, Department of Radiology, Tufts University, Boston, Massachusetts, United States; Dr. MA Strydom, Steve Biko Academic Hospital, Pretoria, South Africa; Drs. MJ Heystek, M Maharaj, E Poulet, and E Raju, Department of Family Medicine, Tshwane District Hospital, University of Pretoria, South Africa; Dr. PS Levay and Prof. D van Zyl, Department of Internal Medicine, Kalafong Hospital, University of Pretoria, South Africa; Dr. AK Mynhardt, University of Pretoria, South Africa; Dr. MY Gamieldien, Oral & Dental Hospital, University of Pretoria, South Africa; Members of the Department of Plastic and Reconstructive Surgery, University of Limpopo (Medunsa campus), South Africa; Dr. Richard Wellings, Consultant Radiologist and Hon Associate Professor, UHCW Trust and Warwick Medical School, United Kingdom; Ms.Kavita Singh and Mr. Janos Balega, Consultant Gynaecological Oncologists, Sandwell and West Birmingham Hospitals Trust, Pan-Birmingham Gynaecology Cancer Centre Birmingham, United Kingdom; Dr. Adam Iqbal, UHCW Trust and Warwick Medical School; Mr. Michael Brown and Mr. Mark Mobley, Warwick Medical School, University of Warwick, Coventry, United Kingdom; Ms. Nadia Boujo and Mr. Alfred Boujo, London; Dr. Vibart Yaw, Consultant Oral and Maxillofacial Surgeon, General Hospital, St. George's, Grenada, West Indies; Dr. Ankur Gulati, Cardiology Specialist Registrar, The London Chest Hospital, UK

User Guide

This book is arranged in the general order 'head to toe'. The Head and Neck section (including the brain) is followed by the Vertebral column and spinal cord, then Upper limb, Thorax, Abdomen and pelvis, Lower limb and finally Lymphatics. In each section, skeletal elements are shown first followed by dissections, with surface views included for orientation. All structures are labelled by numbers, and these are identified in lists beside each image. An arrowhead at the end of a leader indicates that the structure labelled is just out of view beyond the tip of the arrow. Text has been limited to that needed to understand how the preparation was made, and is not intended to be comprehensive.

Contents

Systemic review

Skeleton
Muscles
Arteries
Veins
Nerves
Dermatomes
Cross-sections of the human body

Head, neck and brain 1

Skull	1
Skull bones	18
Neck	28
Root of the neck	36
Face	38
Temporal and infratemporal fossae	40
Infratemporal fossa	42
Deep infratemporal fossa	44
Pharynx	45
Larynx	48
Cranial cavity	51
Eye	54
Nose	58
Nose and tongue	59
Ear	60
Brain	62
Cranial nerves	73
Clinical thumbnails	80

Vertebral column and spinal cord 2

Vertebral column overview	83
Back and shoulder	84
Vertebrae	85
Sacrum	89
Sacrum and coccyx	90
Bony pelvis	92
Vertebral ossification	93
Vertebral column and spinal cord	94
Surface anatomy of the back	100
Muscles of the back	101
Sub-occipital triangle	104
Vertebral radiographs	106
Clinical thumbnails	108

Upper limb 3

Upper limb overview	109
Upper limb bones	110
Shoulder	126
Axilla	138
Arm	143
Elbow	145
Forearm	148
Hand	154
Wrist and hand radiographs	169
Clinical thumbnails	170

Thorax 4

Thorax overview	173
Thoracic bones	174

Thoracic wall surface markings and breast 178
Breast 179
Thoracic wall and surface markings 180
Thoracic wall 181
Thoracic viscera 184
Heart 185
Mediastinum 192
Mediastinal imaging 196
Lungs 197
Superior mediastinum 205
Superior mediastinum and thoracic inlet 206
Superior thoracic aperture (thoracic inlet) 208
Posterior mediastinum 209
Intercostal nerves and thoracic joints 211
Aorta and associated vessels 212
Diaphragm 213
Oesophageal imaging 214
Clinical thumbnails 215

Abdomen and pelvis 5

Abdomen overview 217
Anterior abdominal wall 218
Male pelvis 225
Inguinal region 226
Upper abdomen 227
Intestinal imaging 240
Liver 244
Gall bladder imaging 247
Spleen 249
Spleen and intestines 250
Intestines 251
Small intestine 252
Kidneys and suprarenal glands 253
Kidneys and kidney imaging 259
Diaphragm and posterior abdominal wall 260
Posterior abdominal and pelvic walls 261
Pelvic walls 263
Male inguinal region, external genitalia 265
Male pelvis 266
Pelvic vessels and nerves 269
Pelvic ligaments 271
Female pelvis 272
Female perineum 276
Male perineum 278
Clinical thumbnails 280

Lower Limb 6

Lower limb overview 285
Lower limb bones 286
Foot bones 310
Foot and ankle bones 312
Ankle bones 313
Development of lower limb bones 314
Gluteal region 316
Thigh 318
Front of thigh 320
Hip joint 324
Knee 328
Knee radiographs 336
Leg 337
Ankle and foot 344
Foot 350
Ankle and foot imaging 354
Clinical thumbnails 355

Lymphatics 7

Lymphatic system 359
Lymphangiography 359
Thymus 360
Chest 360
Palatine tonsils 360
Neck 361
Thoracic duct 362
Right axilla 363
Cisterna chyli and thoracic duct 365
Female pelvis 366
Gross lymphadenopathy of the pelvis 367
Thigh and superficial inguinal lymph nodes 368
Clinical thumbnails 369

Index 371

Orientation

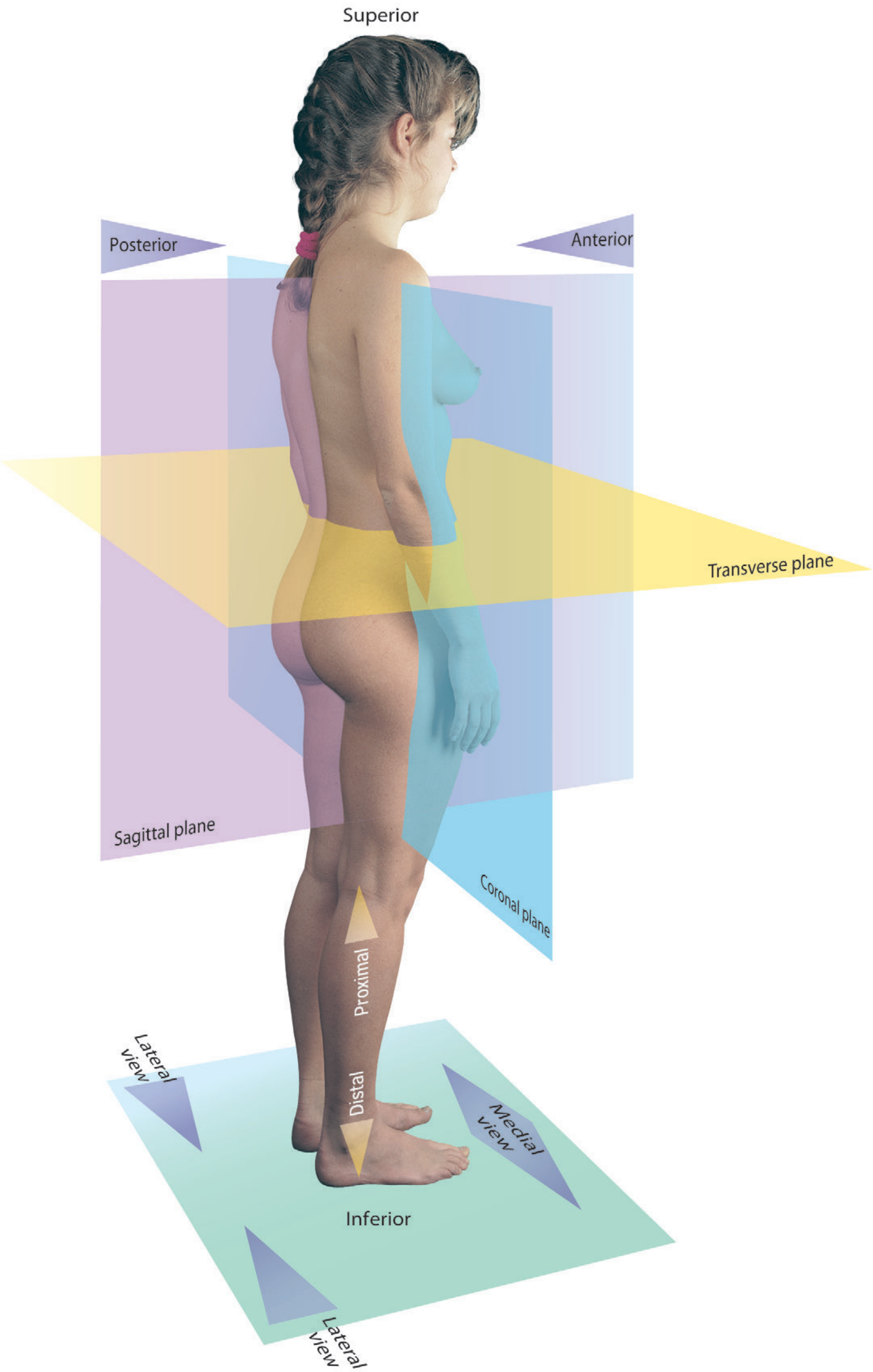

This page intentionally left blank

Dedication from the sixth edition

The preparation of this 6th edition of the McMinn Atlas has in many ways been a challenge made more difficult by two tragedies. First, not long after the appearance of the 5th edition, Sandy Marks Jr was suddenly taken from us. His untimely death robbed *Clinical Anatomy* of an Editor, the AACA of its Past President and Honoured Member, and I of my 'anatomical older brother', who had assisted and guided the 4th and 5th editions. His international respect and worldwide friendships are reflected in a collection of memories to be found on the DVD. None of these worthy documents replace anything of the warm-hearted family man who was a Colossus in the world of international clinical anatomy.

So the task of filling such big shoes was not an easy one. After much searching, the world over, I found at last a young medical anatomist who not only was a former PhD student of mine but truly had the potential to fill those shoes. Hanno Boon, clinical anatomist from Pretoria University, joined me with Jonathan Spratt, another former student of surgical anatomy, who is a Radiologist at the University Hospital of North Durham. This young but multi-talented team now started in earnest, with various meetings on three continents, in the preparation for this 6th edition.

Most of the major decisions of our future plans were made when a second tragedy struck. This time it was the senseless murder of Hanno in an armed robbery just 3 miles from his home in Mamelodi, where every week he did emergency medicine to complement his full-time day job as Professor of Clinical Anatomy in Pretoria University. This disgusting event robbed his young family of a caring father, me of an 'academic son' and academic clinical anatomy of one of its brightest rising stars. He had already, at the tender age of 34, been recognised and honoured by the BACA, AACA and EACA and was to be the new African editor of the journal *Clinical Anatomy.*

This most untimely death was recorded not only in his own medical school and South Africa publications but in journals as far apart as Turkey, USA and the Caribbean, where he had been a popular visiting professor (see DVD). All who knew him will never forget the boyish smile, quiet charm and sharp intellect of a devoted religious family man whose humble nature belied his passion and focus for medical academia in all its aspects.

Thus the preparation of this new atlas lost a most important member. However, to honour Hanno's contribution to clinical anatomy, a Hanno Boon Dissection Master Class attracted teachers and students from all over South Africa as well as the USA and Europe (see acknowledgements) and most of the new dissections in this edition were performed during that master class.

He would, I am sure, be proud to see this new edition with nearly all his suggestions of new content, dissections, and the wide-reaching DVD illustrating so many aspects of anatomy within clinical practice. These clinical cases were prompted by the landmark publication of the AACA, 'A clinical anatomy curriculum for the medical student of the 21st century', *Clinical Anatomy* 9: 71–99, 1996. We all felt that both teachers and students of the human body would welcome this extensive teaching resource. It consists of clinical cases, operative photographs, endoscopic shots, dissections of procedures and a library of imaging pathology as a practical way of integrating anatomy into all the health sciences and general medical education.

This edition, with its many clinical cross-references, new dissections, related endoscopies and a complete new section on lymphatics, as well as the one thousand photographs for personal study available on the enclosed DVD will, we hope, stand as a memorial and proud memory in years to come for Hanno's young children.

Acknowledgements from the sixth edition

An atlas of this kind is not only the work of the authors but of numerous technical, scientific and clinical friends and colleagues who have been so generous of their knowledge and given permission for the inclusion of their original photographs of clinical cases. Hopefully, like the Carlsberg advert, this book and DVD are 'probably the greatest image collection of clinical anatomy cases in the world'. However, this dissection atlas would not be possible were it not for the talents of a special group of people – the prosectors and dissectors listed below.

Dissections Hanno Boon Masterclass, June 2005, Pretoria.

The following professors, doctors and students worked closely together as a team to honour the name of Professor Hanno Boon who had been their student, friend, mentor and an inspiration (see Dedication).

Donal Shanahan (UK); Stephen Carmichael, Rob Spinner (USA); Jan Meiring, Marius Bosman, Linda Greyling, Japie v Tonder, Andrea da Silva, Corrie Jacobs, Nanette Lizamore, Anna Oettle, Nadia Navsa, Albert van Schoor (Pretoria); Helena de Villiers, Daleen Raubenheimer, Francis Klopper (UFS); Nirusha Lachman (DIT).

Post-graduate students: Johan Aikman, Quenton Wessels, Carl Holt, Dawie Kruger, Stephen Lambert, Desire Schabort, Renee Botha, Maira du Plessis, Claire Robinson (Pretoria). *Support team in Pretoria*: Gert Lewis, Marius Loots, Marinda Pretorius, Coen Nienaber, Alet van Heerden, Tshepo Lelaka.

During the past 5 years, the following worldwide contributions have also produced some magnificent dissections, which appear for the first time in this 6th edition.

Mr Bari Logan, formerly The University Prosector, Department of Anatomy, University of Cambridge, England; Dr Marios Loukas, Associate Professor of Anatomy, St George's University, Grenada, West Indies and medical students Lynsey Stewart and B. Hallner from the American University of the Caribbean, St Maarten, West Indies; Ms Lynette Nearn-Forest, Department of Anatomy and Cell Biology, University of Illinois at Chicago (UIC), Illinois, USA; Dr Donal Shanahan, Prosector, Department of Anatomy and Clinical Skills, School of Medical Education Development, University of Newcastle-Upon-Tyne, UK; Ms Sue Standley, Department of Anatomy, University of East Anglia, Norwich, UK.

Clinical cases

The authors and publishers thank the following individuals and their institutions for kindly supplying various clinical, operative, endoscopic and imaging photographs for both the book and especially the DVD.

Dr Solomon Abrahams, Consultant Physiotherapist – Clinical Director, 'Anatomie Physiotherapy Plus', Harrow, Middlesex; Dr Tania Abrahams, Paediatrician, Great Ormond Street Hospital, London; Dr Rosalind Ambrose, Consultant Radiologist, St Vincent, West Indies; Ms Louise Anning, medical student, Girton College, Cambridge; Mr Chris Anderson, Consultant Urologist, Cromwell Hospital, London; Dr Ray Armstrong, Rheumatologist, Southampton General Hospital, Southampton and 'Arthritis Research Campaign (ARC)'; Ms Sally Barnett, Australian athlete, London; Private Johnson Gideon Beharry VC of 1st Battalion Prince of Wales' Royal Regiment and Grenada, West Indies; Professor Paul Boulos, Institute of Surgical Studies, UCL, Medical School, London; Mr John Bridger, Surgeon Anatomist, Department of Anatomy, University of Cambridge; Professor Norman Browse, Emeritus Professor of Surgery – and Hodder Arnold Publishers to use illustrations from *Symptoms and Signs of Surgical Disease* 4th edn. 2005; Mr Carl Chow, Obstetrician and Gynaecologist, Kingston Hospital NHS Trust, Surrey; Professor Bruce Connolly, Hand Surgeon, Sydney Hospital, Sydney, Australia; Mr John Craven, formerly Consultant Surgeon, York District Hospital, York; Mr Paddy Cullen, Consultant Vascular Surgeon, University Hospital of North Durham, Durham; Mr D Dandy, Orthopaedic Consultant and Churchill Livingstone for permission to use illustrations from 'Arthroscopic Management of the Knee'; Mr Alan Davis, Optometrist, Ashdown & Collins, Kensal Rise, London; Dr Marc Davison, Anaesthetist, Stoke Mandeville Hospital, Aylesbury, Bucks; Mr Simon Dexter, Consultant Surgeon, Leeds Infirmary, Leeds; Mr Michael Dinneen, Consultant Urologist, Chelsea and Westminster and Charing Cross Hospitals, London; Professors Enrico Divitiis and Paolo Cappabianca, Neurosurgeons – and Karl Storz Endo-press TM, Tuttlingen, Germany for permission to reproduce pictures from *Endoscopic Pituitary Surgery – Anatomy and Surgery of the Transsphenoidal Approach to the Sellar Region* 2004; Professor J.F. Dumon, France; Ms Brenda Ernst, medical student, SGU, Grenada West Indies; Ms Oghenekome Gbinigie, medical student, Girton College, Cambridge; Professor Francis Nichols, Cardiothoracic Surgeon, Mayo Clinic, Rochester, Minnesota, USA; Professor Ralph Ger, Surgeon and Prof Todd Olson, Anatomist, Albert Einstein College of Medicine New York – and Parthenon Publishers to use illustrations from *Essentials of Clinical Anatomy* 2nd edn. 1996; Professor J. Gielecki, Chairman, Department of Anatomy, Silesian Medical University, Poland; Ms Natalie Gounaris-Shannon, medical student, Girton College, Cambridge; Mr Nadim Gulamhuseinwala, Department of Plastic Surgery, Guy's and St Thomas' Hospitals, London; Mr Fares Haddad, Consultant Orthopaedic and Trauma Surgeon, UCLH, London; Mr I. C. Hargreaves, Hand and Wrist Surgeon, St Luke's Hospital,

Sydney, Australia; Dr David Heylings, Senior Lecturer in Anatomy, School of Medicine Health Policy and Practice, UEA, Norwich; Professor Michael Hobsley, formerly Head of Dept of Surgical Studies, The Middlesex Hospital Medical School, London; Dr Mike Jones, Consultant in Infectious Diseases, Director Edinburgh International Health Centre, Edinburgh, Scotland; Ms Megan Kaminskyj, medical student, SGU, Grenada West Indies; Mr Umraz Khan, Plastic Surgeon, Charing Cross Hospital, London; Mr Stephen Kriss, Podiatrist, Hospital of St John and St Elizabeth, London; Dr Suzanne Krone, Anaesthetist, Queen Victoria Hospital, East Grinstead; Professor Stefan Kubik, Anatomist, formerly Zurich University, Switzerland; Dr Lahiri, Cardiologist and the 'Wellington Hospital Cardiac Imaging and Research Centre', London; Professor John Lumley, Director Vascular Surgery Unit, St Bartholomew's and Great Ormond Street Hospitals, London; Mr Alberto Martinez-Isla, Laparoscopic Surgeon, Charing Cross and Ealing Hospitals, London; Mr Nick Dawe and Medtronic medical equipment company; Professor Jan Meiring, Chairman and Clinical Anatomist, University of Pretoria, South Africa; Ms Kathryn Mitchell, medical student, Bristol University, Bristol; Professor Antony Narula, Head and Neck Surgeon, St Mary's Hospital, London; Dr Barry Nicholls, Anaesthetist and Ultrasonographer, Musgrove Park Hospital, Taunton, Somerset and B. Harris, K. Hill and S. Moss from Toshiba Medical Systems; Dr Nkem Onyeador, Paediatrician and Arochukwu Medical Mission, Nigeria; Mr David Peek, medical student, SGU, Grenada, West Indies; Mr Rob Pollock, Orthopaedic Surgeon, RNOH, Stanmore, Middlesex; Professor Stephen Porter, Oral Medicine, UCL Eastman Dental Institute, London; Dr Lonie Salkowski, Associate Professor of Radiology, University of Wisconsin School of Medicine and Public Health, Madison, WI, USA; Mr Ertan Saridogan, Gynaecologist, The Portland Hospital, London; Mr Peter Scougall, Hand Surgeon, Sydney, Australia; Mr Julian Shah, Senior Lecturer in Urology, Institute of Urology UCL, London; Smith and Nephew Healthcare, Cambridge – Arthroscopic diagrams of limb joints; Mr Rajeev Sharma, Consultant Orthopaedic Surgeon, QE2 Hospital, Welwyn Garden City, Herts; Mr Spencer Quick, medical student, Bristol University Medical School, Bristol; Professor Rob Spinner, Neurosurgeon, Mayo Clinic, Rochester, Minnesota, USA; Professor M. Stoller, Department of Urology, UCSF, San Francisco, USA; Dr William Torreggiani, Radiologist, The Adelaide and Meath Hospital, Tallaght, Dublin, Ireland; Miss Gilli Vafidis, Ophthalmologist, Central Middlesex Hospital, London; Mr Peter Valentine, ENT Consultant, Royal Surrey County Hospital Guilford, Surrey; Mr Joseph Venditto, medical student, SGU, St Vincent, West Indies; Mr Richard Villars, Orthopaedic Consultant and Butterworth Heinemann for permission to reproduce illustrations from 'Hip Arthroscopy'; Mr Peter Webb, Consultant Surgeon, Mayday Maritime Hospital, Kent; Mr Theo Welch, Surgeon, Fellow Commoner Queens' College, Cambridge; Professor Jamie Weir, Department of Clinical Radiology, Grampian University Hospitals Trust, Aberdeen, Scotland – and Imaging Atlas of Human Anatomy 3rd edn,, Elsevier 2003; Mr Heikki Whittet, ENT Surgeon, Singleton Hospital , Swansea, Wales; Professor Tony Wright, Director Ear Institute, UCL Hospitals, London; Dr C. B. Williams, Colonoscopist, The London Clinic Endoscopy Unit, London.

Art, photographic and technical assistance

I would also like to thank Erica Saville, Elizabeth Hawker, Valerie Newman, David Robinson, Marius Loots, Adrian Newman, Richard Tibbetts at Antbits and Kim Knoper, for their secretarial, photographic and artistic skills.

A big thank you to Inta Ozols, Madelene Hyde, Louise Cook, Tim Kimber, Katie Sotiris, Thom Gulseven and Gemma Lawson for their editorial and production talents, coping with my many questions and demands, and for providing a constant plate of tuna sandwiches.

All the mistakes, though hopefully very few, are ours but the following individuals have kept the errors to a minimum with their proof reading skills and expert knowledge: David Choi MA, MB ChB, FRCS, PhD; Elanor Clarke MB ChB, MD; Andrew Fletcher MA, MRCS, PhD; David J. Heylings MB BCh, FHEA; Vishy Mahadevan PhD, FRCS (Ed), FRCS; Michael Message MA, MB, BChir, PhD, MD (Hon. Kigezi); Mike Stansbie MA, BM, FRCS Eng. (Otol); Donal Shanahan BSc, PhD; Theo P. Welch MBBS, FRCS. Finally we would like to thank Marios Loukas MD, PhD and Stephen Carmichael PhD, DSc for their assistance with the multiple choice questions.

Clinical cases acknowledgements from the sixth edition

The authors and publishers thank the following individuals and their institutions for kindly supplying various clinical, operative, endoscopic and imaging photographs for both the book and especially the DVD.

Dr Solomon Abrahams, Consultant Physiotherapist – Clinical Director, 'Anatomie Physiotherapy Plus', Harrow, Middlesex; Dr Tania Abrahams, Paediatrician, Great Ormond Street Hospital, London; Dr Rosalind Ambrose, Consultant Radiologist, St Vincent, West Indies; Ms Louise Anning, medical student, Girton College, Cambridge; Mr Chris Anderson, Consultant Urologist, Cromwell Hospital, London; Dr Ray Armstrong, Rheumatologist, Southampton General Hospital, Southampton and 'Arthritis Research Campaign (ARC)'; Ms Sally Barnett, Australian athlete, London; Private Johnson Gideon Beharry VC of 1st Battalion Prince of Wales' Royal Regiment and Grenada, West Indies; Professor Paul Boulos, Institute of Surgical Studies, UCL, Medical School, London; Mr John Bridger, Surgeon Anatomist, Department of Anatomy, University of Cambridge; Professor Norman Browse, Emeritus Professor of Surgery – and Hodder Arnold Publishers to use illustrations from *Symptoms and Signs of Surgical Disease* 4th edn. 2005; Mr Carl Chow, Obstetrician and Gynaecologist, Kingston Hospital NHS Trust, Surrey; Professor Bruce Connolly, Hand Surgeon, Sydney Hospital, Sydney, Australia; Mr John Craven, formerly Consultant Surgeon, York District Hospital, York; Mr Paddy Cullen, Consultant Vascular Surgeon, University Hospital of North Durham, Durham; Mr D Dandy, Orthopaedic Consultant and Churchill Livingstone for permission to use illustrations from 'Arthroscopic Management of the Knee'; Mr Alan Davis, Optometrist, Ashdown & Collins, Kensal Rise, London; Dr Marc Davison, Anaesthetist, Stoke Mandeville Hospital, Aylesbury, Bucks; Mr Simon Dexter, Consultant Surgeon, Leeds Infirmary, Leeds; Mr Michael Dinneen, Consultant Urologist, Chelsea and Westminster and Charing Cross Hospitals, London; Professors Enrico Divitiis and Paolo Cappabianca, Neurosurgeons – and Karl Storz Endo-press TM, Tuttlingen, Germany for permission to reproduce pictures from *Endoscopic Pituitary Surgery – Anatomy and Surgery of the Transsphenoidal Approach to the Sellar Region* 2004; Professor J.F. Dumon, France; Ms Brenda Ernst, medical student, SGU, Grenada West Indies; Ms Oghenekome Gbinigie, medical student, Girton College, Cambridge; Professor Francis Nichols, Cardiothoracic Surgeon, Mayo Clinic, Rochester, Minnesota, USA; Professor Ralph Ger, Surgeon and Prof Todd Olson, Anatomist, Albert Einstein College of Medicine New York – and Parthenon Publishers to use illustrations from *Essentials of Clinical Anatomy* 2nd edn. 1996; Professor J. Gielecki, Chairman, Department of Anatomy, Silesian Medical University, Poland; Ms Natalie Gounaris-Shannon, medical student, Girton College, Cambridge; Mr Nadim Gulamhuseinwala, Department of Plastic Surgery, Guy's and St Thomas' Hospitals, London; Mr Fares Haddad, Consultant Orthopaedic and Trauma Surgeon, UCLH, London; Mr I. C. Hargreaves, Hand and Wrist Surgeon, St Luke's Hospital, Sydney, Australia; Dr David Heylings, Senior Lecturer in Anatomy, School of Medicine Health Policy and Practice, UEA, Norwich; Professor Michael Hobsley, formerly Head of Dept of Surgical Studies, The Middlesex Hospital Medical School, London; Dr Mike Jones, Consultant in Infectious Diseases, Director Edinburgh International Health Centre, Edinburgh, Scotland; Ms Megan Kaminskyj, medical student, SGU, Grenada West Indies; Mr Umraz Khan, Plastic Surgeon, Charing Cross Hospital, London; Mr Stephen Kriss, Podiatrist, Hospital of St John and St Elizabeth, London; Dr Suzanne Krone, Anaesthetist, Queen Victoria Hospital, East Grinstead; Professor Stefan Kubik, Anatomist, formerly Zurich University, Switzerland; Dr Lahiri, Cardiologist and the 'Wellington Hospital Cardiac Imaging and Research Centre', London; Professor John Lumley, Director Vascular Surgery Unit, St Bartholomew's and Great Ormond Street Hospitals, London; Mr Alberto Martinez-Isla, Laparoscopic Surgeon, Charing Cross and Ealing Hospitals, London; Mr Nick Dawe and Medtronic medical equipment company; Professor Jan Meiring, Chairman and Clinical Anatomist, University of Pretoria, South Africa; Ms Kathryn Mitchell, medical student, Bristol University, Bristol; Professor Antony Narula, Head and Neck Surgeon, St Mary's Hospital, London; Dr Barry Nicholls, Anaesthetist and Ultrasonographer, Musgrove Park Hospital, Taunton, Somerset and B. Harris, K. Hill and S. Moss from Toshiba Medical Systems; Dr Nkem Onyeador, Paediatrician and Arochukwu Medical Mission, Nigeria; Mr David Peek, medical student, SGU, Grenada, West Indies; Mr Rob Pollock, Orthopaedic Surgeon, RNOH, Stanmore, Middlesex; Professor Stephen Porter, Oral Medicine, UCL Eastman Dental Institute, London; Dr Lonie Salkowski, Associate Professor of Radiology, University of Wisconsin School of Medicine and Public Health, Madison, WI, USA; Mr Ertan Saridogan, Gynaecologist, The Portland Hospital, London; Mr Peter Scougall, Hand Surgeon, Sydney, Australia; Mr Julian Shah, Senior Lecturer in Urology, Institute of Urology UCL, London; Smith and Nephew Healthcare, Cambridge – Arthroscopic diagrams of limb joints; Mr Rajeev Sharma, Consultant Orthopaedic Surgeon, QE2 Hospital, Welwyn Garden City, Herts; Mr Spencer Quick, medical student, Bristol University Medical School, Bristol; Professor Rob Spinner, Neurosurgeon, Mayo Clinic, Rochester, Minnesota, USA; Professor M. Stoller, Department of Urology, UCSF, San Francisco, USA; Dr William Torreggiani, Radiologist, The Adelaide and Meath Hospital, Tallaght, Dublin, Ireland; Miss Gilli Vafidis, Ophthalmologist,

Central Middlesex Hospital, London; Mr Peter Valentine, ENT Consultant, Royal Surrey County Hospital Guilford, Surrey; Mr Joseph Venditto, medical student, SGU, St Vincent, West Indies; Mr Richard Villars, Orthopaedic Consultant and Butterworth Heinemann for permission to reproduce illustrations from 'Hip Arthroscopy'; Mr Peter Webb, Consultant Surgeon, Mayday Maritime Hospital, Kent; Mr Theo Welch, Surgeon, Fellow Commoner Queens' College, Cambridge; Professor Jamie Weir, Department of Clinical Radiology, Grampian University Hospitals Trust, Aberdeen, Scotland – and Imaging Atlas of Human Anatomy 3rd edn,, Elsevier 2003; Mr Heikki Whittet, ENT Surgeon, Singleton Hospital , Swansea, Wales; Professor Tony Wright, Director Ear Institute, UCL Hospitals, London; Dr C. B. Williams, Colonoscopist, The London Clinic Endoscopy Unit, London.

Head, neck and brain

1



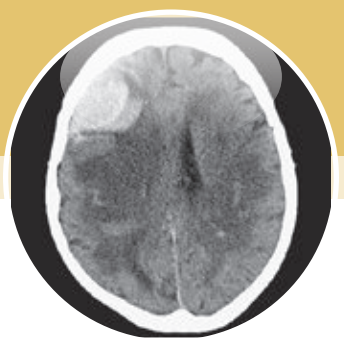

Skull *from the front*

1 Anterior nasal spine
2 Body of mandible
3 Frontal bone
4 Frontal notch
5 Frontal process of maxilla
6 Glabella
7 Greater wing of sphenoid bone
8 Infra-orbital foramen
9 Infra-orbital margin
10 Inferior nasal concha
11 Inferior orbital fissure
12 Lacrimal bone
13 Lesser wing of sphenoid bone
14 Maxilla
15 Mental foramen
16 Mental protuberance
17 Middle nasal concha
18 Nasal bone
19 Nasal septum
20 Nasion
21 Orbit (orbital cavity)
22 Ramus of mandible
23 Superior orbital fissure
24 Supra-orbital foramen
25 Supra-orbital margin
26 Zygomatic bone

The term ‘skull’ includes the mandible, and ‘cranium’ refers to the skull without the mandible.

The calvarium is the vault of the skull (cranial vault or skull-cap) and is the upper part of the cranium that encloses the brain.

The front part of the skull forms the facial skeleton.

The supra-orbital, infra-orbital and mental foramina (24, 8 and 15) lie in approximately the same vertical plane.

Details of individual skull bones are given on pages 18–27, of the bones of the orbit and nose on page 12, and of the teeth on pages 13–19.

Tripod fracture, see pages 80–82.

Skull *muscle attachments, from the front*

1 Buccinator
2 Corrugator supercilii
3 Depressor anguli oris
4 Depressor labii inferioris
5 Levator anguli oris
6 Levator labii superioris
7 Levator labii superioris alaeque nasi
8 Masseter
9 Mentalis
10 Nasalis
11 Orbicularis oculi
12 Platysma
13 Procerus
14 Temporalis
15 Zygomaticus major
16 Zygomaticus minor

Skull *radiograph, occipitofrontal 15° projection*

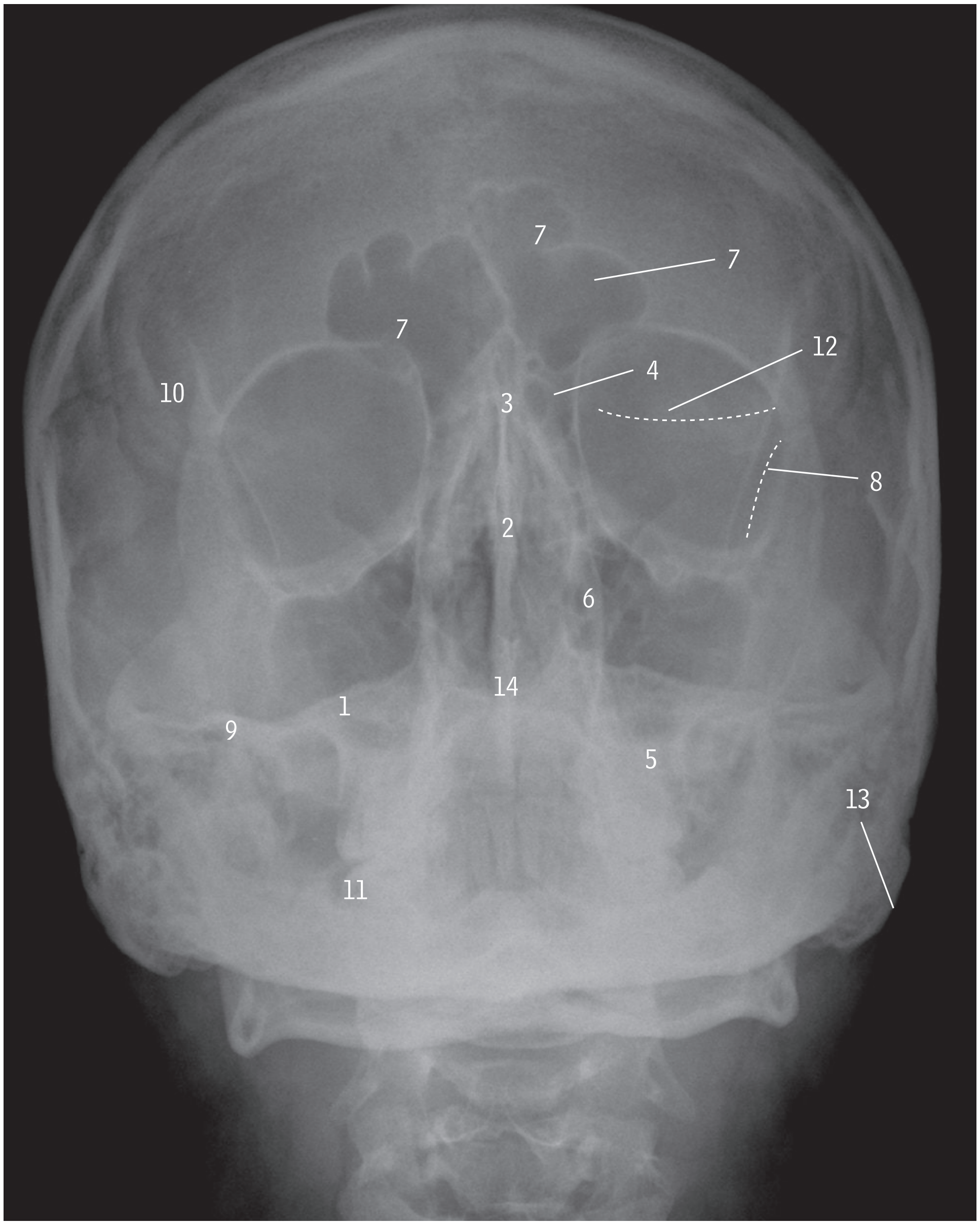

1 Basi-occiput
2 Body of sphenoid
3 Crista galli
4 Ethmoidal air cells
5 Floor of maxillary sinus (antrum)
6 Foramen rotundum
7 Frontal sinus
8 Greater wing of sphenoid
9 Internal acoustic meatus
10 Lambdoid suture
11 Lateral mass of atlas (first cervical vertebra)
12 Lesser wing of sphenoid
13 Mastoid process
14 Nasal septum

Skull *from the right*

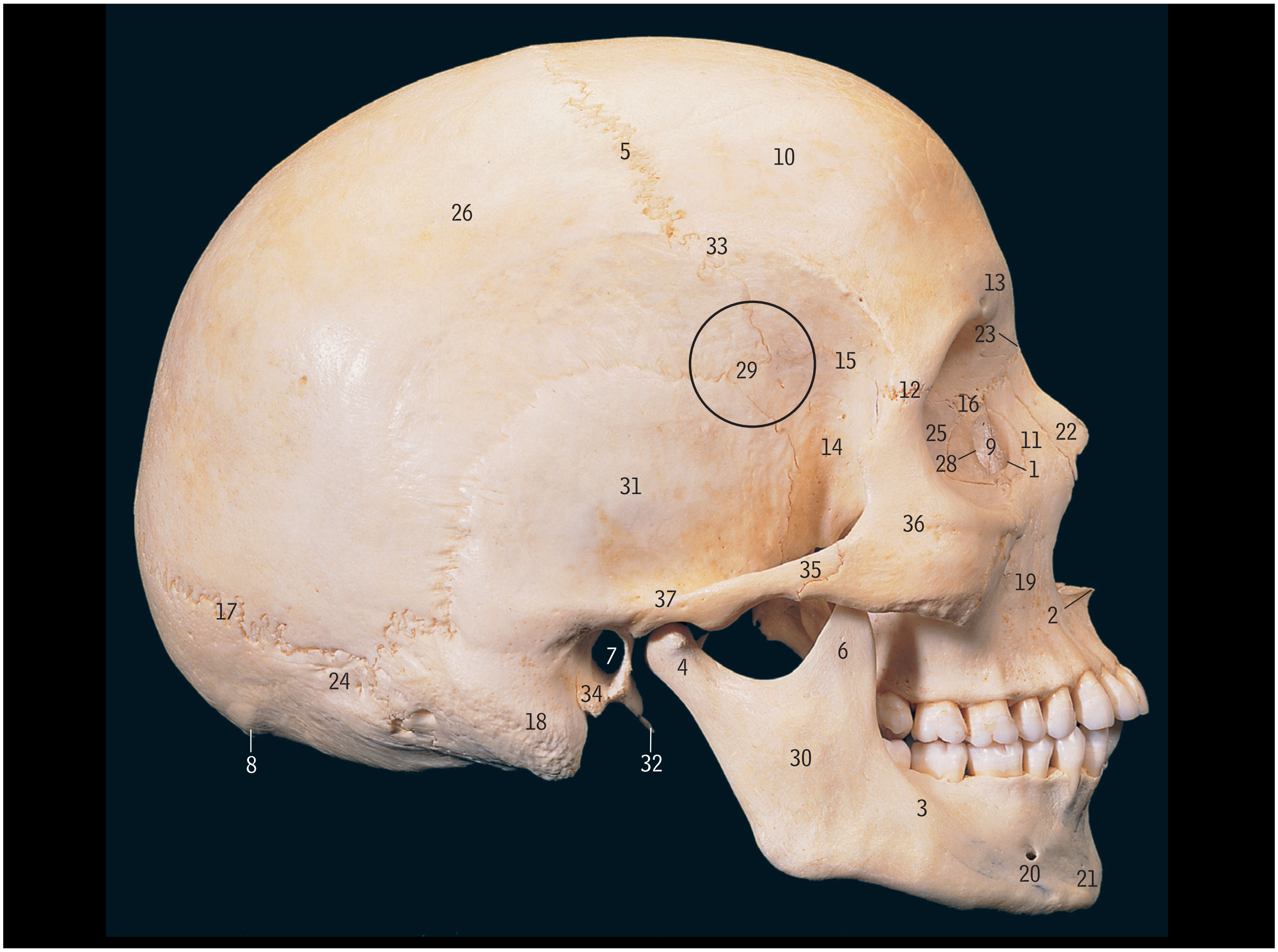

1 Anterior lacrimal crest
2 Anterior nasal spine
3 Body of mandible
4 Condylar process of the mandible
5 Coronal suture
6 Coronoid process of mandible
7 External acoustic meatus of temporal bone
8 External occipital protuberance (inion)
9 Fossa for lacrimal sac
10 Frontal bone
11 Frontal process of maxilla
12 Frontozygomatic suture
13 Glabella
14 Greater wing of sphenoid bone
15 Inferior temporal line
16 Lacrimal bone
17 Lambdoid suture
18 Mastoid process of temporal bone
19 Maxilla
20 Mental foramen
21 Mental protuberance
22 Nasal bone
23 Nasion
24 Occipital bone
25 Orbital plate of ethmoid bone
26 Parietal bone
27 Pituitary fossa (sella turcica) (see Figure A on page 5)
28 Posterior lacrimal crest
29 Pterion (encircled)
30 Ramus of mandible
31 Squamous part of temporal bone
32 Styloid process of temporal bone
33 Superior temporal line
34 Tympanic part of temporal bone
35 Zygomatic arch
36 Zygomatic bone
37 Zygomatic process of temporal bone

Pterion (29) is not a single point but an area where the frontal (10), parietal (26), squamous part of the temporal (31) and greater wing of the sphenoid bone (14) adjoin one another.

It is an important landmark for the anterior branch of the middle meningeal artery, which underlies this area on the inside of the skull (page 17).

Extradural haemorrhage, see pages 80–82.

Skull

A radiograph, lateral projection

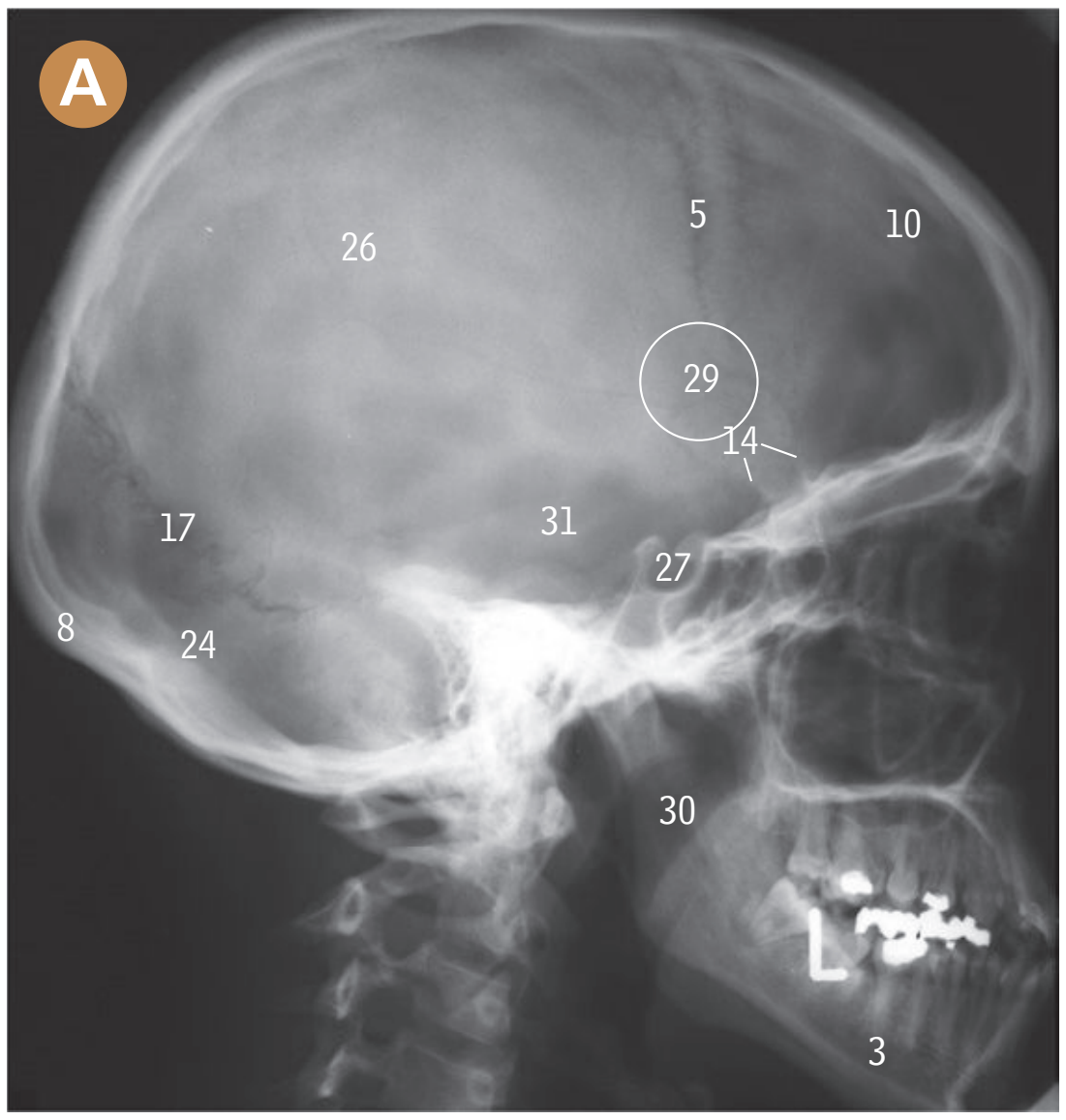

C coloured bones

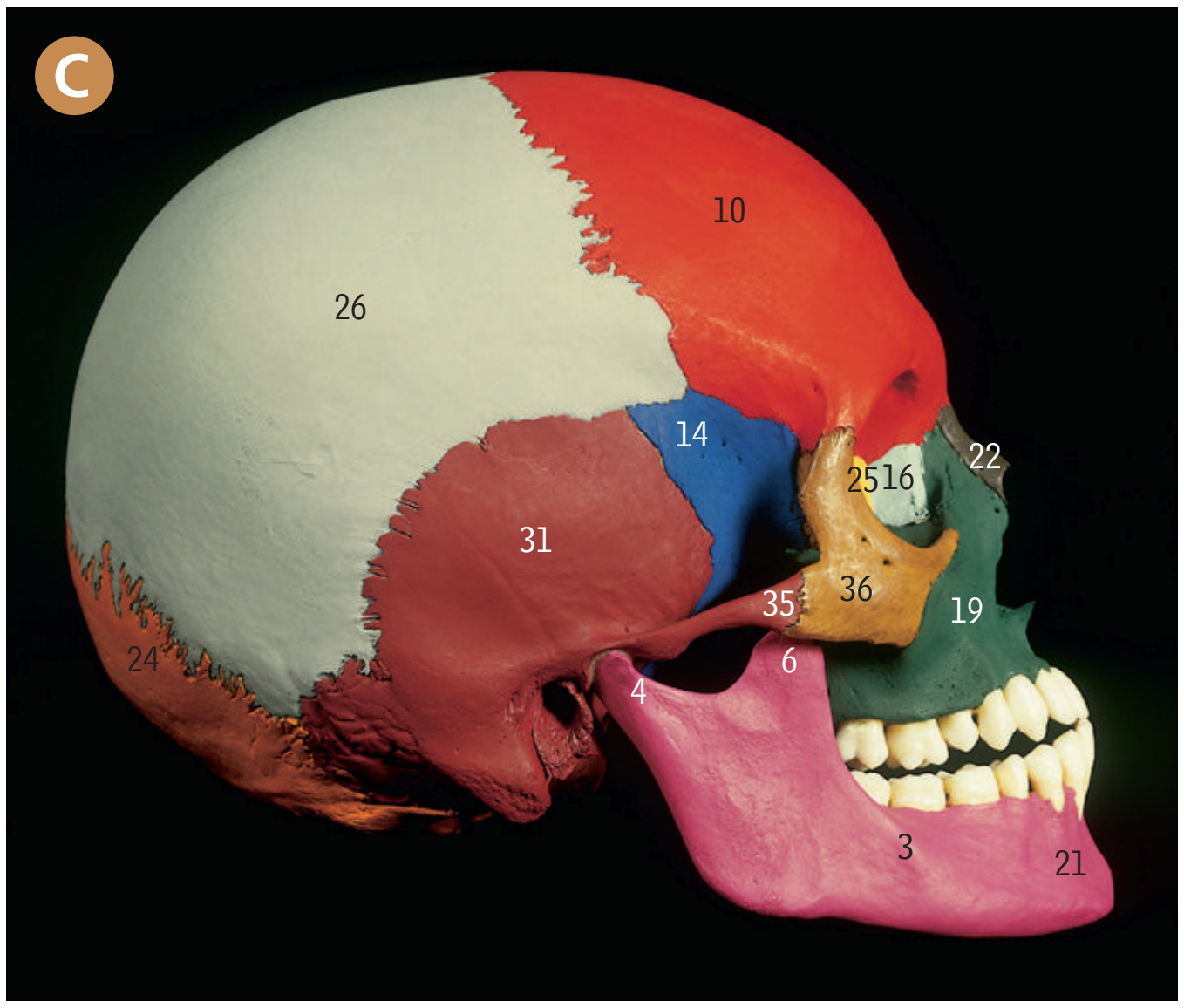

See label list on page 4 for A and C labels

B scalp dissection

Scalp layers

S, skin; **C,** connective tissue; **A,** aponeurosis of occipitofrontalis; **L,** loose areolar tissue; **P,** periosteum.

1 Aponeurosis of occipitofrontalis
2 Dura mater
3 Frontalis muscle (covered by loose areolar tissue)
4 Loose areolar tissue
5 Middle meningeal artery impression on dura mater
6 Parietal branch of the superficial temporal artery
7 Periosteum
8 Skin
9 Subcutaneous tissue
10 Temporal bone
11 Temporal fascia
12 Temporalis muscle

Skull *muscle attachments, from the right*

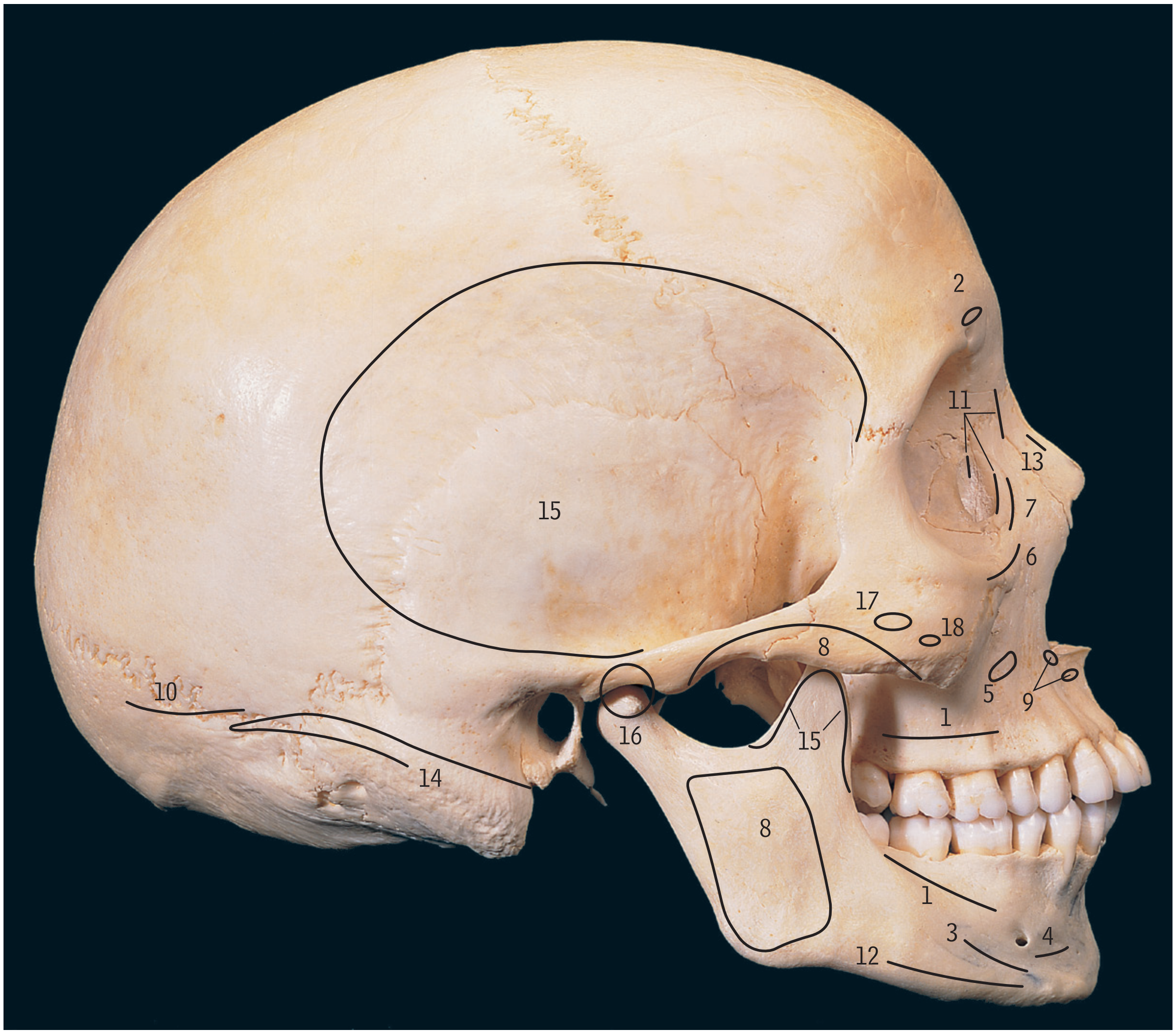

1 Buccinator
2 Corrugator supercilii
3 Depressor anguli oris
4 Depressor labii inferioris
5 Levator anguli oris
6 Levator labii superioris
7 Levator labii superioris alaeque nasi
8 Masseter
9 Nasalis
10 Occipital part of occipitofrontalis
11 Orbicularis oculi
12 Platysma
13 Procerus
14 Sternocleidomastoid
15 Temporalis
16 Temporomandibular joint
17 Zygomaticus major
18 Zygomaticus minor

The bony attachments of the buccinator muscle (1) are to the upper and lower jaws (maxilla and mandible) opposite the three molar teeth. (The teeth are identified on pages 13–19.)

The upper attachment of temporalis (upper 15) occupies the temporal fossa (the narrow space above the zygomatic arch at the side of the skull). The lower attachment of temporalis (lower 15) extends from the lowest part of the mandibular notch of the mandible, over the coronoid process and down the front of the ramus almost as far as the last molar tooth.

Masseter (8) extends from the zygomatic arch to the lateral side of the ramus of the mandible.

Temporomandibular joint (TMJ) dislocation, see pages 80–82.

A Skull *from behind*

1 External occipital protuberance (inion)
2 Highest nuchal line
3 Inferior nuchal line
4 Lambda
5 Lambdoid suture
6 Occipital bone
7 Parietal bone
8 Parietal foramina
9 Sagittal suture
10 Superior nuchal line

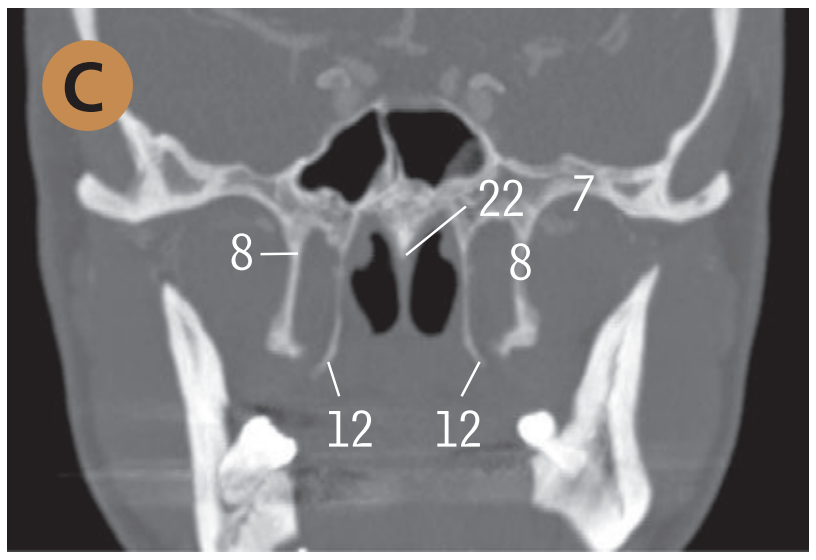

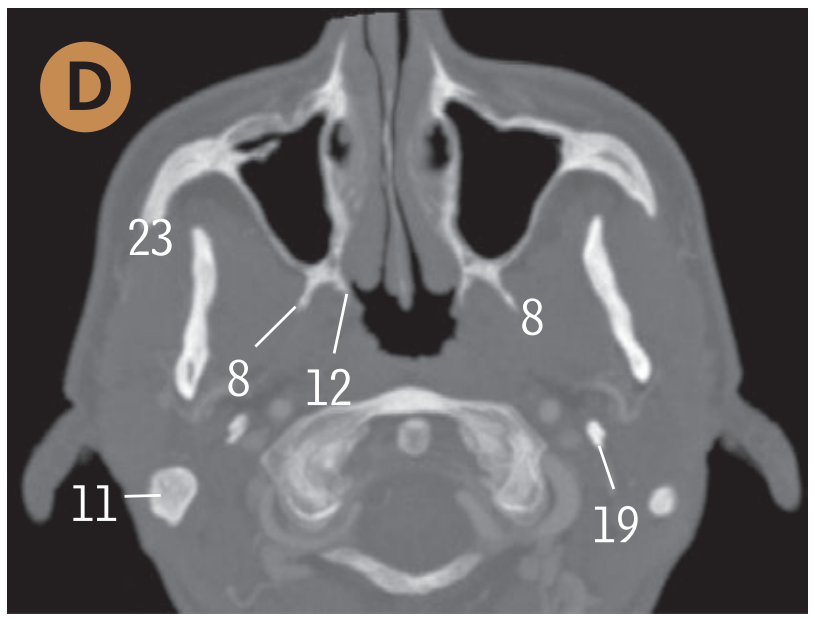

See label list below for C and D.

B Skull *right infratemporal region, obliquely from below*

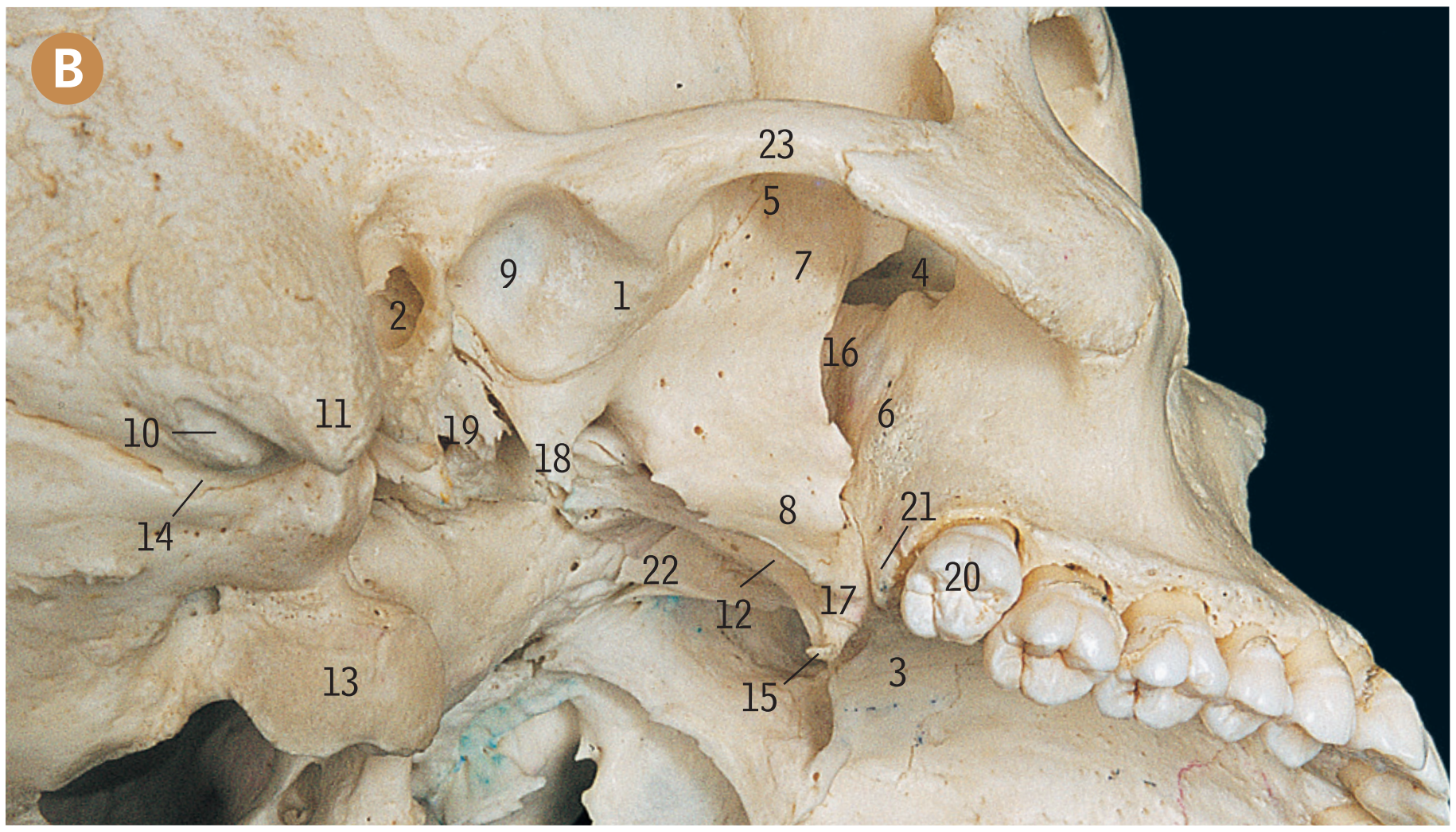

1 Articular tubercle
2 External acoustic meatus
3 Horizontal plate of palatine bone
4 Inferior orbital fissure
5 Infratemporal crest
6 Infratemporal (posterior) surface of maxilla
7 Infratemporal surface of greater wing of sphenoid bone
8 Lateral pterygoid plate
9 Mandibular fossa
10 Mastoid notch
11 Mastoid process
12 Medial pterygoid plate
13 Occipital condyle
14 Occipital groove
15 Pterygoid hamulus
16 Pterygomaxillary fissure and pterygopalatine fossa
17 Pyramidal process of palatine bone
18 Spine of sphenoid bone
19 Styloid process and sheath
20 Third maxillary molar tooth
21 Tuberosity of maxilla
22 Vomer
23 Zygomatic arch

A Skull *from above*

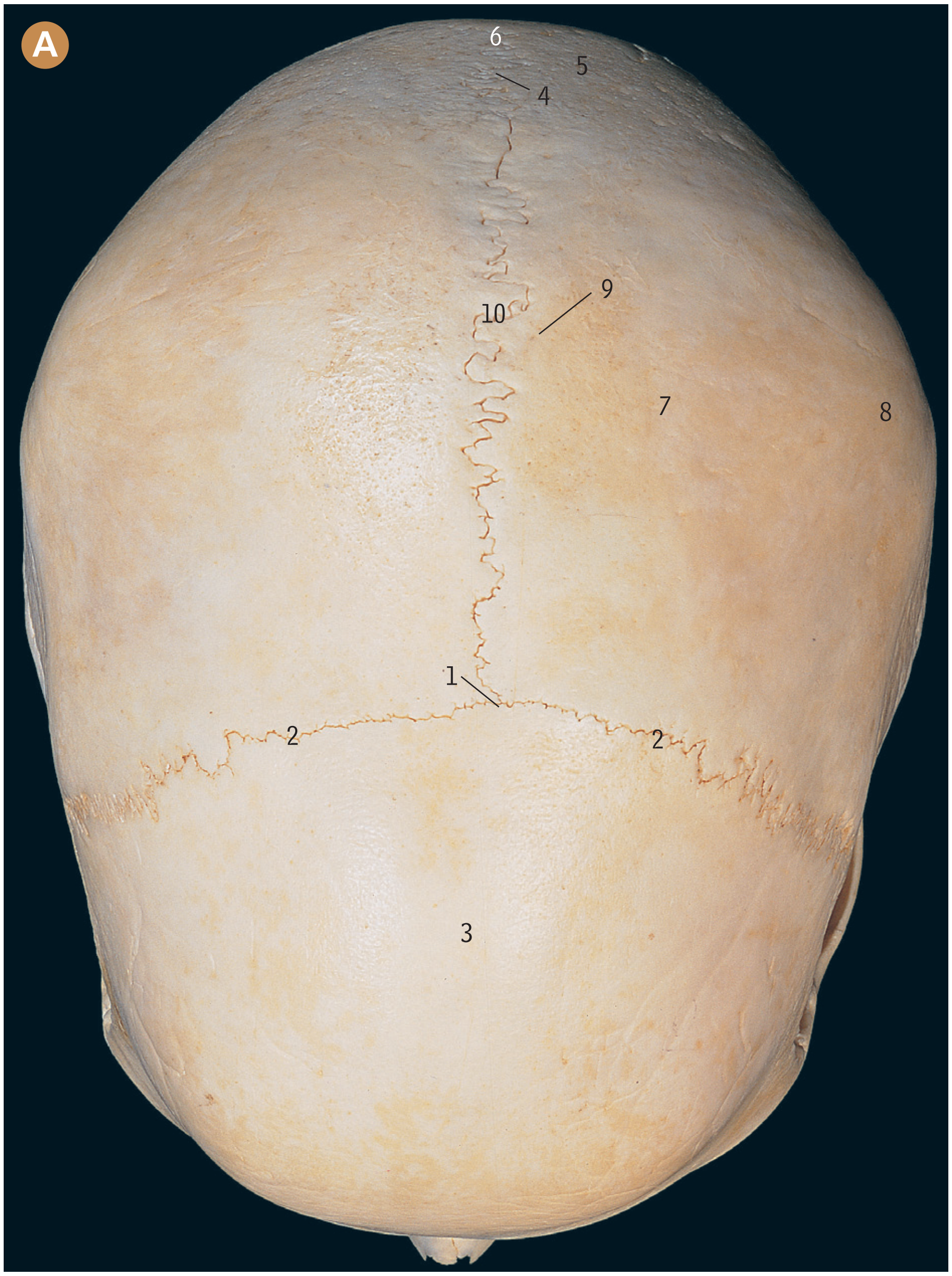

1 Bregma
2 Coronal suture
3 Frontal bone
4 Lambda
5 Lambdoid suture
6 Occipital bone
7 Parietal bone
8 Parietal eminence
9 Parietal foramen
10 Sagittal suture

In this skull, the parietal eminences are prominent (A8).

The point where the sagittal suture (A10) meets the coronal suture (A2) is the bregma (A1). At birth, the unossified parts of the frontal and parietal bones in this region form the membranous anterior fontanelle (page 14, D1).

The point where the sagittal suture (A10) meets the lambdoid suture (A5) is the lambda (A4). At birth, the unossified parts of the parietal and occipital bones in this region form the membranous posterior fontanelle (page 14, C13).

The label A3 in the centre of the frontal bone indicates the line of the frontal suture in the fetal skull (page 14, A5). The suture may persist in the adult skull and is sometimes known as the metopic suture.

The arachnoid granulations (page 62, B1), through which cerebrospinal fluid drains into the superior sagittal sinus, cause the irregular depressions (B2) on the parts of the frontal and parietal bones (B3 and 7) that overlie the sinus.

B Skull *internal surface of the cranial vault, central part*

1 Coronal suture
2 Depressions for arachnoid granulations
3 Frontal bone
4 Frontal crest
5 Groove for superior sagittal sinus
6 Grooves for middle meningeal vessels
7 Parietal bone
8 Parietal foramina
9 Sagittal suture

Pepperpot skull, see pages 80–82.

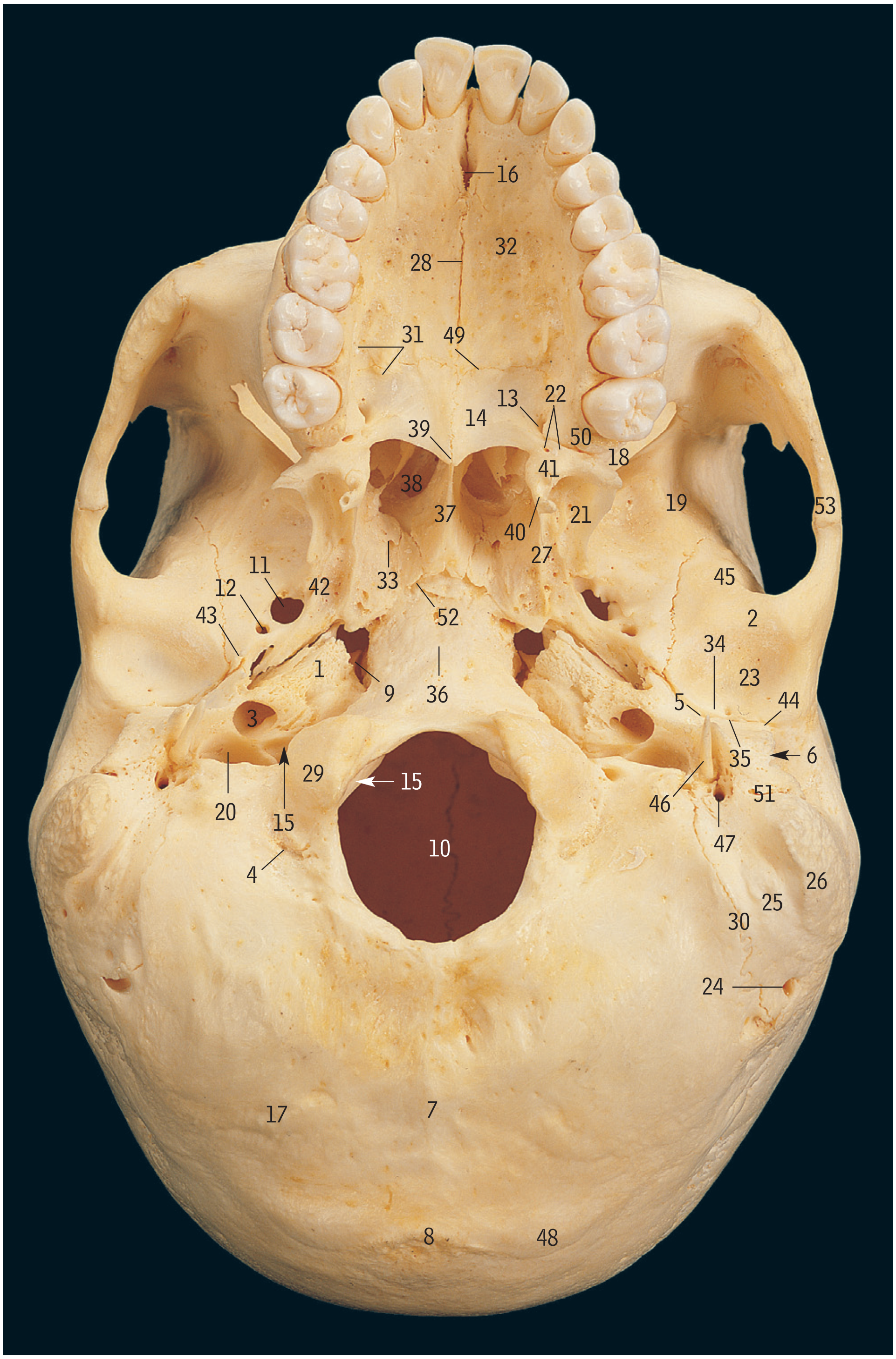

Skull *external surface of the base*

1 Apex of petrous part of temporal bone
2 Articular tubercle
3 Carotid canal
4 Condylar canal (posterior)
5 Edge of tegmen tympani
6 External acoustic meatus
7 External occipital crest
8 External occipital protuberance
9 Foramen lacerum
10 Foramen magnum
11 Foramen ovale
12 Foramen spinosum
13 Greater palatine foramen
14 Horizontal plate of palatine bone
15 Hypoglossal canal
16 Incisive fossa
17 Inferior nuchal line
18 Inferior orbital fissure
19 Infratemporal crest of greater wing of sphenoid bone
20 Jugular foramen
21 Lateral pterygoid plate
22 Lesser palatine foramina
23 Mandibular fossa
24 Mastoid foramen
25 Mastoid notch
26 Mastoid process
27 Medial pterygoid plate
28 Median palatine (intermaxillary) suture
29 Occipital condyle
30 Occipital groove
31 Palatine grooves and spines
32 Palatine process of maxilla
33 Pharyngeal canal
34 Petrosquamous fissure
35 Petrotympanic fissure
36 Pharyngeal tubercle
37 Posterior border of vomer
38 Posterior nasal aperture (choana)
39 Posterior nasal spine
40 Pterygoid hamulus
41 Pyramidal process of palatine bone
42 Scaphoid fossa
43 Spine of sphenoid bone
44 Squamotympanic fissure
45 Squamous part of temporal bone
46 Styloid process
47 Stylomastoid foramen
48 Superior nuchal line
49 Transverse palatine (palatomaxillary) suture
50 Tuberosity of maxilla
51 Tympanic part of temporal bone
52 Vomerovaginal canal
53 Zygomatic arch

The palatine processes of the maxilla (32) and the horizontal plate of the palatine bone (14) form the hard palate (roof of the mouth and floor of the nasal cavity).

The carotid canal (3), recognized by its round shape on the inferior surface of the petrous part of the temporal bone, does not pass straight upwards to open into the inside of the skull but takes a right-angled turn forwards and medially within the petrous temporal to open into the back of the foramen lacerum (9).

Intracranial spread of infection, skull fracture, see pages 80–82.

Skull *muscle attachments, external surface of the base*

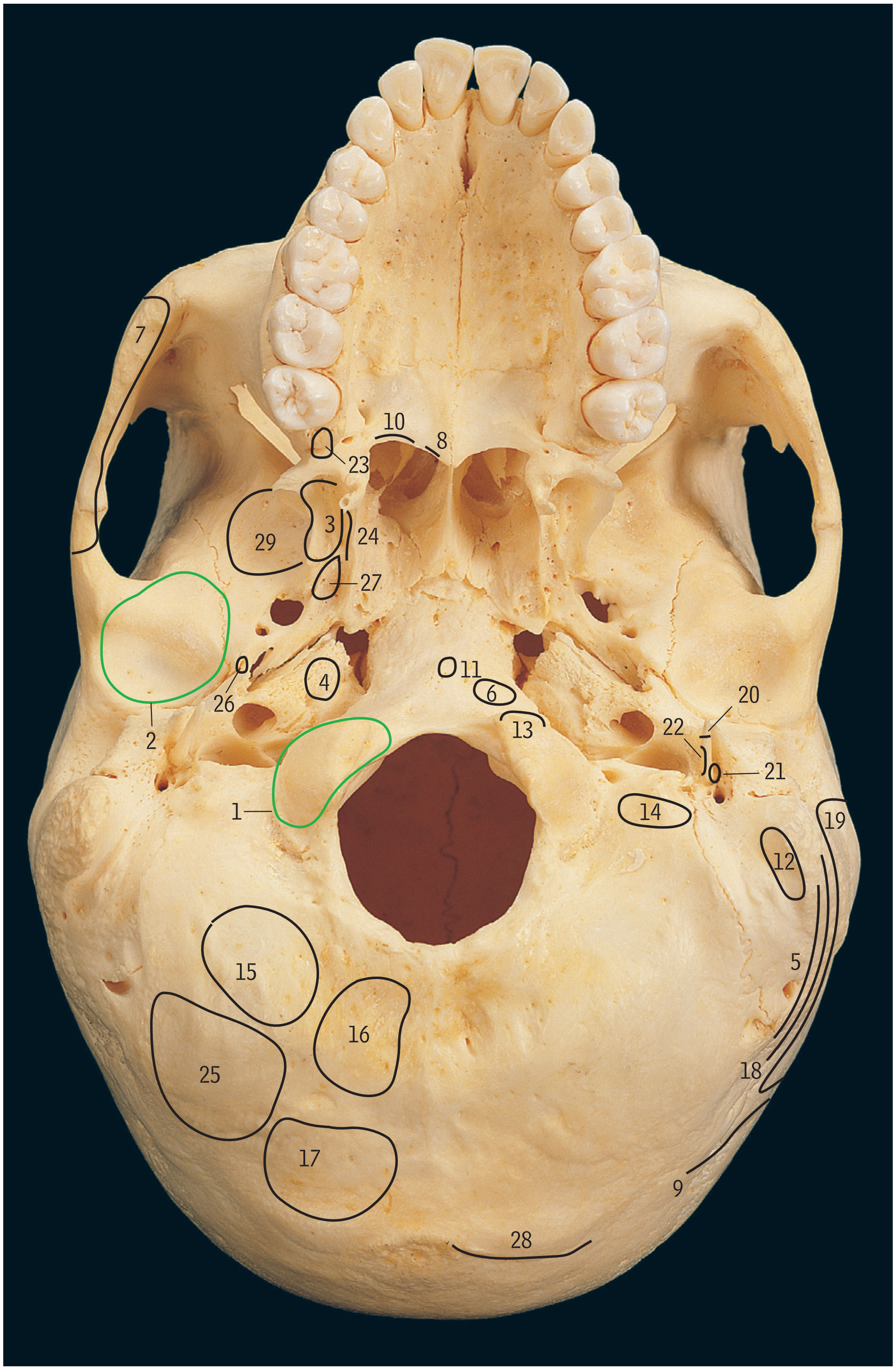

Green line = capsule attachments of atlanto-occipital and temporomandibular joints

1 Capsule attachment of atlanto-occipital joint
2 Capsule attachment of temporomandibular joint
3 Deep head of medial pterygoid
4 Levator veli palatini
5 Longissimus capitis
6 Longus capitis
7 Masseter
8 Musculus uvulae
9 Occipital part of occipitofrontalis
10 Palatopharyngeus
11 Pharyngeal raphe
12 Posterior belly of digastric
13 Rectus capitis anterior
14 Rectus capitis lateralis
15 Rectus capitis posterior major
16 Rectus capitis posterior minor
17 Semispinalis capitis
18 Splenius capitis
19 Sternocleidomastoid
20 Styloglossus
21 Stylohyoid
22 Stylopharyngeus
23 Superficial head of medial pterygoid
24 Superior constrictor
25 Superior oblique
26 Tensor tympani
27 Tensor veli palatini
28 Trapezius
29 Upper head of lateral pterygoid

The medial pterygoid plate has no pterygoid muscles attached to it. It passes straight backwards, giving origin at its lower end to part of the superior constrictor of the pharynx (24).

The lateral pterygoid plate has both pterygoid muscles attached to it: medial and lateral muscles from the medial and lateral surfaces, respectively (3 and 29). The plate becomes twisted slightly laterally because of the constant pull of these muscles which pass backwards and laterally to their attachments to the mandible (pages 18–19).

Skull fractures, see pages 80–82.

Skull *internal surface of the base (cranial fossae)*

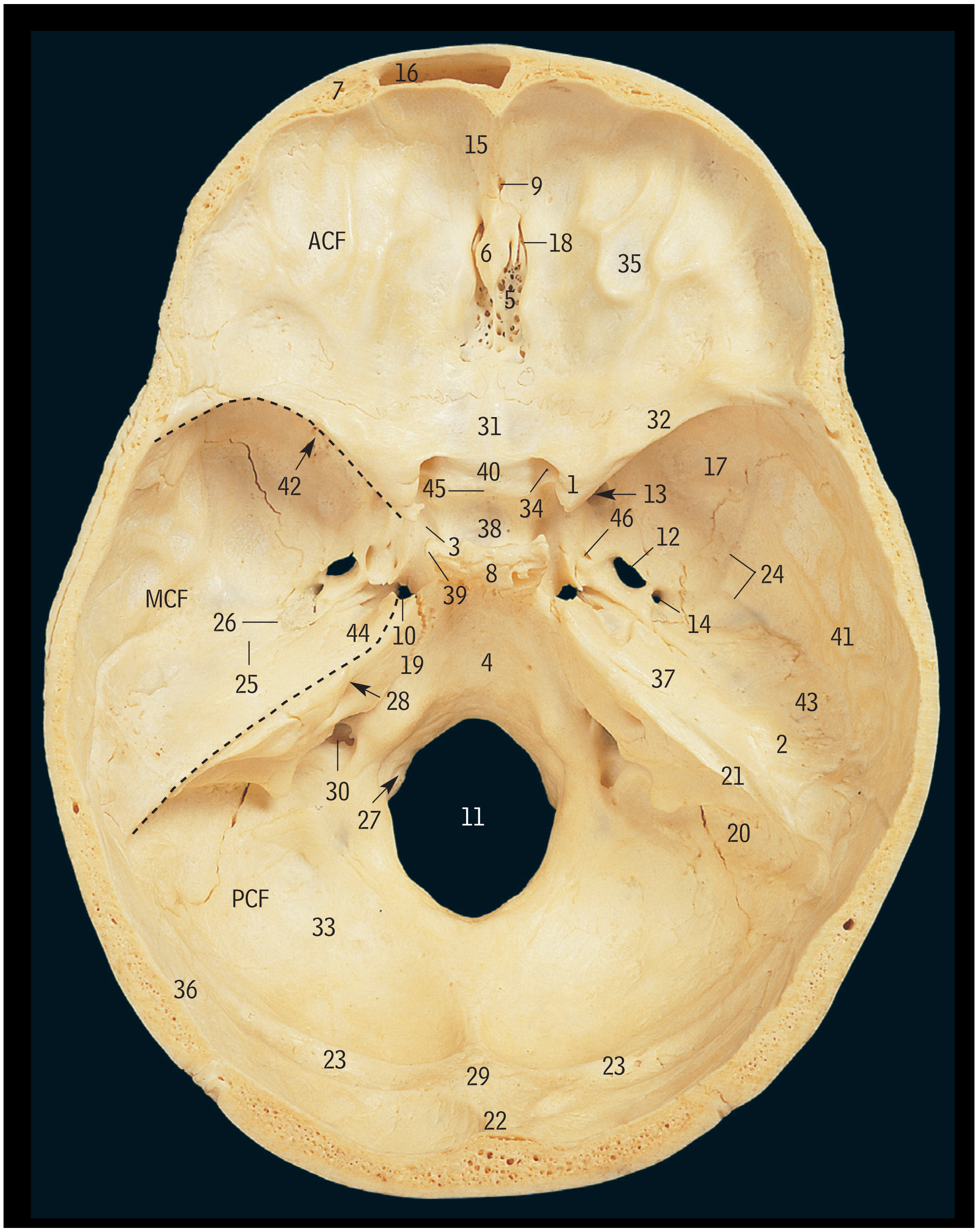

1 Anterior clinoid process
2 Arcuate eminence
3 Carotid groove
4 Clivus
5 Cribriform plate of ethmoid bone
6 Crista galli
7 Diploë
8 Dorsum sellae
9 Foramen caecum
10 Foramen lacerum
11 Foramen magnum
12 Foramen ovale
13 Foramen rotundum
14 Foramen spinosum
15 Frontal crest
16 Frontal sinus
17 Greater wing of sphenoid bone
18 Groove for anterior ethmoidal nerve and vessels
19 Groove for inferior petrosal sinus
20 Groove for sigmoid sinus
21 Groove for superior petrosal sinus
22 Groove for superior sagittal sinus
23 Groove for transverse sinus
24 Grooves for middle meningeal vessels
25 Hiatus and groove for greater petrosal nerve
26 Hiatus and groove for lesser petrosal nerve
27 Hypoglossal canal
28 Internal acoustic meatus
29 Internal occipital protuberance
30 Jugular foramen
31 Jugum of sphenoid bone
32 Lesser wing of sphenoid bone
33 Occipital bone (cerebellar fossa)
34 Optic canal
35 Orbital part of frontal bone
36 Parietal bone (postero-inferior angle only)
37 Petrous part of temporal bone
38 Pituitary fossa (sella turcica)
39 Posterior clinoid process
40 Prechiasmatic groove
41 Squamous part of temporal bone
42 Superior orbital fissure
43 Tegmen tympani
44 Trigeminal impression
45 Tuberculum sellae
46 Venous (emissary) foramen

The anterior cranial fossa (ACF) is limited posteriorly on each side by the free margin of the lesser wing of the sphenoid (32) with its anterior clinoid process (1), and centrally by the anterior margin of the prechiasmatic groove (40).

The middle cranial fossa (MCF) is butterfly-shaped and consists of a central or median part and right and left lateral parts. The central part includes the pituitary fossa (38) on the upper surface of the body of the sphenoid, with the prechiasmatic groove (40) in front and the dorsum sellae (8) with its posterior clinoid processes (39) behind. Each lateral part extends from the posterior border of the lesser wing of the sphenoid (32) to the groove for the superior petrosal sinus (21) on the upper edge of the petrous part of the temporal bone.

The posterior cranial fossa (PCF), whose most obvious feature is the foramen magnum (11), is behind the dorsum sellae (8) and the grooves for the superior petrosal sinuses (21).

For cranial dural attachments and reflections, see pages 51–53 and 62.

Anosmia, skull base fracture, see pages 80–82.

A Skull *bones of the left orbit*

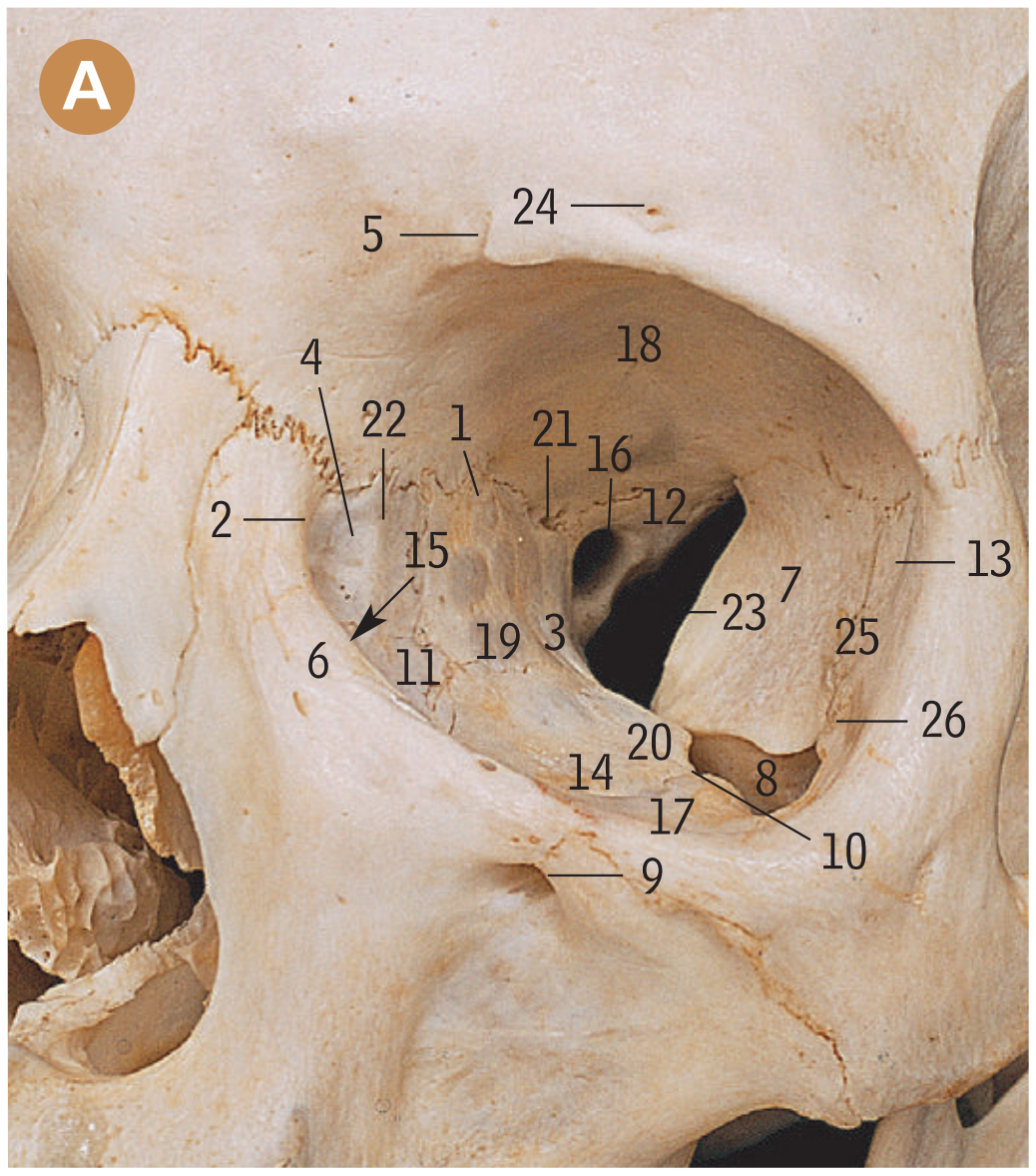

1 Anterior ethmoidal foramen
2 Anterior lacrimal crest
3 Body of sphenoid bone, forming medial wall
4 Fossa for lacrimal sac
5 Frontal notch
6 Frontal process of maxilla, forming medial wall
7 Greater wing of sphenoid bone, forming lateral wall
8 Inferior orbital fissure
9 Infra-orbital foramen
10 Infra-orbital groove
11 Lacrimal bone, forming medial wall
12 Lesser wing of sphenoid bone, forming roof
13 Marginal tubercle
14 Maxilla, forming floor
15 Nasolacrimal canal
16 Optic canal
17 Orbital border of zygomatic bone, forming floor
18 Orbital part of frontal bone, forming roof
19 Orbital plate of ethmoid bone, forming medial wall
20 Orbital process of palatine bone, forming floor
21 Posterior ethmoidal foramen
22 Posterior lacrimal crest
23 Superior orbital fissure
24 Supra-orbital foramen
25 Zygomatic bone forming lateral wall
26 Zygomatico-orbital foramen

C Nasal cavity *lateral wall*

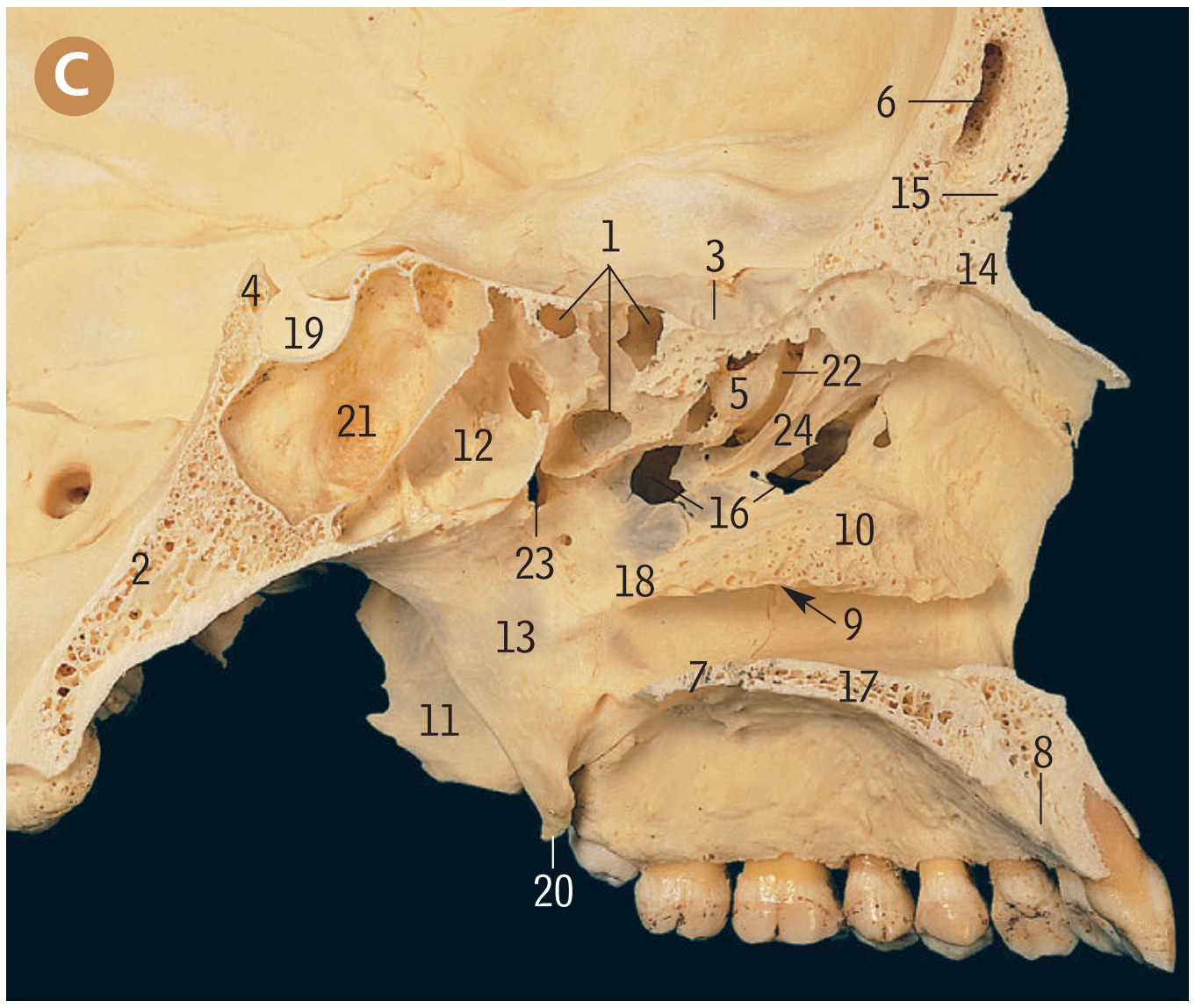

In this midline sagittal section of the skull, with the nasal septum removed, the superior and middle nasal conchae have been dissected away to reveal the air cells of the ethmoidal sinus, in particular the ethmoidal bulla (5).

1 Air cells of ethmoidal sinus
2 Clivus
3 Cribriform plate of ethmoid bone
4 Dorsum sellae
5 Ethmoidal bulla
6 Frontal sinus
7 Horizontal plate of palatine bone
8 Incisive canal
9 Inferior meatus
10 Inferior nasal concha
11 Lateral pterygoid plate
12 Left sphenoidal sinus
13 Medial pterygoid plate
14 Nasal bone
15 Nasal spine of frontal bone
16 Opening of maxillary sinus
17 Palatine process of maxilla
18 Perpendicular plate of palatine bone
19 Pituitary fossa (sella turcica)
20 Pterygoid hamulus
21 Right sphenoidal sinus
22 Semilunar hiatus
23 Sphenopalatine foramen
24 Uncinate process of ethmoid bone

The roof of the nasal cavity consists mainly of the cribriform plate of the ethmoid bone (C3) with the body of the sphenoid containing the sphenoidal sinuses (C21 and 12) behind, and the nasal bone (C14) and the nasal spine of the frontal bone (C15) at the front.

The floor of the cavity consists of the palatine process of the maxilla (C17) and the horizontal plate of the palatine bone (C7).

The medial wall is the nasal septum which is formed mainly by two bones – the perpendicular plate of the ethmoid and the vomer – and the septal cartilage.

The lateral wall consists of the medial surface of the maxilla with its large opening (C16), overlapped from above by parts of the ethmoid (C1, 5 and 24) and lacrimal bones, from behind by the perpendicular plate of the palatine (C18), and below by the inferior concha (C10).

B Skull *Left orbit, individual bones*

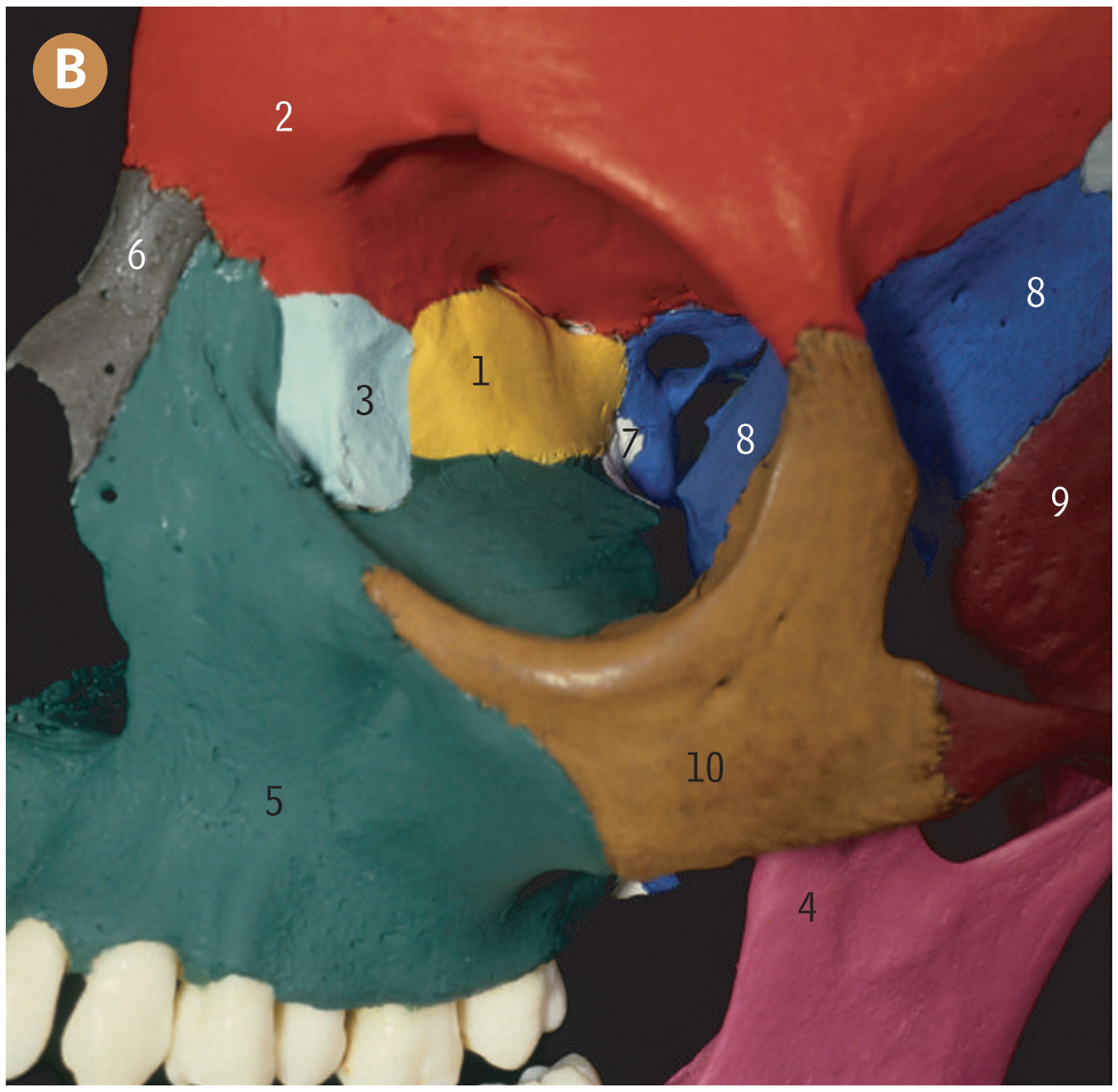

1 Ethmoid
2 Frontal
3 Lacrimal
4 Mandible
5 Maxilla
6 Nasal
7 Palatine
8 Sphenoid
9 Temporal
10 Zygomatic

Sinus pathology, see pages 80–82.

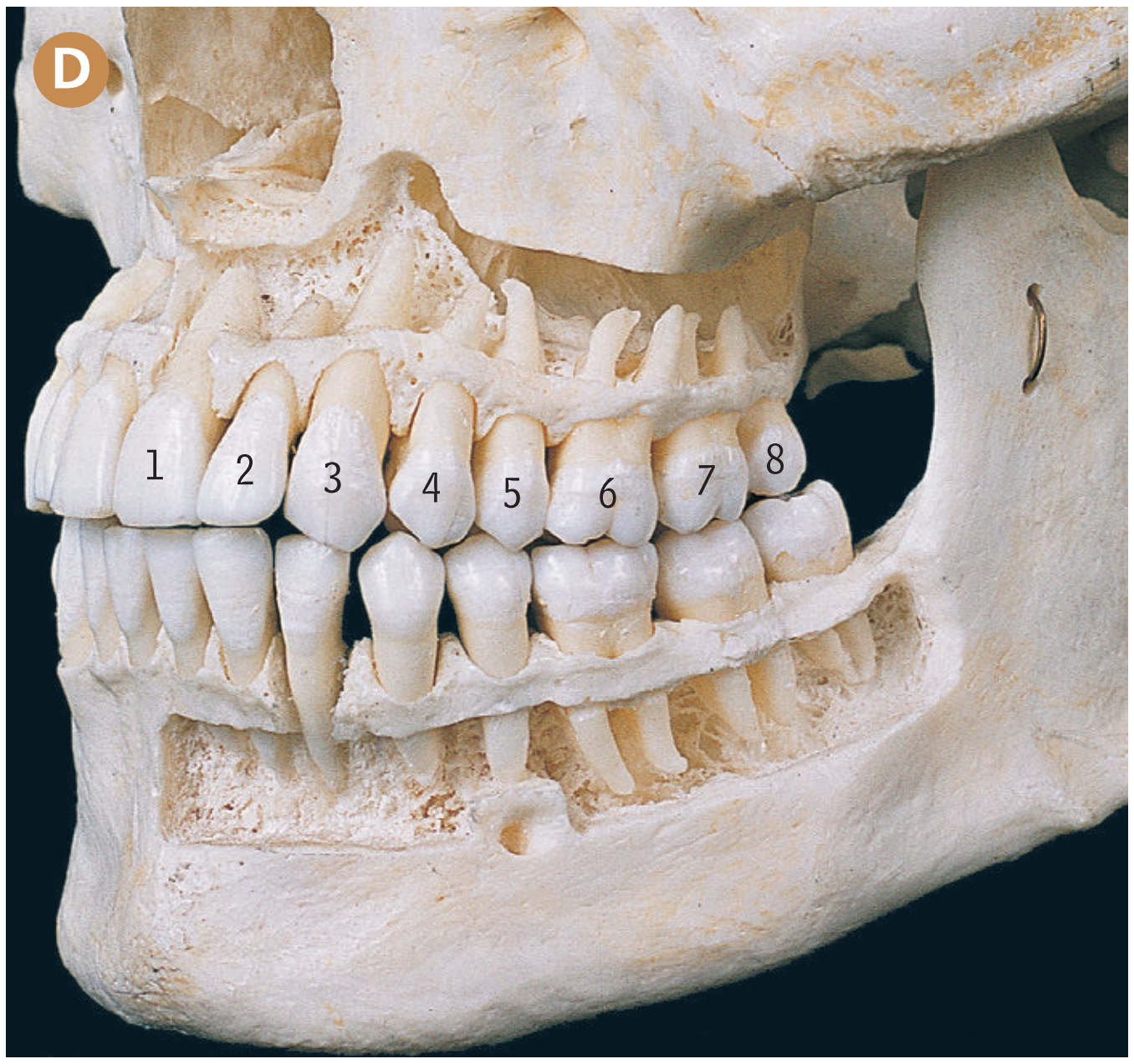

D Permanent teeth
from the left and in front

1 First (central) incisor
2 Second (lateral) incisor
3 Canine
4 First premolar
5 Second premolar
6 First molar
7 Second molar
8 Third molar

The corresponding teeth of the upper and lower jaws have similar names. In clinical dentistry, the teeth are usually identified by the numbers 1–8 (as listed here) rather than by name.

The third molar is sometimes called the wisdom tooth.

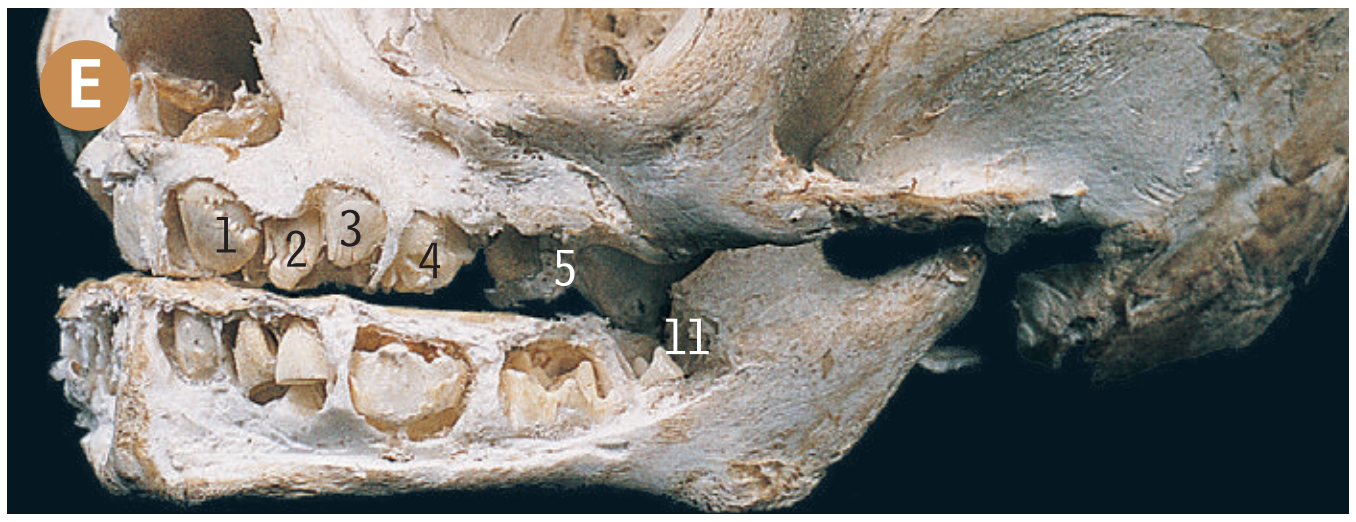

Upper and lower jaws
from the left and in front

E **in the newborn with unerupted deciduous teeth**

F **in a 4-year-old child with erupted deciduous teeth and unerupted permanent teeth**

1 First (central) incisor of deciduous dentition
2 Second (lateral) incisor of deciduous dentition
3 Canine of deciduous dentition
4 First molar of deciduous dentition
5 Second molar of deciduous dentition
6 First (central) incisor of permanent dentition
7 Second (lateral) incisor of permanent dentition
8 Canine of permanent dentition
9 First premolar of permanent dentition
10 Second premolar of permanent dentition
11 First molar of permanent dentition
12 Second molar of permanent dentition

The deciduous molars occupy the positions of the premolars of the permanent dentition.

G Edentulous mandible
in old age, from the left

1 Angle
2 Body
3 Mental foramen
4 Ramus

With the loss of teeth, the alveolar bone becomes resorbed, so that the mental foramen (3) and mandibular canal lie near the upper margin of the bone.

The angle (1) between the ramus (4) and body (2) becomes more obtuse, resembling the infantile angle (as in E and F, above).

Skull of a full-term fetus

A from the front

B from the left and slightly below

C from behind

D from above

1 Anterior fontanelle
2 Coronal suture
3 Elevations over deciduous teeth in body of mandible
4 External acoustic meatus
5 Frontal suture
6 Frontal tuberosity
7 Half of frontal bone
8 Lambdoid suture
9 Mastoid fontanelle
10 Maxilla
11 Occipital bone
12 Parietal tuberosity
13 Posterior fontanelle
14 Ramus of mandible
15 Sagittal suture
16 Sella turcica
17 Semicircular canals, superior
18 Sphenoidal fontanelle
19 Stylomastoid foramen
20 Symphysis menti
21 Tympanic ring

Cleft lip and palate, see pages 80–82.

Fetal skull radiographs E *frontal projection* F *lateral projection*

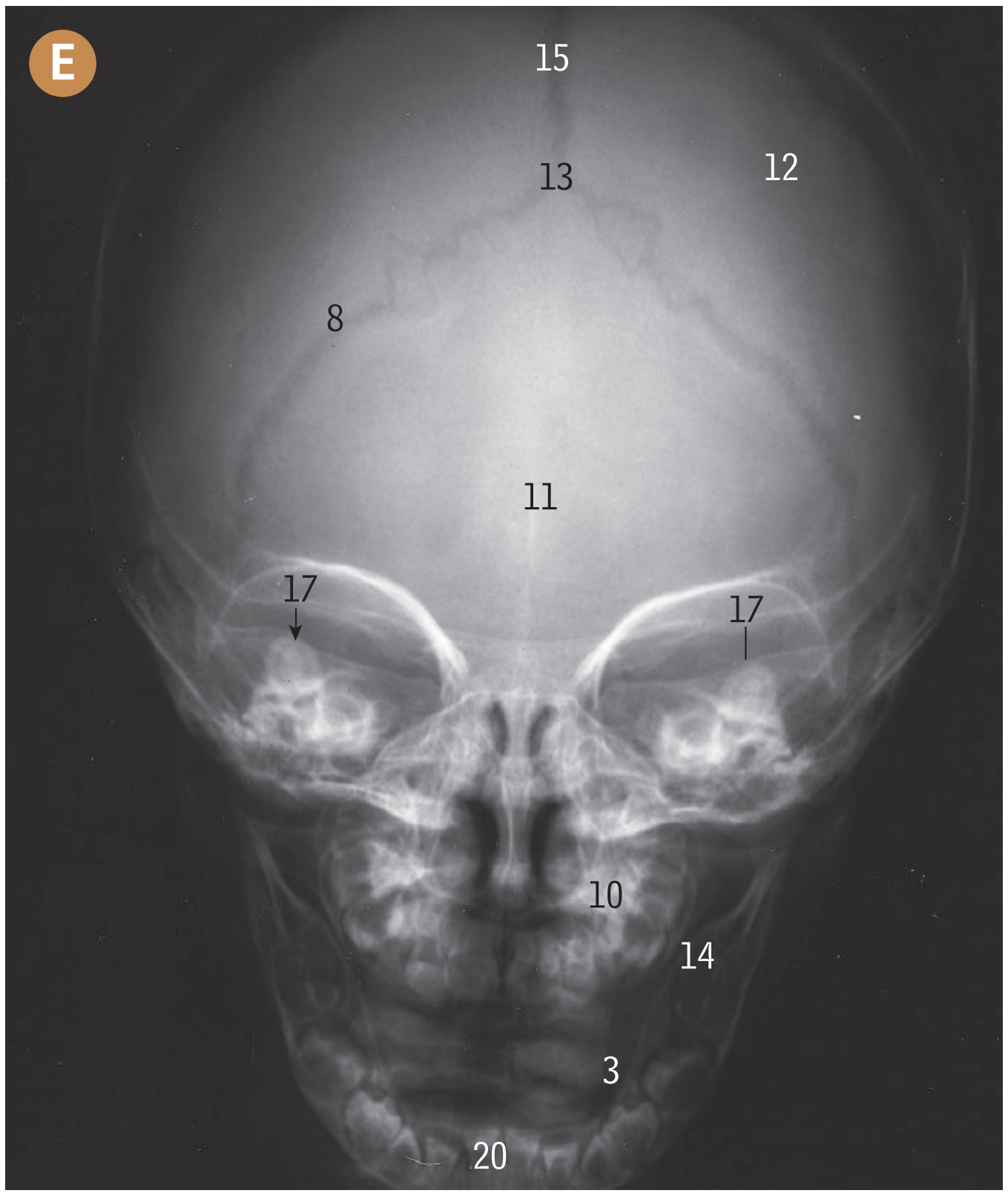

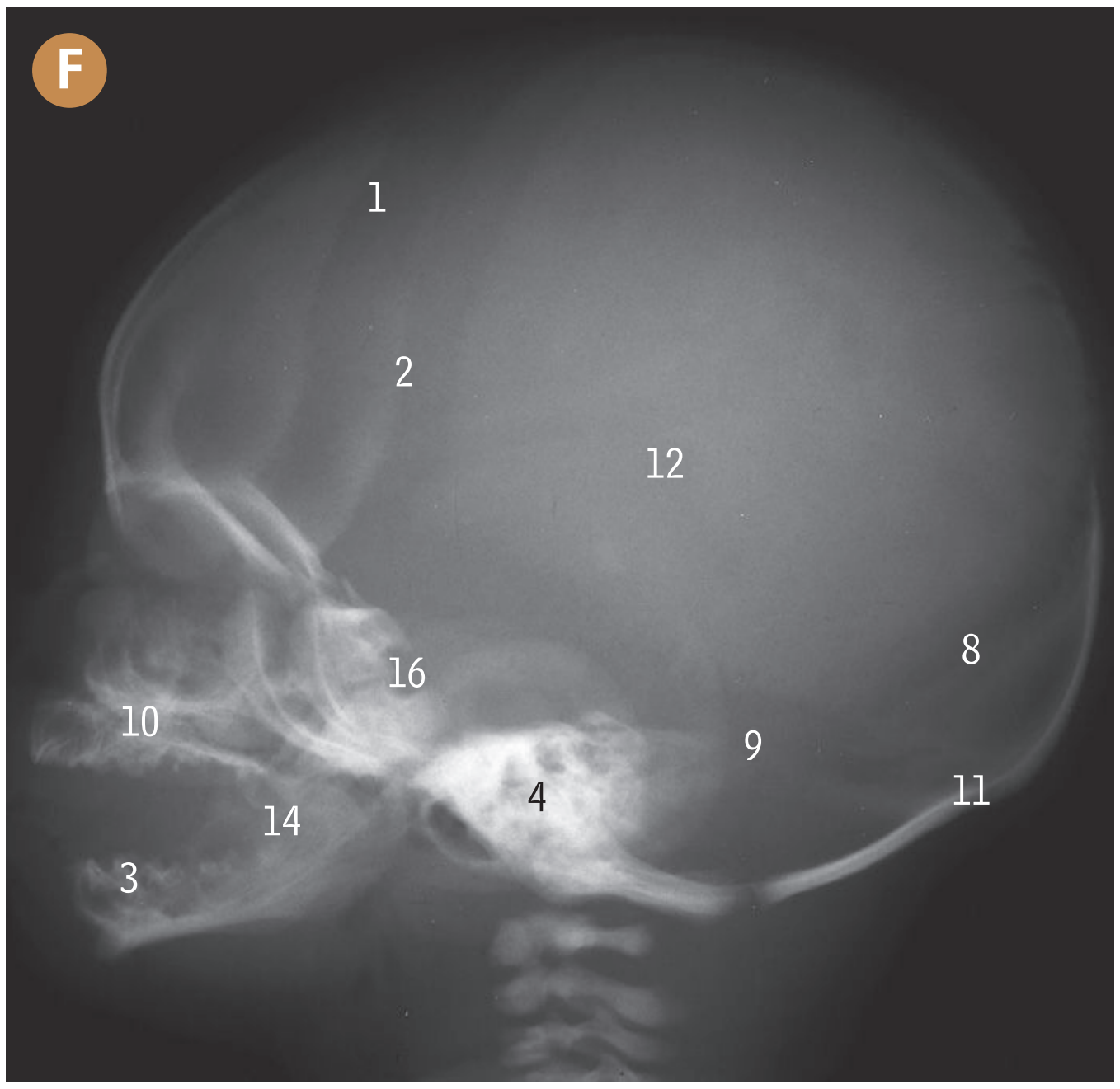

The face at birth forms a relatively smaller proportion of the cranium than in the adult (about one-eighth compared with one-half) because of the small size of the nasal cavity and maxillary sinuses and the lack of erupted teeth.

The posterior fontanelle (C13, E13) closes about 2 months after birth, the anterior fontanelle (A1, D1, F1) in the second year.

Owing to the lack of the mastoid process (which does not develop until the second year), the stylomastoid foramen (B19) and the emerging facial nerve are relatively near the surface and unprotected.

G **Resin cast of head and neck arteries** *full-term fetus, from the left*

In this cast of fetal arteries, note in the front of the neck the dense arterial pattern indicating the thyroid gland (G), and above and in front of it the fine vessels outlining the tongue (T).

Hydrocephalus, scalp wounds, see pages 80–82.

Skull A coloured left half of the skull in sagittal section

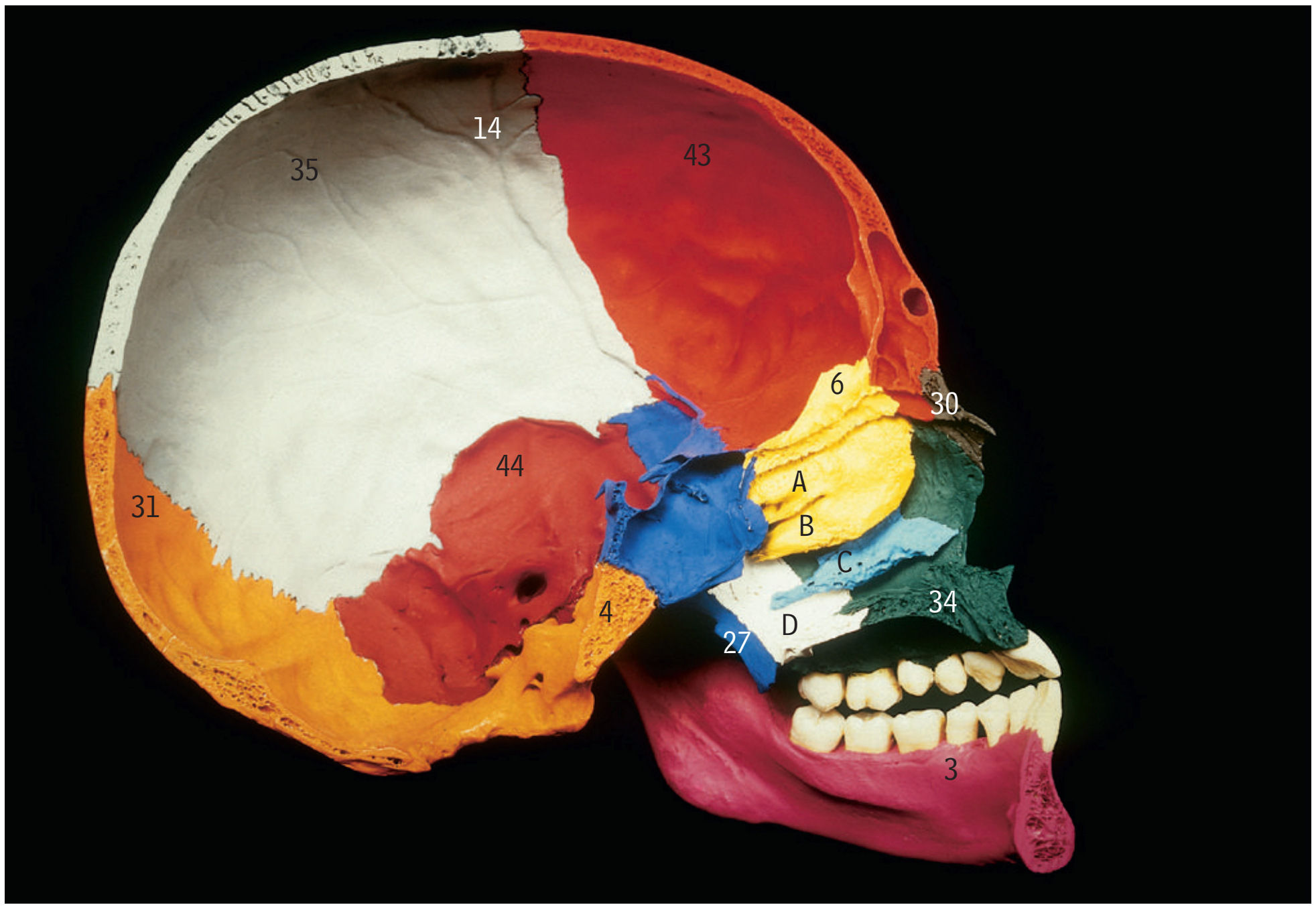

A Superior nasal concha
B Middle nasal concha
C Inferior nasal concha
D Palatine bone

See page 17 for additional label numbers.

NB: The perpendicular plate of the ethmoid has been removed to expose the conchae.

B cleared specimen from the front, illuminated from behind

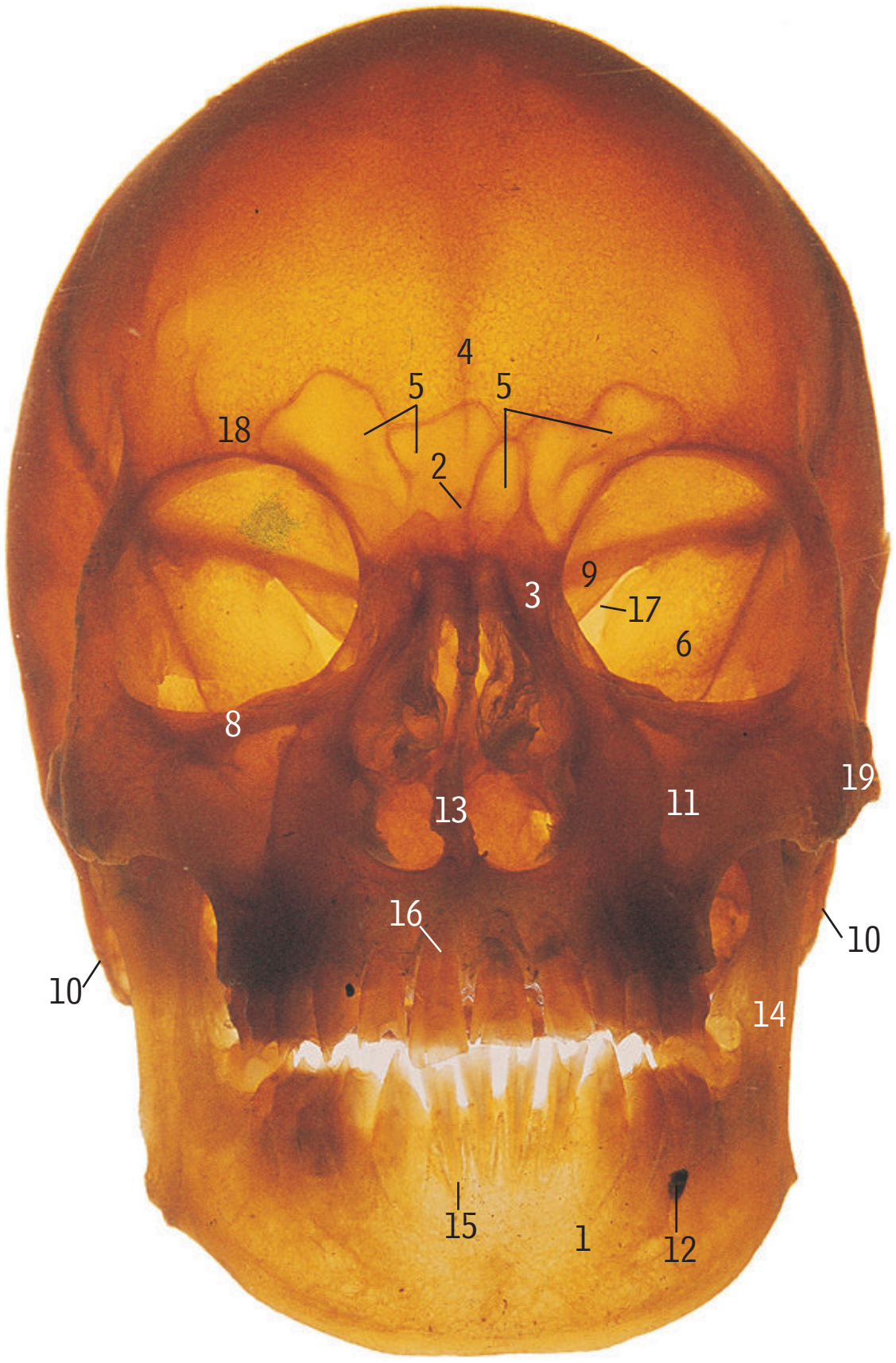

C radiograph of facial bones, occipitofrontal view

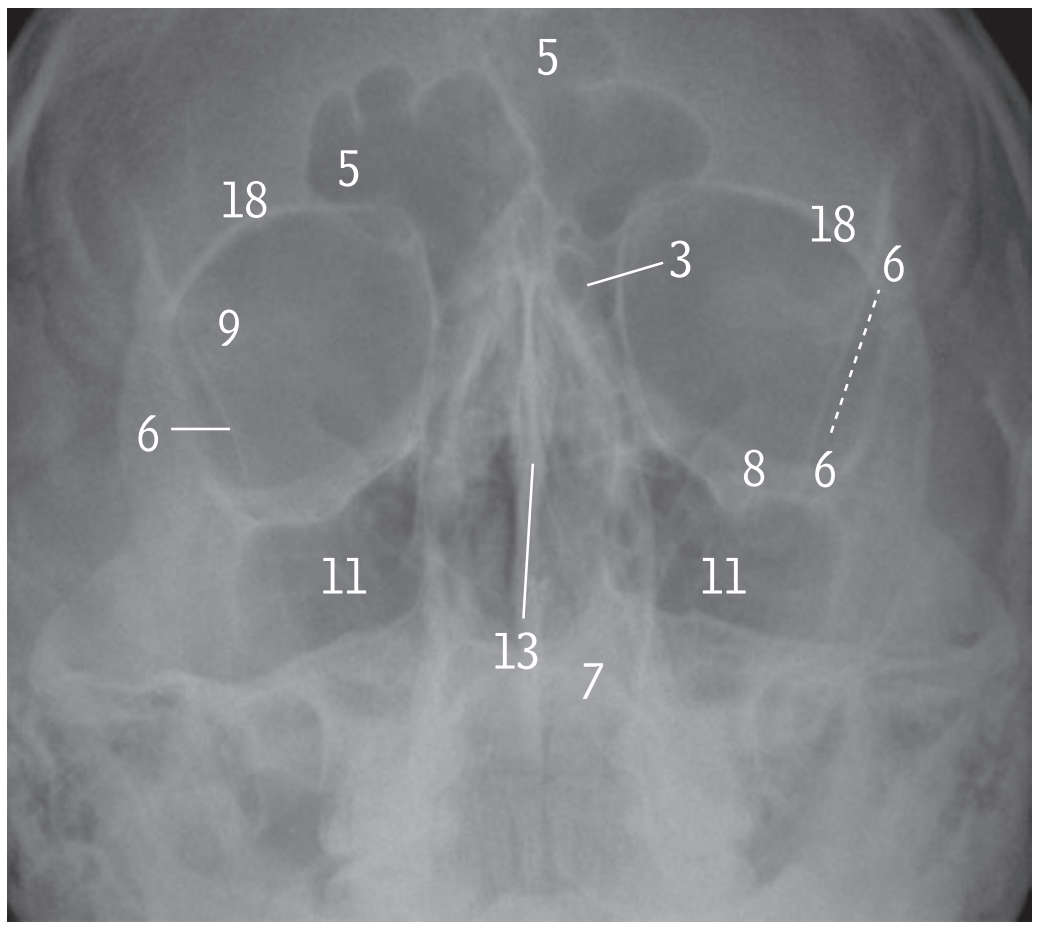

Compare with the skull on page 1.

1. Body of mandible
2. Crista galli
3. Ethmoidal air cells
4. Frontal crest
5. Frontal sinus
6. Greater wing of sphenoid bone
7. Inferior nasal concha
8. Infra-orbital margin
9. Lesser wing of sphenoid bone
10. Mastoid process
11. Maxillary sinus
12. Mental foramen
13. Nasal septum
14. Ramus of mandible
15. Root of lower lateral incisor
16. Root of upper central incisor
17. Superior orbital fissure
18. Supra-orbital margin
19. Zygomatic arch

Blow-out fractures of the orbit, mastoiditis, see pages 80–82.

Skull *left half of the skull in sagittal section*

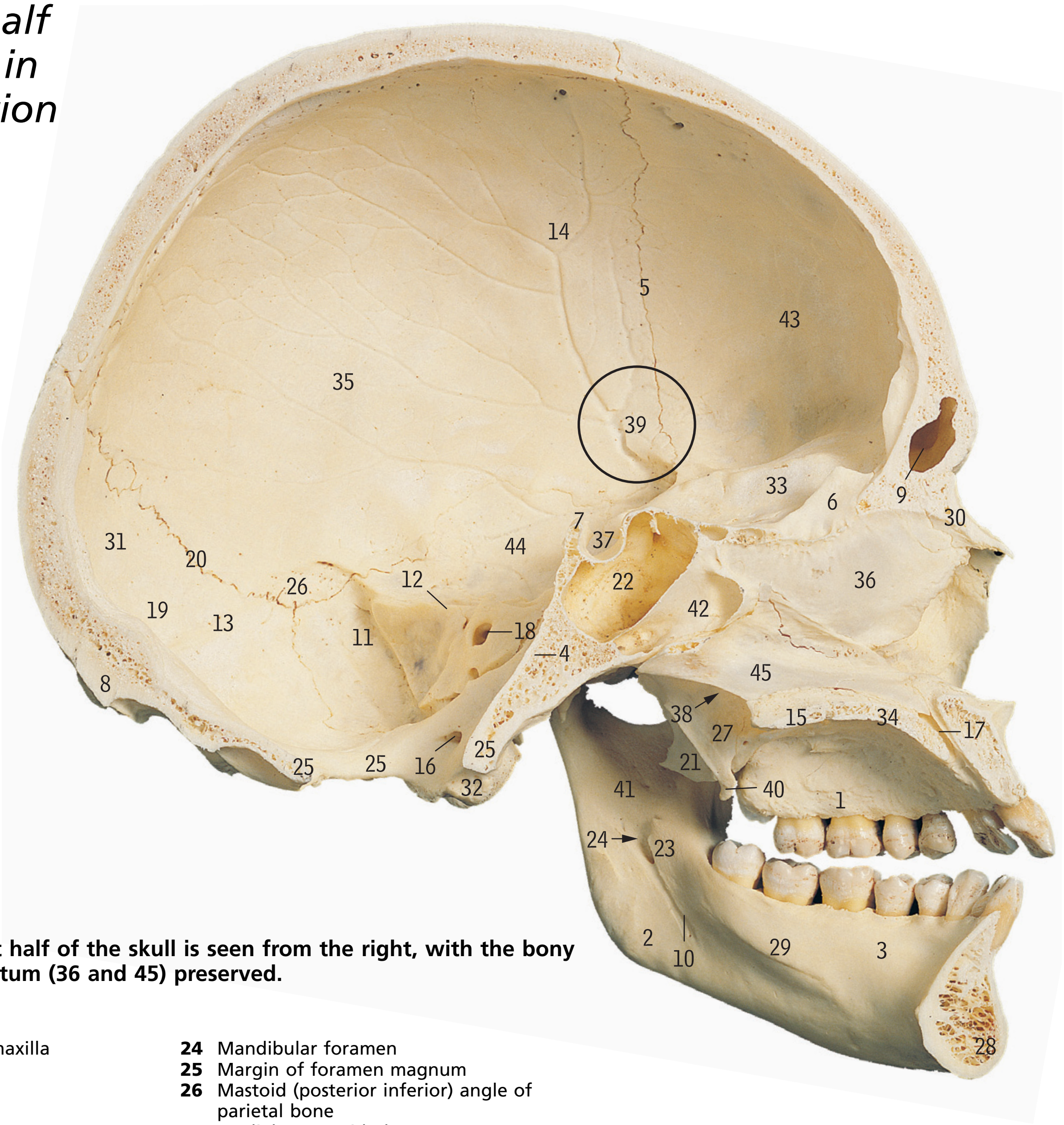

The inside of the left half of the skull is seen from the right, with the bony part of the nasal septum (36 and 45) preserved.

1 Alveolar process of maxilla
2 Angle of mandible
3 Body of mandible
4 Clivus
5 Coronal suture
6 Crista galli of ethmoid bone
7 Dorsum sellae
8 External occipital protuberance
9 Frontal sinus
10 Groove for mylohyoid nerve
11 Groove for sigmoid sinus
12 Groove for superior petrosal sinus
13 Groove for transverse sinus
14 Grooves for middle meningeal vessels (anterior division)
15 Horizontal plate of palatine bone
16 Hypoglossal canal
17 Incisive canal
18 Internal acoustic meatus in petrous part of temporal bone
19 Internal occipital protuberance
20 Lambdoid suture
21 Lateral pterygoid plate
22 Left sphenoidal sinus
23 Lingula
24 Mandibular foramen
25 Margin of foramen magnum
26 Mastoid (posterior inferior) angle of parietal bone
27 Medial pterygoid plate
28 Mental protuberance
29 Mylohyoid line
30 Nasal bone
31 Occipital bone
32 Occipital condyle
33 Orbital part of frontal bone
34 Palatine process of maxilla
35 Parietal bone
36 Perpendicular plate of ethmoid bone
37 Pituitary fossa (sella turcica)
38 Posterior nasal aperture (choana)
39 Pterion (encircled)
40 Pterygoid hamulus of medial pterygoid plate
41 Ramus of mandible
42 Right sphenoidal sinus
43 Squamous part of frontal bone
44 Squamous part of temporal bone
45 Vomer

The bony part of the nasal septum consists of the vomer (45) and the perpendicular plate of the ethmoid bone (36). The anterior part of the septum consists of the septal cartilage (pages 58 and 59).

In this skull, the sphenoidal sinuses (42 and 22) are large, and the right one (42) has extended to the left of the midline. The pituitary fossa (37) projects down into the left sinus (22).

The grooves for the middle meningeal vessels (14) pass upwards and backwards. The circle (39) marks the region of the pterion, and corresponds to the position shown on the outside of the skull on page 4.

Extradural haemorrhage, pituitary tumour, see pages 80–82.

Mandible

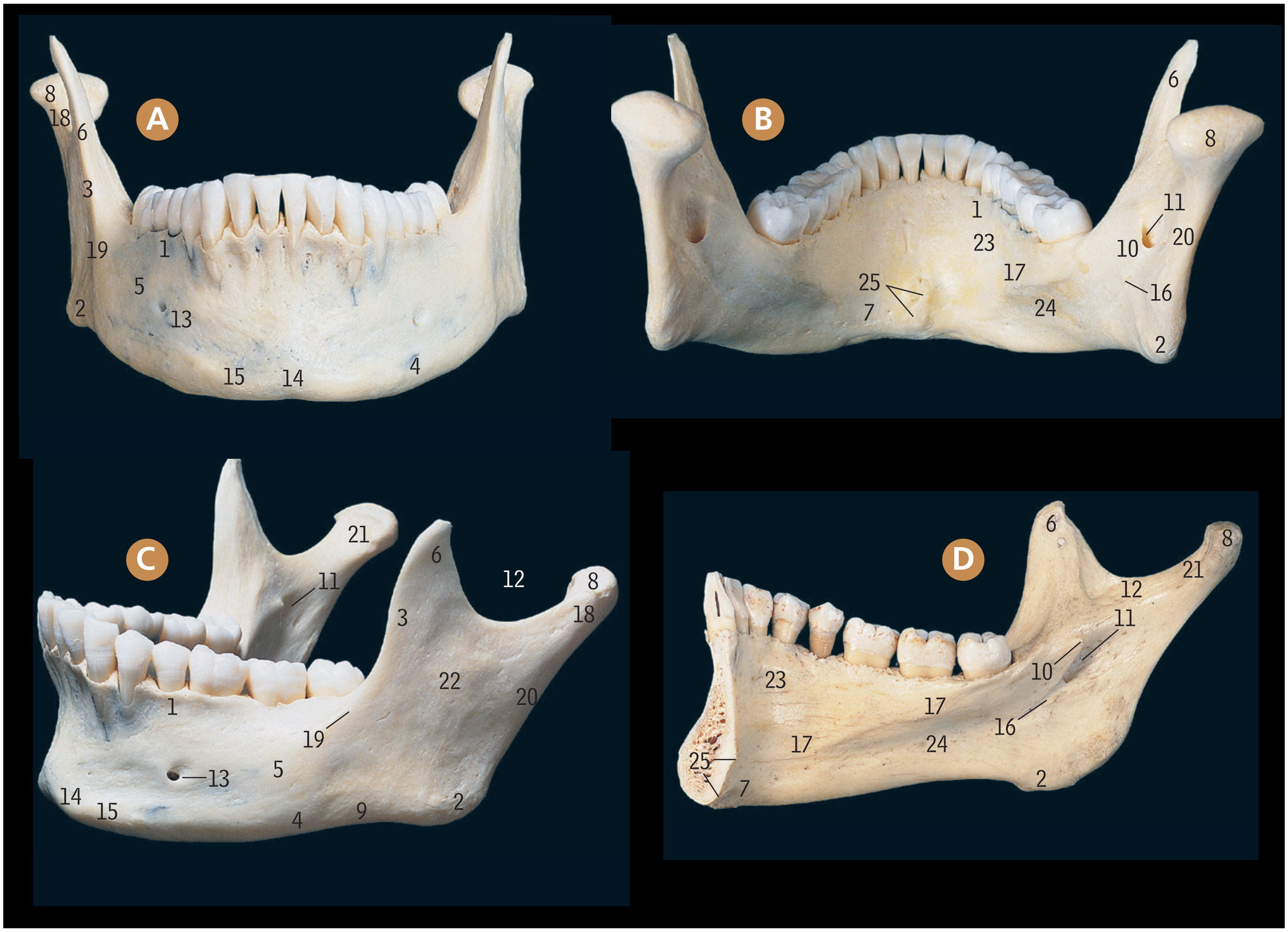

A from the front

B from behind

C from the left and front

D internal view from the left

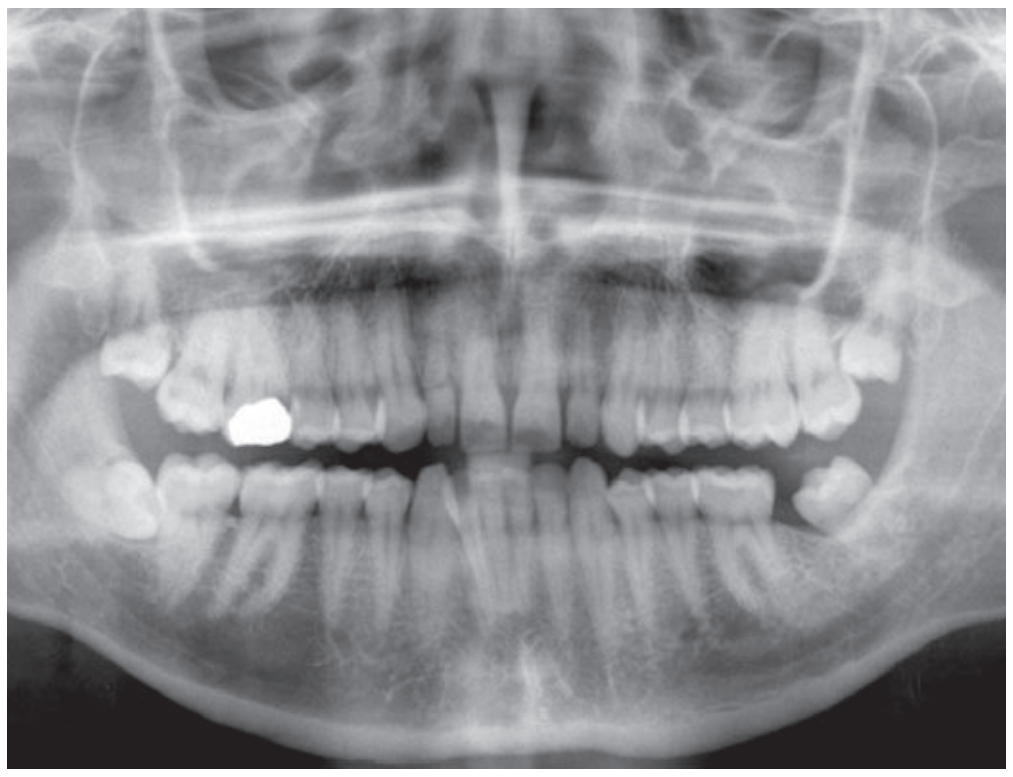

Orthopantomogram

Impacted wisdom tooth, mastoiditis, see *pages 80–82.*

1 Alveolar part
2 Angle
3 Anterior border of ramus
4 Base
5 Body
6 Coronoid process
7 Digastric fossa
8 Head
9 Inferior border of ramus
10 Lingula
11 Mandibular foramen
12 Mandibular notch
13 Mental foramen
14 Mental protuberance
15 Mental tubercle
16 Mylohyoid groove
17 Mylohyoid line
18 Neck
19 Oblique line
20 Posterior border of ramus
21 Pterygoid fovea
22 Ramus
23 Sublingual fossa
24 Submandibular fossa
25 Superior and inferior mental spines (genial tubercles)

The head (8) and the neck (18, including the pterygoid fovea, 21) constitute the condyle.

The alveolar part (1) contains the sockets for the roots of the teeth.

The base (4) is the inferior border of the body (5), and becomes continuous with the inferior border (9) of the ramus (22).

Mandible *muscle attachments*

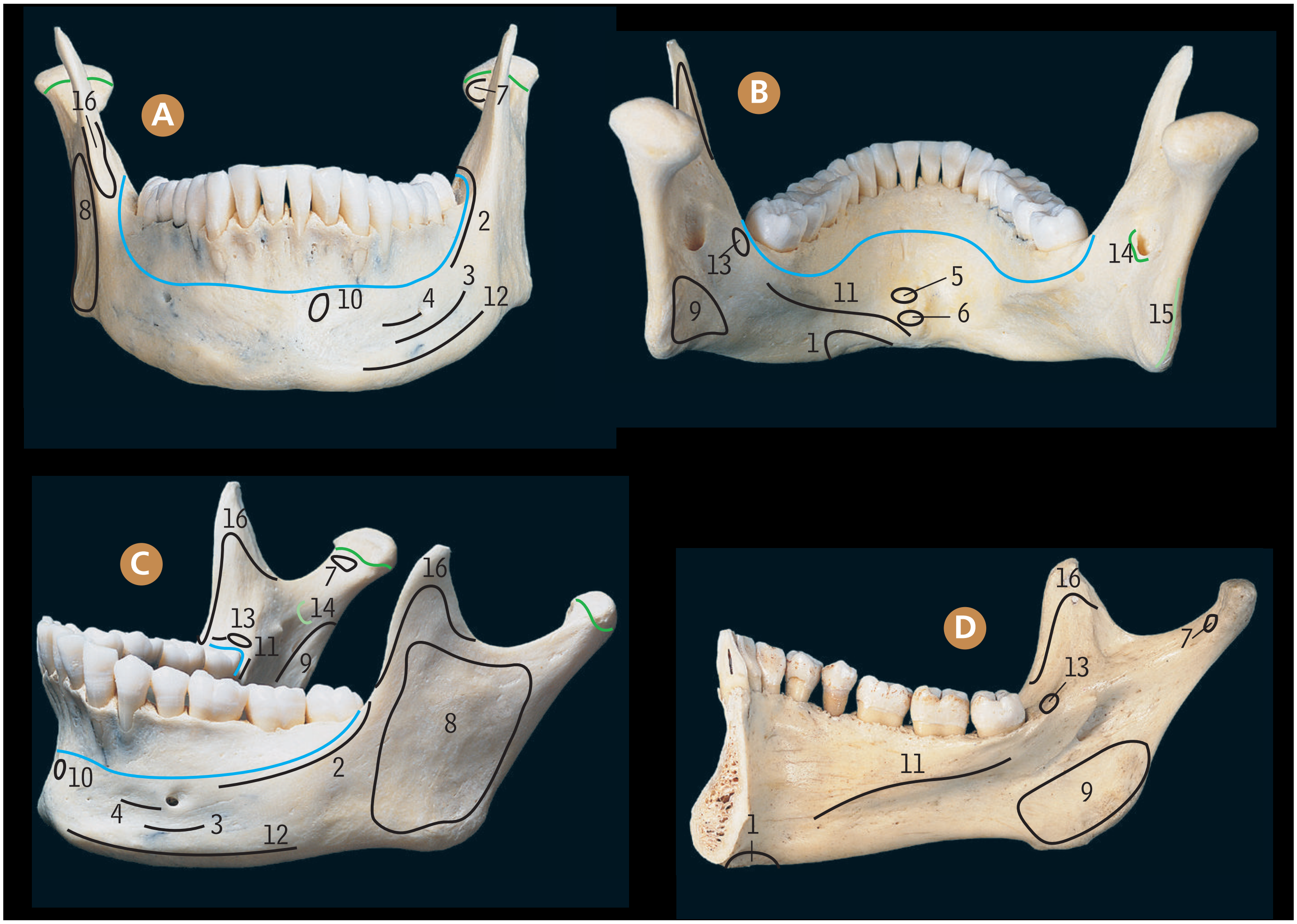

A from the front

B from behind

C from the left and front

D internal view from the left

Green line = capsular attachment of temporomandibular joint; blue line = limit of attachment of the oral mucous membrane; pale green line = ligament attachment

1. Anterior belly of digastric
2. Buccinator
3. Depressor anguli oris
4. Depressor labii inferioris
5. Genioglossus
6. Geniohyoid
7. Lateral pterygoid
8. Masseter
9. Medial pterygoid
10. Mentalis
11. Mylohyoid
12. Platysma
13. Pterygomandibular raphe and superior constrictor
14. Sphenomandibular ligament
15. Stylomandibular ligament
16. Temporalis

The lateral pterygoid (A7) is attached to the pterygoid fovea on the neck of the mandible (and also to the capsule of the temporomandibular joint and the articular disc – see page 42, A27, A28).

The medial pterygoid (B9, C9) is attached to the medial surface of the angle of the mandible, below the groove for the mylohyoid nerve.

Masseter (C8) is attached to the lateral surface of the ramus.

Temporalis (C16) is attached over the coronoid process, extending back as far as the deepest part of the mandibular notch and downwards over the front of the ramus almost as far as the last molar tooth.

Buccinator (C2) is attached opposite the three molar teeth, at the back reaching the pterygomandibular raphe (C13).

Genioglossus (B5) is attached to the upper mental spine and geniohyoid (B6) to the lower.

Mylohyoid (11) is attached to the mylohyoid line.

The attachment of the lateral temporomandibular ligament to the lateral aspect of the neck of the condyle is not shown.

Fractured mandible, see pages 80–82.

Frontal bone

A external surface from the front

B external surface from the left

C from below

D internal surface from above and behind (right half removed; ethmoidal notch is inferior)

1. Anterior ethmoidal canal (position of groove)
2. Ethmoidal notch
3. Foramen caecum
4. Fossa for lacrimal gland
5. Frontal crest
6. Frontal sinus
7. Frontal tuberosity
8. Glabella
9. Inferior temporal line
10. Nasal spine
11. Orbital part
12. Position of frontal notch or foramen
13. Posterior ethmoidal canal (position of groove)
14. Roof of ethmoidal air cells
15. Sagittal crest
16. Superciliary arch
17. Superior temporal line
18. Supra-orbital margin
19. Supra-orbital notch or foramen
20. Trochlear fovea (or tubercle)
21. Zygomatic process

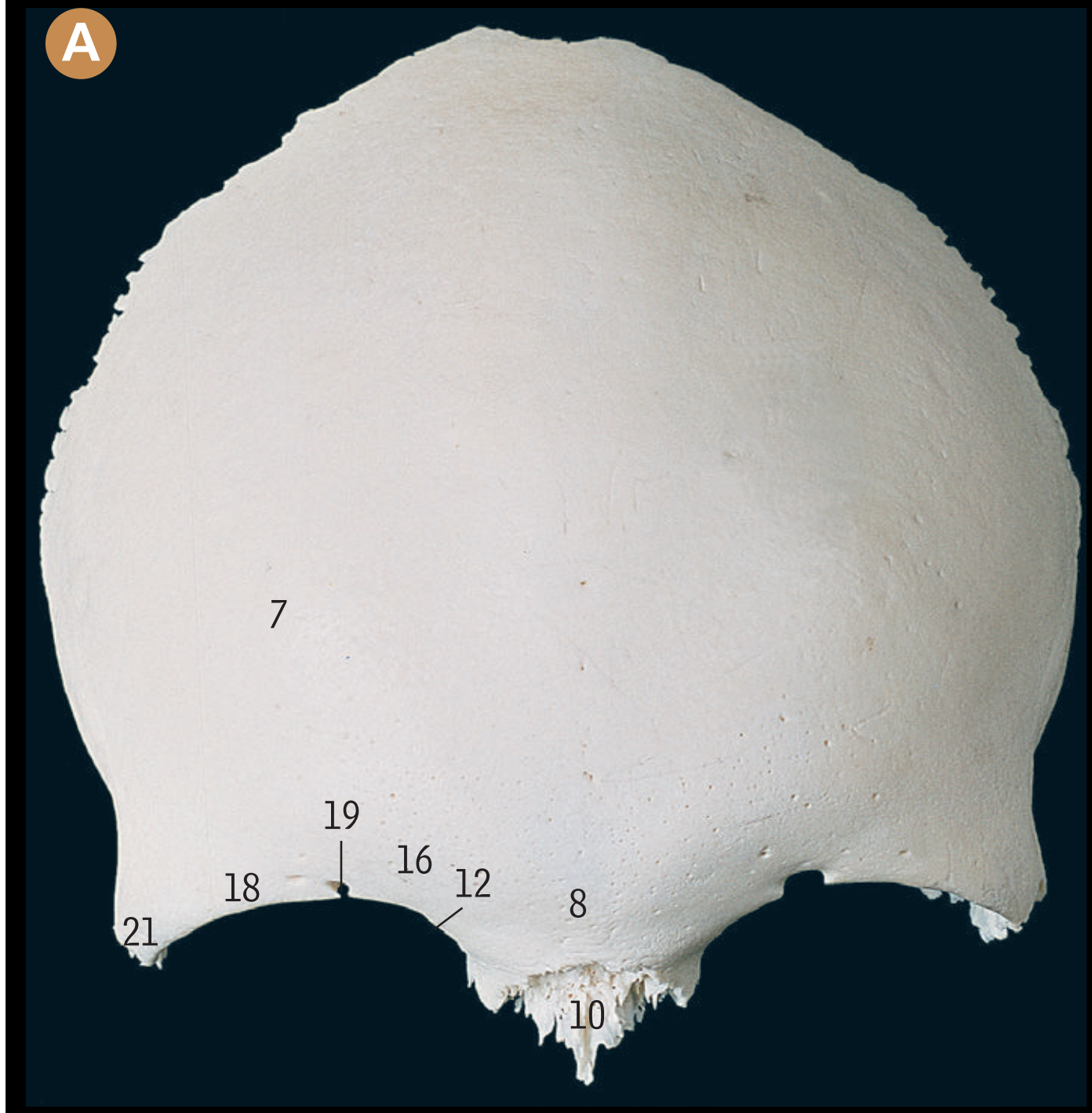

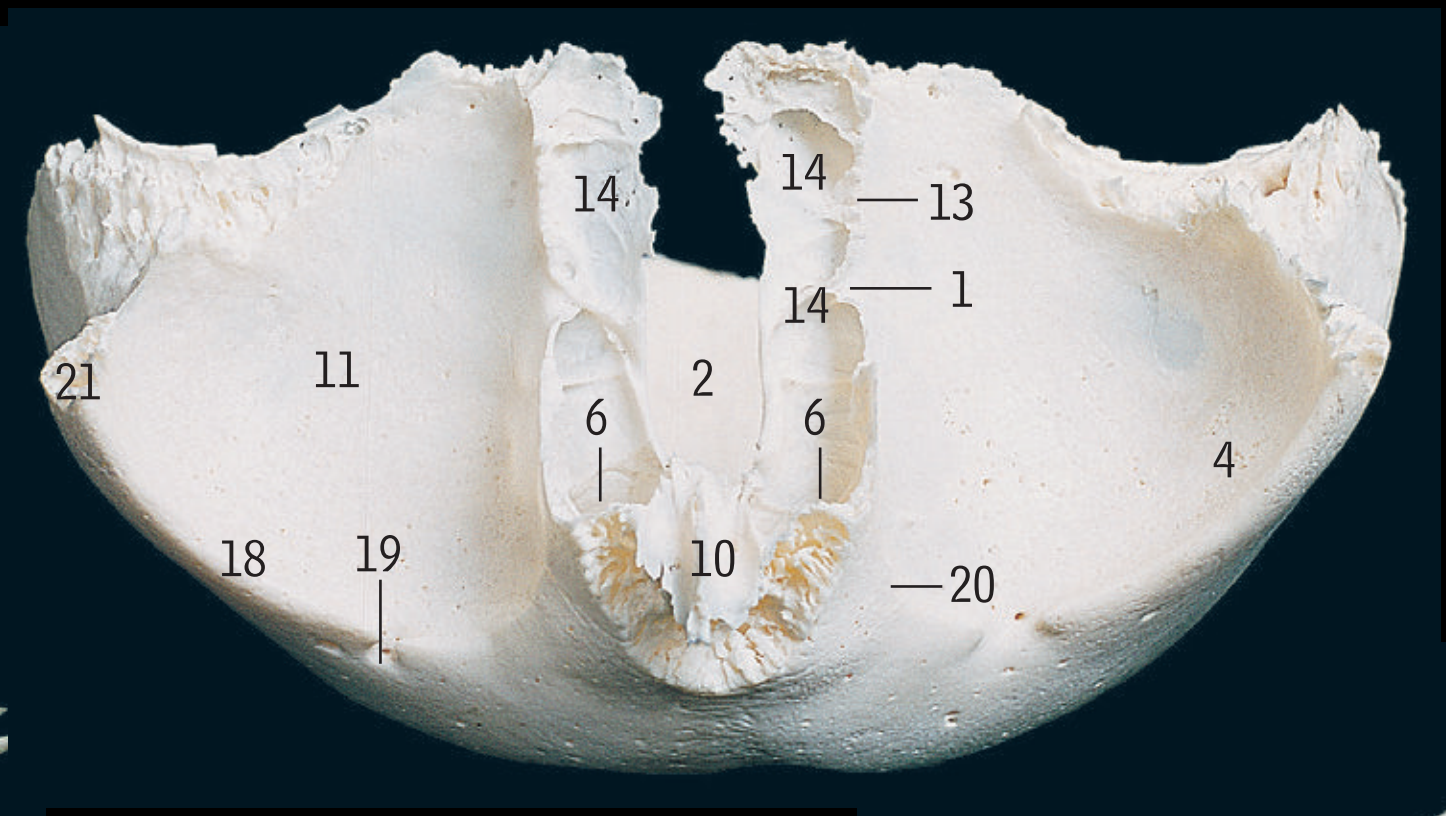

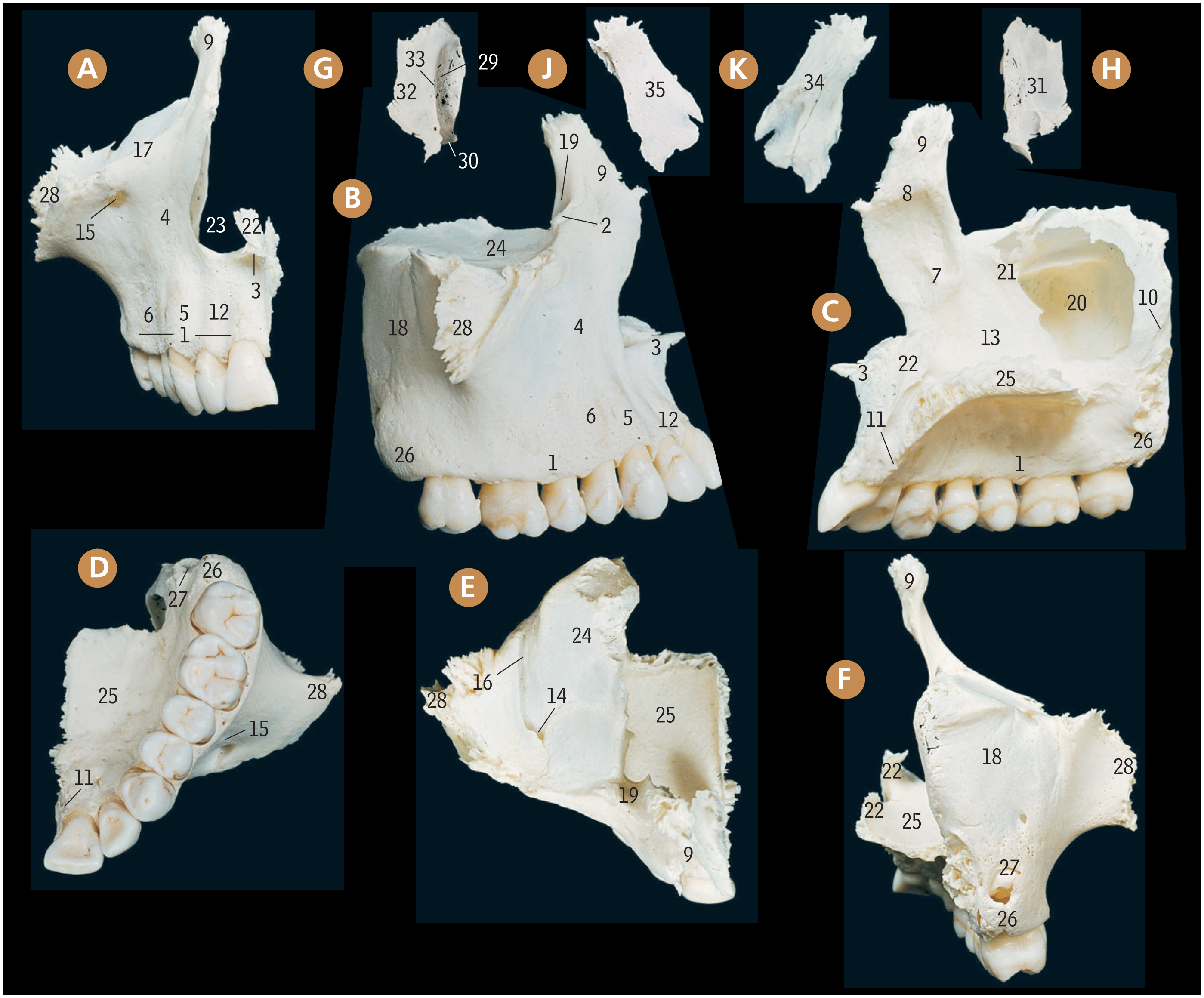

Right maxilla

A from the front

B from the lateral side

C from the medial side

D from below

E from above

F from behind

1 Alveolar process
2 Anterior lacrimal crest
3 Anterior nasal spine
4 Anterior surface
5 Canine eminence
6 Canine fossa
7 Conchal crest
8 Ethmoidal crest
9 Frontal process
10 Greater palatine canal (position of groove)
11 Incisive canal
12 Incisive fossa
13 Inferior meatus
14 Infra-orbital canal
15 Infra-orbital foramen
16 Infra-orbital groove
17 Infra-orbital margin
18 Infratemporal surface
19 Lacrimal groove
20 Maxillary hiatus and sinus
21 Middle meatus
22 Nasal crest
23 Nasal notch
24 Orbital surface
25 Palatine process
26 Tuberosity
27 Unerupted third molar tooth
28 Zygomatic process

Right lacrimal bone

G from the lateral (orbital) side

H from the medial (nasal) side

29 Lacrimal groove
30 Lacrimal hamulus
31 Nasal surface
32 Orbital surface
33 Posterior lacrimal crest

Right nasal bone

J from the lateral side

K from the medial side

34 Internal surface and groove for anterior ethmoidal nerve
35 Lateral surface

Right palatine bone

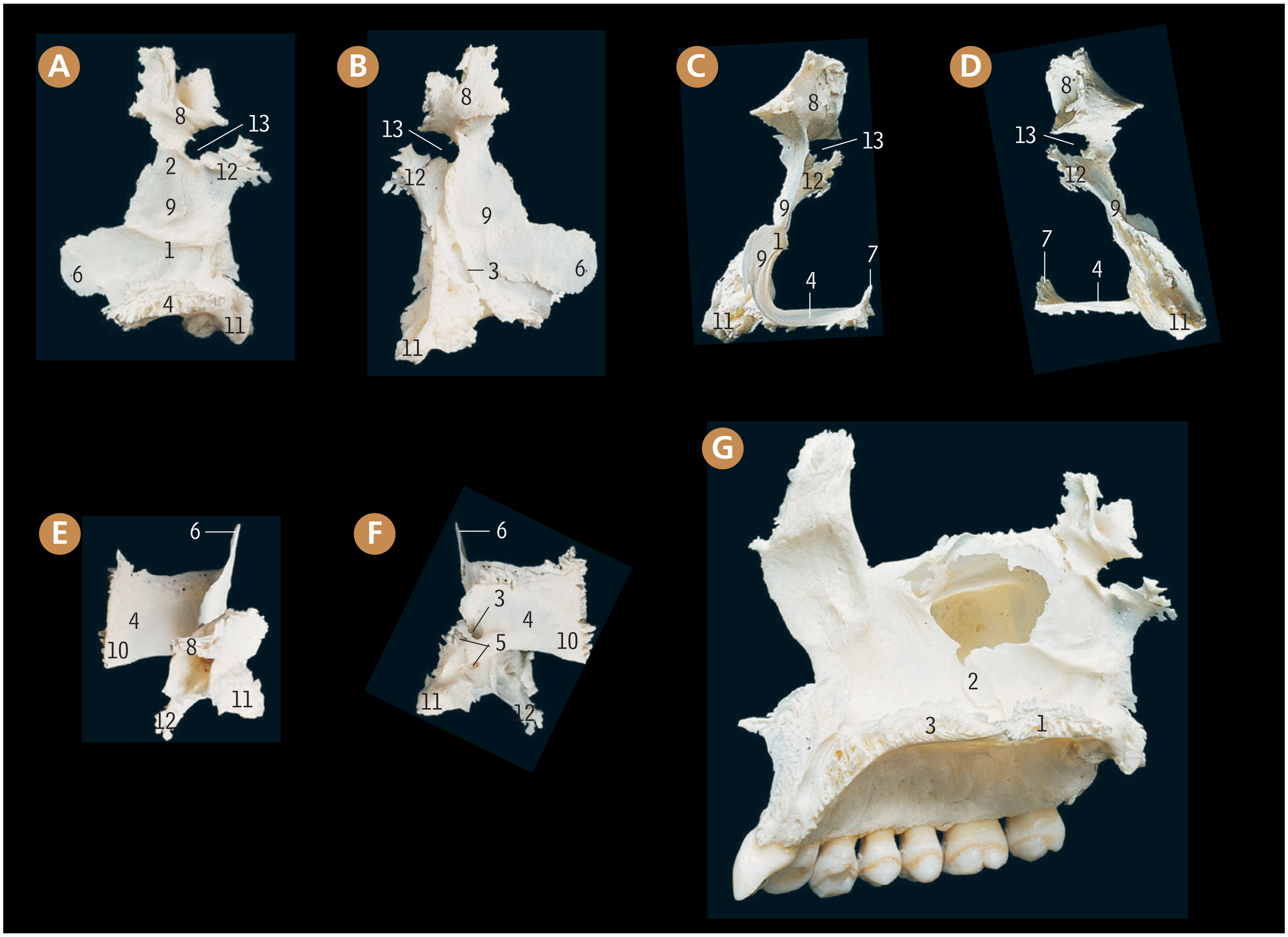

A from the medial side

B from the lateral side

C from the front

D from behind

E from above

F from below

G Articulation of the right maxilla and the palatine bone, from the medial side

1 Horizontal plate of palatine
2 Maxillary process of palatine
3 Palatine process of maxilla

1 Conchal crest
2 Ethmoidal crest
3 Greater palatine groove
4 Horizontal plate
5 Lesser palatine canals
6 Maxillary process
7 Nasal crest
8 Orbital process
9 Perpendicular plate
10 Posterior nasal spine
11 Pyramidal process
12 Sphenoidal process
13 Sphenopalatine notch

Right temporal bone

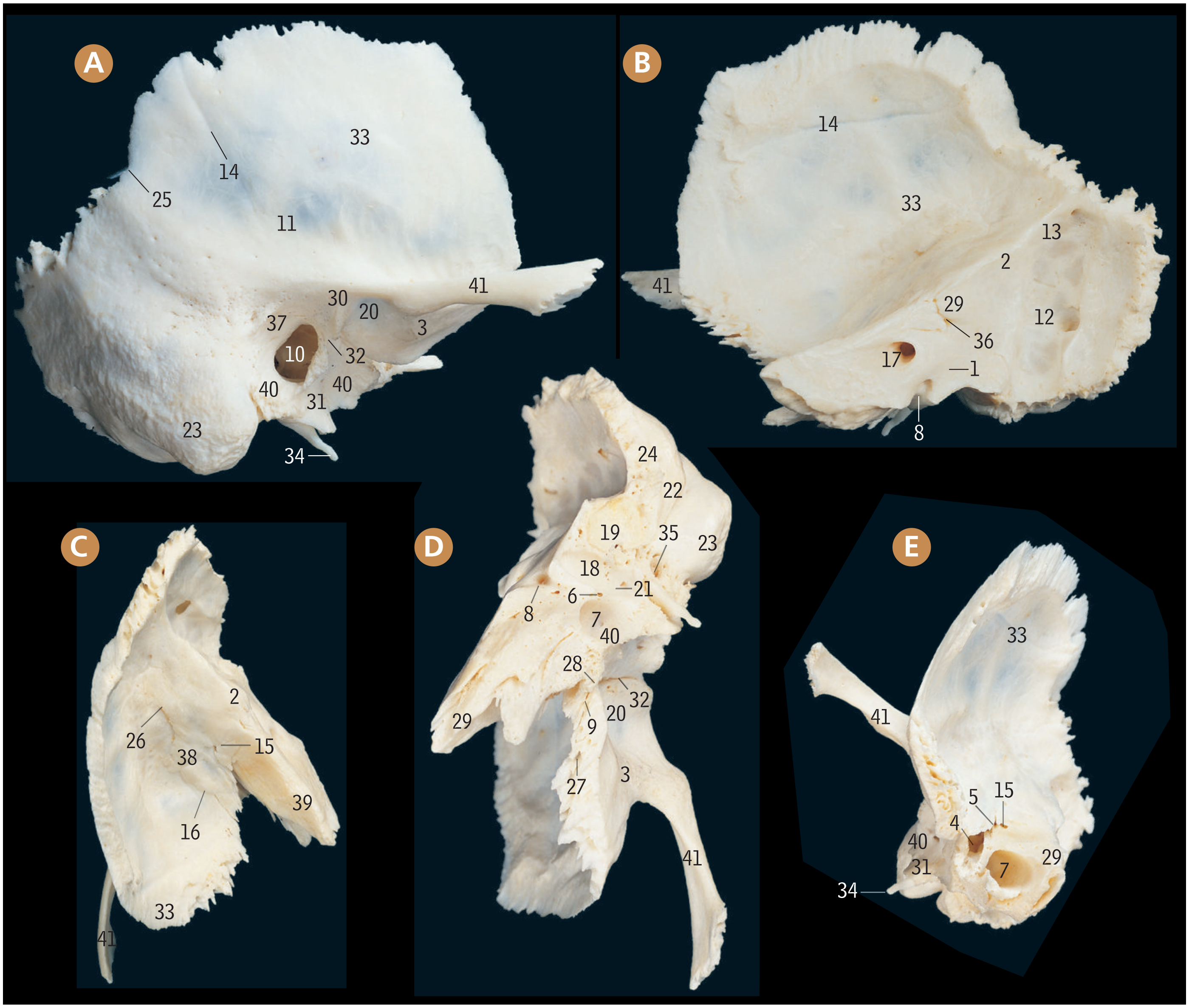

A external aspect

B internal aspect

C from above

D from below

E from the front

1 Aqueduct of vestibule
2 Arcuate eminence
3 Articular tubercle
4 Auditory (eustachian) tube
5 Canal for tensor tympani
6 Canaliculus for tympanic branch of glossopharyngeal nerve
7 Carotid canal
8 Cochlear canaliculus
9 Edge of tegmen tympani
10 External acoustic meatus
11 Groove for middle temporal artery
12 Groove for sigmoid sinus
13 Groove for superior petrosal sinus
14 Grooves for branches of middle meningeal vessels
15 Hiatus and groove for greater petrosal nerve
16 Hiatus and groove for lesser petrosal nerve
17 Internal acoustic meatus
18 Jugular fossa
19 Jugular surface
20 Mandibular fossa
21 Mastoid canaliculus for auricular branch of vagus nerve
22 Mastoid notch
23 Mastoid process
24 Occipital groove
25 Parietal notch
26 Petrosquamous fissure (from above)
27 Petrosquamous fissure (from below)
28 Petrotympanic fissure
29 Petrous part
30 Postglenoid tubercle
31 Sheath of styloid process
32 Squamotympanic fissure
33 Squamous part
34 Styloid process
35 Stylomastoid foramen
36 Subarcuate fossa
37 Suprameatal triangle
38 Tegmen tympani
39 Trigeminal impression on apex of petrous part
40 Tympanic part
41 Zygomatic process

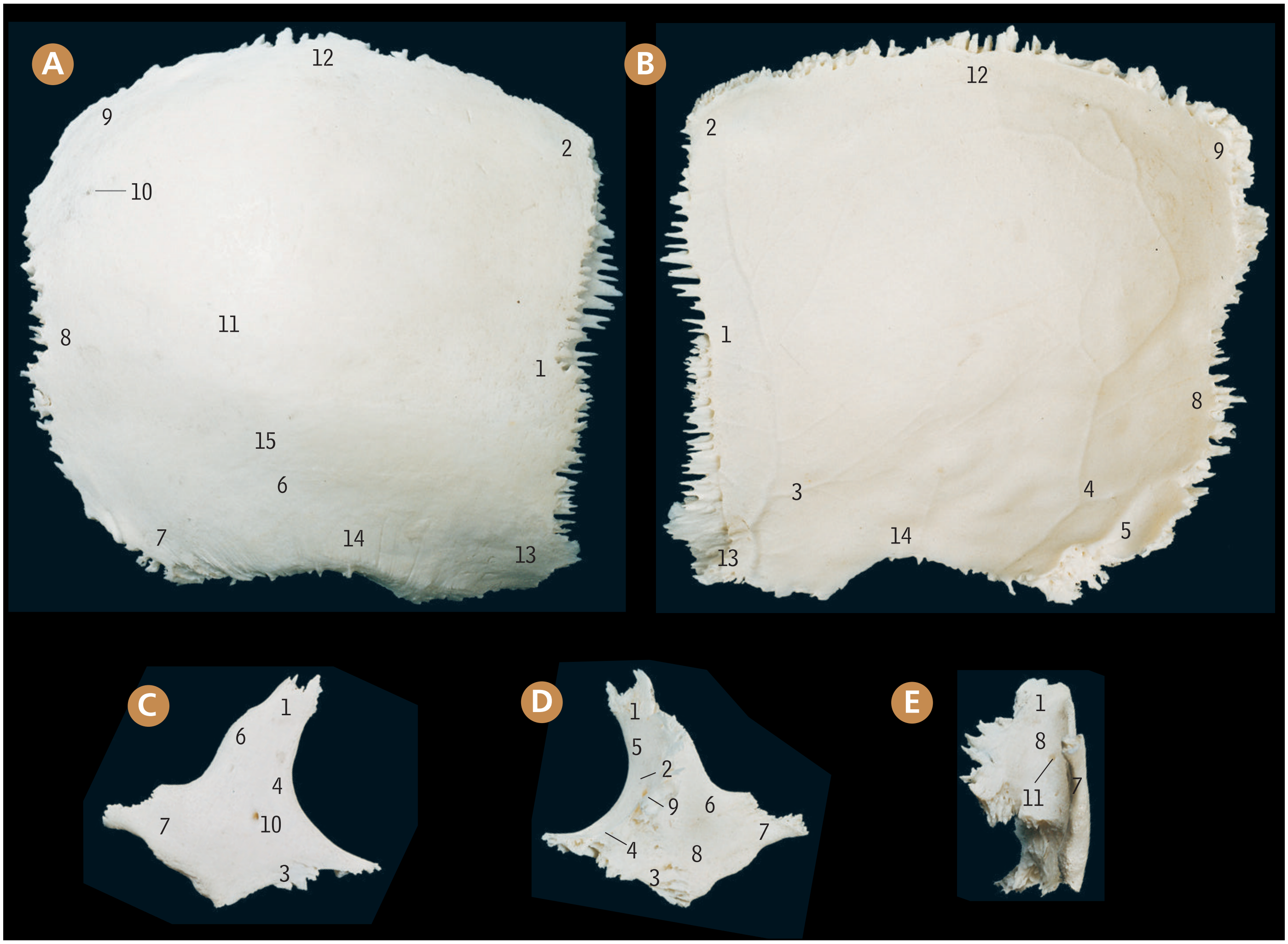

Right parietal bone

A external surface

B internal surface

1 Frontal (anterior) border
2 Frontal (antero-superior) angle
3 Furrows for frontal branch of middle meningeal vessels (anterior division)
4 Furrows for parietal branch of middle meningeal vessels (posterior division)
5 Groove for sigmoid sinus at mastoid angle
6 Inferior temporal line
7 Mastoid (postero-inferior) angle
8 Occipital (posterior) border
9 Occipital (postero-superior) angle
10 Parietal foramen
11 Parietal tuberosity
12 Sagittal (superior) border
13 Sphenoidal (antero-inferior) angle
14 Squamosal (inferior) border
15 Superior temporal line

Right zygomatic bone

C lateral surface

D from the medial side

E from behind

1 Frontal process
2 Marginal tubercle
3 Maxillary border
4 Orbital border
5 Orbital surface
6 Temporal border
7 Temporal process
8 Temporal surface
9 Zygomatico-orbital foramen
10 Zygomaticofacial foramen
11 Zygomaticotemporal foramen

The zygomatic process of the temporal bone (page 4, 37) and the temporal process of the zygomatic bone (C7, D7) form the zygomatic arch (page 4, 35).

Sphenoid bone

A from the front

B from behind

C from above and behind

D from below

E from the left

Vomer

F from the right

G from behind

1 Ala of vomer
2 Anterior clinoid process
3 Body with openings of sphenoidal sinuses
4 Carotid groove
5 Cerebral surface of greater wing
6 Dorsum sellae
7 Ethmoidal spine
8 Foramen ovale
9 Foramen rotundum
10 Foramen spinosum
11 Groove for nasopalatine nerve and vessels
12 Infratemporal crest of greater wing
13 Infratemporal surface of greater wing
14 Jugum
15 Lateral pterygoid plate
16 Lesser wing
17 Medial pterygoid plate
18 Optic canal
19 Orbital surface of greater wing
20 Posterior border of vomer
21 Posterior clinoid process
22 Prechiasmatic groove
23 Pterygoid canal
24 Pterygoid hamulus
25 Pterygoid notch
26 Pterygoid process
27 Rostrum
28 Scaphoid fossa
29 Sella turcica (pituitary fossa)
30 Spine
31 Superior orbital fissure
32 Temporal surface of greater wing
33 Tuberculum sellae
34 Vaginal process

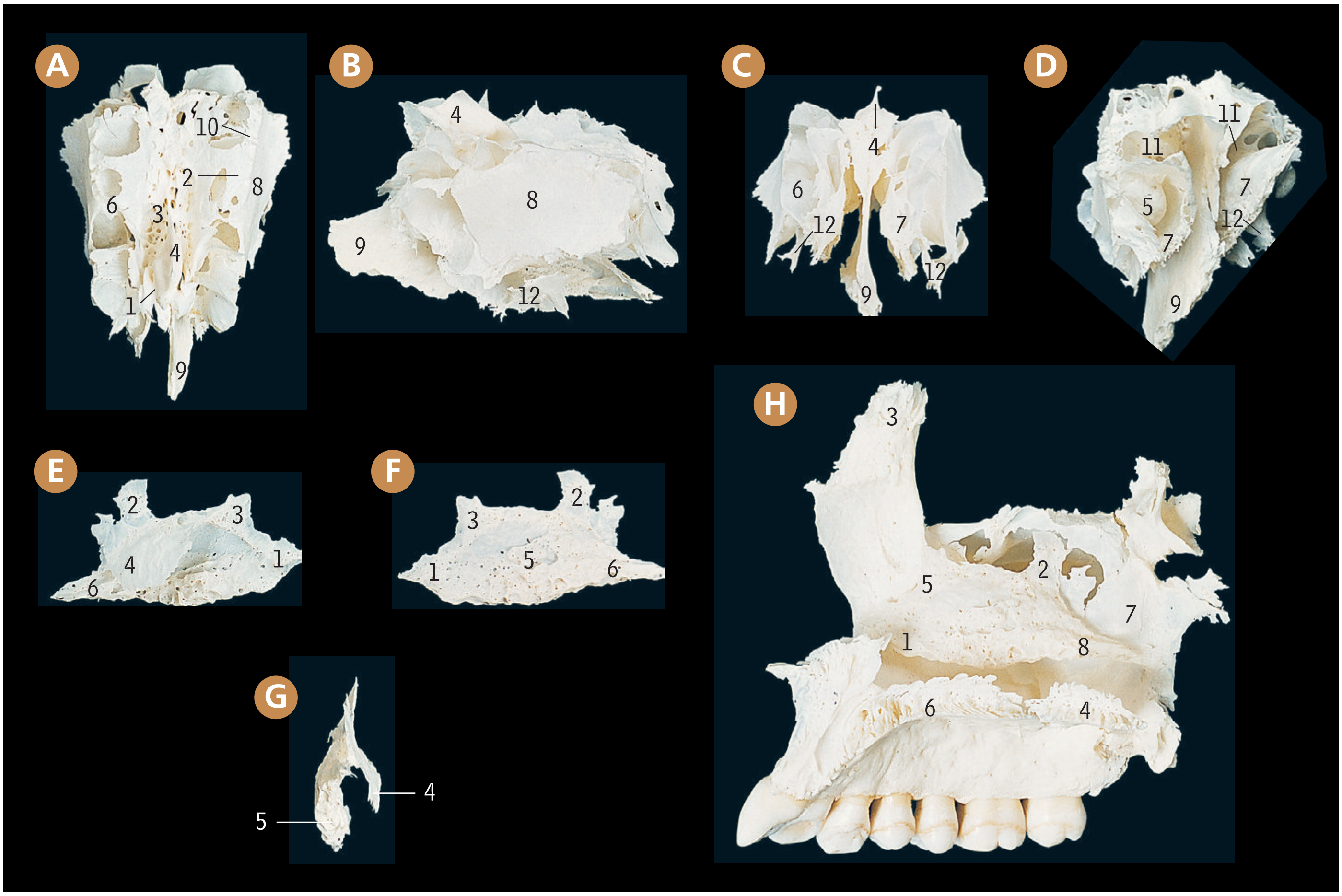

Ethmoid bone

A from above

B from the left

C from the front

D from the left, below and behind

1 Ala of crista galli
2 Anterior ethmoidal groove
3 Cribriform plate
4 Crista galli
5 Ethmoidal bulla
6 Ethmoidal labyrinth (containing ethmoidal air cells)
7 Middle nasal concha
8 Orbital plate
9 Perpendicular plate
10 Posterior ethmoidal groove
11 Superior nasal concha (meatus)
12 Uncinate process

Right inferior nasal concha

E from the lateral side

F from the medial side

G from behind

1 Anterior end
2 Ethmoidal process
3 Lacrimal process
4 Maxillary process
5 Medial surface
6 Posterior end

Maxilla

H Articulation of right maxilla, palatine bone and inferior nasal concha, from the medial side

1 Anterior end of inferior nasal concha
2 Ethmoidal process of inferior nasal concha
3 Frontal process of maxilla
4 Horizontal plate of palatine
5 Lacrimal process of inferior nasal concha
6 Palatine process of maxilla
7 Perpendicular plate of palatine
8 Posterior end of inferior nasal concha

Occipital bone

A external surface from below

B internal surface

C external surface from the right and below

D bones of the base of the skull

orange, occipital; red, temporal; blue, sphenoid

1 Basilar part
2 Cerebellar fossa
3 Cerebral fossa
4 Condylar fossa (and condylar canal in B and C)
5 Condyle
6 External occipital crest
7 External occipital protuberance
8 Foramen magnum
9 Groove for inferior petrosal sinus
10 Groove for sigmoid sinus
11 Groove for superior sagittal sinus
12 Groove for transverse sinus
13 Highest nuchal line
14 Hypoglossal canal
15 Inferior nuchal line
16 Internal occipital crest
17 Internal occipital protuberance
18 Jugular notch
19 Jugular process
20 Jugular tubercle
21 Lambdoid margin
22 Lateral angle
23 Lateral part
24 Mastoid margin
25 Pharyngeal tubercle
26 Squamous part
27 Superior angle
28 Superior nuchal line

Neck *surface markings of the front and right side*

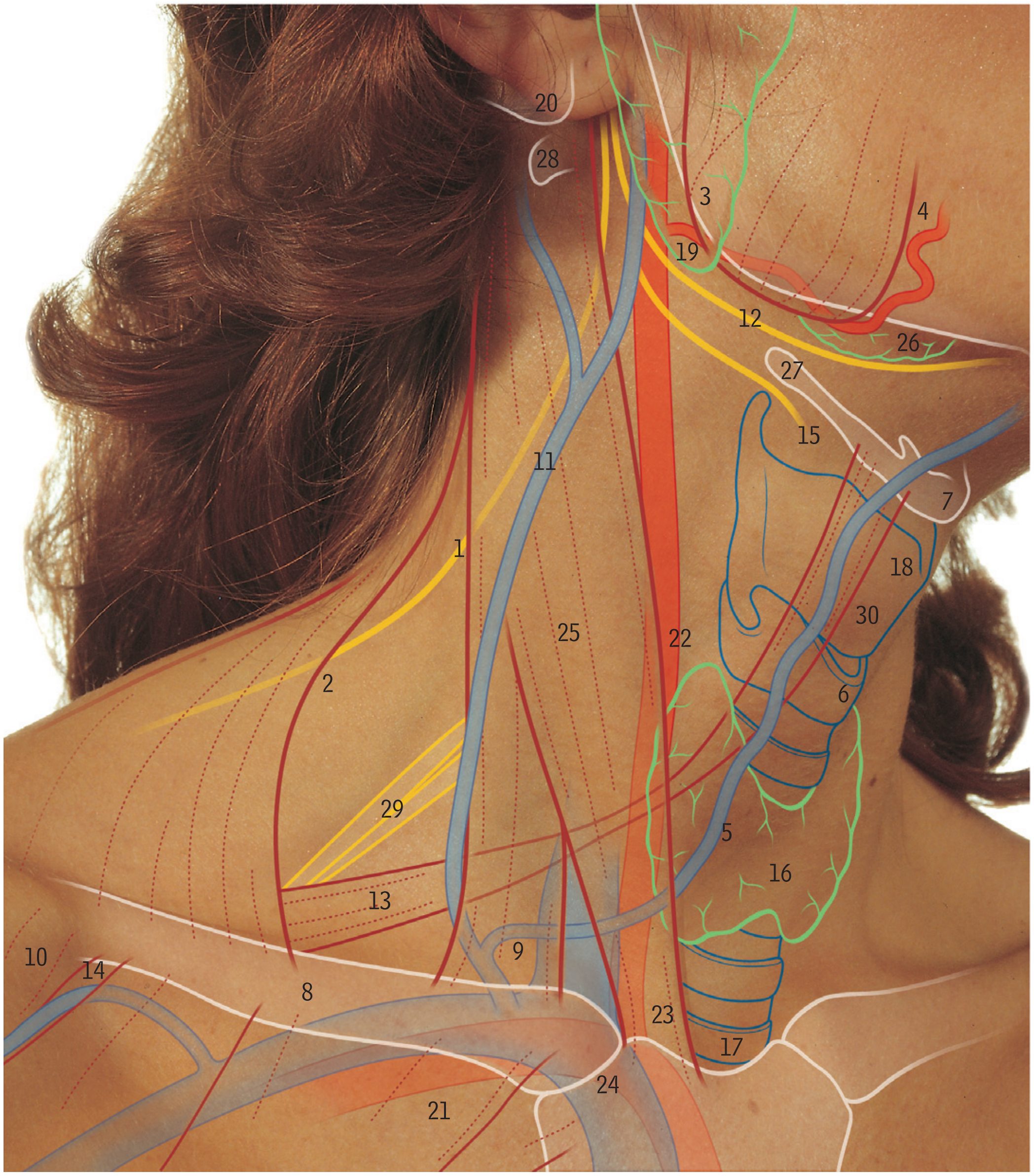

The pulsation of the common carotid artery (22, opposite page, 8) can be felt by backward pressure in the angle between the lower anterior border of sternocleidomastoid and the side of the larynx and trachea.

The cricoid cartilage (6) is about 5 cm (2 in) above the jugular notch of the manubrium of the sternum (17).

The lower end of the internal jugular vein lies behind the interval between the sternal (23) and clavicular (9) heads of sternocleidomastoid (when viewed from the front), just above the point where it joins the subclavian vein to form the brachiocephalic vein (24).

The trunks of the brachial plexus (29) can be felt as a cord-like structure in the lower part of the posterior triangle.

1 Accessory nerve emerging from sternocleidomastoid
2 Accessory nerve passing under anterior border of trapezius
3 Angle of mandible
4 Anterior border of masseter and facial artery
5 Anterior jugular vein
6 Arch of cricoid cartilage
7 Body of hyoid bone
8 Clavicle
9 Clavicular head of sternocleidomastoid
10 Deltoid
11 External jugular vein
12 Hypoglossal nerve
13 Inferior belly of omohyoid
14 Infraclavicular fossa and cephalic vein
15 Internal laryngeal nerve
16 Isthmus of thyroid gland
17 Jugular notch and trachea
18 Laryngeal prominence (Adam's apple)
19 Lowest part of parotid gland
20 Mastoid process
21 Pectoralis major
22 Site for palpation of common carotid artery
23 Sternal head of sternocleidomastoid
24 Sternoclavicular joint and union of internal jugular and subclavian veins to form brachiocephalic vein
25 Sternocleidomastoid
26 Submandibular gland
27 Tip of greater horn of hyoid bone
28 Tip of transverse process of atlas
29 Upper trunk of brachial plexus
30 Vocal cord position

Torticollis, varicella-zoster virus infection, see pages 80–82.

Side of the neck *right side, deep dissection*

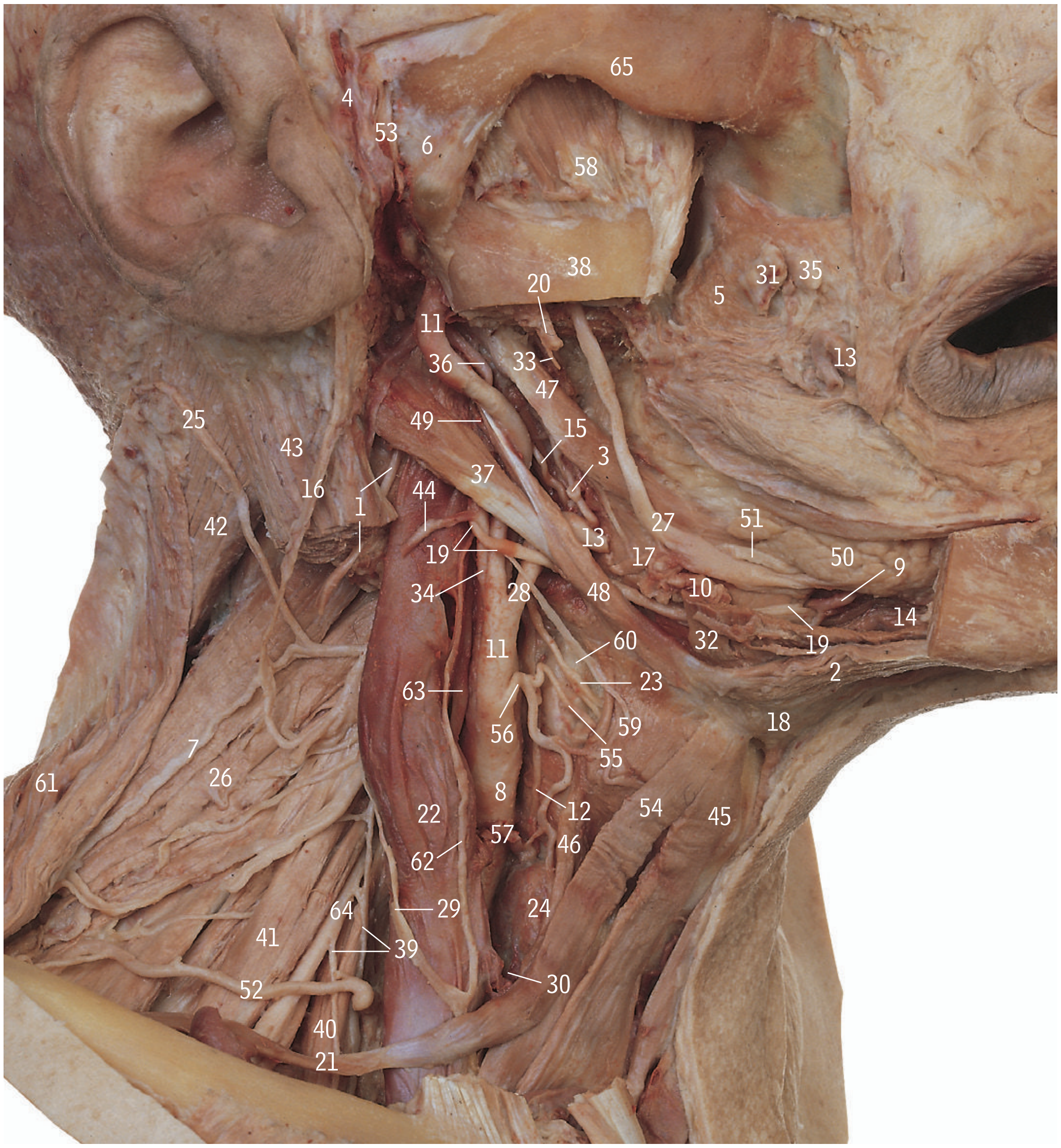

The lingual nerve (27) lies superficial to hyoglossus (17) and at this level is a flattened band rather than a typical round nerve, with the deep part of the submandibular gland (10) below it. The nerve crosses underneath the submandibular duct (51), lying first lateral to the duct and then medial to it.

The thyrohyoid membrane (60) is pierced by the internal laryngeal nerve (23) and the superior laryngeal artery (55).

Apart from supplying muscles of the tongue, the hypoglossal nerve (19) gives branches to geniohyoid (14) and thyrohyoid (59) and forms the upper root of the ansa cervicalis (62). These three branches consist of the fibres from the first cervical nerve that have joined the hypoglossal nerve higher in the neck; they are not derived from the hypoglossal nucleus. The C1 fibres in the upper root of the ansa contribute to the supply of sternohyoid (45) and omohyoid (21, 54).

1 Accessory nerve
2 Anterior belly of digastric and nerve
3 Ascending palatine artery
4 Auriculotemporal nerve
5 Buccinator
6 Capsule of temporomandibular joint
7 Cervical nerves to trapezius
8 Common carotid artery
9 Deep lingual artery
10 Deep part of submandibular gland
11 External carotid artery
12 External laryngeal nerve
13 Facial artery
14 Geniohyoid
15 Glossopharyngeal nerve
16 Great auricular nerve
17 Hyoglossus
18 Hyoid bone
19 Hypoglossal nerve
20 Inferior alveolar nerve
21 Inferior belly of omohyoid
22 Internal jugular vein
23 Internal laryngeal nerve
24 Lateral lobe of thyroid gland
25 Lesser occipital nerve
26 Levator scapulae
27 Lingual nerve
28 Linguofacial trunk
29 Lower root of ansa cervicalis
30 Middle thyroid vein
31 Molar salivary glands
32 Mylohyoid and nerve
33 Nerve to mylohyoid
34 Occipital artery
35 Parotid duct
36 Posterior auricular artery
37 Posterior belly of digastric
38 Ramus of mandible
39 Roots of phrenic nerve
40 Scalenus anterior
41 Scalenus medius
42 Splenius capitis
43 Sternocleidomastoid (cut)
44 Sternocleidomastoid branch of occipital artery
45 Sternohyoid
46 Sternothyroid
47 Styloglossus
48 Stylohyoid
49 Stylohyoid ligament
50 Sublingual gland
51 Submandibular duct
52 Superficial (transverse) cervical artery
53 Superficial temporal artery
54 Superior belly of omohyoid
55 Superior laryngeal artery
56 Superior thyroid artery
57 Superior thyroid vein
58 Temporalis
59 Thyrohyoid and nerve
60 Thyrohyoid membrane
61 Trapezius
62 Upper root of ansa cervicalis
63 Vagus nerve
64 Ventral ramus of fifth cervical nerve
65 Zygomatic arch

Front of the neck *deeper dissection*

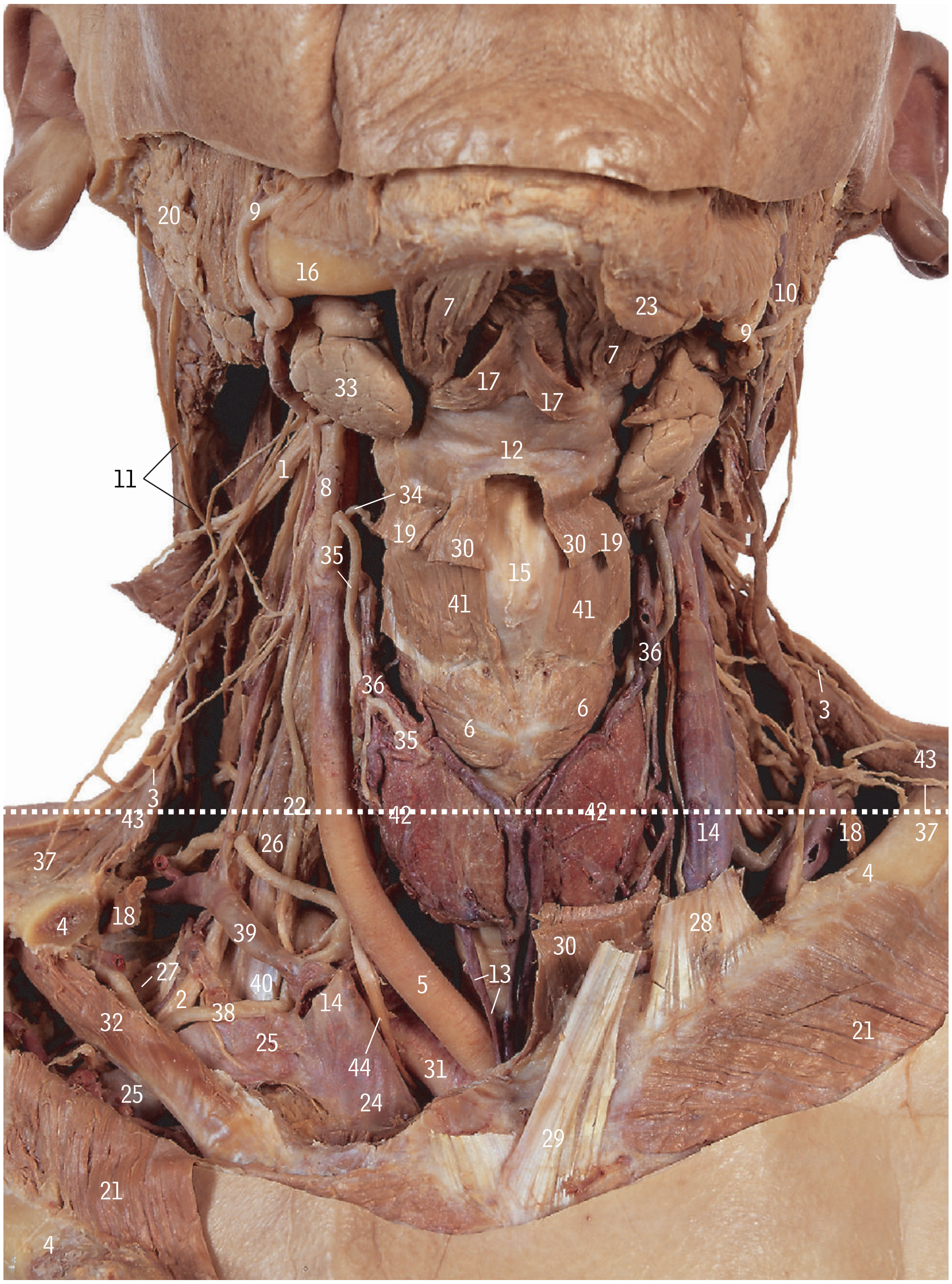

1 Accessory nerve
2 Brachial plexus (roots)
3 Cervical nerves to trapezius
4 Clavicle
5 Common carotid artery
6 Cricothyroid
7 Digastric, anterior belly
8 External carotid artery
9 Facial artery
10 Facial vein
11 Great auricular nerve
12 Hyoid bone, body
13 Inferior thyroid vein
14 Internal jugular vein
15 Laryngeal prominence
16 Mandible
17 Mylohyoid, anomalous fibres
18 Omohyoid, inferior belly
19 Omohyoid, superior belly
20 Parotid gland
21 Pectoralis major
22 Phrenic nerve
23 Platysma
24 Right brachiocephalic vein
25 Right subclavian vein
26 Scalenus anterior
27 Scalenus medius
28 Sternocleidomastoid, clavicular head
29 Sternocleidomastoid, sternal head
30 Sternohyoid
31 Subclavian artery
32 Subclavius
33 Submandibular gland
34 Superior laryngeal artery
35 Superior thyroid artery
36 Superior thyroid vein
37 Supraclavicular nerve
38 Suprascapular artery
39 Suprascapular vein
40 Tendon of scalenus anterior
41 Thyrohyoid
42 Thyroid gland, lateral lobe
43 Trapezius
44 Vagus nerve

On the right hand side, the clavicle (4) has been cut and removed to reveal the underlying subclavius (32). Dotted line is the level of axial CT (shown on the right).

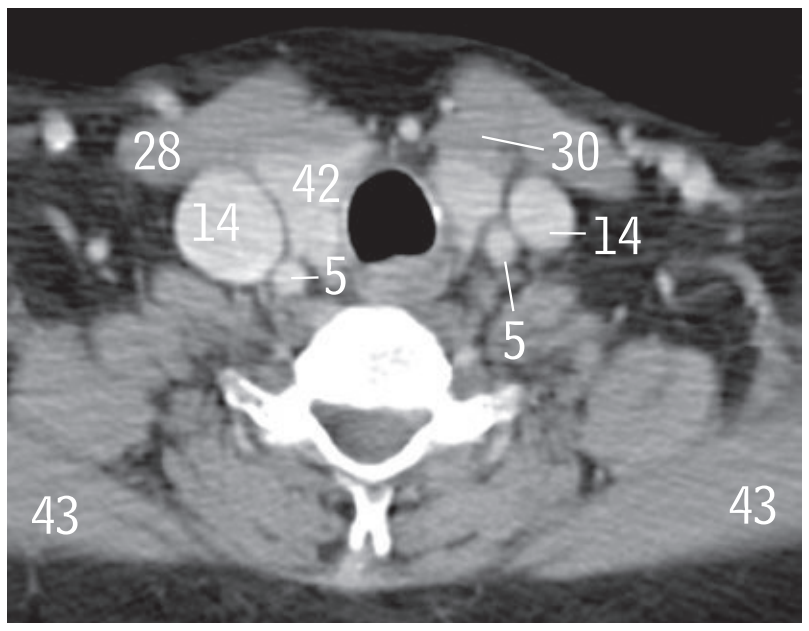

Accessory nerve palsy, goitre, sialectasis, submandibular tumour, see pages 80–82.

Right side of the neck

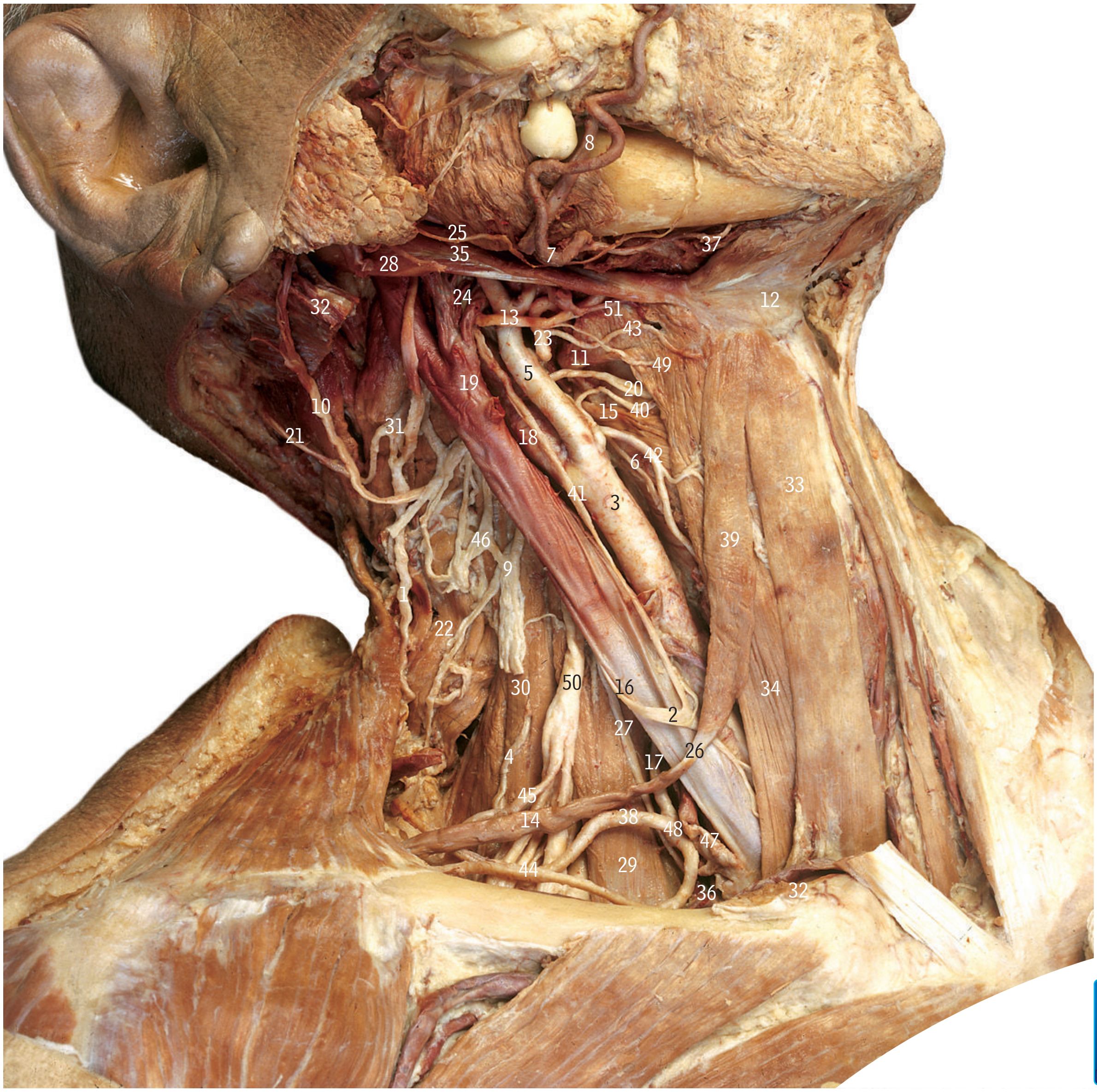

1 Accessory nerve
2 Ansa cervicalis
3 Common carotid artery
4 Dorsal scapular nerve
5 External carotid artery
6 External laryngeal nerve
7 Facial artery
8 Facial vein
9 Fourth cervical nerve ventral rami
10 Great auricular nerve
11 Greater horn of hyoid bone
12 Hyoid bone
13 Hypoglossal nerve
14 Inferior belly of omohyoid
15 Inferior constrictor of pharynx
16 Inferior root of ansa cervicalis
17 Inferior thyroid artery
18 Internal carotid artery
19 Internal jugular vein (double at upper end)
20 Internal laryngeal nerve penetrating thyrohyoid membrane
21 Lesser occipital nerve
22 Levator scapulae
23 Lingual artery
24 Lingual vein
25 Marginal mandibular branch of facial nerve
26 Omohyoid tendon
27 Phrenic nerve
28 Posterior belly of digastric
29 Scalenus anterior
30 Scalenus medius
31 Second cervical nerve ventral rami
32 Sternocleidomastoid (cut)
33 Sternohyoid
34 Sternothyroid
35 Stylohyoid
36 Subclavian vein
37 Submental artery
38 Transverse cervical artery (superficial)
39 Superior belly of omohyoid
40 Superior laryngeal artery
41 Superior root of ansa cervicalis
42 Superior thyroid artery
43 Suprahyoid artery on hyoglossus
44 Suprascapular artery
45 Suprascapular nerve
46 Third cervical nerve ventral rami
47 The right lymphatic duct termination
48 Thyrocervical trunk
49 Thyrohyoid muscle and nerve to thyrohyoid
50 Upper trunk of brachial plexus
51 Vena comitans of hypoglossal nerve

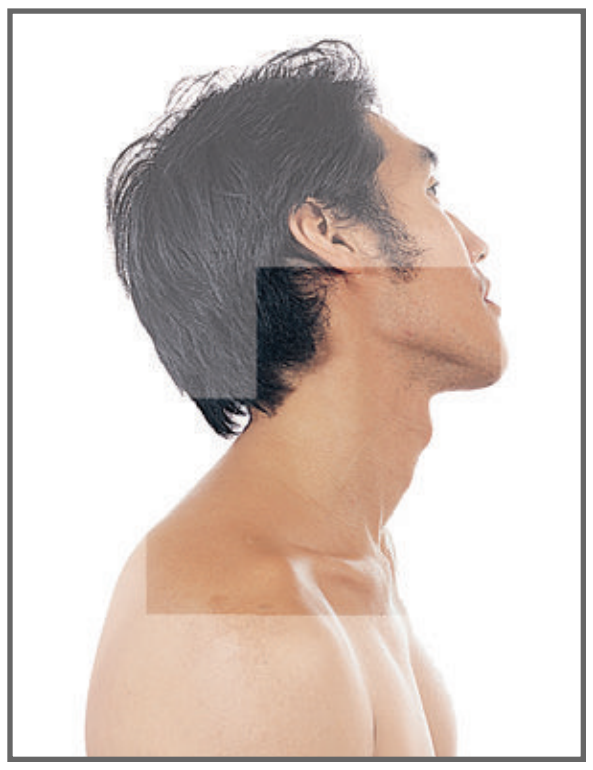

Branchial cysts, carotid artery stenosis, see pages 80–82.

Left side of the neck *from the left and front*

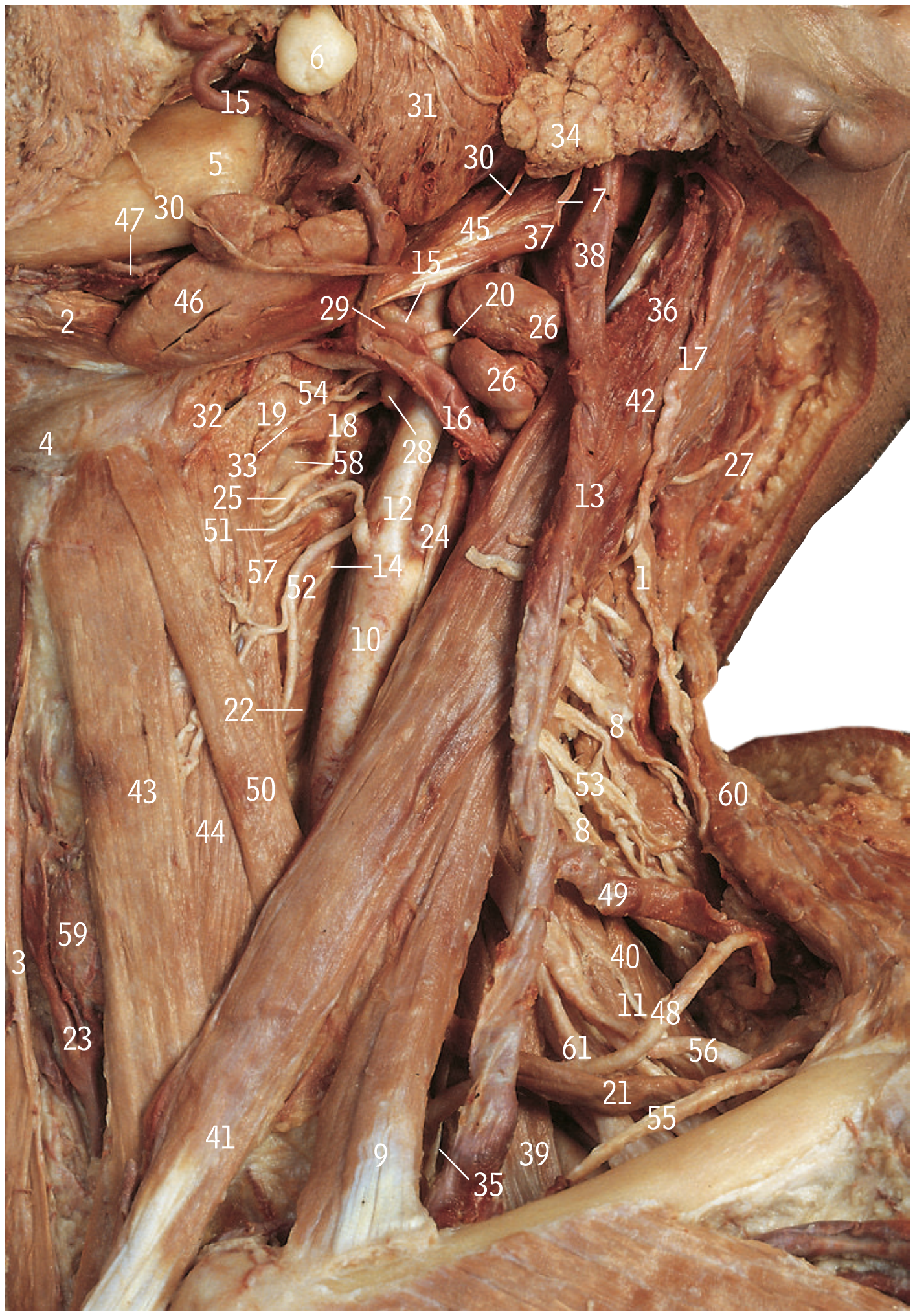

Platysma and the deep cervical fascia have been removed.

In 20% of faces, as in this specimen, the marginal mandibular branch of the facial nerve (30) arches downwards off the face for part of its course and overlies the submandibular gland (46).

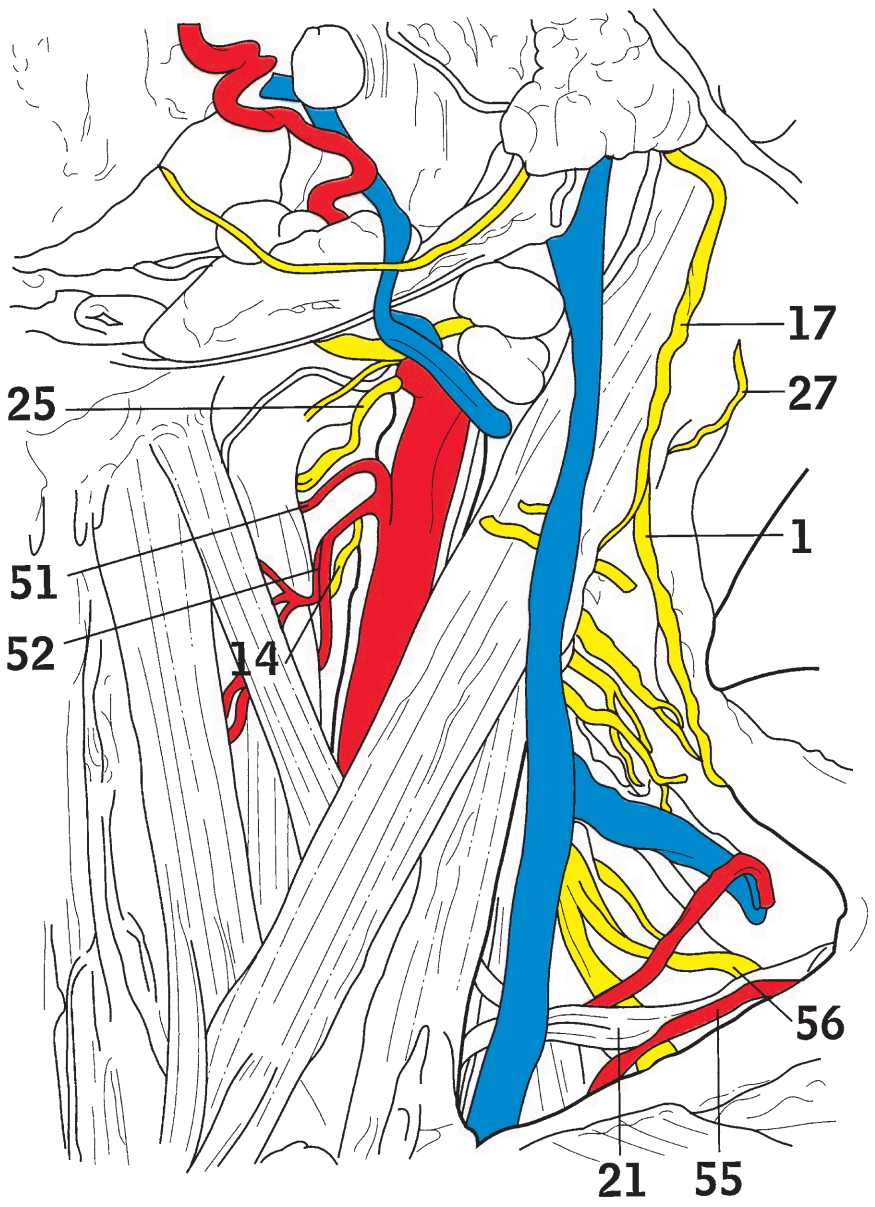

1 Accessory nerve
2 Anterior belly of digastric
3 Anterior jugular vein
4 Body of hyoid bone
5 Body of mandible
6 Buccal fat pad
7 Cervical branch of facial nerve
8 Cervical nerves to trapezius
9 Clavicular head of sternocleidomastoid
10 Common carotid artery
11 Dorsal scapular nerve
12 External carotid artery
13 External jugular vein
14 External laryngeal nerve
15 Facial artery
16 Facial vein
17 Great auricular nerve
18 Greater horn of hyoid bone (underlying 25)
19 Hyoglossus
20 Hypoglossal nerve
21 Inferior belly of omohyoid
22 Inferior constrictor of pharynx
23 Inferior thyroid vein
24 Internal carotid artery and superior root of ansa cervicalis
25 Internal laryngeal nerve
26 Jugulodigastric lymph nodes
27 Lesser occipital nerve
28 Lingual artery
29 Lingual vein
30 Marginal mandibular branch of facial nerve
31 Masseter
32 Mylohyoid
33 Nerve to thyrohyoid
34 Parotid gland
35 Phrenic nerve (on scalenus anterior)
36 Posterior auricular vein
37 Posterior belly of digastric
38 Posterior branch of retromandibular vein
39 Scalenus anterior
40 Scalenus medius
41 Sternal head of sternocleidomastoid
42 Sternocleidomastoid
43 Sternohyoid
44 Sternothyroid
45 Stylohyoid
46 Submandibular gland
47 Submental artery and vein
48 Superficial (transverse) cervical artery
49 Superficial (transverse) cervical vein
50 Superior belly of omohyoid
51 Superior laryngeal artery
52 Superior thyroid artery
53 Supraclavicular nerve (cut upper edge)
54 Suprahyoid artery
55 Suprascapular artery
56 Suprascapular nerve
57 Thyrohyoid
58 Thyrohyoid membrane
59 Thyroid gland (left lobe)
60 Trapezius
61 Upper trunk of brachial plexus

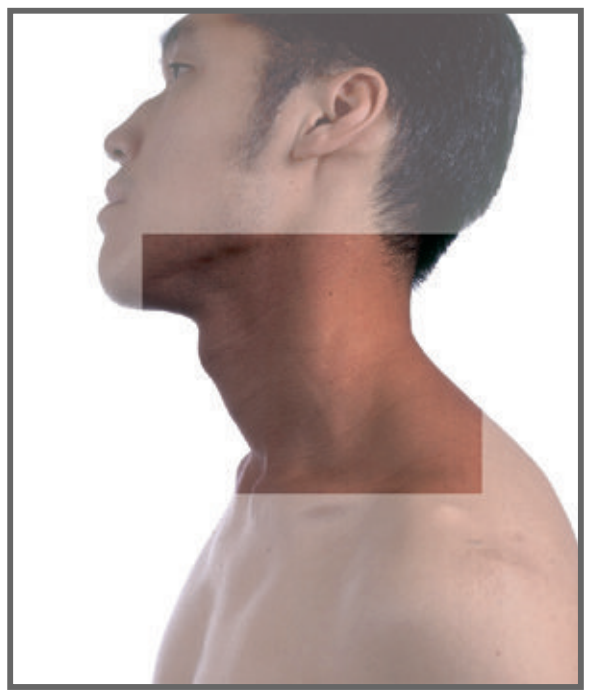

Carotid artery bruits, carotid artery variants, cervical lymph node enlargement, see pages 80–82.

Right lower face and upper neck

A parotid and upper cervical regions

B submandibular region

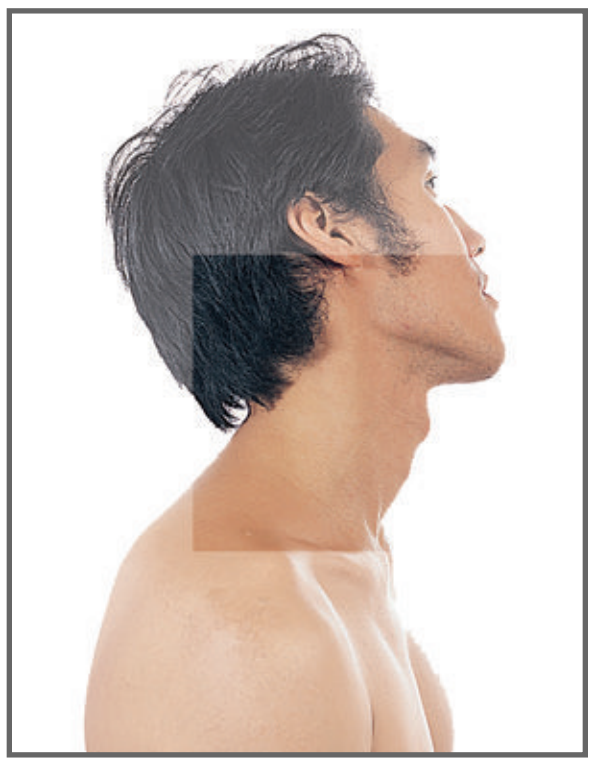

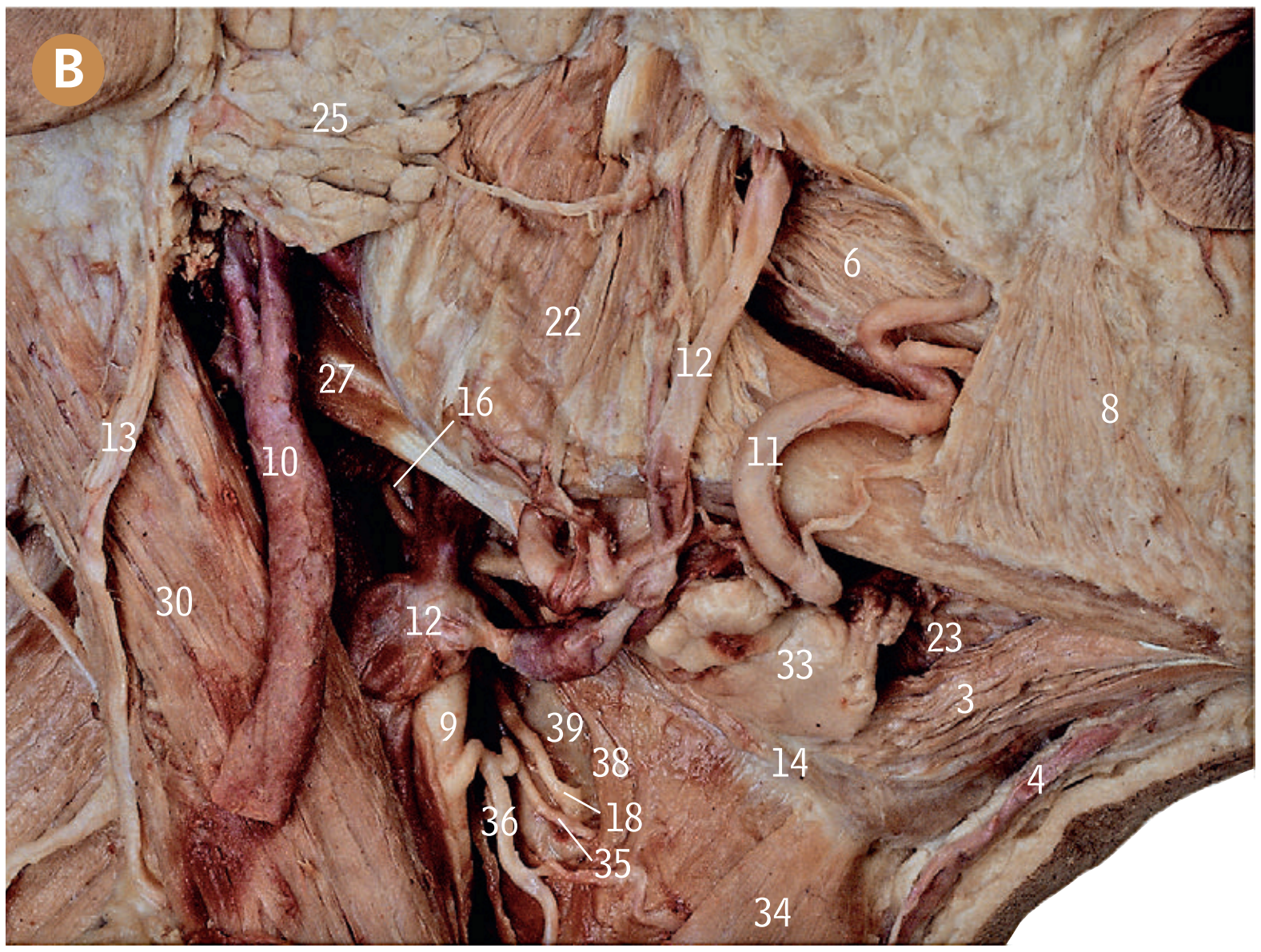

1 Ansa cervicalis, inferior branch
2 Ansa cervicalis, superior branch
3 Anterior belly of digastric
4 Anterior jugular vein
5 Brachial plexus (roots)
6 Buccinator
7 Common carotid artery
8 Depressor anguli oris
9 External carotid artery
10 External jugular vein
11 Facial artery
12 Facial vein
13 Great auricular nerve
14 Greater horn of hyoid bone
15 Hyoid bone
16 Hypoglossal nerve
17 Internal jugular vein
18 Internal laryngeal nerve
19 Lesser occipital nerve
20 Levator scapulae
21 Mandible
22 Masseter
23 Mylohyoid
24 Oblique line of the thyroid cartilage
25 Parotid gland and facial nerve branches at anterior border
26 Platysma
27 Posterior belly of digastric
28 Retromandibular vein
29 Scalenus anterior
30 Sternocleidomastoid
31 Sternohyoid
32 Sternothyroid
33 Submandibular gland
34 Superior belly of omohyoid (bifid-variation)
35 Superior laryngeal artery
36 Superior thyroid artery
37 Suprascapular artery
38 Thyrohyoid
39 Thyrohyoid membrane
40 Thyroid gland (right lobe)
41 Trapezius

Mumps, parotidectomy (removal of parotid gland), parotid tumours, see pages 80–82.

Left lower face and upper neck

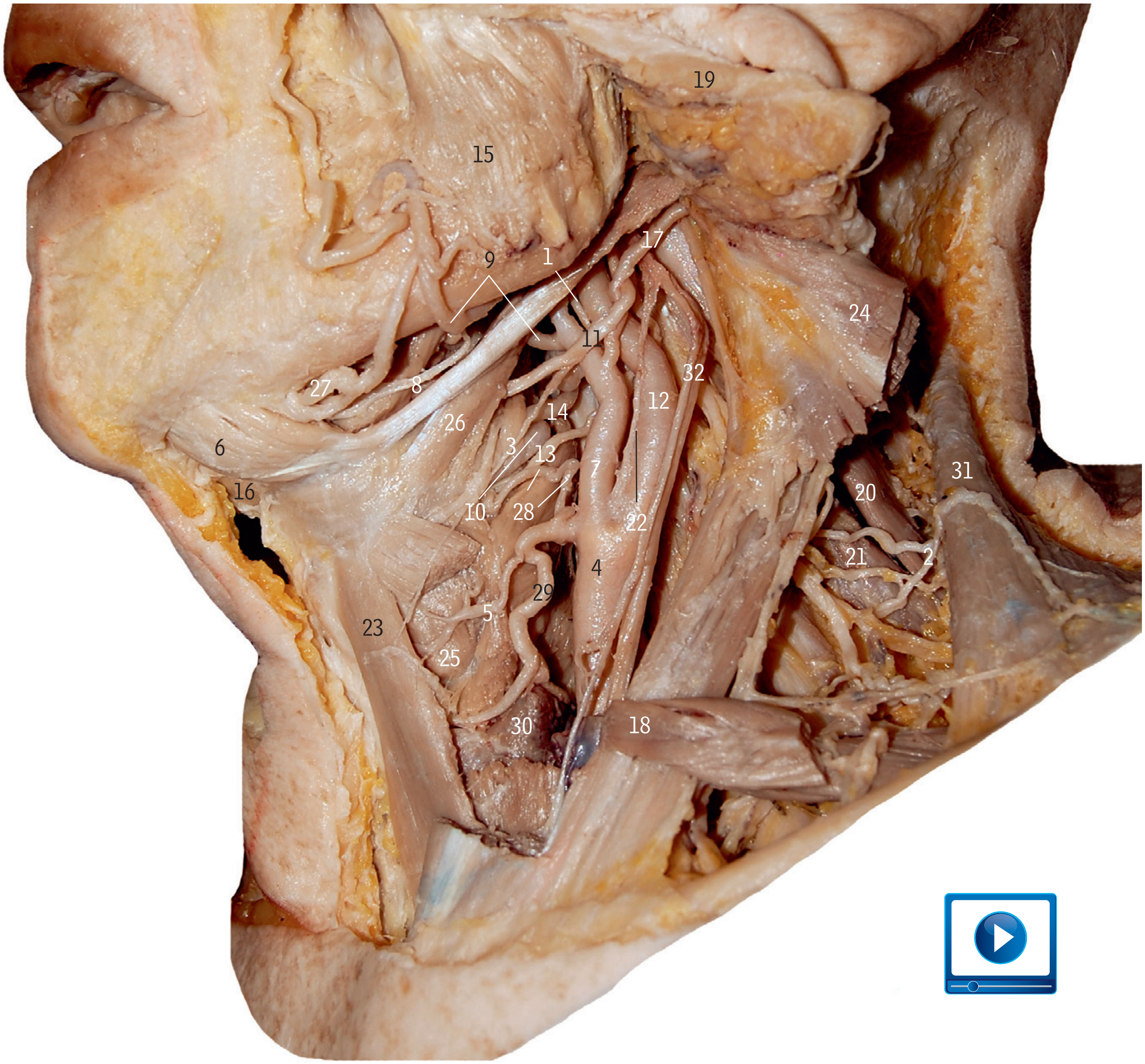

1 Ascending pharyngeal artery
2 Branches of cervical plexus
3 C1 (descendens hypoglossi)
4 Common carotid artery
5 Cricothyroid artery
6 Digastric muscle (anterior belly)
7 External carotid artery
8 Facial nerve, marginal branch
9 Facial artery
10 Greater horn of the hyoid bone
11 Hypoglossal nerve
12 Internal carotid artery
13 Internal laryngeal nerve
14 Lingual artery
15 Masseter muscle
16 Mylohyoid muscle
17 Occipital artery
18 Omohyoid muscle (reflected)
19 Parotid gland (reflected)
20 Scalenus posterior muscle
21 Scalenus medius muscle
22 Sinus nerve to carotid sinus and body
23 Sternohyoid muscle
24 Sternocleidomastoid muscle (reflected)
25 Sternothyroid muscle (cut)
26 Stylohyoid muscle
27 Submental artery
28 Superior laryngeal artery
29 Superior thyroid artery
30 Thyroid gland (lateral lobe)
31 Trapezius muscle
32 Vagus nerve

Carotid endarterectomy, see pages 80–82.

Right side of the neck *deep dissection*

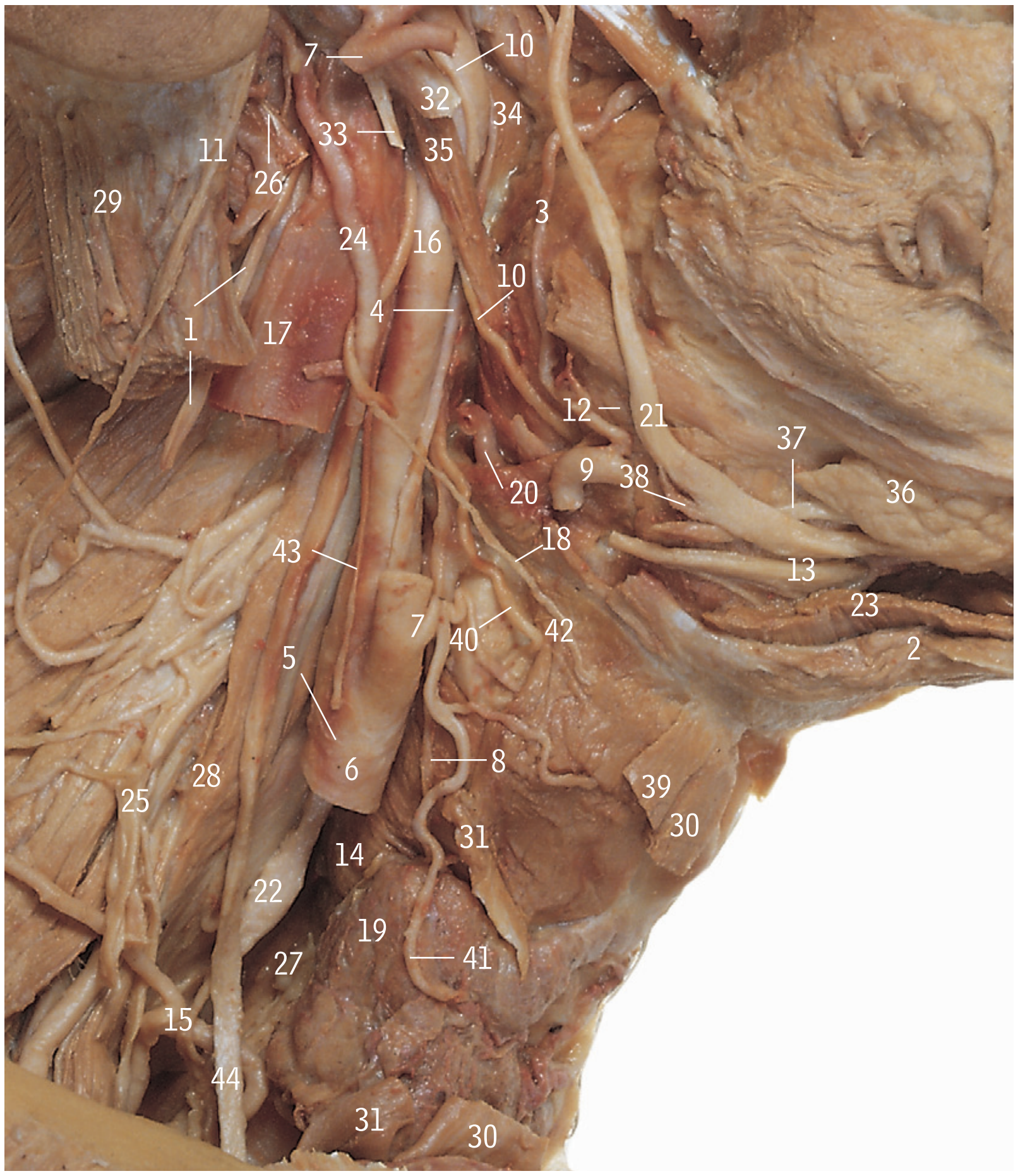

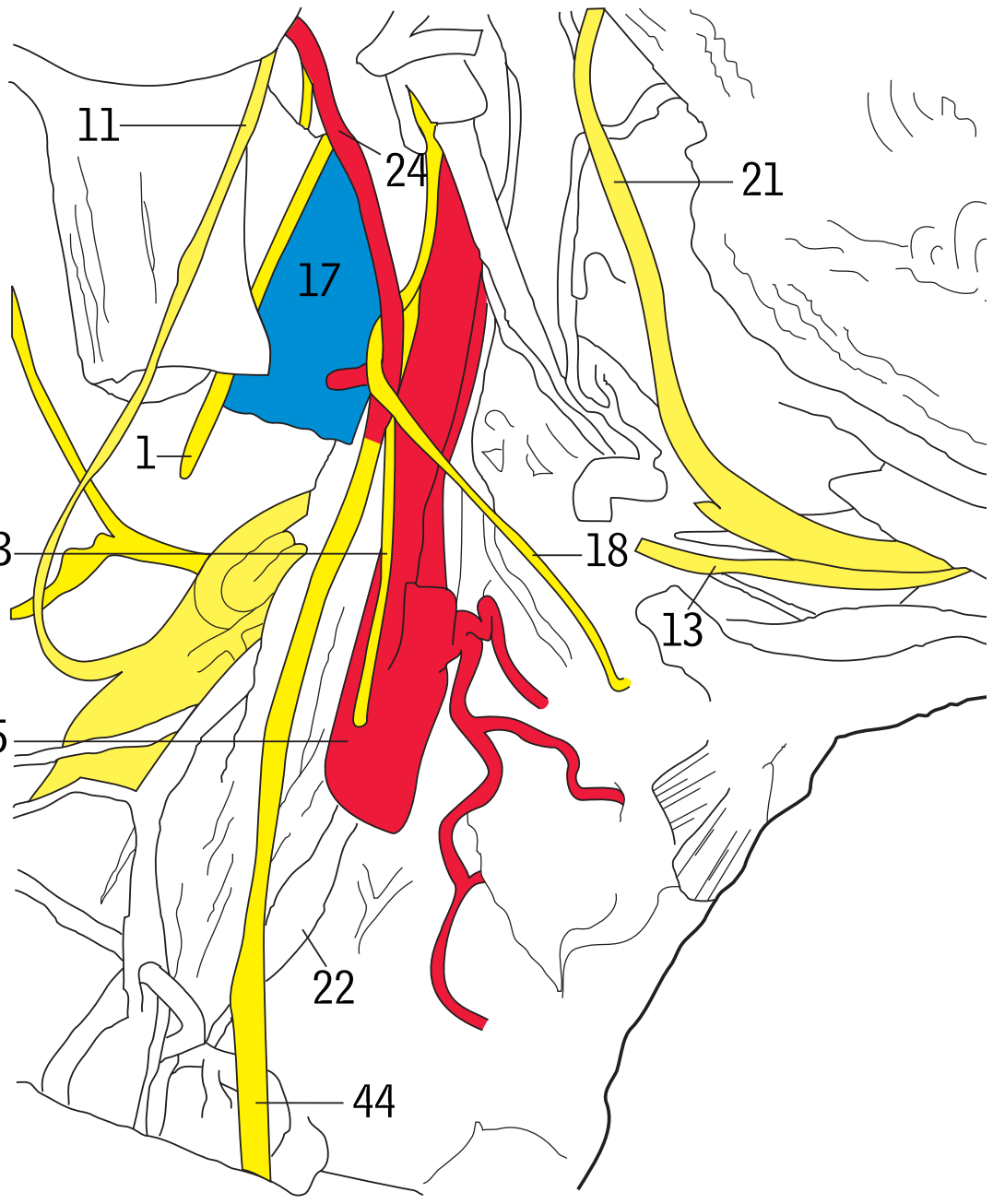

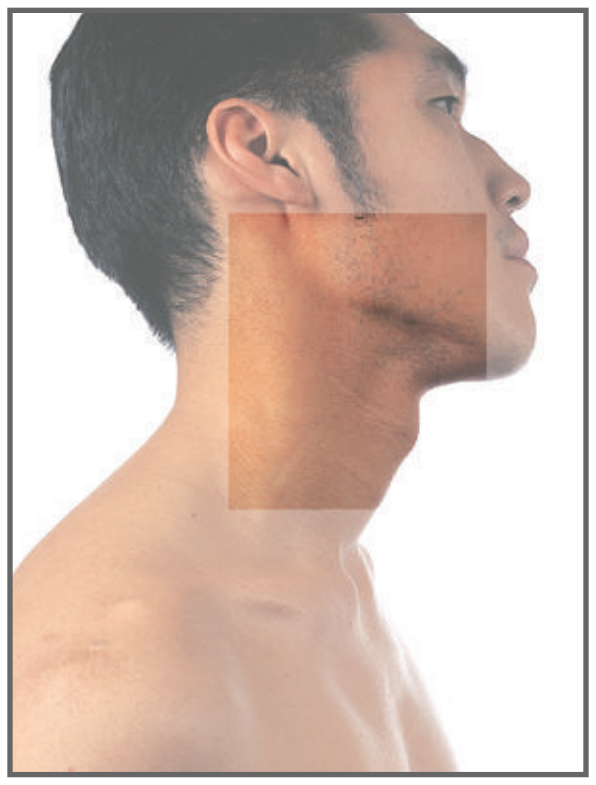

1 Accessory nerve (cut)
2 Anterior belly of digastric
3 Ascending palatine artery
4 Ascending pharyngeal artery
5 Carotid sinus
6 Common carotid artery
7 External carotid artery
8 External laryngeal nerve
9 Facial artery
10 Glossopharyngeal nerve
11 Great auricular nerve
12 Hyoglossus
13 Hypoglossal nerve (cut)
14 Inferior constrictor
15 Inferior thyroid artery
16 Internal carotid artery
17 Internal jugular vein
18 Internal laryngeal nerve
19 Lateral lobe of thyroid gland
20 Lingual artery
21 Lingual nerve
22 Middle cervical sympathetic ganglion
23 Mylohyoid
24 Occipital artery
25 Phrenic nerve
26 Posterior belly of digastric (cut)
27 Recurrent laryngeal nerve
28 Scalenus anterior
29 Sternocleidomastoid
30 Sternohyoid
31 Sternothyroid
32 Styloglossus
33 Stylohyoid (cut end displaced medially)
34 Stylohyoid ligament
35 Stylopharyngeus
36 Sublingual gland
37 Submandibular duct
38 Submandibular ganglion
39 Superior belly of omohyoid
40 Superior laryngeal artery
41 Superior thyroid artery
42 Thyrohyoid and nerve
43 Upper root of ansa cervicalis
44 Vagus nerve

The hypoglossal nerve (13) passes downwards, curling around the occipital artery (24) and lying superficial to the external carotid (7) and lingual (20) arteries.

The glossopharyngeal nerve (10) passes downwards and forwards, curling round the lateral side of stylopharyngeus (35).

The removal of parts of the sternohyoid (30), omohyoid (39) and sternothyroid (31) displays the lateral lobe of the thyroid gland (19). Note the inferior thyroid artery (15) behind the lower part of the lobe, with the recurrent laryngeal nerve (27) passing deep to this looping vessel to enter the pharynx beneath the inferior constrictor (14).

Prevertebral region

1 Accossory nerve (spinal root)
2 Anterior longitudinal ligament
3 Ascending cervical artery and vein
4 Ascending pharyngeal artery
5 Brachiocephalic artery
6 Dorsal scapular artery
7 Glossopharyngeal nerve
8 Inferior cervical ganglion
9 Inferior thyroid artery
10 Inferior vagal ganglion
11 Internal carotid artery
12 Internal carotid nerve
13 Internal jugular vein, upper end
14 Internal jugular vein, lower end
15 Internal thoracic artery
16 Jugular lymphatic trunk
17 Left brachiocephalic vein
18 Left common carotid artery
19 Left subclavian artery
20 Levator scapulae
21 Longus capitis
22 Longus colli
23 Mastoid process
24 Mediastinal lymphatic trunk
25 Meningeal branch of ascending pharyngeal artery
26 Middle cervical ganglion
27 Occipital artery
28 Oesophageal branch of inferior thyroid artery
29 Oesophagus
30 Phrenic nerve
31 Posterior belly of digastric
32 Rectus capitis lateralis
33 Recurrent laryngeal nerve
34 Right brachiocephalic vein
35 Right common carotid artery
36 Right lymphatic duct
37 Right subclavian artery
38 Scalenus anterior
39 Scalenus medius
40 Spine of sphenoid bone
41 Sternocleidomastoid
42 Subclavian vein
43 Superficial cervical artery
44 Superior cervical ganglion
45 Suprascapular artery
46 Sympathetic trunk
47 Thoracic duct
48 Thyrocervical trunk
49 Trachea
50 Transverse process of atlas
51 Tympanic part of temporal bone
52 Upper trunk of brachial plexus
53 Vagus nerve, on left
54 Vagus nerve, on right
55 Ventral ramus of third cervical nerve
56 Vertebral artery
57 Vertebral vein

Horner's syndrome, see pages 80–82.

Root of the neck

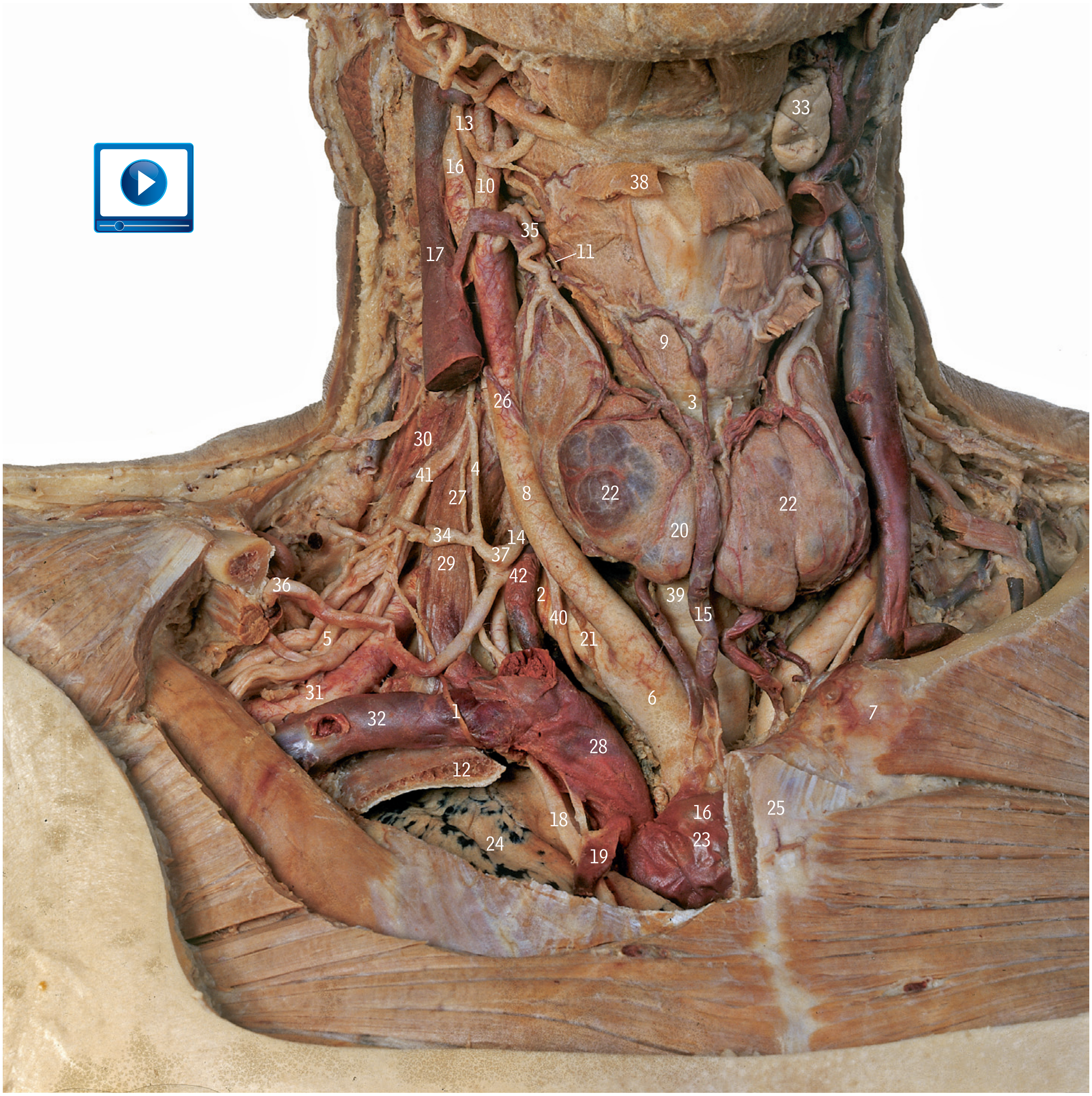

1 Accessory phrenic nerve
2 Ansa subclavia
3 Arch of cricoid cartilage
4 Ascending cervical artery
5 Brachial plexus
6 Brachiocephalic artery
7 Capsule of sternoclavicular joint
8 Common carotid artery
9 Cricothyroid muscle
10 External carotid artery
11 External laryngeal nerve
12 First rib (sectioned)
13 Hypoglossal nerve
14 Inferior thyroid artery
15 Inferior thyroid veins
16 Internal carotid artery
17 Internal jugular vein
18 Internal thoracic artery
19 Internal thoracic vein
20 Isthmus of thyroid gland
21 Jugular lymphatic trunk
22 Lateral lobe of thyroid gland
23 Left brachiocephalic vein
24 Lung apex
25 Manubrium of sternum
26 Middle thyroid vein
27 Phrenic nerve
28 Right brachiocephalic vein
29 Scalenus anterior
30 Scalenus medius
31 Subclavian artery
32 Subclavian vein
33 Submandibular gland
34 Superficial (transverse) cervical artery
35 Superior thyroid artery and vein
36 Suprascapular artery
37 Thyrocervical trunk
38 Sternohyoid
39 Trachea
40 Vagus nerve
41 Ventral ramus of fifth cervical nerve
42 Vertebral vein

Internal jugular vein catheterisation, subclavian vein catheterisation, see pages 80–82.

Face *surface markings on the front and right side*

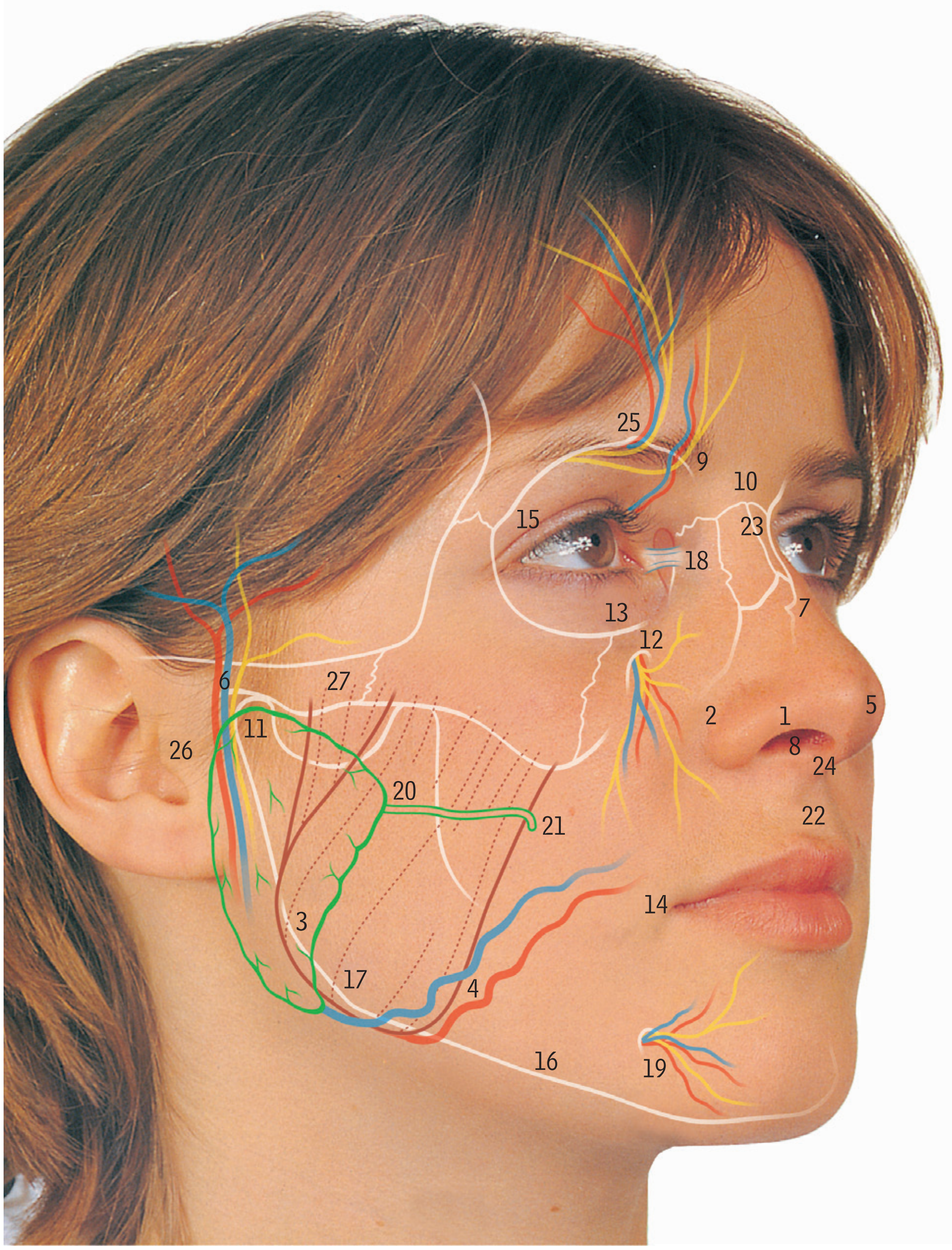

1 Ala
2 Alar groove (nasolabial groove)
3 Angle of mandible
4 Anterior border of masseter and facial vessels
5 Apex of external nose
6 Auriculotemporal nerve and superficial temporal vessels
7 Dorsum of nose
8 External aperture (anterior naris)
9 Frontal notch and supratrochlear nerve and vessels
10 Glabella of nose
11 Head of mandible
12 Infra-orbital foramen, nerve and vessels
13 Infra-orbital margin
14 Lateral angle of mouth
15 Lateral part of supra-orbital margin
16 Lower border of body of mandible
17 Lower border of ramus of mandible
18 Medial palpebral ligament anterior to lacrimal sac
19 Mental foramen, nerve and vessels
20 Parotid duct emerging from gland
21 Parotid duct turning medially at anterior border of masseter
22 Philtrum
23 Root of nose
24 Septum of nose (nasal columella)
25 Supra-orbital notch (or foramen), nerve and vessels
26 Tragus
27 Zygomatic arch

The pulsation of the superficial temporal artery (6) is palpable in front of the tragus of the ear (26).

The parotid duct (20 and 21) lies under the middle-third of a line drawn from the tragus of the ear (26) to the midpoint of the philtrum (22).

The pulsation of the facial artery (4) is palpable where the vessel crosses the lower border of the mandible at the anterior margin of the masseter muscle, about 2.5 cm (1 in) in front of the angle of the mandible (3).

Ophthalmic herpes zoster, see pages 80–82.

Face *superficial dissection from the front and the right*

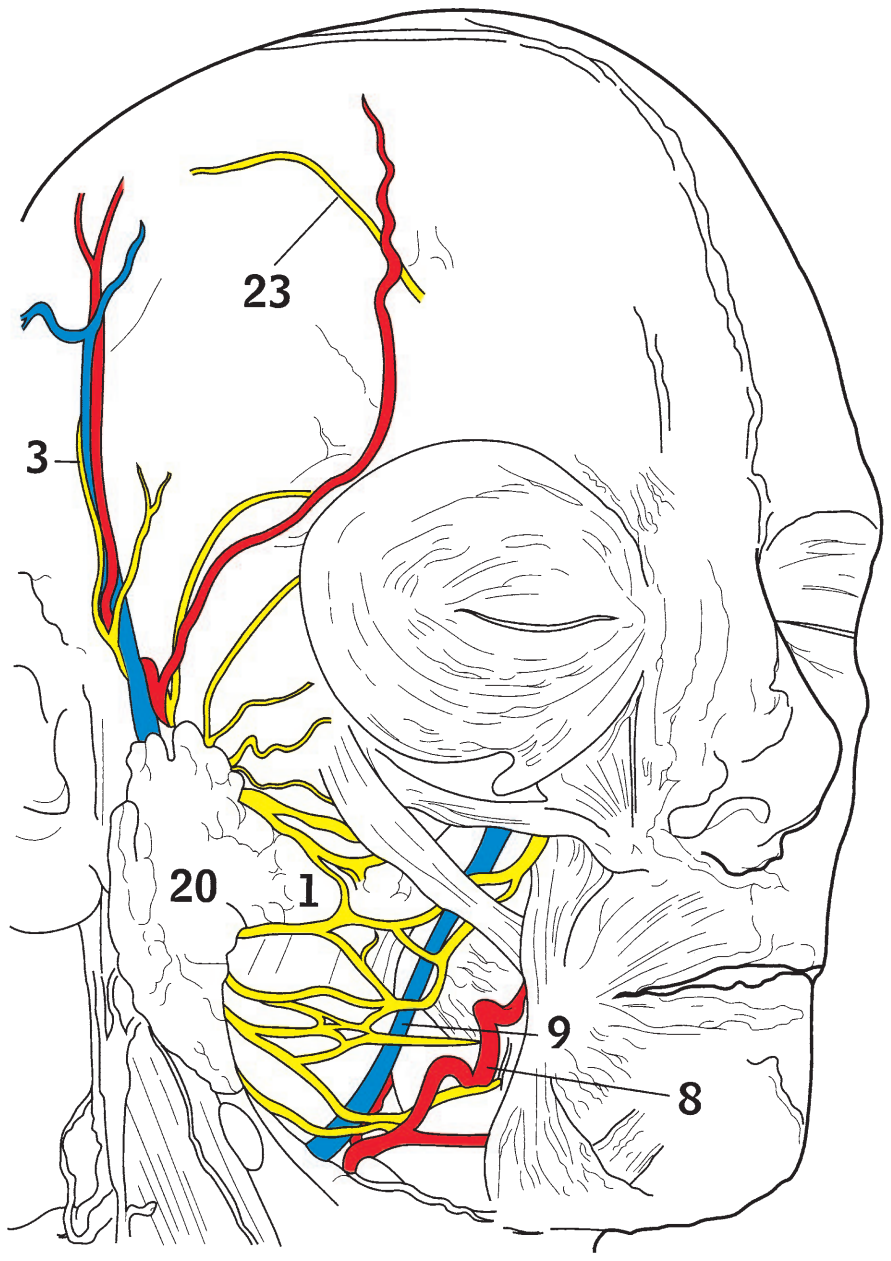

1. Accessory parotid gland overlying parotid duct
2. Anterior branch of superficial temporal artery
3. Auriculotemporal nerve and superficial temporal vessels
4. Body of mandible
5. Buccinator and buccal branches of facial nerve
6. Depressor anguli oris
7. Depressor labii inferioris
8. Facial artery
9. Facial vein
10. Frontalis part of occipitofrontalis
11. Great auricular nerve
12. Levator anguli oris
13. Levator labii superioris
14. Levator labii superioris alaeque nasi
15. Marginal mandibular branch of facial nerve
16. Masseter
17. Nasalis
18. Orbicularis oculi
19. Orbicularis oris
20. Parotid gland
21. Procerus
22. Sternocleidomastoid
23. Supra-orbital nerve
24. Supratrochlear nerve
25. Temporal branch of facial nerve
26. Temporalis underlying temporal fascia
27. Zygomatic branch of facial nerve
28. Zygomaticus major
29. Zygomaticus minor

Facial nerve palsy, intracranial spread of infection, surgical flaps of the scalp, see pages 80–82.

Face *superficial dissection from the right*

After removal of skin and some fat (A, B, C, D, E = temporal, zygomatic, buccal, mandibular and cervical branches of facial nerve, respectively).

1 Auriculotemporal nerve
2 Buccal fat pad
3 Buccal nerve (V3)
4 Buccinator
5 Capsule of temporomandibular joint
6 Depressor anguli oris
7 Facial artery
8 Facial nerve (A, B, C, D, E branches)
9 Facial vein
10 Great auricular nerve
11 Infra-orbital nerve
12 Mandible, body
13 Masseter
14 Mental nerve
15 Mentalis
16 Orbicularis oculi
17 Orbicularis oris
18 Parotid duct
19 Parotid gland
20 Platysma
21 Retromandibular vein
22 Risorius, overlying facial artery and vein
23 Submandibular gland
24 Superficial temporal vessels
25 Superior labial artery
26 Supraorbital nerve
27 Supratrochlear nerve
28 Temporal fascia
29 Temporal line, inferior
30 Temporal line, superior
31 Temporalis
32 Tragus
33 Transverse facial artery
34 Zygomatic arch
35 Zygomaticus major

Right temporal fossa

After removal of temporal fascia, parotid gland and most branches of the facial nerve. Dotted line indicates field of deeper dissections shown on next page.

Infratemporal fossa *progressively deeper dissections*

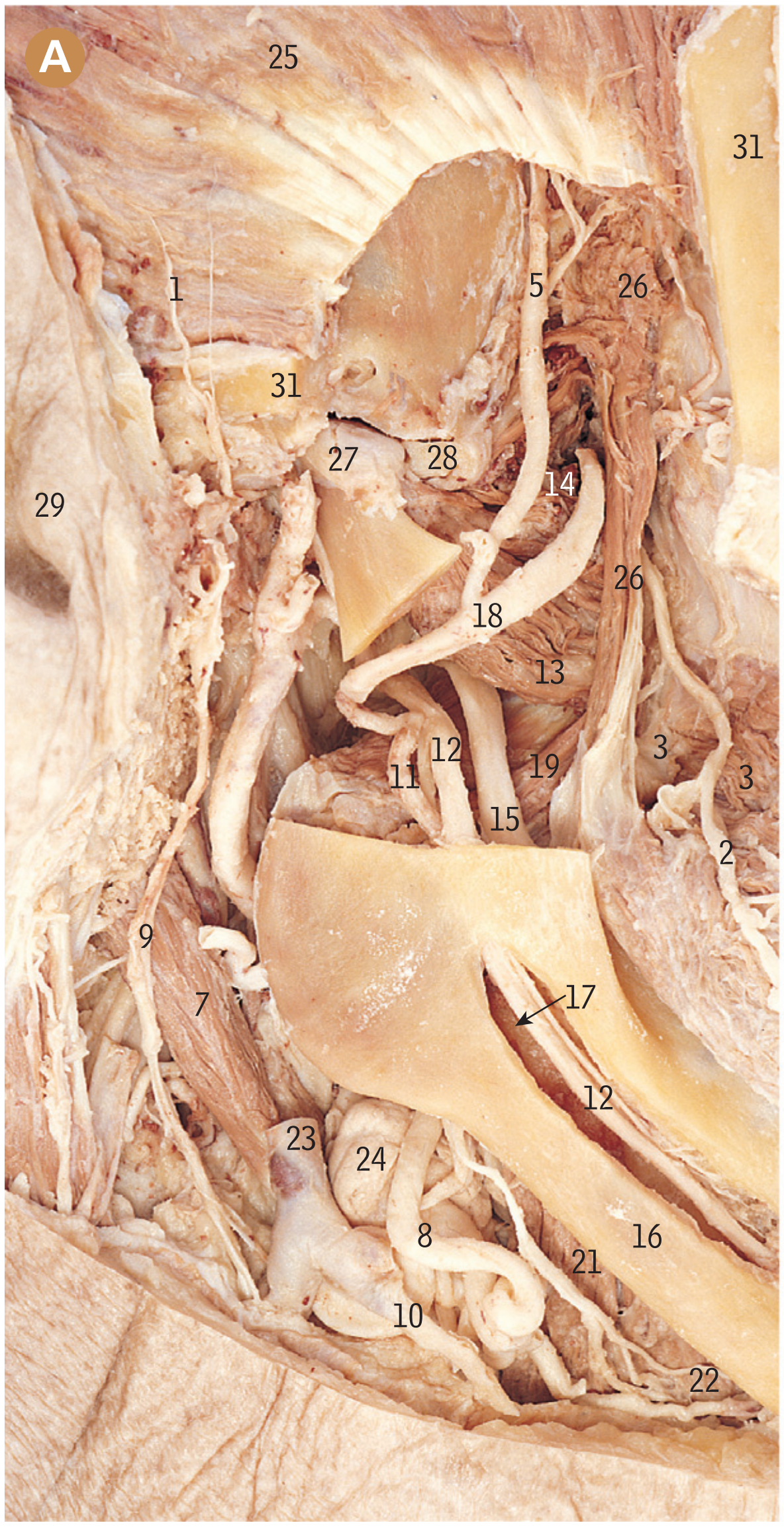

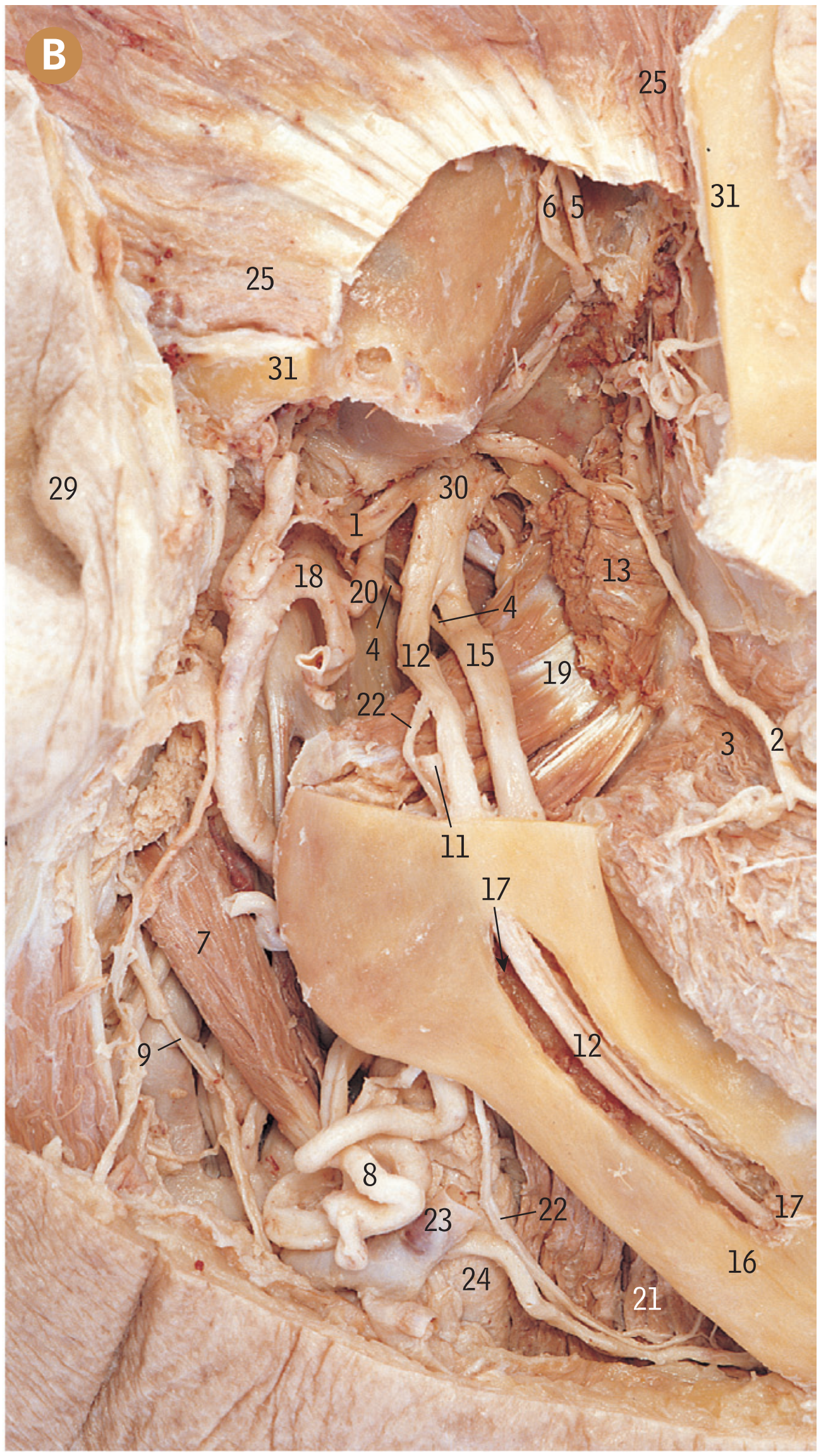

A **Removal of the masseter, part of the zygomatic arch, most of the superficial and inferior parts of temporalis, the superior half of the mandibular ramus (except the neck and condyle) and the pterygoid venous plexus reveals the superficial contents of the infratemporal fossa.**

B **Removal of the deep head of temporalis, the lateral pterygoid and the neck and condyle of the mandible exposes the deepest structures.**

1 Auriculotemporal nerve
2 Buccal nerve (V3)
3 Buccinator
4 Chorda tympani
5 Deep temporal artery
6 Deep temporal nerve
7 Digastric, posterior belly
8 Facial artery
9 Facial nerve, cervical branch
10 Facial vein
11 Inferior alveolar artery
12 Inferior alveolar nerve
13 Lateral pterygoid, inferior head
14 Lateral pterygoid, superior head
15 Lingual nerve
16 Mandible, body
17 Mandibular canal (opened)
18 Maxillary artery
19 Medial pterygoid
20 Middle meningeal artery
21 Mylohyoid
22 Nerve to mylohyoid
23 Retromandibular vein
24 Submandibular gland
25 Temporalis
26 Temporalis, deep head (sphenomandibularis)
27 Temporomandibular joint, capsule
28 Temporomandibular joint, disc
29 Tragus
30 Trigeminal nerve, mandibular division (V3)
31 Zygomatic arch

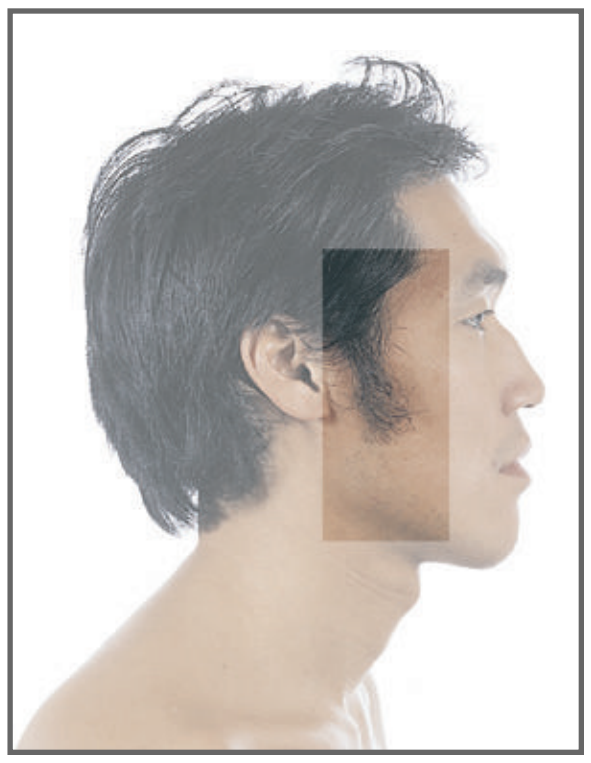

A Coronal section of cadaveric face *temporalis heads*

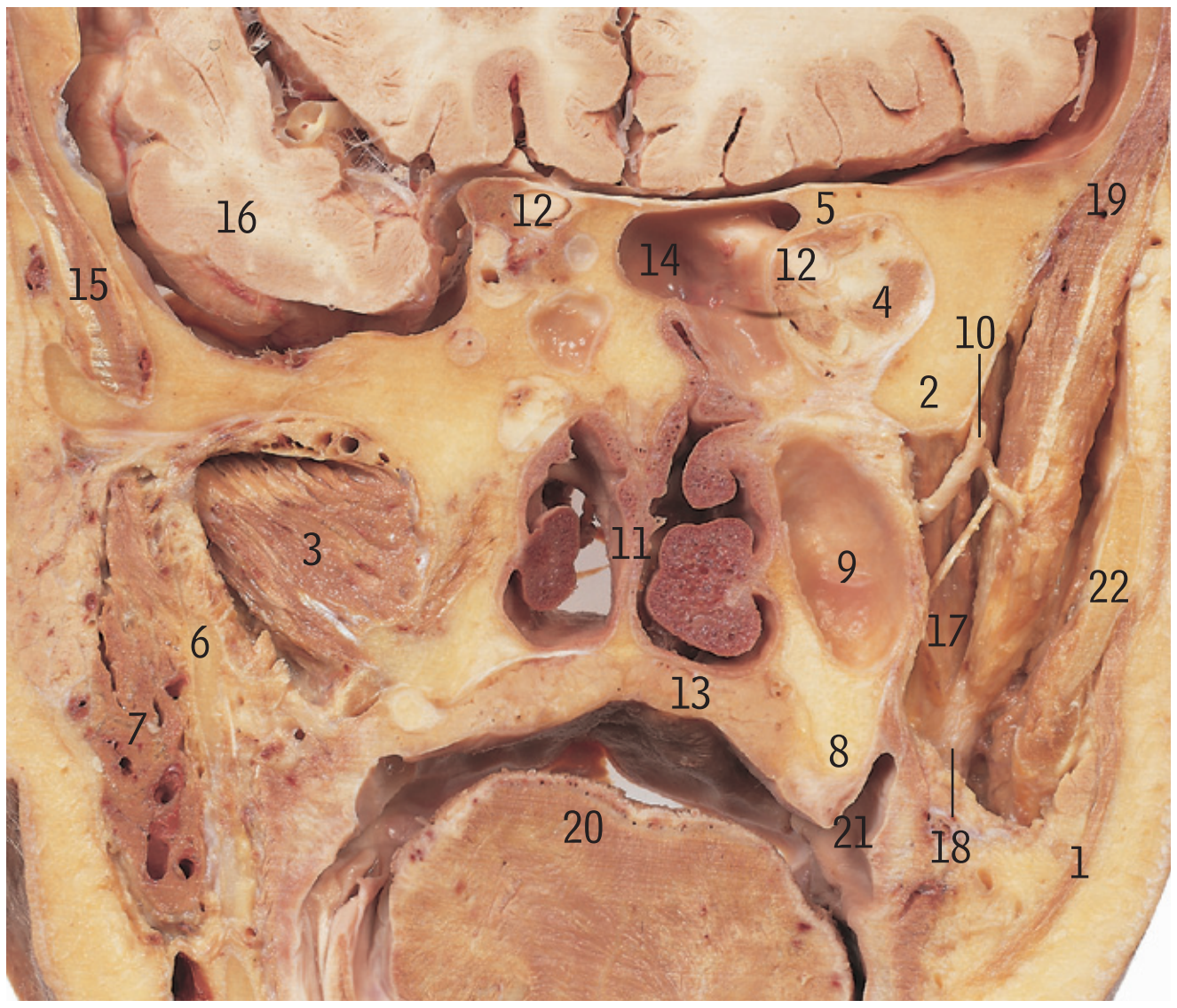

1 Buccinator
2 Greater wing of sphenoid
3 Lateral pterygoid
4 Lateral rectus
5 Lesser wing of sphenoid
6 Mandible
7 Masseter
8 Maxilla
9 Maxillary air (paranasal) sinus
10 Maxillary artery, muscular branches
11 Nasal septum
12 Optic nerve
13 Palate
14 Sphenoidal sinus
15 Temporal bone
16 Temporal lobe, brain
17 Temporalis, deep head (sphenomandibularis – Zenker 1955)
18 Temporalis, insertion
19 Temporalis, superficial head
20 Tongue
21 Vestibule of oral cavity
22 Zygoma

C Endoscopic view of nasal septum (choanae)

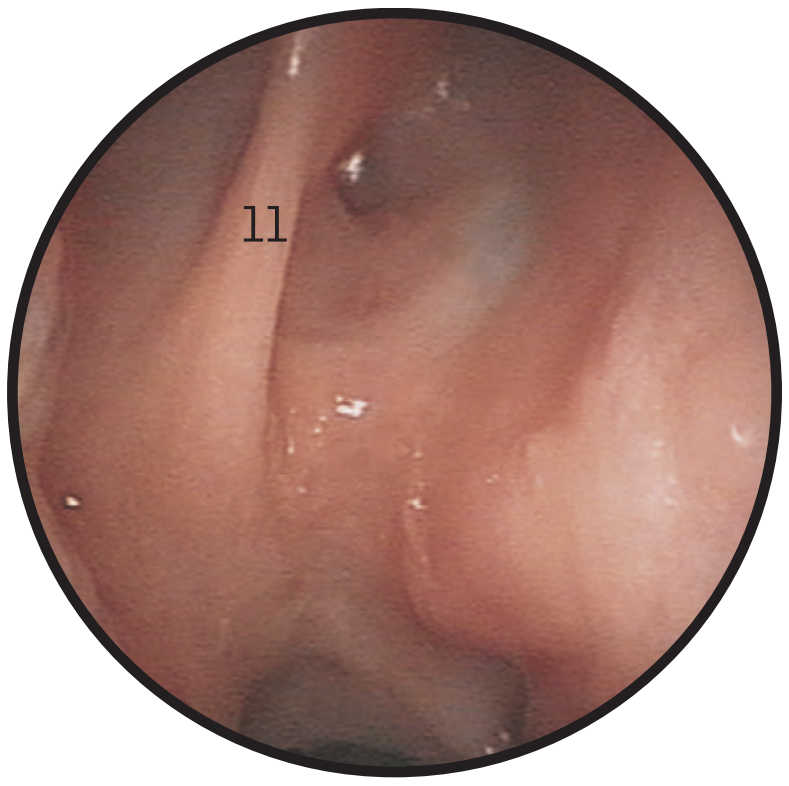

B Coronal MR image of face *muscles of mastication*

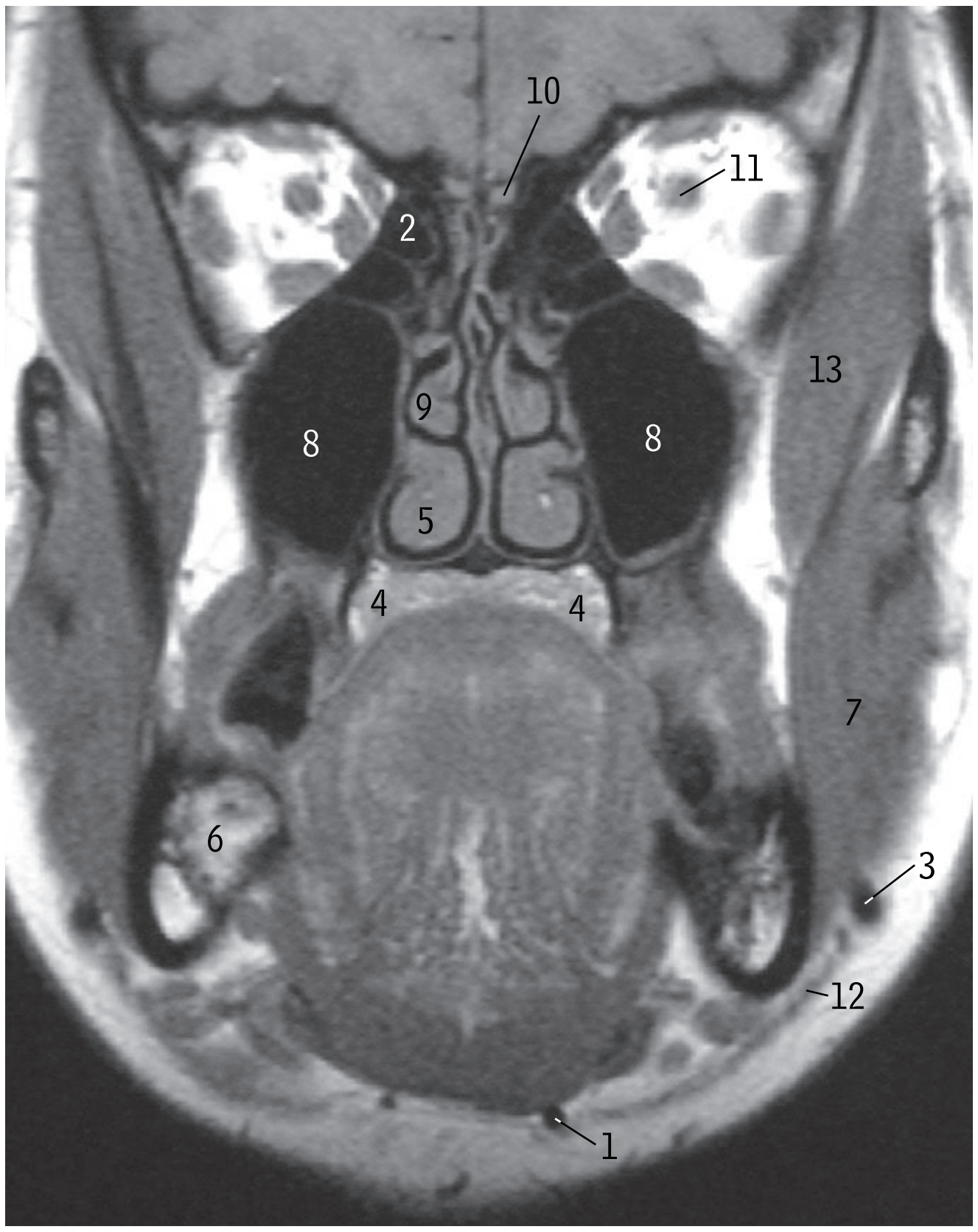

1 Anterior jugular vein
2 Ethmoid air cells
3 Facial artery
4 Hard palate
5 Inferior concha
6 Mandible
7 Masseter
8 Maxillary sinus
9 Middle concha
10 Olfactory tract
11 Optic nerve
12 Platysma
13 Temporalis

Inferior alveolar nerve block, see pages 80–82.

Right trigeminal, facial and petrosal nerves *with associated ganglia*

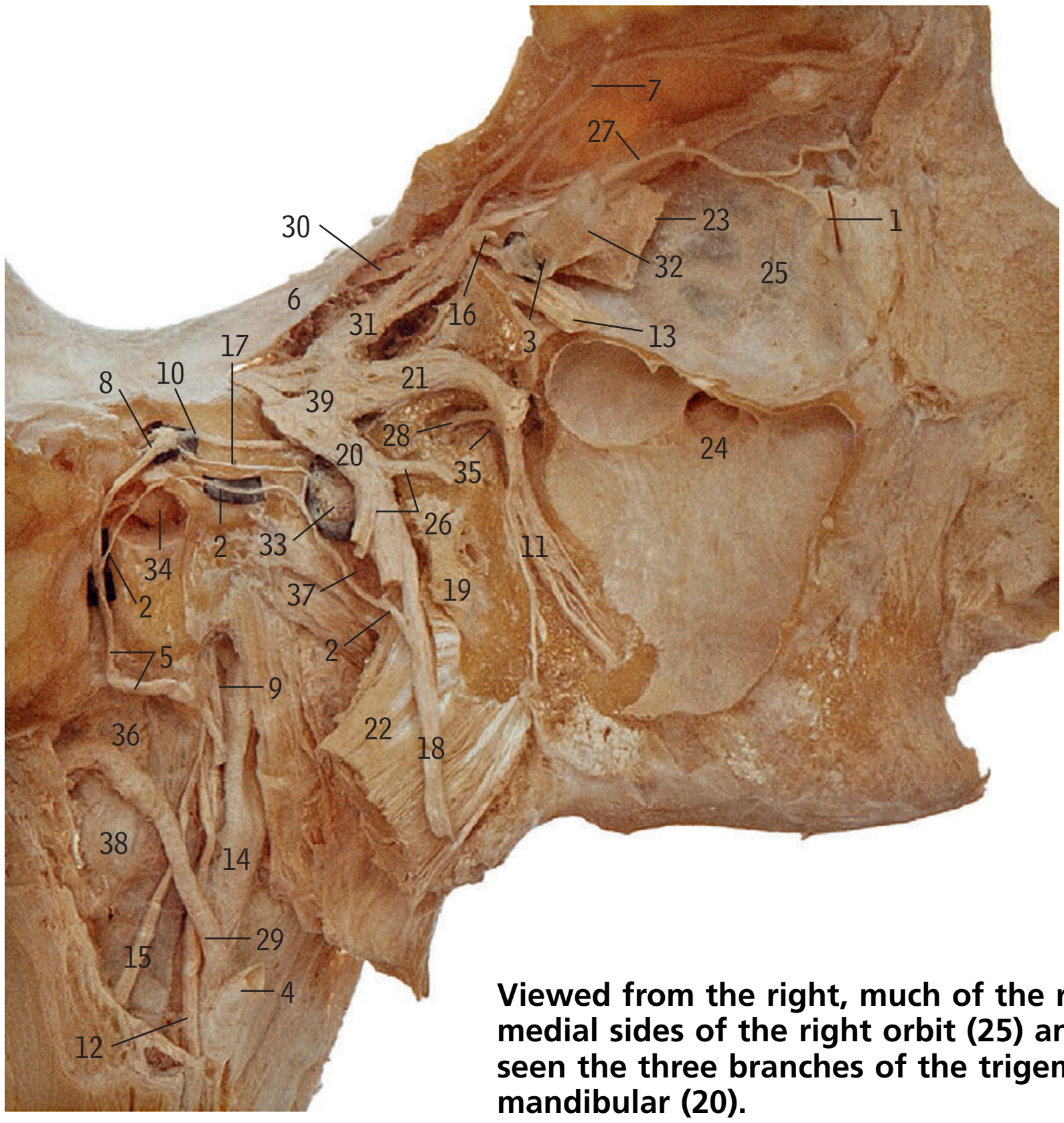

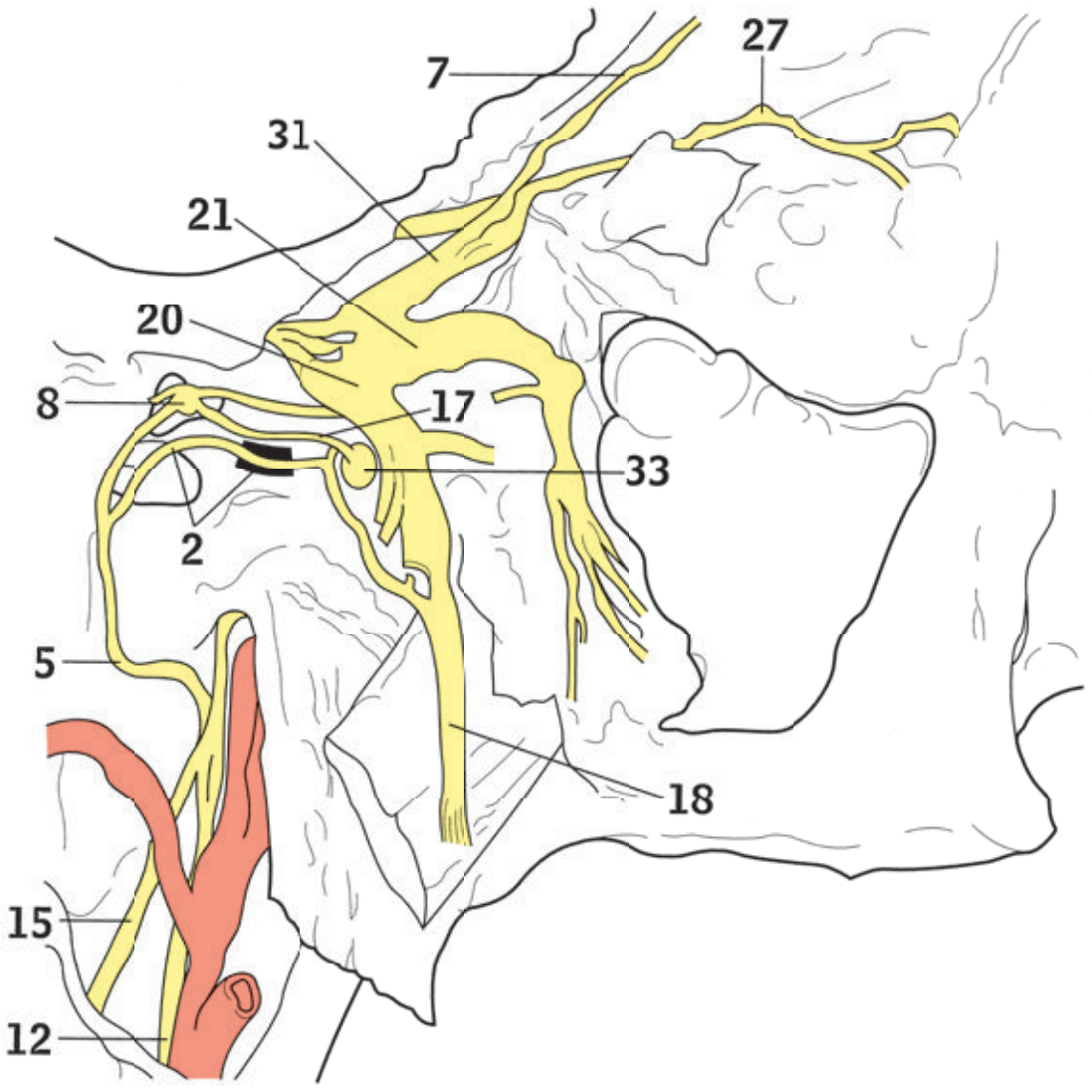

Viewed from the right, much of the right side of the skull has been removed leaving the medial sides of the right orbit (25) and the maxillary sinus (24). Posterior to the sinus are seen the three branches of the trigeminal nerve: ophthalmic (31), maxillary (21) and mandibular (20).

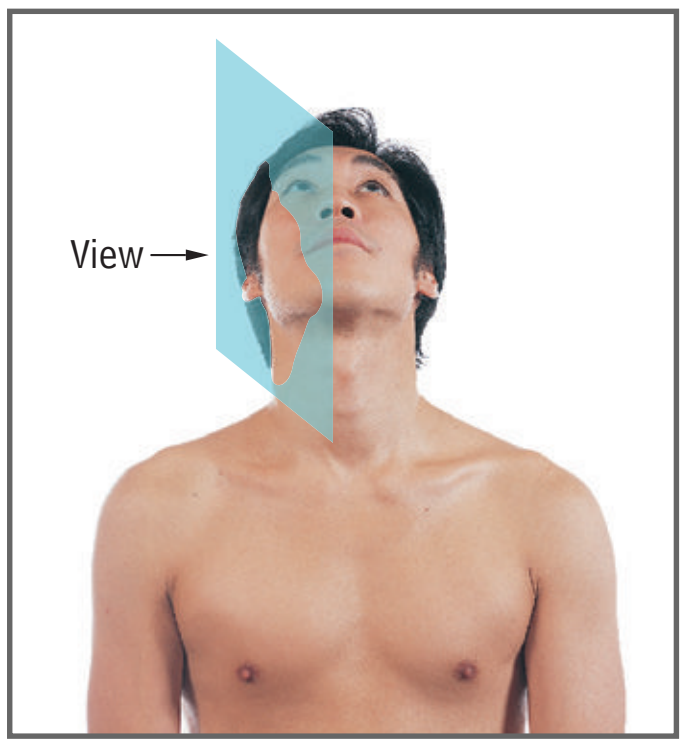

1 Bristle in lacrimal canaliculus
2 Chorda tympani
3 Ciliary ganglion
4 External carotid artery
5 Facial nerve
6 Free margin of tentorium cerebelli
7 Frontal nerve
8 Geniculate ganglion of facial nerve
9 Glossopharyngeal nerve
10 Greater petrosal nerve
11 Greater and lesser palatine nerves
12 Hypoglossal nerve
13 Inferior rectus
14 Internal carotid artery
15 Internal jugular vein and accessory nerve
16 Lacrimal nerve
17 Lesser petrosal nerve
18 Lingual nerve
19 Lower head of lateral pterygoid and lateral pterygoid plate
20 Mandibular nerve
21 Maxillary nerve
22 Medial pterygoid
23 Medial rectus
24 Medial wall of maxillary sinus and ostium
25 Medial wall of orbit
26 Muscular branches of mandibular nerve
27 Nasociliary nerve
28 Nerve of pterygoid canal
29 Occipital artery
30 Oculomotor nerve
31 Ophthalmic nerve
32 Optic nerve
33 Otic ganglion
34 Position of tympanic membrane
35 Pterygopalatine ganglion
36 Rectus capitis lateralis
37 Tensor veli palatini
38 Transverse process of atlas
39 Trigeminal ganglion

The greater petrosal nerve (10) is a branch of the geniculate ganglion of the facial nerve (8) and can be remembered as the nerve of tear secretion (though it also supplies nasal glands). It carries preganglionic fibres from the superior salivary nucleus in the pons, and runs in the groove on the floor of the middle cranial fossa (page 11, 25) to enter the foramen lacerum and become the nerve of the pterygoid canal (28) which joins the pterygopalatine ganglion (35). Postganglionic fibres leave the ganglion to join the maxillary nerve and enter the orbit by the zygomatic branch which communicates with the lacrimal nerve, supplying the gland.

The lesser petrosal nerve (17), although having a communication with the facial nerve, is a branch of the glossopharyngeal nerve, being derived from the tympanic branch which supplies the mucous membrane of the middle ear by the tympanic plexus (page 60, C19). Its fibres are derived from the inferior salivary nucleus in the pons, and after leaving the middle ear and running in its groove on the floor of the middle cranial fossa (17, and page 11, 26), the nerve reaches the otic ganglion (33) via the foramen ovale. From the ganglion secretomotor fibres join the mandibular nerve (20) to be distributed to the parotid gland by filaments from the auriculotemporal nerve.

The chorda tympani (2) arises from the facial nerve before the latter leaves the stylomastoid foramen (5, upper leader line). It crosses the upper part of the tympanic membrane (34) underneath its mucosal covering and runs through the temporal bone, emerging from the petrotympanic fissure (page 9, 35) to join the lingual nerve (18). It carries preganglionic fibres to the submandibular ganglion (page 59, C35) for the submandibular and sublingual salivary glands, and also taste fibres for the anterior two-thirds of the tongue.

The otic ganglion (33), which normally adheres to the deep surface of the mandibular nerve (20), has been teased off from the nerve and a black marker has been placed behind it.

Pharynx *posterior surface, from behind*

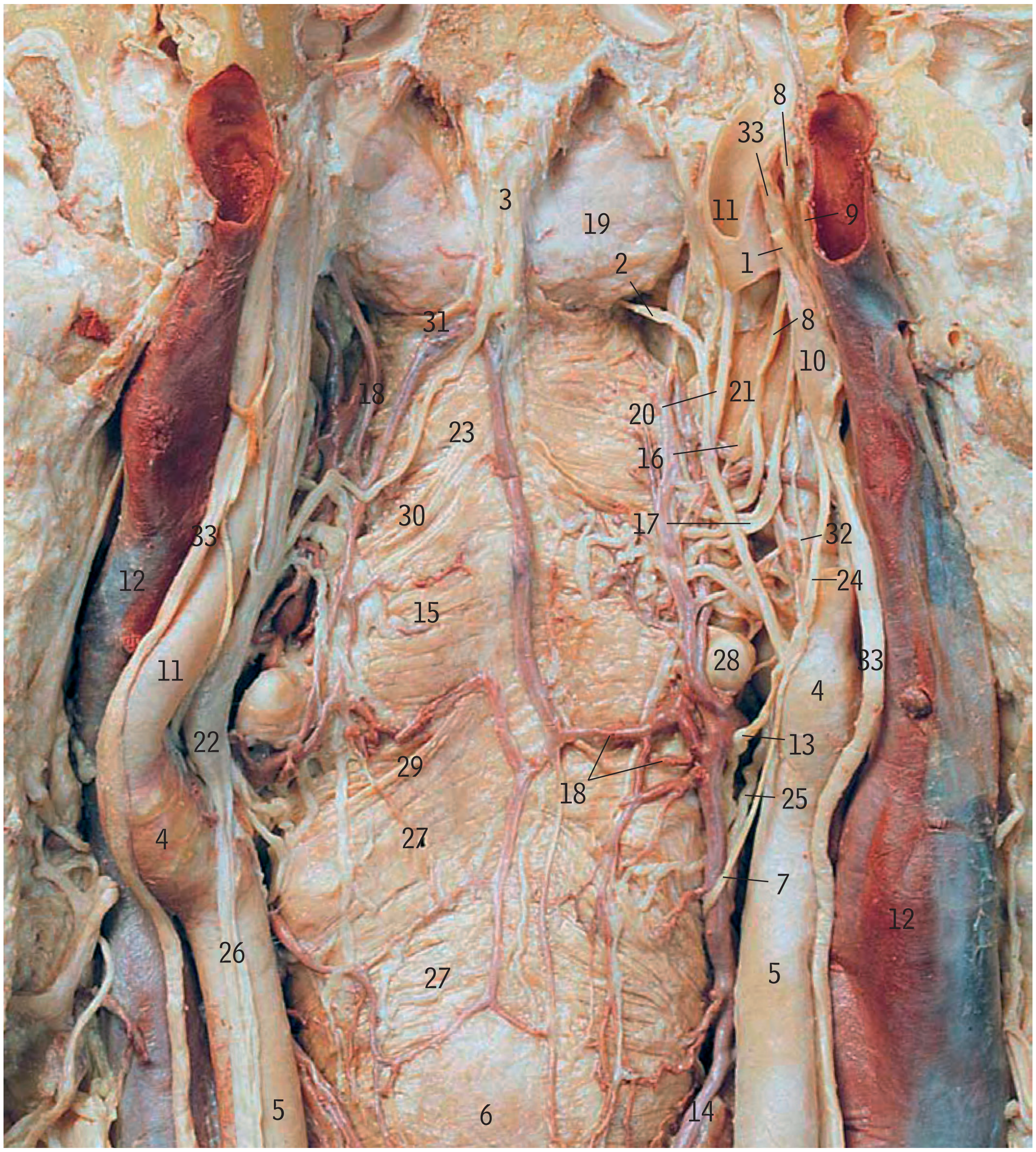

1 Accessory nerve
2 Ascending pharyngeal artery
3 Attachment of pharyngeal raphe to pharyngeal tubercle of base of skull
4 Carotid sinus
5 Common carotid artery
6 Cricopharyngeal part of inferior constrictor
7 External laryngeal nerve
8 Glossopharyngeal nerve
9 Hypoglossal nerve
10 Inferior ganglion of vagus nerve
11 Internal carotid artery
12 Internal jugular vein
13 Internal laryngeal nerve
14 Lateral lobe of thyroid gland
15 Middle constrictor
16 Pharyngeal branch of glossopharyngeal nerve
17 Pharyngeal branch of vagus nerve
18 Pharyngeal veins
19 Pharyngobasilar fascia
20 Posterior meningeal artery
21 Stylopharyngeus
22 Superior cervical sympathetic ganglion
23 Superior constrictor
24 Superior laryngeal branch of vagus nerve
25 Superior thyroid artery
26 Sympathetic trunk
27 Thyropharyngeal part of inferior constrictor
28 Tip of greater horn of hyoid bone
29 Upper border of inferior constrictor
30 Upper border of middle constrictor
31 Upper border of superior constrictor
32 Vagal branch to carotid body
33 Vagus nerve

The vertebral column has been removed to reveal the carotid sheath and constrictor muscles of the pharynx.

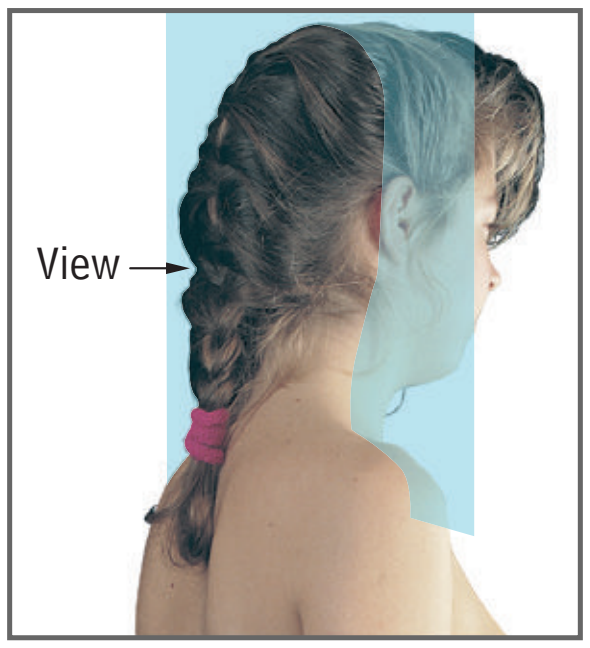

Gag reflex, see pages 80–82.

Posterior pharyngeal wall *from behind*

Slightly oblique coronal section of the head and neck in the plane of the posterior pharyngeal wall, with the right side slightly posterior to the left.

Sections of the posterior pharyngeal wall have been removed (asterisks – superiorly the pharyngobasilar fascia and inferiorly the lower border of the inferior constrictor) to reveal parts of the nasopharynx and the laryngopharynx, respectively.

Refer to the key on page 47 for the numbers on this figure.

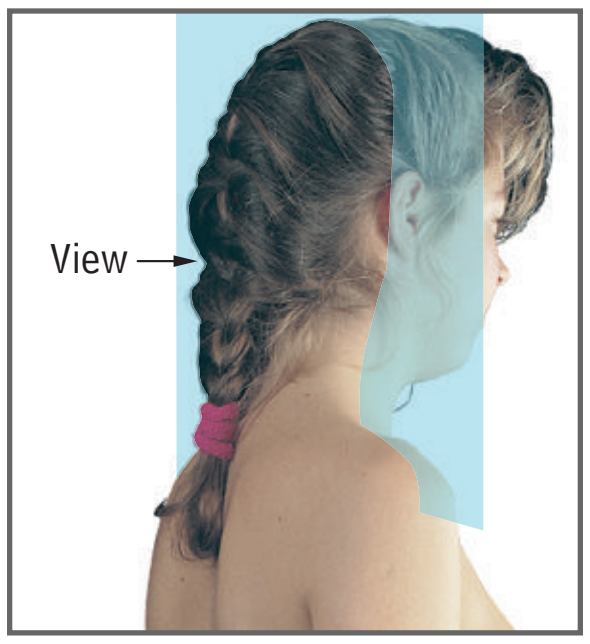

Pharyngeal pouch, tonsillectomy, see pages 80–82.

A 'Opened' pharynx *from behind*

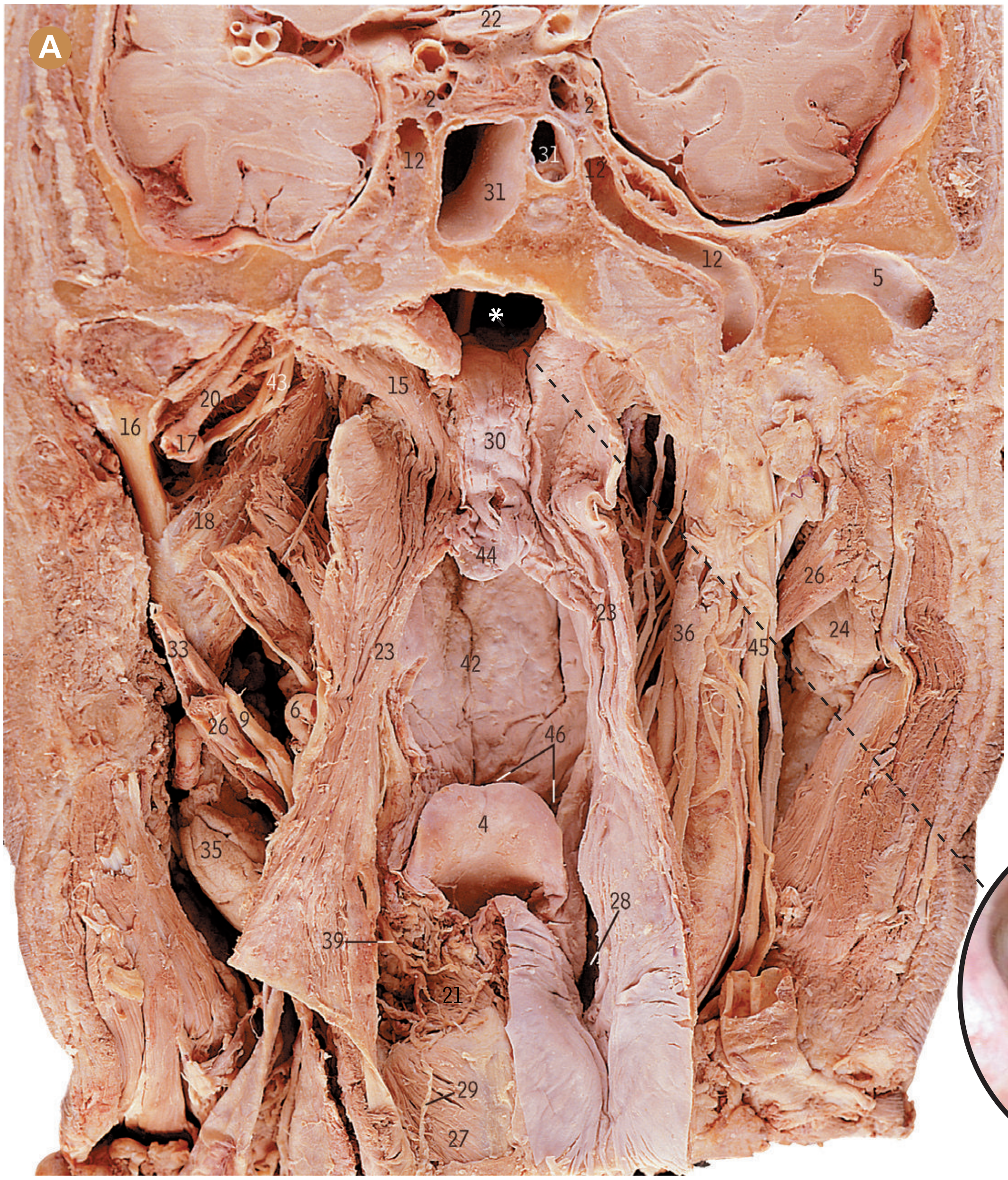

Close-up of interior of the pharynx, after incising and reflecting posterior pharyngeal wall and removing the mucosa from the left pharyngeal walls.

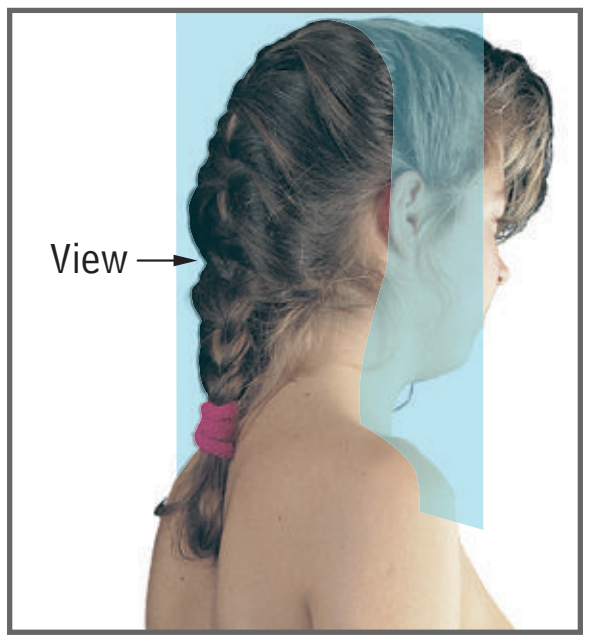

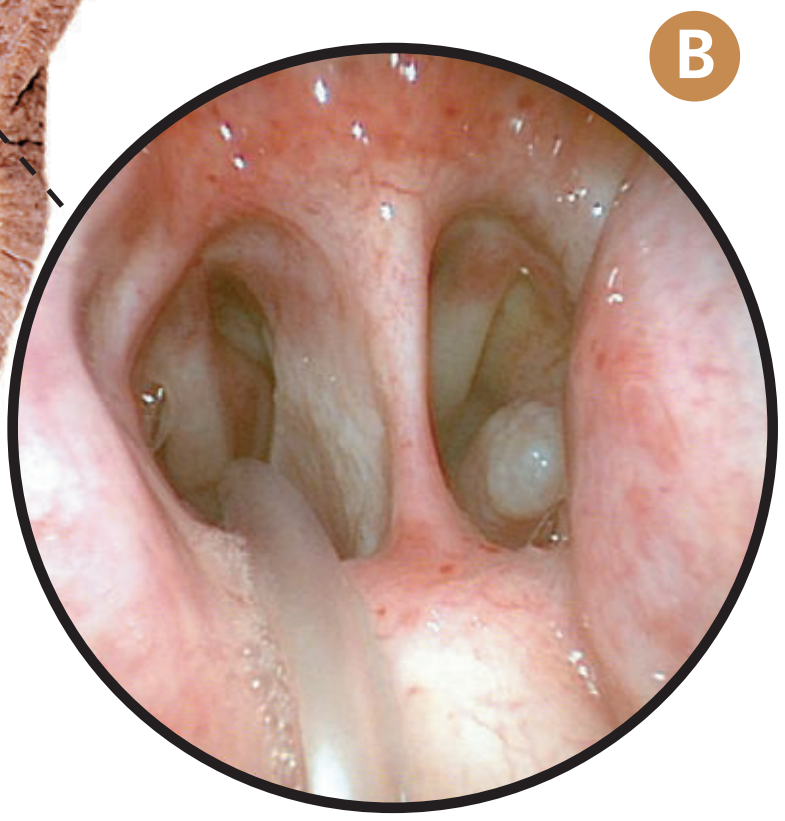

1 Anterior cerebral artery
2 Cavernous sinus
3 Common carotid
4 Epiglottis
5 External auditory canal
6 Facial artery
7 Falx cerebri
8 Hyoid-tip of greater horn
9 Hypoglossal nerve
10 Inferior constrictor
11 Inferior constrictor-cricopharyngeus part
12 Internal carotid
13 Internal carotid giving off middle cerebral
14 Lateral ventricle
15 Levator veli palatini
16 Mandible, neck
17 Maxillary artery
18 Medial pterygoid
19 Middle constrictor
20 Middle meningeal artery
21 Oblique arytenoid
22 Optic chiasm
23 Palatopharyngeus
24 Parotid gland
25 Pharyngeal plexus of veins
26 Posterior belly of digastric
27 Posterior crico-arytenoid
28 Piriform fossa (recess)
29 Recurrent laryngeal nerve
30 Soft palate, nasal surface
31 Sphenoidal sinus
32 Styloglossus muscle
33 Stylohyoid muscle
34 Stylopharyngeus, with glossopharyngeal nerve
35 Submandibular gland
36 Superior cervical ganglion
37 Superior constrictor
38 Superior pharyngeal branch of vagus
39 Superior laryngeal nerve, internal branch
40 Superior sagittal sinus
41 Thyroid cartilage lamina, cut
42 Tongue, dorsum, posterior third
43 Trigeminal nerve, mandibular division
44 Uvula
45 Vagus
46 Vallecula

B Endoscopic view of choanae and posterior nasal septum

NB: Nasogastric tube in situ

Pharyngitis, see pages 80–82.

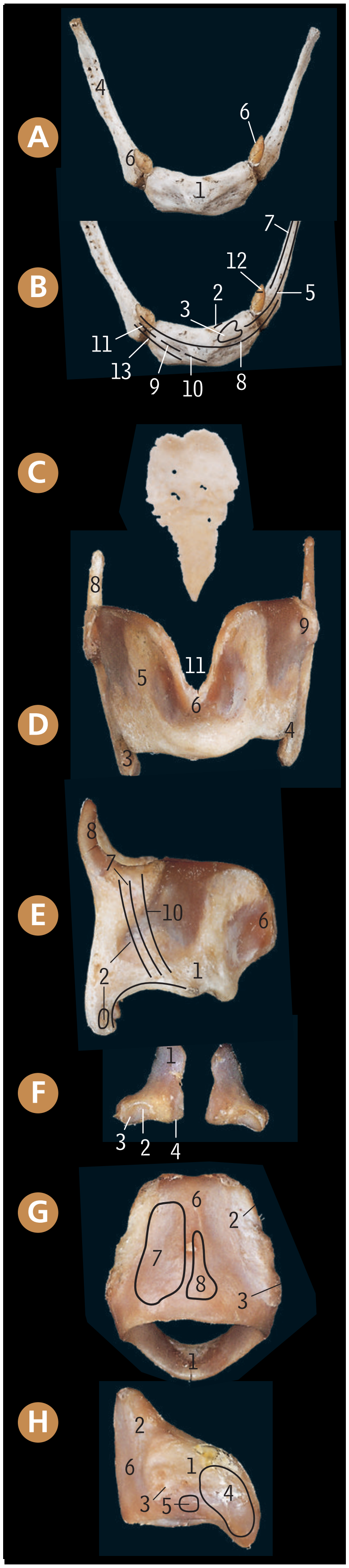

Hyoid bone

A from above and in front

B with muscle attachments

1. Body
2. Genioglossus
3. Geniohyoid
4. Greater horn
5. Hyoglossus
6. Lesser horn
7. Middle constrictor
8. Mylohyoid
9. Omohyoid
10. Sternohyoid
11. Stylohyoid
12. Stylohyoid ligament
13. Thyrohyoid

Epiglottis

C cartilage, from the front

Thyroid

D cartilage, from the front

E from the right, with attachments

1. Cricothyroid
2. Inferior constrictor
3. Inferior horn
4. Inferior tubercle
5. Lamina
6. Laryngeal prominence (Adam's apple)
7. Sternothyroid
8. Superior horn
9. Superior tubercle
10. Thyrohyoid
11. Thyroid notch

Arytenoid cartilages

F from behind

1. Apex
2. Articular surface for cricoid cartilage
3. Muscular process
4. Vocal process

Cricoid cartilage *and muscle attachments*

G from behind and below

H from the right

1. Arch
2. Articular surface for arytenoid cartilage
3. Articular surface for inferior horn of thyroid cartilage
4. Cricothyroid
5. Inferior constrictor
6. Lamina
7. Posterior crico-arytenoid
8. Tendon of oesophagus

Laryngeal *surface anatomy*

I lateral view

J anterior view

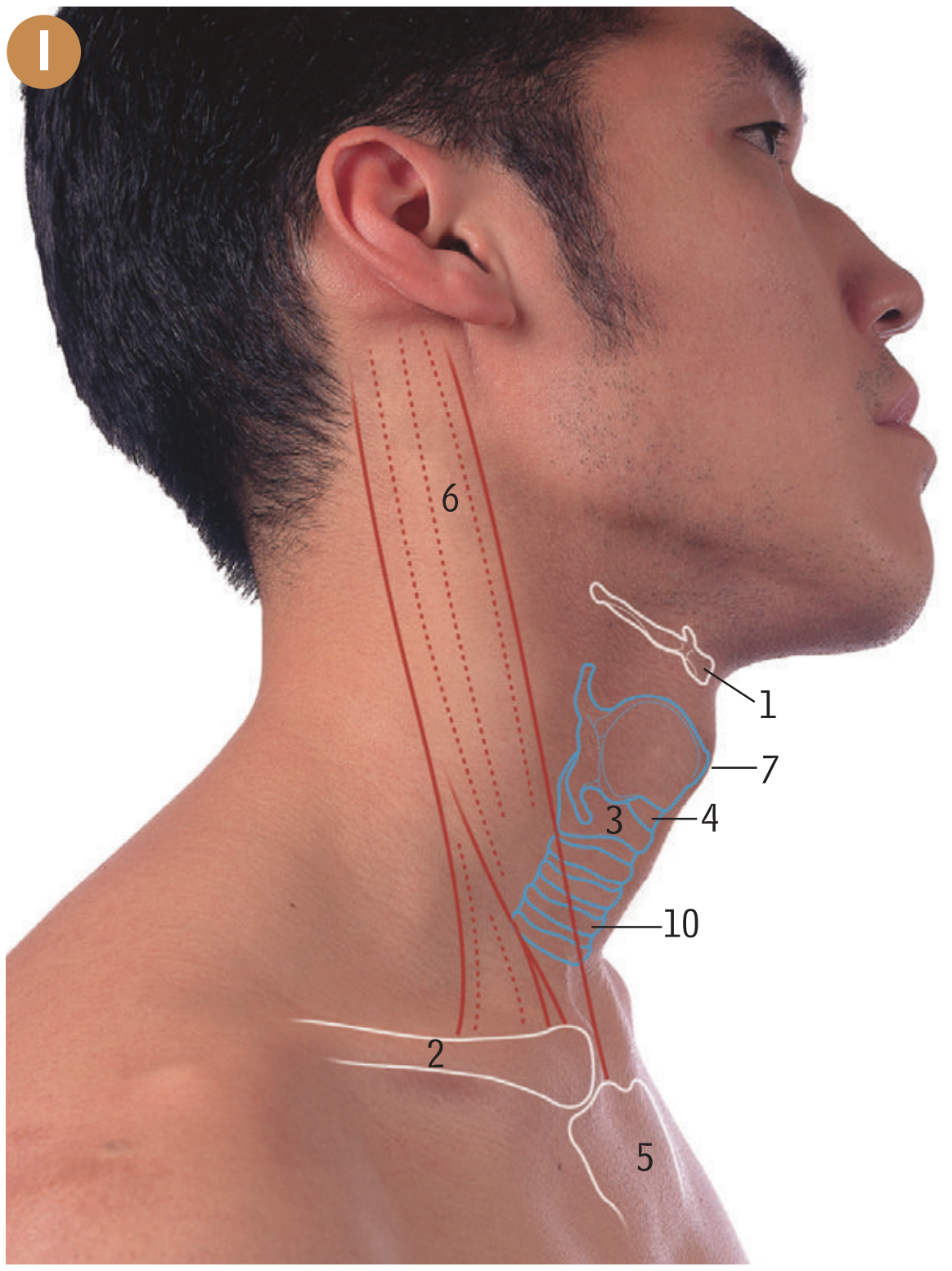

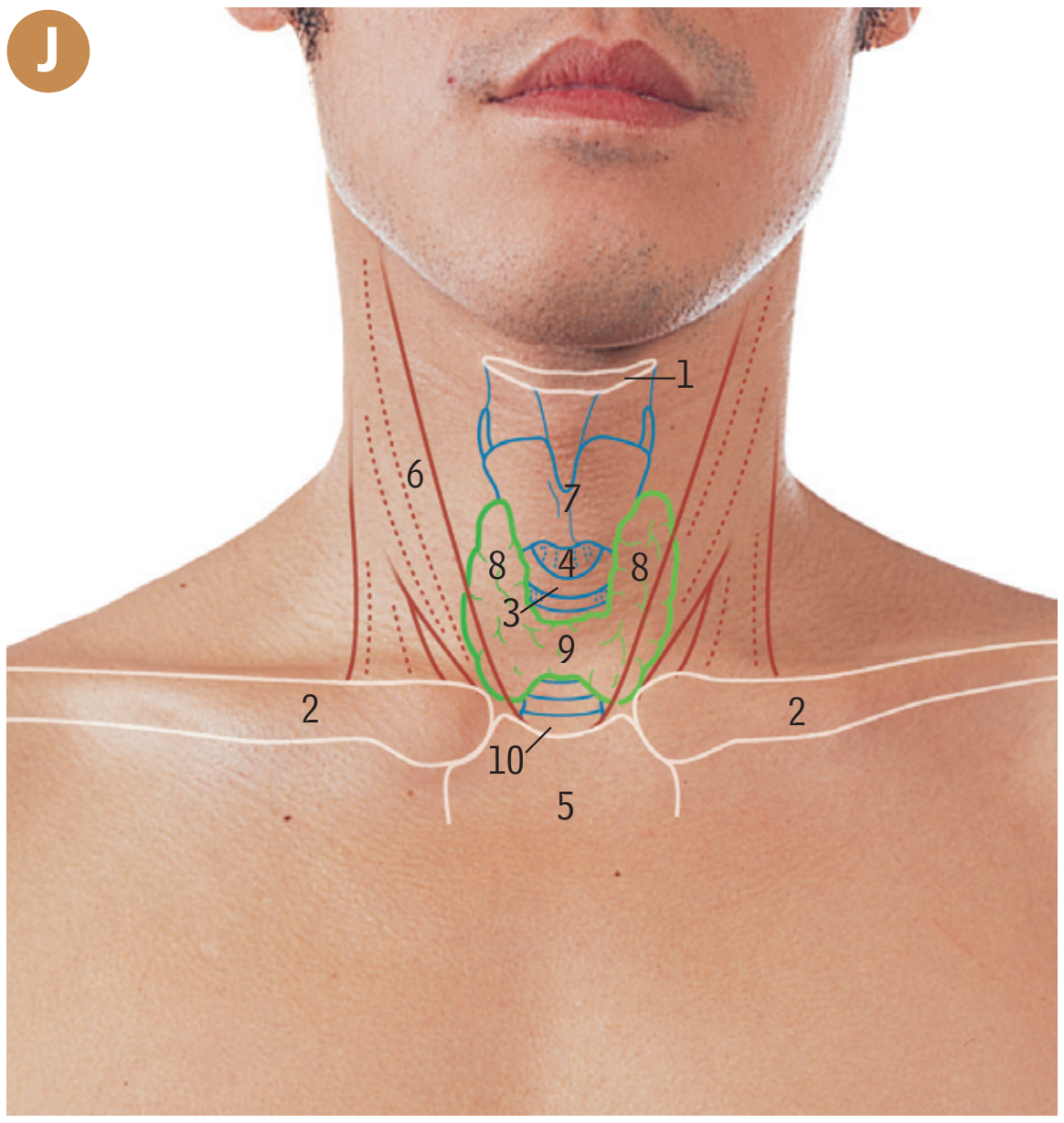

1. Body of hyoid bone
2. Clavicle
3. Cricoid cartilage
4. Cricothyroid ligament/ membrane
5. Manubrium
6. Sternocleidomastoid muscle
7. Thyroid cartilage, laryngeal prominence
8. Thyroid gland, lateral lobe
9. Thyroid gland, isthmus
10. Tracheal ring

Tracheostomy, see pages 80–82.

A Tongue and the inlet of the larynx *from above*

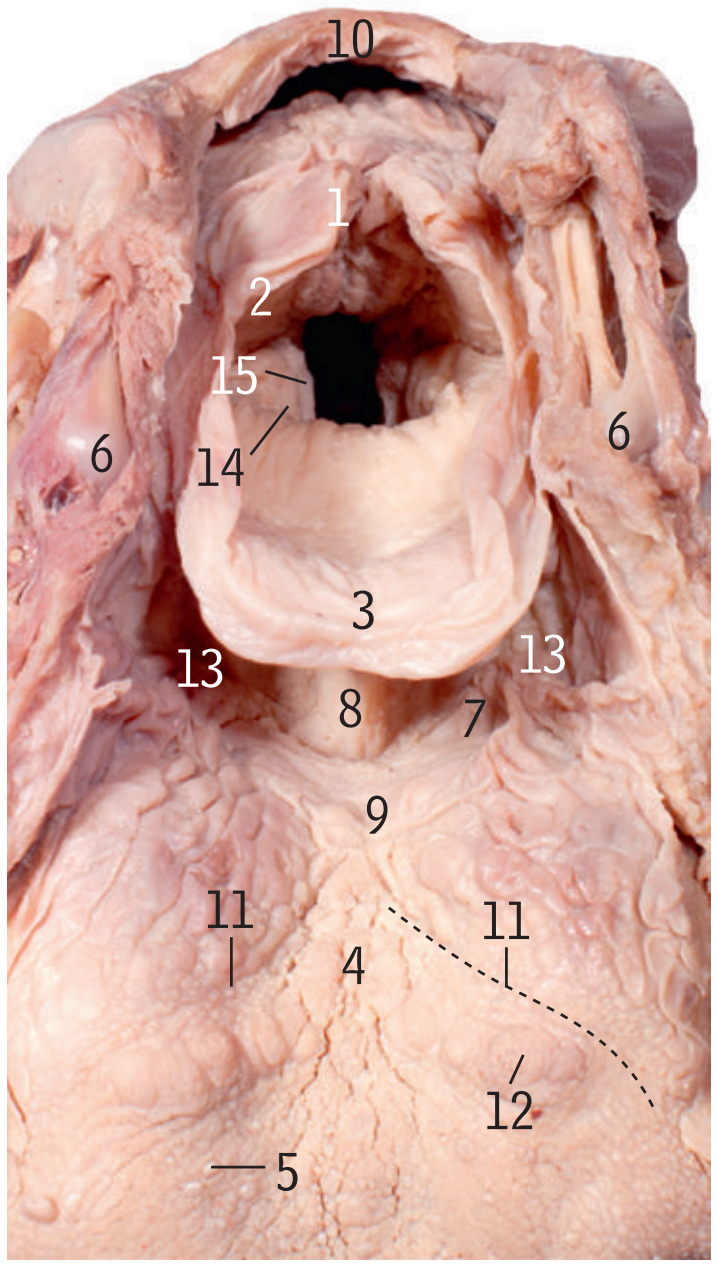

1 Corniculate cartilage in aryepiglottic fold
2 Cuneiform cartilage in aryepiglottic fold
3 Epiglottis
4 Foramen caecum
5 Fungiform papilla
6 Hyoid, greater horn
7 Lateral glossoepiglottic fold
8 Median glossoepiglottic fold
9 Pharyngeal part of dorsum of tongue
10 Posterior wall of pharynx
11 Sulcus terminalis, unilaterally indicated by dashed line
12 Vallate papilla
13 Vallecula
14 Vestibular fold (false vocal cord)
15 Vocal fold (true vocal cord)

B Larynx *from behind*

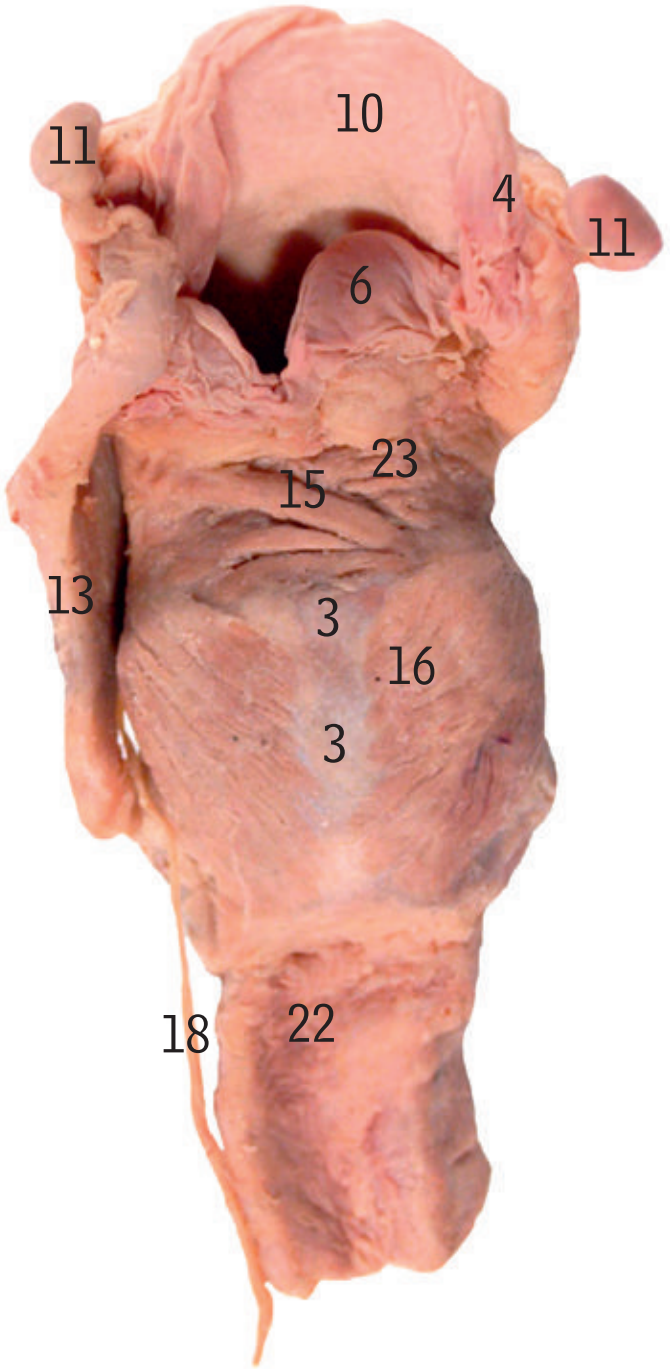

See label list below right for B.

Intrinsic muscles of the larynx

C *from the left*

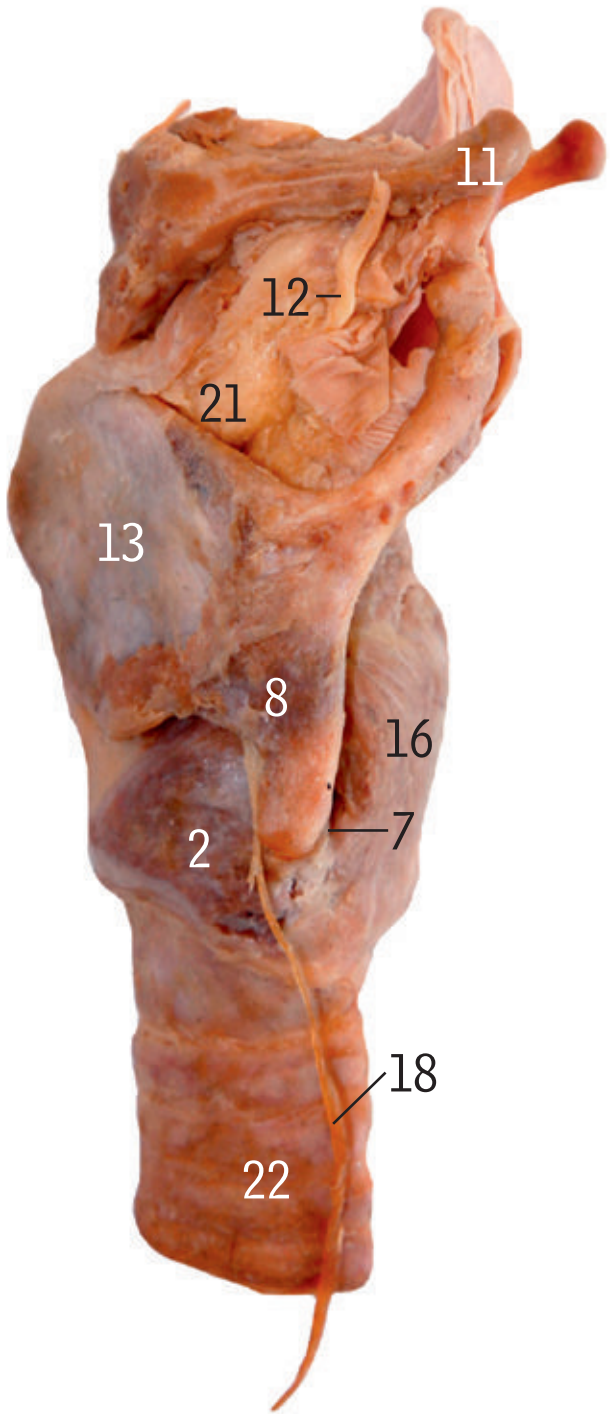

D *from the posterior oblique view*

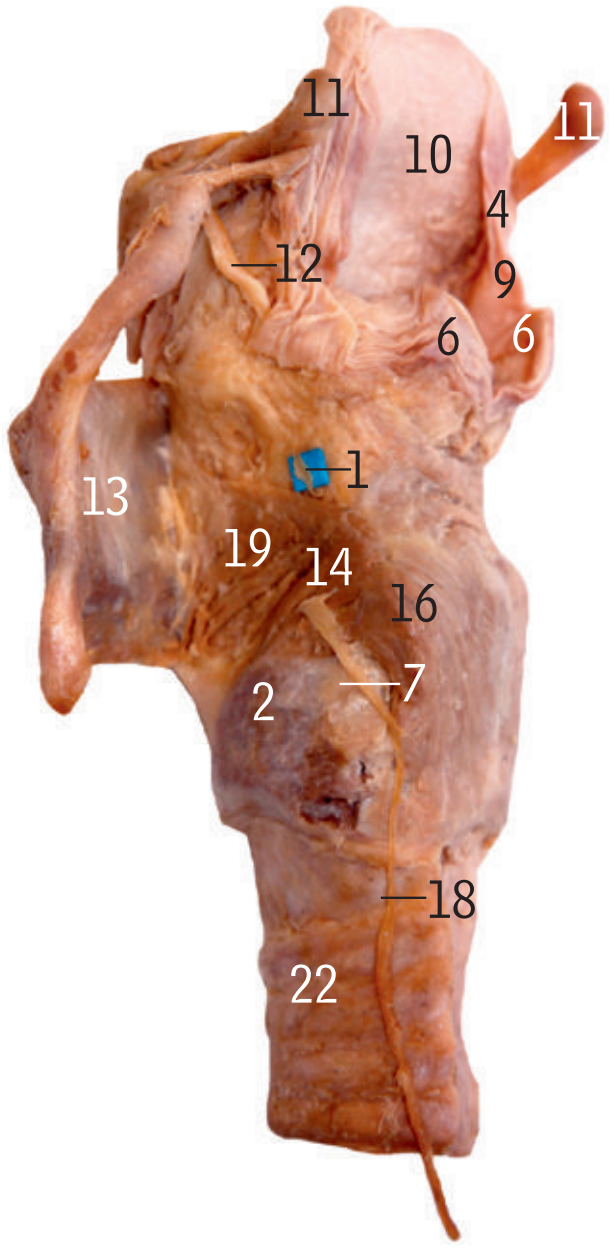

E *from the right*

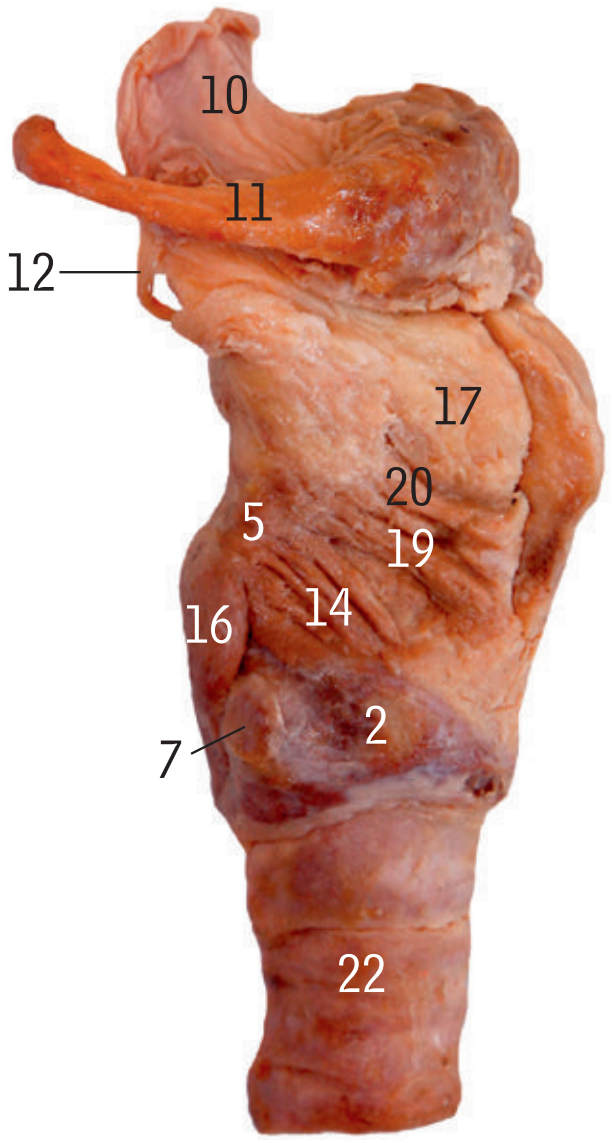

1 Anastomosis of internal and recurrent laryngeal nerves (galen's anastomosis)
2 Arch of cricoid cartilage
3 Area on lamina of cricoid cartilage for attachment of oesophagus
4 Aryepiglottic fold
5 Aryepiglottic muscle
6 Corniculate cartilage
7 Cricothyroid joint
8 Cricothyroid muscle (origin from thyroid cartilage)
9 Cuneiform cartilage
10 Epiglottis
11 Greater horn of hyoid bone
12 Internal laryngeal nerve
13 Lamina of thyroid cartilage
14 Lateral crico-arytenoid muscle
15 Oblique arytenoid cartilage
16 Posterior crico-arytenoid muscle
17 Quadrangular ligament
18 Recurrent laryngeal nerve
19 Thyro-arytenoid muscle
20 Thyro-epiglottic muscle
21 Thyrohyoid membrane
22 Trachea
23 Transverse arytenoid muscle

In D, the thyroid cartilage has been reflected forward, and in E the right lamina of the thyroid cartilage has been removed.

Endotracheal intubation, recurrent laryngeal nerve palsy, see pages 80–82.

A Larynx *in sagittal section, from the right*

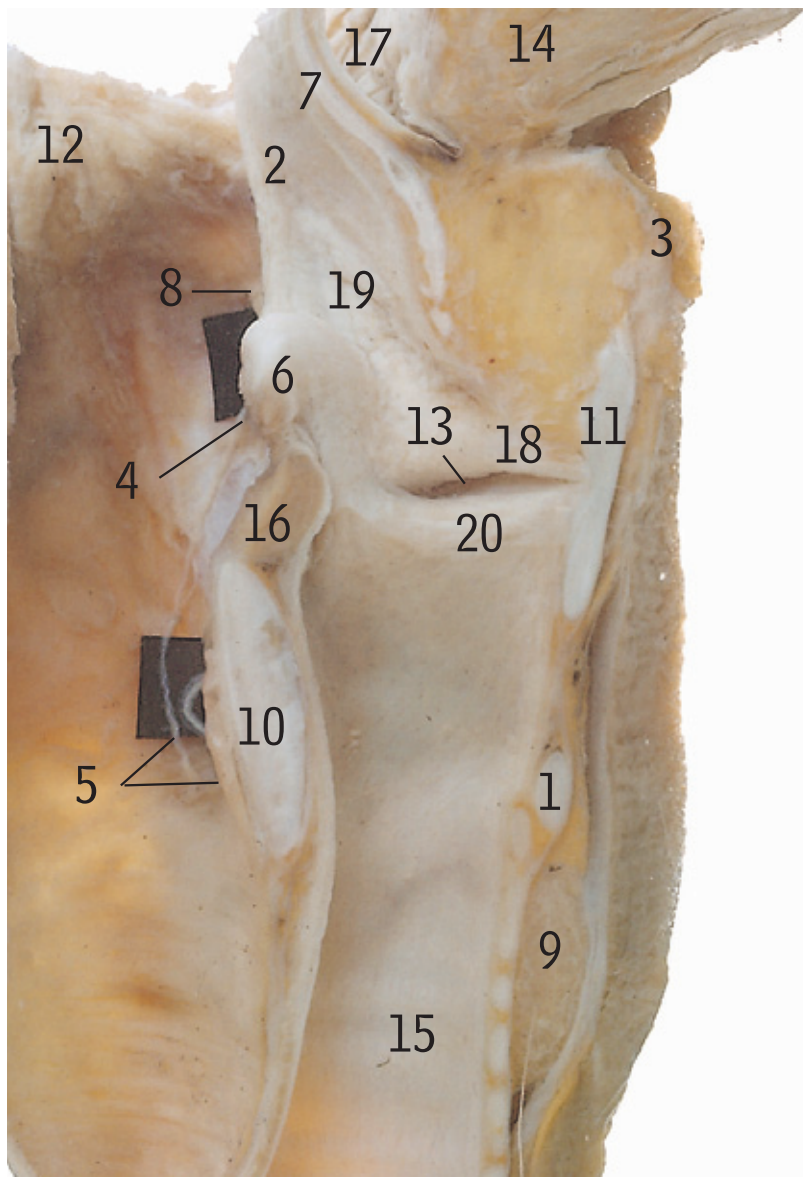

The vocal fold (vocal cord, 20) lies below the vestibular fold (false vocal cord, 18).

1 Arch of cricoid cartilage
2 Aryepiglottic fold and inlet of larynx
3 Body of hyoid bone
4 Branches of internal laryngeal nerve anastomosing with recurrent laryngeal nerve
5 Branches of recurrent laryngeal nerve
6 Corniculate cartilage and apex of arytenoid cartilage
7 Epiglottis
8 Internal laryngeal nerve entering piriform recess
9 Isthmus of thyroid gland
10 Lamina of cricoid cartilage
11 Lamina of thyroid cartilage
12 Pharyngeal wall
13 Sinus of larynx (laryngeal ventricle)
14 Tongue
15 Trachea
16 Transverse arytenoid muscle
17 Vallecula
18 Vestibular fold
19 Vestibule of larynx
20 Vocal fold

The space between the vestibular and vocal folds is the sinus of the larynx (A13), and this is continuous with the saccule, a small pouch that extends upwards for a few millimetres between the vestibular fold and the inner surface of the thyroarytenoid muscle.

The fissure between the two vestibular folds (A18) is the rima of the vestibule. The fissure between the vocal folds is the rima of the glottis.

The vestibular folds are often called the false vocal cords.

The intrinsic muscles of the larynx are supplied by the recurrent laryngeal nerve, except the cricothyroid (page 49, C8) which is supplied by the external laryngeal nerve (page 29, 12).

B Larynx *internal views*

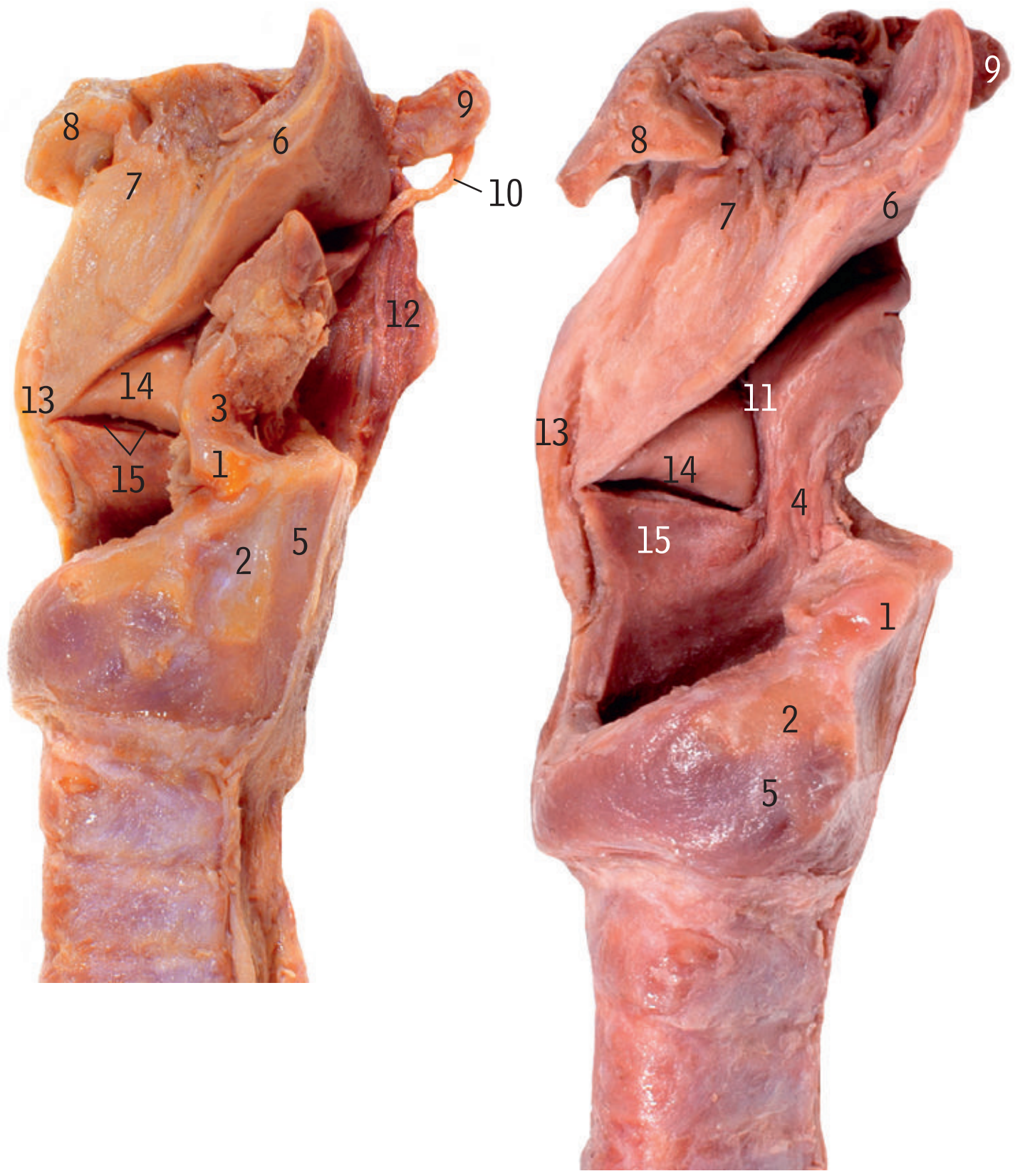

1 Articular facet on cricoid for left arytenoid cartilage
2 Articular site of thyroid and cricoid cartilages
3 Arytenoid cartilage, left, lateral surface
4 Arytenoid cartilage, right, medial surface
5 Cricoid cartilage, lamina
6 Epiglottis
7 Hyoepiglottic ligament
8 Hyoid arch, cross-section
9 Hyoid, greater horn
10 Internal laryngeal nerve
11 Quadrangular membrane
12 Thyrohyoid membrane
13 Thyroid cartilage, lamina, cross-section
14 Vestibular fold (false vocal cord)
15 Vocal fold (true vocal cord)

Endoscopic view of cricoid and tracheal rings

Cranial fossae A *with dura mater intact* B *with some dura removed*

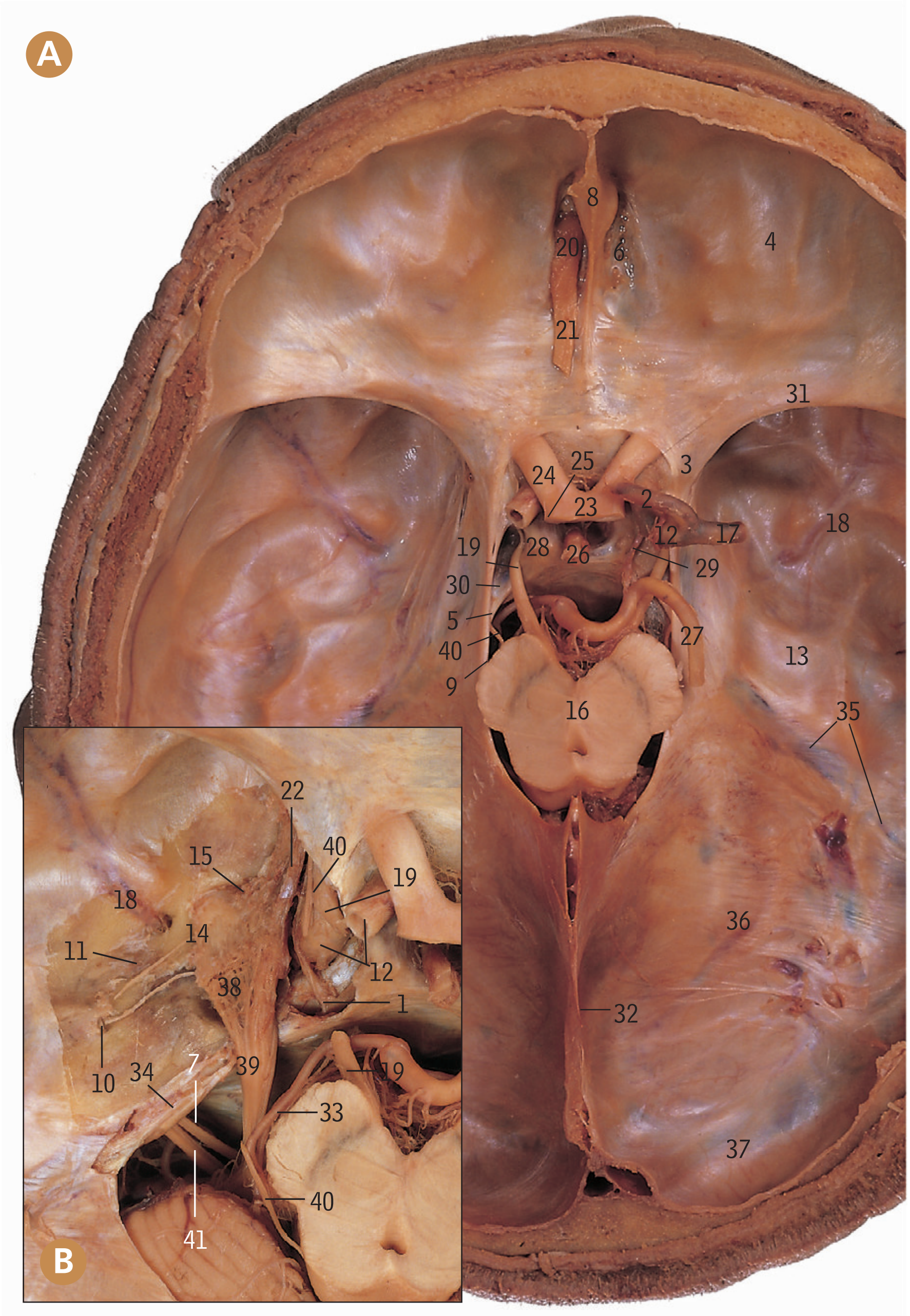

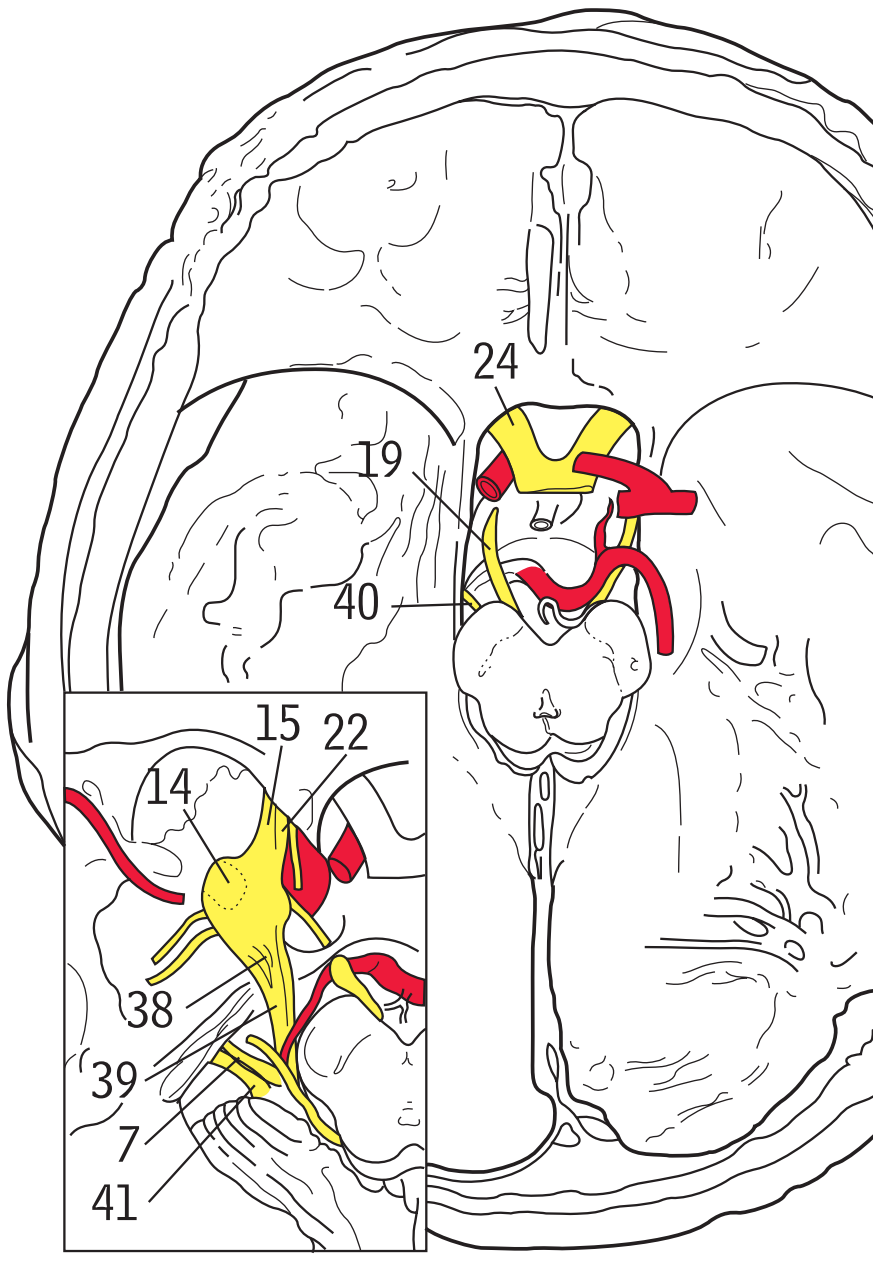

1 Abducent nerve
2 Anterior cerebral artery
3 Anterior clinoid process
4 Anterior cranial fossa
5 Attached margin of tentorium cerebelli
6 Cribriform plate of ethmoid bone
7 Facial nerve
8 Falx cerebri attached to crista galli
9 Free margin of tentorium cerebelli
10 Hiatus for greater petrosal nerve
11 Hiatus for lesser petrosal nerve
12 Internal carotid artery
13 Lateral part of middle cranial fossa
14 Mandibular nerve
15 Maxillary nerve
16 Midbrain (superior colliculus level)
17 Middle cerebral artery
18 Middle meningeal vessels
19 Oculomotor nerve (cut)
20 Olfactory bulb
21 Olfactory tract
22 Ophthalmic nerve
23 Optic chiasma
24 Optic nerve
25 Optic tract
26 Pituitary stalk
27 Posterior cerebral artery
28 Posterior clinoid process
29 Posterior communicating artery
30 Roof of cavernous sinus
31 Sphenoparietal sinus (at posterior border of lesser wing of sphenoid bone)
32 Straight sinus (at junction of falx cerebri and tentorium cerebelli)
33 Superior cerebellar artery
34 Superior petrosal sinus
35 Superior petrosal sinus (at attached margin of tentorium cerebelli)
36 Tentorium cerebelli
37 Transverse sinus (at attached margin of tentorium cerebelli)
38 Trigeminal ganglion
39 Trigeminal nerve
40 Trochlear nerve
41 Vestibulocochlear nerve

Cavernous sinus thrombosis, see pages 80–82.

Sagittal section of the head

A right half, from the left

B endoscopic view of nasopharynx

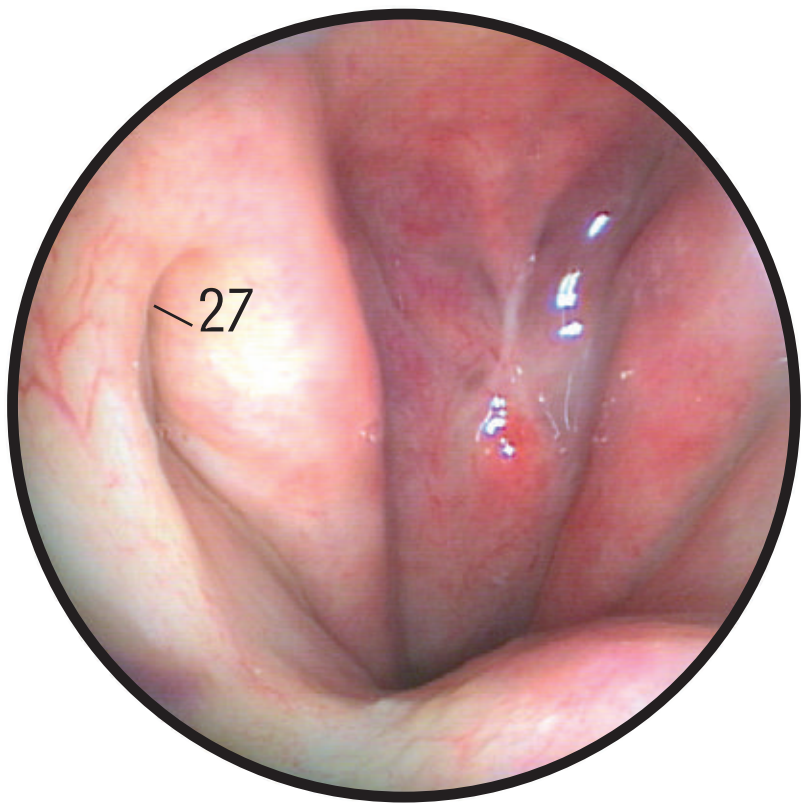

The falx cerebri (10) separates the two cerebral hemispheres. The tentorium cerebelli (39) separates the posterior parts of the cerebral hemispheres from the cerebellum (5).

C MRI (magnetic resonance image)

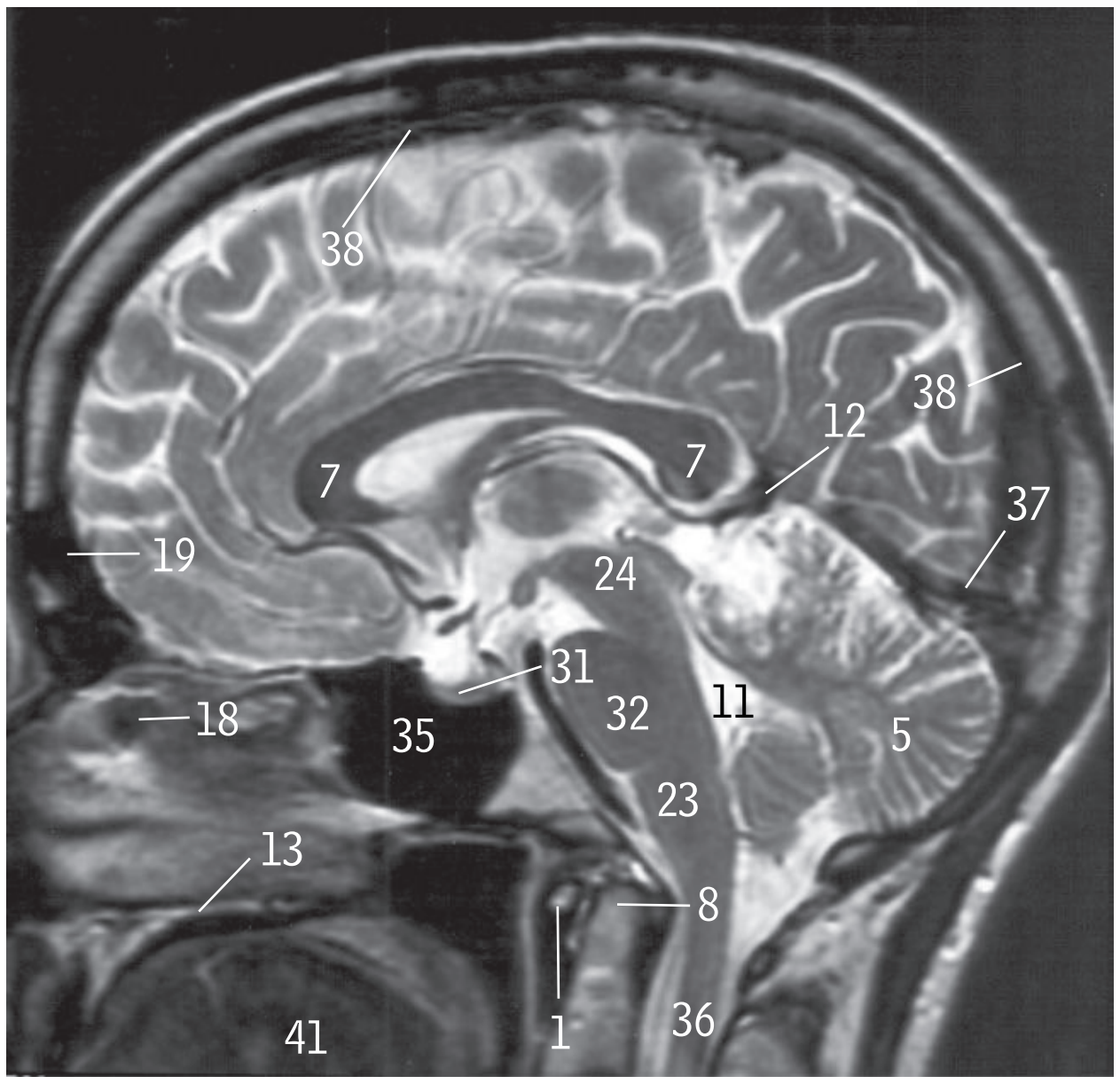

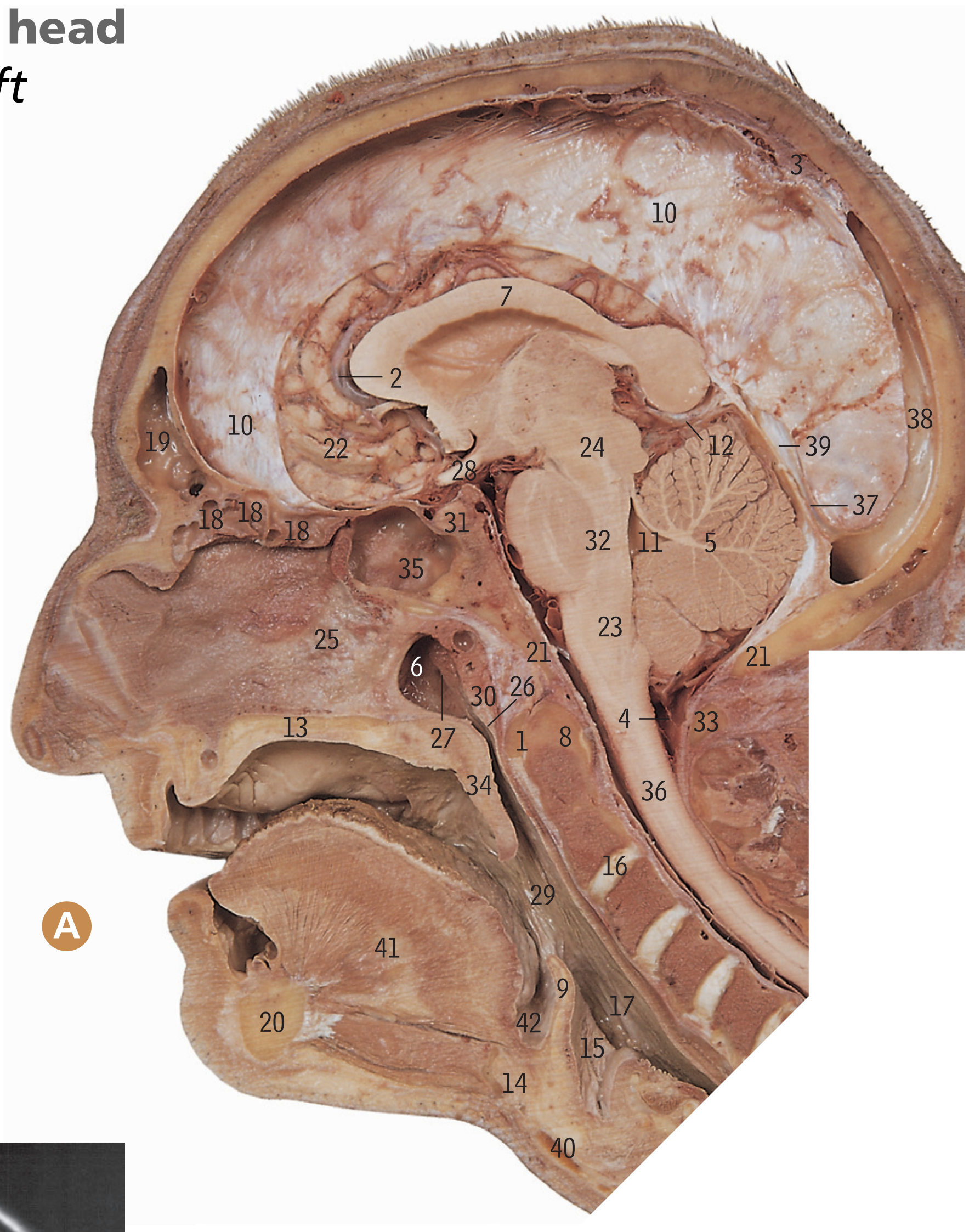

1 Anterior arch of atlas
2 Anterior cerebral artery
3 Arachnoid granulations
4 Cerebellomedullary cistern (cisterna magna)
5 Cerebellum
6 Choana (posterior nasal aperture)
7 Corpus callosum
8 Dens of axis
9 Epiglottis
10 Falx cerebri
11 Fourth ventricle
12 Great cerebral vein (of Galen)
13 Hard palate
14 Hyoid bone
15 Inlet of larynx
16 Intervertebral disc between axis and third cervical vertebra
17 Laryngeal part of pharynx
18 Left ethmoidal air cells
19 Left frontal sinus
20 Mandible
21 Margin of foramen magnum
22 Medial surface of right cerebral hemisphere
23 Medulla oblongata
24 Midbrain
25 Nasal septum (bony part)
26 Nasopharynx
27 Opening of auditory tube
28 Optic chiasma
29 Oral part of pharynx (oropharynx)
30 Pharyngeal (nasopharyngeal) tonsil (adenoids)
31 Pituitary gland
32 Pons
33 Posterior arch of atlas
34 Soft palate
35 Sphenoidal sinus
36 Spinal cord
37 Straight sinus
38 Superior sagittal sinus
39 Tentorium cerebelli
40 Thyroid cartilage
41 Tongue
42 Vallecula

Adenoid (pharyngeal tonsil) enlargement, pituitary apoplexy, see pages 80–82.

A Cerebral dura mater and cranial nerves

1 Abducent nerve
2 Arachnoid granulations
3 Attached margin of tentorium cerebelli
4 Choana (posterior nasal aperture)
5 Clivus
6 Dens of axis
7 Falx cerebri
8 Free margin of tentorium cerebelli
9 Glossopharyngeal, vagus and accessory nerves
10 Inferior sagittal sinus
11 Internal carotid artery
12 Margin of foramen magnum
13 Medulla oblongata
14 Motor root of facial nerve
15 Nasal septum
16 Oculomotor nerve
17 Olfactory tract
18 Optic nerve
19 Pituitary gland
20 Posterior arch of atlas
21 Rootlets of hypoglossal nerve
22 Sensory root (nervus intermedius) of facial nerve
23 Sphenoidal sinus
24 Sphenoparietal sinus
25 Spinal cord
26 Spinal part of accessory nerve
27 Straight sinus
28 Superior sagittal sinus
29 Tentorium cerebelli
30 Transverse sinus
31 Trigeminal nerve
32 Trochlear nerve
33 Vertebral artery
34 Vestibulocochlear nerve

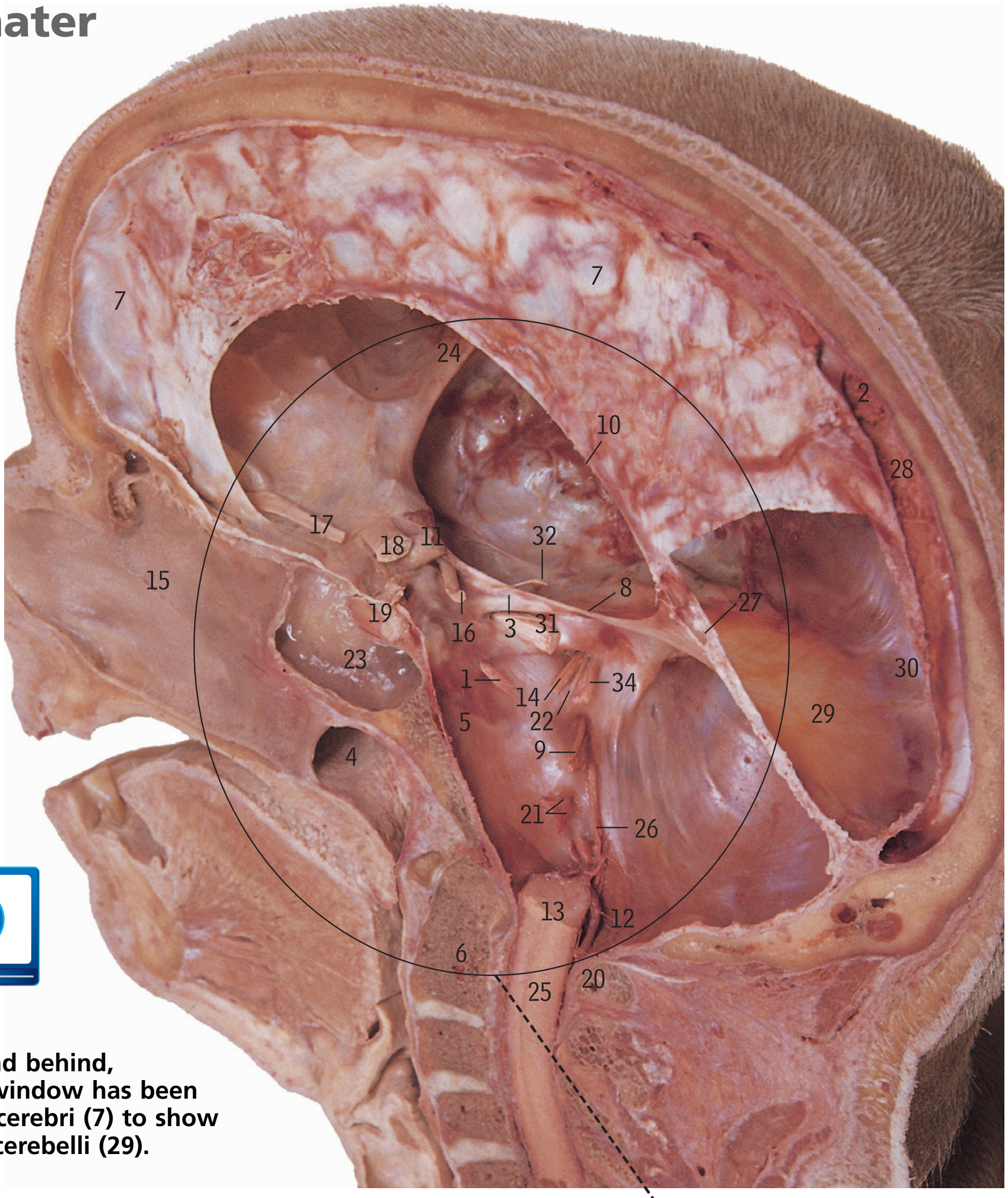

In this oblique view from the left and behind, the brain has been removed and a window has been cut in the posterior part of the falx cerebri (7) to show the upper surface of the tentorium cerebelli (29).

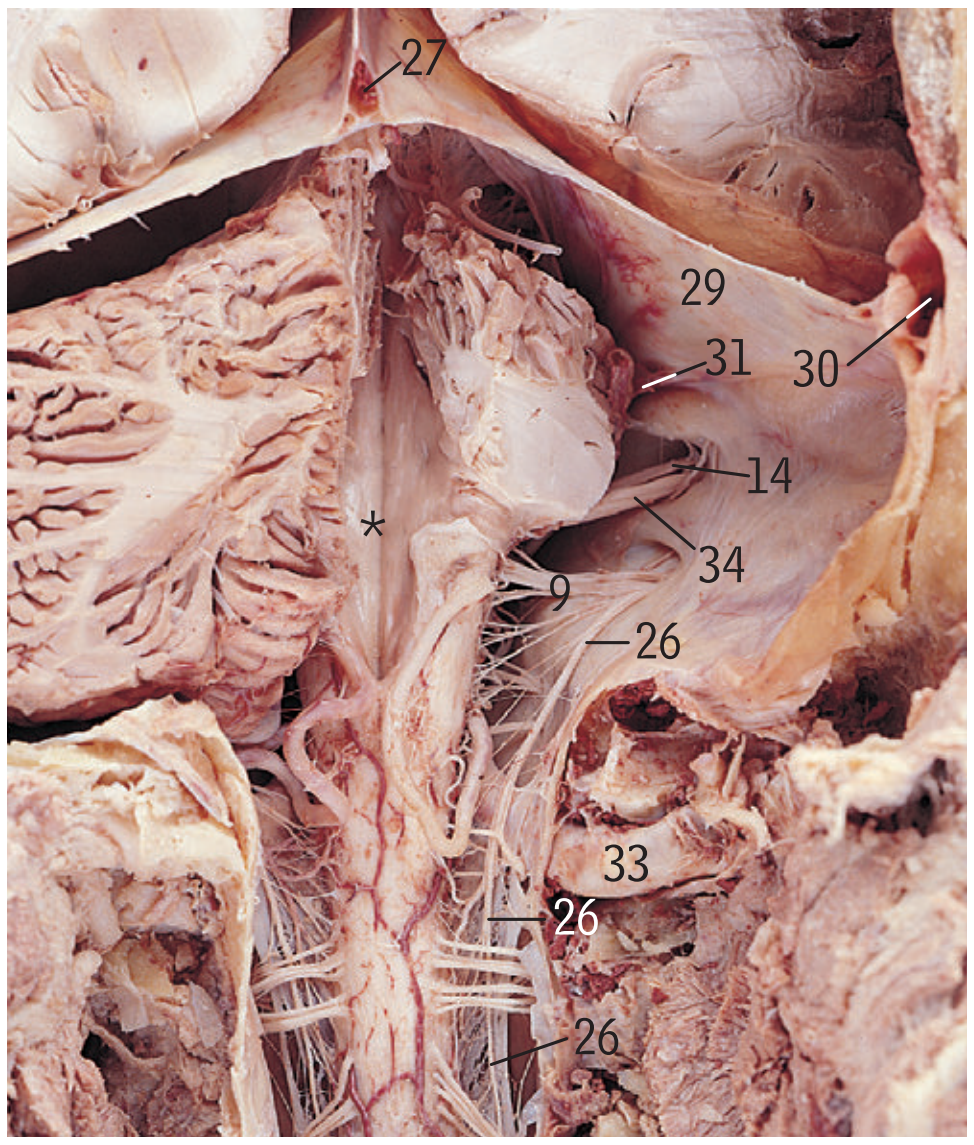

B Right posterior cranial fossa *viewed from behind*

After removal of posterior skull, dura, upper cervical vertebral laminae, all of right cerebellar hemisphere and much of left to expose the floor of the fourth ventricle (asterisk).

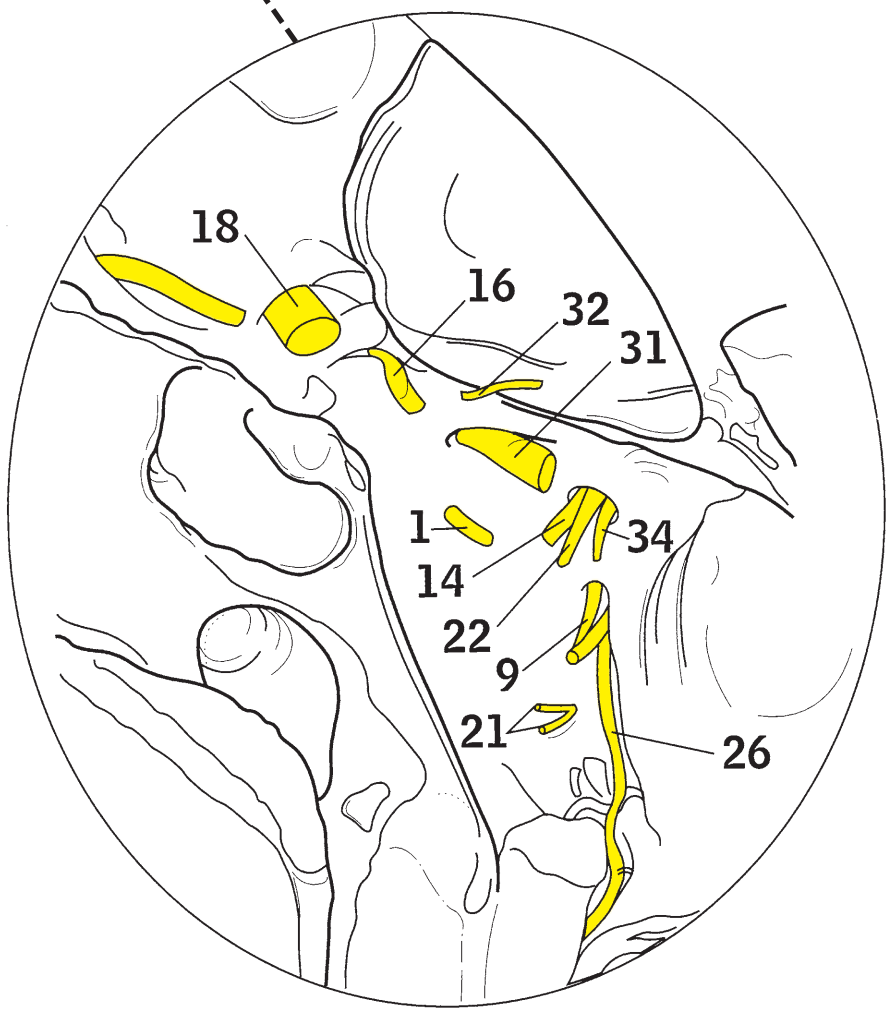

Craniotomy, subdural haemorrhage, see pages 80–82.

Left eye

A *surface features*

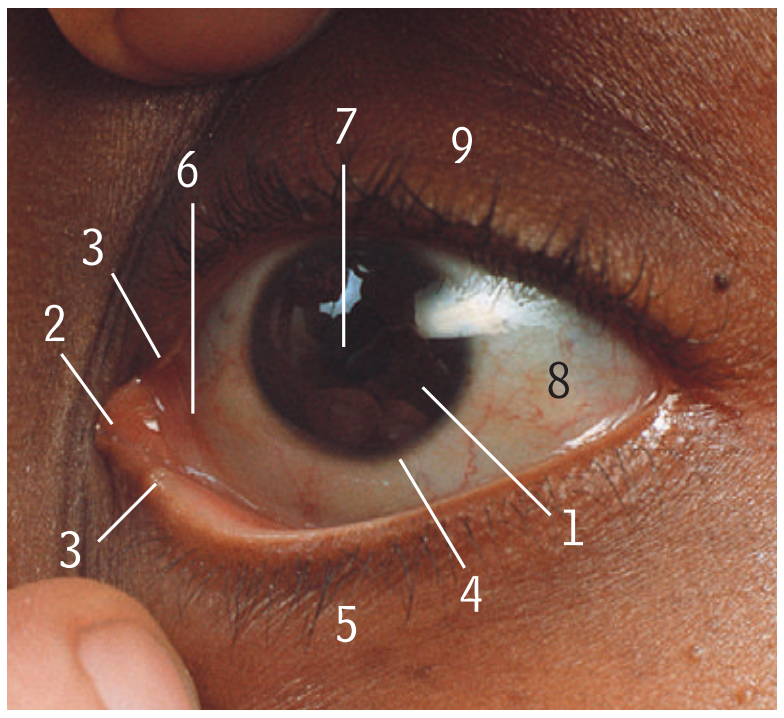

With the eyelids in the normal open position, the lower margin of the upper lid (9) overlaps approximately the upper half of the iris (1); the margin of the lower lid (5) is level with the lower margin of the iris (1).

1. Iris behind cornea
2. Lacrimal caruncle
3. Lacrimal papilla
4. Limbus (corneoscleral junction)
5. Lower lid
6. Plica semilunaris
7. Pupil behind cornea
8. Sclera
9. Upper lid

The cornea is the transparent anterior part of the outer coat of the eyeball and is continuous with the sclera (8) at the limbus (4).

The pupil (7) is the central aperture of the iris (1), the circular pigmented diaphragm that lies in front of the lens.

Each lacrimal papilla (3) contains the lacrimal punctum, the minute opening of the lacrimal canaliculus (B8) which runs medially to open into the lacrimal sac, lying deep to the medial palpebral ligament (B10) and continuing downwards as the nasolacrimal duct (B12) within the nasolacrimal canal.

B Nasolacrimal duct

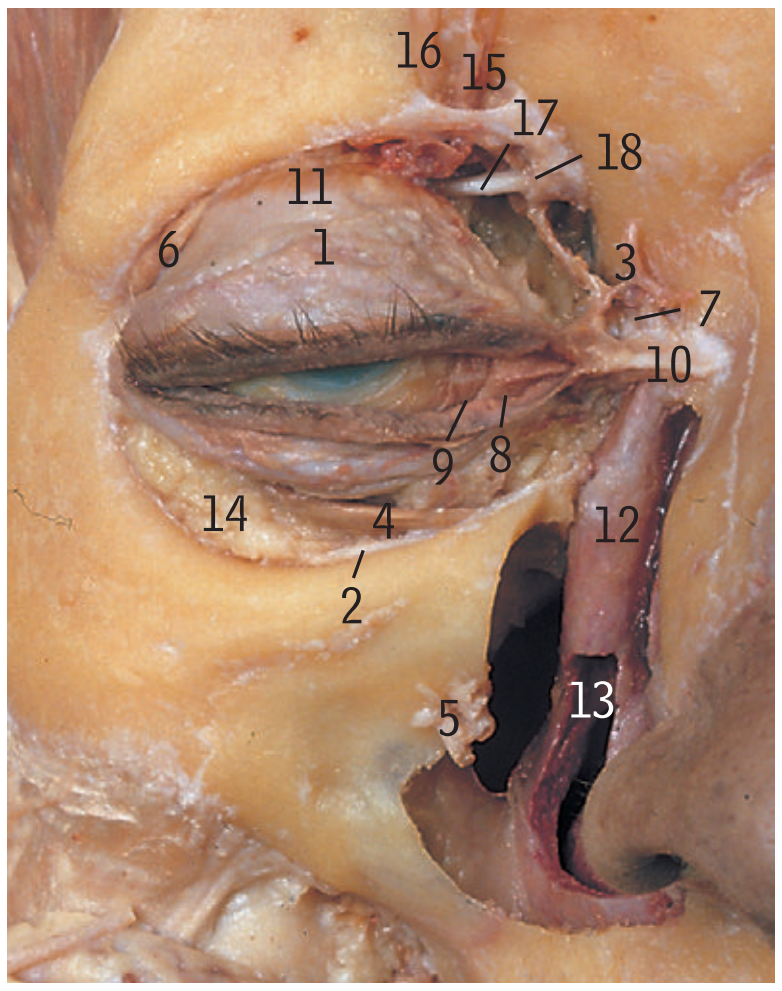

1. Aponeurosis of levator palpebrae superioris
2. Cut edge of orbital septum and periosteum
3. Dorsal nasal artery
4. Inferior oblique
5. Infra-orbital nerve
6. Lacrimal gland
7. Lacrimal sac (upper extremity)
8. Lower lacrimal canaliculus
9. Lower lacrimal papilla and punctum
10. Medial palpebral ligament
11. Muscle fibres of levator palpebrae superioris
12. Nasolacrimal duct
13. Opening of nasolacrimal duct (anterior wall removed) in inferior meatus of nose
14. Orbital fat pad
15. Supra-orbital artery
16. Supra-orbital nerve
17. Tendon of superior oblique
18. Trochlea

In B, the facial muscles and part of the skull have been dissected away to display the nasolacrimal duct (12) opening into the inferior meatus of the nose (13).

C Macrodacryocystogram

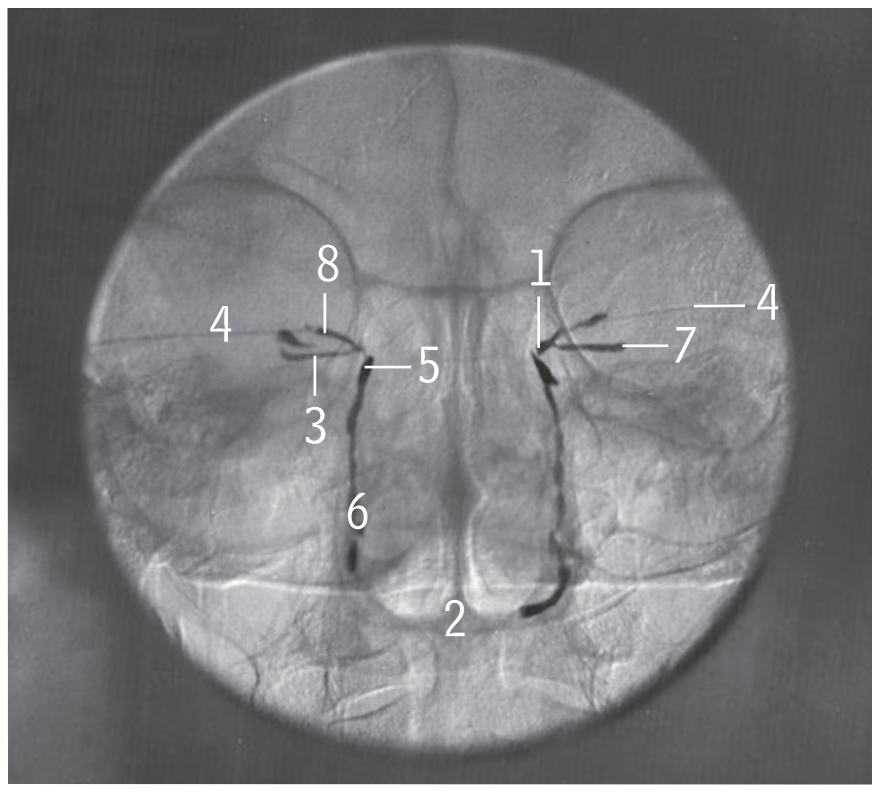

1. Common canaliculus
2. Hard palate
3. Inferior canaliculus
4. Lacrimal catheters
5. Lacrimal sac
6. Nasolacrimal duct
7. Site of lacrimal punctum
8. Superior canaliculus

D Orbits *from above*

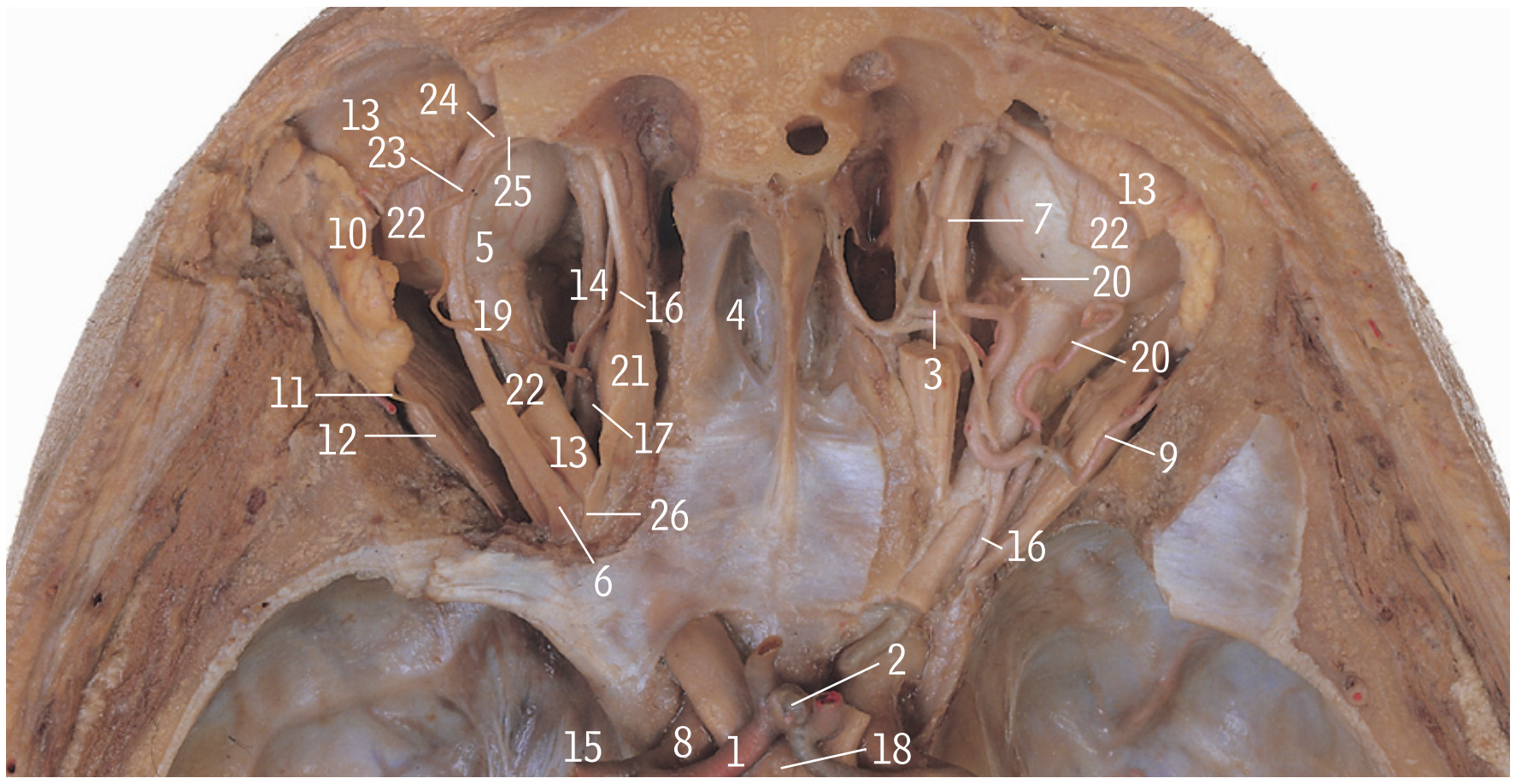

1. Anterior cerebral artery
2. Anterior communicating artery
3. Anterior ethmoidal artery and nerve
4. Cribriform plate of ethmoid bone
5. Eyeball
6. Frontal nerve
7. Infratrochlear nerve and ophthalmic artery
8. Internal carotid artery
9. Lacrimal artery
10. Lacrimal gland
11. Lacrimal nerve
12. Lateral rectus
13. Levator palpebrae superioris (cut)
14. Medial rectus
15. Middle cerebral artery
16. Nasociliary nerve
17. Ophthalmic artery
18. Optic chiasma
19. Optic nerve (with overlying short ciliary nerves in left orbit)
20. Posterior ciliary artery
21. Superior oblique
22. Superior rectus (cut)
23. Supra-orbital artery
24. Supra-orbital nerve
25. Supratrochlear nerve
26. Trochlear nerve

Central retinal artery occlusion, corneal arcus, corneal reflex, meibomian cyst, ophthalmoscopy, pupillary reflex, see *pages 80–82*.

Internal view left orbit

A medial wall view

MEDIAL

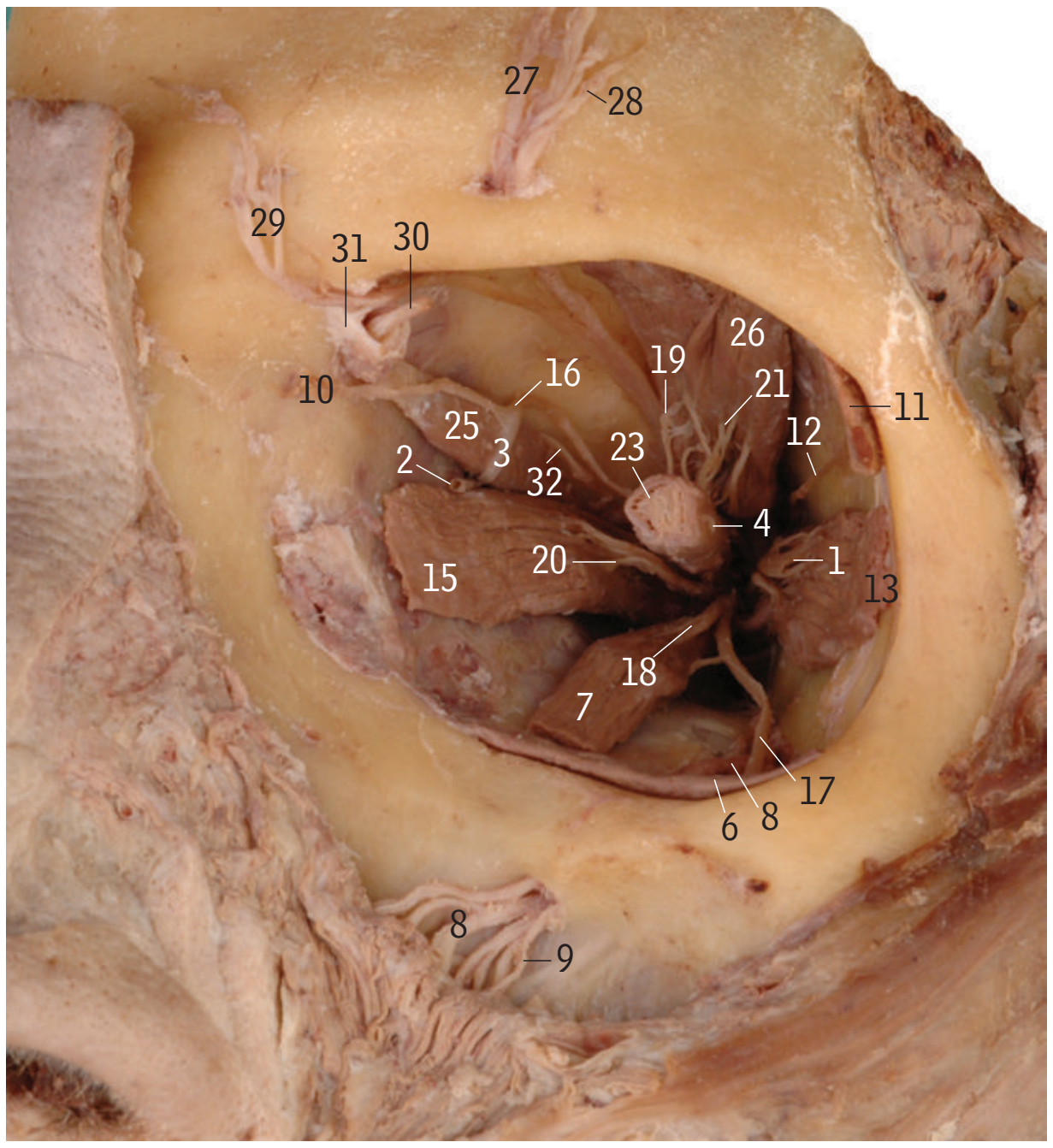

LATERAL

B lateral wall view

MEDIAL

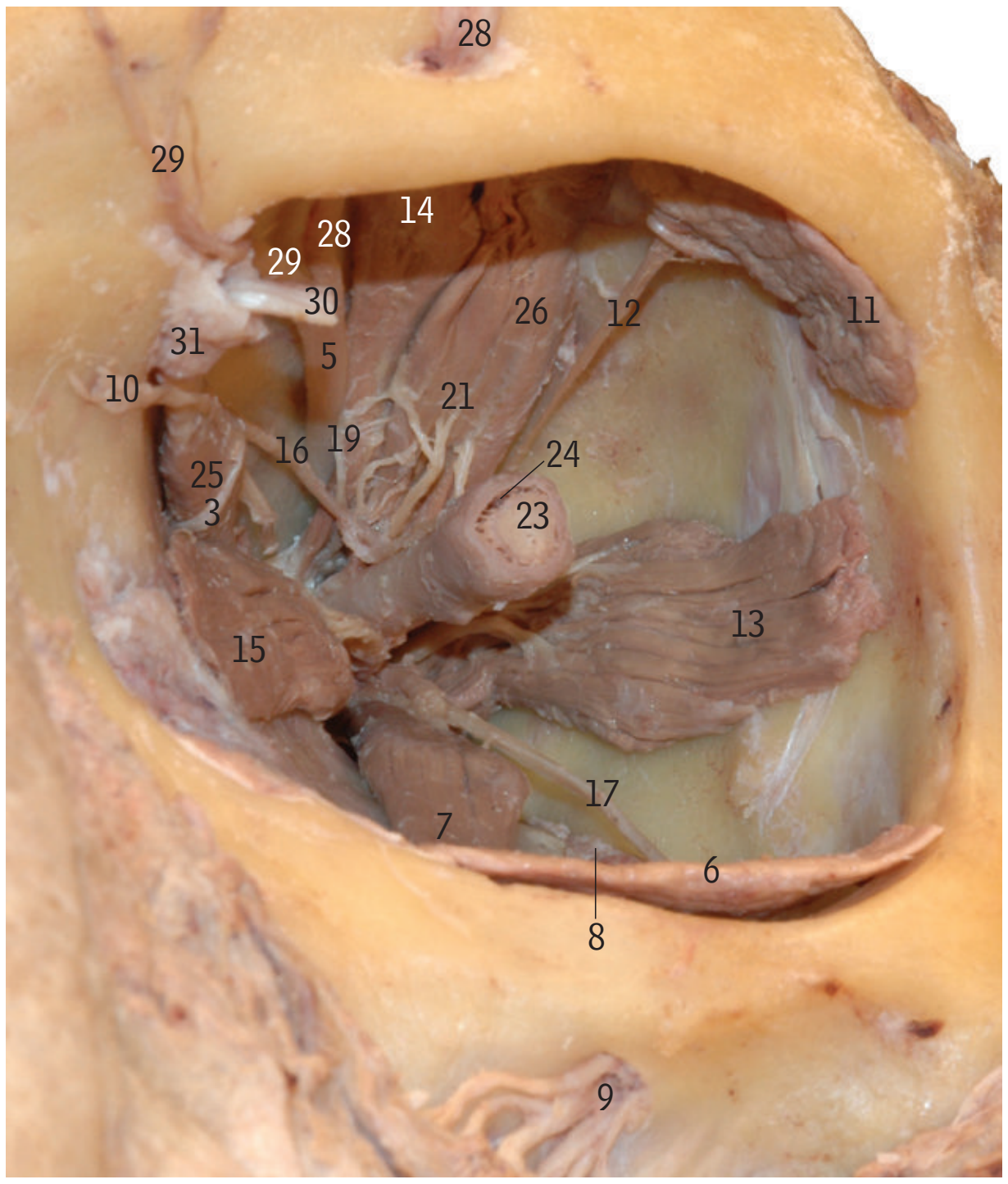

LATERAL

C frontal view

MEDIAL

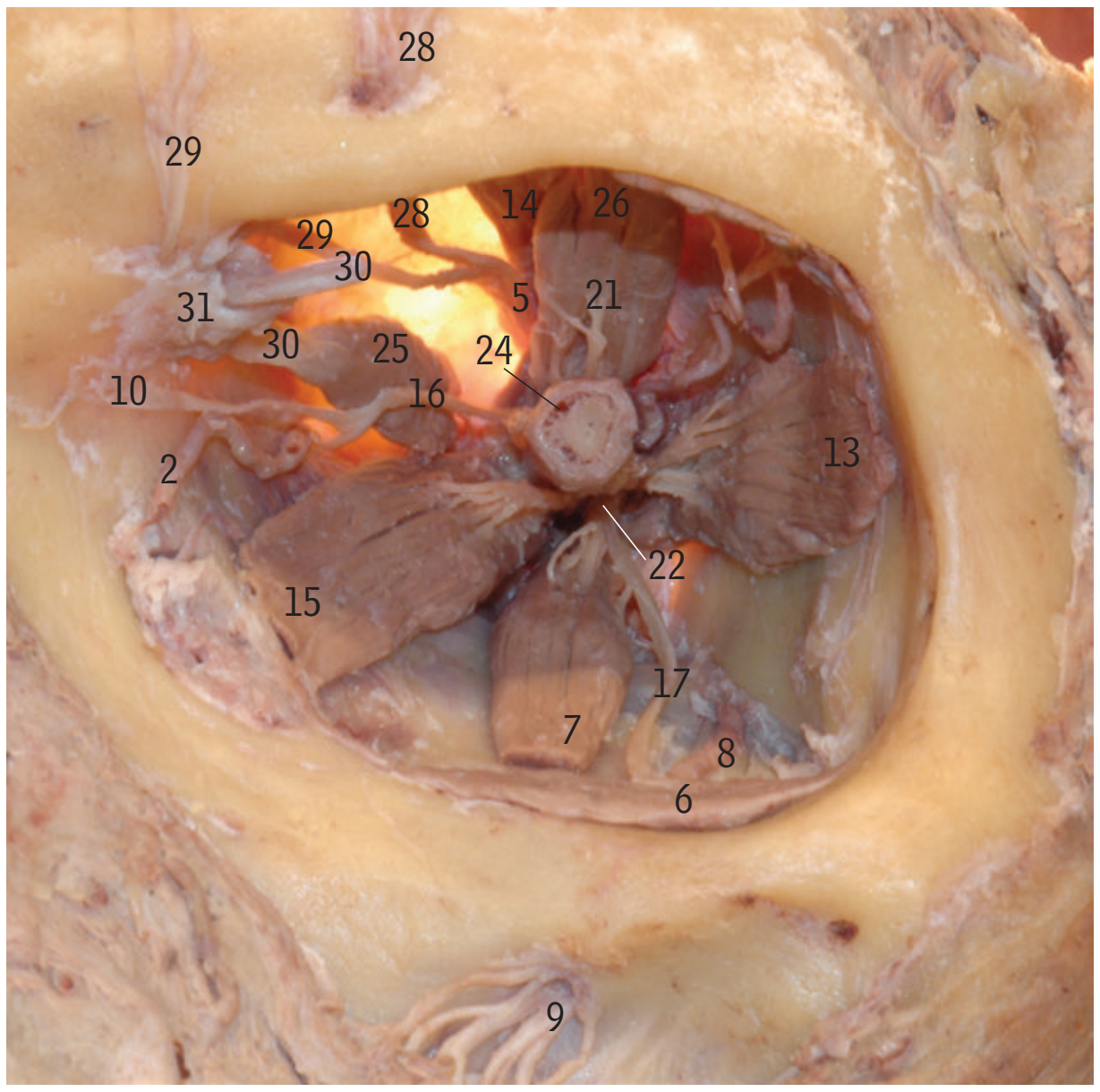

LATERAL

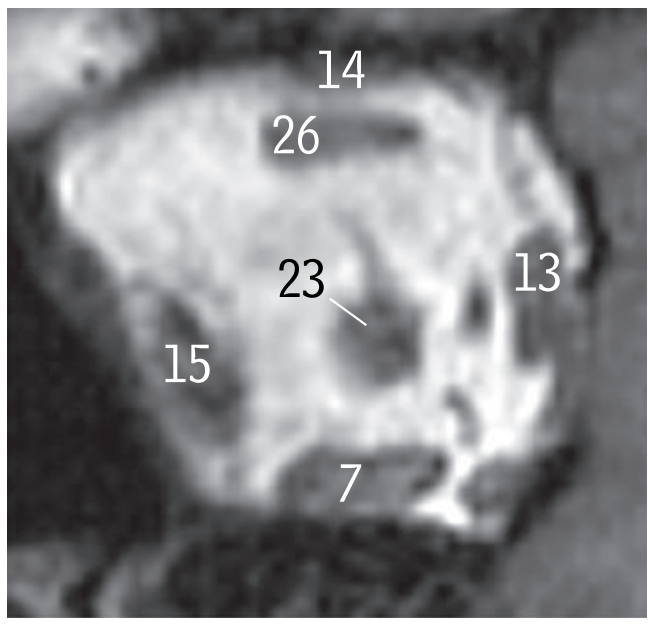

1 Abducent nerve
2 Anterior ethmoidal artery
3 Anterior ethmoidal nerve
4 Dural sheath of optic nerve
5 Frontal nerve
6 Inferior oblique
7 Inferior rectus
8 Infra-orbital artery
9 Infra-orbital nerve
10 Infratrochlear nerve
11 Lacrimal gland
12 Lacrimal nerve
13 Lateral rectus
14 Levator palpebrae superioris
15 Medial rectus
16 Nasociliary nerve
17 Nerve to inferior oblique
18 Nerve to inferior rectus
19 Nerve to levator palpebrae superioris
20 Nerve to medial rectus
21 Nerve to superior rectus
22 Oculomotor nerve
23 Optic nerve surrounding central artery of retina
24 Subarachnoid space
25 Superior oblique
26 Superior rectus
27 Supra-orbital artery
28 Supra-orbital nerve
29 Supratrochlear nerve
30 Tendon of superior oblique
31 Trochlea
32 Trochlear nerve

Meibomian cyst, periorbital and subconjunctival haemorrhage, glaucoma, see pages 80–82.

Superior view of right orbit

A superficial

ANTERIOR

MEDIAL

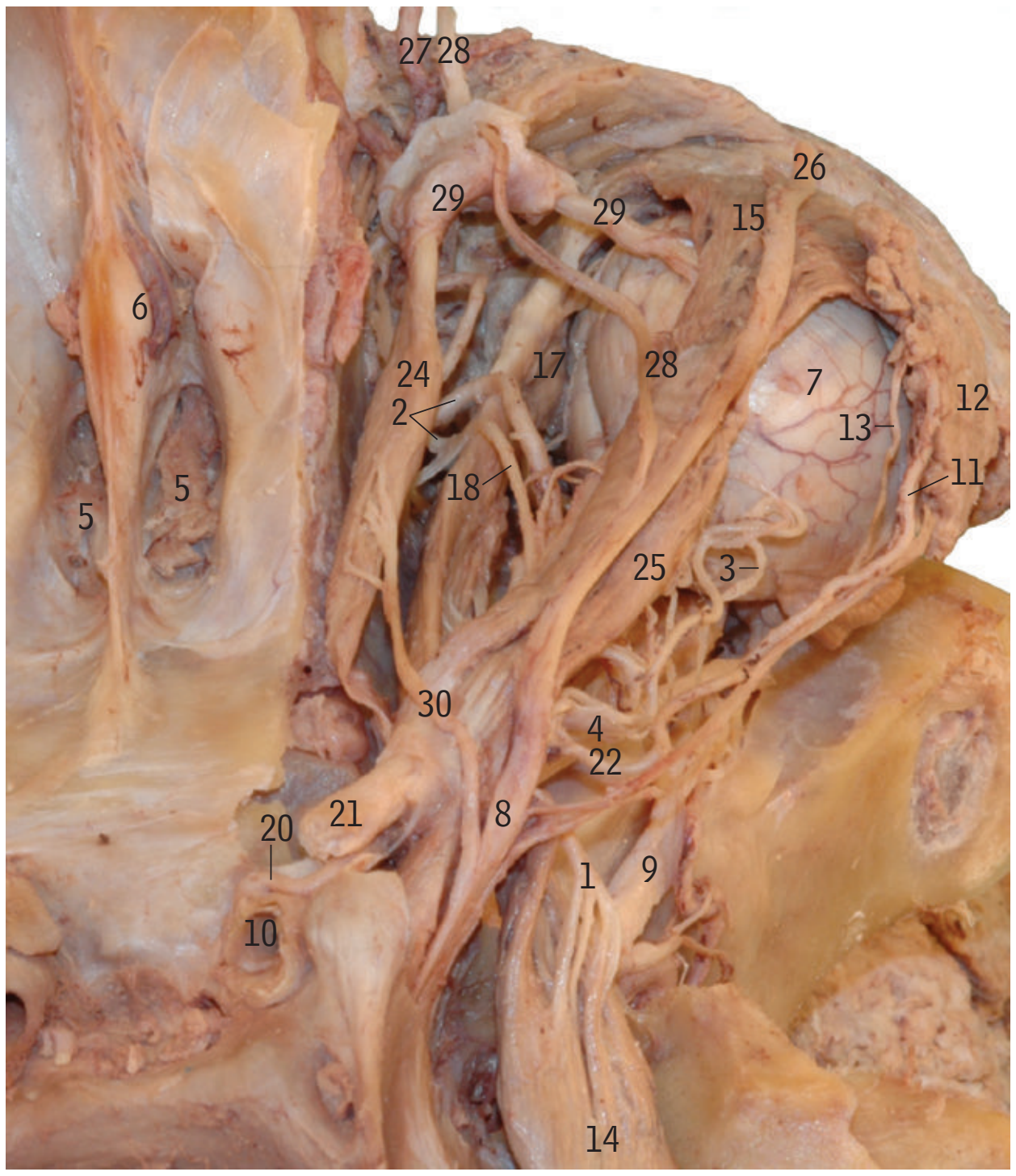

LATERAL

B deep, with muscle reflection

ANTERIOR

MEDIAL

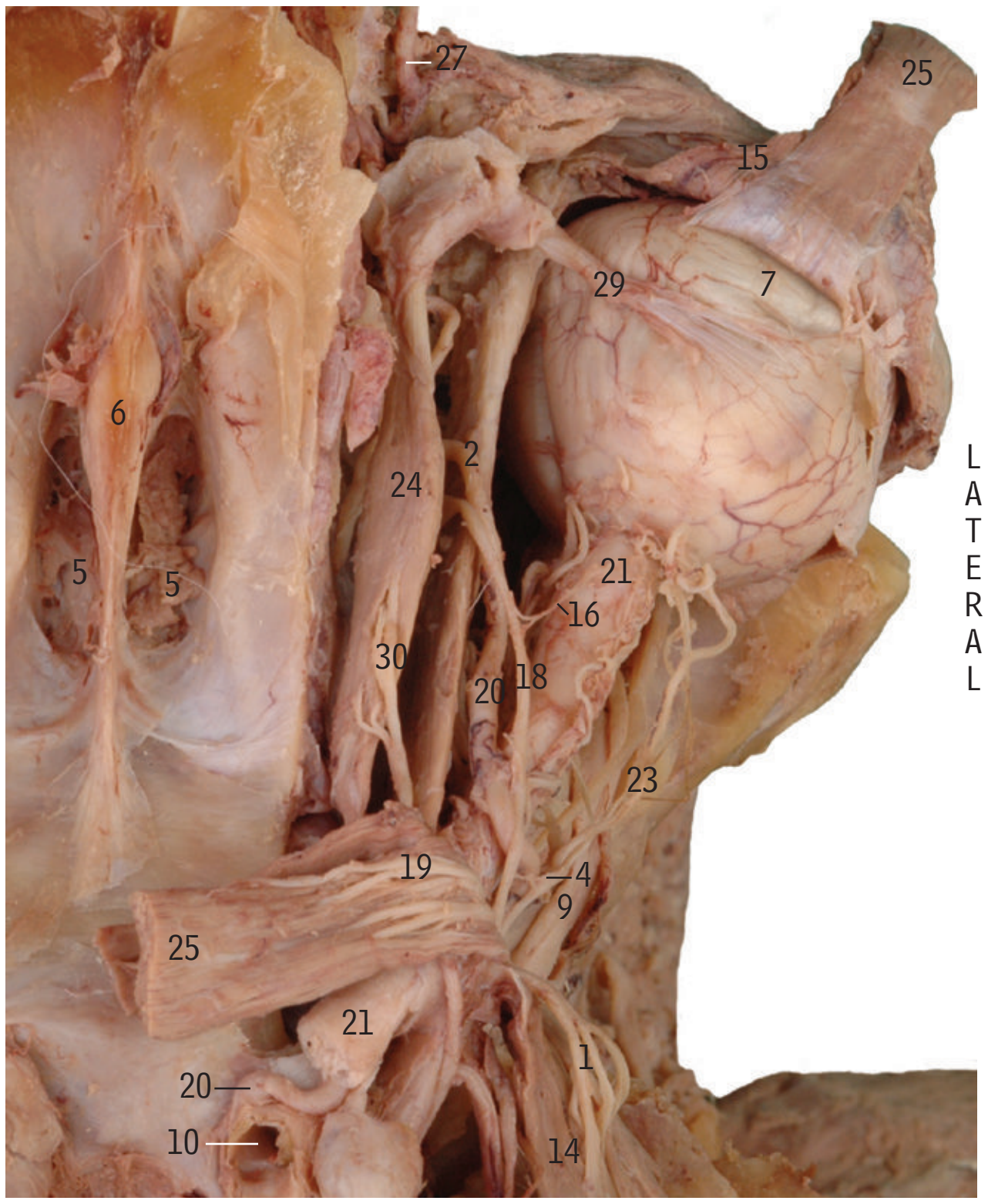

LATERAL

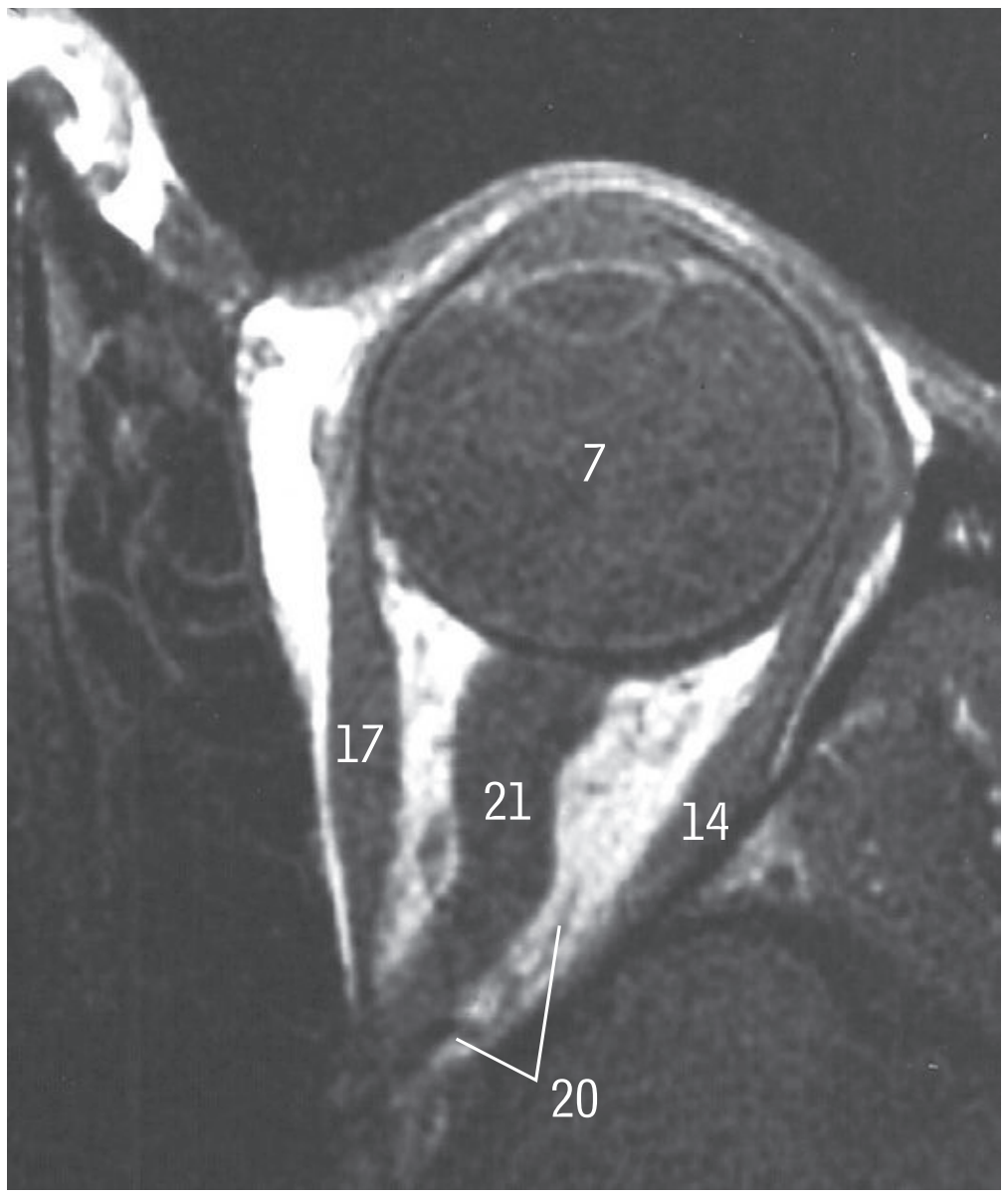

1 Abducent nerve
2 Anterior ethmoidal artery and nerve
3 Ciliary arteries
4 Ciliary ganglion
5 Cribriform plate of ethmoid bone
6 Crista galli
7 Eyeball
8 Frontal nerve
9 Infra-orbital nerve
10 Internal carotid artery
11 Lacrimal artery
12 Lacrimal gland
13 Lacrimal nerve
14 Lateral rectus (reflected)
15 Levator palpebrae superioris
16 Long ciliary nerve
17 Medial rectus
18 Nasociliary nerve
19 Nerve to superior rectus
20 Ophthalmic artery
21 Optic nerve
22 Posterior ciliary artery
23 Short ciliary nerves
24 Superior oblique
25 Superior rectus
26 Supra-orbital nerve
27 Supratrochlear artery
28 Supratrochlear nerve
29 Tendon of superior oblique
30 Trochlear nerve

Abducent nerve palsy, oculomotor nerve palsy, orbital cellulitis, trochlear nerve palsy, see pages 80–82.

Lateral view of right orbit

A *superficial* B *deep*

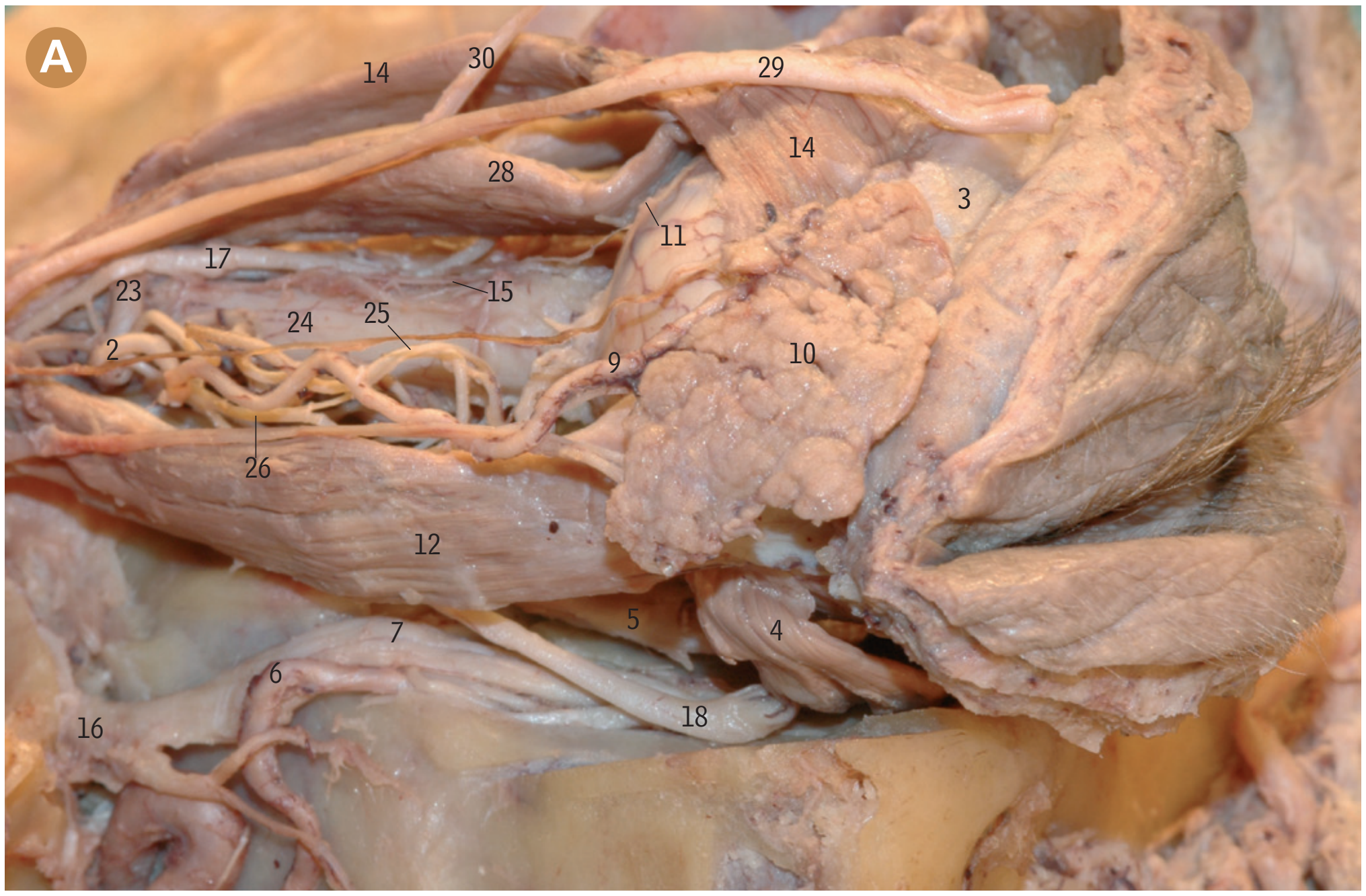

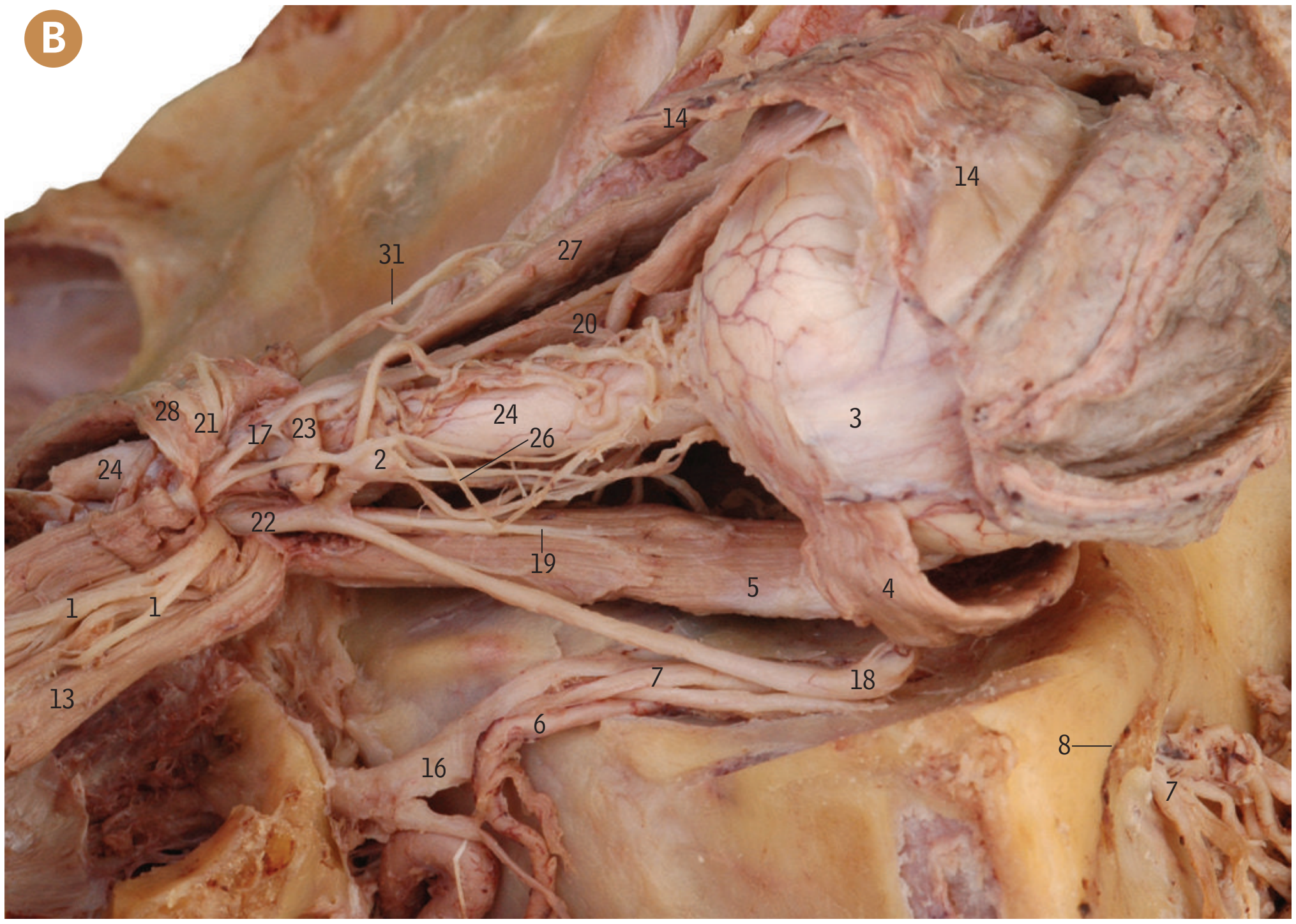

1 Abducent nerve
2 Ciliary ganglion
3 Eyeball
4 Inferior oblique
5 Inferior rectus
6 Infra-orbital artery
7 Infra-orbital nerve
8 Infra-orbital foramen
9 Lacrimal artery
10 Lacrimal gland
11 Lacrimal nerve
12 Lateral rectus
13 Lateral rectus (reflected backwards)
14 Levator palpebrae superioris
15 Long ciliary nerve
16 Maxillary branch of trigeminal nerve
17 Nasociliary nerve
18 Nerve to inferior oblique
19 Nerve to inferior rectus
20 Nerve to medial rectus
21 Nerve to superior rectus
22 Oculomotor nerve, inferior division
23 Ophthalmic artery
24 Optic nerve
25 Short ciliary artery
26 Short ciliary nerves
27 Superior oblique
28 Superior rectus
29 Supra-orbital nerve
30 Supratrochlear nerve
31 Trochlear nerve

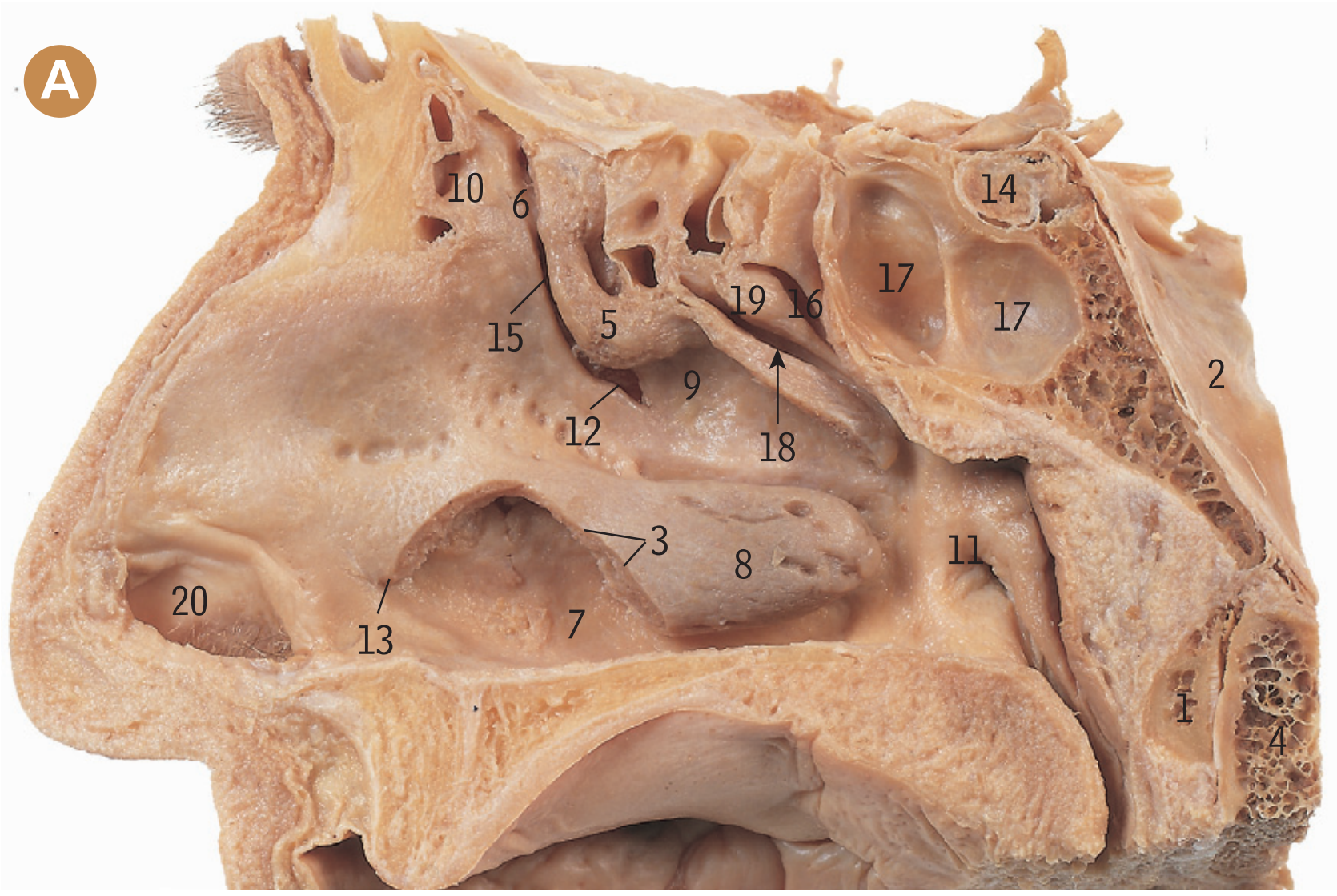

A Lateral wall of the right nasal cavity

1 Anterior arch of atlas
2 Clivus
3 Cut edge of inferior nasal concha
4 Dens of axis
5 Ethmoidal bulla
6 Ethmoidal infundibulum
7 Inferior meatus
8 Inferior nasal concha
9 Middle meatus
10 Opening of anterior ethmoidal air cells
11 Opening of auditory tube
12 Opening of maxillary sinus
13 Opening of nasolacrimal duct
14 Pituitary gland
15 Semilunar hiatus
16 Sphenoethmoidal recess
17 Sphenoidal sinus
18 Superior meatus
19 Superior nasal concha
20 Vestibule

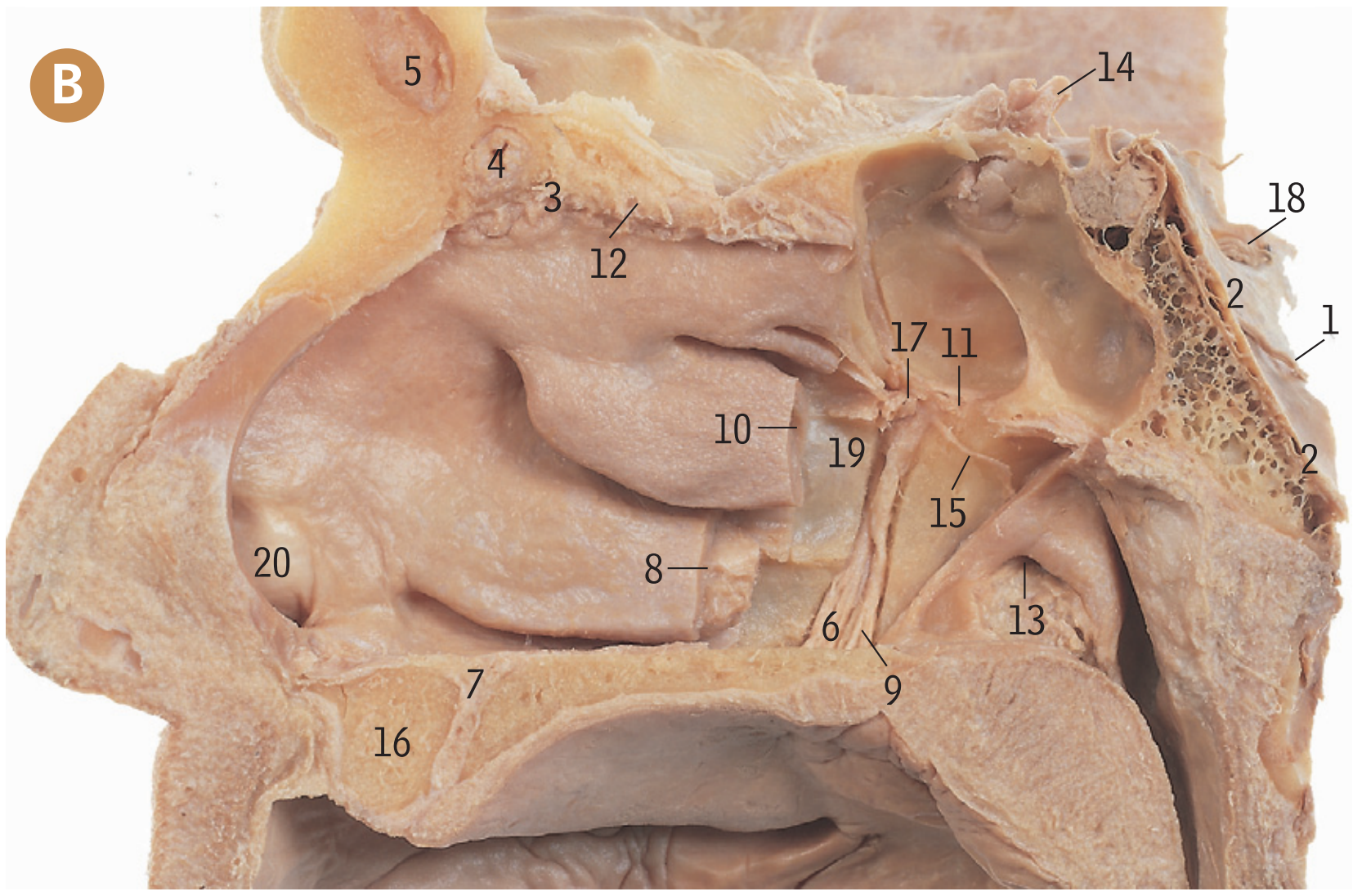

B Right nasal cavity and pterygopalatine ganglion
from the left

1 Abducent nerve
2 Clivus
3 Cribriform plate of ethmoid
4 Ethmoidal air cell (anterior)
5 Frontal sinus
6 Greater palatine nerve
7 Incisive foramen
8 Inferior nasal concha, cut edge of mucoperiosteum
9 Lesser palatine nerves
10 Middle nasal concha, cut
11 Nerve of pterygoid canal
12 Olfactory nerve fibres
13 Opening of auditory tube
14 Optic nerve
15 Pharyngeal branch to ganglion
16 Premaxilla
17 Pterygopalatine ganglion
18 Trigeminal nerve
19 Vertical plate of palatine bone
20 Vestibule

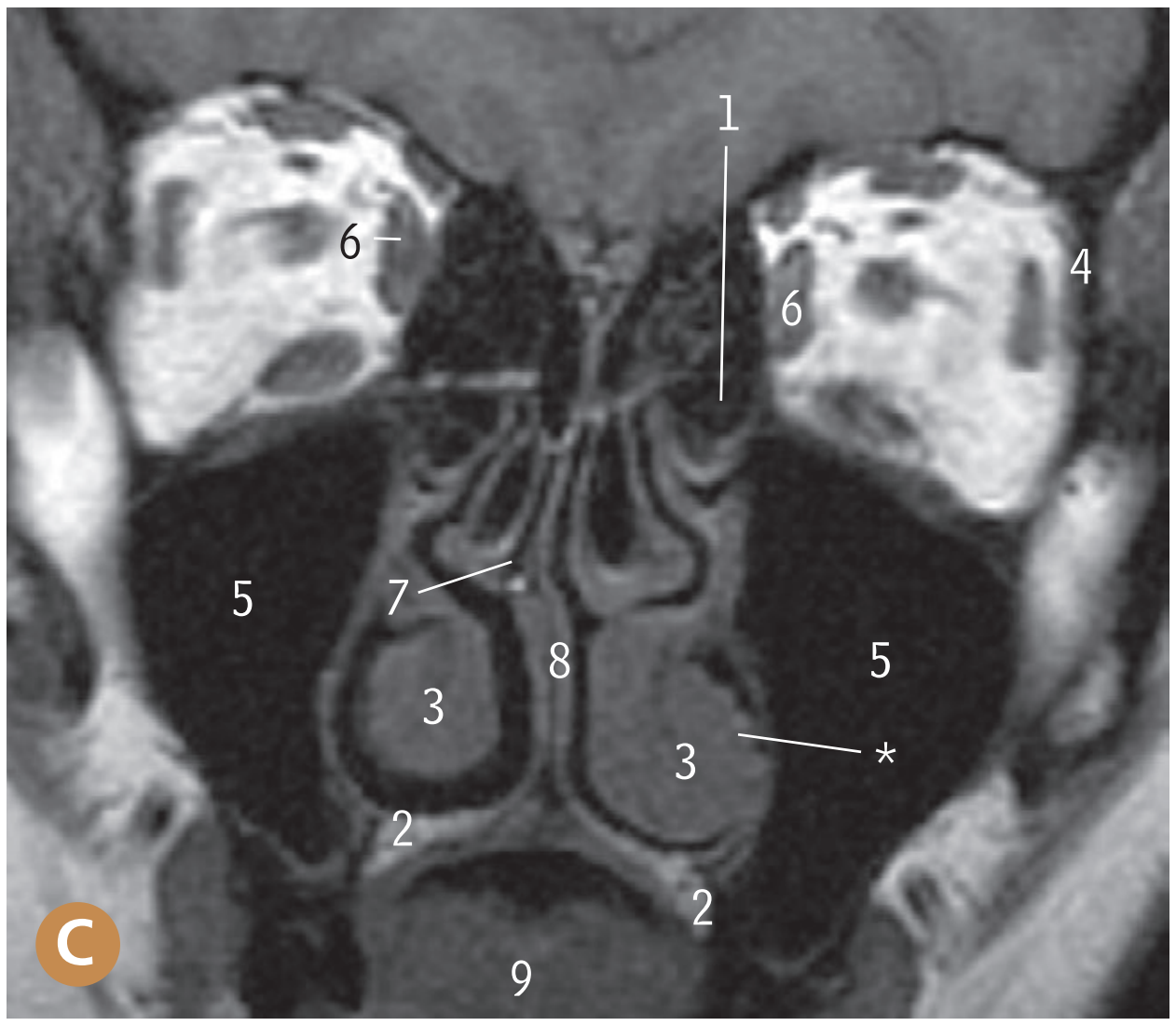

*NB: This is a variant concha bullosa

C Face
coronal MR image

1 Ethmoid air cells
2 Hard palate
3 Inferior concha
4 Lacrimal gland
5 Maxillary sinus
6 Medial rectus muscle
7 Middle meatus
8 Nasal septum
9 Tongue

Middle ear pressure equalisation, nasal polyps, nasogastric intubation, see pages 80–82.

Right trigeminal nerve branches *from the midline*

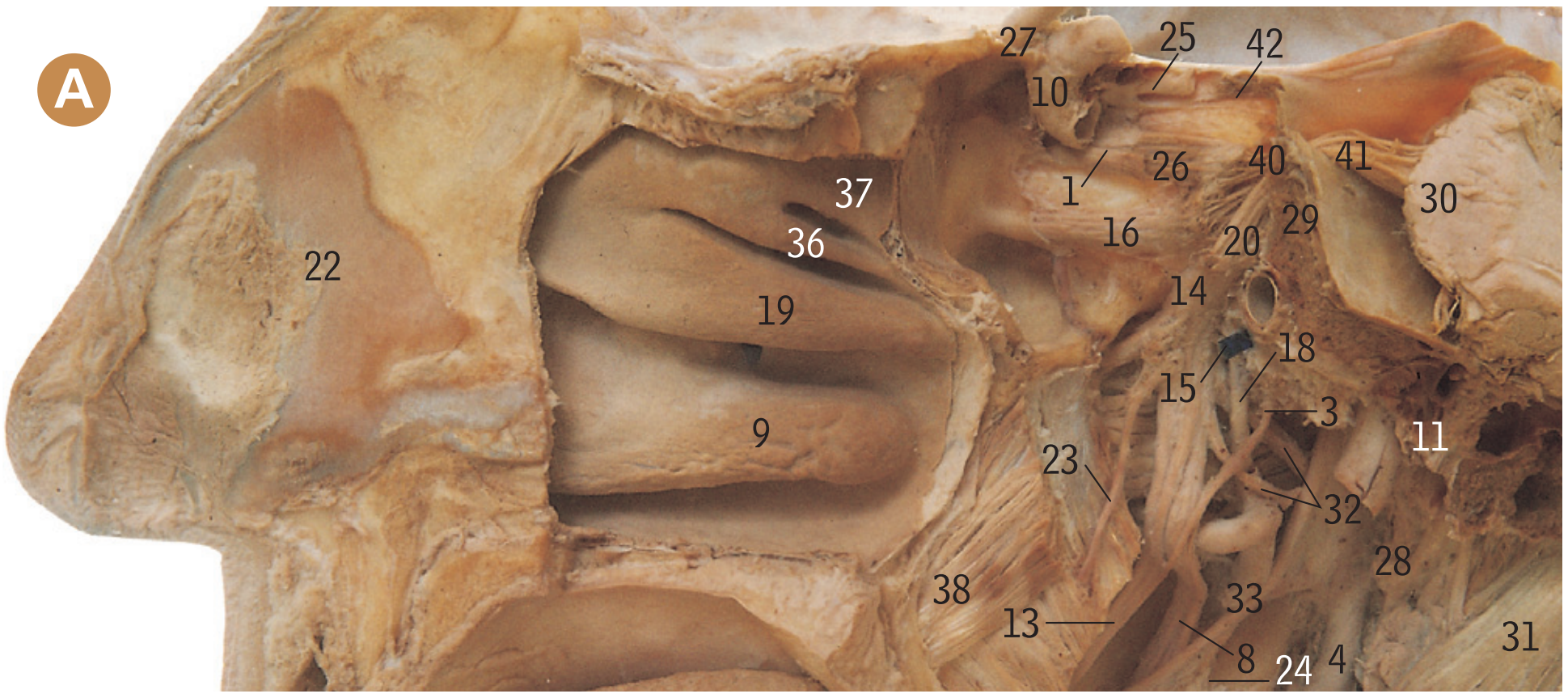

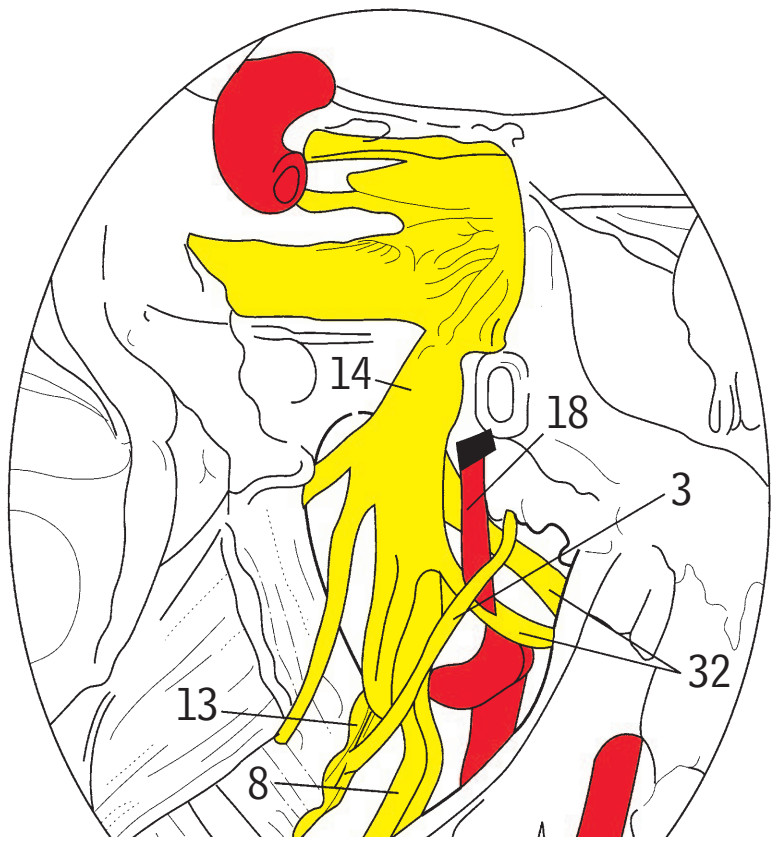

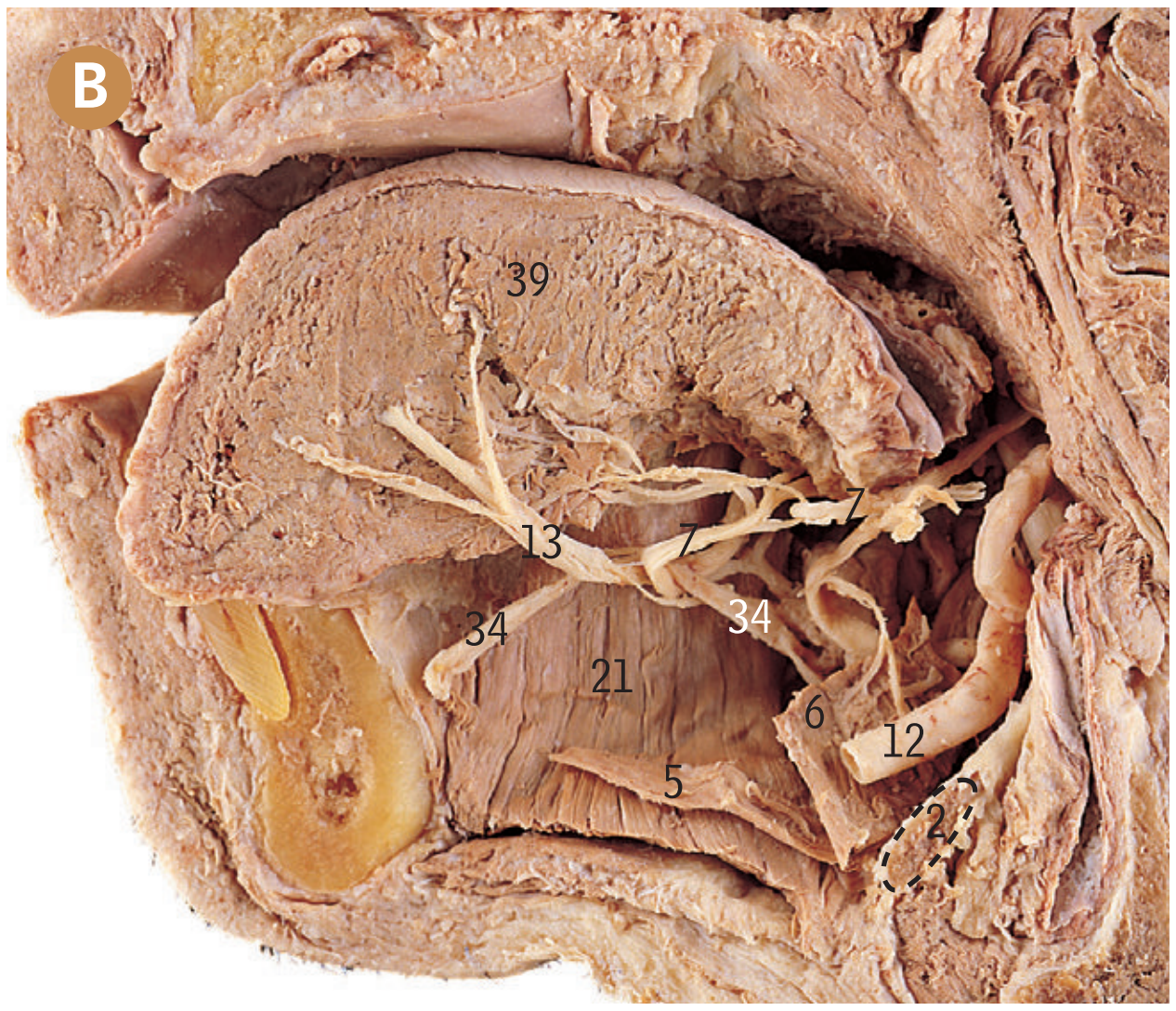

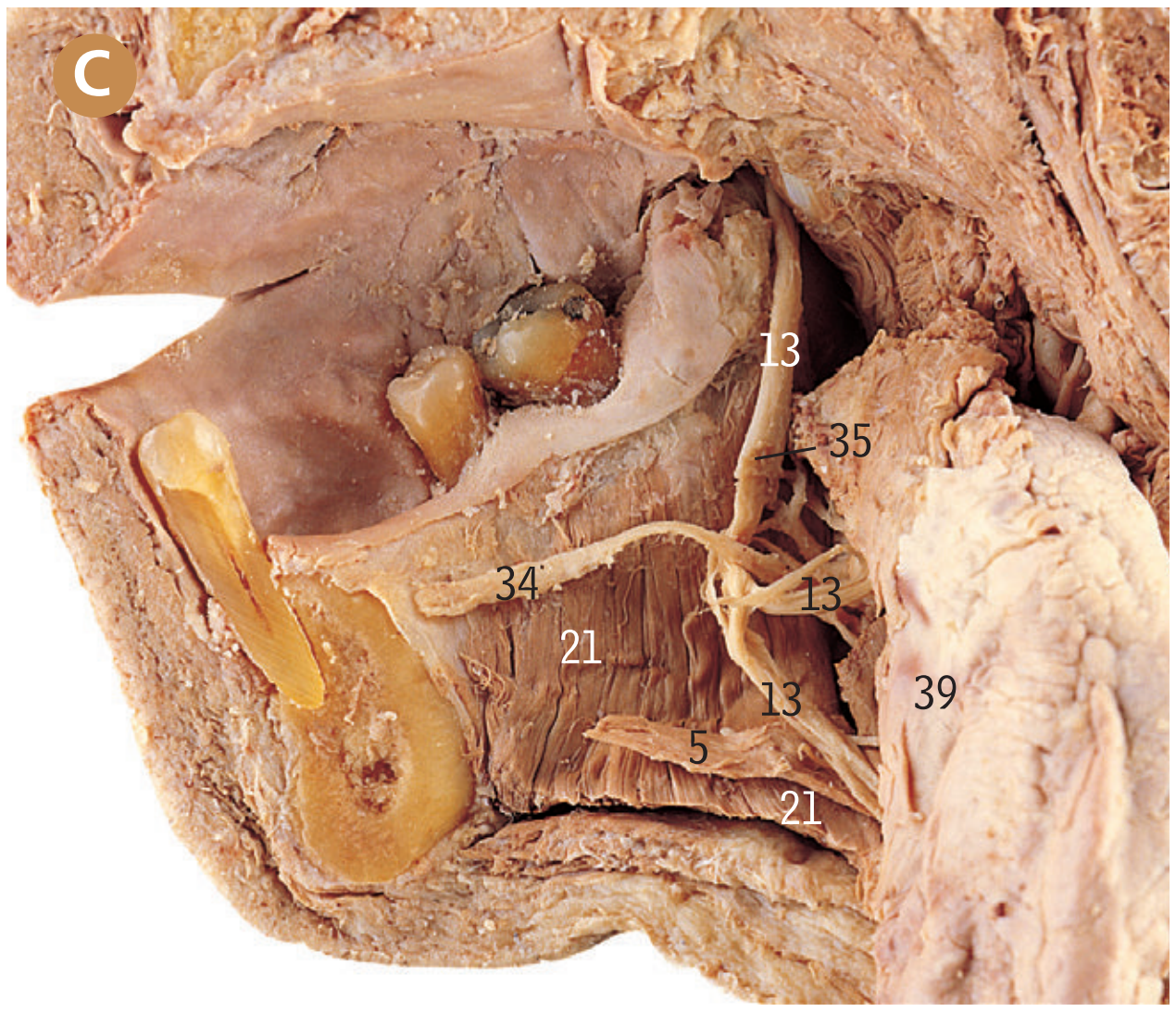

A **sagittal section just left of midline**

B **C** **sagittal sections just right of the midline after removal of geniohyoid muscle, sublingual gland and oral mucosa. Tongue reflected medially in C.**

1 Abducent nerve
2 Body of hyoid bone
3 Chorda tympani
4 External carotid artery
5 Geniohyoid
6 Hyoglossus
7 Hypoglossal nerve
8 Inferior alveolar nerve
9 Inferior nasal concha
10 Internal carotid artery
11 Jugular bulb
12 Lingual artery
13 Lingual nerve
14 Mandibular branch of trigeminal nerve
15 Marker in auditory tube
16 Maxillary branch of trigeminal nerve
17 Medial pterygoid
18 Middle meningeal artery
19 Middle nasal concha
20 Motor root of trigeminal nerve
21 Mylohyoid
22 Nasal septum (cartilaginous part)
23 Nerve to medial pterygoid
24 Nerve to mylohyoid
25 Oculomotor nerve
26 Ophthalmic branch of trigeminal nerve
27 Optic nerve
28 Parotid gland
29 Petrous part of temporal bone
30 Pons
31 Posterior belly of digastric
32 Roots of auriculotemporal nerve
33 Sphenomandibular ligament and maxillary artery
34 Submandibular duct
35 Submandibular ganglion
36 Superior nasal concha
37 Supreme nasal concha
38 Tensor veli palatini
39 Tongue
40 Trigeminal ganglion
41 Trigeminal nerve
42 Trochlear nerve

Hypoglossal nerve palsy, oral pathology, tongue carcinoma, see pages 80–82.

A Right external ear

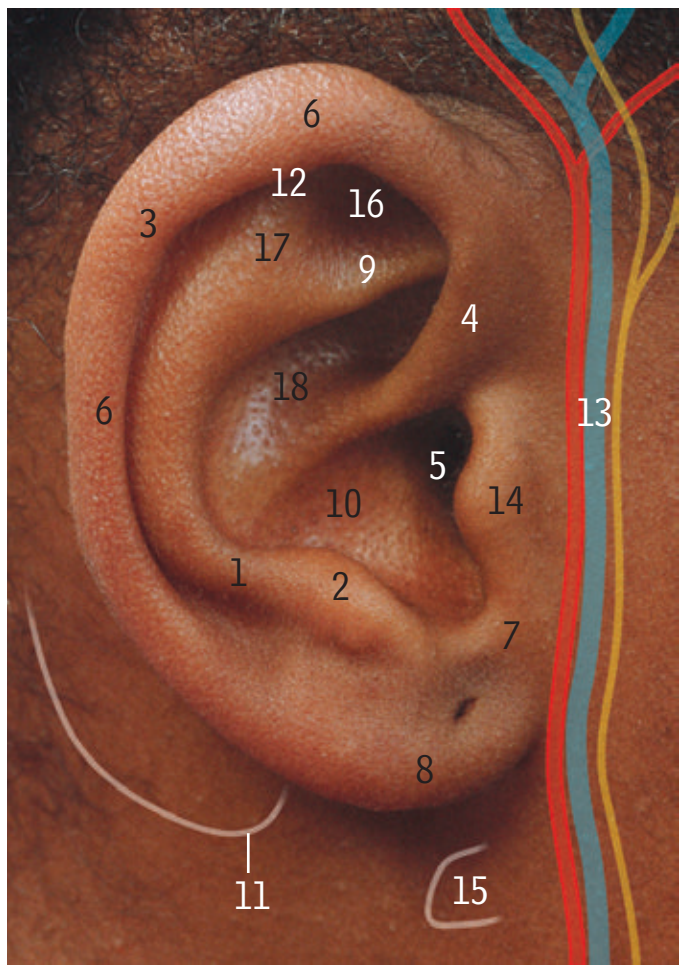

1 Antihelix
2 Antitragus
3 Auricular tubercle
4 Crus of helix
5 External acoustic meatus
6 Helix
7 Intertragic notch
8 Lobule
9 Lower crus of antihelix
10 Lower part of concha
11 Mastoid process
12 Scaphoid fossa
13 Superficial temporal vessels and auriculotemporal nerve
14 Tragus
15 Transverse process of atlas
16 Triangular fossa
17 Upper crus of antihelix
18 Upper part of concha

B Right tympanic membrane *as seen using auriscope*

POSTERIOR

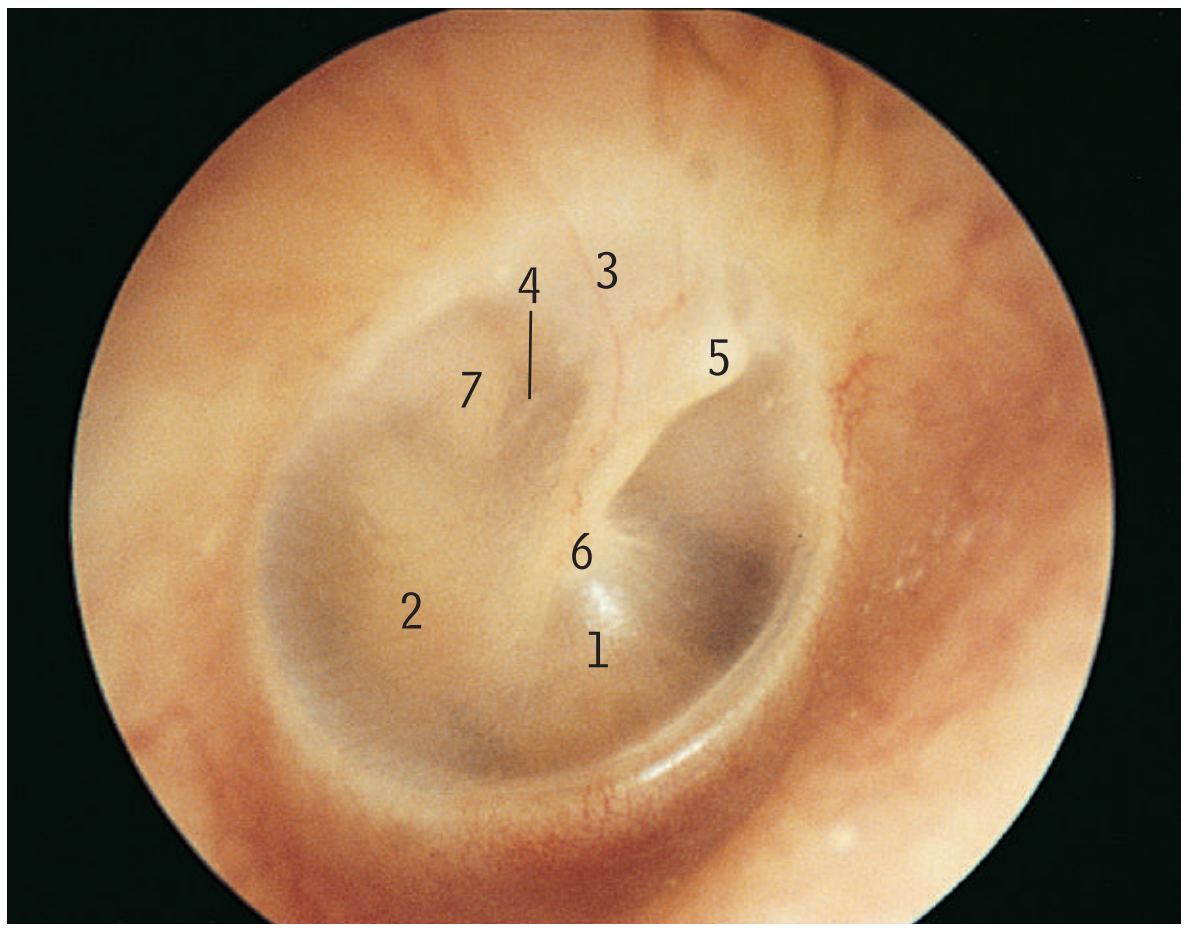

ANTERIOR

1 Cone of light (light reflex)
2 Pars tensa
3 Pars flaccida
4 Chorda tympani
5 Malleus, lateral process
6 Umbo
7 Incus, long process

C Right temporal bone and ear

The bone has been bisected and opened out like a book, with some removal of the upper part of the petrous part. The section has opened up the tympanic (middle ear) cavity. On the left side of the figure the lateral wall of the middle ear, which includes the tympanic membrane (26), is seen from the medial side, while on the right the main features of the medial wall are in view.

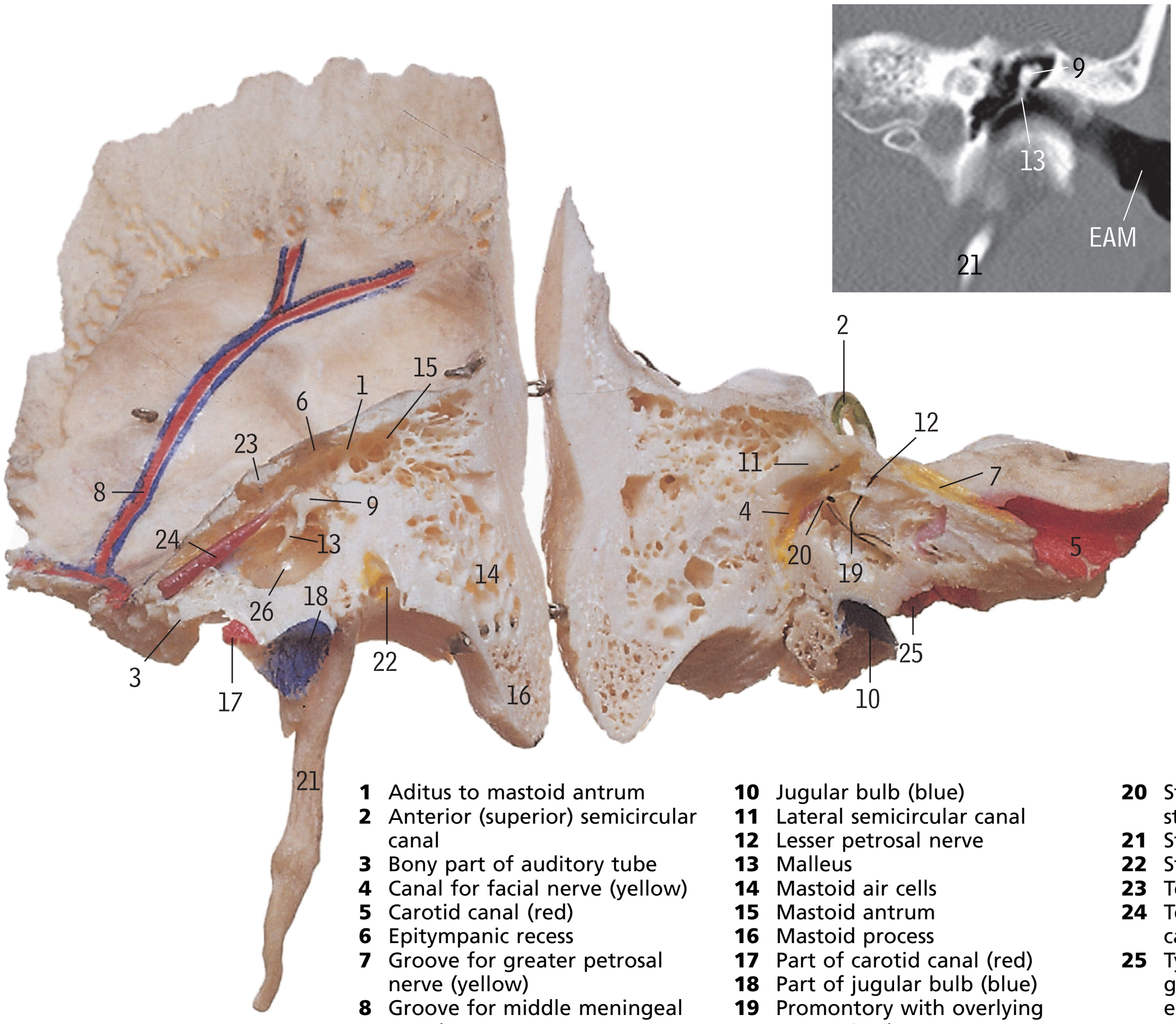

1 Aditus to mastoid antrum
2 Anterior (superior) semicircular canal
3 Bony part of auditory tube
4 Canal for facial nerve (yellow)
5 Carotid canal (red)
6 Epitympanic recess
7 Groove for greater petrosal nerve (yellow)
8 Groove for middle meningeal vessels
9 Incus
10 Jugular bulb (blue)
11 Lateral semicircular canal
12 Lesser petrosal nerve
13 Malleus
14 Mastoid air cells
15 Mastoid antrum
16 Mastoid process
17 Part of carotid canal (red)
18 Part of jugular bulb (blue)
19 Promontory with overlying tympanic plexus
20 Stapes in oval window and stapedius muscle
21 Styloid process
22 Stylomastoid foramen
23 Tegmen tympani
24 Tensor tympani muscle in its canal
25 Tympanic branch of glossopharyngeal nerve entering its canaliculus
26 Tympanic membrane

Hyperacusis, perforated drum, otalgia (referred pain), see pages 80–82.

Ear *right temporal bone*

A middle ear and the facial nerve and branches

B enlarged view of A

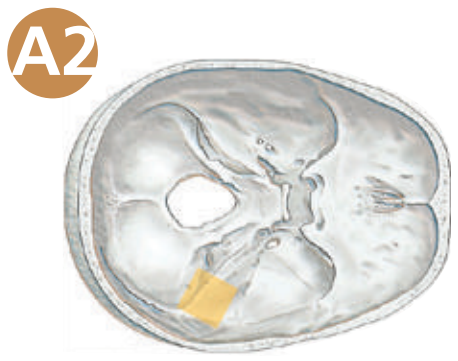

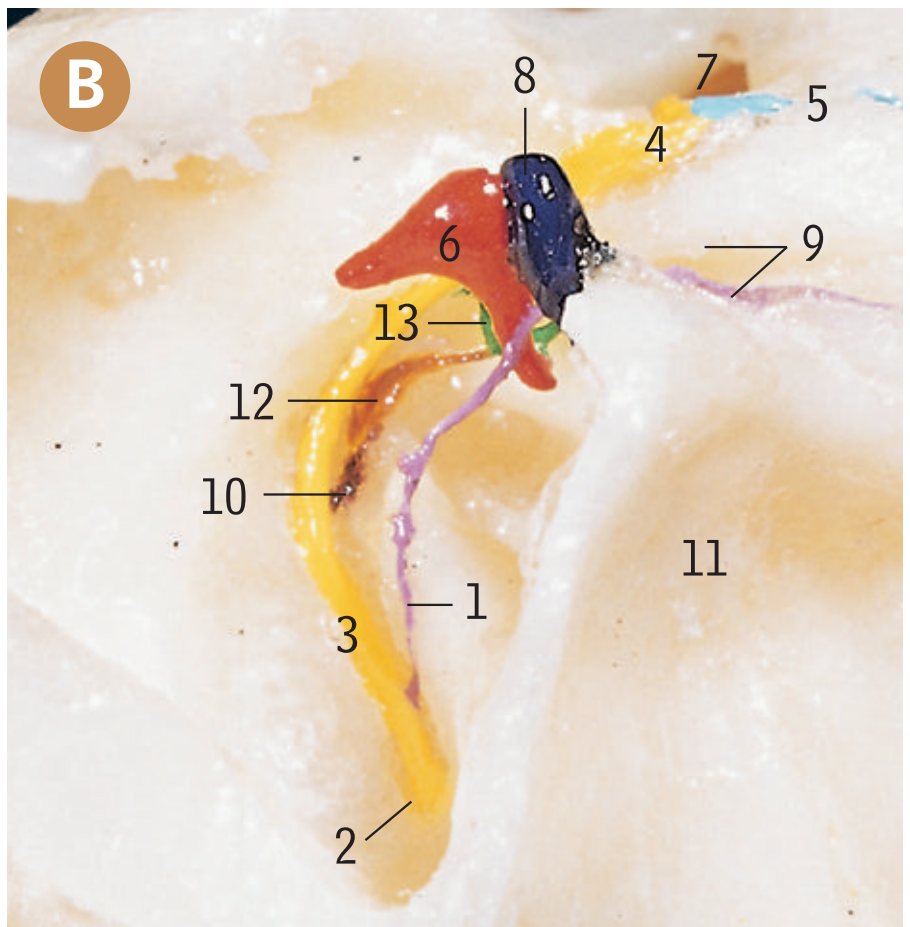

This dissection is seen from the right and above, looking forwards and medially. Bone has been removed to show the upper parts of the malleus (8) and incus (6), which normally project up into the epitympanic recess. The upper part of the facial canal (2) has been opened to show the facial nerve (3) giving off the chorda tympani (1) and the nerve to stapedius (10). The geniculate ganglion of the facial nerve (4) is seen giving off the greater petrosal nerve (5).

1 Chorda tympani
2 Facial canal leading to stylomastoid foramen
3 Facial nerve
4 Geniculate ganglion of facial nerve
5 Greater petrosal nerve
6 Incus
7 Internal acoustic meatus
8 Malleus
9 Margin of auditory tube
10 Nerve to stapedius
11 Paraffin wax (for support) overlying tympanic membrane
12 Stapedius
13 Stapes

> The stapedius (12) tendon emerges from a small conical projection on the posterior wall of the tympanic cavity, the pyramid (here dissected away).

Ear

C right temporal bone; middle ear and inner ear, enlarged

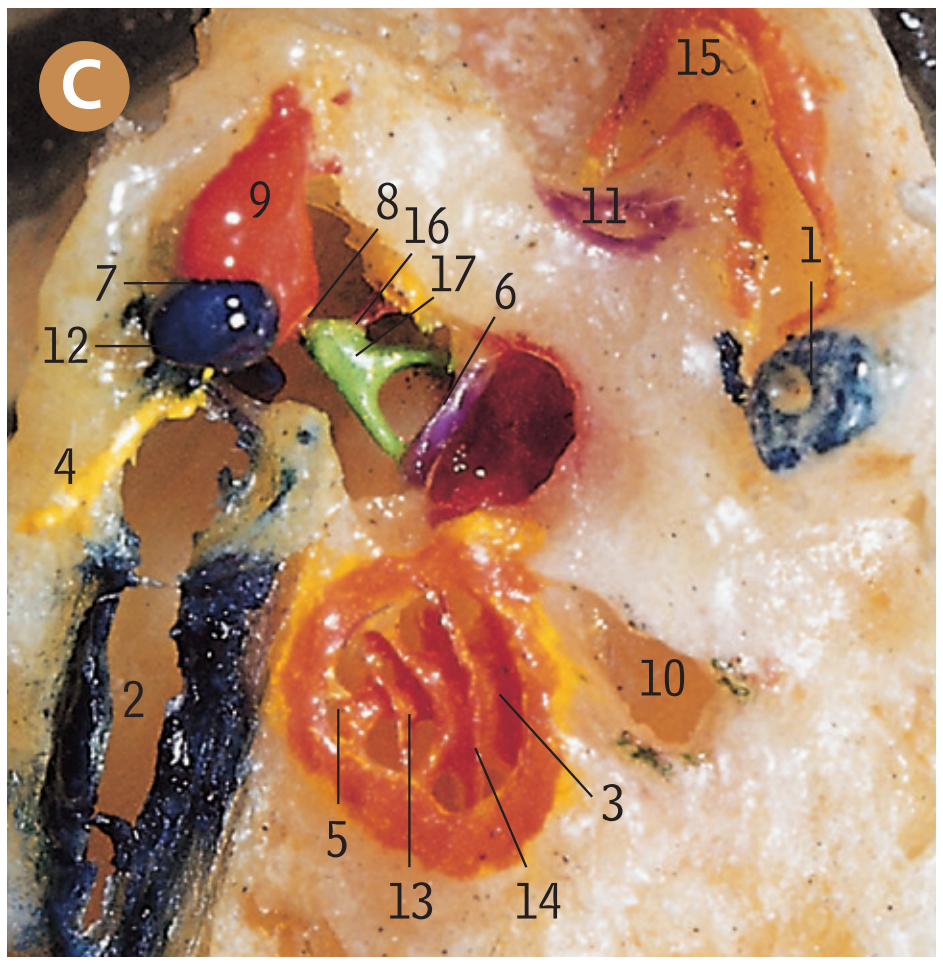

This dissection is viewed from above, looking slightly backwards and laterally. Within the cavity of the middle ear are the three auditory ossicles – malleus (12), incus (9) and stapes (17). The tympanic membrane and external acoustic meatus are not seen but lie below the label 7. The cochlea has been opened up to show its internal bony structure (3, 5, 13 and 14).

1 Anterior (superior) semicircular canal
2 Auditory tube
3 Bony canal of cochlea
4 Chorda tympani
5 Cupola of cochlea
6 Footplate of stapes in oval window of vestibule
7 Incudomalleolar joint
8 Incudostapedial joint
9 Incus
10 Internal acoustic meatus
11 Lateral semicircular canal
12 Malleus
13 Modiolus of cochlea
14 Osseous spiral lamina of cochlea
15 Posterior semicircular canal
16 Stapedius tendon
17 Stapes

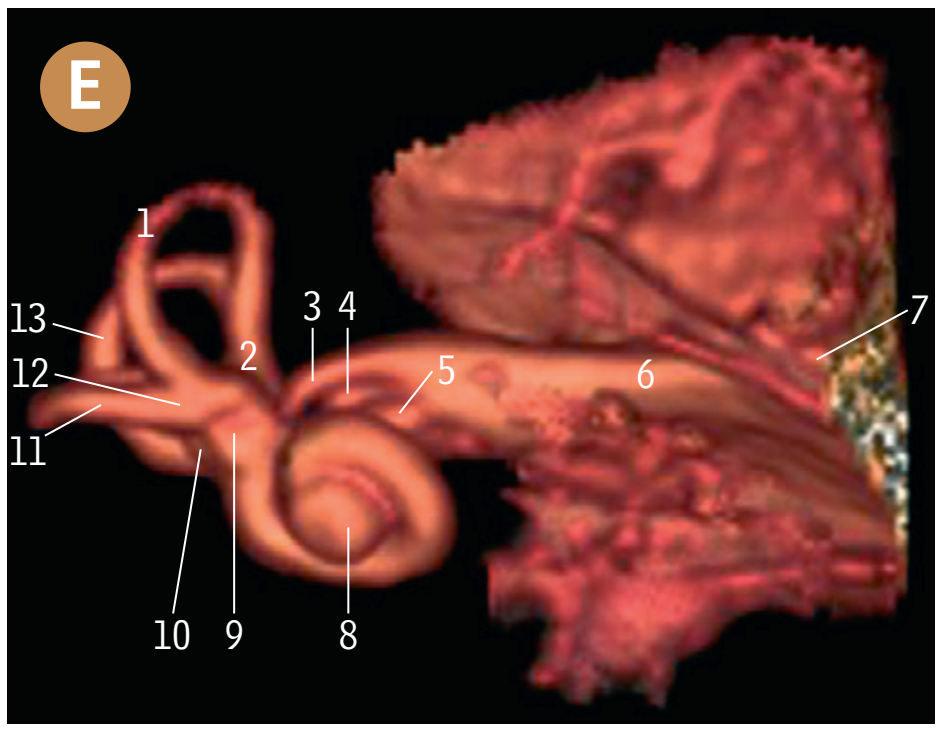

Right ear

D from above, diagram of parts

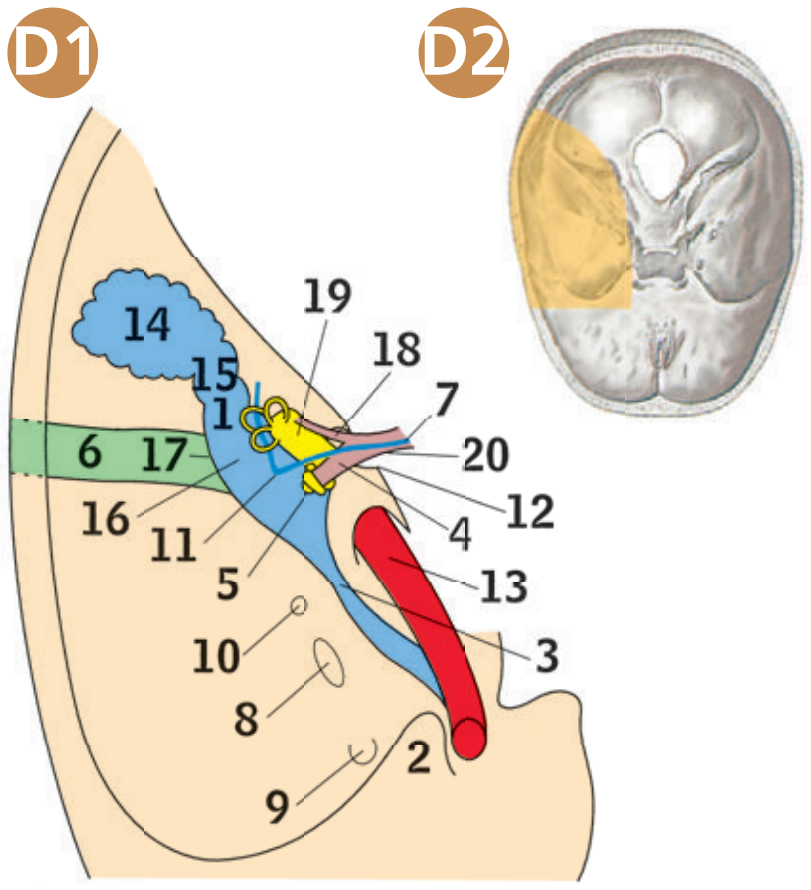

1 Aditus to mastoid antrum
2 Anterior clinoid process
3 Auditory tube
4 Cochlear nerve
5 Cochlear part of inner ear
6 External acoustic meatus
7 Facial nerve
8 Foramen ovale
9 Foramen rotundum
10 Foramen spinosum
11 Geniculate ganglion of facial nerve
12 Internal acoustic meatus
13 Internal carotid artery emerging from foramen lacerum
14 Mastoid air cells
15 Mastoid antrum
16 Middle ear
17 Tympanic membrane
18 Vestibular nerve
19 Vestibular part of inner ear
20 Vestibulocochlear nerve

E **Inner ear CT (3D reconstruction)**

1 Anterior (superior) semicircular canals (SSC)
2 Common crus
3 Labyrinthine segment of facial nerve
4 Superior vestibular nerve
5 Cochlear nerve
6 Vestibulocochlear nerve
7 Abducent nerve CN VI
8 Cochlea
9 Vestibule
10 Oval window
11 Lateral SCC
12 Lateral SCC, ampulla
13 Posterior SCC

Labyrinthitis, see pages 80–82.

A Cranial vault and falx *from below*

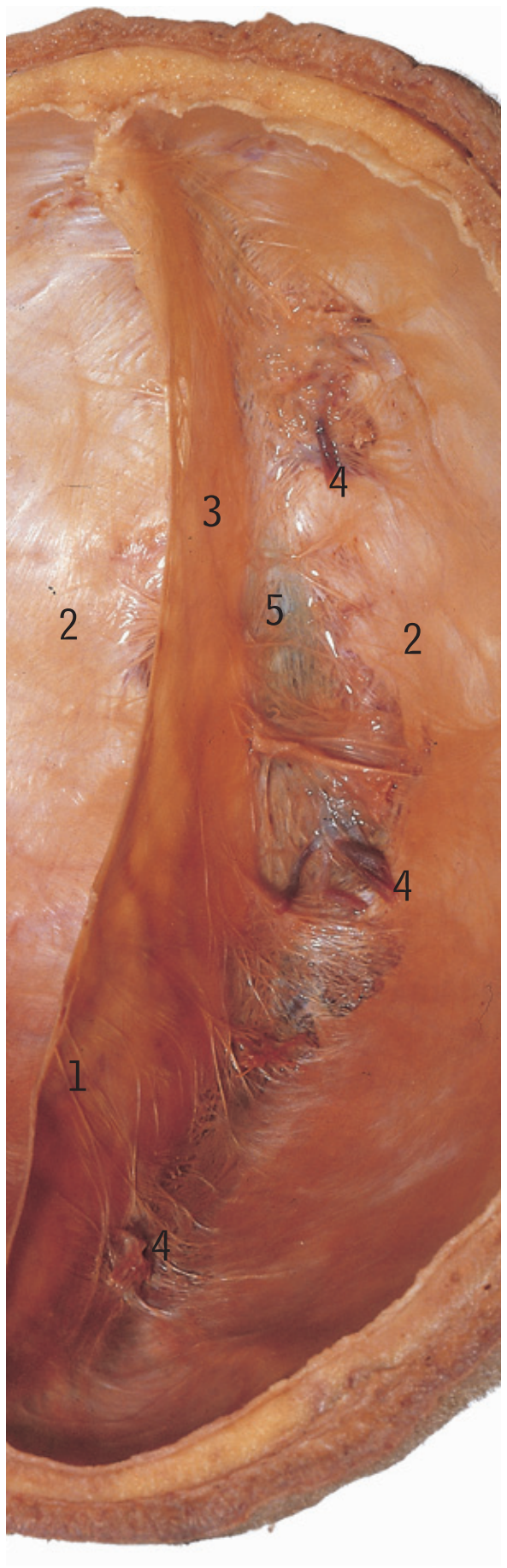

Looking up into the cranial vault from below, the falx cerebri (3) is seen to be continuous with the dura over the vault (2), and has been cut off at the back (1) from the tentorium cerebelli.

1 Cut edge of falx cerebri
2 Dura mater over cranial vault
3 Falx cerebri
4 Superior cerebral veins
5 Superior sagittal sinus

B Brain *from above*

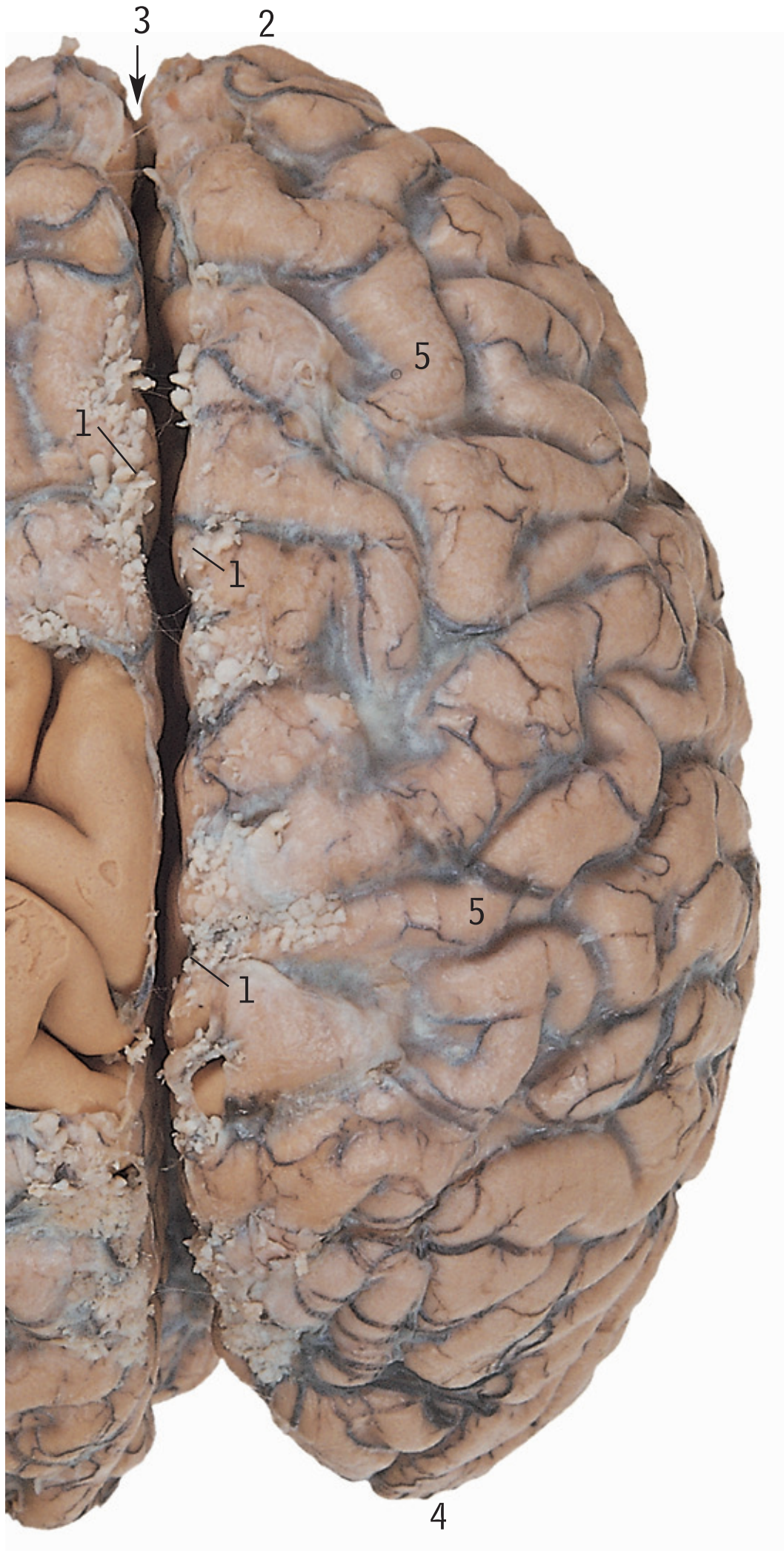

The right cerebral hemisphere is seen with the overlying arachnoid mater and arachnoid granulations (1) adjacent to the longitudinal fissure (3). Over the small part of the left hemisphere shown, a window has been cut in the arachnoid revealing the subarachnoid space.

1 Arachnoid granulations
2 Frontal pole
3 Longitudinal fissure
4 Occipital pole
5 Superolateral surface

C Brain *right cerebral hemisphere, from above*

Removal of the arachnoid and the underlying vessels displays the gyri and sulci. Only a small number are named here; the most important are the central sulcus (1) and the precentral and postcentral gyri (5 and 3).

1 Central sulcus
2 Parieto-occipital sulcus
3 Postcentral gyrus
4 Postcentral sulcus
5 Precentral gyrus
6 Precentral sulcus
7 Superior frontal gyrus

Subarachnoid haemorrhage, see pages 80–82.

Brain (A) *from the right* (B) *right cerebral hemisphere, from the right*

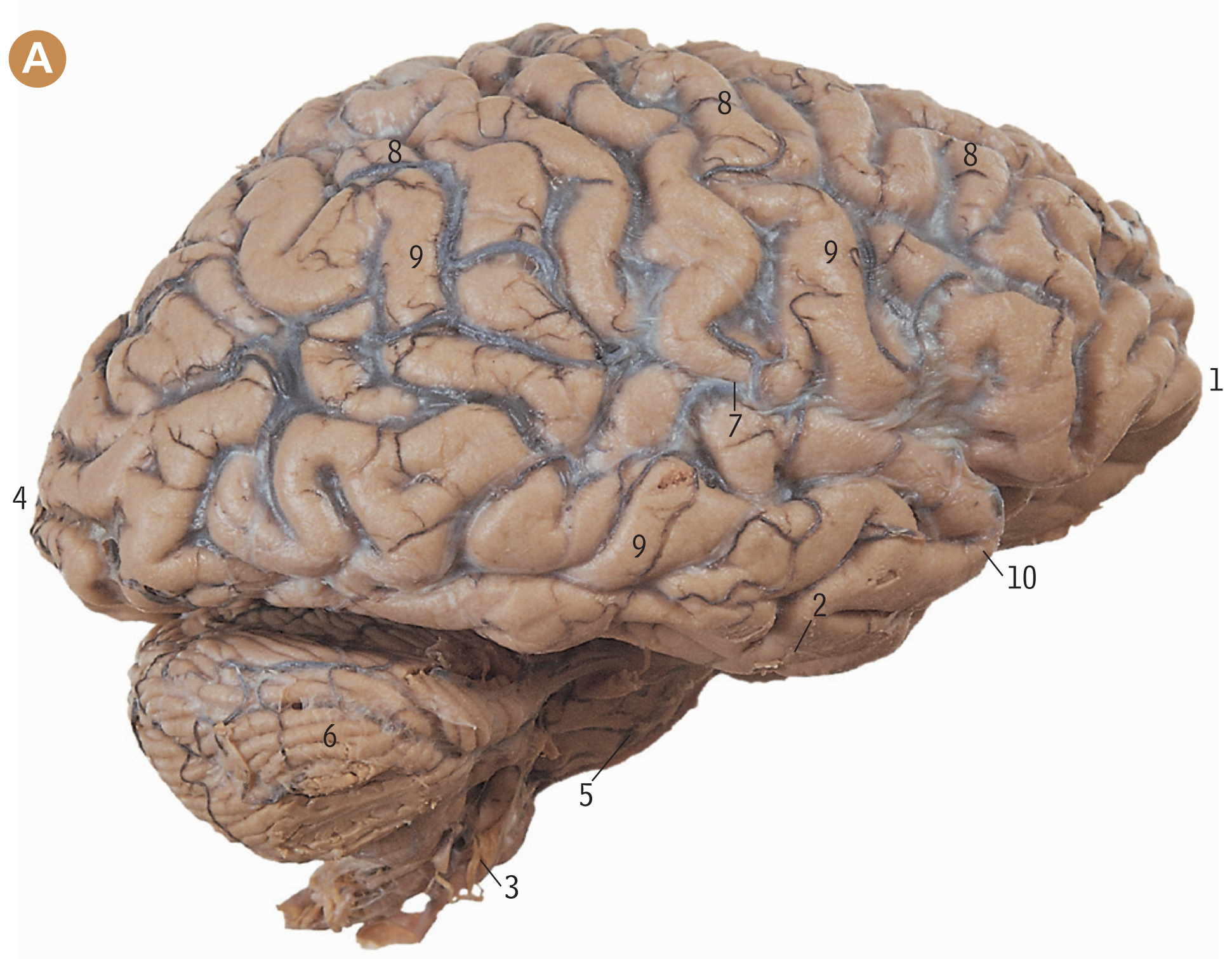

As in B (page 62), the arachnoid mater has been left intact and vessels are seen beneath it; the larger ones are veins (as at 7).

1 Frontal pole
2 Inferior cerebral veins
3 Medulla oblongata and vertebral artery
4 Occipital pole
5 Pons and basilar artery
6 Right cerebellar hemisphere
7 Superficial middle cerebral vein overlying lateral sulcus
8 Superior cerebral veins
9 Superolateral surface of right cerebral hemisphere
10 Temporal pole

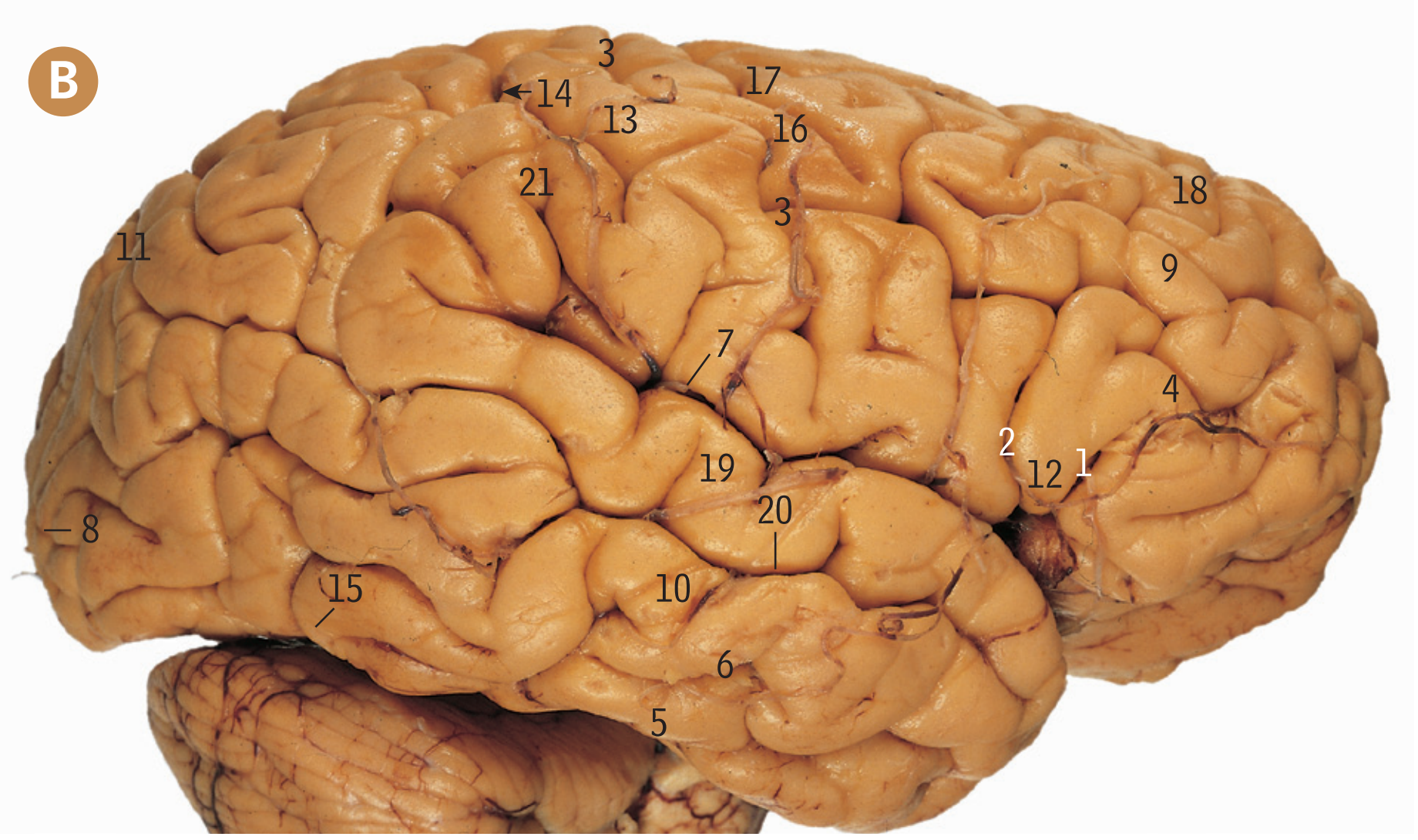

The arachnoid mater has been removed, leaving some of the larger branches of the middle cerebral artery (unlabelled) after they have emerged from the lateral sulcus (7). Only the main gyri and sulci are named here: the most important are the precentral and postcentral gyri (16 and 13) and the central and lateral sulci (3 and 7).

1 Anterior ramus of lateral sulcus
2 Ascending ramus of lateral sulcus
3 Central sulcus
4 Inferior frontal gyrus
5 Inferior temporal gyrus
6 Inferior temporal sulcus
7 Lateral sulcus (posterior ramus)
8 Lunate sulcus
9 Middle frontal gyrus
10 Middle temporal gyrus
11 Parieto-occipital sulcus
12 Pars triangularis
13 Postcentral gyrus
14 Postcentral sulcus
15 Pre-occipital notch
16 Precentral gyrus
17 Precentral sulcus
18 Superior frontal gyrus
19 Superior temporal gyrus
20 Superior temporal sulcus
21 Supramarginal gyrus

The central sulcus (C1 (page 62) and B3, above) marks the boundary between the frontal and parietal lobes.

An arbitrary line from the pre-occipital notch (B15) to the parieto-occipital sulcus (B11) marks the boundary between the parietal and occipital lobes, and the part of the hemisphere in front of this line and below the lateral sulcus (strictly, the posterior ramus of the lateral sulcus, B7) forms the temporal lobe.

The precentral and postcentral gyri (B16 and 13) contain the classically described primary 'motor' and 'sensory' areas of the cortex.

The motor speech (Broca) areas (usually in the left cerebral hemisphere) are in the region of the ascending and anterior rami of the lateral sulcus and the pars triangularis (B2, 1 and 12).

The auditory areas of the cortex probably comprise parts of the superior temporal gyrus (B19), especially the upper surface of it within the lateral sulcus (B7).

A Brain *from below*

This is the view of the under-surface of the brain as typically seen when first removed from the skull, without any dissection. Arachnoid mater, torn in places and with blood vessels beneath it, remains on the outer surface.

1 Abducent nerve
2 Anterior perforated substance
3 Arachnoid mater overlying mamillary bodies
4 Basilar artery
5 Cerebellar hemisphere
6 Crus of cerebral peduncle (midbrain)
7 Facial nerve
8 Frontal pole
9 Gyrus rectus
10 Inferior surface of frontal lobe
11 Inferior surface of temporal lobe
12 Internal carotid artery
13 Longitudinal fissure
14 Medulla oblongata
15 Oculomotor nerve
16 Olfactory bulb
17 Olfactory tract
18 Optic chiasma
19 Optic nerve
20 Pituitary stalk (infundibulum)
21 Pons
22 Posterior communicating artery
23 Spinal part of accessory nerve
24 Temporal pole
25 Trigeminal nerve
26 Uncus
27 Vertebral artery
28 Vestibulocochlear nerve

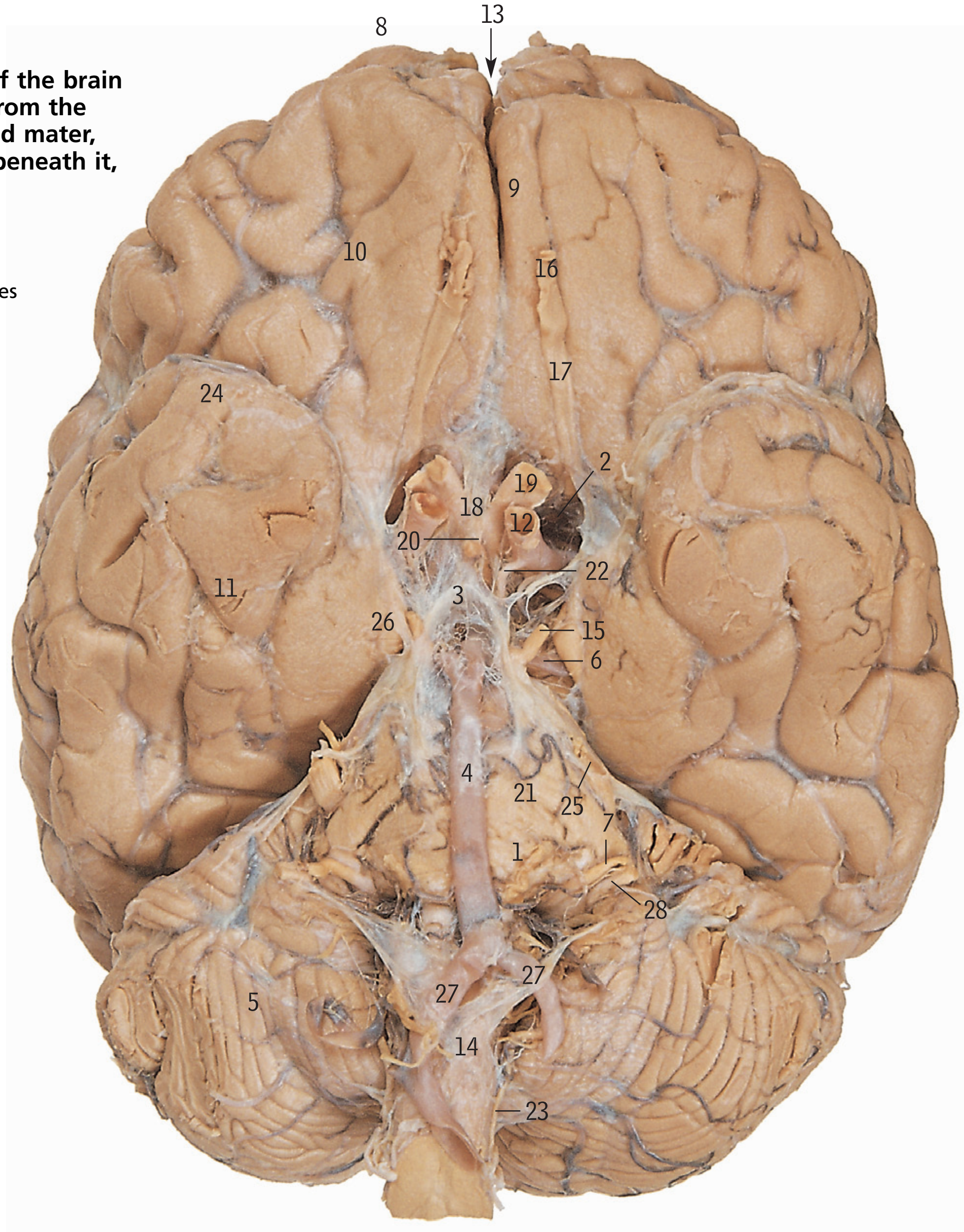

B Optic tract and geniculate bodies *from below*

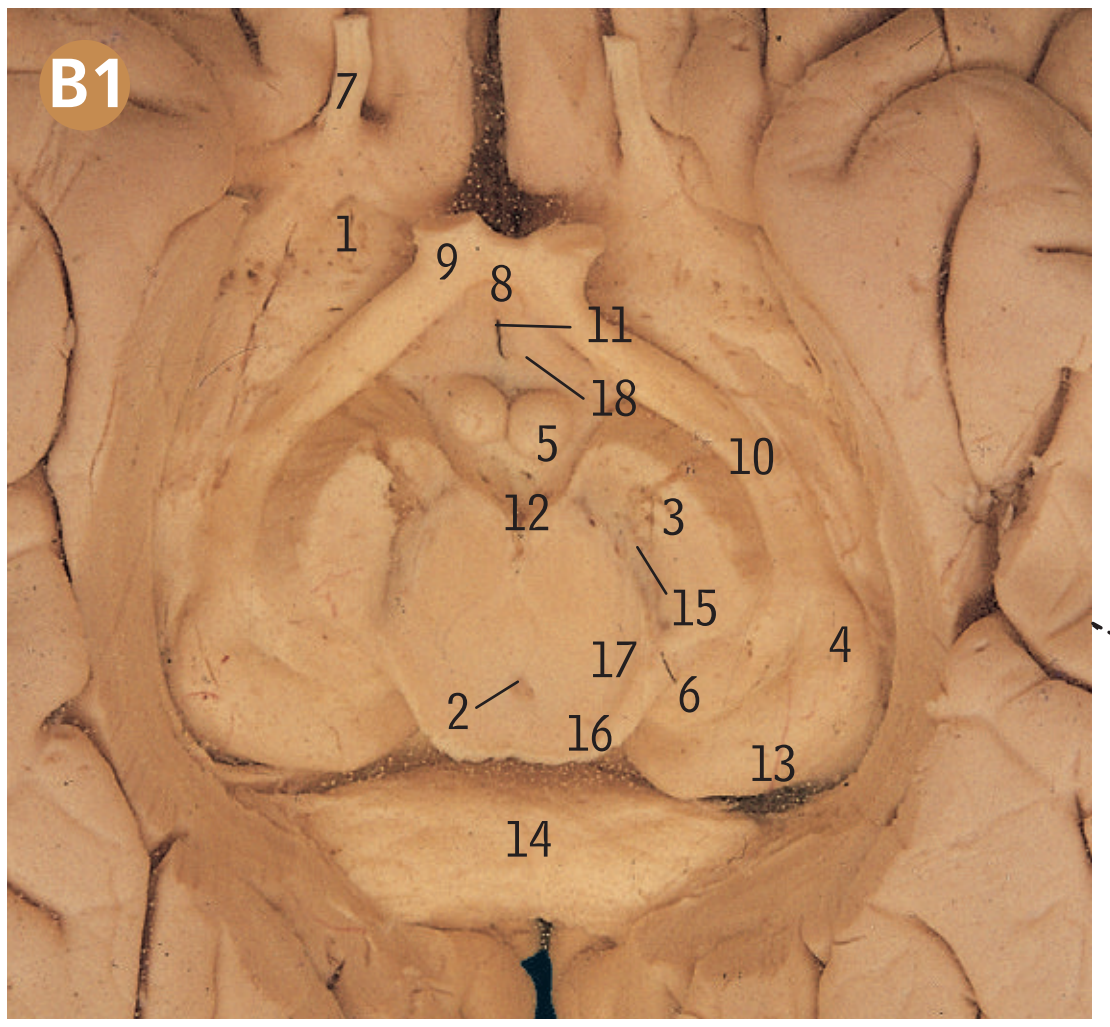

The brainstem has been mostly removed, leaving only the upper part of the midbrain. The most medial parts of each cerebral hemisphere have also been dissected away. To find the geniculate bodies (4 and 6), which are on the under-surface of the posterior part (pulvinar, 13) of the thalamus, identify the optic chiasma (8) and then follow the optic tract (10) backwards round the side of the midbrain (3).

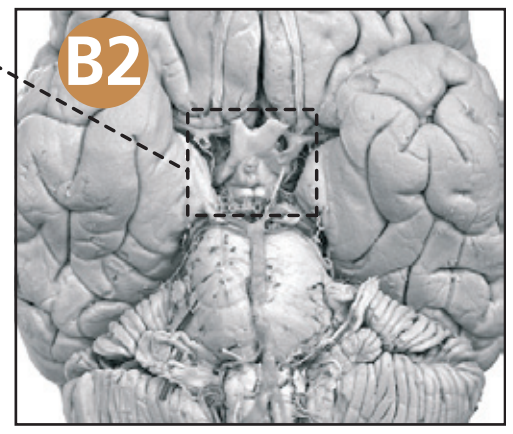

1 Anterior perforated substance
2 Aqueduct of midbrain
3 Crus of midbrain
4 Lateral geniculate body
5 Mamillary body
6 Medial geniculate body
7 Olfactory tract
8 Optic chiasma
9 Optic nerve
10 Optic tract
11 Pituitary stalk (infundibulum)
12 Posterior perforated substance
13 Pulvinar of thalamus
14 Splenium of corpus callosum
15 Substantia nigra of midbrain
16 Tectum of midbrain
17 Tegmentum of midbrain
18 Tuber cinereum

A Brain *from below*

A1

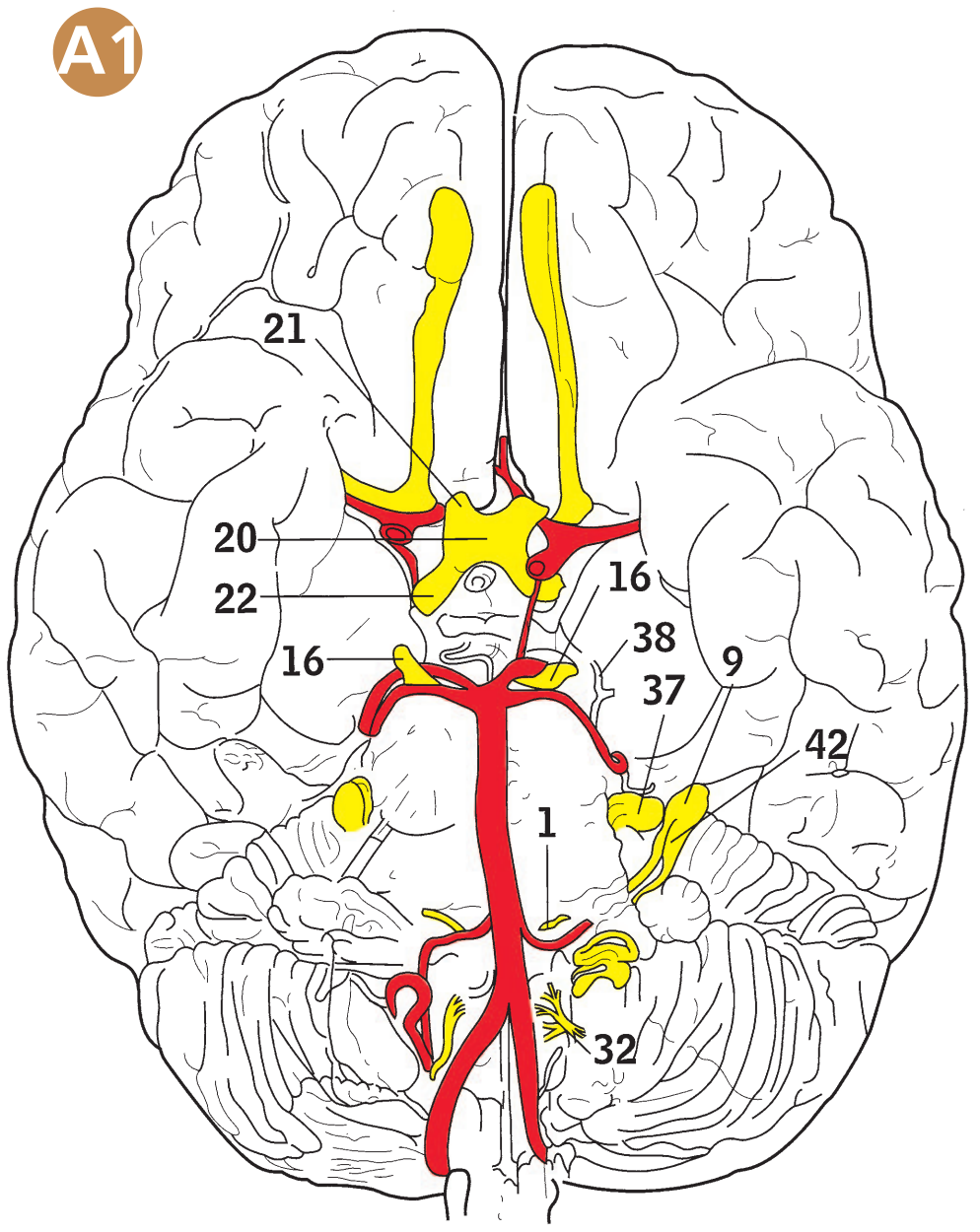

A2

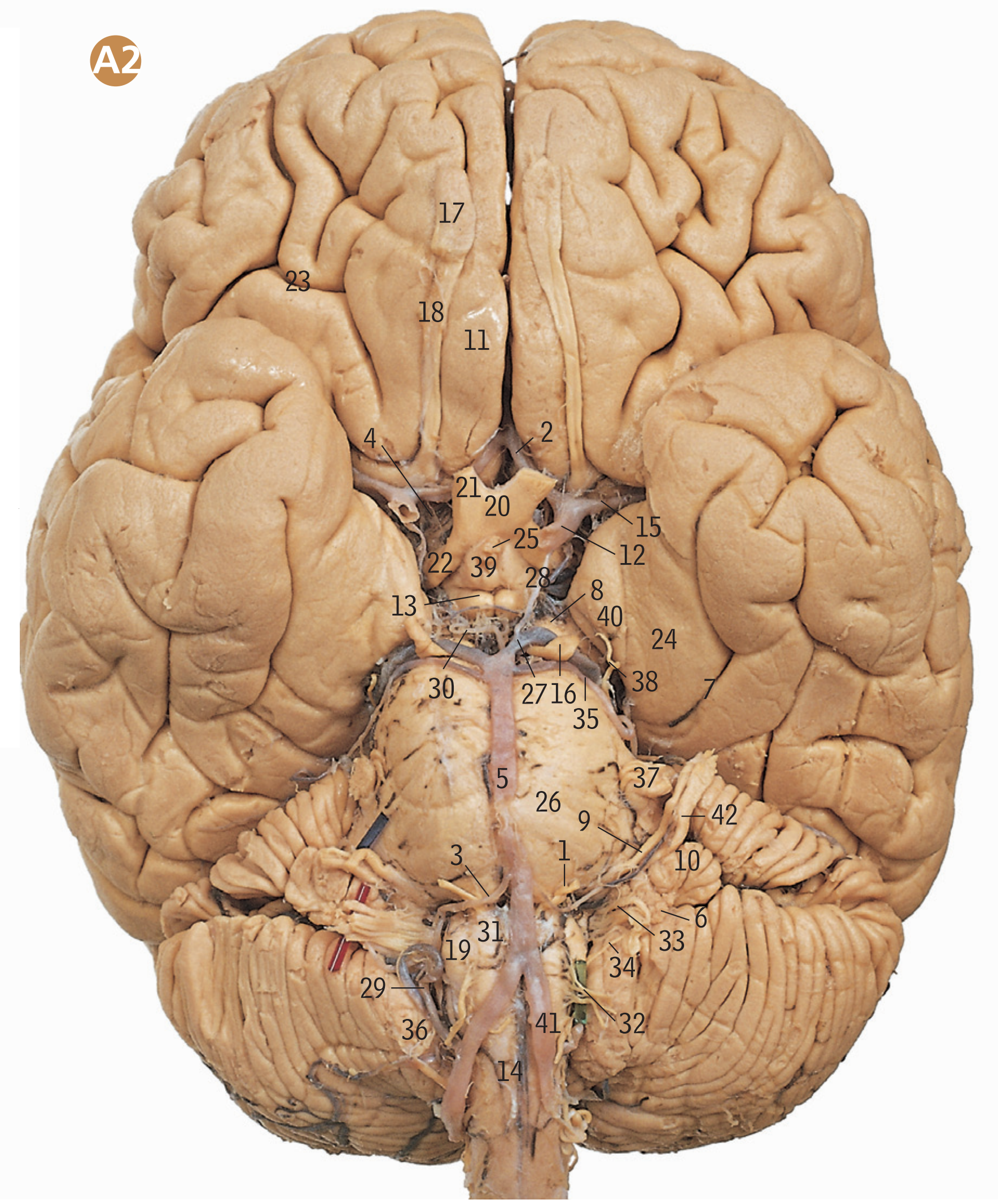

- **1** Abducent nerve
- **2** Anterior cerebral artery
- **3** Anterior inferior cerebellar artery
- **4** Anterior perforated substance
- **5** Basilar artery
- **6** Choroid plexus from lateral recess of fourth ventricle
- **7** Collateral sulcus
- **8** Crus of cerebral peduncle
- **9** Facial nerve
- **10** Flocculus of cerebellum
- **11** Gyrus rectus
- **12** Internal carotid artery
- **13** Mamillary body
- **14** Medulla oblongata
- **15** Middle cerebral artery
- **16** Oculomotor nerve
- **17** Olfactory bulb
- **18** Olfactory tract
- **19** Olive of medulla oblongata
- **20** Optic chiasma
- **21** Optic nerve
- **22** Optic tract
- **23** Orbital sulcus
- **24** Parahippocampal gyrus
- **25** Pituitary stalk (infundibulum)
- **26** Pons
- **27** Posterior cerebral artery
- **28** Posterior communicating artery
- **29** Posterior inferior cerebellar artery
- **30** Posterior perforated substance
- **31** Pyramid of medulla oblongata
- **32** Rootlets of hypoglossal nerve (superficial to marker)
- **33** Roots of glossopharyngeal, vagus and accessory nerves
- **34** Spinal part of accessory nerve
- **35** Superior cerebellar artery
- **36** Tonsil of cerebellum
- **37** Trigeminal nerve
- **38** Trochlear nerve
- **39** Tuber cinereum and median eminence
- **40** Uncus
- **41** Vertebral artery
- **42** Vestibulocochlear nerve

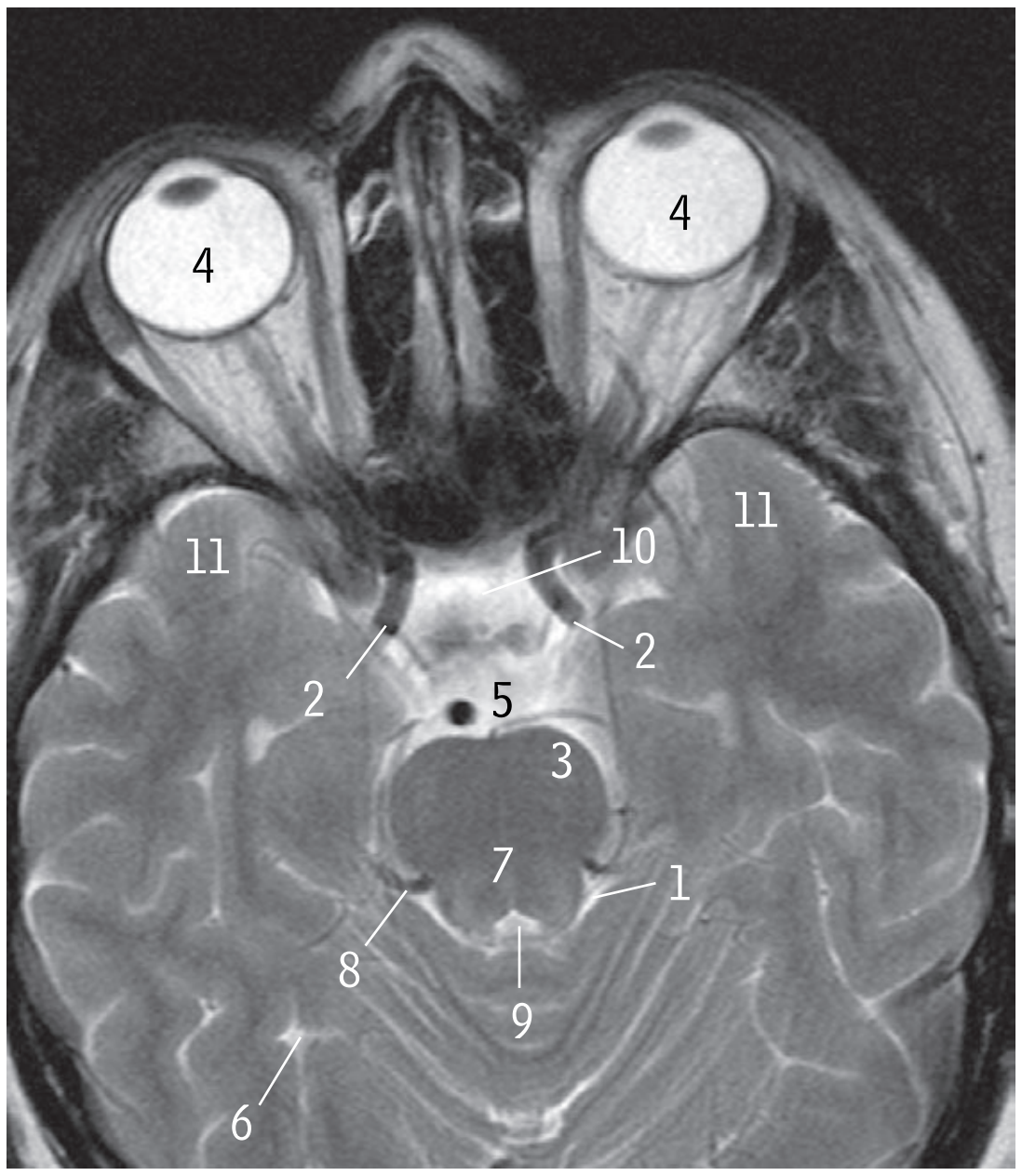

B Brain

axial MR image showing cisterns

- **1** Ambient cistern
- **2** Carotid artery, internal
- **3** Cerebral peduncle
- **4** Globe (eyeball)
- **5** Interpeduncular cistern
- **6** Lateral ventricle, posterior horn
- **7** Midbrain
- **8** Posterior cerebral artery
- **9** Quadrigeminal cistern
- **10** Suprachiasmatic cistern
- **11** Temporal lobe

A Right half of the brain *in a midline sagittal section, from the left*

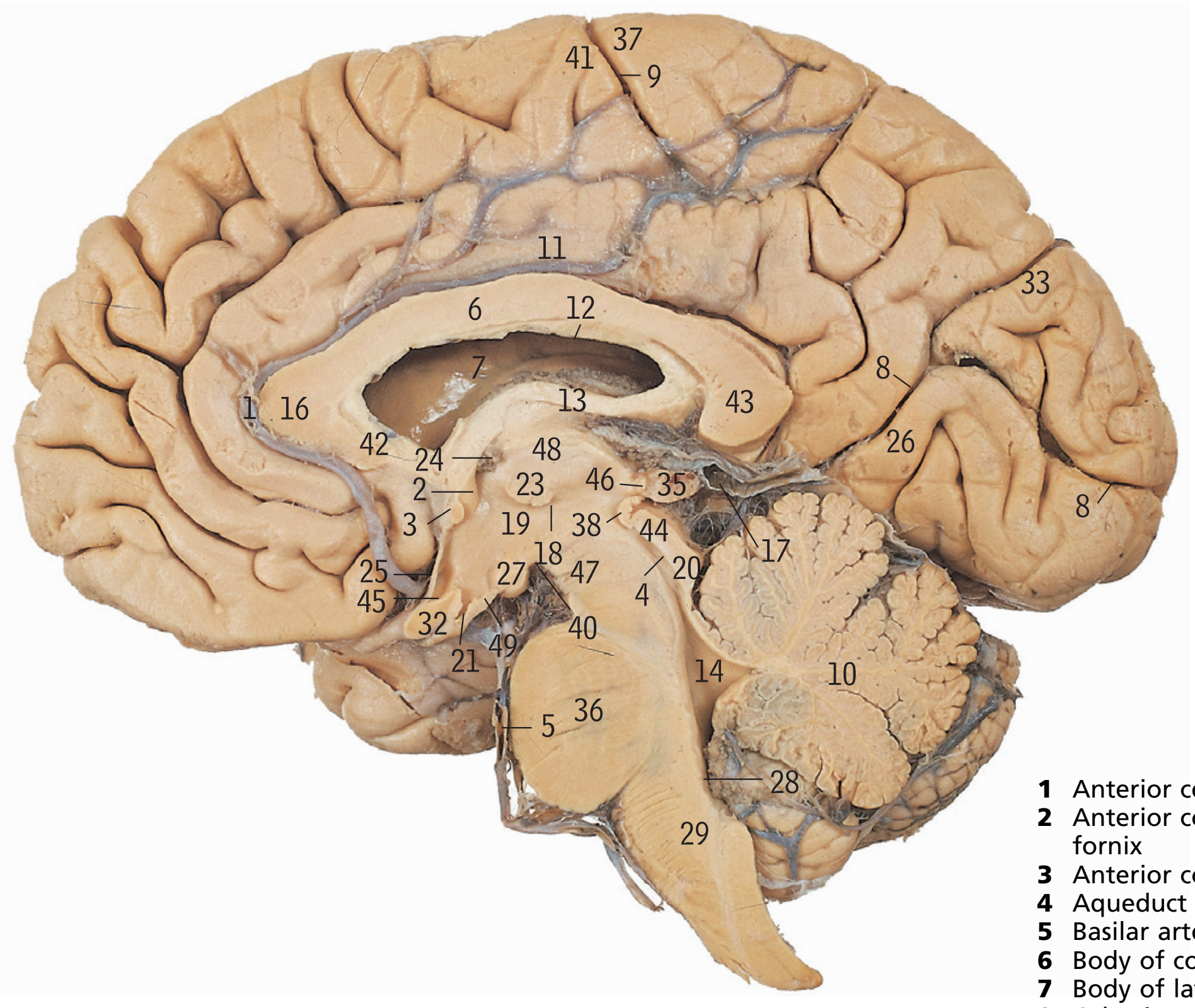

In this typical half-section of the brain, the medial surface of the right cerebral hemisphere is seen, together with the sectioned brainstem (midbrain, 4, 20, 44, 47; pons, 36; and medulla oblongata, 29). The septum pellucidum, which is a midline structure and whose cut edge (12) is seen below the body of the corpus callosum (6), has been removed to show the interior of the body of the lateral ventricle (7). The third ventricle has the thalamus (48) and hypothalamus (19) in its lateral wall, while in its floor from front to back are the optic chiasma (32), the base of the pituitary stalk (21), the median eminence (49), the mamillary bodies (27), and the posterior perforated substance (40).

1 Anterior cerebral artery
2 Anterior column of fornix
3 Anterior commissure
4 Aqueduct of midbrain
5 Basilar artery
6 Body of corpus callosum
7 Body of lateral ventricle
8 Calcarine sulcus
9 Central sulcus
10 Cerebellum
11 Cingulate gyrus
12 Cut edge of septum pellucidum
13 Fornix
14 Fourth ventricle
15 Frontopolar artery
16 Genu of corpus callosum
17 Great cerebral vein
18 Hypothalamic sulcus
19 Hypothalamus
20 Inferior colliculus of midbrain
21 Infundibular recess (base of pituitary stalk)
22 Internal carotid artery
23 Interthalamic connexion
24 Interventricular foramen and choroid plexus
25 Lamina terminalis
26 Lingual gyrus
27 Mamillary body
28 Median aperture of fourth ventricle
29 Medulla oblongata
30 Middle cerebral artery
31 Ophthalmic artery
32 Optic chiasma
33 Parieto-occipital sulcus
34 Pericallosal artery
35 Pineal body
36 Pons
37 Postcentral gyrus
38 Posterior commissure
39 Posterior communicating artery
40 Posterior perforated substance
41 Precentral gyrus
42 Rostrum of corpus callosum
43 Splenium of corpus callosum
44 Superior colliculus of midbrain
45 Supra-optic recess
46 Suprapineal recess
47 Tegmentum of midbrain
48 Thalamus
49 Tuber cinereum and median eminence

B Carotid arteriogram *digitally subtracted arterial phase of carotid arteriogram, lateral projection*

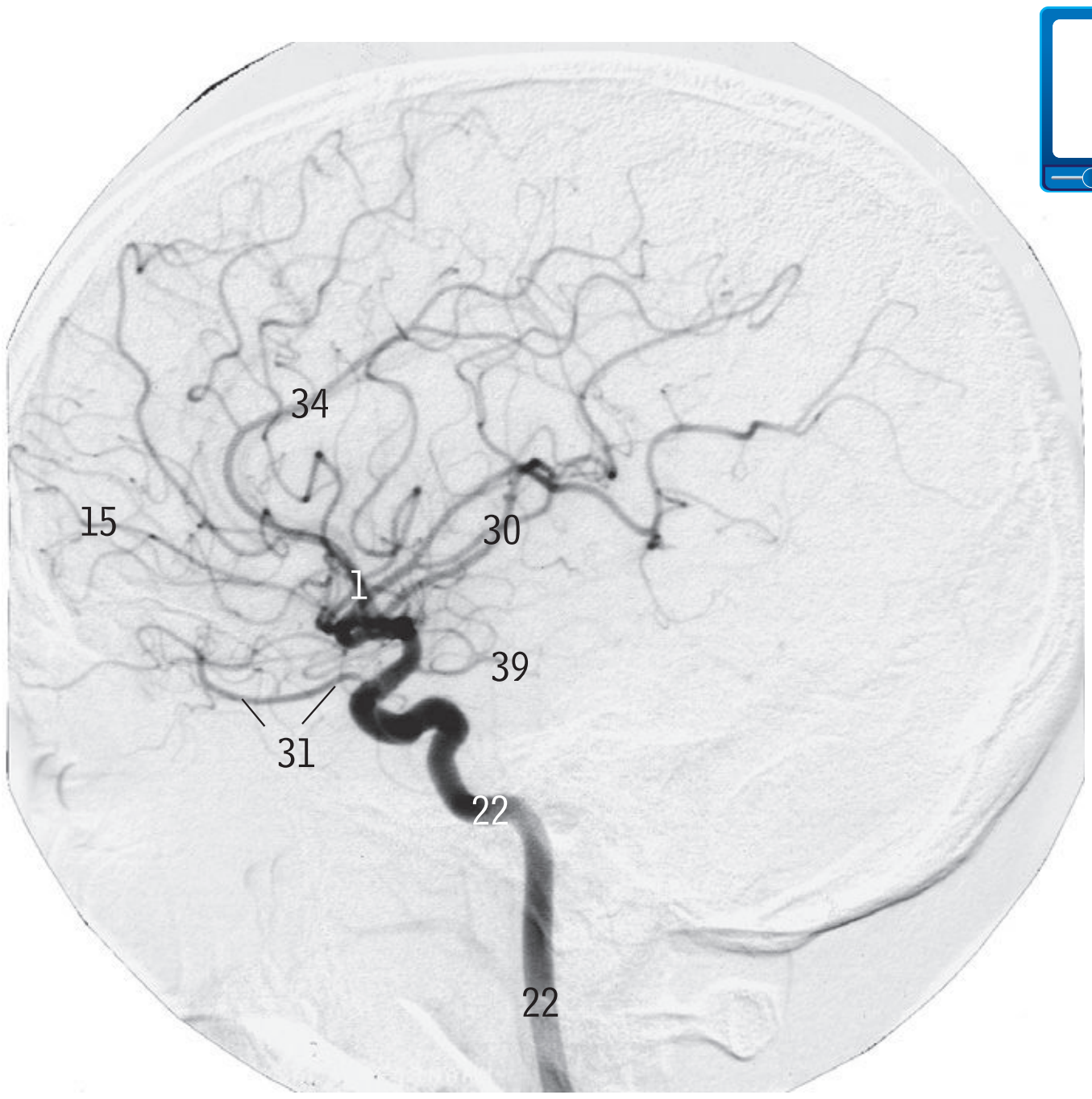

The third ventricle is the cavity which has in its lateral wall the thalamus (A48) and hypothalamus (A19).

The fourth ventricle (A14) is largely between the pons (A36) and cerebellum (A10), although its lower end is behind the upper part of the medulla oblongata (A29) (see page 53, B).

The aqueduct of the midbrain (A4) connects the third and fourth ventricles; cerebrospinal fluid normally flows through it from the third to the fourth ventricle.

The interventricular foramen (A24) connects the third to the lateral ventricle, and is bounded in front by the anterior column of the fornix (A2) and behind by the thalamus (A48).

C Brain *median sagittal MR image*

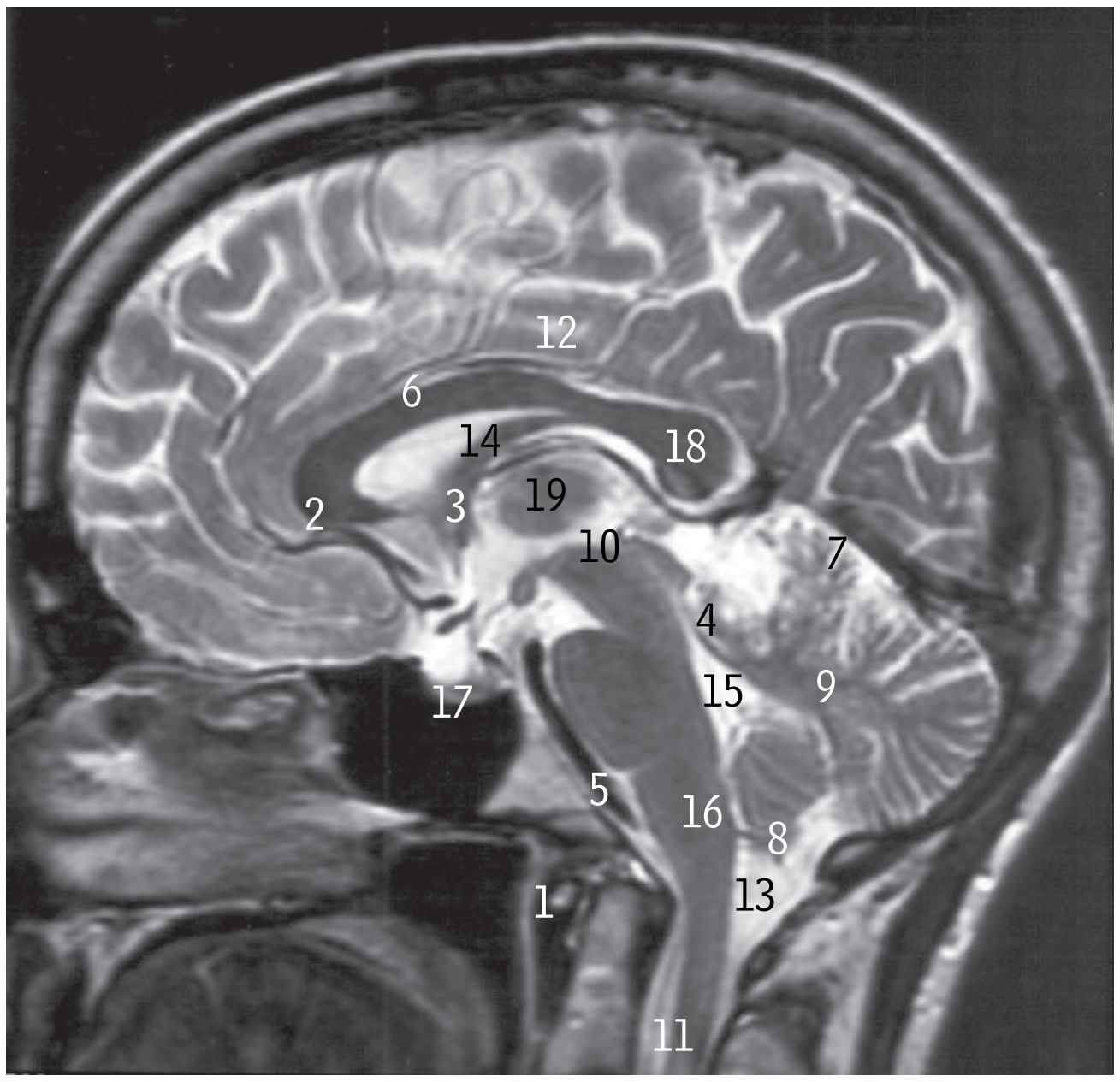

1 Anterior arch of atlas
2 Anterior cerebral artery
3 Anterior commissure
4 Aqueduct of Sylvius
5 Basilar artery
6 Body of corpus callosum
7 Cerebellar folia
8 Cerebellar tonsil
9 Cerebellum
10 Cerebral peduncle of midbrain
11 Cervical spinal cord
12 Cingulate gyrus
13 Cisterna magna
14 Fornix
15 Fourth ventricle
16 Medulla oblongata
17 Pituitary gland
18 Splenium of corpus callosum
19 Thalamus in lateral wall third ventricle

D *Cranial nerves*

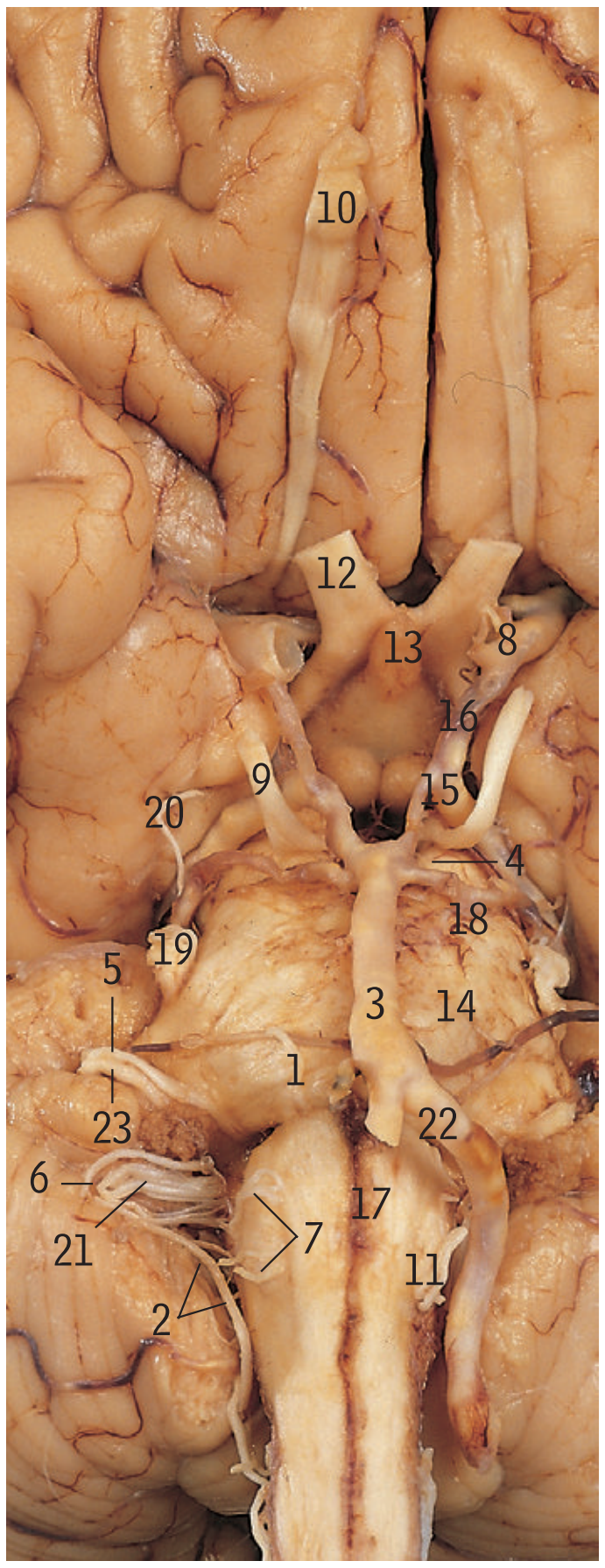

E *Endoscopy – base of brain*

In this ventral view of the central part of the brain, the right vertebral artery (on the left of the picture) has been removed almost at the junction with its fellow (22). The filaments of the first nerve (olfactory) are not seen entering the olfactory bulb (10) as they are torn off when removing the brain. The roots forming the glossopharyngeal, vagus and accessory nerves (6, 21 and 2) cannot be clearly identified from one another, but the spinal part of the accessory nerve (2) is seen running up beside the medulla to join the cranial part.

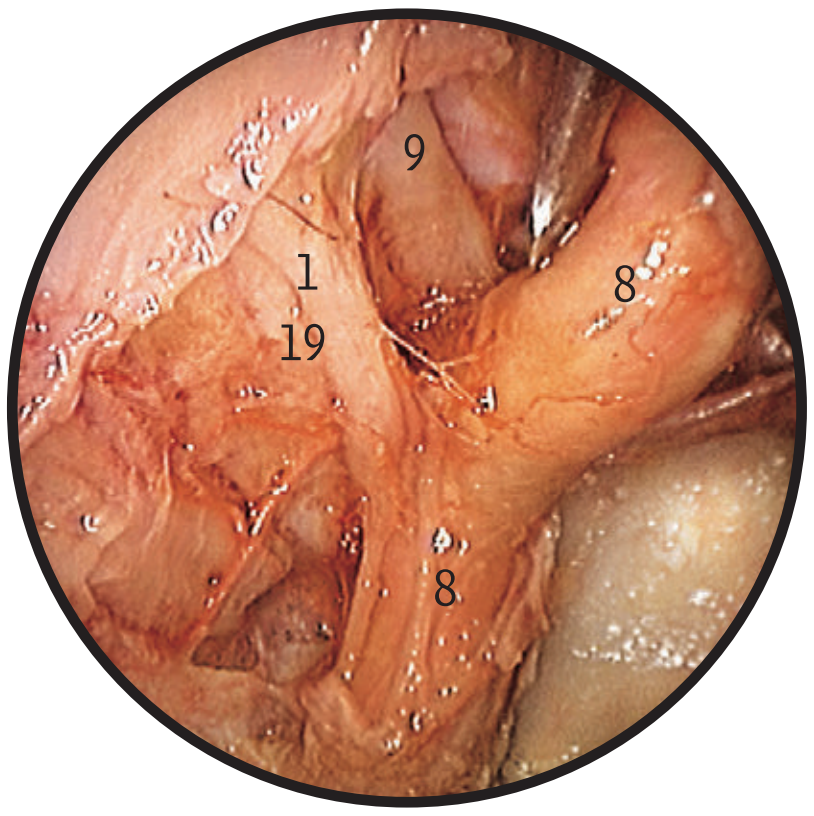

1 Abducent nerve
2 Accessory nerve, spinal root
3 Basilar artery
4 Crus of cerebral peduncle
5 Facial nerve
6 Glossopharyngeal nerve
7 Hypoglossal nerve
8 Internal carotid artery
9 Oculomotor nerve
10 Olfactory bulb
11 Olive of medulla oblongata
12 Optic nerve
13 Pituitary stalk
14 Pons
15 Posterior cerebral artery
16 Posterior communicating artery
17 Pyramid of medulla oblongata
18 Superior cerebellar artery
19 Trigeminal nerve
20 Trochlear nerve
21 Vagus nerve
22 Vertebral artery
23 Vestibulocochlear nerve

The oculomotor nerve (D9) emerges on the medial side of the crus of the cerebral peduncle (D4), and the trochlear nerve (D20) winds round the lateral side of the peduncle. Both nerves pass between the posterior cerebral and superior cerebellar arteries (D15 and 18).

The trochlear nerve (D20) is the only cranial nerve to emerge from the dorsal surface of the brainstem and to decussate after emergence.

The trigeminal nerve (D19) emerges from the lateral side of the pons (D14).

The abducent nerve (D1) emerges between the pons and the pyramid (D14 and 17).

The facial and vestibulocochlear nerves (D5 and 23) emerge from the lateral pontomedullary angle.

The glossopharyngeal and vagus nerves (D6, 21) and the cranial root of the accessory nerve emerge from the medulla oblongata lateral to the olive (D11).

The hypoglossal nerve (D7) emerges as two series of rootlets from the medulla oblongata between the pyramid (D17) and the olive (D11).

The spinal part of the accessory nerve emerges from the lateral surface of the upper five or six cervical segments of the spinal cord, dorsal to the denticulate ligament (page 69, G27).

Arteries of the base of the brain (A) *injected arteries* (B) *arterial circle (Willis) and basilar artery*

(C) *MR angiogram of arterial circle (Willis)*

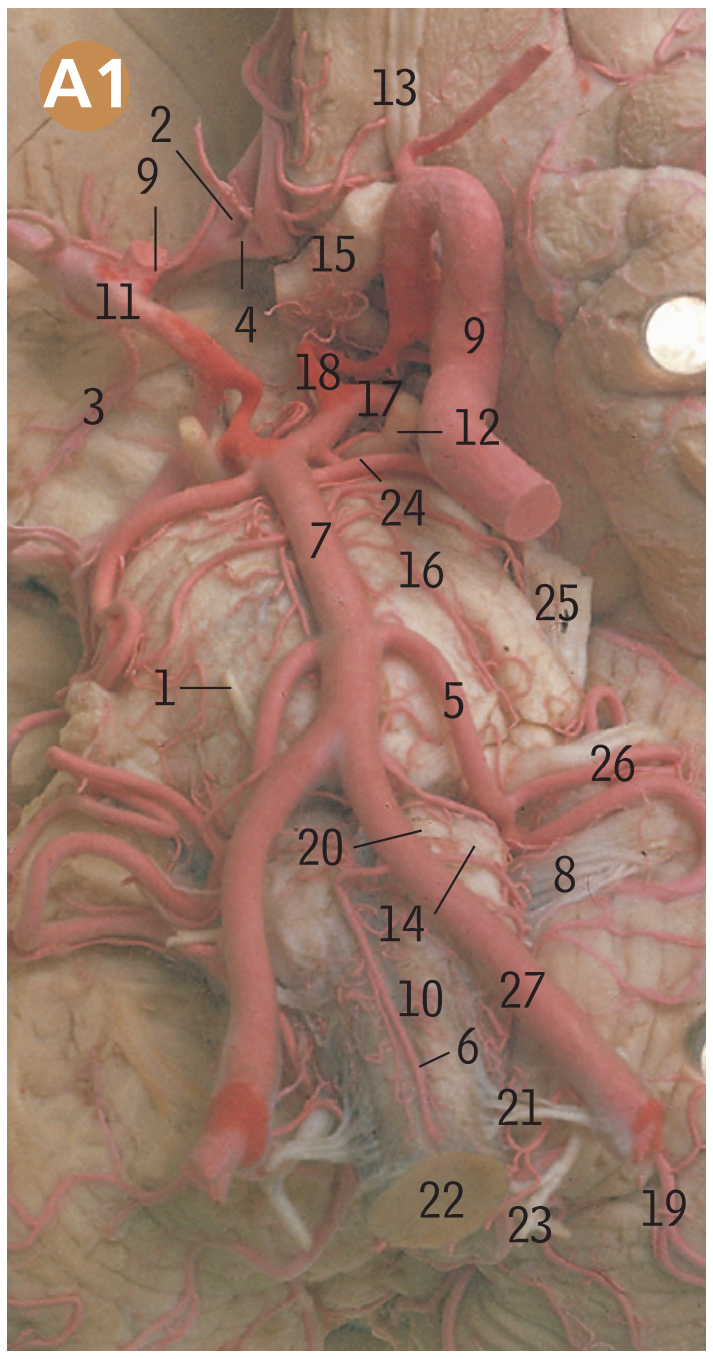

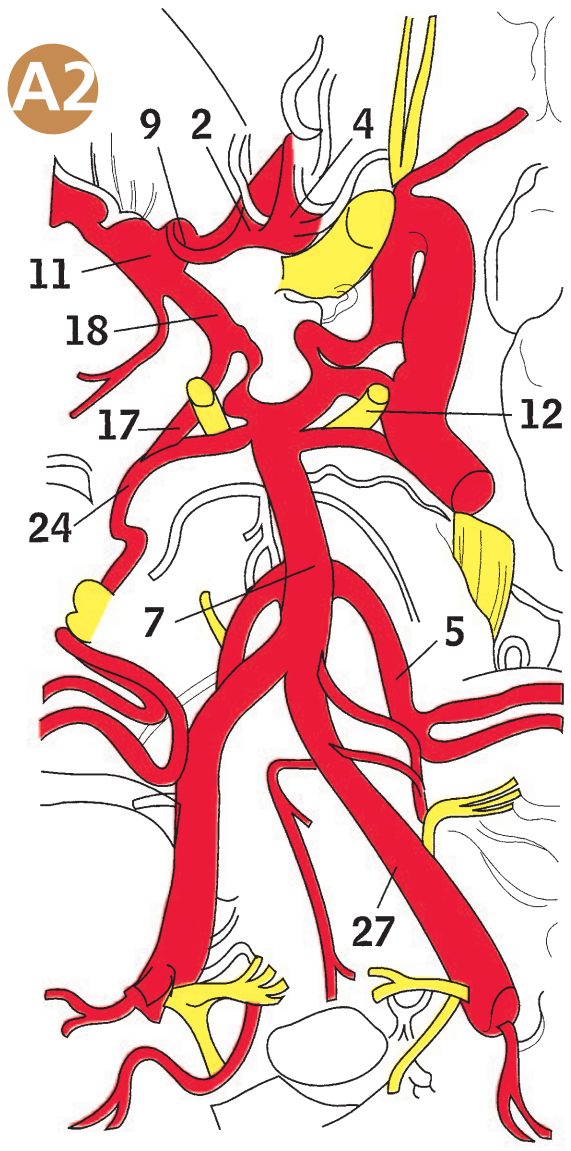

Part of the right cerebral hemisphere (on the left of the picture) has been removed to show the right middle cerebral artery (11).

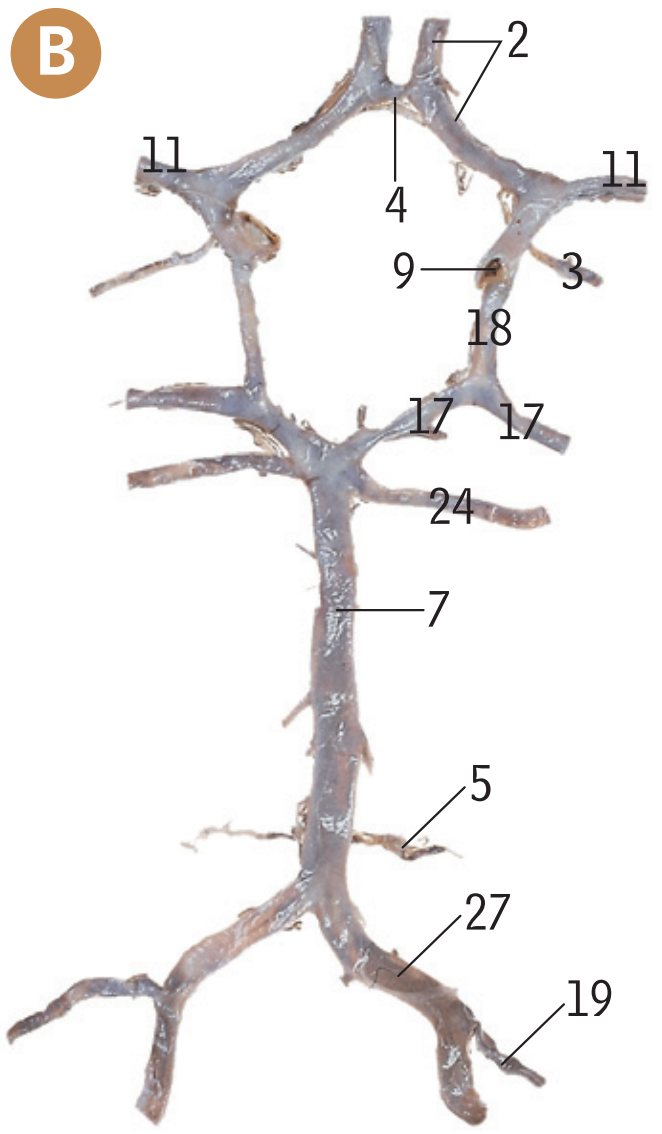

The anastomosing vessels have been removed from the base of the brain and spread out in their relative positions.

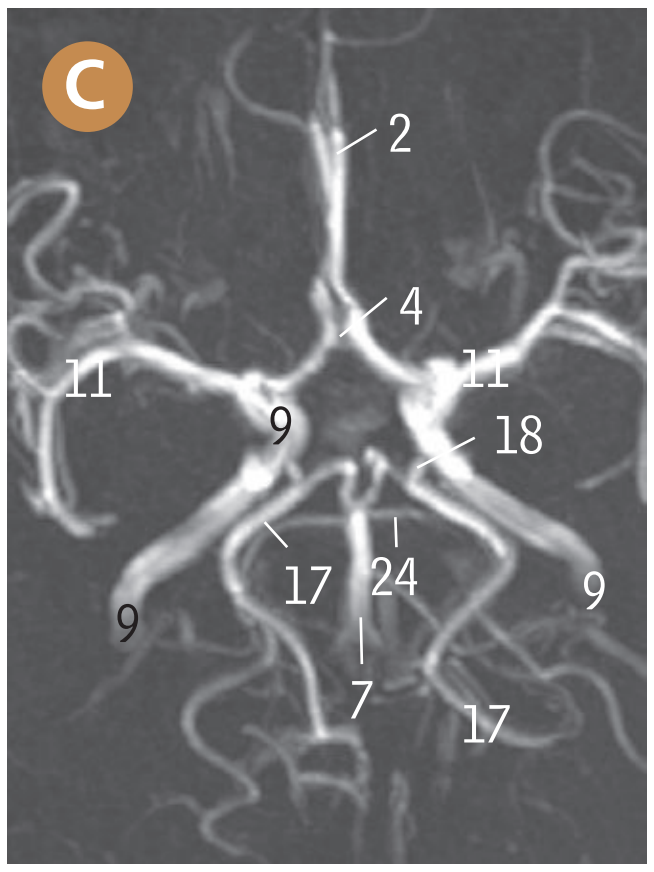

(D) *Intracranial endoscopy at the base of the brain*

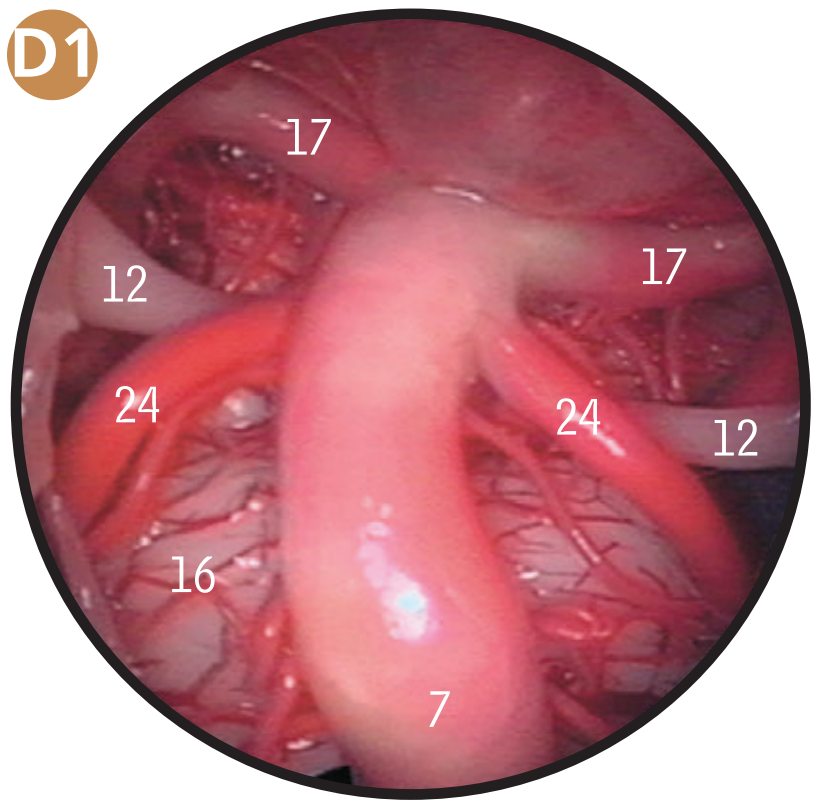

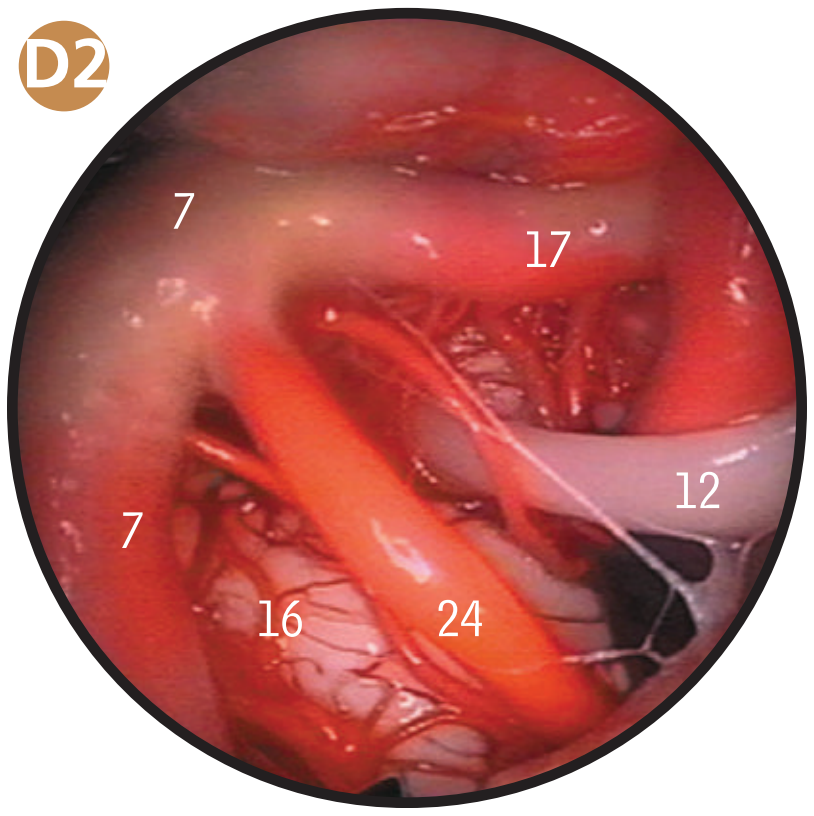

1 Abducent nerve
2 Anterior cerebral artery
3 Anterior choroidal artery
4 Anterior communicating artery
5 Anterior inferior cerebellar artery
6 Anterior spinal artery
7 Basilar artery with pontine branches
8 Filaments of glossopharyngeal, vagus and accessory nerves
9 Internal carotid artery
10 Medulla oblongata
11 Middle cerebral artery
12 Oculomotor nerve
13 Olfactory tract
14 Olive
15 Optic nerve
16 Pons
17 Posterior cerebral artery
18 Posterior communicating artery
19 Posterior inferior cerebellar artery
20 Pyramid
21 Rootlets of first cervical nerve
22 Spinal cord
23 Spinal part of accessory nerve
24 Superior cerebellar artery
25 Trigeminal nerve
26 Unusually large branch of 5 overlying facial and vestibulocochlear nerves
27 Vertebral artery

Berry aneurysm, see *pages 80–82.*

F Brainstem and floor of the fourth ventricle

In this view of the dorsal surface of the brainstem, it has been cut off from the rest of the brain at the top of the midbrain, just above the superior colliculi (15). The cerebellum has been removed by transecting the superior (14), middle (12) and inferior (6) cerebellar peduncles.

1 Cuneate tubercle
2 Cut edge of superior medullary velum
3 Facial colliculus
4 Gracile tubercle
5 Hypoglossal triangle
6 Inferior cerebellar peduncle
7 Inferior colliculus
8 Lateral recess
9 Medial eminence
10 Median sulcus
11 Medullary striae
12 Middle cerebellar peduncle
13 Obex
14 Superior cerebellar peduncle
15 Superior colliculus
16 Trochlear nerve
17 Vagal triangle
18 Vestibular area

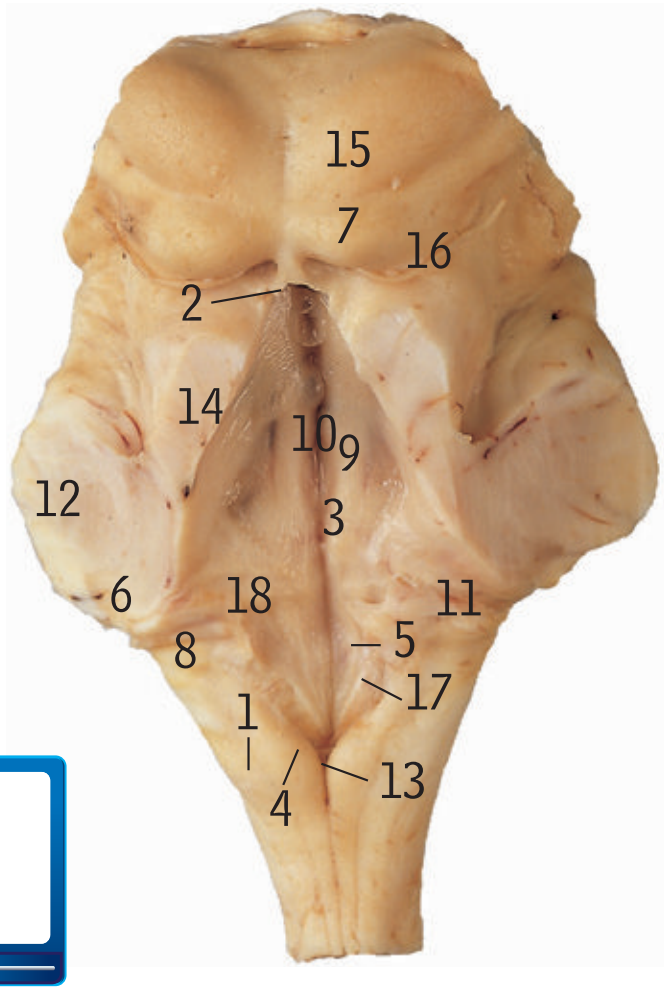

G Brainstem and upper part of the spinal cord *from behind after removal of vertebrae*

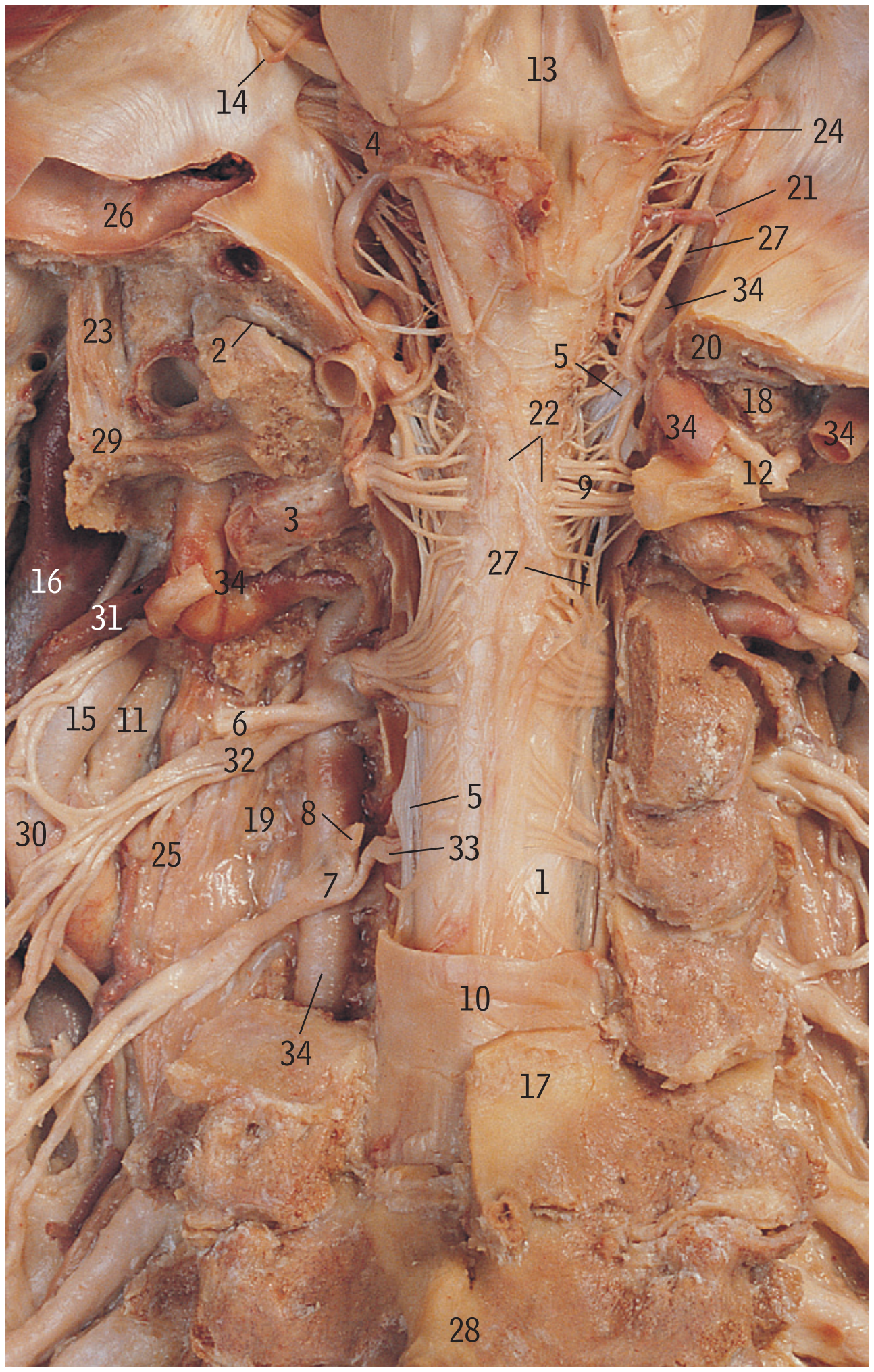

The posterior parts of the skull and upper vertebrae have been removed to show the continuity of the brainstem with the spinal cord, from which dorsal nerve rootlets are seen to emerge (as at 9). The spinal part of the accessory nerve (27) runs up through the foramen magnum (20) to join the cranial part in the jugular foramen (24). Ventral nerve rootlets (as at 33), ventral to the denticulate ligament (5), unite to form a ventral nerve root which joins with a dorsal nerve root (8, whose formative rootlets dorsal to the ligament have been cut off from the cord in order to make the ventral roots visible) to form a spinal nerve immediately beyond the dorsal root ganglion (7). The nerve immediately divides into ventral and dorsal rami (as at 32 and 6).

1 Arachnoid mater
2 Atlanto-occipital joint
3 Capsule of lateral atlanto-axial joint
4 Choroid plexus emerging from lateral recess of fourth ventricle
5 Denticulate ligament
6 Dorsal ramus of third cervical nerve
7 Dorsal root ganglion of fourth cervical nerve
8 Dorsal root of fourth cervical nerve
9 Dorsal rootlets of second cervical nerve
10 Dura mater
11 External carotid artery
12 First cervical nerve and posterior arch of atlas
13 Floor of the fourth ventricle
14 Internal acoustic meatus with facial and vestibulocochlear nerves and labyrinthine artery
15 Internal carotid artery
16 Internal jugular vein
17 Lamina of sixth cervical vertebra
18 Lateral mass of atlas
19 Longus capitis
20 Margin of foramen magnum
21 Posterior inferior cerebellar artery
22 Posterior spinal arteries
23 Rectus capitis lateralis
24 Roots of glossopharyngeal, vagus and cranial part of accessory nerves and jugular foramen
25 Scalenus anterior
26 Sigmoid sinus
27 Spinal part of accessory nerve
28 Spinous process of seventh cervical vertebra
29 Transverse process of atlas
30 Vagus nerve
31 Vein from vertebral venous plexuses
32 Ventral ramus of third cervical nerve
33 Ventral rootlets of fourth cervical nerve
34 Vertebral artery

The lower part of the diamond-shaped floor of the fourth ventricle containing the hypoglossal and vagal triangles (F5 and 17) is part of the medulla oblongata; the rest of the floor is part of the pons.

The gracile and cuneate tubercles (F4 and 1) are caused by the underlying gracile and cuneate nuclei, where the fibres of the gracile and cuneate tracts (posterior white columns) end by synapsing with the cells of the nuclei. The fibres from these cells form the medial lemniscus which runs through the brainstem to the thalamus.

The facial colliculus (F3), at the lower end of the medial eminence (F9) in the floor of the fourth ventricle, is caused by fibres of the facial nerve overlying the abducent nerve nucleus; it is not produced by the facial nerve nucleus, which lies at a deeper level in the pons.

After emerging from the foramen in the transverse process of the atlas the vertebral artery (G34) winds backwards round the lateral mass of the atlas (G18) on its posterior arch before turning upwards to enter the skull, via the foramen magnum.

Cerebral hemispheres A *sectioned horizontally* B *axial MR image*

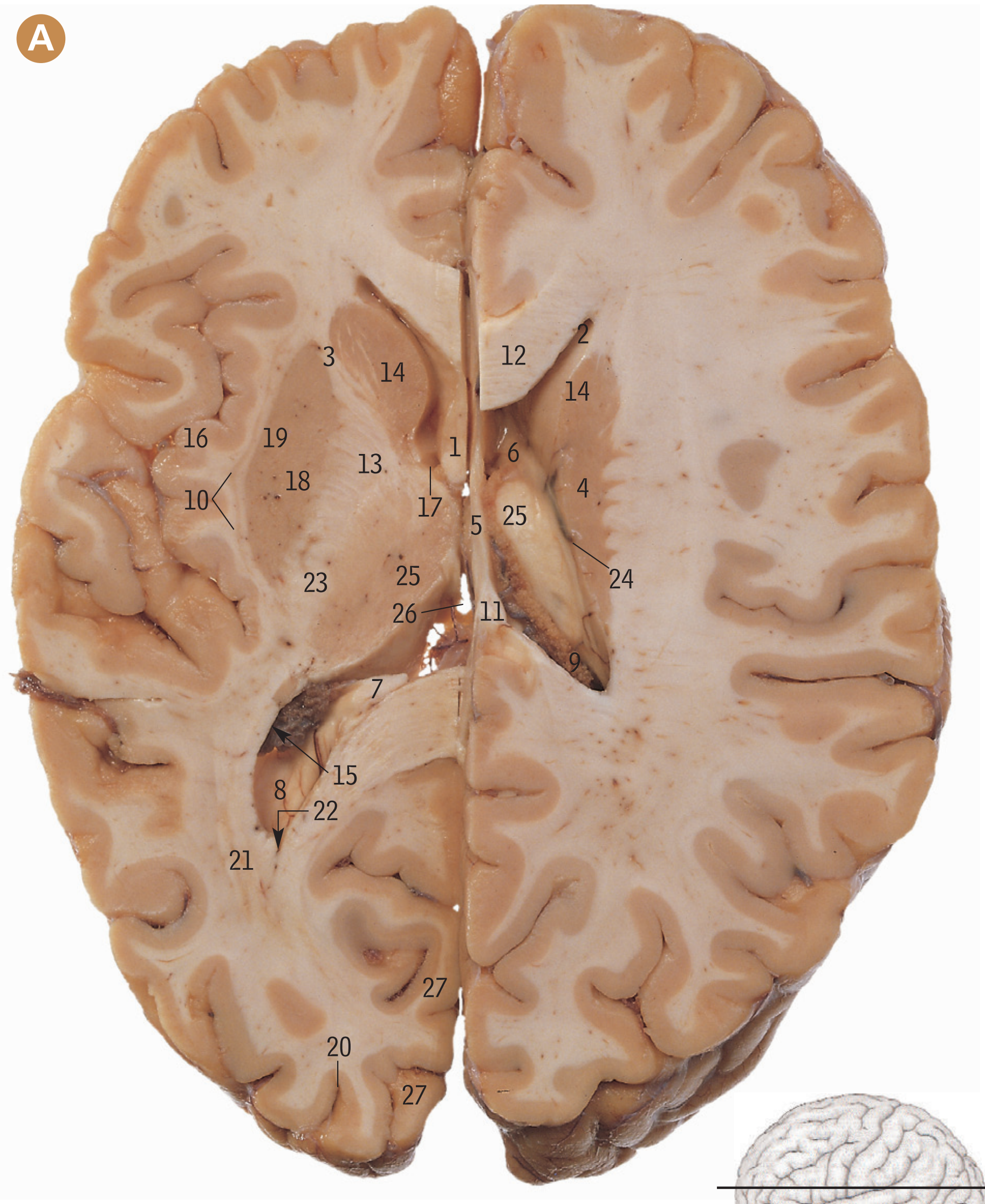

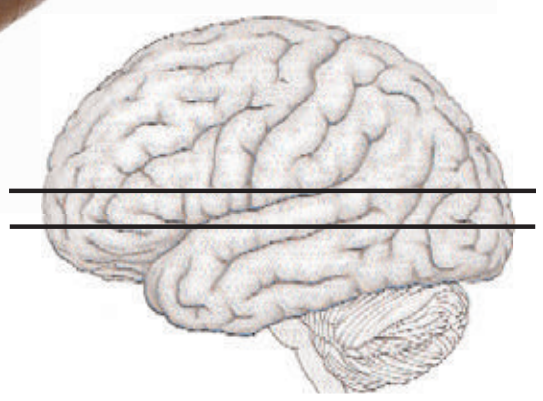

Viewed from above, the left cerebral hemisphere has been sectioned on a level with the interventricular foramen (17), and that on the right about 1.5 cm higher. The most important feature seen in the left hemisphere is the internal capsule (3, 13 and 23), situated between the caudate (14) and lentiform (18 and 19) nuclei and the thalamus (25). On the right side, a large part of the corpus callosum (11) has been removed, so opening up the lateral ventricle (6) from above and showing the caudate nucleus (14 and 4) arching backwards over the thalamus (25), with the thalamostriate vein (24) and choroid plexus (9) in the shallow groove between them.

1 Anterior column of fornix
2 Anterior horn of lateral ventricle
3 Anterior limb of internal capsule
4 Body of caudate nucleus
5 Body of fornix
6 Body of lateral ventricle
7 Bulb
8 Calcar avis
9 Choroid plexus
10 Claustrum
11 Corpus callosum
12 Forceps minor (corpus callosum)
13 Genu of internal capsule
14 Head of caudate nucleus
15 Inferior horn of lateral ventricle
16 Insula
17 Interventricular foramen
18 Lentiform nucleus: globus pallidus
19 Lentiform nucleus: putamen
20 Lunate sulcus
21 Optic radiation
22 Posterior horn of lateral ventricle
23 Posterior limb of internal capsule
24 Thalamostriate vein
25 Thalamus
26 Third ventricle
27 Visual area of cortex

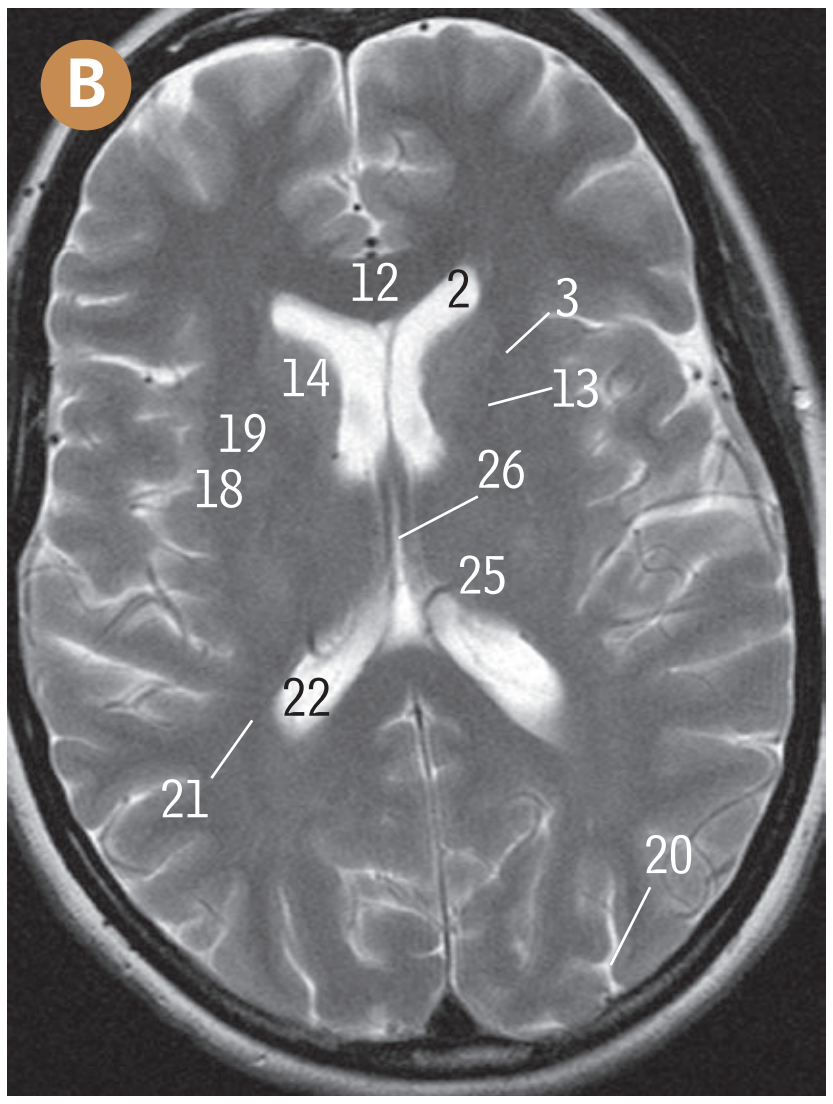

The anterior limb of the internal capsule (3) is bounded medially by the head of the caudate nucleus (14) and laterally by the lentiform nucleus (putamen and globus pallidus, 18 and 19).

The genu of the internal capsule (13) lies at the most medial edge of the globus pallidus (18).

The posterior limb of the internal capsule (23) is bounded medially by the thalamus (25) and laterally by the lentiform nucleus (18 and 19).

Corticonuclear fibres (motor fibres from the cerebral cortex to the motor nuclei of cranial nerves) pass through the genu of the internal capsule (13).

Corticospinal fibres (motor fibres from the cerebral cortex to anterior horn cells of the spinal cord) pass through the anterior two-thirds of the posterior limb of the internal capsule (23).

The genu and the posterior limb of the internal capsule, supplied by the striate branches of the anterior and middle cerebral arteries and by the anterior choroidal artery, are of the greatest clinical importance as they are the common sites for cerebral haemorrhage or thrombosis ('stroke').

Brain A coronal section, from the front B coronal MR image

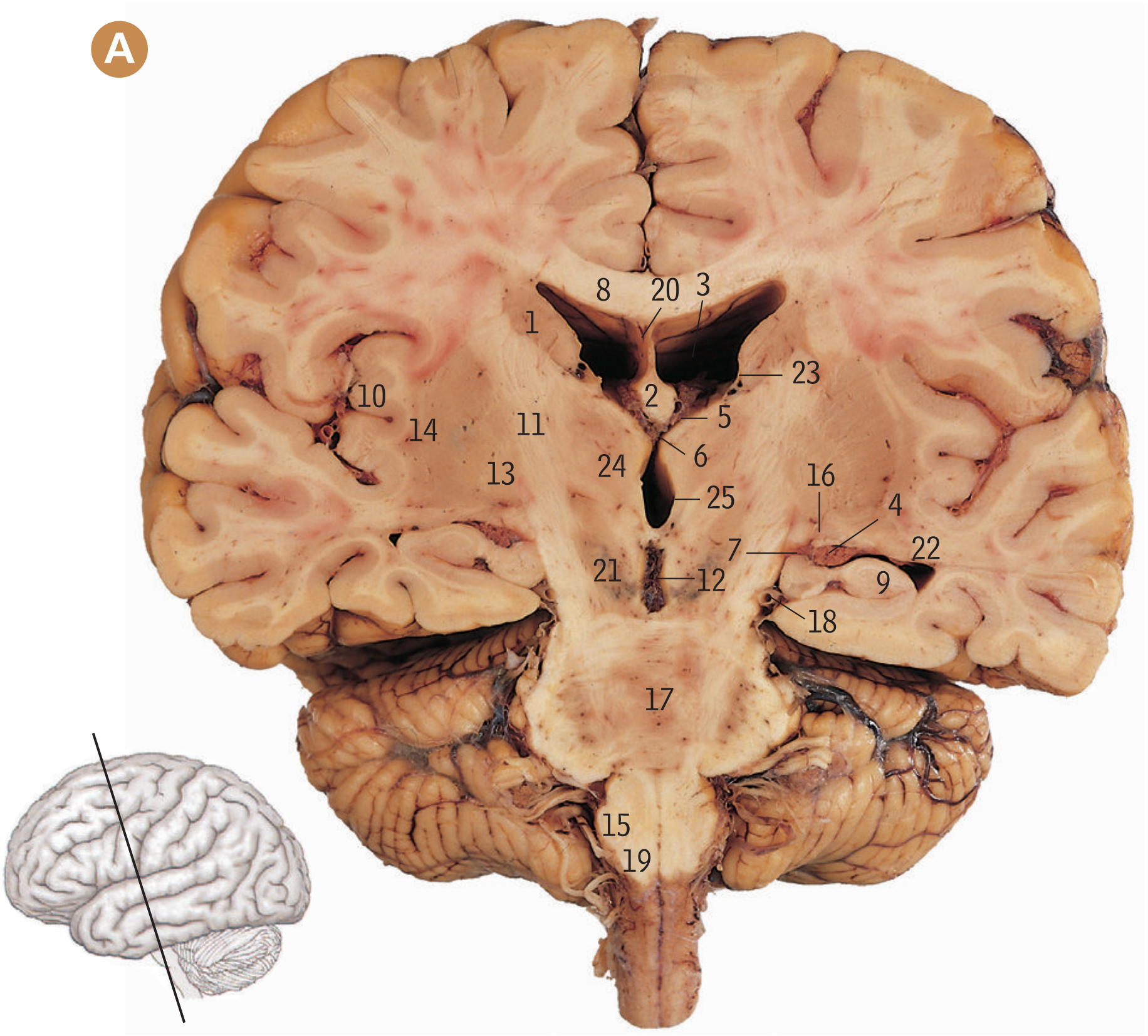

This coronal section is not quite vertical but passes slightly backwards, through the third ventricle (25) and bodies of the lateral ventricles (3) from a level about 0.5 cm behind the interventricular foramina, and down through the pons (17) and the pyramid of the medulla (19). It has been cut in this way to show the path of the important corticospinal (motor) fibres passing down through the internal capsule (11) and pons (17) to form the pyramid of the medulla (19). Compare with features in the MR image.

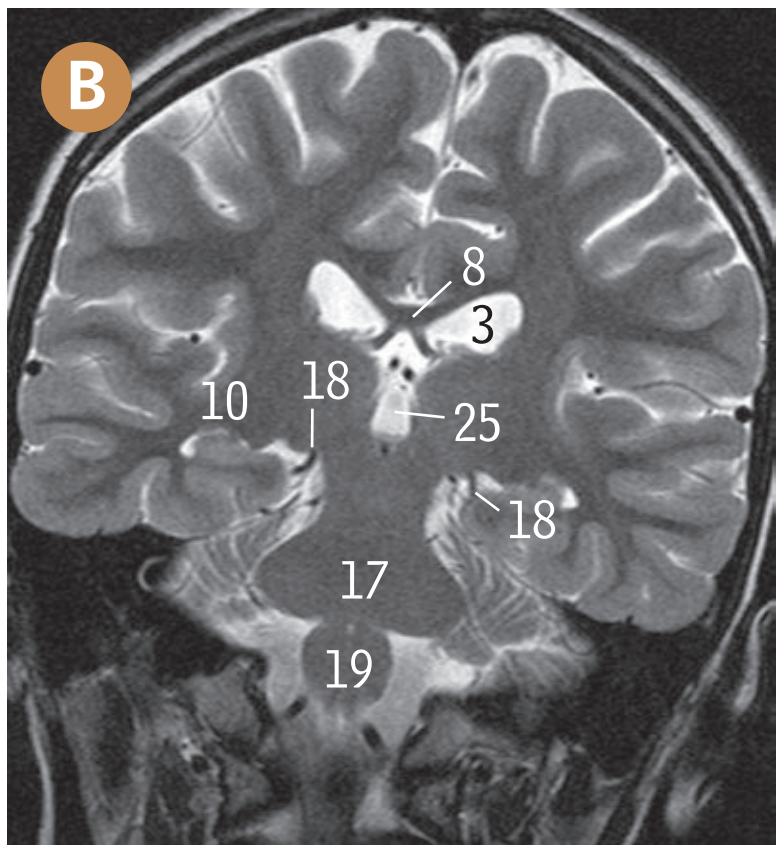

1 Body of caudate nucleus
2 Body of fornix
3 Body of lateral ventricle
4 Choroid plexus of inferior horn of lateral ventricle
5 Choroid plexus of lateral ventricle
6 Choroid plexus of third ventricle
7 Choroidal fissure
8 Corpus callosum
9 Hippocampus
10 Insula
11 Internal capsule
12 Interpeduncular cistern
13 Lentiform nucleus: globus pallidus
14 Lentiform nucleus: putamen
15 Olive of medulla oblongata
16 Optic tract
17 Pons
18 Posterior cerebral artery
19 Pyramid of medulla oblongata
20 Septum pellucidum
21 Substantia nigra
22 Tail of caudate nucleus
23 Thalamostriate vein
24 Thalamus
25 Third ventricle

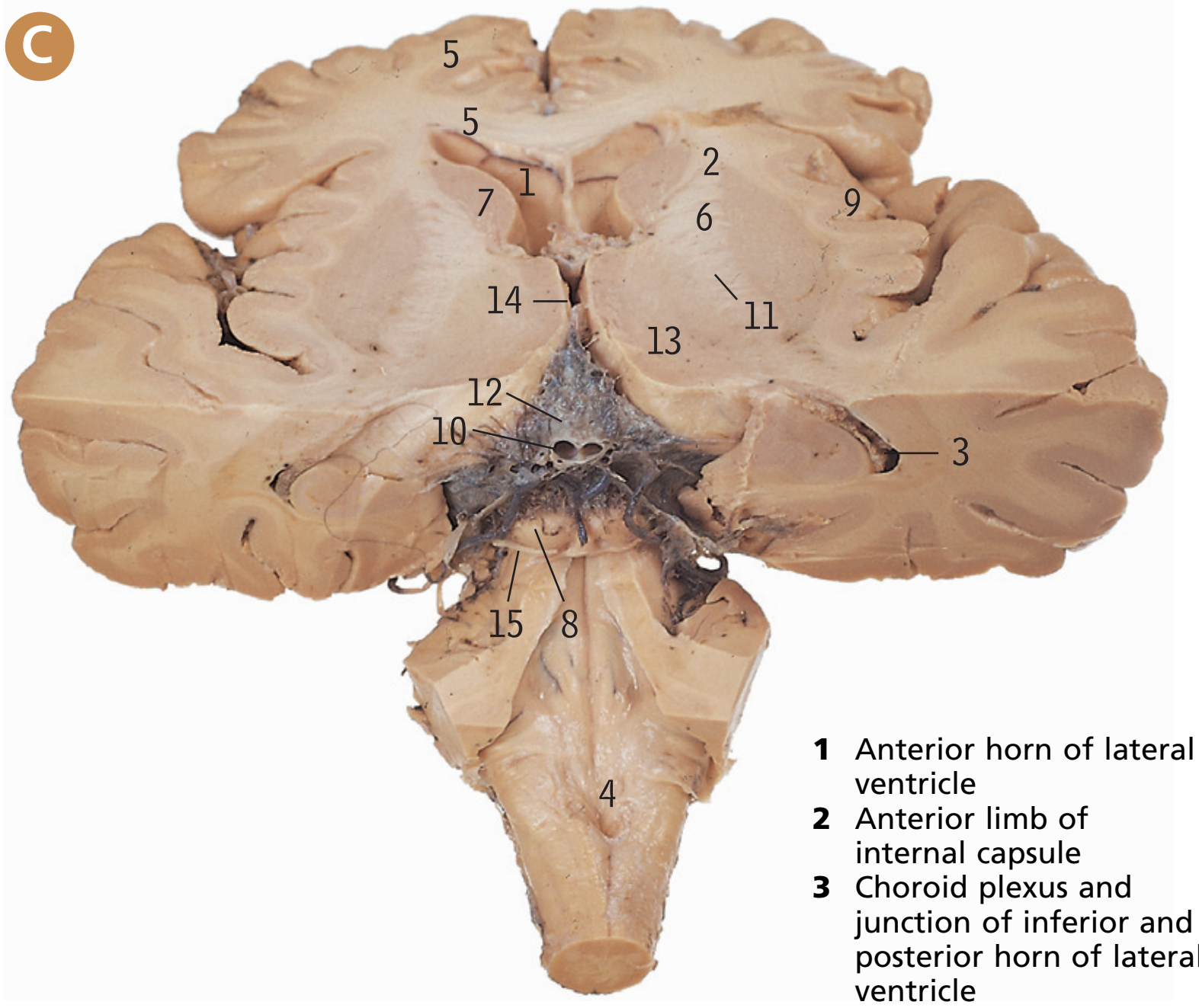

C Sectioned cerebral hemispheres and the brainstem

from above and behind

The cerebral hemispheres have been sectioned horizontally just above the level of the interventricular foramina, and the posterior parts of the hemispheres have been removed, together with the whole of the cerebellum, to show the tela choroidea (12) of the posterior part of the roof of the third ventricle and the underlying internal cerebral veins (10).

1 Anterior horn of lateral ventricle
2 Anterior limb of internal capsule
3 Choroid plexus and junction of inferior and posterior horn of lateral ventricle
4 Floor of fourth ventricle
5 Forceps minor
6 Genu of internal capsule
7 Head of caudate nucleus
8 Inferior colliculus
9 Insula
10 Internal cerebral vein
11 Posterior limb of internal capsule
12 Tela choroidea of roof of third ventricle
13 Thalamus
14 Third ventricle
15 Trochlear nerve

Arteriovenous fistulae, see pages 80–82.

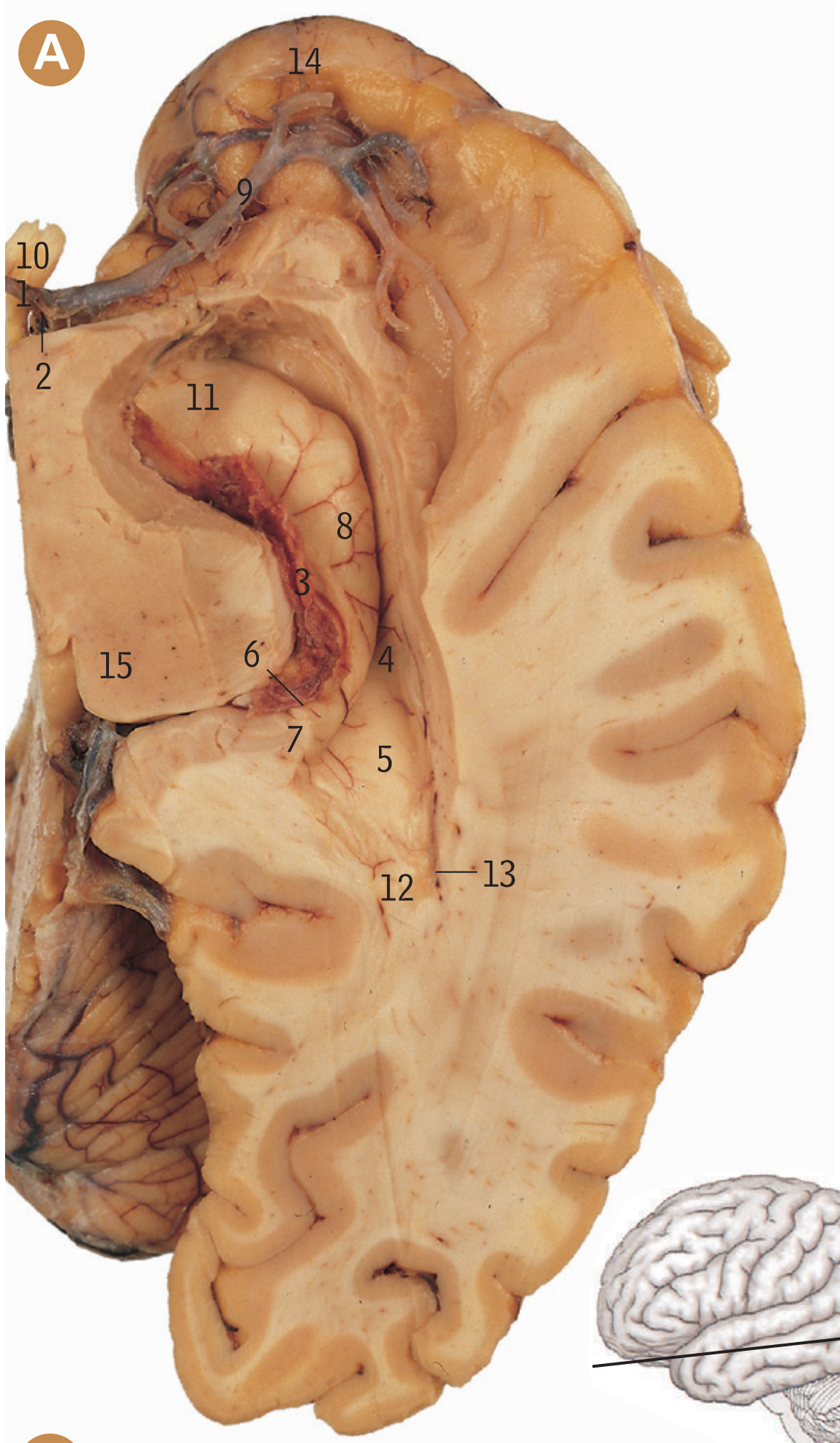

A Inferior horn of right lateral ventricle

Brain substance above the front part of the lateral sulcus has been removed, displaying the middle cerebral artery (9) running laterally over the upper surface of the front of the temporal lobe (14). Part of the temporal lobe has been opened up from above to show the hippocampus (11 and 8) in the floor of the inferior horn.

1 Anterior cerebral artery
2 Anterior choroidal artery
3 Choroid plexus
4 Collateral eminence
5 Collateral trigone
6 Fimbria
7 Fornix
8 Hippocampus
9 Middle cerebral artery
10 Optic nerve
11 Pes hippocampi
12 Posterior horn
13 Tapetum
14 Temporal pole of temporal lobe
15 Thalamus

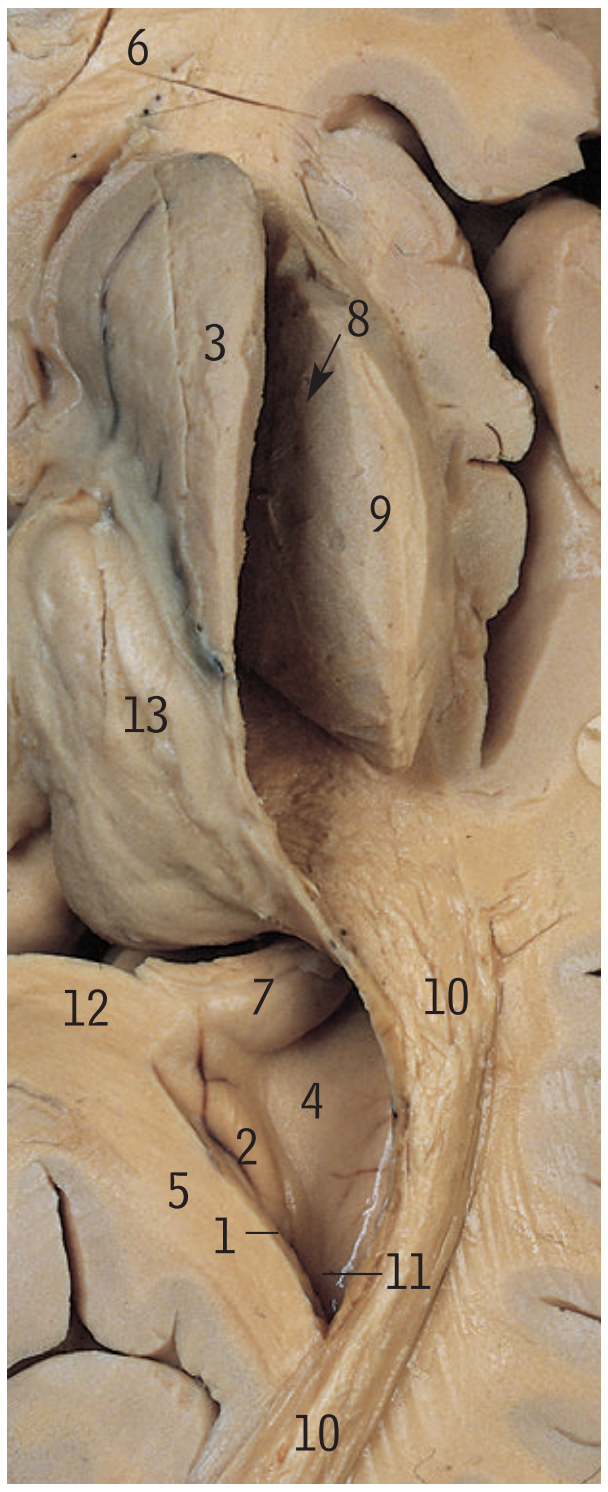

B Right cerebral hemisphere dissection *from above*

Much of the cerebral substance has been dissected away to show the caudate nucleus (3), thalamus (13) and lentiform nucleus (9). The intervening gap (8) is occupied by the internal capsule. The optic radiation (10) has also been dissected out; it runs backwards lateral to the posterior horn of the lateral ventricle. Compare this three-dimensional view of these structures with the brain section in the Systemic Review on studentconsult.com.

1 Bulb
2 Calcar avis
3 Caudate nucleus
4 Collateral trigone
5 Forceps major
6 Forceps minor
7 Fornix
8 Internal capsule
9 Lentiform nucleus
10 Optic radiation
11 Posterior horn of lateral ventricle
12 Splenium of corpus callosum
13 Thalamus

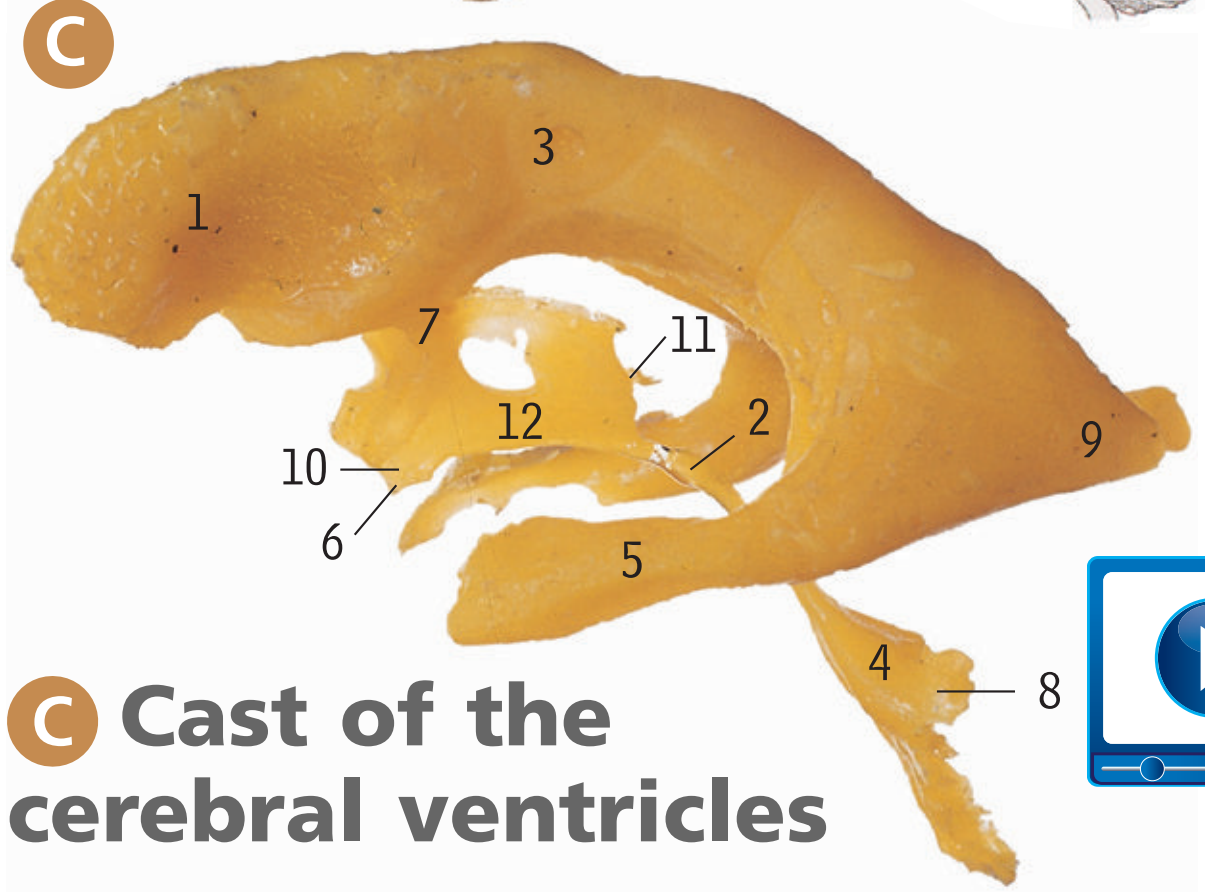

C Cast of the cerebral ventricles *from the left*

In this side view, the left lateral ventricle largely overlaps the right one.

1 Anterior horn of lateral ventricle
2 Aqueduct of midbrain
3 Body of lateral ventricle
4 Fourth ventricle
5 Inferior horn of lateral ventricle
6 Infundibular recess of third ventricle
7 Interventricular foramen
8 Lateral recess
9 Posterior horn of lateral ventricle
10 Supra-optic recess of third ventricle
11 Suprapineal recess of third ventricle
12 Third ventricle (with gap for interthalamic connexion)

The third ventricle (C12) communicates at its upper front end with each lateral ventricle through the interventricular foramen (C7).

The main part of the lateral ventricle is the body (C3). The part in front of the interventricular foramen (C7) is the anterior horn (C1), which extends into the frontal lobe of the brain. At its posterior end, the body divides into the posterior horn (C9), which extends backwards into the occipital lobe, and the inferior horn (C5), which passes downwards and forwards into the temporal lobe.

The lower posterior part of the third ventricle (C12) communicates with the fourth ventricle (C4) through the aqueduct of the midbrain (C2).

The floor of the inferior horn consists of the hippocampus (A11 and 8) medially and the collateral eminence (A4) laterally. At its junction with the posterior horn (A12 and B11) the eminence broadens into the collateral trigone (A5, B4).

The collateral eminence (A4) is produced by the inward projection of the collateral sulcus.

In the medial wall of the posterior horn, the bulb (B1) is produced by fibres of the corpus callosum, and the calcar avis (B2) by the inward projection of the calcarine sulcus.

A Cranial nerve *I – olfactory*

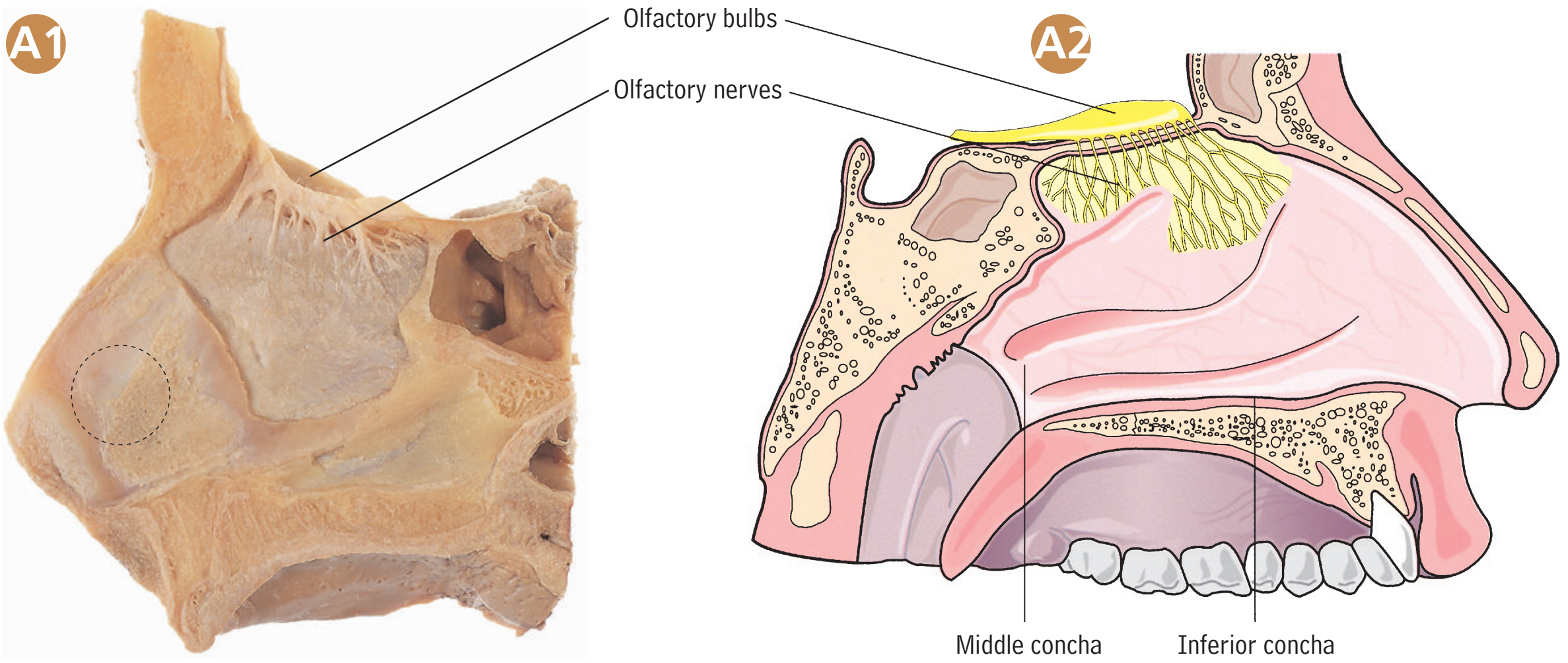

See pages 58, 64 and 65.

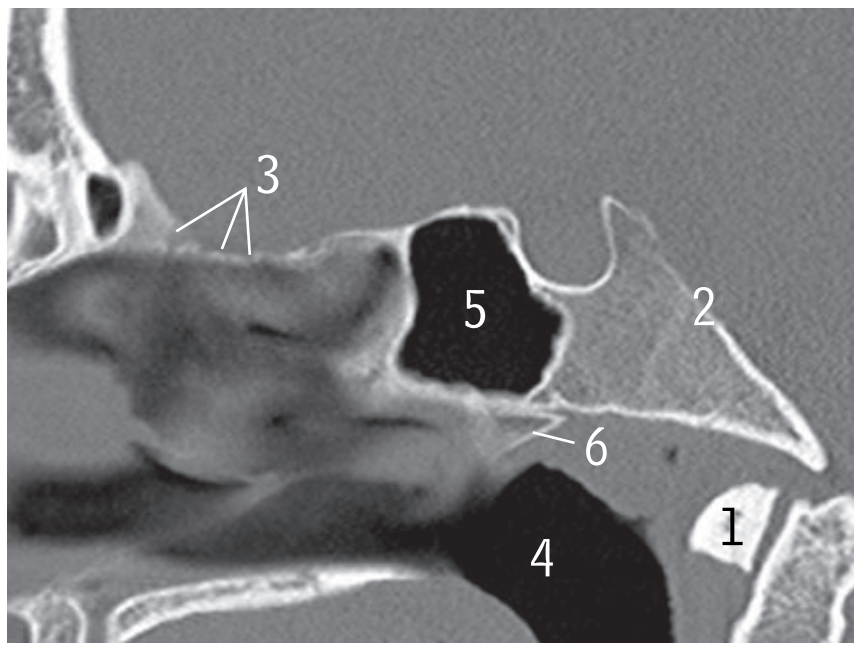

1 Anterior arch of C1
2 Clivus
3 Cribriform plate
4 Nasopharynx
5 Sphenoidal air sinus
6 Vomer

Endoscopy of olfactory mucosa

B Cranial nerve *II – optic* *(seen from above)*

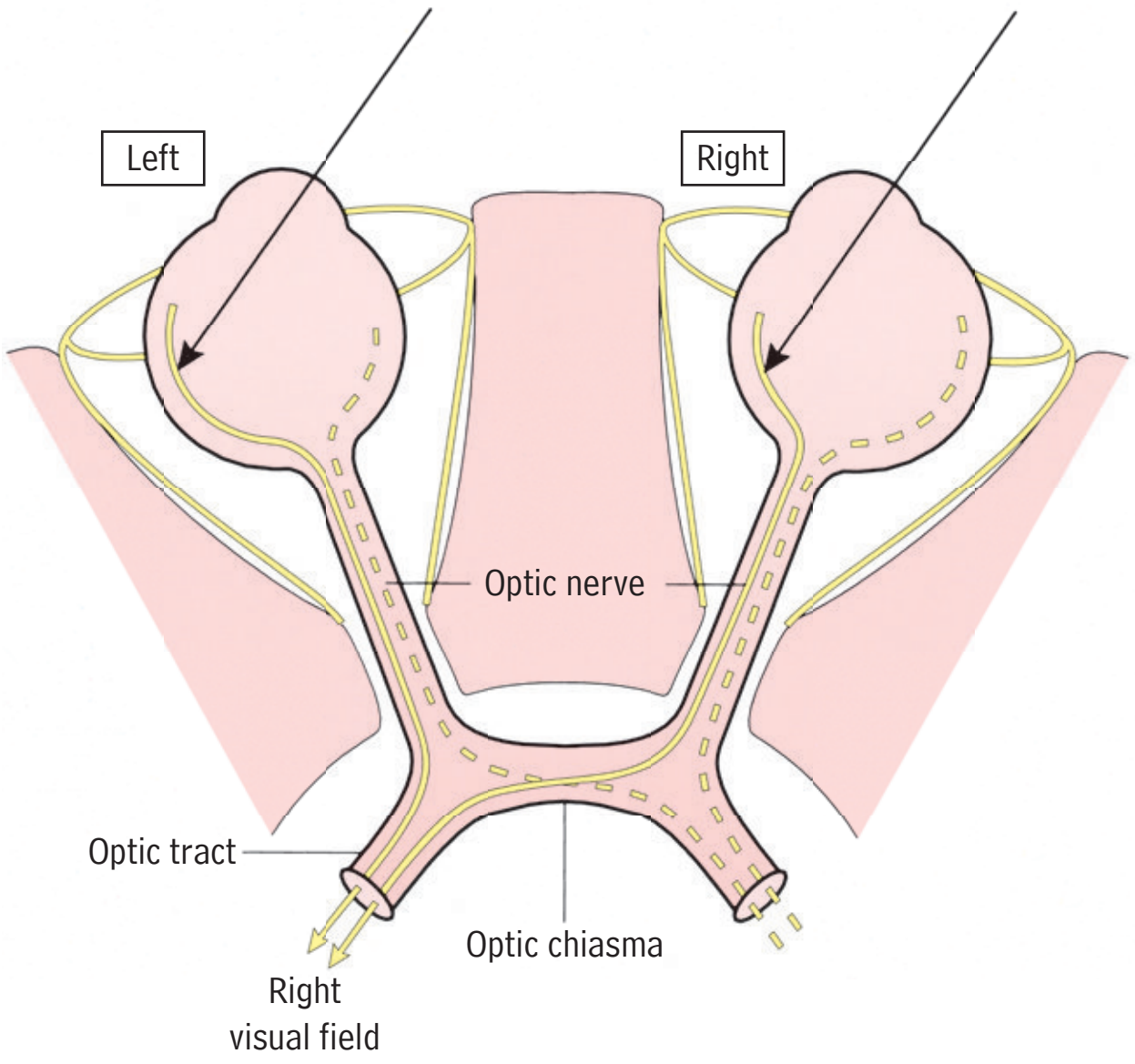

See pages 53, 57, 58 and 65.

C Fundus of eye

ophthalmoscopic photograph of a retina

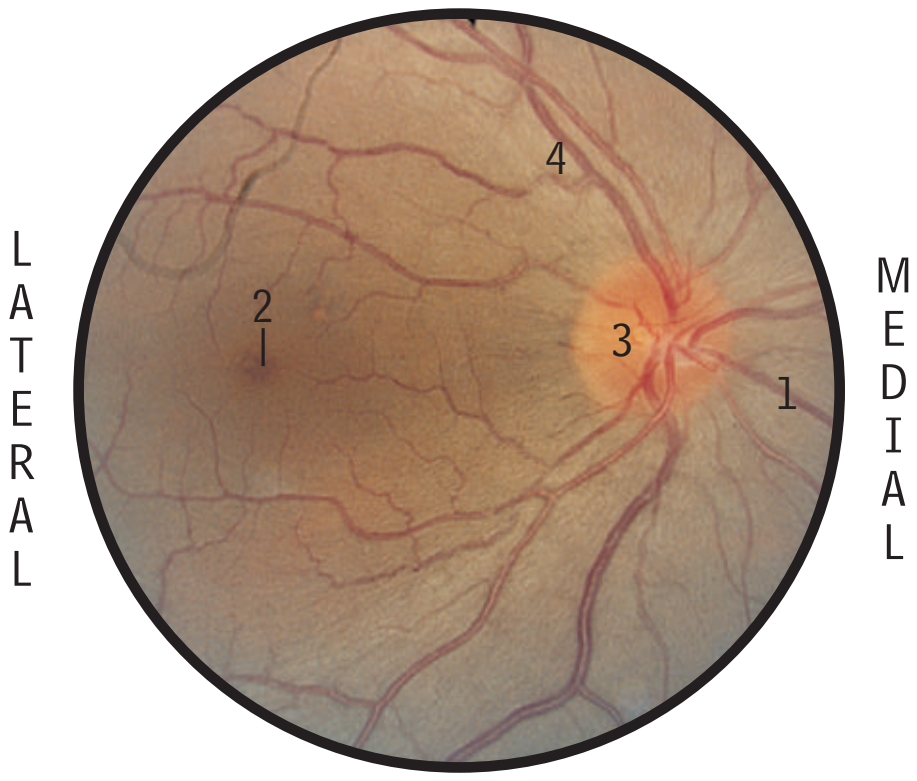

1 Inferior nasal branches of central vein and artery
2 Macula with central fovea
3 Optic disc
4 Superior temporal branches of central vein and artery

Anosmia, epistaxis, ophthalmoscopy, retinoscopy, tonsillitis, see pages 80–82.

Cranial nerves *III – oculomotor, IV – trochlear, VI – abducent*

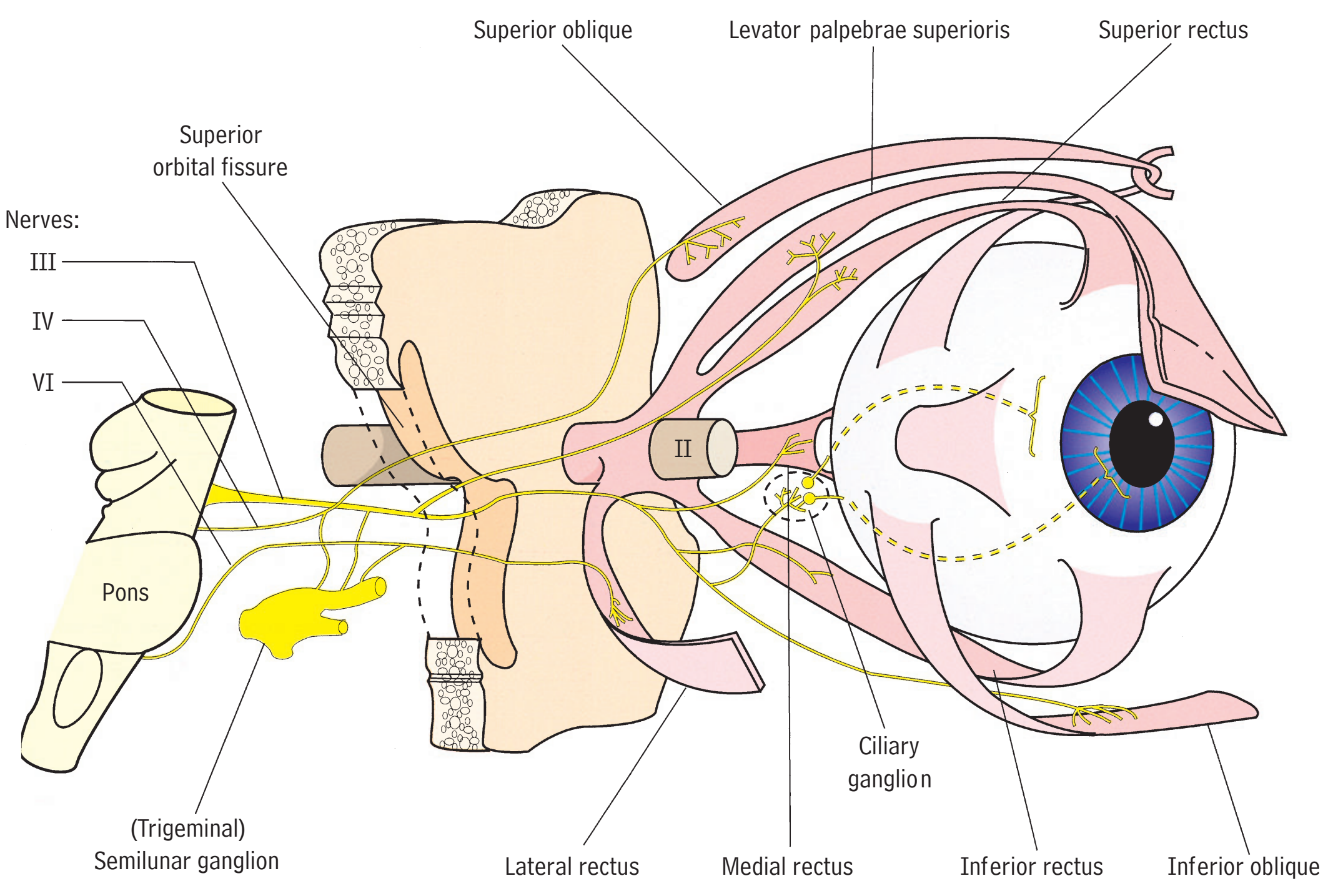

See pages 53, 54–57 and 65 for III.
See pages 54–57 and 65 for IV.
See pages 53, 54–57 and 65 for VI.

Ciliary ganglion

1 Abducent nerve
2 Ciliary ganglion
3 Eyeball
4 Frontal nerve
5 Inferior oblique
6 Inferior rectus
7 Infra-orbital artery
8 Infra-orbital nerve
9 Lacrimal artery
10 Lateral rectus, reflected
11 Levator palpebrae superioris
12 Maxillary artery
13 Maxillary branch of trigeminal nerve
14 Nasociliary nerve
15 Nerve to inferior rectus
16 Oculomotor nerve
17 Ophthalmic artery
18 Optic nerve in anterior cranial fossa
19 Optic nerve in orbit
20 Sensory root to ciliary ganglion
21 Short ciliary arteries
22 Short ciliary nerves
23 Sphenopalatine nerve
24 Superior rectus
25 Supra-orbital nerve
26 Supratrochlear nerve

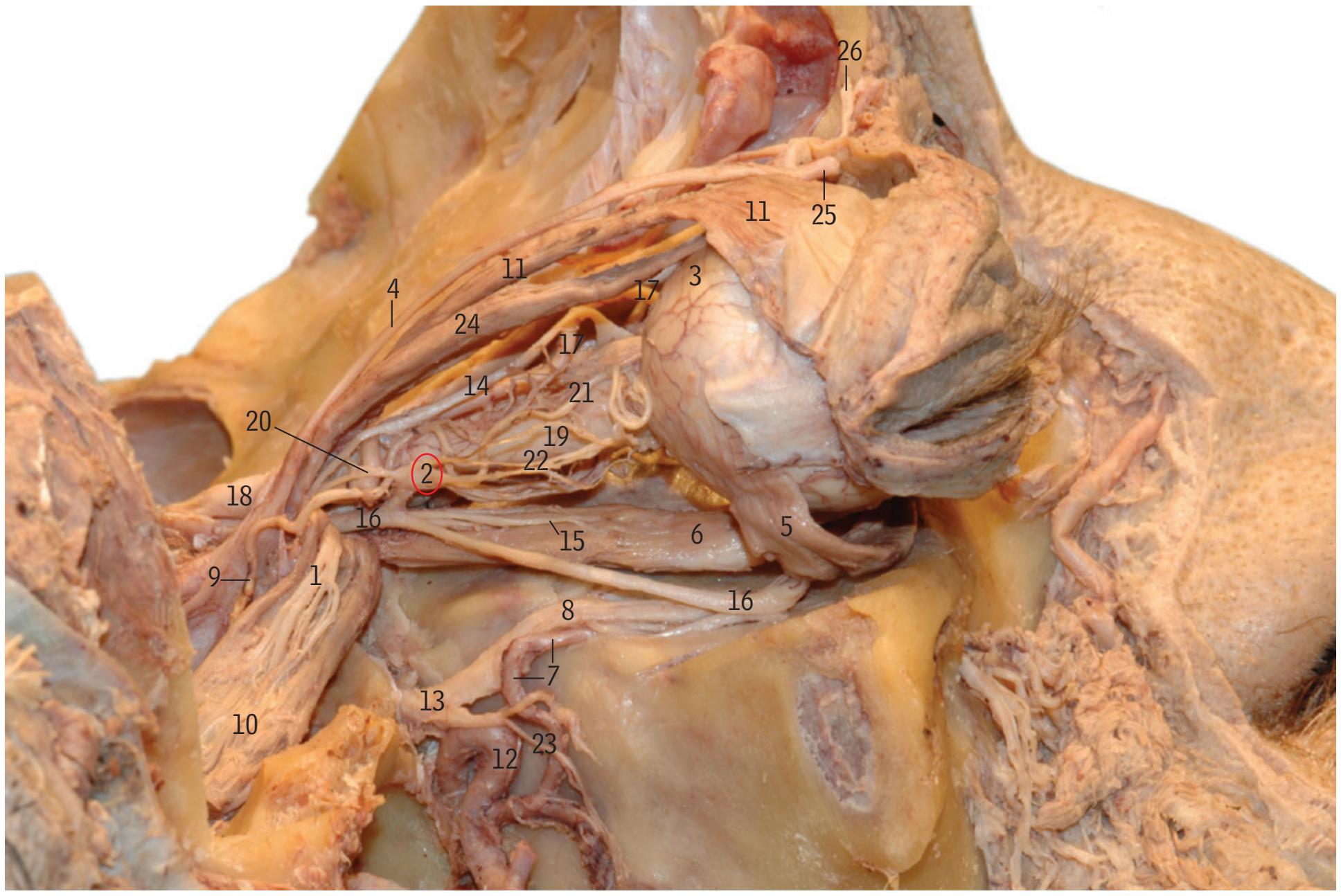

Abducent nerve palsy, accommodation reflex, oculomotor nerve palsy, trochlear nerve palsy, see pages 80–82.

Cranial nerve
A V – trigeminal (overview)

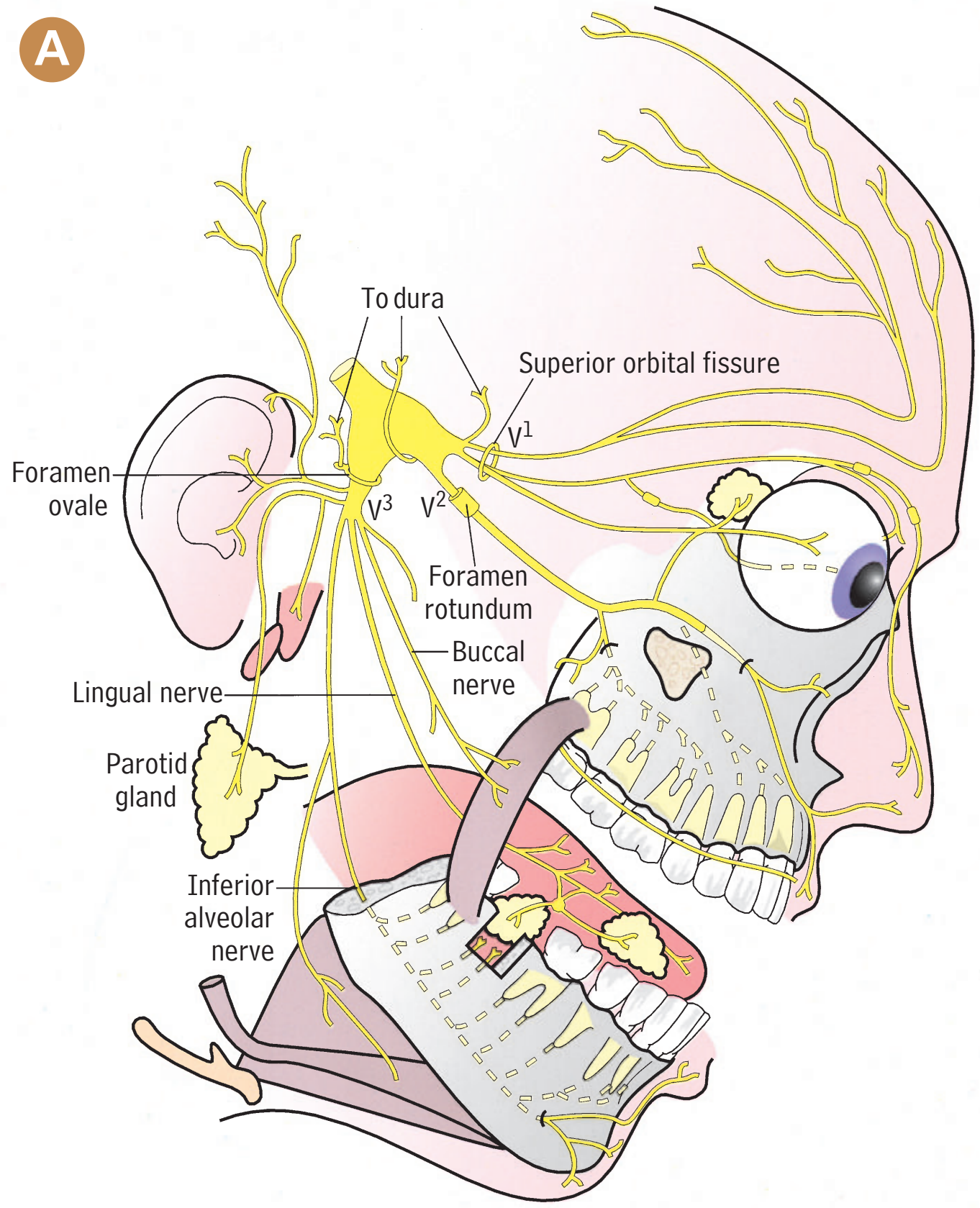

B V¹ ophthalmic division of trigeminal

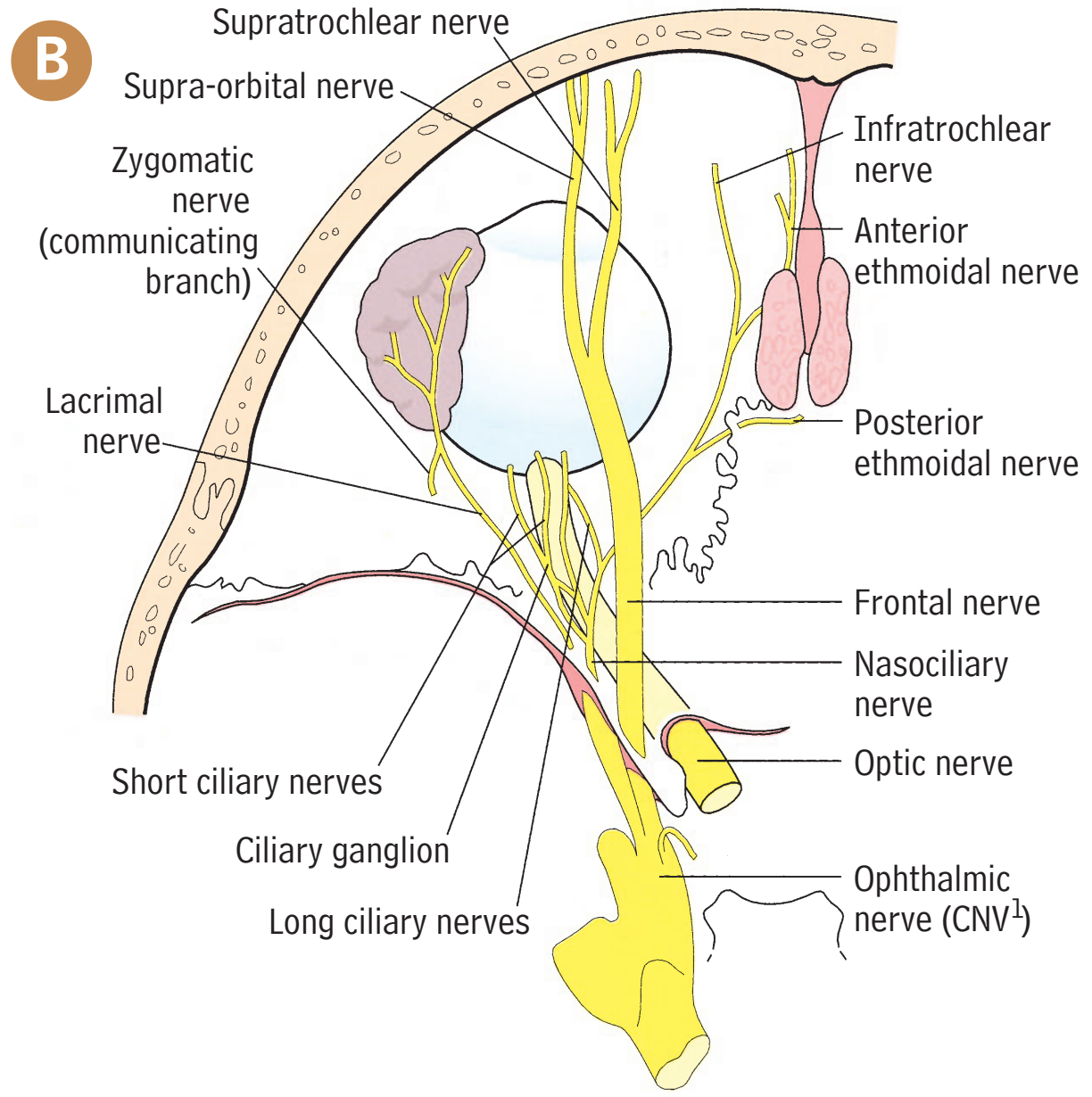

See pages 44 and 51 for V.
See pages 44, 51 and 54–57 for V¹.

C V² maxillary division of trigeminal

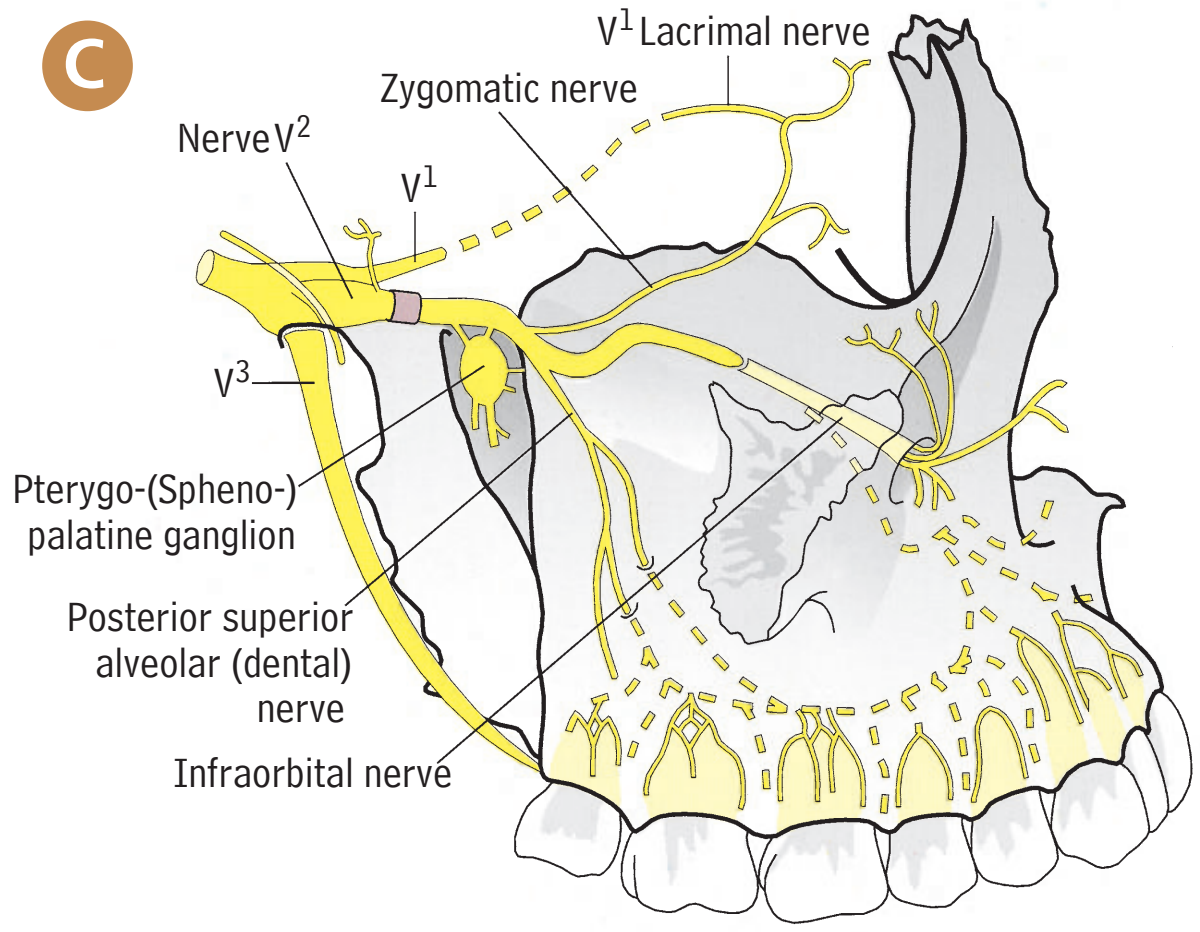

See pages 44 and 51 for V².
See pages 42, 44, 59 and 76 for V³.

D V³ mandibular division of trigeminal

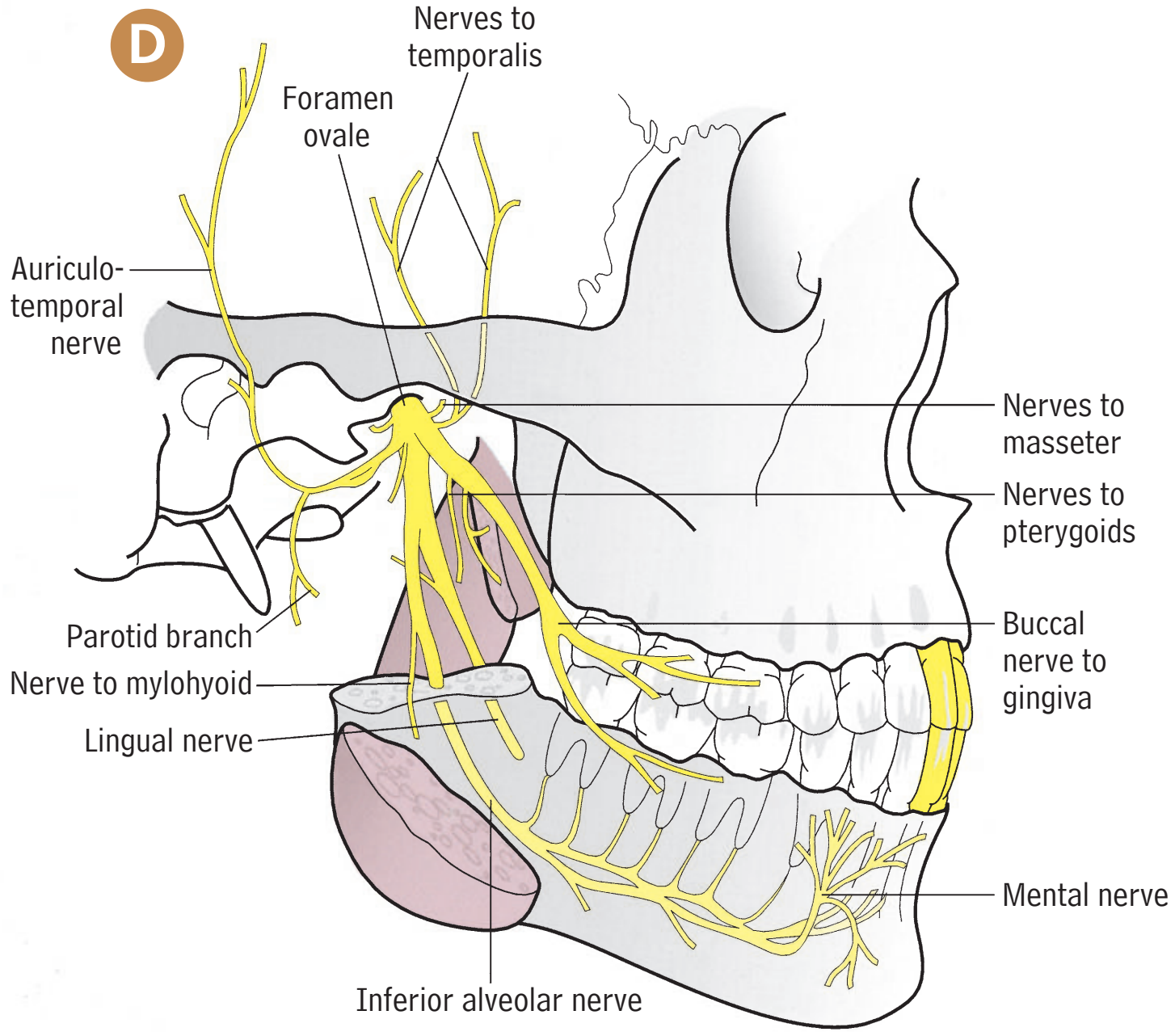

Trigeminal nerve *branches and associated parasympathetic ganglia*

1 Auriculotemporal nerve
2 Chorda tympani
3 Ciliary ganglion
4 Deep temporal nerve
5 Dura mater
6 Inferior alveolar nerve within canal
7 Infra-orbital nerve
8 Lingual nerve
9 Mandibular nerve
10 Maxillary air sinus (opened)
11 Maxillary artery
12 Maxillary nerve
13 Mental nerve
14 Middle meningeal artery
15 Nerve to lateral pterygoid
16 Nerve to masseter
17 Otic ganglion
18 Parotid gland
19 Posterior superior alveolar nerves
20 Pterygopalatine ganglion
21 Retromandibular vein
22 Supra-orbital nerve
23 Supratrochlear nerve

A Cranial nerve *VII – facial*

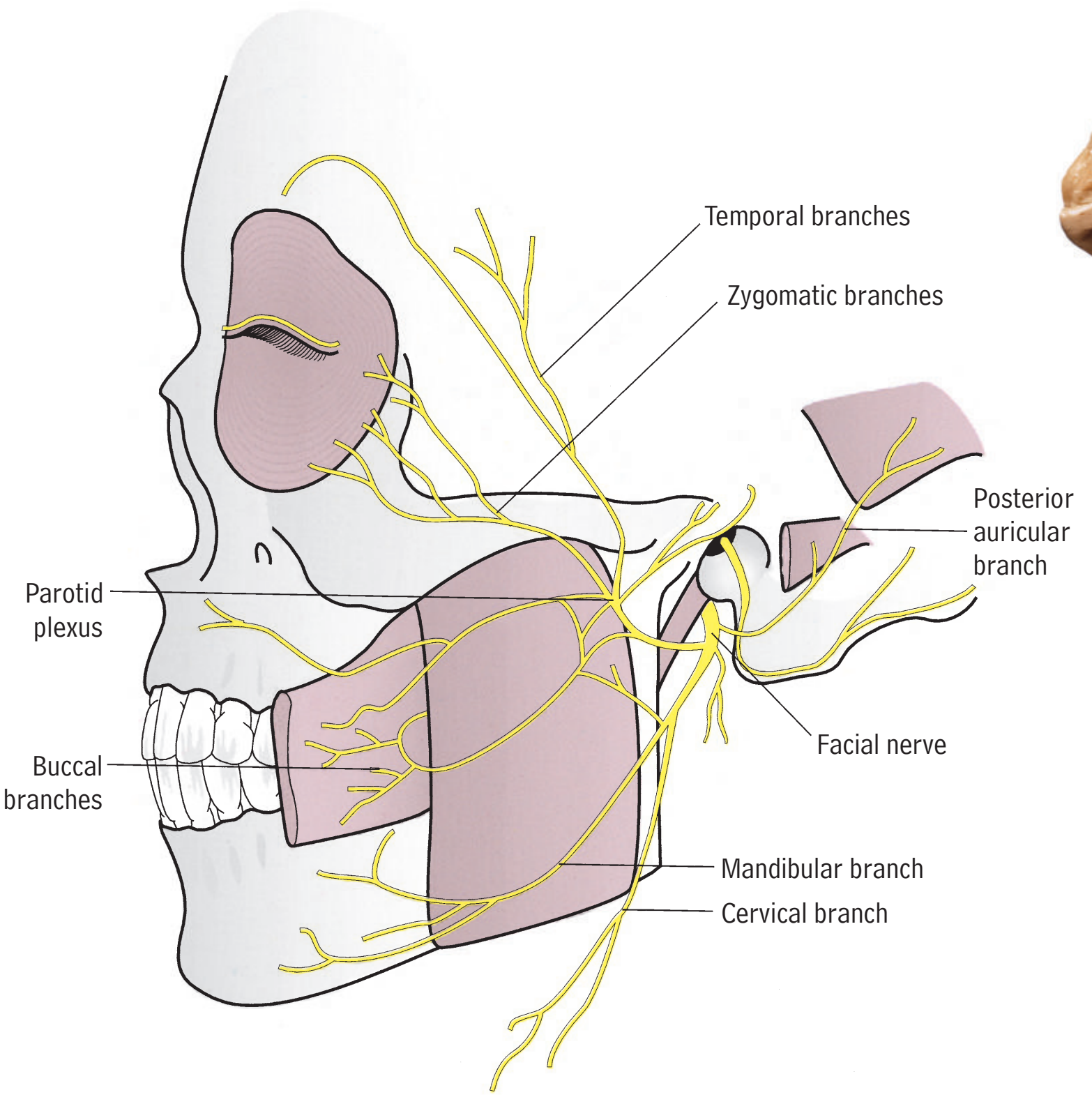

B Nasal cartilage

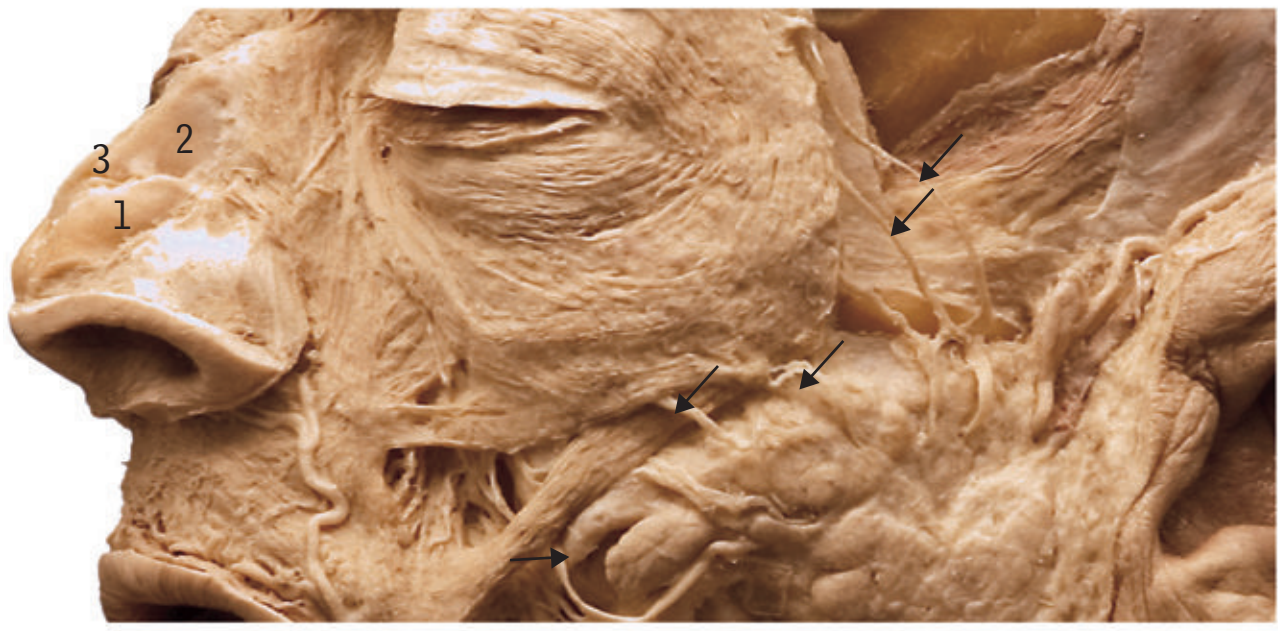

1 Lateral crus of alar cartilage
2 Lateral nasal cartilage
3 Septal angle

NB: Facial nerve branches exit the parotid gland (arrows).

See pages 39–41, 53, 61 and 67.

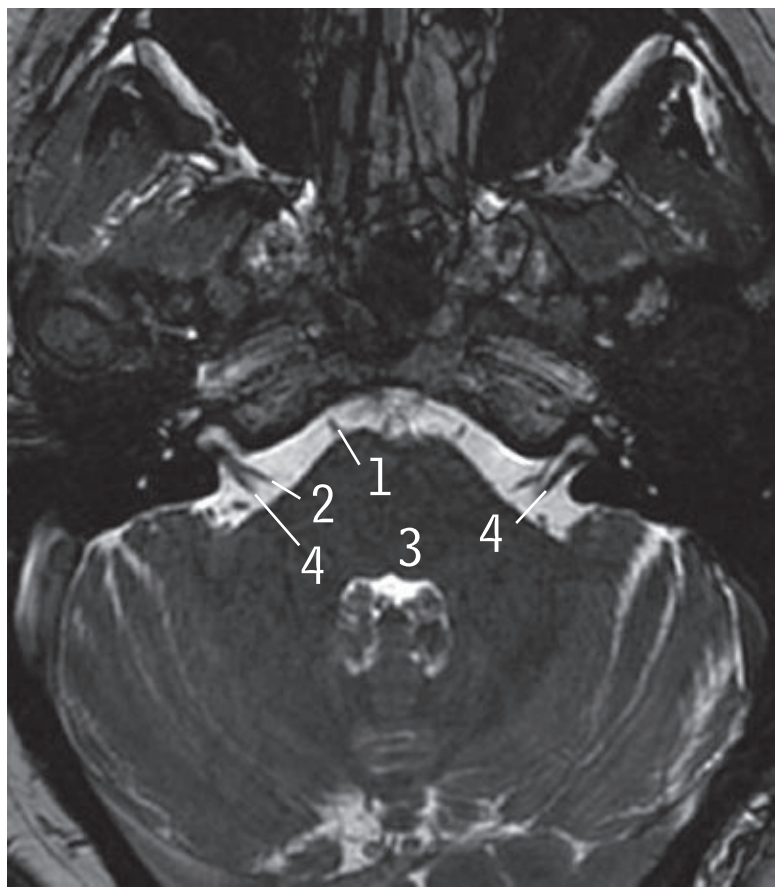

Axial MR, level of pontomedullary junction

1 Abducent nerve (CN VI)
2 Facial nerve (CN VII)
3 Pons
4 Vestibulocochlear nerve (CN VIII)

C Cranial nerve *VIII – vestibulocochlear*

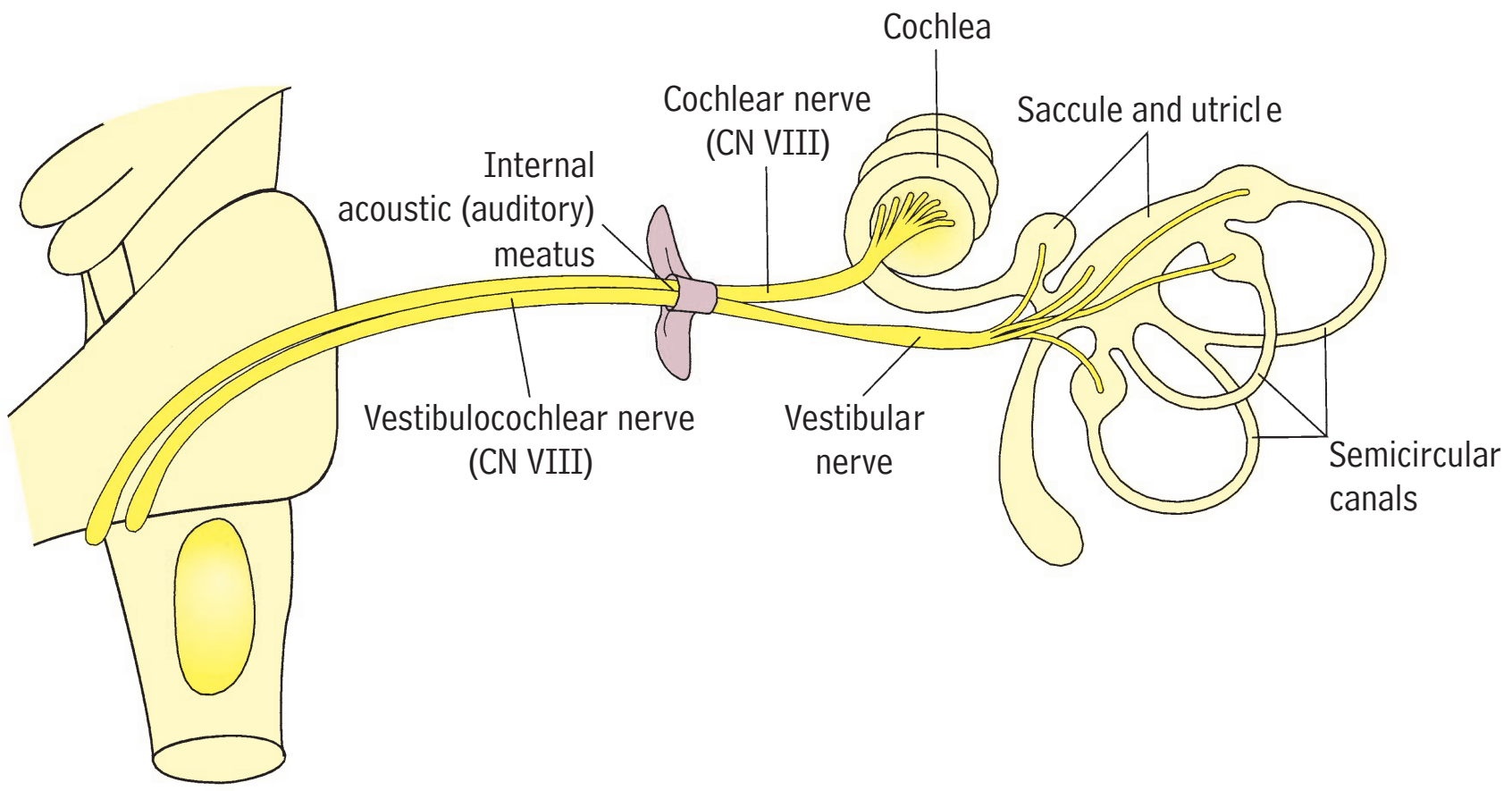

See pages 51, 53, 61 and 67.

Acoustic neuroma, facial nerve palsy, hyperacusis, otalgia, see pages 80–82.

Cranial nerve **A** *IX – glossopharyngeal* **B** *X – vagus*

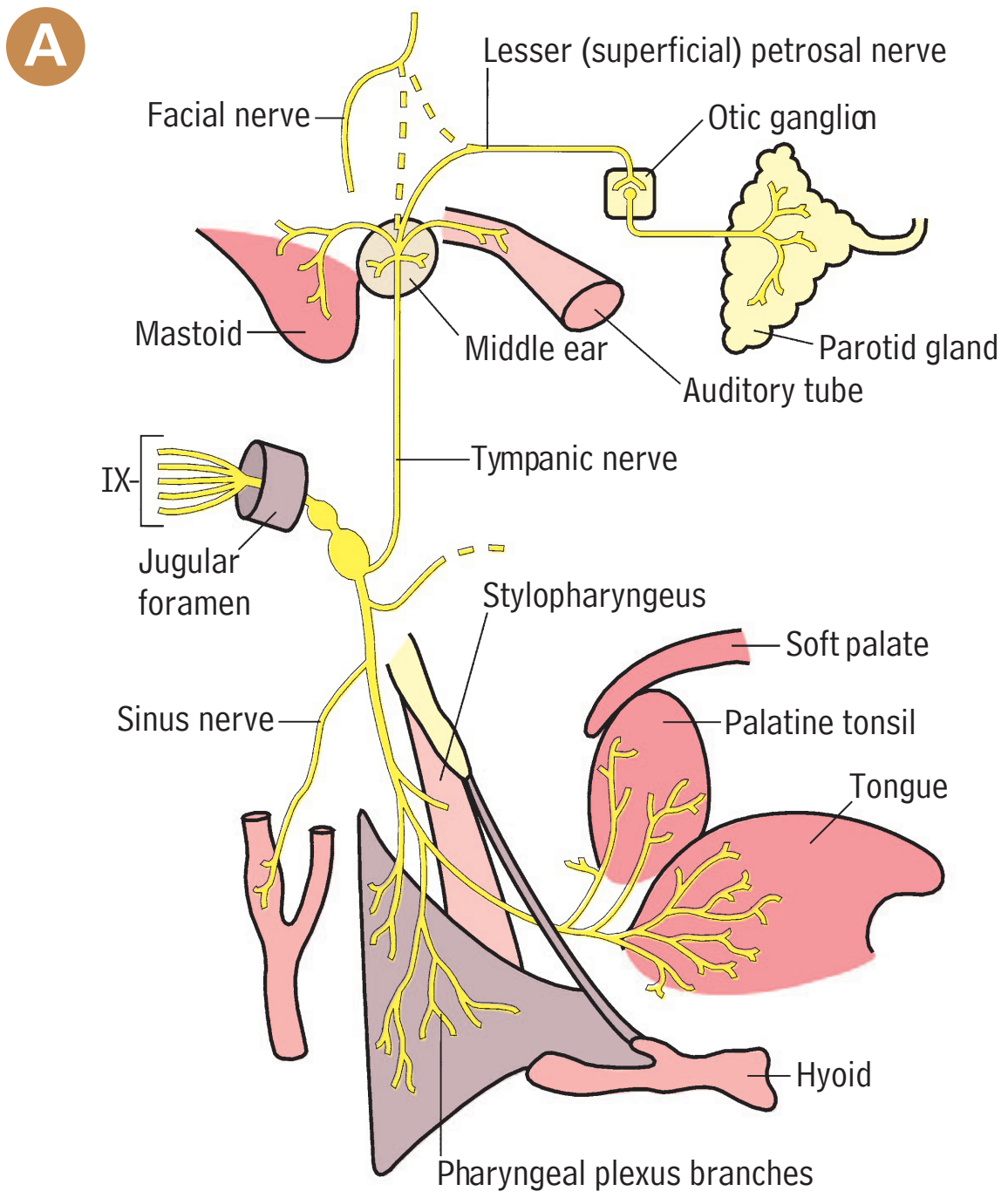

See pages 44–47, 53 and 67.

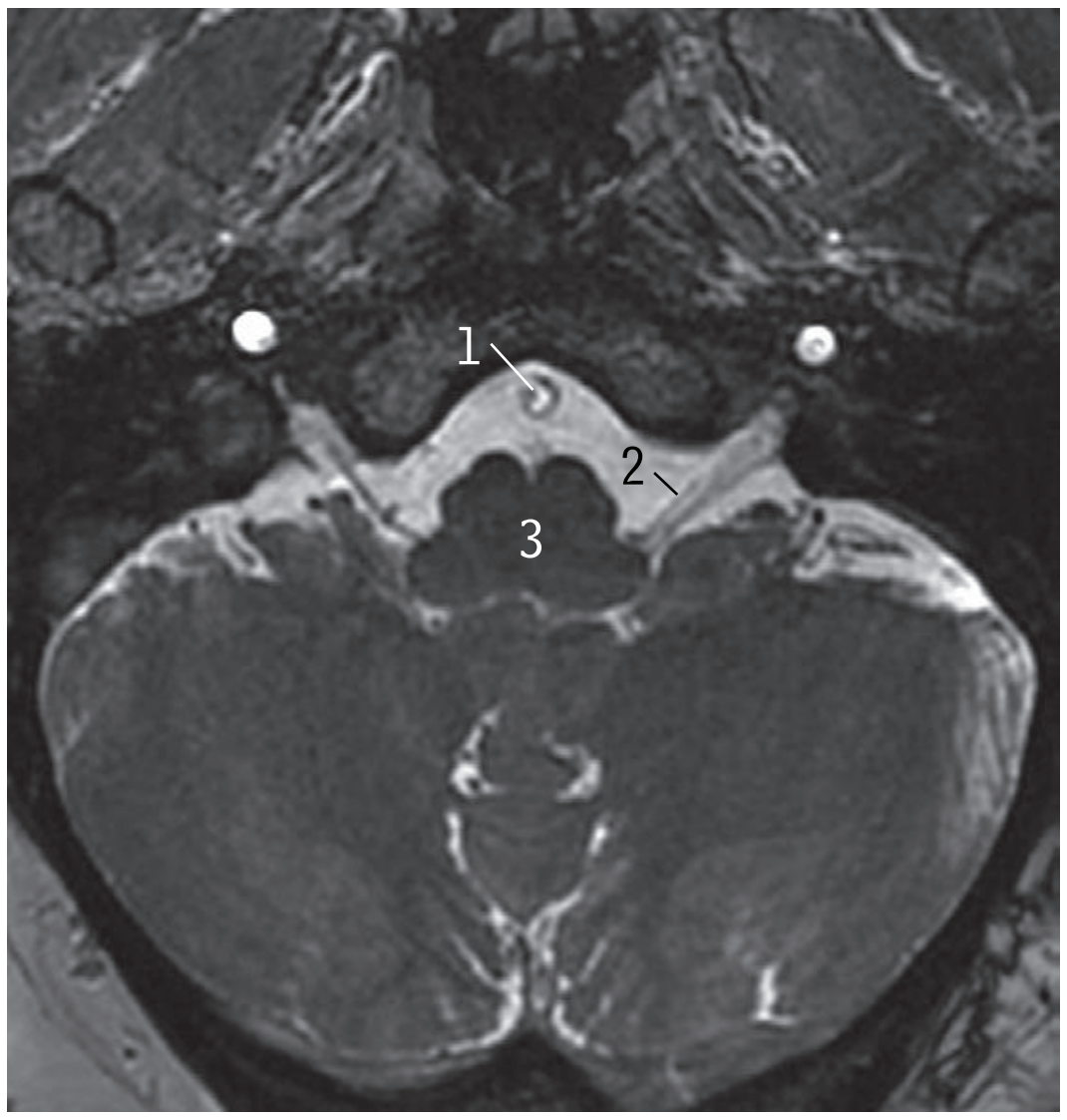

Axial MR, upper medulla

1 Basilar artery
2 Hypoglossal nerve rootlets
3 Medulla

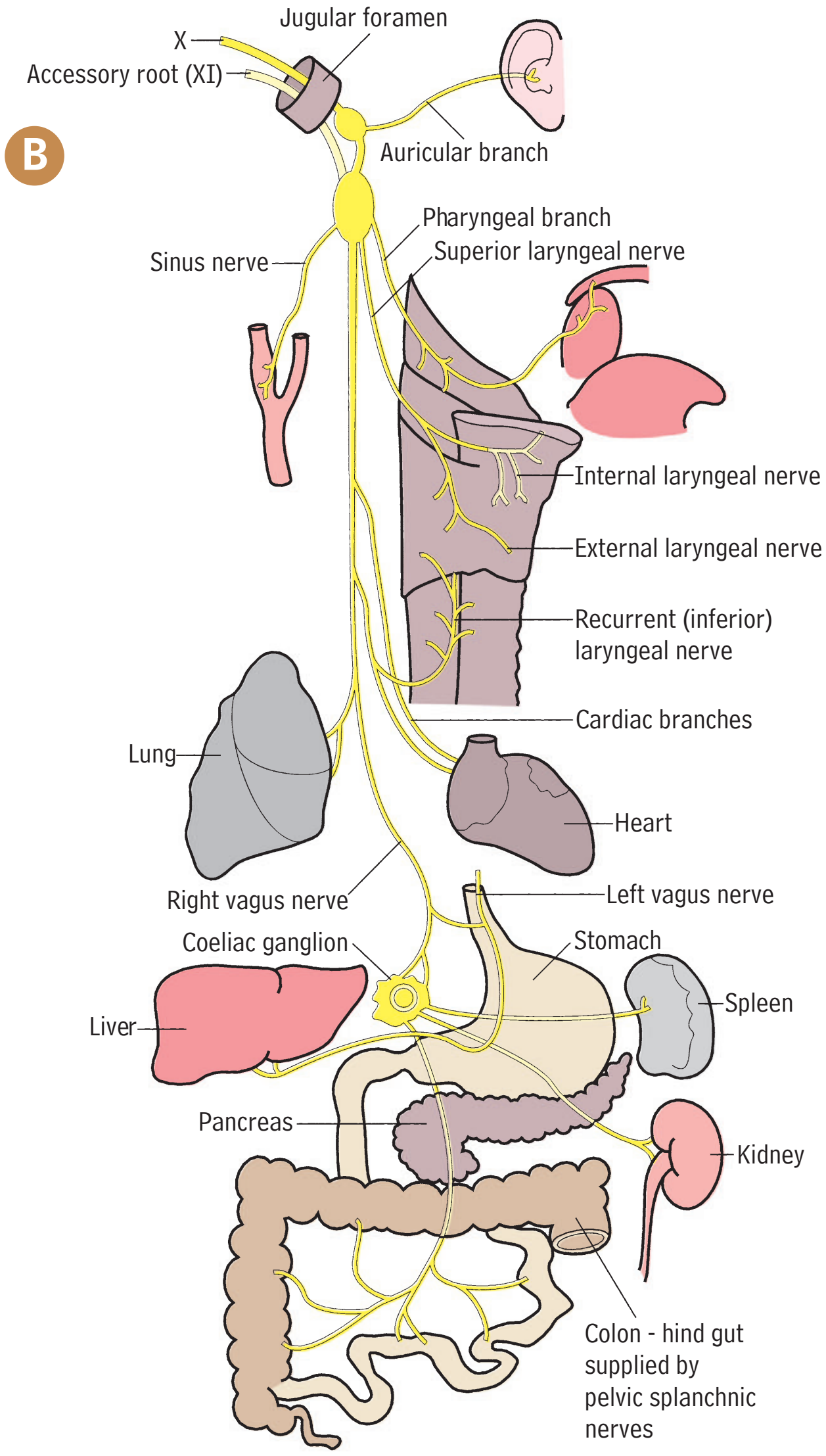

See pages 44–47, 53, 67 and 69.

Parotid tumours, recurrent laryngeal nerve palsy, see pages 80–82.

Cranial nerve (A) XI – accessory (B) XII – hypoglossal

A

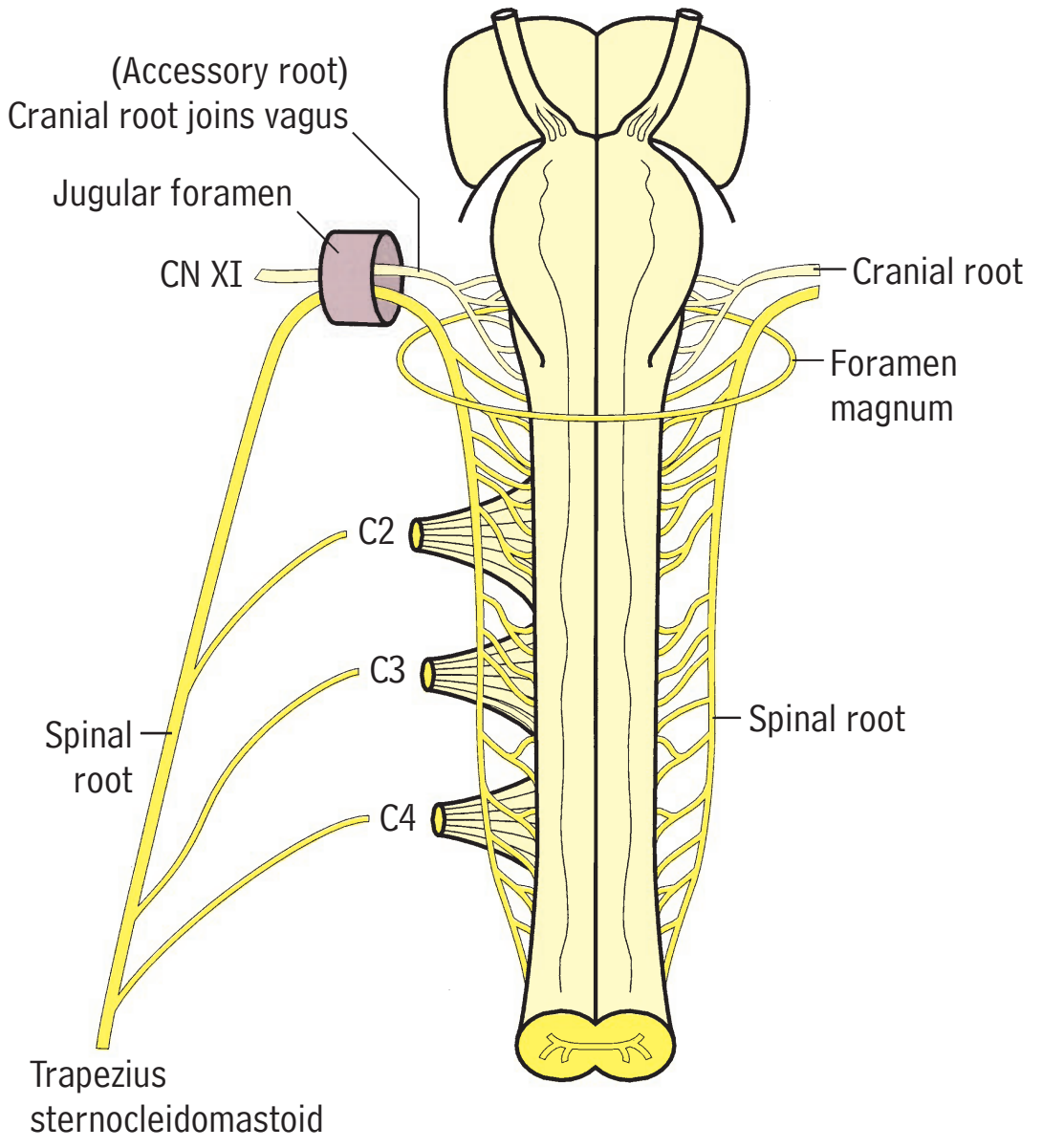

See pages 53 and 67.

B

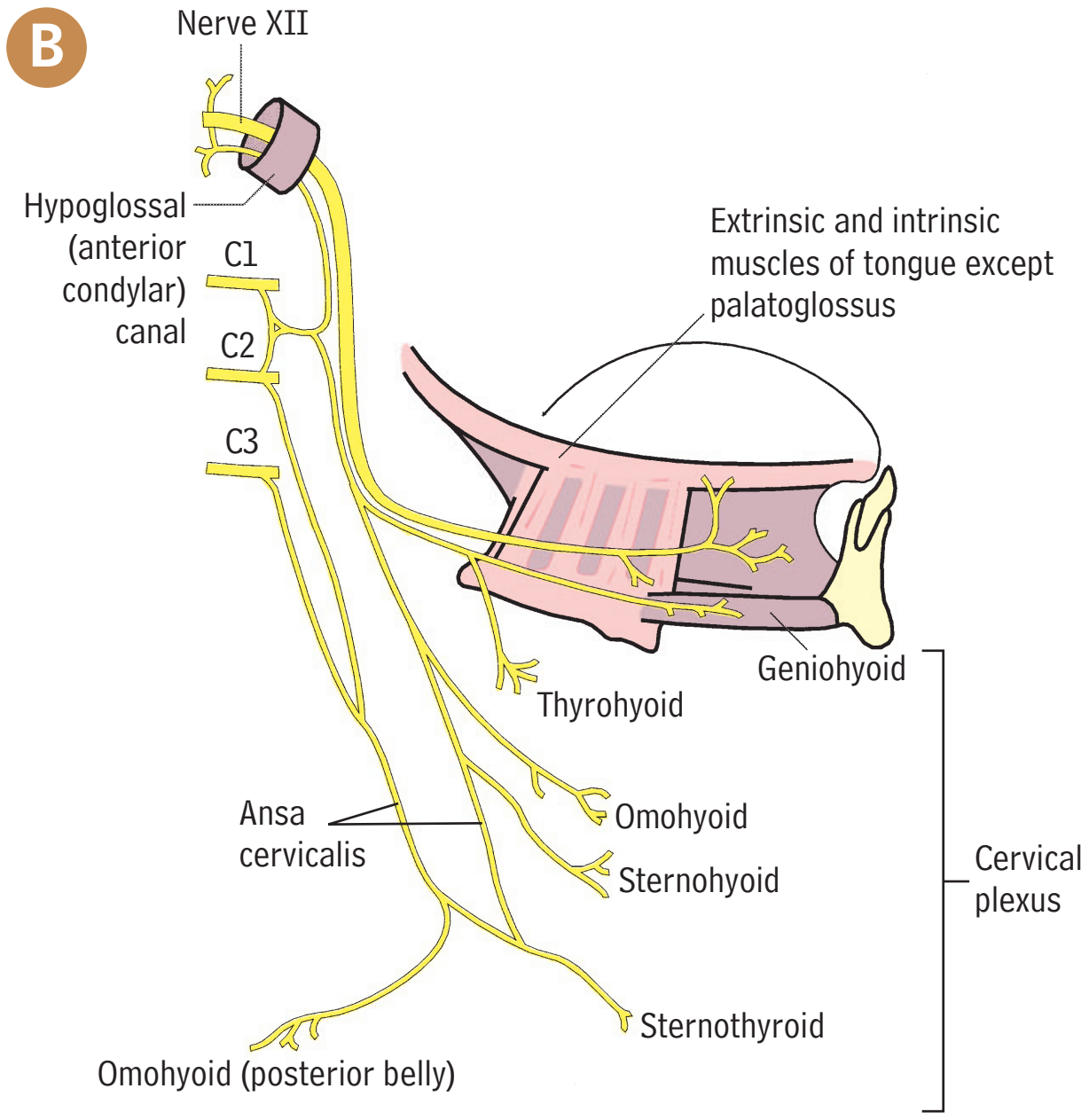

See pages 47, 59 and 67.

C

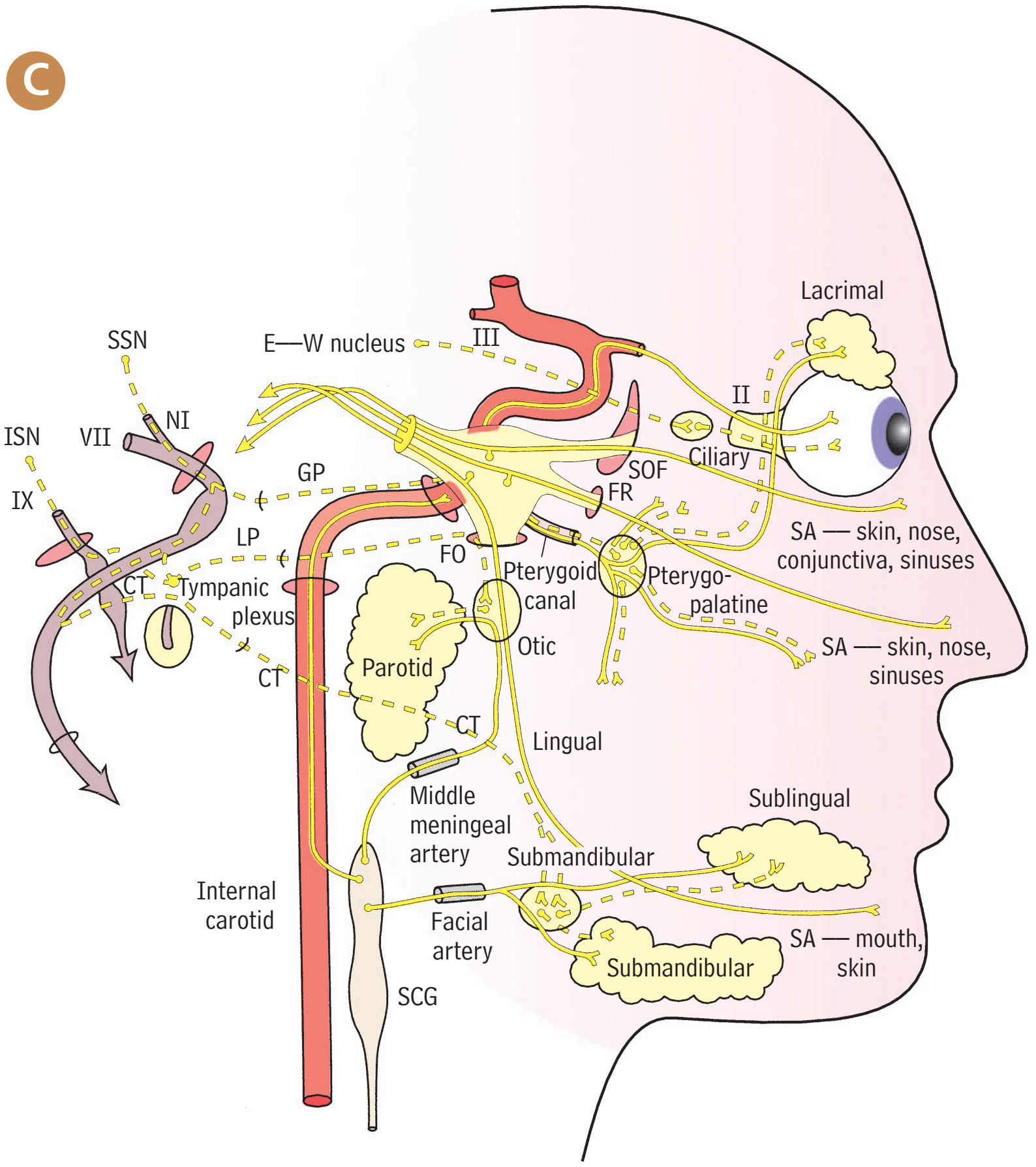

(C) Cranial autonomics

CT	chorda tympani
E–W	Edinger–Westphal
FO	foramen ovale
FR	foramen rotundum
GP	greater petrosal
ISN	inferior salivatory nucleus
LP	lesser petrosal
NI	nervus intermedius
SA	somatic afferent
SCG	superior cervical ganglion
SOF	superior orbital fissure
SSN	superior salivatory nucleus

Accessory nerve palsy, gag reflex, hypoglossal nerve palsy, see pages 80–82.

Head, neck and brain

Clinical thumbnails, see website for details and further clinical images to download into your own notes.

Abducent nerve palsy

Accessory nerve palsy

Accommodation reflex

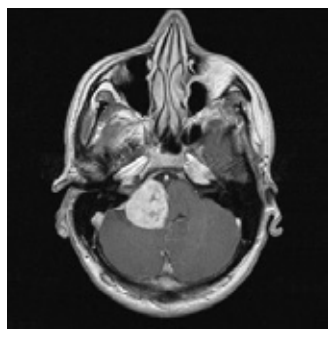
Acoustic neuroma

Adenoid enlargement

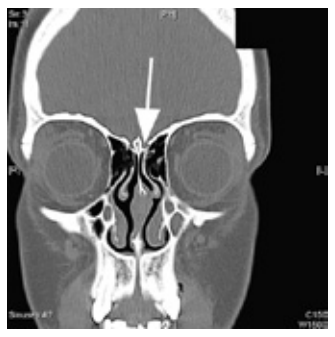
Anosmia

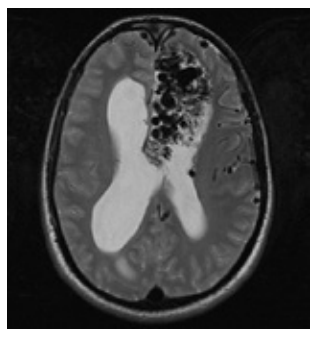
Arteriovenous fistulae

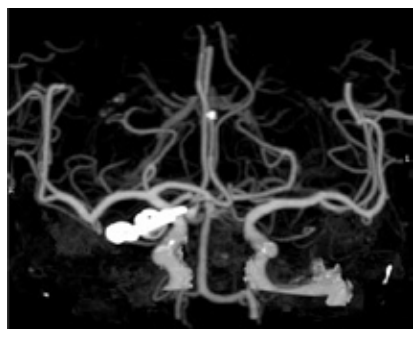
Berry aneurysm

Blow-out fractures of the orbit

Branchial cysts

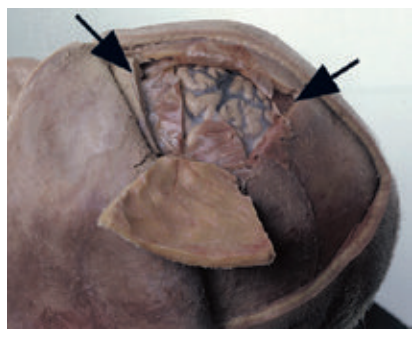
Burr holes

Carotid artery bruits

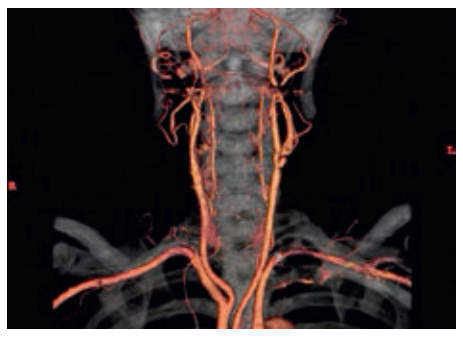
Carotid artery stenosis

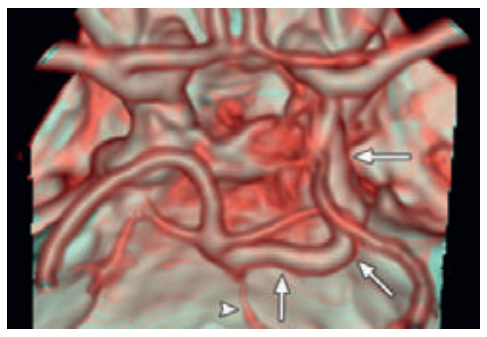
Carotid artery variants

Carotid endarterectomy

Cavernous sinus thrombosis

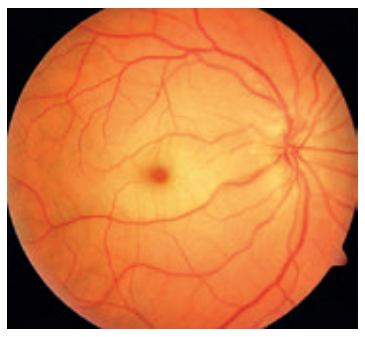
Central retinal artery occlusion

Cervical lymph node enlargement

Cleft lip and palate

Corneal arcus

Corneal reflex

Craniotomy

Endotracheal intubation

Epistaxis

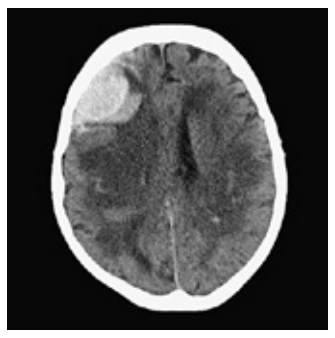
Extradural haemorrhage

Facial nerve (Bell's) palsy

Fractured mandible

Gag reflex

Glaucoma

Goitre

Horner's syndrome

Hydrocephalus

Hyperacusis

Hypoglossal nerve palsy

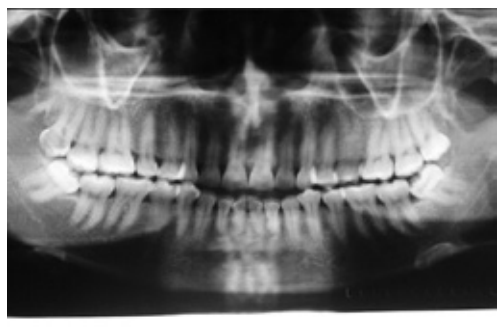
Impacted wisdom tooth

Inferior alveolar nerve block

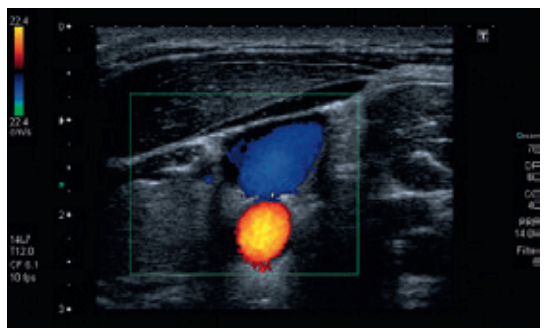
Internal jugular vein catheterisation

Intracranial spread of infection – face

Intracranial spread of infection – scalp

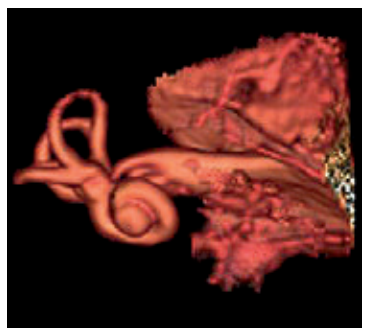
Labyrinthitis

Mastoiditis

Meibomian cyst (chalazion)

Middle ear pressure equalisation

Mumps

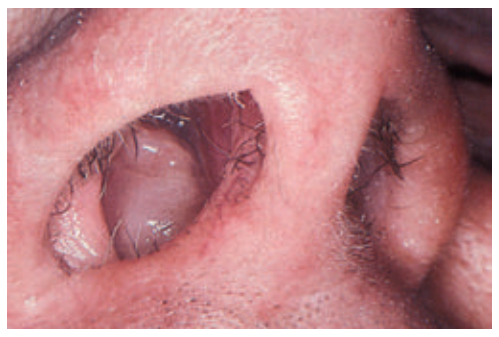
Nasal polyps

Nasogastric intubation

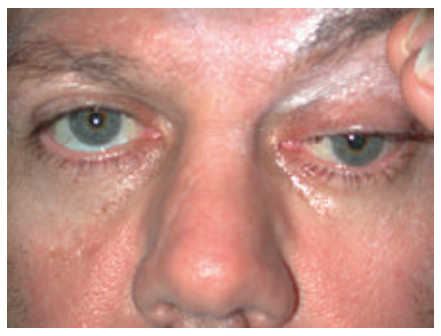
Oculomotor nerve palsy

Ophthalmic herpes zoster

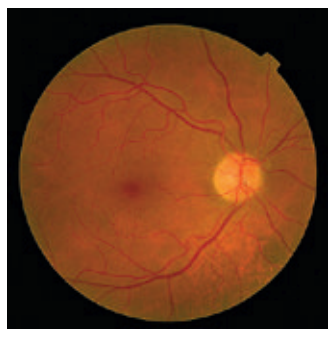
Ophthalmoscopy

Oral pathology

Orbital cellulitis

Otalgia (referred pain)

Parotid tumours

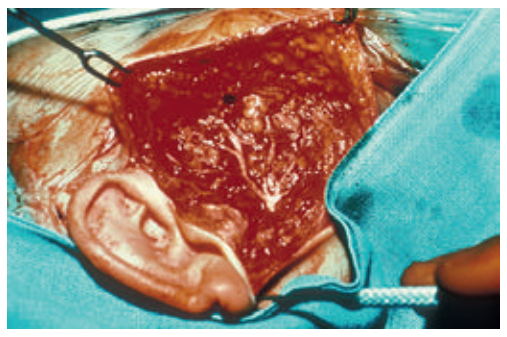
Parotidectomy

Pepperpot skull

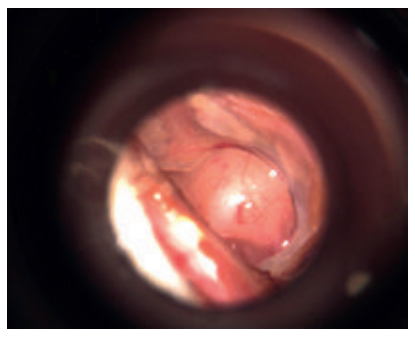
Perforated drum

Periorbital and subconjunctival haemorrhage

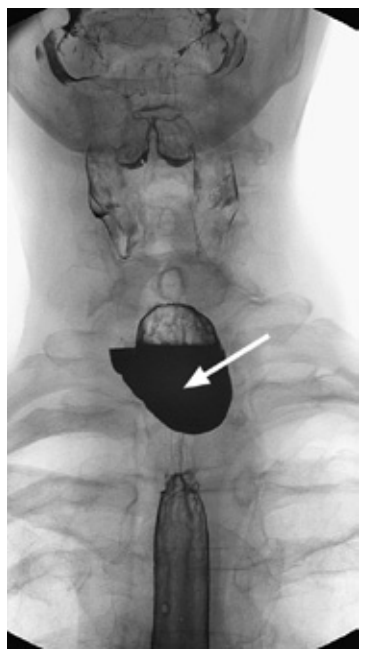
Pharyngeal pouch

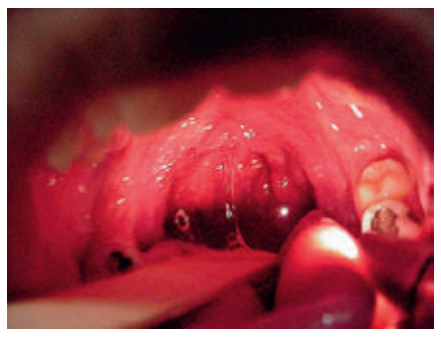
Pharyngitis

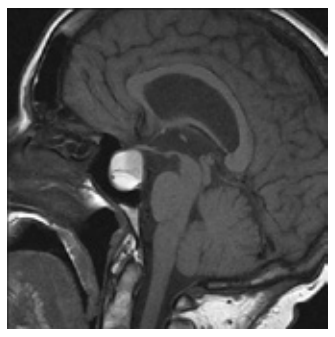
Pituitary apoplexy

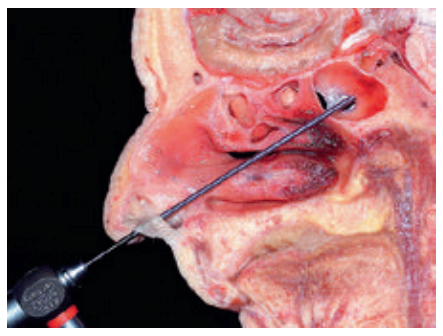
Pituitary tumour

Pupillary reflex

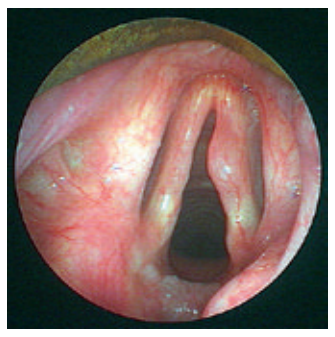
Recurrent laryngeal nerve palsy

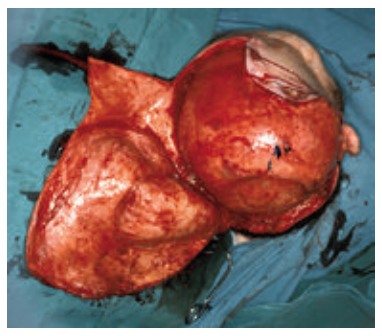
Scalp wounds

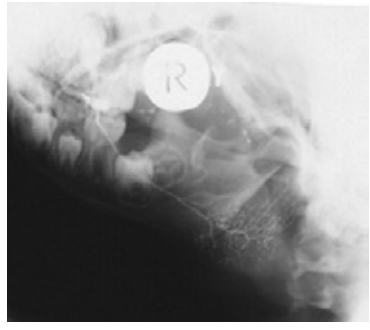
Sialectasis

Sinus pathology

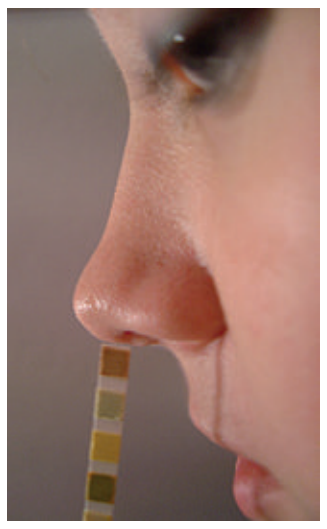
Skull base fracture

Skull fracture

Subarachnoid haemorrhage

Subclavian vein catheterisation

Subdural haemorrhage

Submandibular tumour

Surgical flaps of scalp

Temporomandibular joint (TMJ) dislocation

Tongue carcinoma

Tonsillectomy

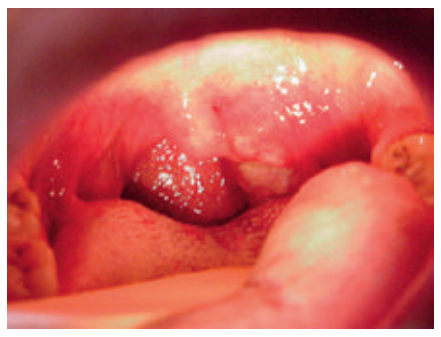
Tonsillitis

Torticollis

Tracheostomy

Tripod fracture

Trochlear nerve palsy

Varicella-zoster virus infection – head and neck

Vertebral column and spinal cord

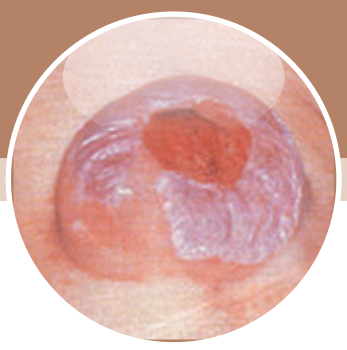

2

Back and vertebral column

A *surface anatomy* **B** *axial skeleton* **C** *vertebral column*

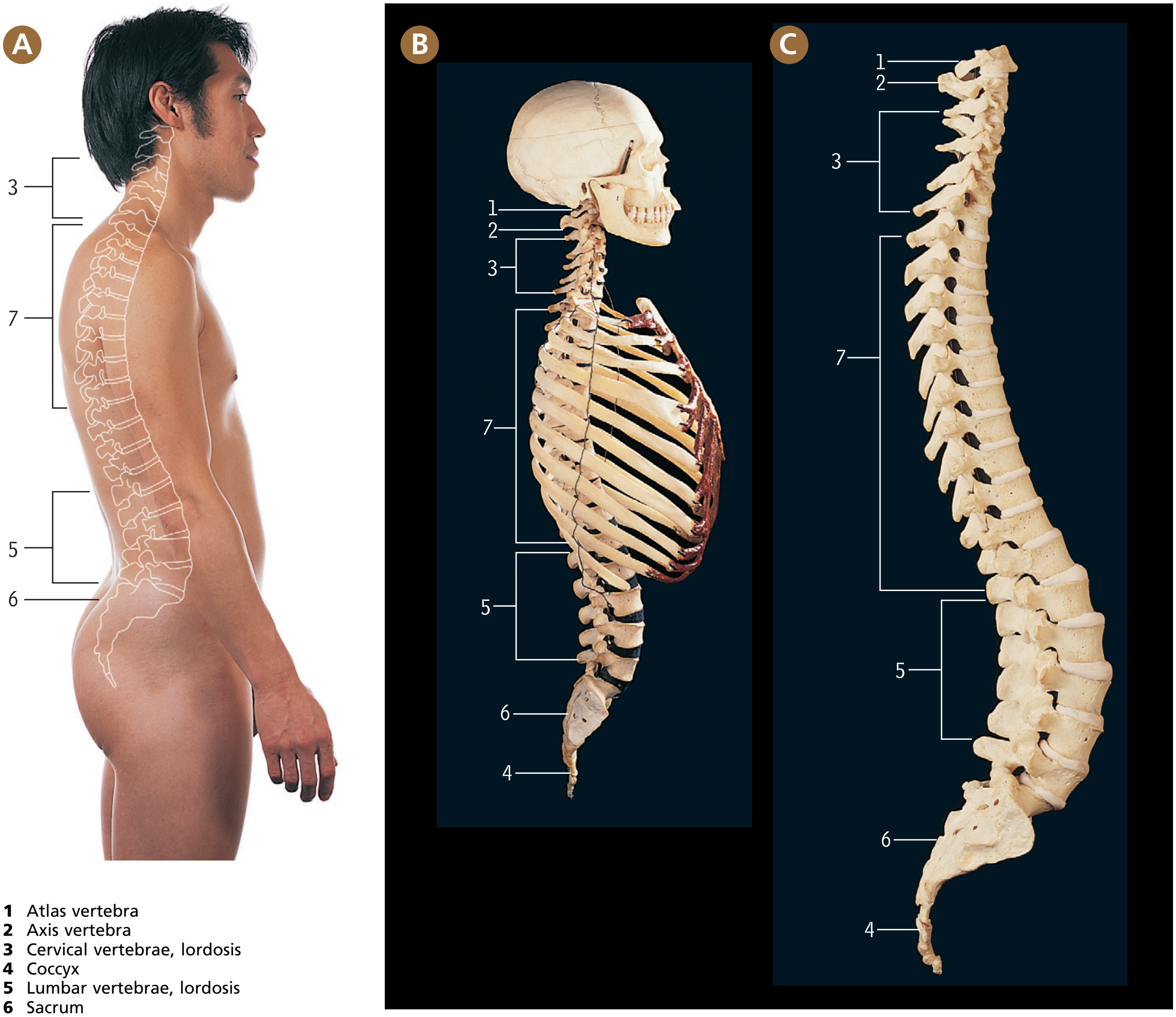

1 Atlas vertebra
2 Axis vertebra
3 Cervical vertebrae, lordosis
4 Coccyx
5 Lumbar vertebrae, lordosis
6 Sacrum
7 Thoracic vertebrae, kyphosis

Back and shoulder

A surface anatomy B muscles

1 Coccyx
2 Deltoid
3 External oblique
4 Gluteus maximus
5 Iliac crest
6 Latissimus dorsi
7 Medial border scapula (dotted)
8 Rhomboid major
9 Rhomboid minor
10 Sacrum
11 Trapezius
12 Thoracolumbar fascia

A

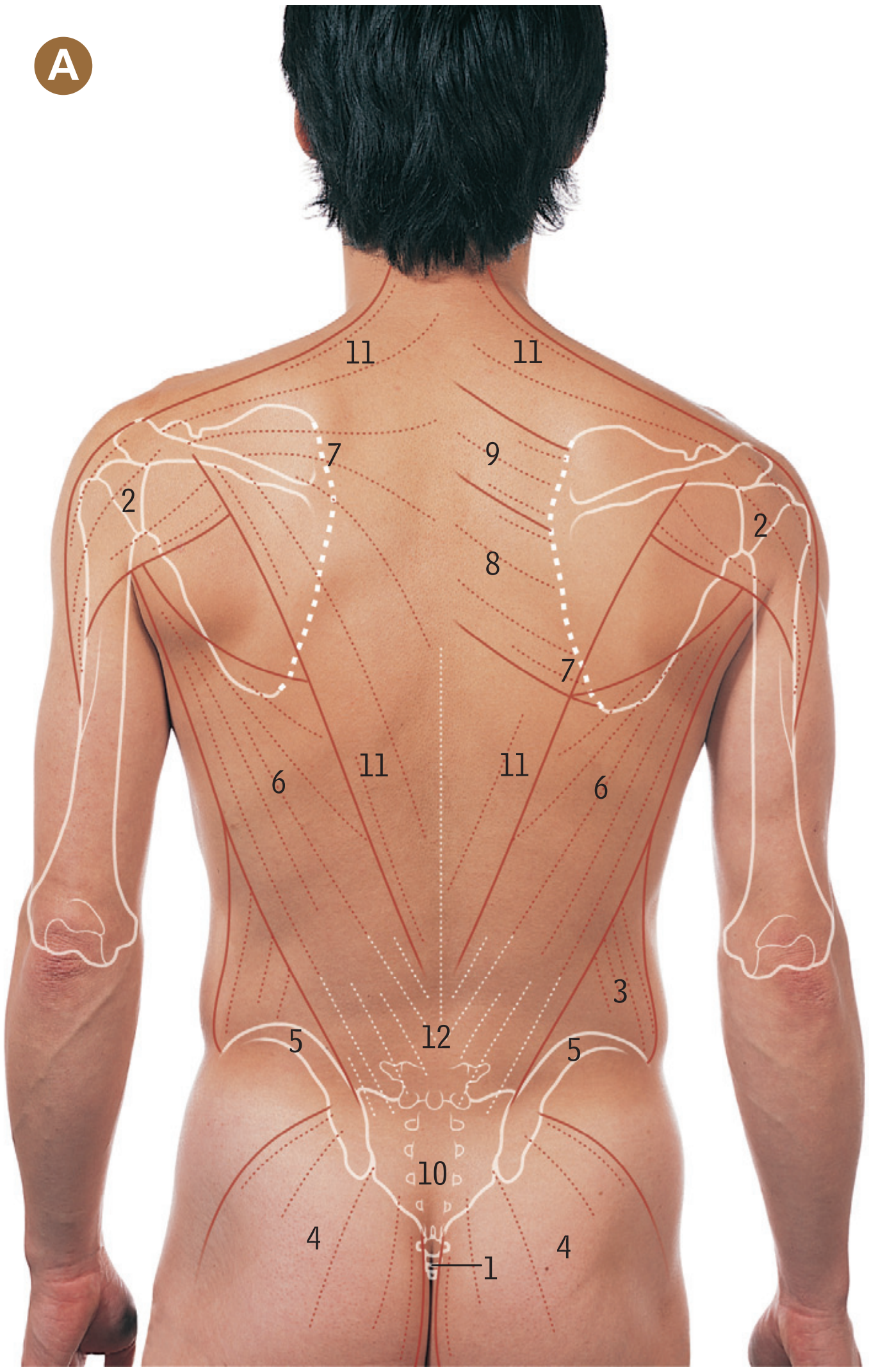

B

First cervical vertebra *atlas*

A from above

B from below

1 Anterior arch and tubercle
2 Facet for dens of axis
3 Groove for vertebral artery
4 Lateral mass with inferior articular facet
5 Lateral mass with superior articular facet
6 Posterior arch
7 Posterior tubercle
8 Transverse process and foramen

The superior articular facets (5) are concave and kidney-shaped.

The inferior articular facets (4) are circular and almost flat.

The anterior arch (1) is straighter and shorter than the posterior arch (6) and contains on its posterior surface the facet for the dens of the axis (2).

The atlas is the only vertebra that has no body.

Second cervical vertebra *axis*

C from above

D from the front

E from below

F articulated with the atlas, from above

1 Anterior arch of atlas
2 Bifid spinous process
3 Body
4 Dens (odontoid peg)
5 Impression for alar ligament
6 Inferior articular facet
7 Lamina
8 Pedicle
9 Superior articular surface
10 Transverse process and foramen
11 Vertebral foramen

The axis is unique in having the dens (4) which projects upwards from the body, representing the body of the atlas.

Odontoid peg fracture, see page 108.

Fifth cervical vertebra
typical cervical vertebra

A from above

B from the front

C from the left

1. Anterior tubercle of transverse process
2. Bifid spinous process
3. Body
4. Foramen of transverse process
5. Inferior articular process
6. Intertubercular lamella of transverse process
7. Lamina
8. Pedicle
9. Posterior tubercle of transverse process
10. Posterolateral lip (uncus)
11. Superior articular process
12. Vertebral foramen

Seventh cervical vertebra
vertebra prominens

D from above

1. Anterior tubercle of transverse process
2. Body
3. Foramen of transverse process
4. Intertubercular lamella of transverse process
5. Lamina
6. Pedicle
7. Posterior tubercle of transverse process
8. Posterolateral lip (uncus)
9. Spinous process with tubercle
10. Superior articular process
11. Vertebral foramen

All cervical vertebrae (first to seventh) have a foramen in each transverse process (as A4).

Typical cervical vertebrae (third to sixth) have superior articular processes that face backwards and upwards (A11, C11), posterolateral lips on the upper surface of the body (A10), a triangular vertebral foramen (A12) and a bifid spinous process (A2).

The anterior tubercle of the transverse process of the sixth cervical vertebra is large and known as the carotid tubercle.

The seventh cervical vertebra (vertebra prominens) has a spinous process that ends in a single tubercle (D9).

The rib element of a cervical vertebra is represented by the anterior root of the transverse process, the anterior tubercle, the intertubercular lamella (with its groove for the ventral ramus of a spinal nerve) and the anterior part of the posterior tubercle (as at D1, 4 and 7).

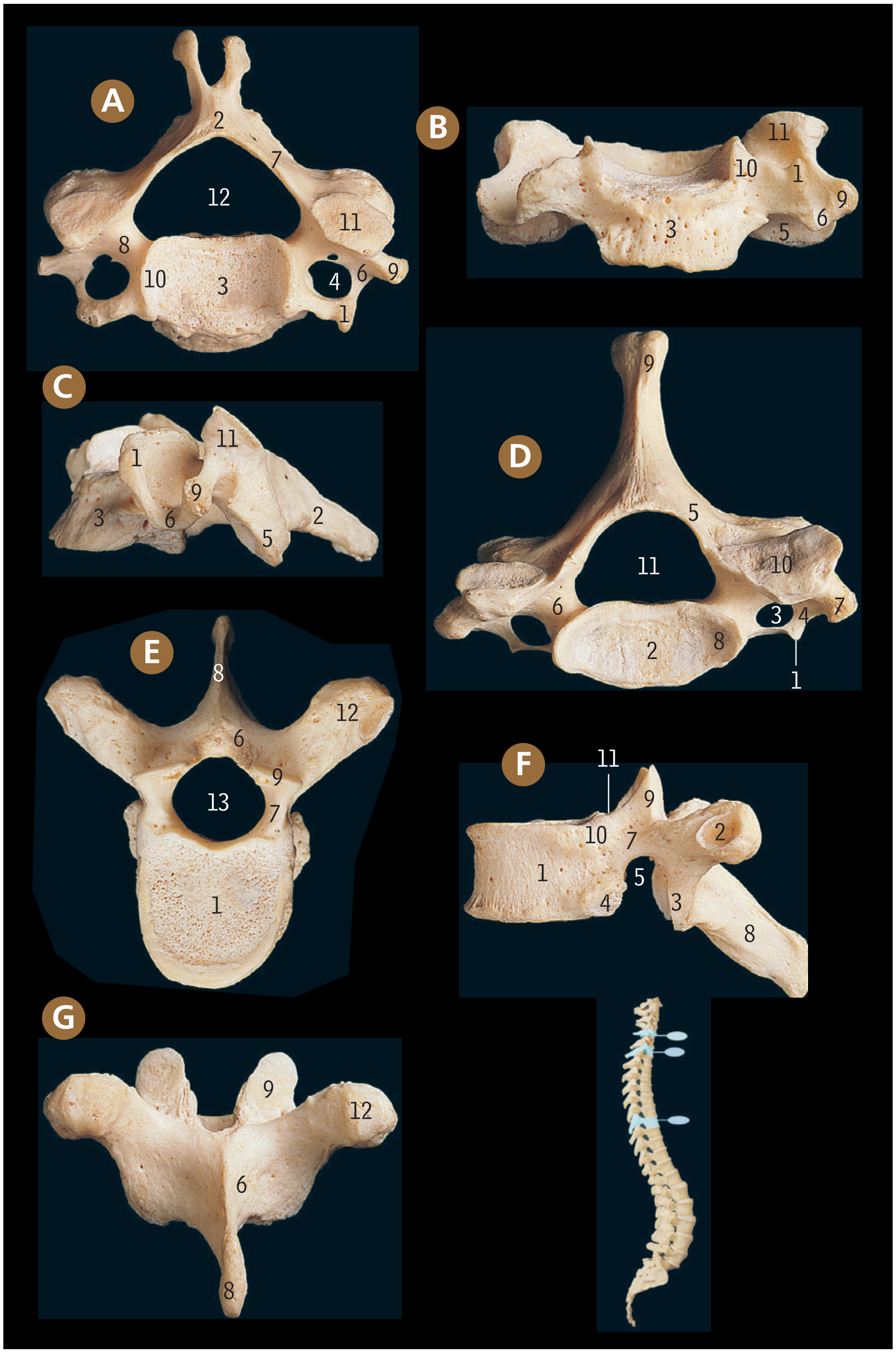

Seventh thoracic vertebra
typical

E from above

F from the left

G from behind

1. Body
2. Costal facet of transverse process
3. Inferior articular process
4. Inferior costal facet
5. Inferior vertebral notch
6. Lamina
7. Pedicle
8. Spinous process
9. Superior articular process
10. Superior costal facet
11. Superior vertebral notch
12. Transverse process
13. Vertebral foramen

Typical thoracic vertebrae (second to ninth) are characterised by costal facets on the bodies (F10, 4), costal facets on the transverse processes (F2), a round vertebral foramen (E13), a spinous process that points downwards as well as backwards (F8, G8) and superior articular processes that are vertical, flat and face backwards and laterally (E9, F9, G9).

Ankylosing spondylitis, see page 108.

First thoracic vertebra

A from above

B from the front and the left

1 Body
2 Inferior articular process
3 Inferior costal facet
4 Lamina
5 Pedicle
6 Posterolateral lip (uncus)
7 Spinous process
8 Superior articular process
9 Superior costal facet
10 Transverse process with costal facet
11 Vertebral foramen

Tenth and eleventh thoracic vertebrae

C tenth thoracic vertebra, from the left

D eleventh thoracic vertebra, from the left

1 Body
2 Costal facet
3 Inferior articular process
4 Inferior vertebral notch
5 Pedicle
6 Spinous process
7 Superior articular process
8 Transverse process

Twelfth thoracic vertebra

E from the left

F from above

G from behind

1 Body
2 Costal facet
3 Inferior articular process
4 Inferior tubercle
5 Lateral tubercle
6 Pedicle
7 Spinous process
8 Superior articular process
9 Superior tubercle

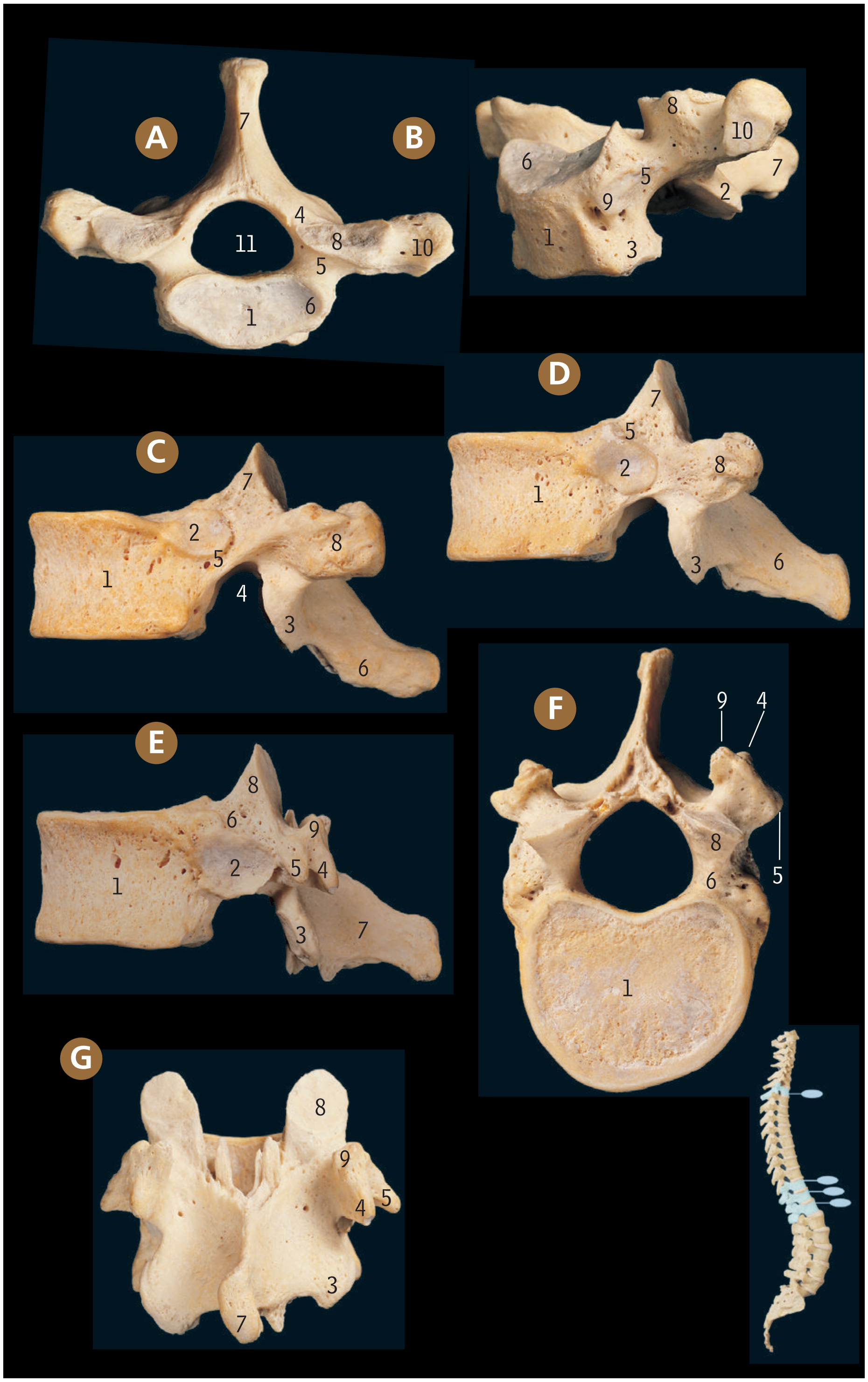

The atypical thoracic vertebrae are the first, tenth, eleventh and twelfth.

The first thoracic vertebra has a posterolateral lip (A6, B6) on each side of the upper surface of the body and a triangular vertebral foramen (features like typical cervical vertebrae), and complete (round) superior costal facets (B9) on the sides of the body.

The tenth, eleventh and twelfth thoracic vertebrae are characterised by a single complete costal facet on each side of the body that in successive vertebrae comes to lie increasingly far from the upper surface of the body and encroaches increasingly onto the pedicle (C2, D2 and E2). There is also no articular facet on the transverse process.

Spondylolisthesis, see page 108.

First lumbar vertebra

A from above

B from the left

C from behind

1 Accessory process
2 Body
3 Inferior articular process
4 Inferior vertebral notch
5 Lamina
6 Mammillary process
7 Pedicle
8 Spinous process
9 Superior articular process
10 Superior vertebral notch
11 Transverse process
12 Vertebral foramen

Lumbar vertebrae are characterised by the large size of the bodies, the absence of costal facets on the bodies and the transverse processes, a triangular vertebral foramen (A12), a spinous process that points backwards and is quadrangular or hatchet-shaped (B8) and superior articular processes that are vertical, curved, face backwards and medially (A9) and possess a mamillary process at their posterior rim (A6).

The rib element of a lumbar vertebra is represented by the transverse process (A11).

The level at which facet joint orientation changes between the thoracic and lumbar regions is variable.

Posterior view

D second lumbar vertebra

E third lumbar vertebra

F fourth lumbar vertebra

G fifth lumbar vertebra

View from above

H fifth lumbar vertebra

1 Body
2 Lamina
3 Pedicle
4 Spinous process
5 Superior articular process
6 Transverse process fusing with pedicle and body
7 Vertebral foramen

Viewed from behind, the four articular processes of the first and second lumbar vertebrae make a pattern (indicated by the interrupted line) of a vertical rectangle; those of the third or fourth vertebra make a square, and those of the fifth lumbar vertebra make a horizontal rectangle.

The fifth lumbar vertebra is unique in that the transverse process (H6) unites directly with the side of the body (H1) as well as with the pedicle (H3).

Laminectomy, lumbar stenosis, vertebral fracture, vertebral lumbar fracture, see page 108.

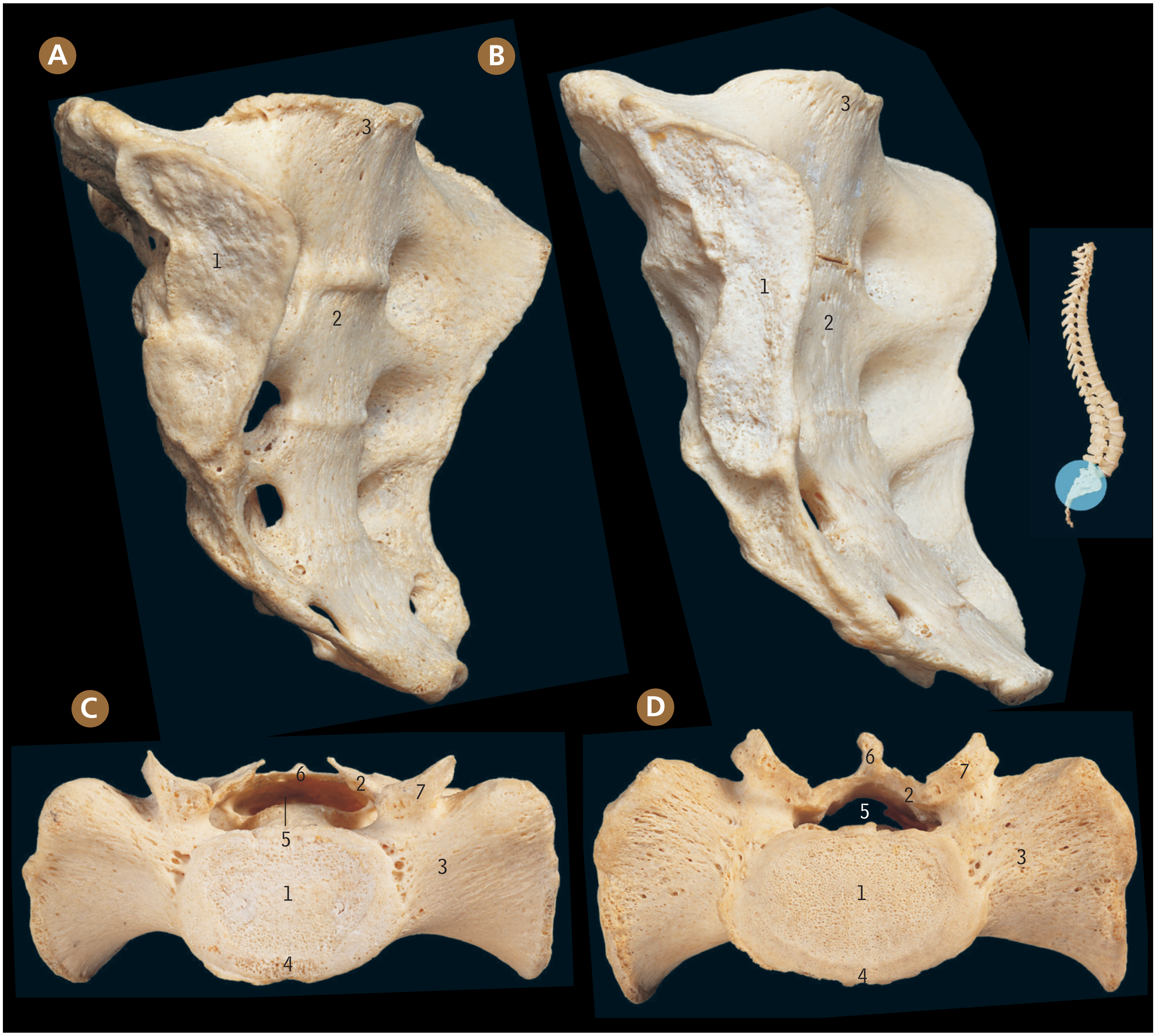

Sacrum *from the front and the right*

A **in the female**

B **in the male**

1 Auricular surface
2 Pelvic surface
3 Promontory

In the female, the pelvic surface is relatively straight over the first three sacral vertebrae and becomes more curved below. In the male, the pelvic surface is more uniformly curved.

The capsule of the sacro-iliac joint is attached to the margin of the auricular (articular) surface (A1, B1).

Base of the sacrum *upper surface*

C **in the female**

D **in the male**

1 Body of first sacral vertebra
2 Lamina
3 Lateral part (ala)
4 Promontory
5 Sacral canal
6 Spinous tubercle of median sacral crest
7 Superior articular process

In the male, the body of the first sacral vertebra (judged by its transverse diameter) forms a greater part of the base of the sacrum than in the female (compare D1 with C1).

In C, there is some degree of spina bifida (non-fusion of the laminae, 2, in the vertebral arch of the first sacral vertebra). Compare with the complete arch in D.

Sacralisation, see page 108.

Sacrum and coccyx

A pelvic surface

1 Coccygeal cornu
2 Facet for coccyx
3 First coccygeal vertebra
4 Fused second to fourth vertebrae
5 Intermediate sacral crest
6 Lateral part
7 Lateral sacral crest
8 Median sacral crest
9 Promontory
10 Sacral canal

B dorsal surface

11 Sacral cornu
12 Sacral hiatus
13 Second pelvic sacral foramen
14 Site of fusion of first and second sacral vertebrae
15 Superior articular process
16 Third dorsal sacral foramen
17 Transverse process
18 Upper surface of lateral part (ala)

The sacrum is formed by the fusion of the five sacral vertebrae. The median sacral crest (B8) represents the fused spinous processes, the intermediate crest (B5) the fused articular processes, and the lateral crest (B7) the fused transverse processes.

The sacral hiatus (B12) is the lower opening of the sacral canal (B10).

The coccyx is usually formed by the fusion of four rudimentary vertebrae but the number varies from three to five. In this specimen, the first piece of the coccyx (3) is not fused with the remainder (4).

Coccydynia, see page 108.

Sacrum *with sacralisation of the fifth lumbar vertebra*

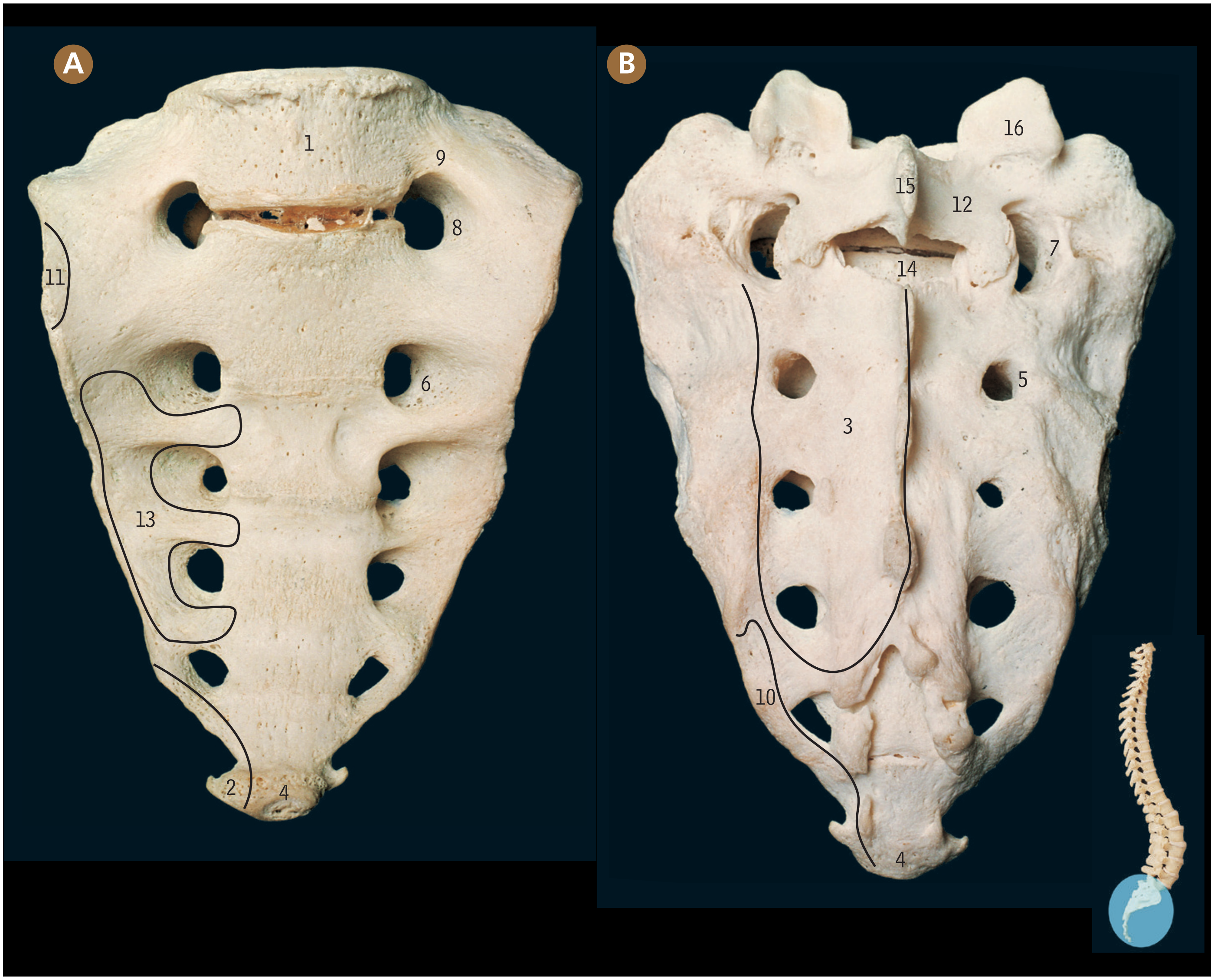

A pelvic surface

B dorsal surface, and sacral muscle attachments

1 Body of fifth lumbar vertebra
2 Coccygeus
3 Erector spinae
4 First coccygeal vertebra fused to apex of sacrum
5 First dorsal sacral foramen
6 First pelvic sacral foramen
7 Foramen for dorsal ramus of fifth lumbar nerve
8 Foramen for ventral ramus of fifth lumbar nerve
9 Fusion of transverse process and lateral part of sacrum
10 Gluteus maximus
11 Iliacus
12 Lamina
13 Piriformis
14 Sacral canal
15 Spinous process of fifth lumbar vertebra
16 Superior articular process of fifth lumbar vertebra

In sacralisation of the fifth lumbar vertebra, that vertebra (A1) is (usually incompletely) fused with the sacrum. In the more rare condition of lumbarization of the first sacral vertebra (not illustrated) the first piece of the sacrum is incompletely fused with the remainder.

In this specimen, as well as fusion of the fifth lumbar vertebra with the top of the sacrum, the body of the first coccygeal vertebra (4) is fused with the apex of the sacrum.

Caudal anaesthesia, see page 108.

Bony pelvis *from in front and above*

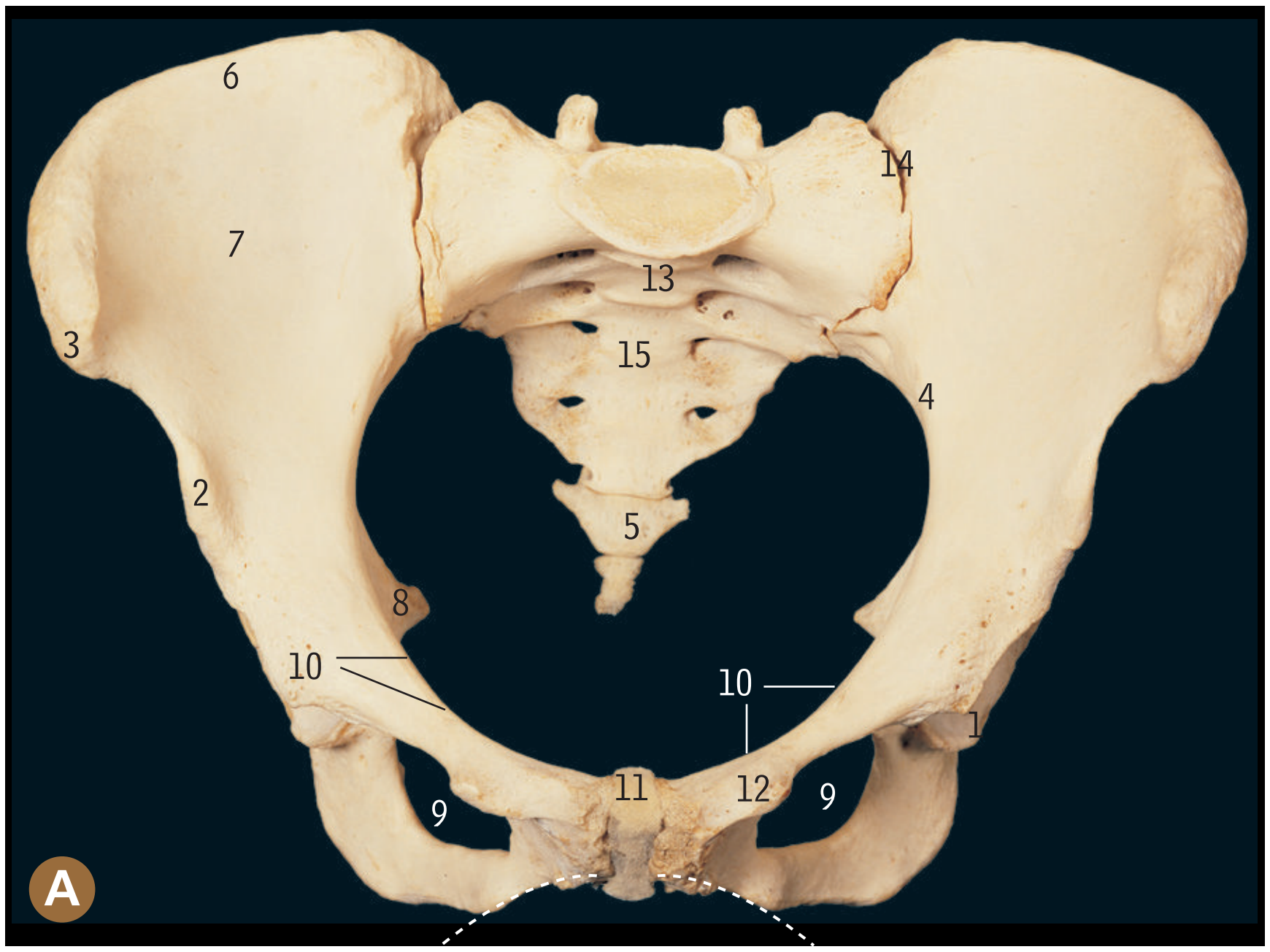

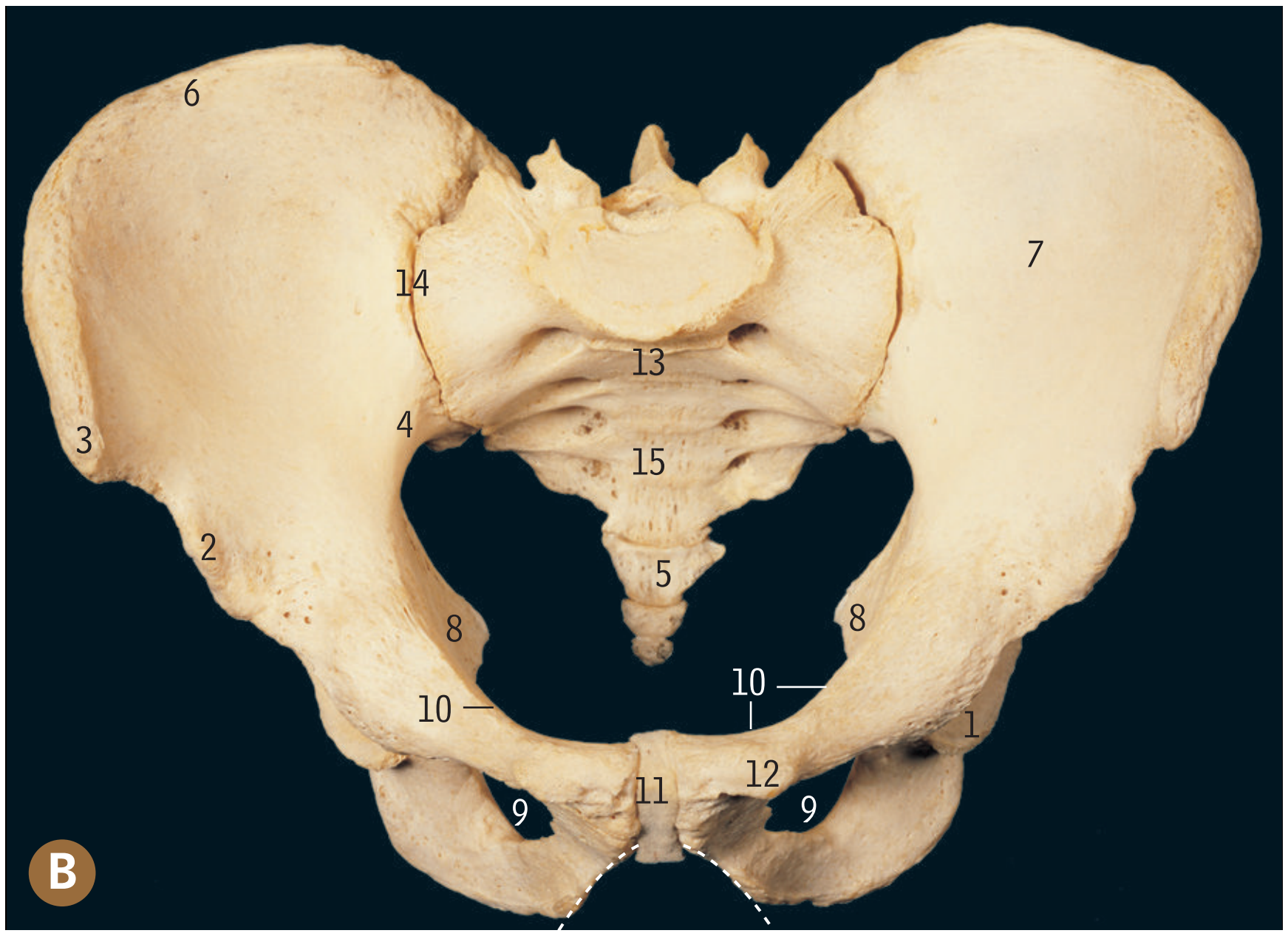

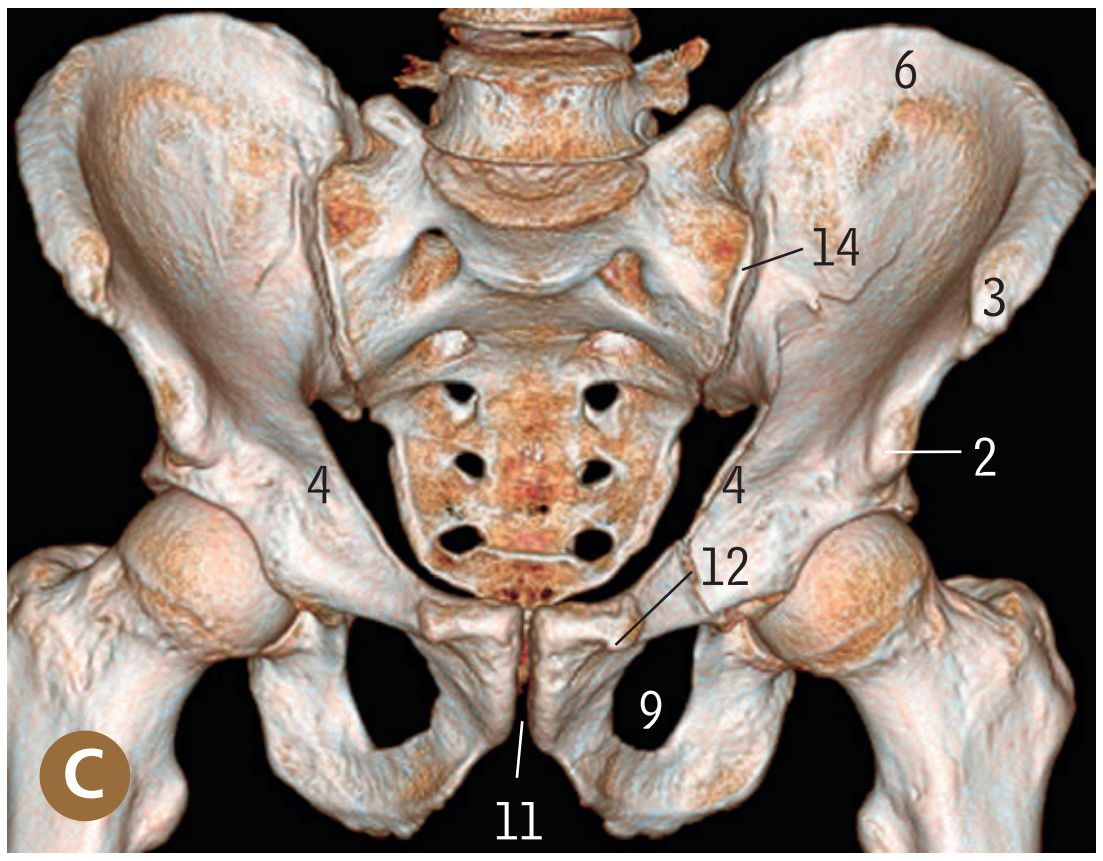

A female

B male

C from the front

1. Acetabulum
2. Anterior inferior iliac spine
3. Anterior superior iliac spine
4. Arcuate line
5. Coccyx
6. Iliac crest
7. Iliac fossa
8. Ischial spine
9. Obturator foramen
10. Pectineal line
11. Pubic symphysis
12. Pubic tubercle
13. Sacral promontory
14. Sacro-iliac joint
15. Sacrum

The pelvic inlet (brim) is bounded by the sacral promontory (13), arcuate and pectineal lines (4 and 10), the crest of the pubic bones and anteriorly the pubic symphysis (11).

The female brim is more circular, the male more heart-shaped.

The female sacrum (15) is wider, shorter and less curved.

The female ischial spines (8) are further apart.

The female subpubic angle (white dotted line on A) is wide (90–120°) and the male subpubic angle (white dotted line on B) only 60–90°.

Vertebrae, ribs and sternum *ossification*

A typical vertebra in a 6-month fetus

B at 4 years of age

C **D** during puberty

E atlas at 4 years of age

F axis, primary and secondary centres

G typical rib, secondary centres

H sternum at birth, with primary centres

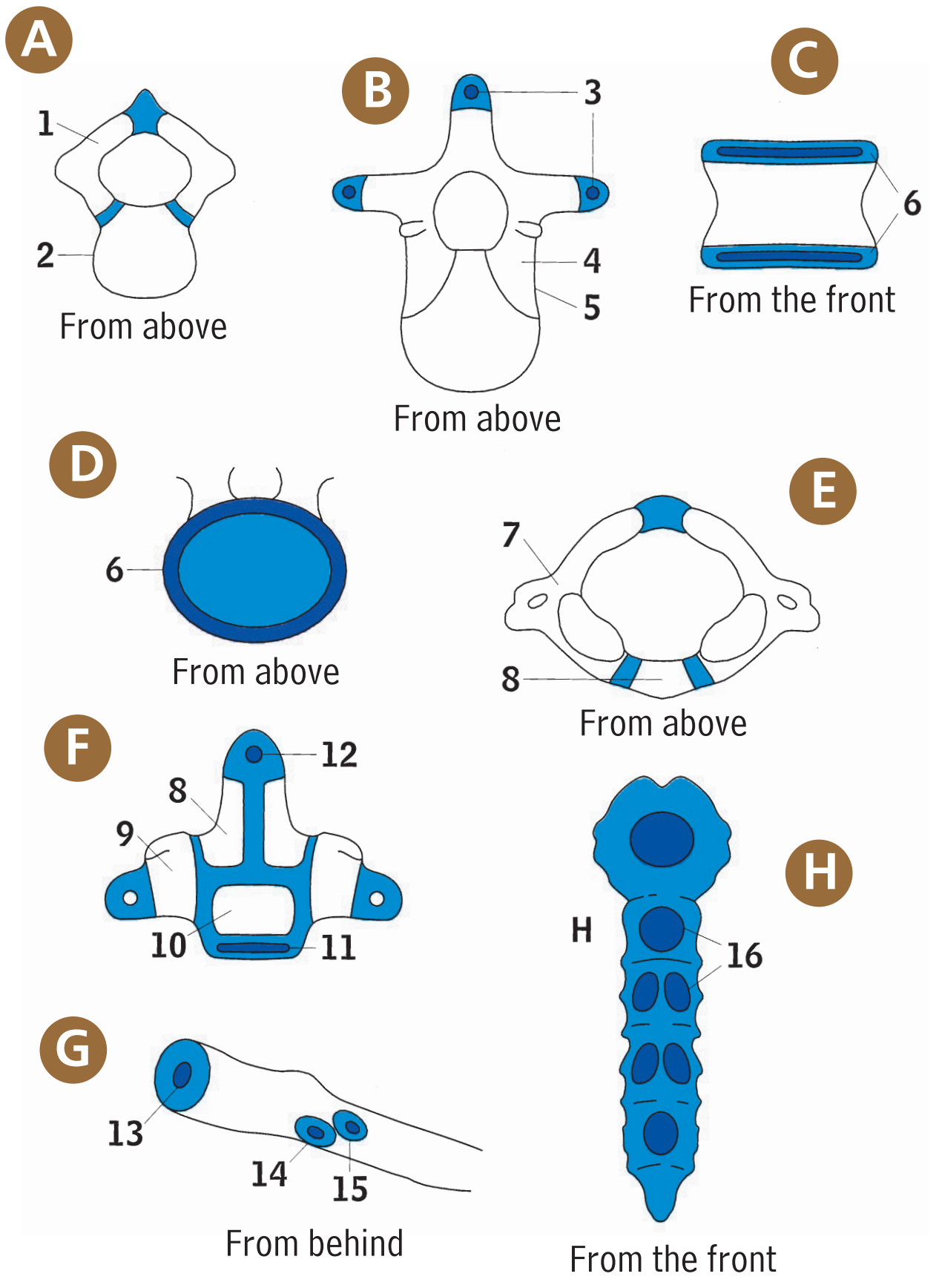

A typical vertebra, which is first cartilaginous, ossifies in early fetal life from three primary centres – one for most of the body (the centrum, A2) and one for each half of the neural arch (A1). The part of the adult body to which the pedicle is attached (B4) is part of the centre for the arch; the site in the developing vertebra where they meet is the neurocentral junction (B5). The two halves of the arch and the neurocentral junctions unite at variable times between birth and 6 years. Ossification spreads into the transverse processes and spine which grow out from the arch, but secondary centres (B3) appear at their tips during puberty and become fused at about 25 years of age. (Lumbar vertebrae have similar additional secondary centres for the mamillary processes.) There are also ring-like epiphyses on the periphery of the upper and lower surfaces of the vertebral bodies (C6 and D6).

The atlas has a primary centre (E7) for each lateral mass and the adjacent half of the posterior arch, and one for the anterior arch (E8). Fusion is complete by about 8 years.

The axis has five primary centres – one for most of the body (F10), one for each lateral mass (F9), and one for each half of the dens and adjacent part of the body (F8). They should all fuse by about 3 years. There are secondary centres for the tip of the dens (F12, appearing by about 2 years and fusing at 12 years) and the lower surface of the body (F11, appearing during puberty and fusing at about 25 years).

The sacrum, representing five fused sacral vertebrae, has many ossification centres, corresponding to the centrum, neural arch halves and costal elements of each vertebra, as well as ring epiphyses for the vertebral bodies and for the auricular surfaces. Most have fused by about 20 years, but some not until middle-age or later.

A typical rib has a primary centre for the body with secondary centres for the head (G13) and the articular and non-articular parts of the tubercle (G14 and 15), appearing during puberty and uniting at about 20 years.

The sternum has a variable number of primary centres (H16), one or two in the manubrium and in each of the four pieces of the body. Fusion occurs between puberty and 25 years of age. ‘Bullet holes’ in the sternum (sternal foramina) may occur when fusion is incomplete.

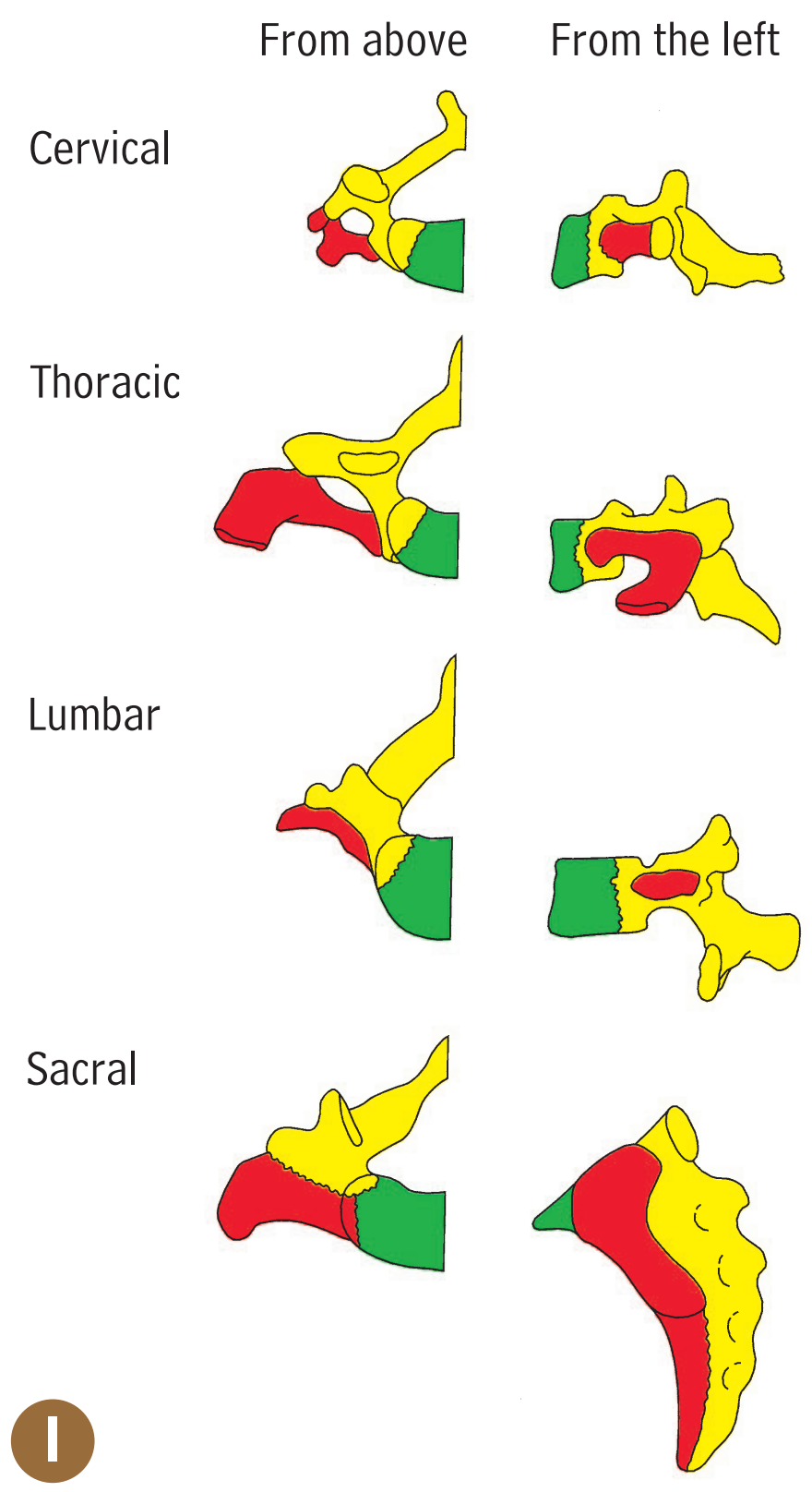

I Vertebrae *developmental origins*

Red, costal elements; green, centrum; yellow, neural arch

Parts of the cervical, lumbar and sacral vertebrae represent the ribs that articulate with thoracic vertebrae. These costal elements are indicated here in red.

***Cervical*: anterior and posterior tubercles and the intertubercular lamella.**

***Thoracic*: the true rib articulates with the vertebra.**

***Lumbar*: the anterior part of the transverse process.**

***Sacral*: the lateral part, including the auricular surface.**

Vertebral column and spinal cord

A cervical region, from the front B cervical region, from behind

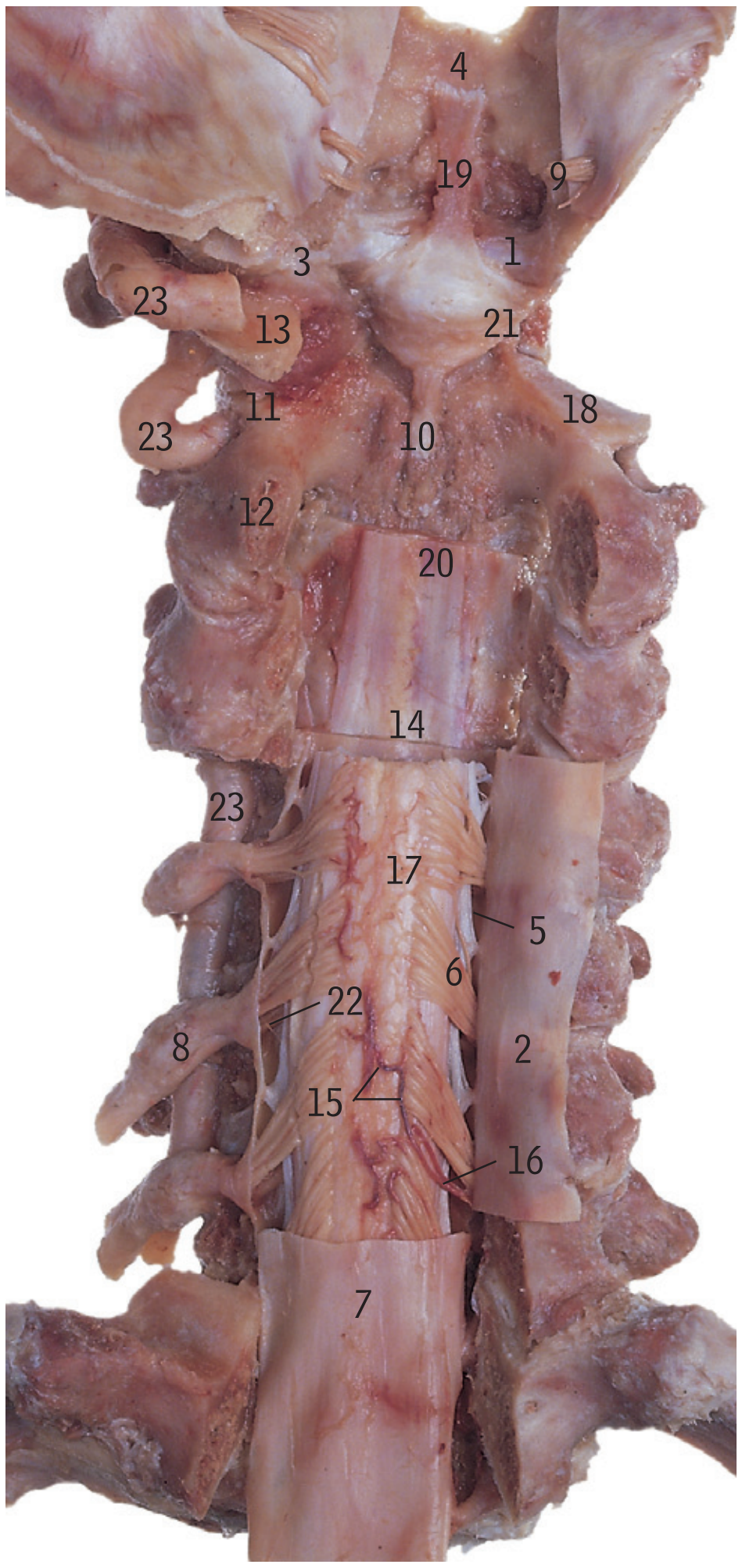

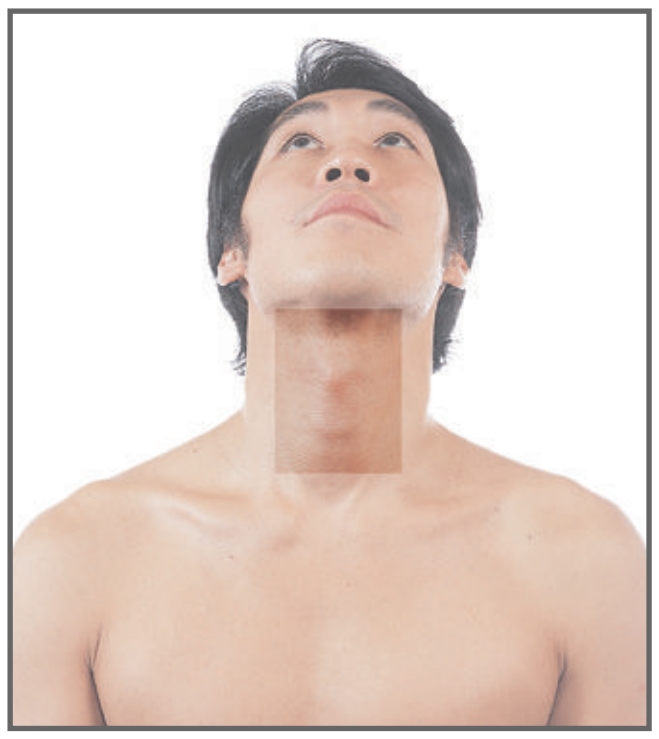

The vertebral artery (14) is seen within foramina of cervical transverse processes.

- **1** Anterior longitudinal ligament
- **2** Anterior tubercle of transverse process
- **3** Axis
- **4** Body of the fifth cervical vertebra
- **5** Cut edge of the pleura
- **6** Intertubercular lamella of transverse process
- **7** Intervertebral disc
- **8** Joint of head of first rib
- **9** Lateral mass of atlas
- **10** Posterior tubercle of transverse process
- **11** Scalenus anterior muscle
- **12** Transverse process of atlas
- **13** Ventral ramus of fourth cervical nerve
- **14** Vertebral artery

Much of the skull, the vertebral arches, brainstem and the upper part of the spinal cord have been removed to show the cruciform, transverse and alar ligaments (19, 10, 21 and 1). Lower down, the arachnoid and dura mater (2) have been reflected to show dorsal and ventral nerve roots (as at 6 and 22).

- **1** Alar ligament
- **2** Arachnoid and dura mater (reflected)
- **3** Atlanto-occipital joint
- **4** Basilar part of occipital bone and position of attachment of tectorial membrane
- **5** Denticulate ligament
- **6** Dorsal rootlets of spinal nerve
- **7** Dura mater
- **8** Dural sheath over dorsal root ganglion
- **9** Hypoglossal nerve and canal
- **10** Inferior longitudinal band of cruciform ligament
- **11** Lateral atlanto-axial joint
- **12** Pedicle of axis
- **13** Posterior arch of atlas
- **14** Posterior longitudinal ligament
- **15** Posterior spinal arteries
- **16** Radicular artery
- **17** Spinal cord
- **18** Superior articular surface of axis
- **19** Superior longitudinal band of cruciform ligament
- **20** Tectorial membrane
- **21** Transverse ligament of atlas (transverse part of cruciform ligament)
- **22** Ventral rootlets of spinal nerve
- **23** Vertebral artery

Vertebral column and spinal cord

C cervical and upper thoracic regions, from the right

Ventral and dorsal rami of spinal nerves (as at 16 and 4) are seen emerging from intervertebral foramina (as at 7).

1. Anterior tubercle of transverse process of fifth cervical vertebra
2. Body of first thoracic vertebra
3. Body of seventh cervical vertebra
4. Dorsal ramus of first cervical nerve
5. First cervical nerve
6. First rib
7. Intervertebral foramen
8. Lateral atlanto-axial joint
9. Lateral mass of atlas
10. Posterior arch of atlas
11. Eighth cervical nerve
12. Spinous process of second cervical vertebra
13. Spinous process of seventh cervical vertebra
14. Transverse process of atlas
15. Tubercle of first rib
16. Ventral ramus of sixth cervical nerve
17. Vertebral artery
18. Zygapophyseal joint

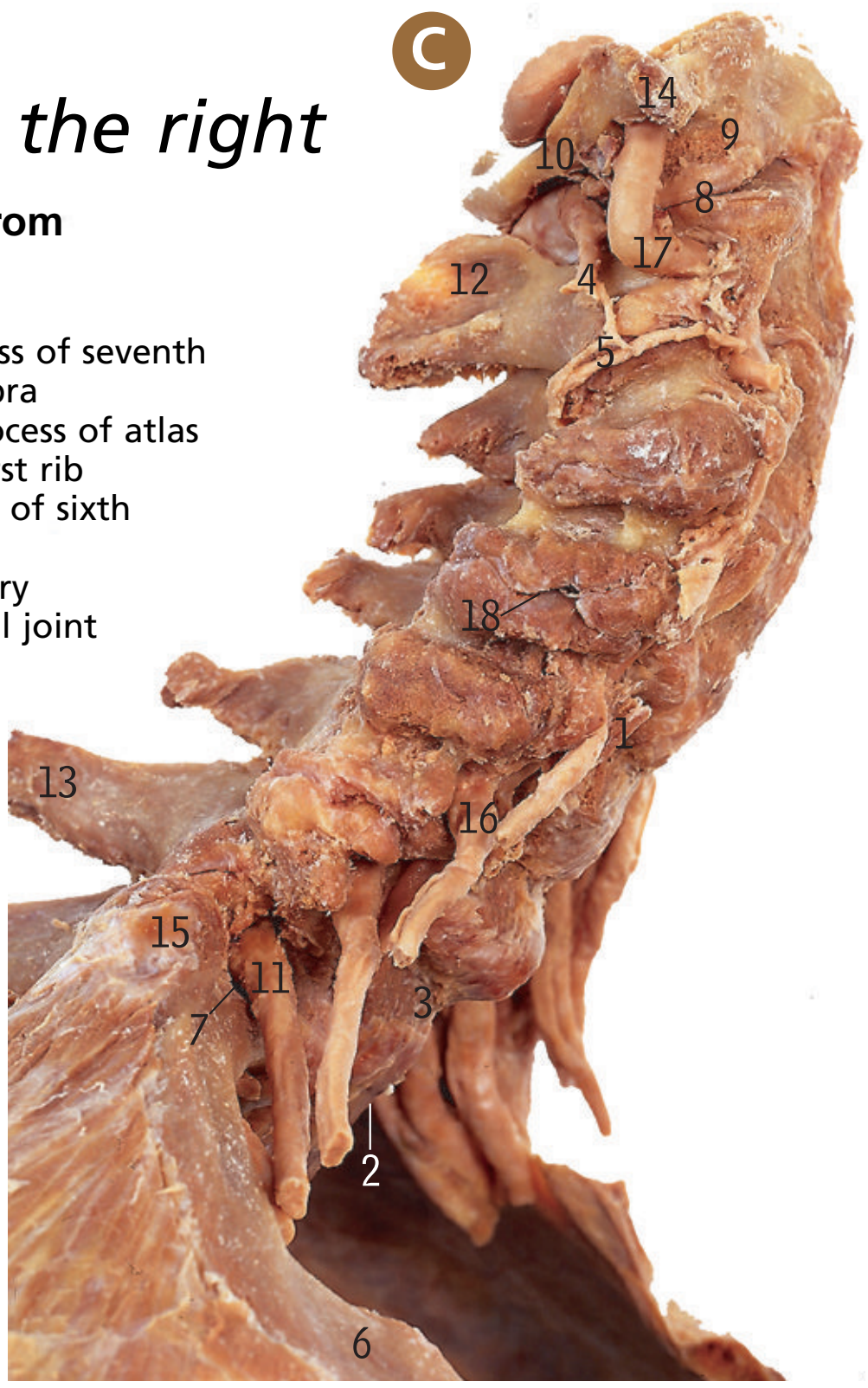

The first and second spinal nerves pass, respectively, above and below the posterior arch of the atlas.

D Cervical region, from the left

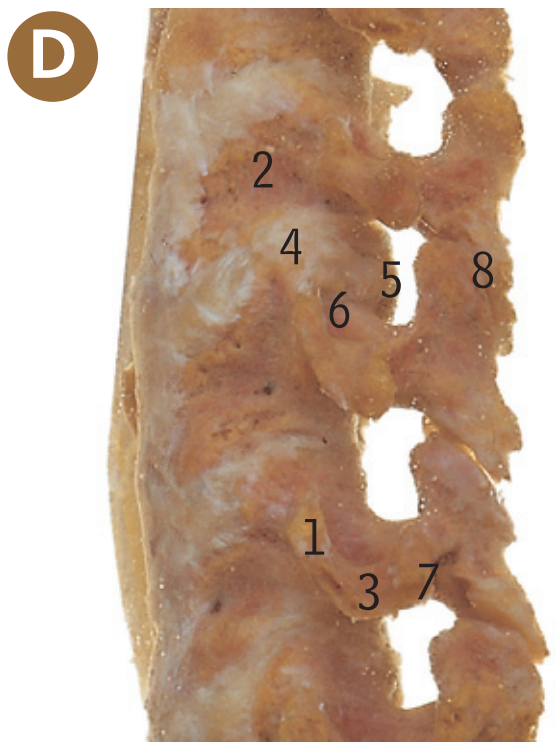

Soft tissue has been removed to show the boundaries of intervertebral foramina (as at 5). Compare with the cleared specimens of thoracic vertebrae on page 98, A.

1. Anterior tubercle of transverse process of fifth cervical vertebra
2. Body of third cervical vertebra
3. Intertubercular lamella of transverse process of fifth cervical vertebra
4. Intervertebral disc
5. Intervertebral foramen
6. Pedicle
7. Posterior tubercle of transverse process of fifth cervical vertebra
8. Zygapophyseal joint

Each intervertebral foramen (as at D5) is bounded in front by a vertebral body and intervertebral disc (D2 and 4), above and below by pedicles (D6), and behind by a zygapophyseal joint (D8).

In the thoracic and lumbar regions there are the same number of pairs of spinal nerves as there are vertebrae (twelve thoracic and five lumbar), and spinal nerves are numbered from the vertebra beneath whose pedicles they emerge. In the cervical region, there are seven cervical vertebrae and eight cervical nerves. The first nerve emerges between the occipital bone of the skull and the atlas, and the eighth below the pedicle of the seventh cervical vertebra.

E Lower cervical and upper thoracic regions, from behind

The vertebral arches and most of the dura mater and arachnoid have been removed, to show dorsal nerve rootlets (5) emerging from the spinal cord (9) to unite as a dorsal nerve root and enter the dural sheath (as at 7). Ventral nerve roots do the same from the ventral aspect of the cord but are not seen in this view as they are obscured by the dorsal roots.

1. Angulation of nerve roots entering dural sheath
2. Dorsal ramus of fifth thoracic nerve
3. Dorsal root ganglion of eighth cervical nerve
4. Dorsal root ganglion of second thoracic nerve
5. Dorsal rootlets of eighth cervical nerve
6. Dura mater
7. Dural sheath of second thoracic nerve
8. Pedicle of first thoracic vertebra
9. Spinal cord and posterior spinal vessels
10. Ventral ramus of fifth thoracic nerve

A Vertebral column and spinal cord

cervical and upper thoracic regions, from the left

1 Arachnoid mater
2 Body of first thoracic vertebra
3 Denticulate ligament
4 Dorsal ramus of fifth cervical nerve
5 Dorsal root ganglion of eighth cervical nerve
6 Dorsal root ganglion of fifth cervical nerve
7 Dorsal rootlets of fifth cervical nerve
8 Dura mater
9 Foramen magnum
10 Medulla oblongata
11 Occipital bone
12 Posterior arch of atlas
13 Spinal cord
14 Spinal part of accessory nerve
15 Spinous process of axis (abnormally large)
16 Spinous process of seventh cervical vertebra
17 Sympathetic trunk
18 Ventral ramus of fifth cervical nerve
19 Ventral rootlets of fifth cervical nerve

Parts of the vertebral arches and meninges have been removed to show the denticulate ligament (3). Dorsal nerve rootlets lie behind it (as at 7) and ventral nerve rootlets in front of it (as at 19 but largely hidden in this view).

Each spinal nerve is formed by the union of ventral and dorsal nerve roots.

Each nerve root is formed by the union of several rootlets (as at A7).

The union of ventral and dorsal nerve roots to form a spinal nerve occurs immediately distal to the ganglion on the dorsal root (as at A6), within the intervertebral foramen, and the nerve at once divides into a ventral and a dorsal ramus (formerly called ventral and dorsal primary rami) (as at A18 and 4). The spinal nerve proper is thus only 1–2 mm in length, but is often so short that the rami appear to be branches of the ganglion itself.

The lowest cervical and upper thoracic nerve roots become acutely angled in order to enter their dural sheaths.

B Spinal cord

cervical region, from the front

For this ventral view of the upper part of the spinal cord (6), the dura and arachnoid mater have been incised longitudinally and turned aside (2) to show the ventral nerve rootlets and roots (as at 7) passing laterally in front of the denticulate ligament (3) to enter meningeal nerve sheaths with dorsal roots (as at 4) and form a spinal nerve. On some roots, branches of radicular vessels (as at 5) are seen anastomosing with anterior spinal vessels (1).

1 Anterior spinal vessels
2 Arachnoid and dura mater
3 Denticulate ligament
4 Dorsal root of sixth cervical nerve
5 Radicular vessels
6 Spinal cord
7 Ventral root of seventh cervical nerve entering dural sheath

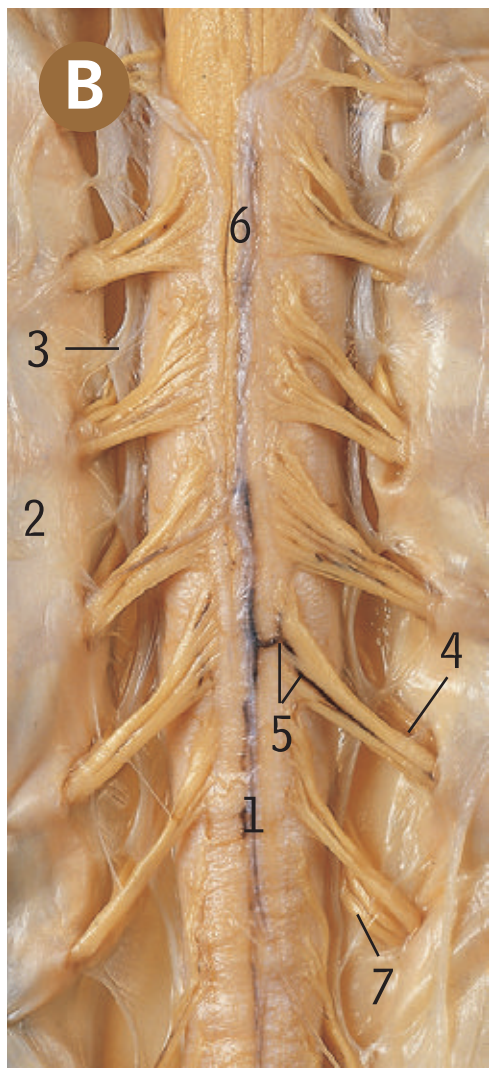

The denticulate ligament (B3) is composed of pia mater. The ventral and dorsal nerve roots pass, respectively, ventral and dorsal to the ligament, which extends laterally from the side of the cord and is attached by its spiky denticulations (as at B3) to the arachnoid and dura mater in the intervals between dural nerve sheaths. The highest denticulation is above the first cervical nerve and the lowest below the twelfth thoracic nerve.

Transverse myelitis, see page 108.

Vertebral column and spinal cord

C Lumbar and sacral regions, from behind

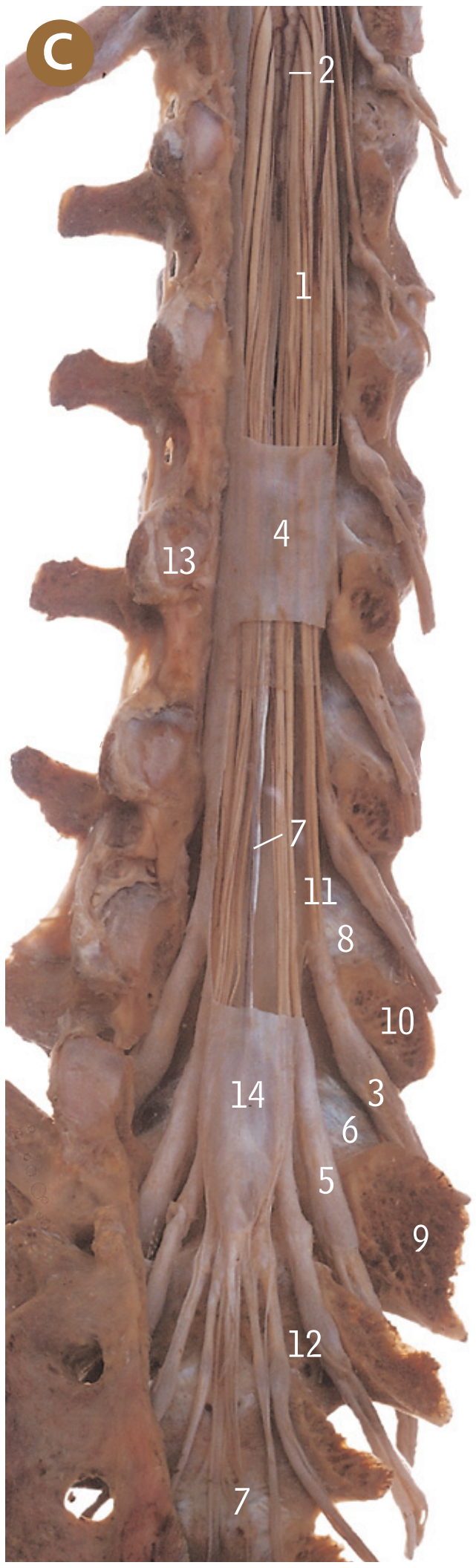

Parts of the vertebral arches and meninges have been removed, to show the cauda equina (1) and nerve roots entering their meningeal sheaths (as at 11), outlined as linear bands by contrast medium in the radiculogram (D).

1 Cauda equina
2 Conus medullaris of spinal cord
3 Dorsal root ganglion of fifth lumbar nerve
4 Dura mater
5 Dural sheath of first sacral nerve roots
6 Fifth lumbar (lumbosacral) intervertebral disc
7 Filum terminale
8 Fourth lumbar intervertebral disc
9 Lateral part of sacrum
10 Pedicle of fifth lumbar vertebra
11 Roots of fifth lumbar nerve
12 Second sacral vertebra
13 Superior articular process of third lumbar vertebra
14 Thecal sac

D Lumbar radiculogram

See label list above for D.

E Lower thoracic and upper lumbar regions

The specimen is seen from the left with parts of the vertebral arches and meninges removed, to show (at the front) part of the sympathetic trunk (13) on the vertebral bodies and (at the back) the spinous ligaments (7 and 11).

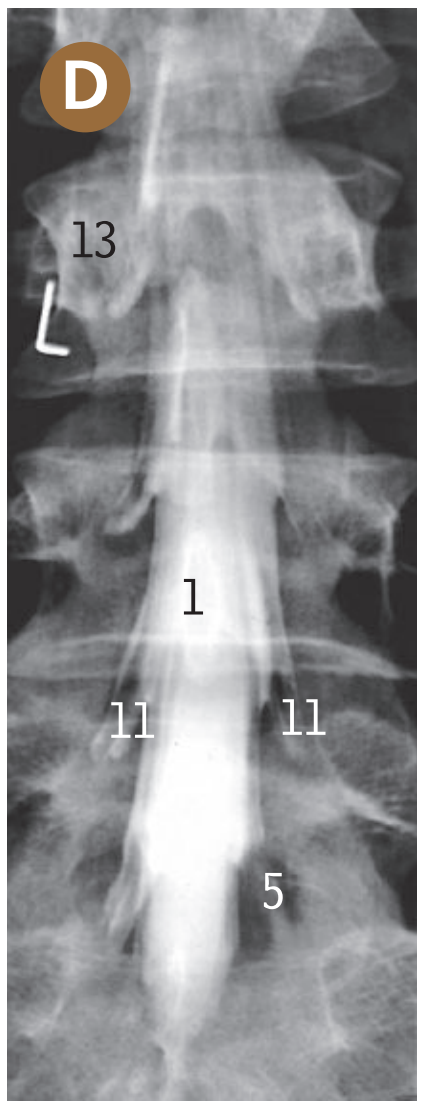

1 Body of first lumbar vertebra
2 Cauda equina
3 Dorsal root ganglion of tenth thoracic nerve
4 Dura mater
5 First lumbar intervertebral disc
6 Greater splanchnic nerve
7 Interspinous ligament
8 Rami communicantes
9 Spinal cord
10 Spinous process of tenth thoracic vertebra
11 Supraspinous ligament
12 Sympathetic ganglion
13 Sympathetic trunk

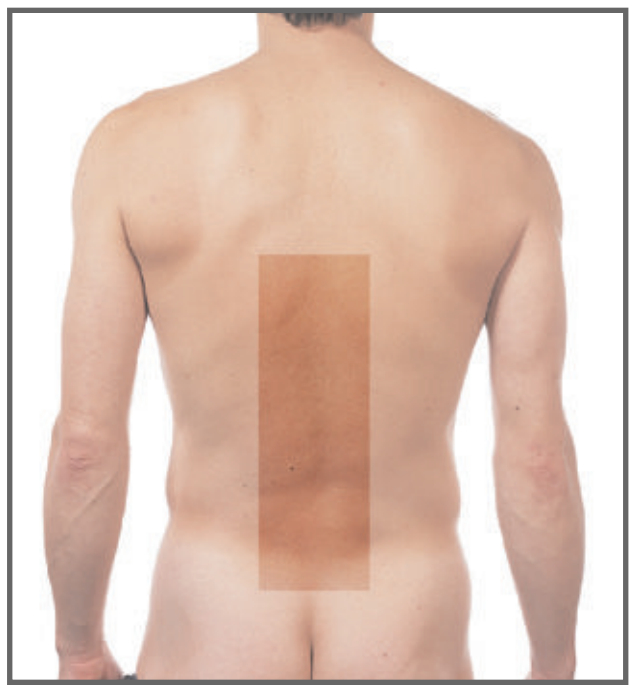

The spinal cord usually ends at the level of the first lumbar vertebra.

The subarachnoid space ends at the level of the second sacral vertebra.

The conus medullaris (C2) is the lower, pointed end of the spinal cord.

The cauda equina (C1) consists of the dorsal and ventral roots of the lumbar, sacral and coccygeal nerves. Note that it is nerve roots which form the cauda, not the spinal nerves themselves; these are not formed until ventral and dorsal roots unite at the level of an intervertebral foramen, immediately distal to the dorsal root ganglion (as at C3).

Epidural anaesthesia, spinal anaesthesia, see page 108.

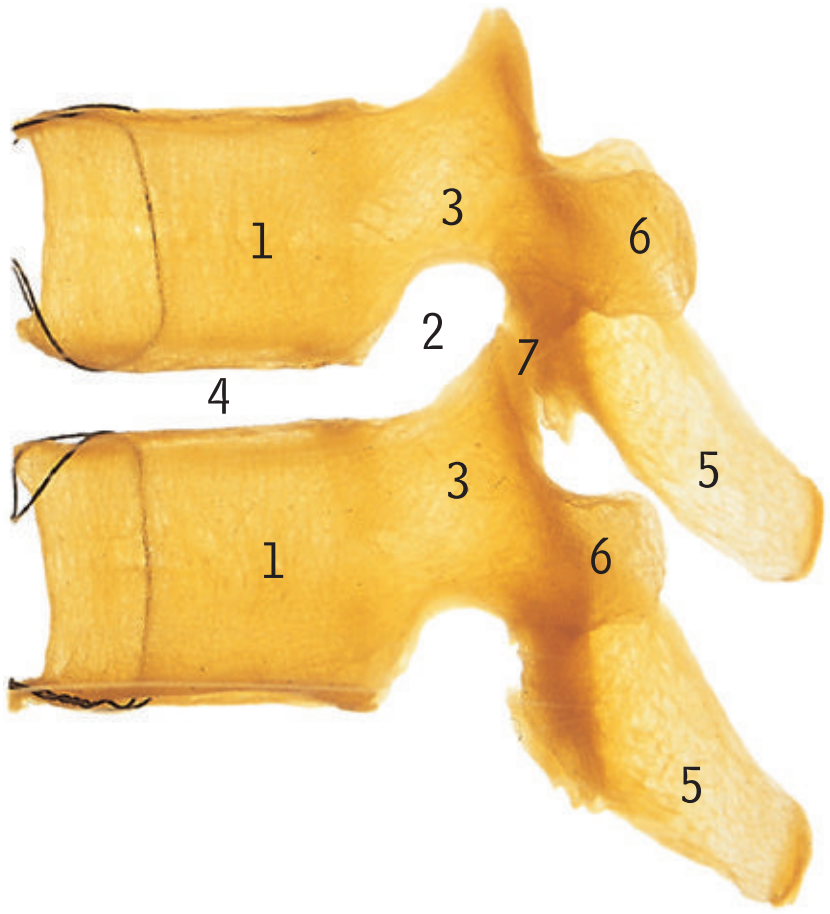

A Thoracic vertebrae *cleared specimens*

The pairs of vertebrae are seen from the side and articulated to show the boundaries of an intervertebral foramen (2).

1 Body
2 Intervertebral foramen
3 Pedicle
4 Space for intervertebral disc
5 Spinous process
6 Transverse process
7 Zygapophyseal joint

The intervertebral foramen (A2) is bounded in front by the lower part of the vertebral body (A1) and the intervertebral disc (A4), above and below by the pedicles (A3), and behind by the zygapophyseal joint (A7).

The posterior longitudinal ligament is broad where it is firmly attached to the intervertebral discs, but narrow and less firmly attached to the vertebral bodies, leaving vascular foramina patent and allowing the basivertebral veins which emerge from them to enter the internal vertebral venous plexus.

The anterior longitudinal ligament (B1) is uniformly broad and firmly attached to discs and vertebral bodies.

B Vertebral column *lower lumbar region, from the front*

At the top the anterior longitudinal ligament (1) has a marker behind it, and part of it lower down has been reflected off an intervertebral disc (4) and vertebral bodies (2 and 3).

1 Anterior longitudinal ligament
2 Body of fifth lumbar vertebra
3 Body of fourth lumbar vertebra
4 Fourth lumbar intervertebral disc
5 Lateral part of sacrum
6 Ventral ramus of fifth lumbar nerve

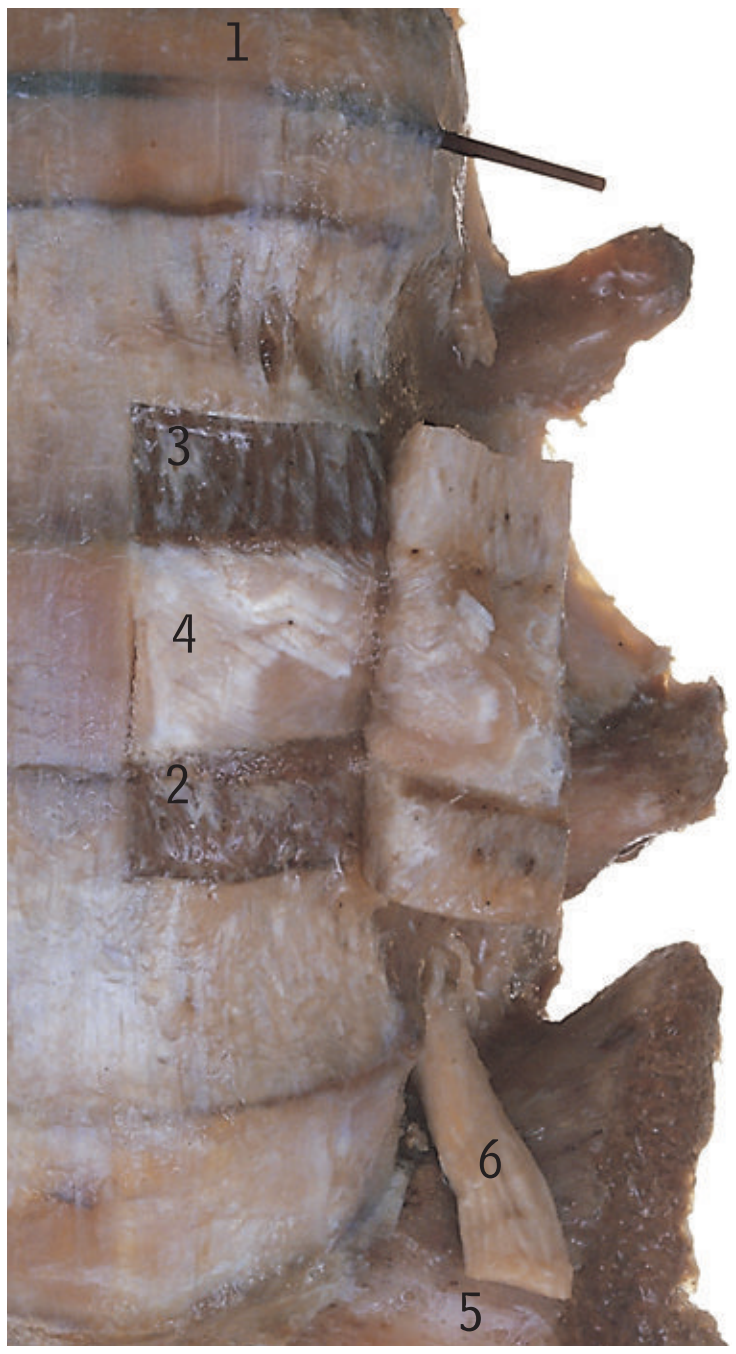

C Vertebral column *upper lumbar region, from the right*

The side view shows lumbar nerves emerging from intervertebral foramina (as at 5).

1 Anterior longitudinal ligament
2 Dorsal ramus of first lumbar nerve
3 Dorsal ramus of second lumbar nerve
4 First lumbar intervertebral disc
5 First lumbar nerve emerging from intervertebral foramen
6 First lumbar vertebra
7 Interspinous ligament
8 Rami communicantes
9 Spinous process of second lumbar vertebra
10 Supraspinous ligament
11 Sympathetic trunk ganglion
12 Twelfth rib
13 Ventral ramus of first lumbar nerve
14 Ventral ramus of second lumbar nerve
15 Zygapophyseal joint

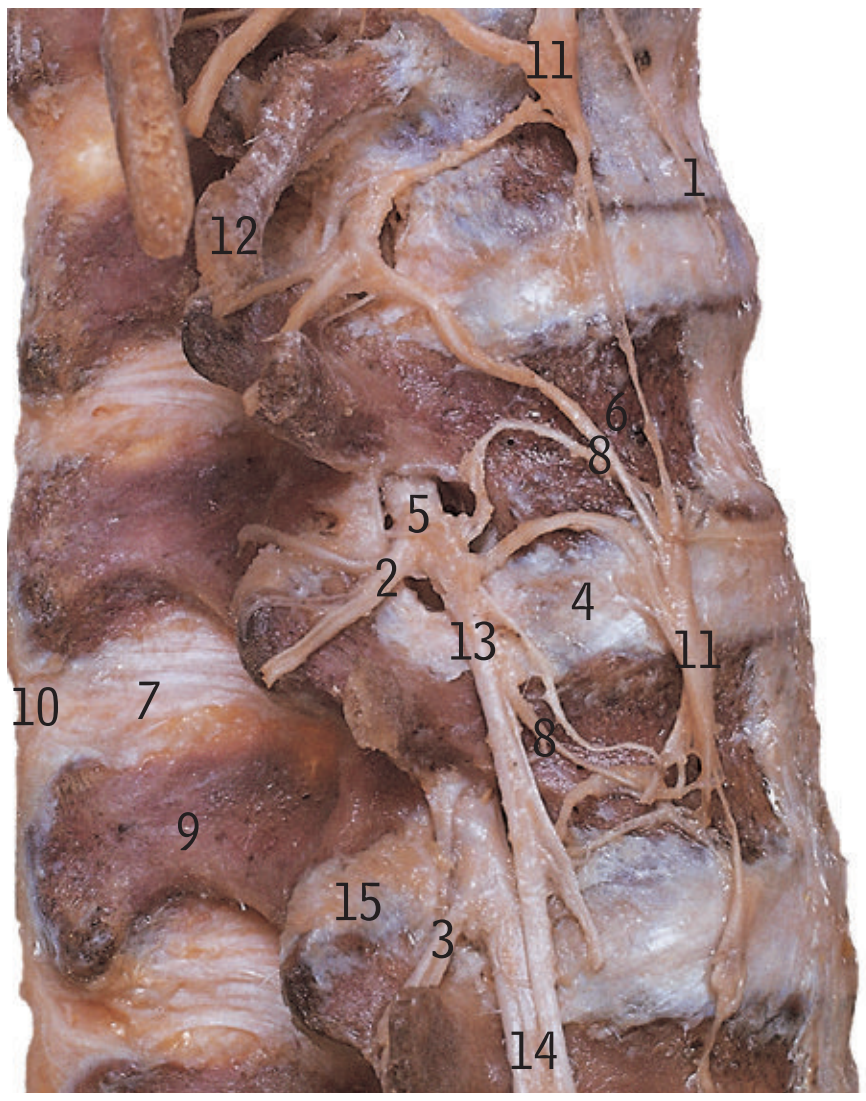

Compression of spinal nerve, vertebral venous plexus, see page 108.

A Vertebral column
lumbar region, from the right and behind

This posterolateral view of the right side of some lumbar vertebrae shows ligamenta flava (as at 4), which pass between the laminae of adjacent vertebrae (as at 2 and 3).

1 Interspinous ligament
2 Lamina of second lumbar vertebra
3 Lamina of third lumbar vertebra
4 Ligamentum flavum
5 Spinous process of second lumbar vertebra
6 Supraspinous ligament
7 Transverse process of third lumbar vertebra
8 Zygapophyseal joint

B Lumbar intervertebral disc
from above, in situ

1 Annulus fibrosus
2 Aorta
3 Extraperitoneal fat
4 Inferior vena cava
5 Laminations of annulus
6 Nucleus pulposus
7 Gonadal artery
8 Gonadal vein
9 Peritoneum, posterior abdominal wall
10 Psoas major muscle
11 Thoracolumbar fascia, anterior layer
12 Ureter

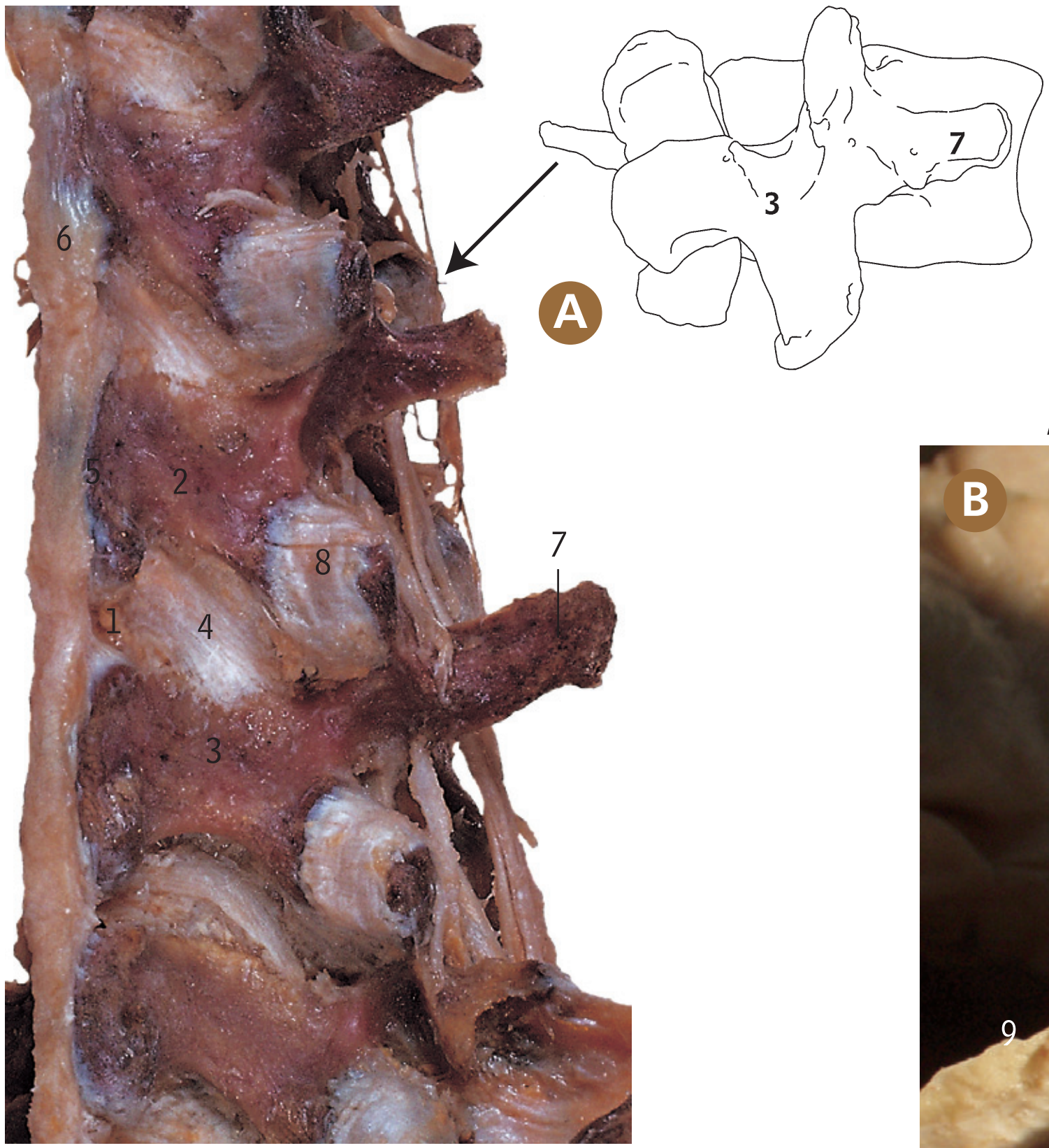

The nucleus pulposus of an intervertebral disc represents the remains of the notochord.

The annulus fibrosus of an intervertebral disc is derived from the mesenchyme between adjacent vertebral bodies.

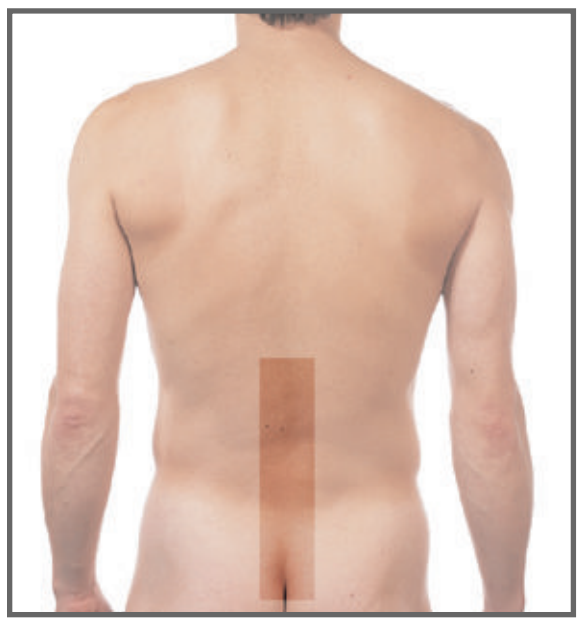

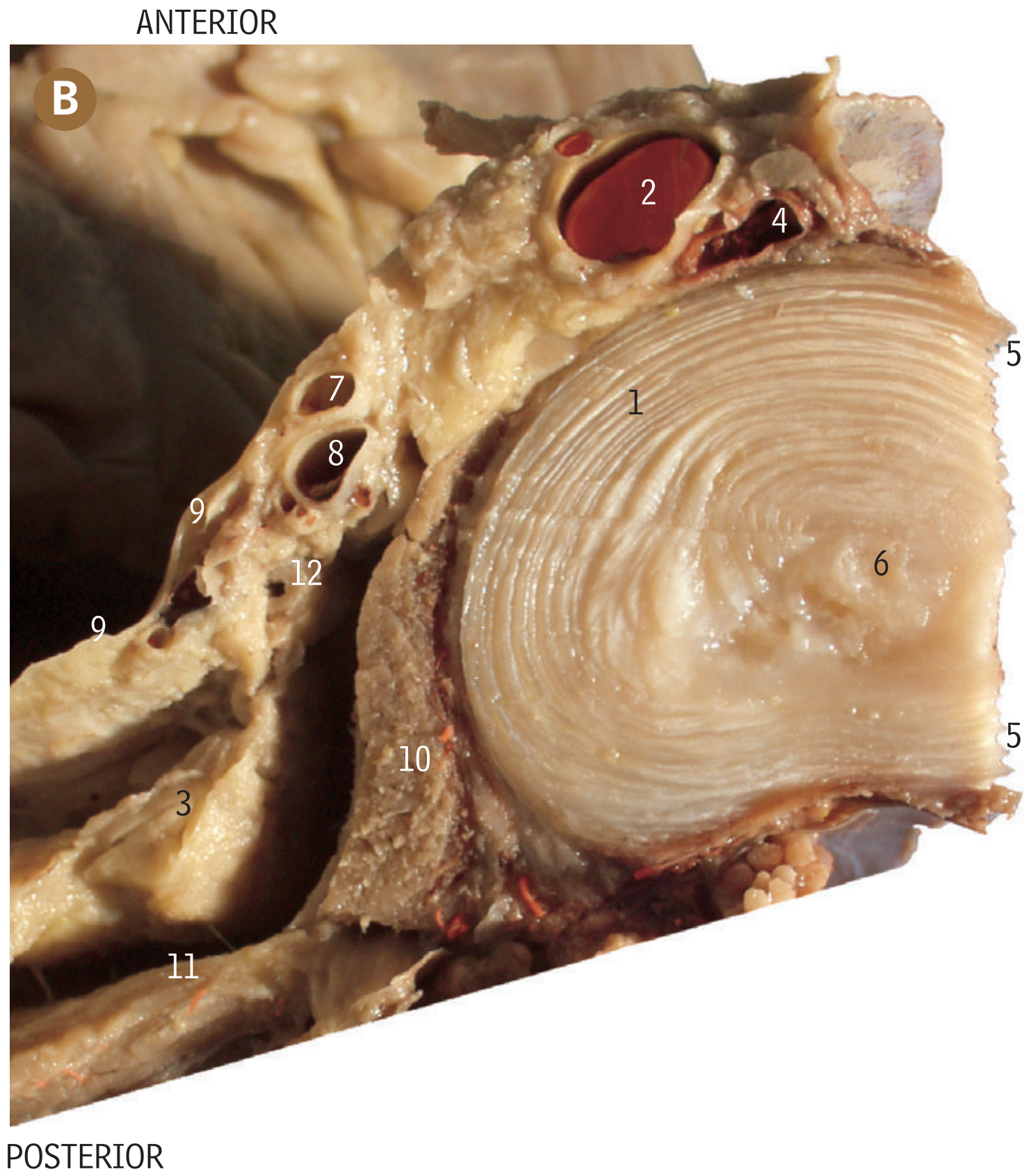

Lumbar puncture, spinal malformations (meningocoele), see page 108.

Back *surface anatomy*

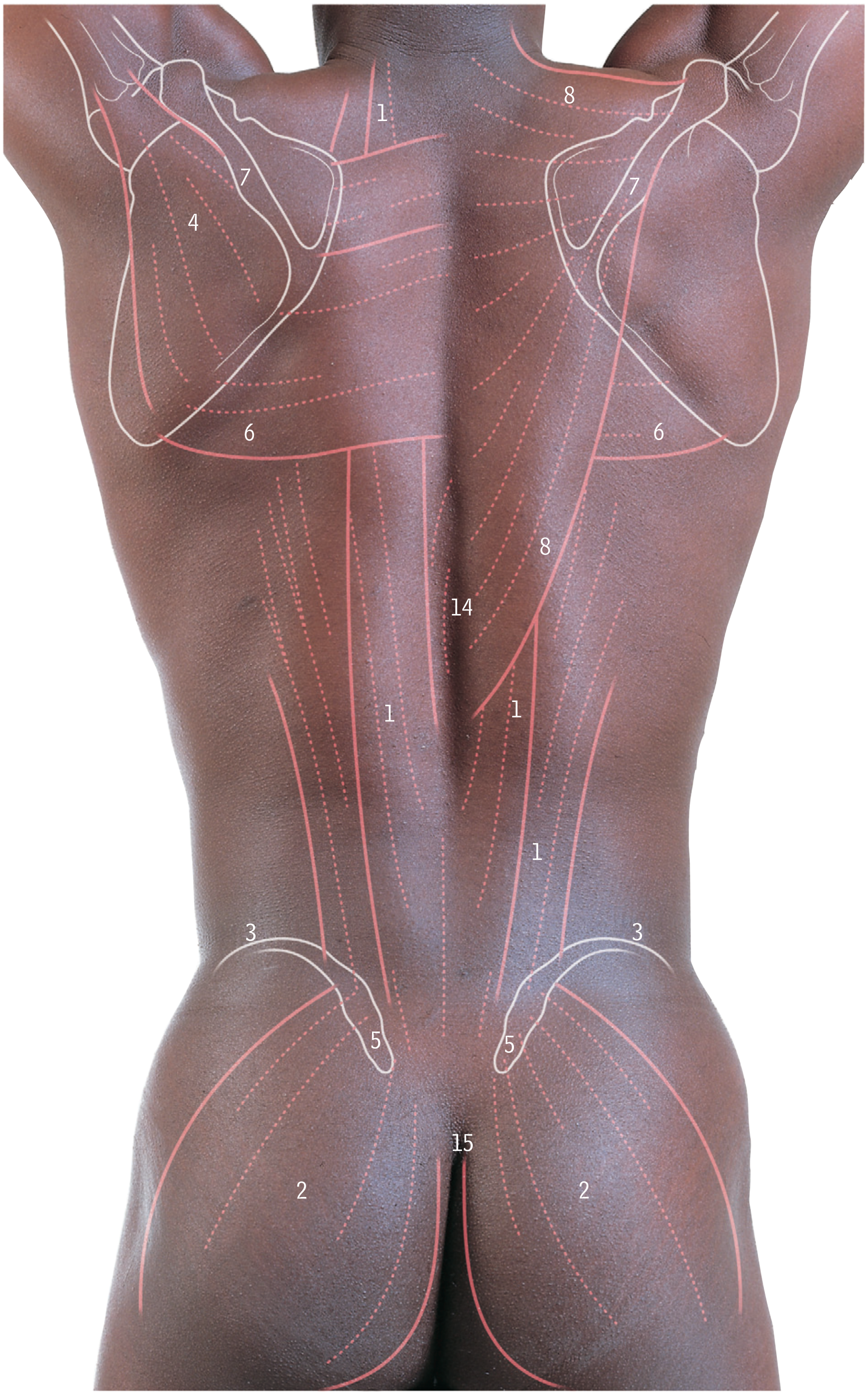

1 Erector spinae
2 Gluteus maximus
3 Iliac crest
4 Infraspinatus
5 Posterior superior iliac spine
6 Rhomboids
7 Spine of scapula
8 Trapezius

Back

Superficial musculature on left, deeper dissection on right.

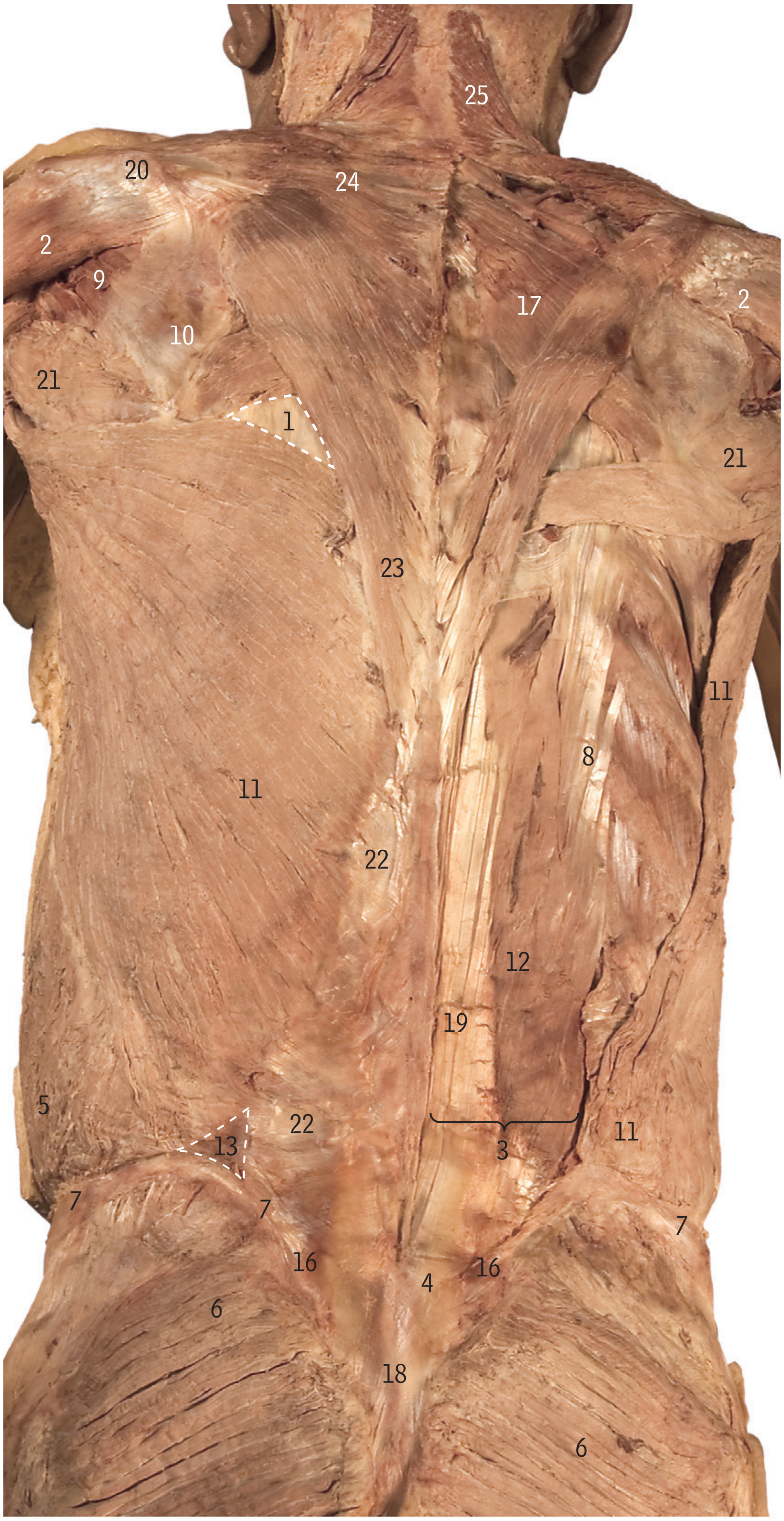

1 Auscultation triangle
2 Deltoid
3 Erector spinae
4 Erector spinae, tendon
5 External oblique muscle of the abdomen
6 Gluteus maximus
7 Iliac crest
8 Iliocostalis
9 Infraspinatus
10 Infraspinatus fascia
11 Latissimus dorsi
12 Longissimus
13 Lumbar triangle (of Petit)
14 Median furrow – see surface
15 Natal cleft – see surface
16 Posterior superior iliac spine
17 Rhomboid major
18 Sacrum
19 Spinalis
20 Spine of scapula
21 Teres major
22 Thoracolumbar fascia
23 Trapezius, lower fibres
24 Trapezius, middle fibres
25 Trapezius, upper fibres

Back

A close up left side

B close up right side

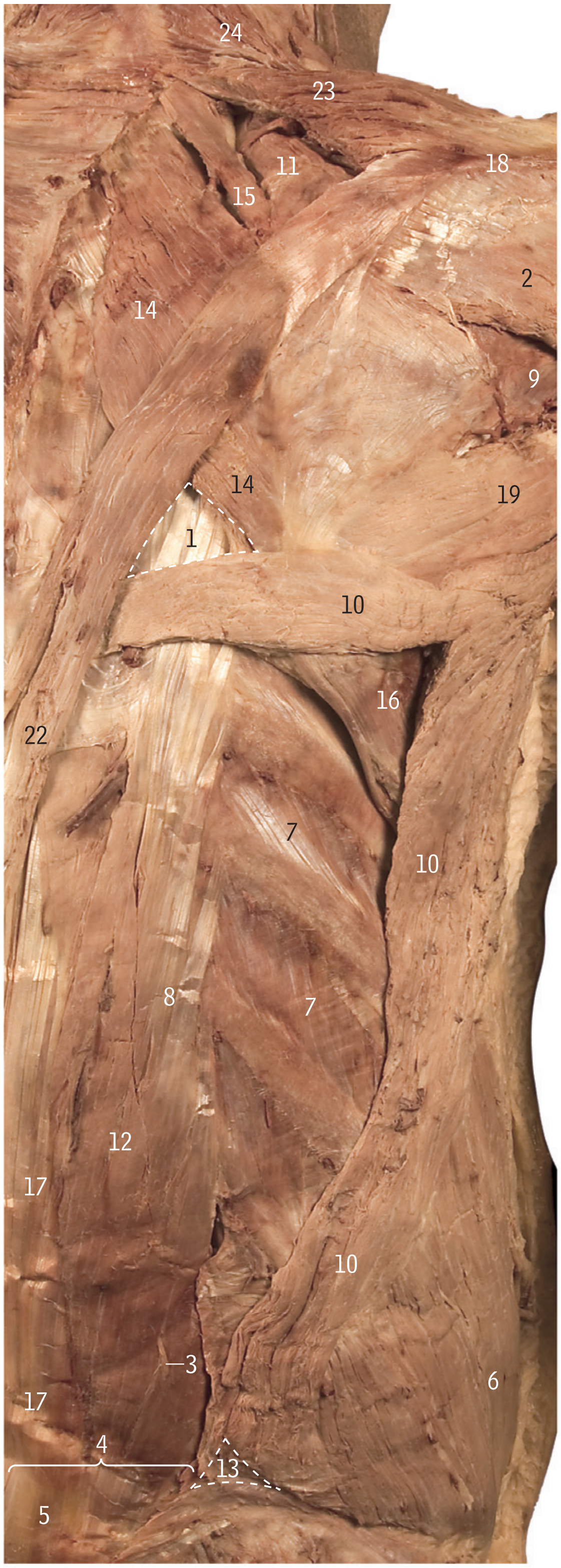

Windows cut in latissimus dorsi and trapezius muscles to reveal deeper layer of back musculature.

1 Auscultation triangle
2 Deltoid
3 Dorsal ramus, lumbar spinal nerve
4 Erector spinae
5 Erector spinae, tendon
6 External oblique muscle of the abdomen
7 External intercostal
8 Iliocostalis
9 Infraspinatus
10 Latissimus dorsi
11 Levator scapulae
12 Longissimus
13 Lumbar triangle
14 Rhomboid major
15 Rhomboid minor
16 Serratus anterior
17 Spinalis
18 Spine of scapula
19 Teres major
20 Teres minor
21 Thoracolumbar fascia
22 Trapezius, lower fibres
23 Trapezius, middle fibres
24 Trapezius, upper fibres
25 Triceps, long head

Back

A close up right side

Note windows cut in latissimus dorsi and trapezius.

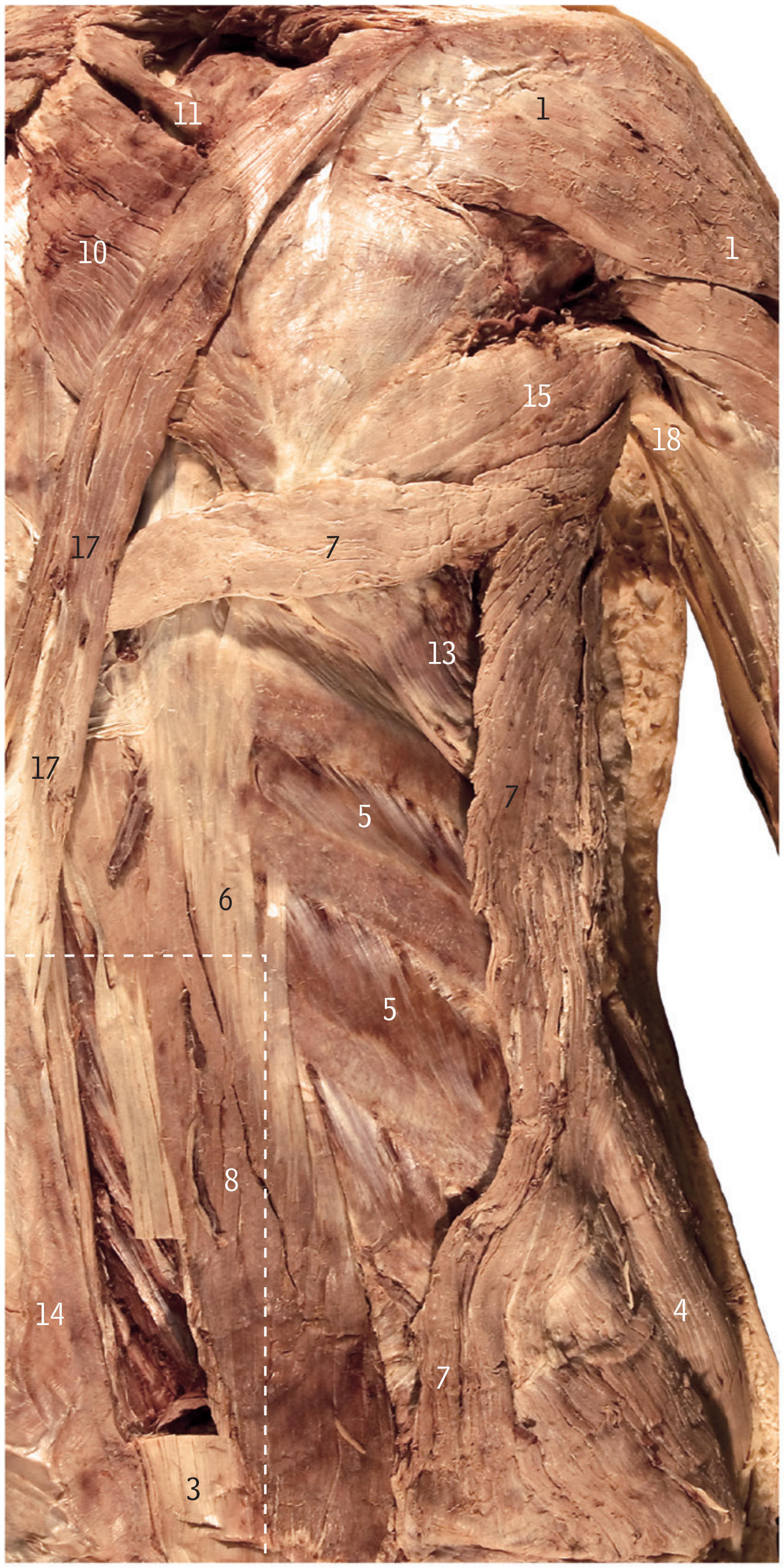

B close up right side

Note resection of upper lumbar and lower thoracic spinalis and part of longissimus muscles to reveal the transversospinalis group of muscles – the deepest components of erector spinae.

1 Deltoid
2 Dorsal ramus, thoracic spinal nerve
3 Erector spinae, tendon
4 External oblique muscle of the abdomen
5 External intercostal
6 Iliocostalis
7 Latissimus dorsi
8 Longissimus
9 Multifidus
10 Rhomboid major
11 Rhomboid minor
12 Semispinalis
13 Serratus anterior
14 Spinalis
15 Teres major
16 Thoracolumbar fascia
17 Trapezius, lower fibres
18 Triceps, long head

Sub-occipital triangle *superficial dissection*

1 Dorsal cutaneous branch, spinal nerve
2 Great auricular nerve
3 Greater occipital nerve
4 Lesser occipital nerve
5 Lesser occipital nerve anastomosis with third occipital nerve
6 Ligamentum nuchae
7 Occipital artery
8 Occipital belly (occipitalis) of occipitofrontalis muscle
9 Splenius capitis muscle
10 Third occipital nerve
11 Third occipital nerve reflected
12 Trapezius muscle

Sub-occipital triangle *deep dissection*

1 Greater occipital nerve
2 Ligamentum nuchae
3 Obliquus capitis inferior muscle
4 Obliquus capitis superior muscle
5 Occipital artery
6 Occipital bone
7 Posterior arch of C1 vertebra
8 Rectus capitis posterior major muscle
9 Semispinalis capitis muscle reflected
10 Semispinalis cervicis muscle
11 Spinalis cervicis muscle
12 Splenius capitis muscle reflected
13 Suboccipital nerve
14 Third occipital nerve
15 Vertebral artery

Upper cervical vertebrae *intraoral view*

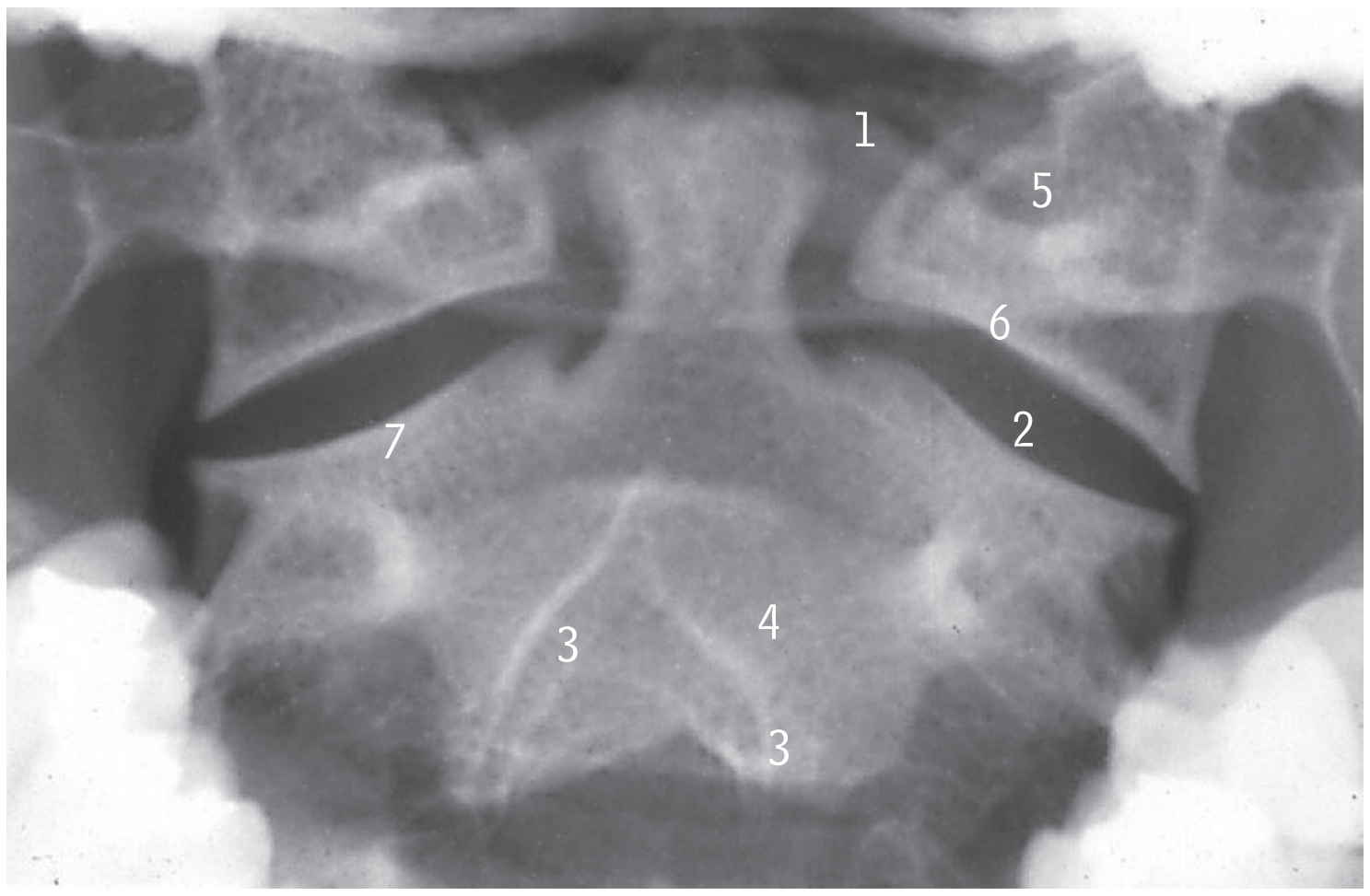

This is a standard radiographic view of the axis and its dens. The correct angle must be chosen with the mouth open to avoid overlying shadows of the teeth and jaws. The surfaces of the lateral atlanto-axial joints (5 and 7) do not make bony contact because the hyaline cartilage which covers the bony surfaces is not radio-opaque (this applies to any synovial joint). The outlines of the arches of the atlas are seen faintly between the sides of the shadow of the dens and the lateral masses of the atlas (5).

1 Arch of atlas
2 Atlanto-axial joint
3 Bifid spinous process
4 Body of axis
5 Lateral mass of atlas
6 Inferior articular process of atlas
7 Superior articular process of axis

Lower cervical and upper thoracic vertebrae

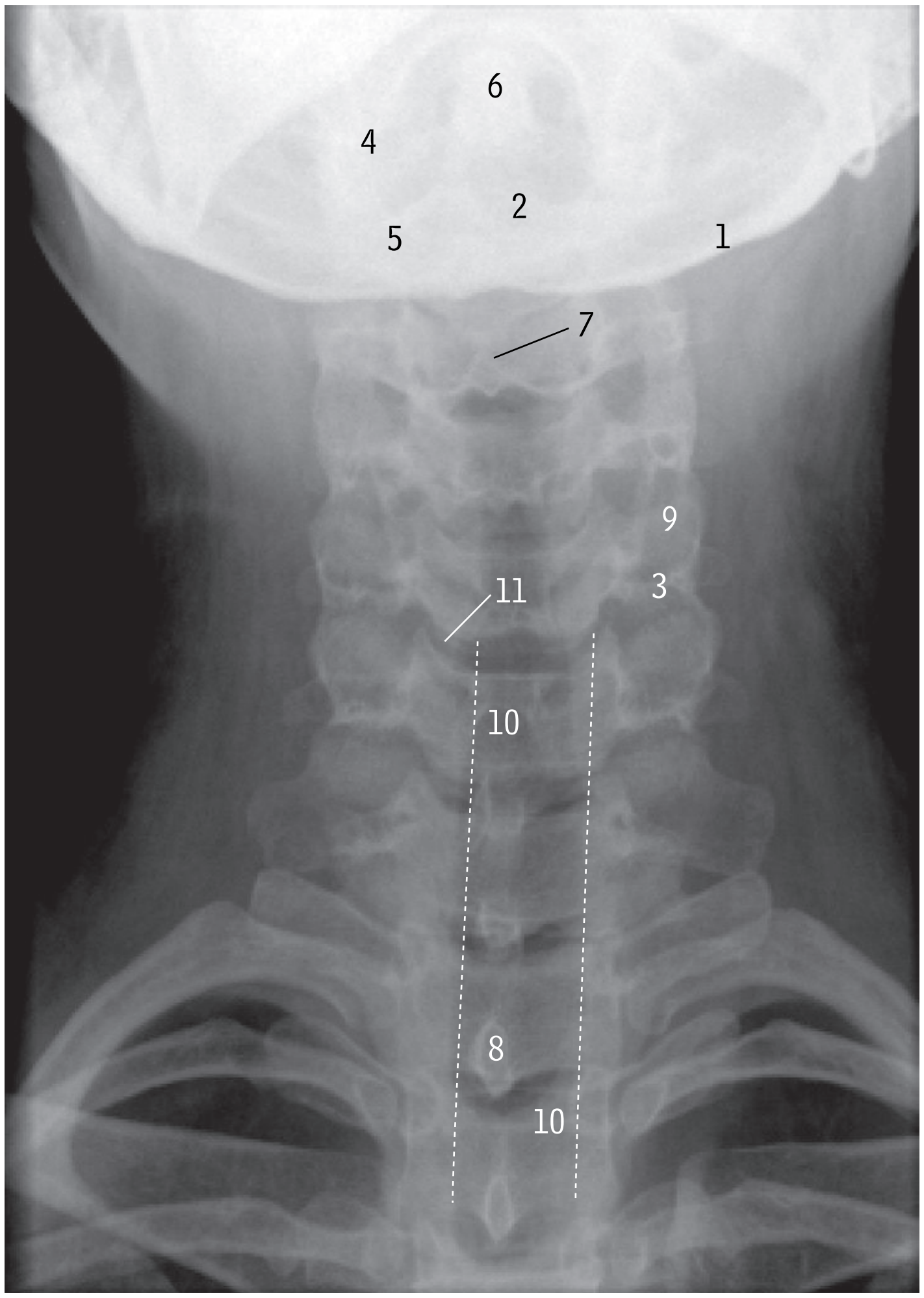

Note the tracheal shadow produced by the translucency of its contained air.

1 Basi-occiput
2 Body of axis
3 Inferior articular process
4 Lateral mass of atlas
5 Lateral mass of axis
6 Odontoid peg (dens)
7 Spinous process of third cervical vertebra
8 Spinous process of first thoracic vertebra
9 Superior articular process
10 Trachea
11 Uncovertebral joint

Atlanto-axial instability, cervical spinal immobilisation, see page 108.

Spine

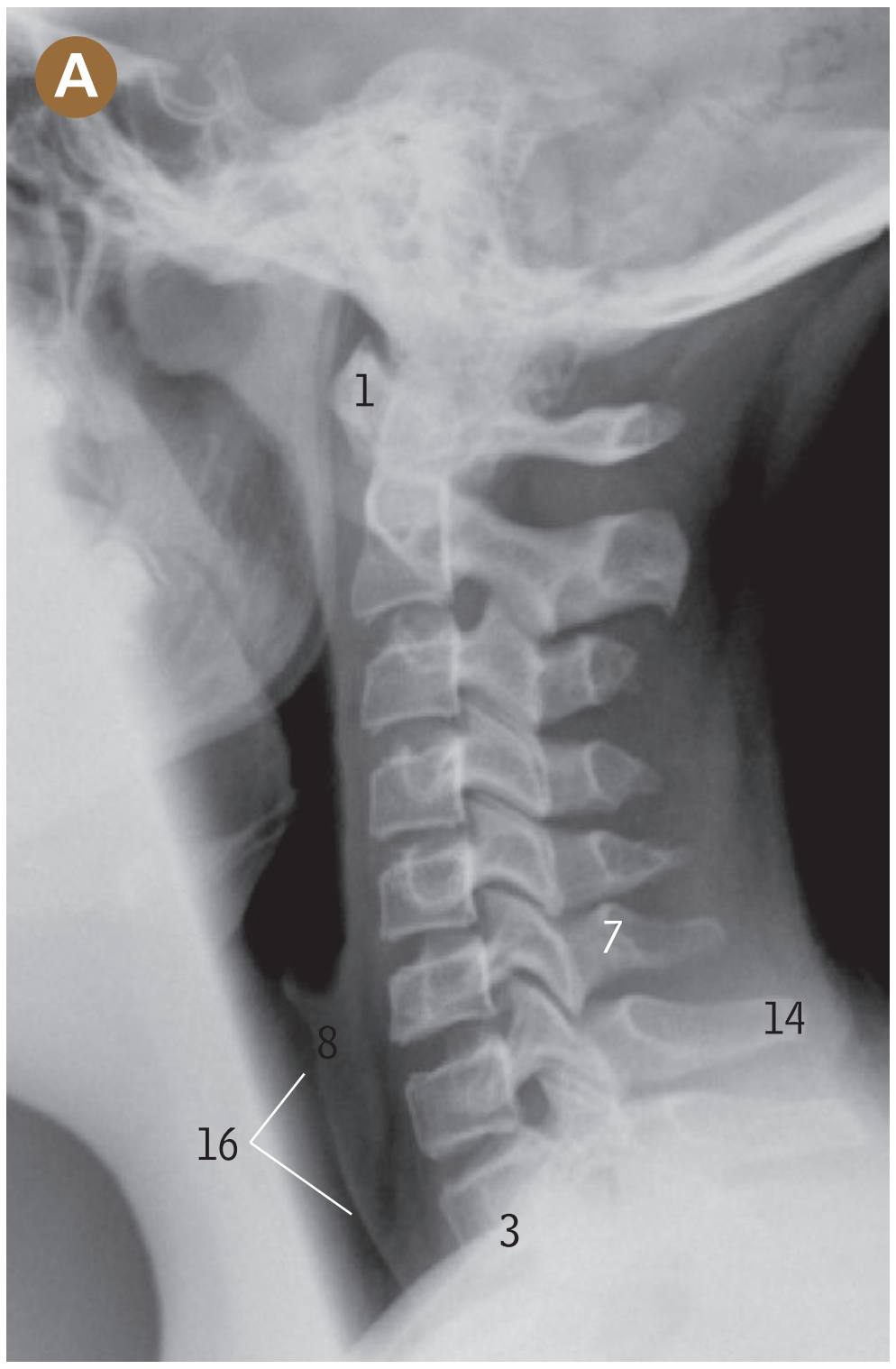

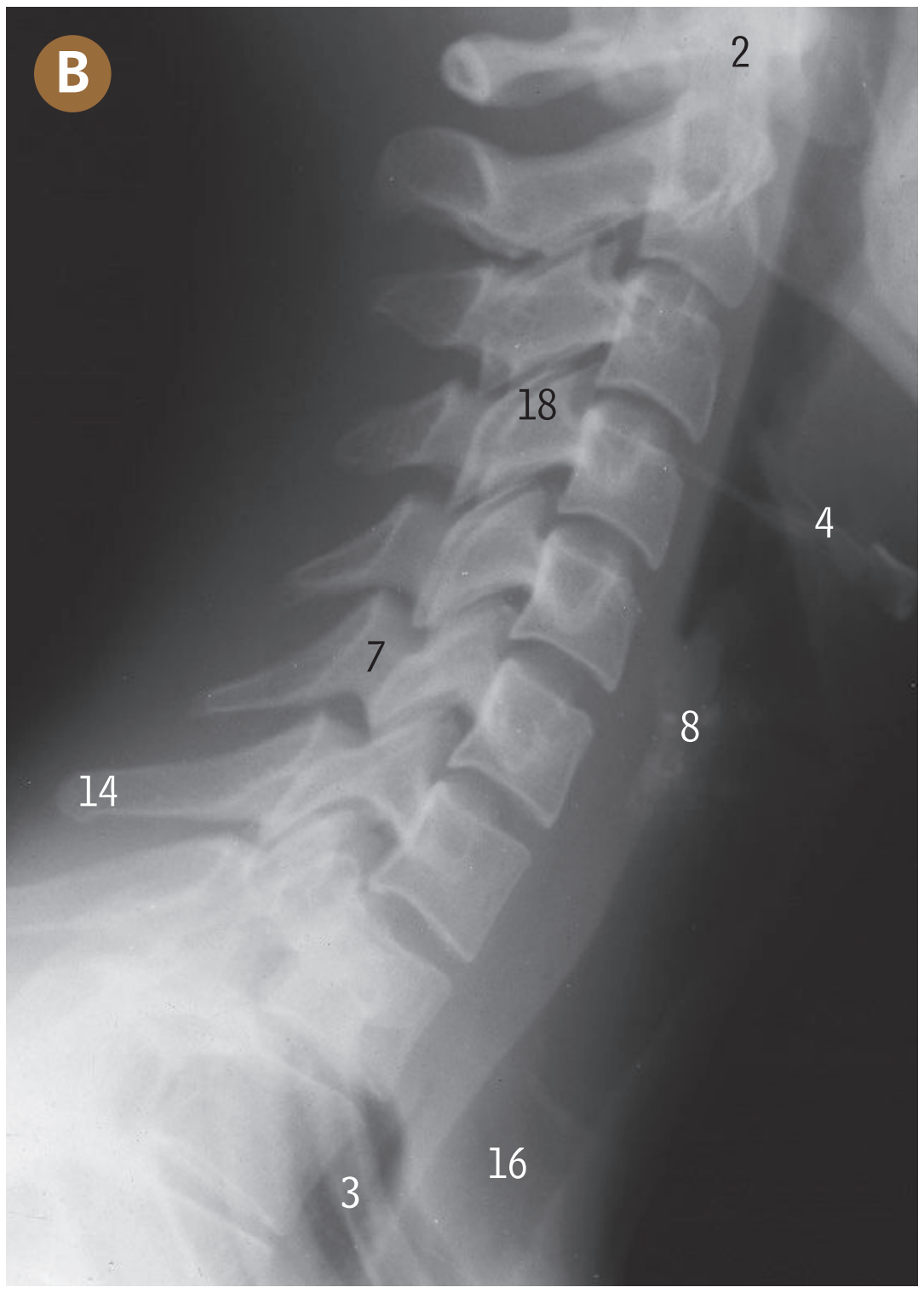

1 Anterior arch of axis
2 Dens of axis
3 First rib
4 Hyoid bone
5 Inferior articular process of first lumbar vertebra
6 Intervertebral disc space L2/3 level
7 Lamina of sixth cervical vertebra
8 Larynx
9 Lateral atlanto-axial joint
10 Lateral mass of atlas
11 Pars interarticularis of second lumbar vertebra
12 Pedicle of third lumbar vertebra
13 Spinous process of second lumbar vertebra
14 Spinous process of seventh cervical vertebra
15 Superior articular process of second lumbar vertebra
16 Trachea
17 Transverse process of third lumbar vertebra
18 Zygapophyseal joint

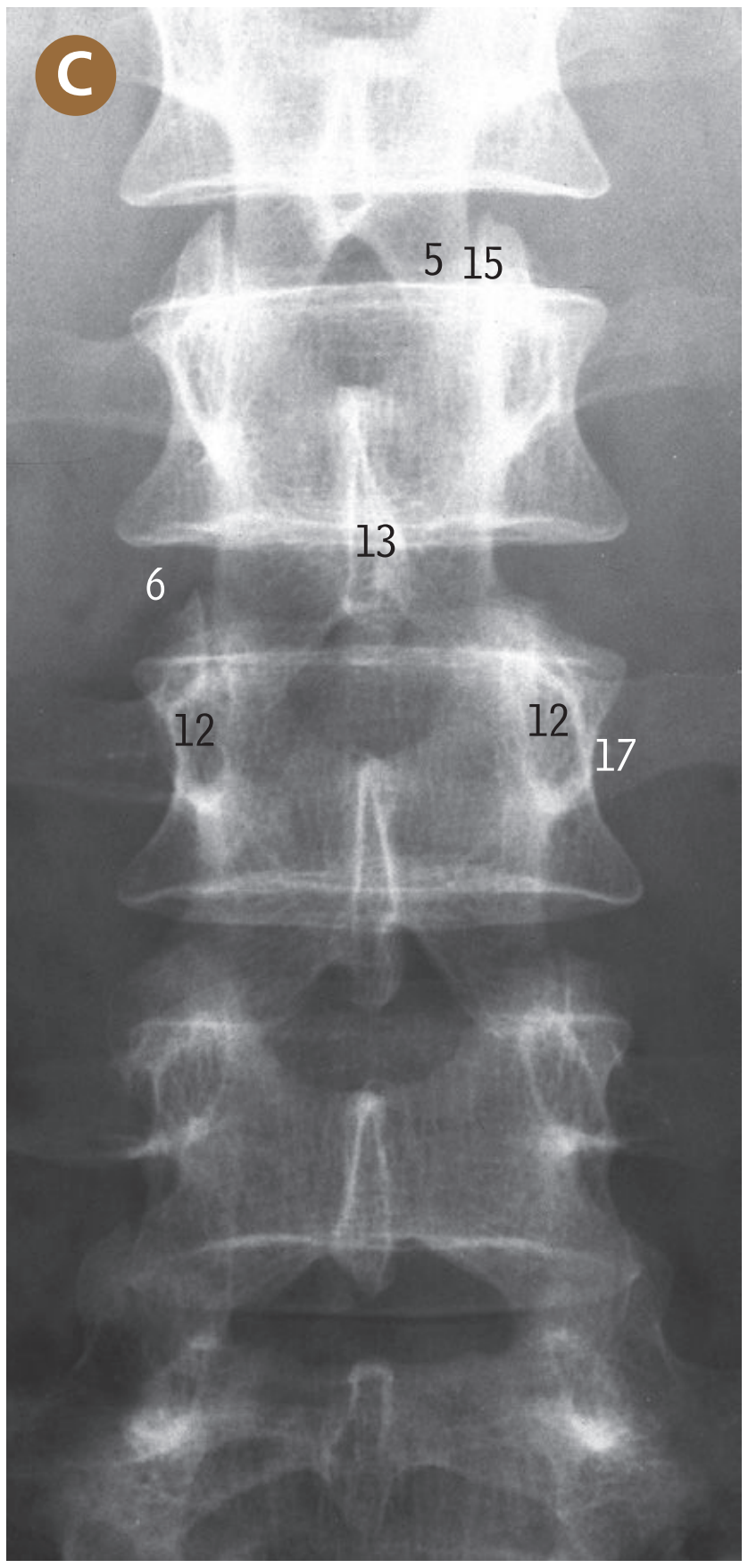

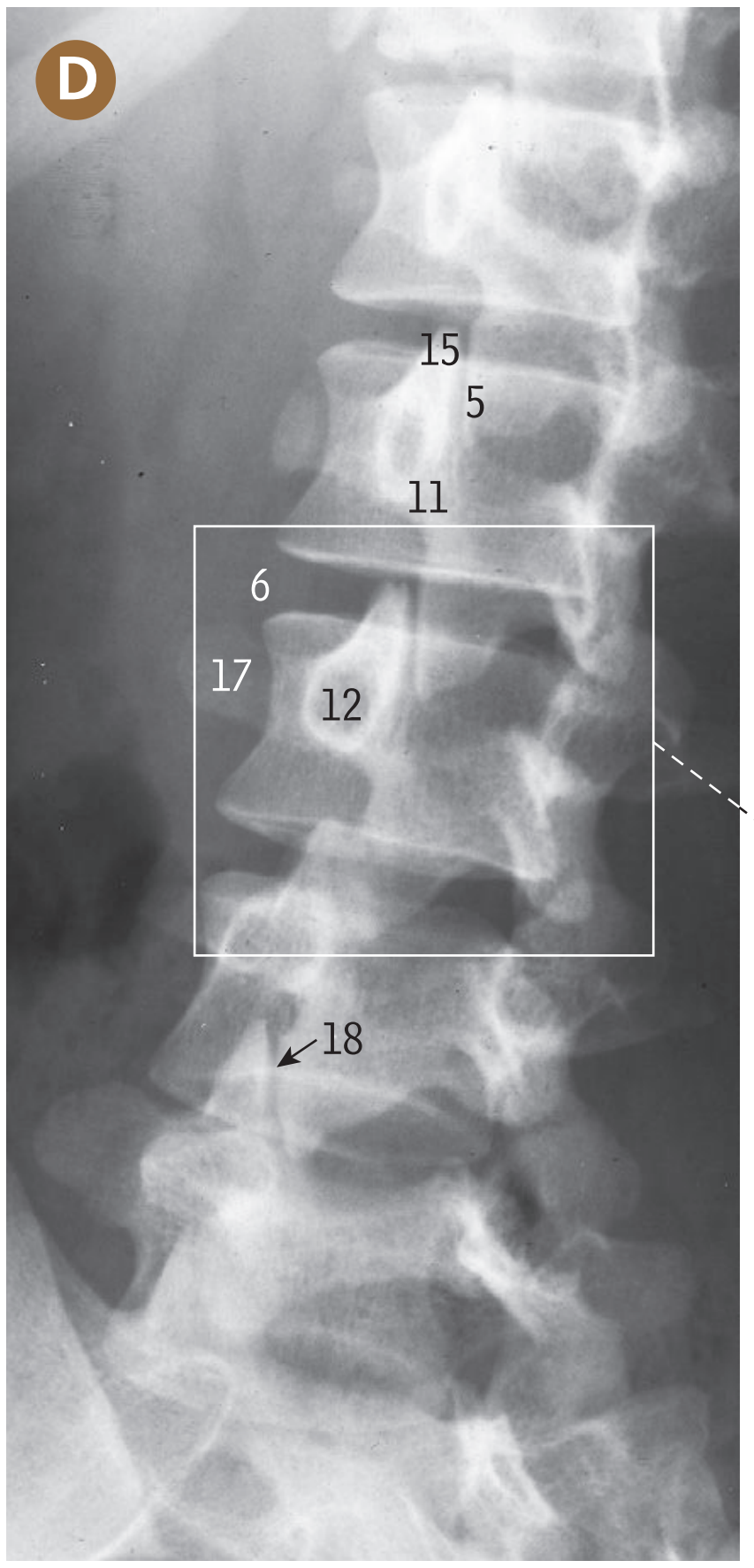

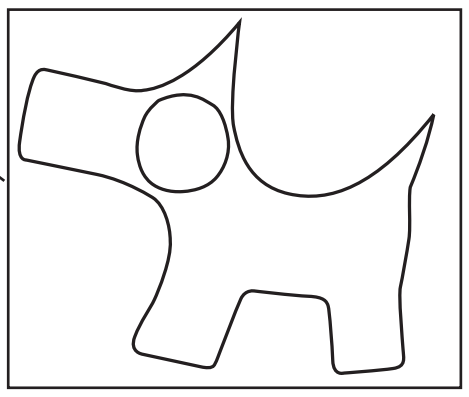

A cervical spine, lateral projection

B cervical spine, lateral projection

C lumbar spine, anteroposterior projection

D lumbar spine, oblique projection

The Scottie dog is seen on the oblique projection lumbar spine. The nose (17) is the transverse process, the ear (15) is the superior articular process, the eye (12) is the pedicle and the neck (11) is the pars interarticularis which may be incomplete in spondylolysis.

Vertebral fractures, see page 108.

Vertebral column and spinal cord

Clinical thumbnails, see website for details and further clinical images to download into your own notes.

Ankylosing spondylitis

Atlanto-axial instability

Caudal anaesthesia

Cervical spinal immobilisation

Coccydynia

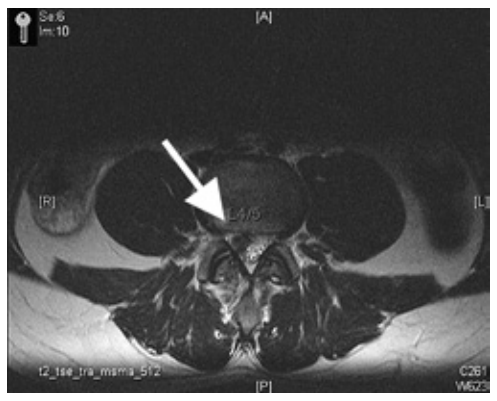
Compression of spinal nerve

Epidural anaesthesia

Laminectomy

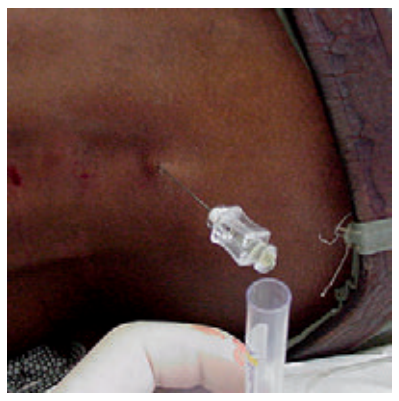
Lumbar puncture

Lumbar stenosis

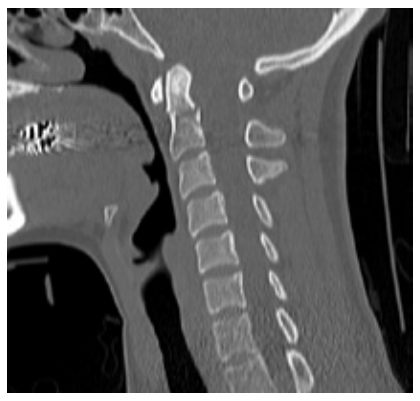
Odontoid peg fracture

Sacralisation

Spinal anaesthesia

Spinal malformations (meningocoele)

Spondylolisthesis

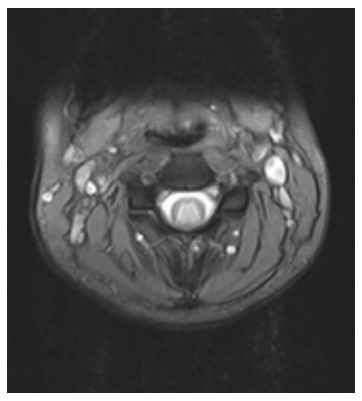
Transverse myelitis

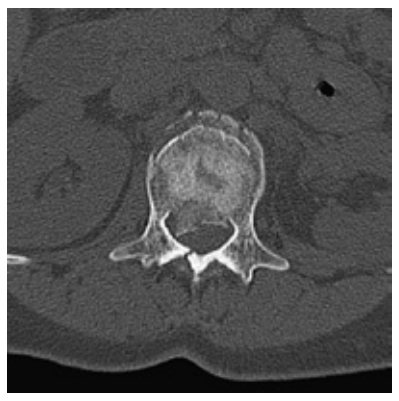
Vertebral fracture

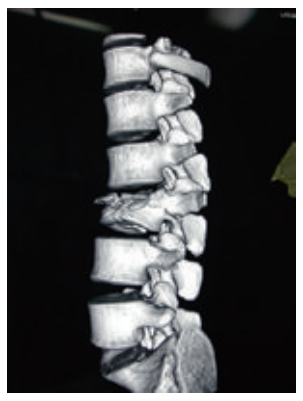
Vertebral lumbar fracture

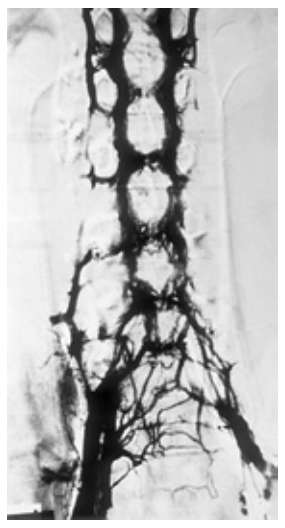
Vertebral venous plexus

Upper limb

3

Upper limb

A *surface anatomy* B *muscles* C *bones*

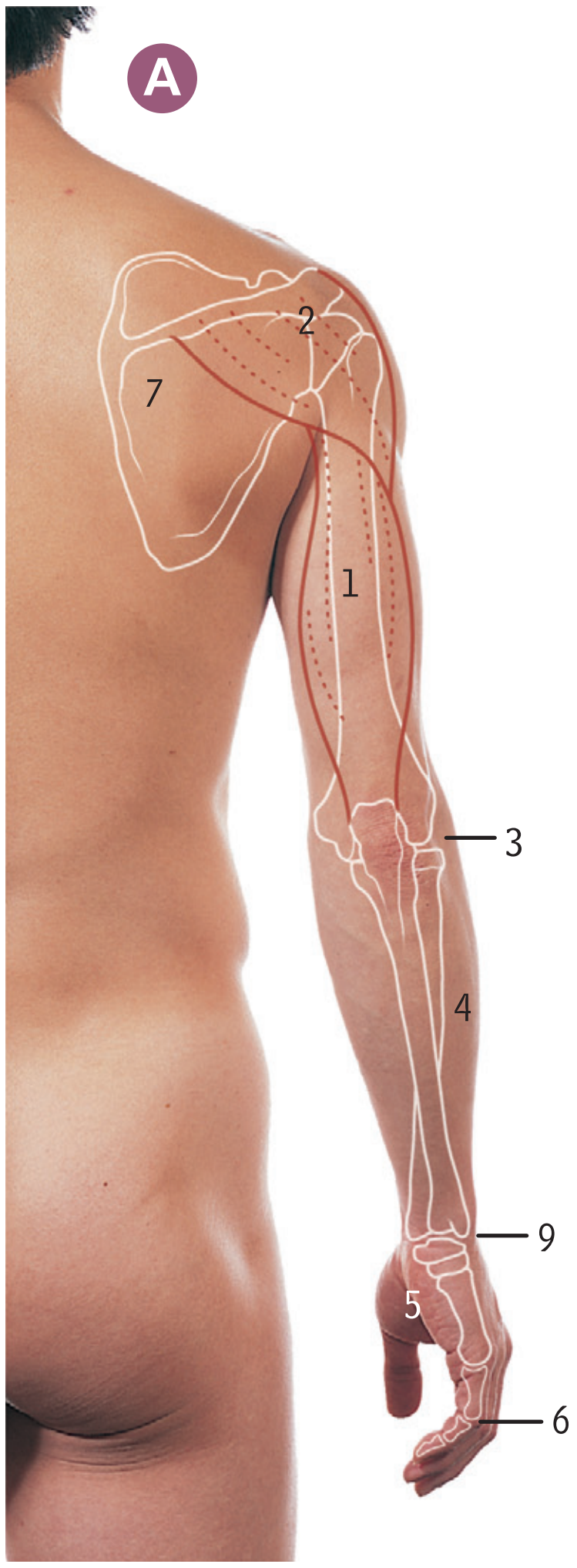

1 Arm
2 Deltoid
3 Elbow joint
4 Forearm
5 Hand
6 Interphalangeal joint
7 Scapula
8 Shoulder joint
9 Wrist joint

Accessory ossicles, see pages 170–172.

Left scapula

A **dorsal surface**

B **costal surface**

1. Acromial angle
2. Acromion
3. Coracoid process
4. Inferior angle
5. Infraspinous fossa
6. Lateral border
7. Margin of glenoid cavity
8. Medial border
9. Neck (and spinoglenoid notch on dorsal surface)
10. Spine
11. Subscapular fossa
12. Superior angle
13. Superior border
14. Suprascapular notch
15. Supraspinous fossa

The spine (A10) of the scapula projects from its dorsal surface with the acromion (A2) at the lateral end of the spine.

Left scapula *attachments*

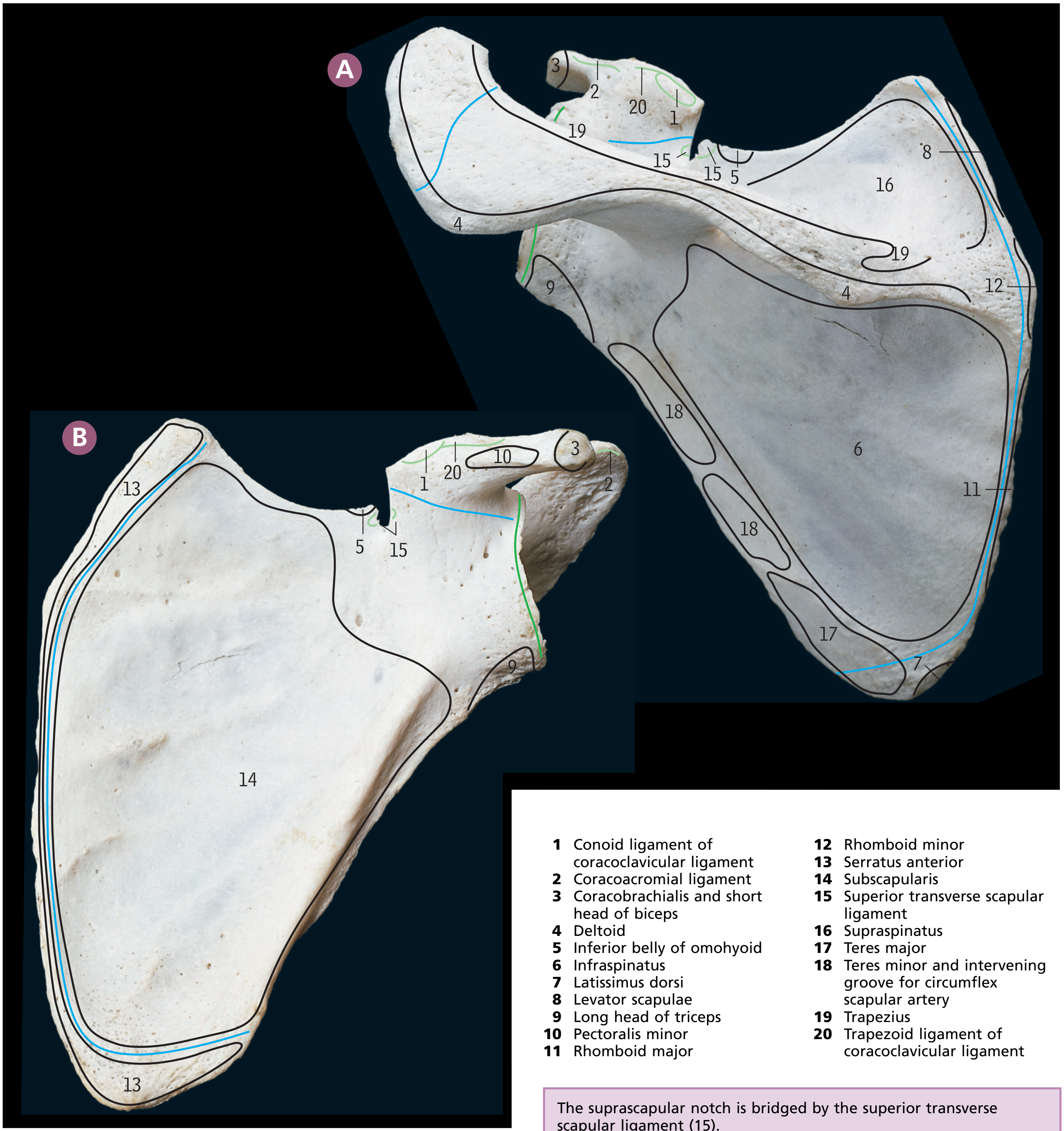

A **dorsal surface** **B** **costal surface**

Blue lines, epiphysial lines; green lines, capsular attachments of shoulder joint; pale green lines, ligament attachments

1. Conoid ligament of coracoclavicular ligament
2. Coracoacromial ligament
3. Coracobrachialis and short head of biceps
4. Deltoid
5. Inferior belly of omohyoid
6. Infraspinatus
7. Latissimus dorsi
8. Levator scapulae
9. Long head of triceps
10. Pectoralis minor
11. Rhomboid major
12. Rhomboid minor
13. Serratus anterior
14. Subscapularis
15. Superior transverse scapular ligament
16. Supraspinatus
17. Teres major
18. Teres minor and intervening groove for circumflex scapular artery
19. Trapezius
20. Trapezoid ligament of coracoclavicular ligament

The suprascapular notch is bridged by the superior transverse scapular ligament (15).

The conoid (1) and trapezoid (20) ligaments together form the coracoclavicular ligament, which attaches the coracoid process of the scapula to the under-surface of the lateral end of the clavicle.

The coracoacromial ligament (2) passes between the coracoid process and the acromion, forming with these bony processes an arch above the shoulder joint.

A Left scapula *from the lateral side*

1 Acromion
2 Coracoid process
3 Glenoid cavity
4 Inferior angle
5 Infraglenoid tubercle
6 Infraspinous fossa
7 Lateral border
8 Spine
9 Supraglenoid tubercle
10 Supraspinous fossa

B Left scapula and clavicle *articulation, from above*

1 Acromial end of clavicle
2 Acromioclavicular joint
3 Acromion
4 Coracoid process
5 Shaft of clavicle
6 Spine of scapula
7 Sternal end of clavicle
8 Supraspinous fossa

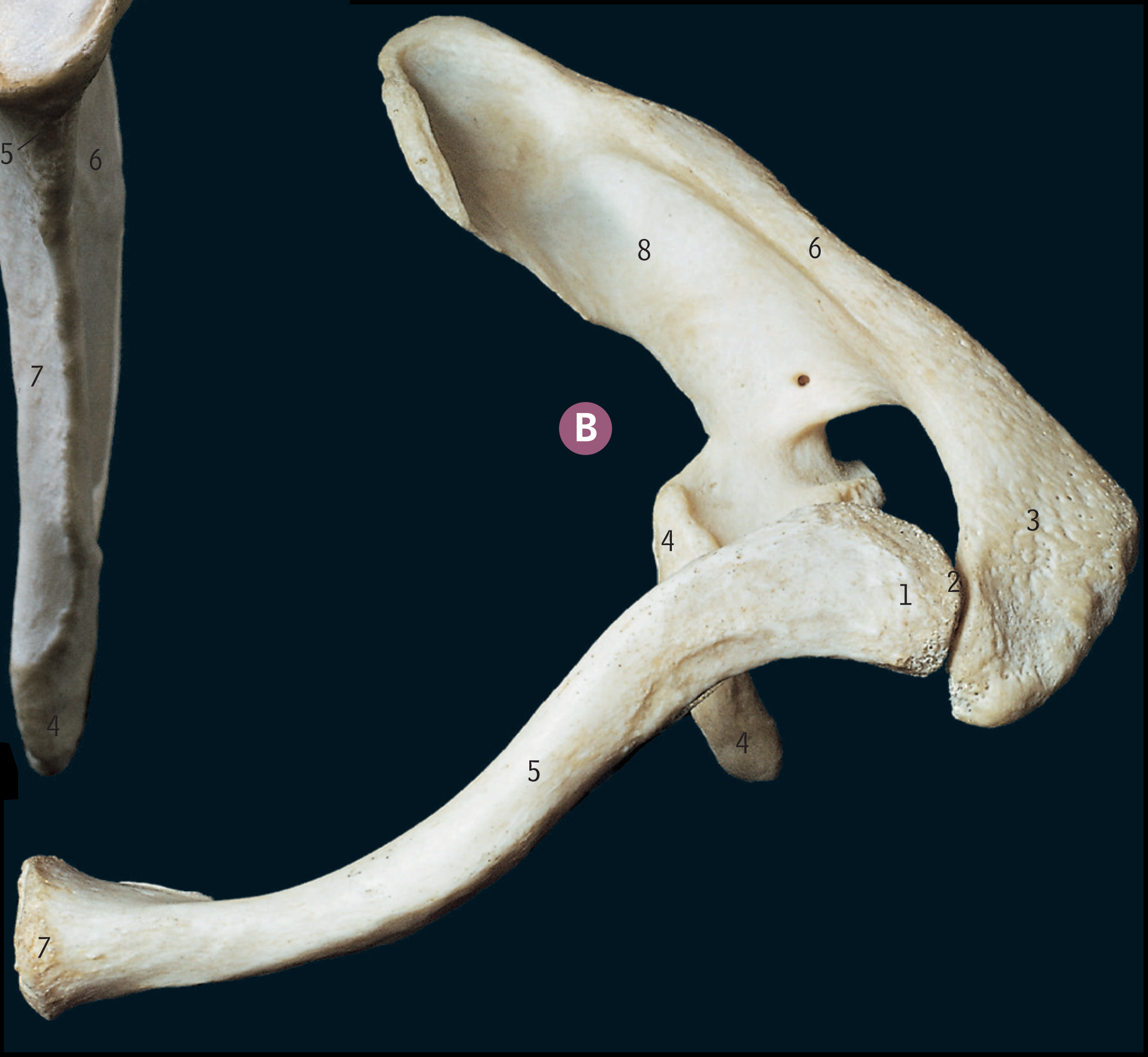

C Left clavicle *from below*

1 Acromial end with articular surface (arrow)
2 Conoid tubercle
3 Groove for subclavius muscle
4 Impression for costoclavicular ligament
5 Sternal end with articular surface (arrow)
6 Trapezoid line

The sternal end of the clavicle (B7, C5) is bulbous; the acromial end (B1, C1) is flattened. The shaft is convex towards the front in its medial two-thirds, and the groove for the subclavius muscle is on the inferior surface (C3).

Acromioclavicular separation, see pages 170–172.

A **Left scapula** *attachments, from the lateral side*

Blue lines, epiphysial lines; green lines, capsular attachments of shoulder joint; pale green lines, ligament attachments

1 Coracoacromial ligament
2 Coracobrachialis and short head of biceps
3 Coracohumeral ligament
4 Deltoid
5 Infraspinatus
6 Long head of biceps
7 Long head of triceps
8 Serratus anterior
9 Subscapularis
10 Teres major
11 Teres minor (with intervening groove for circumflex scapular artery)

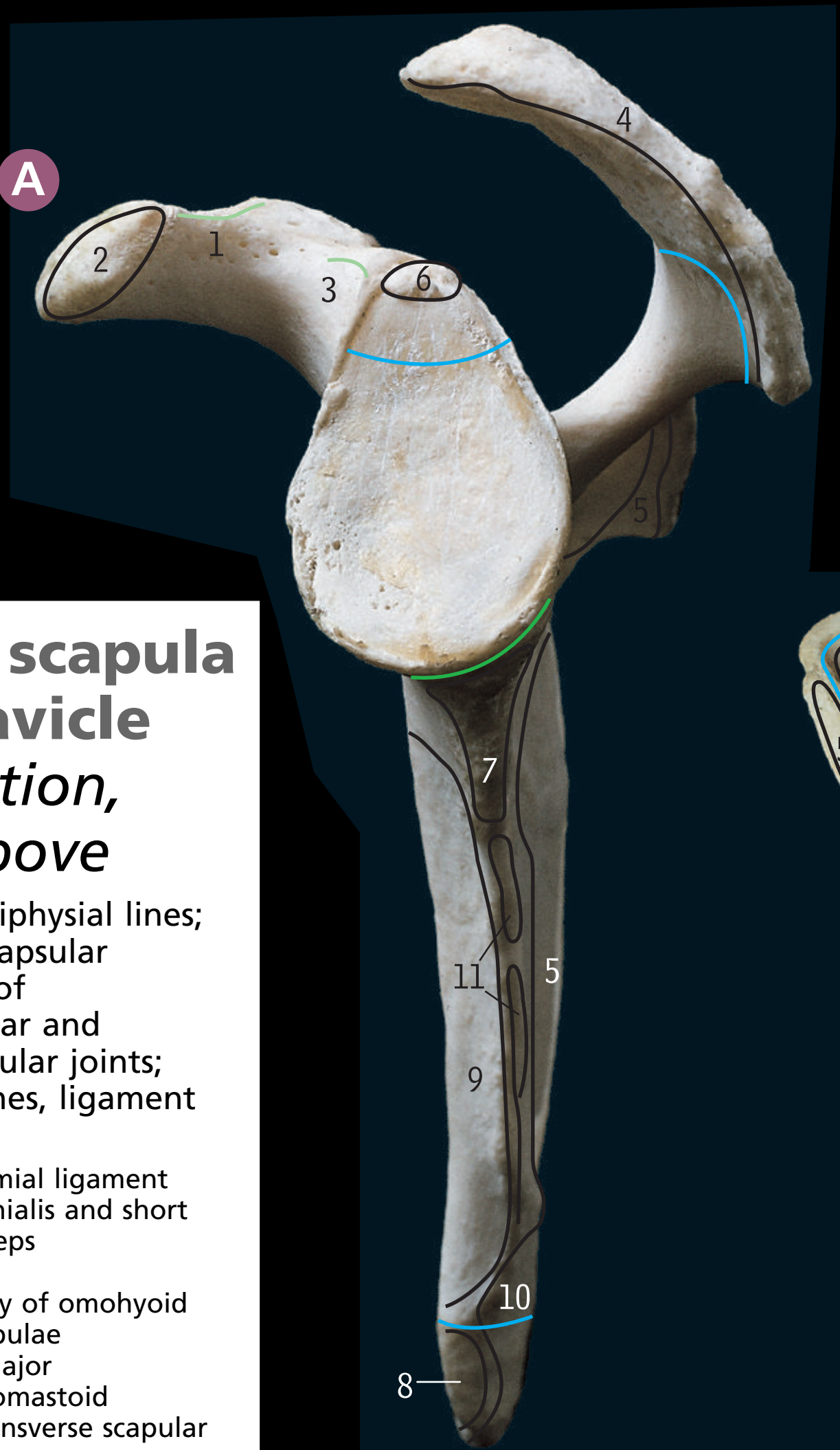

B **Left scapula and clavicle** *articulation, from above*

Blue lines, epiphysial lines; green lines, capsular attachments of sternoclavicular and acromioclavicular joints; pale green lines, ligament attachments

1 Coracoacromial ligament
2 Coracobrachialis and short head of biceps
3 Deltoid
4 Inferior belly of omohyoid
5 Levator scapulae
6 Pectoralis major
7 Sternocleidomastoid
8 Superior transverse scapular ligament
9 Supraspinatus
10 Trapezius

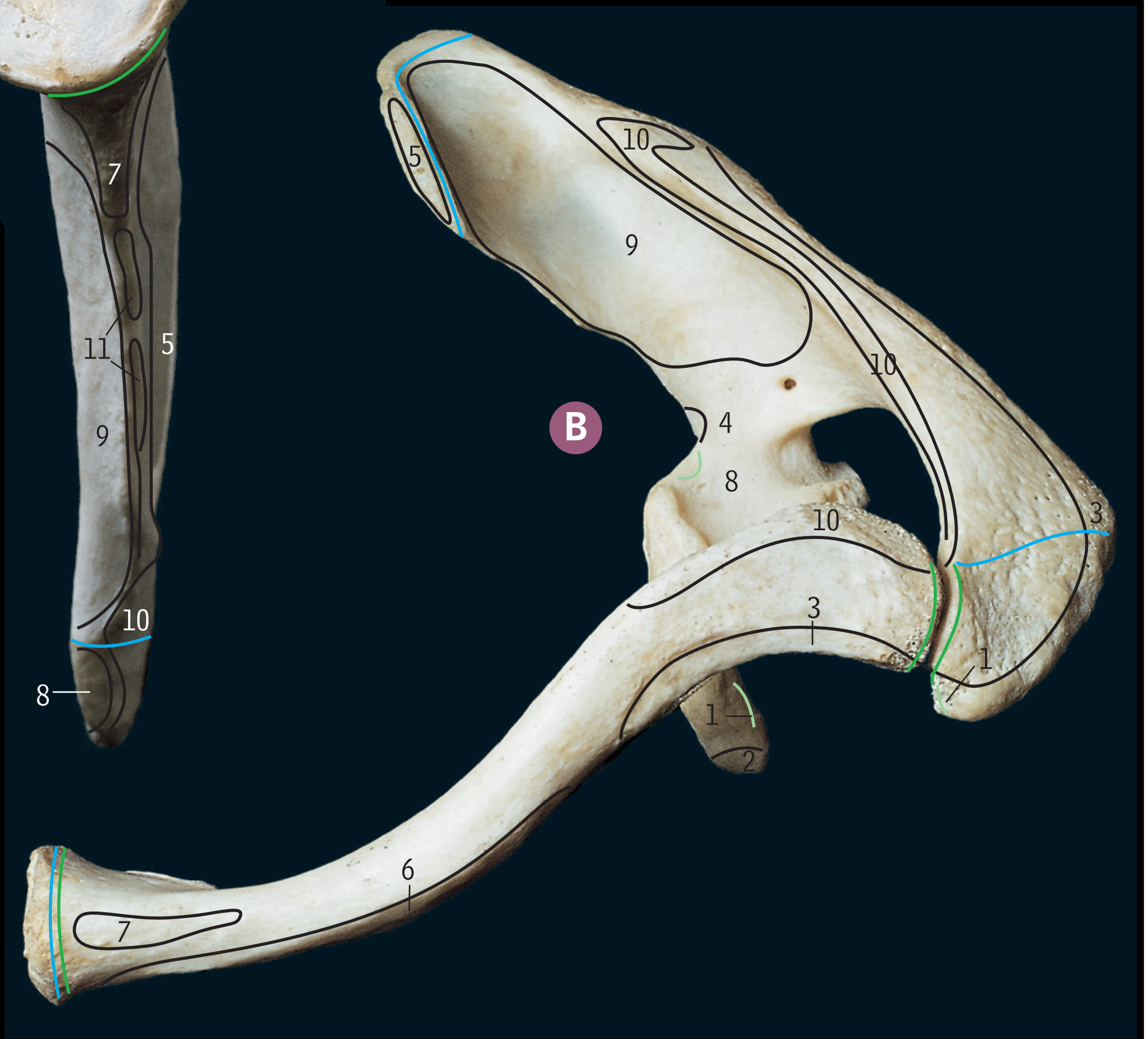

C **Left clavicle** *attachments, from below*

Blue lines, epiphysial lines; green lines, capsular attachments of sternoclavicular and acromioclavicular joints; pale green lines, ligament attachments

1 Conoid ligament
2 Costoclavicular ligament
3 Deltoid
4 Pectoralis major
5 Sternohyoid
6 Subclavius and clavipectoral fascia
7 Trapezius
8 Trapezoid ligament

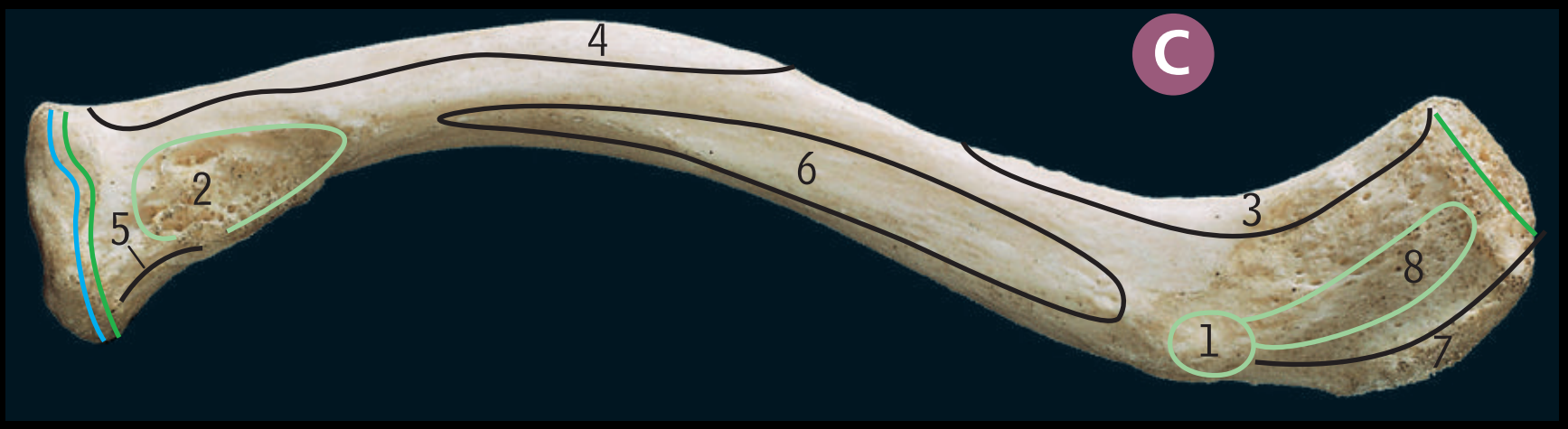

Fractured clavicle, fractured scapula, see pages 170–172.

Right humerus *upper end*

A **from the front**

B **from behind**

C **from the medial side**

D **from the lateral side**

E **from above**

1. Anatomical neck
2. Deltoid tuberosity
3. Greater tubercle
4. Groove for radial nerve
5. Head
6. Intertubercular groove
7. Lateral lip of intertubercular groove
8. Lesser tubercle
9. Medial lip of intertubercular groove
10. Surgical neck

The intertubercular (bicipital) groove (A6) is on the front of the upper end and is occupied by the tendon of the long head of biceps. (For attachments see page 115.)

Dislocation of the humerus, see pages 170–172.

Right humerus *attachments, upper end*

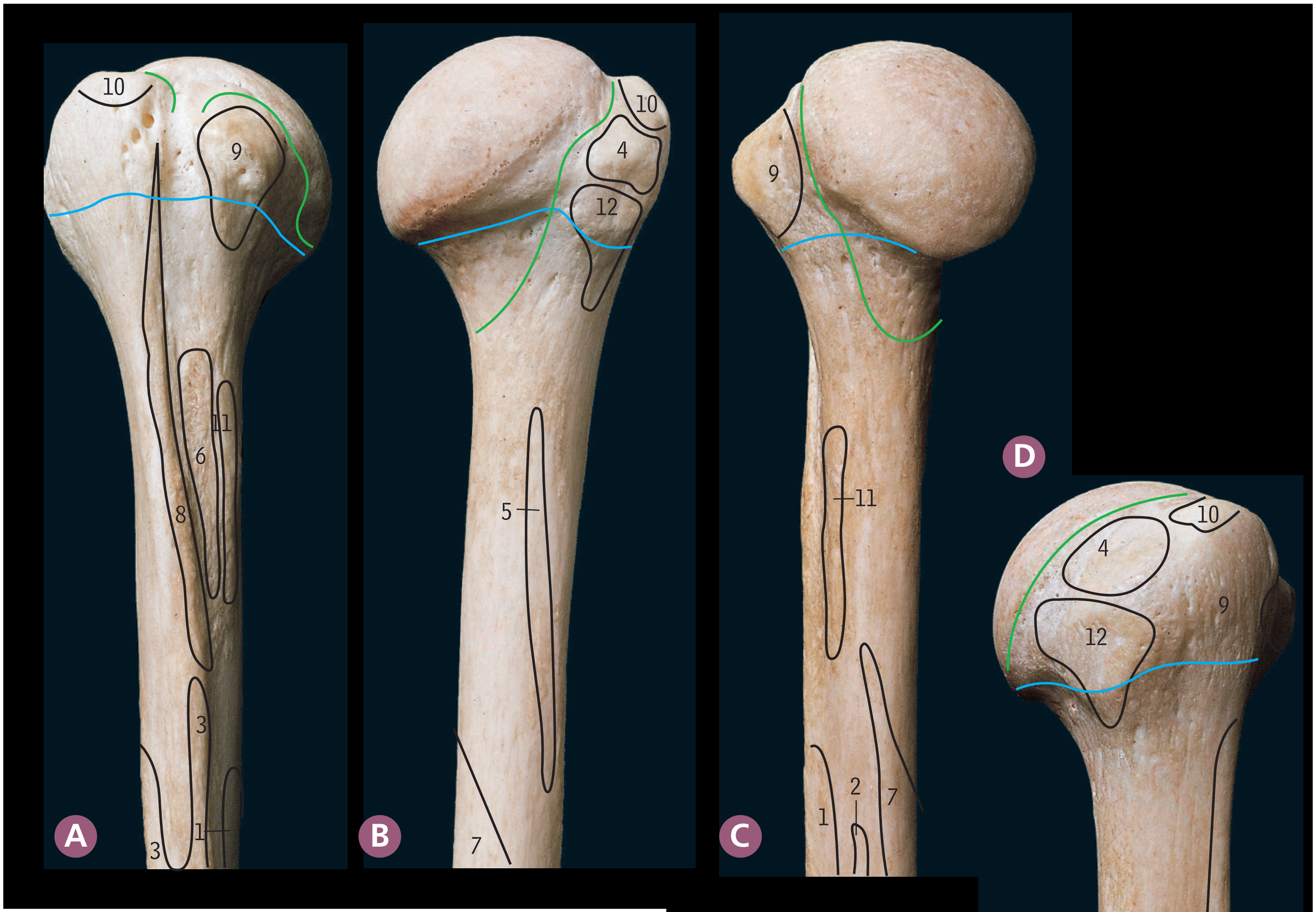

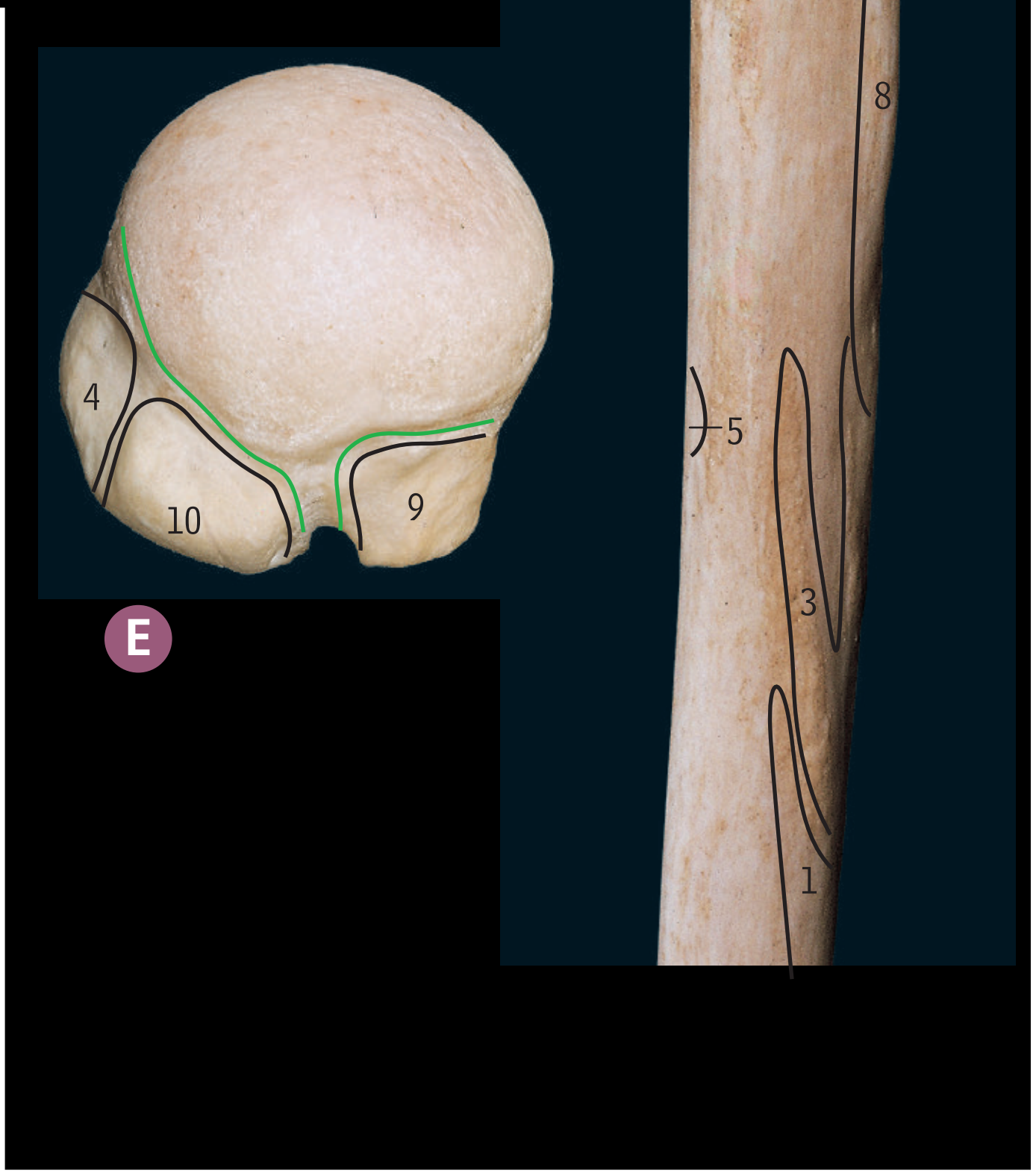

A from the front

B from behind

C from the medial side

D from the lateral side

E from above

Blue lines, epiphysial lines; green lines, capsular attachment of shoulder joint

1 Brachialis
2 Coracobrachialis
3 Deltoid
4 Infraspinatus
5 Lateral head of triceps
6 Latissimus dorsi
7 Medial head of triceps
8 Pectoralis major
9 Subscapularis
10 Supraspinatus
11 Teres major
12 Teres minor

Deltoid is attached to the V-shaped deltoid tuberosity (A3 and D3) on the *lateral* surface of the middle of the shaft.

Coracobrachialis is attached to the *medial* surface of the middle of the shaft (C2) (opposite the deltoid tuberosity).

Note the relative positions of the epiphysial and capsular lines: the epiphysis is partly intracapsular and partly extracapsular at the upper end of the humerus.

Right humerus *lower end*

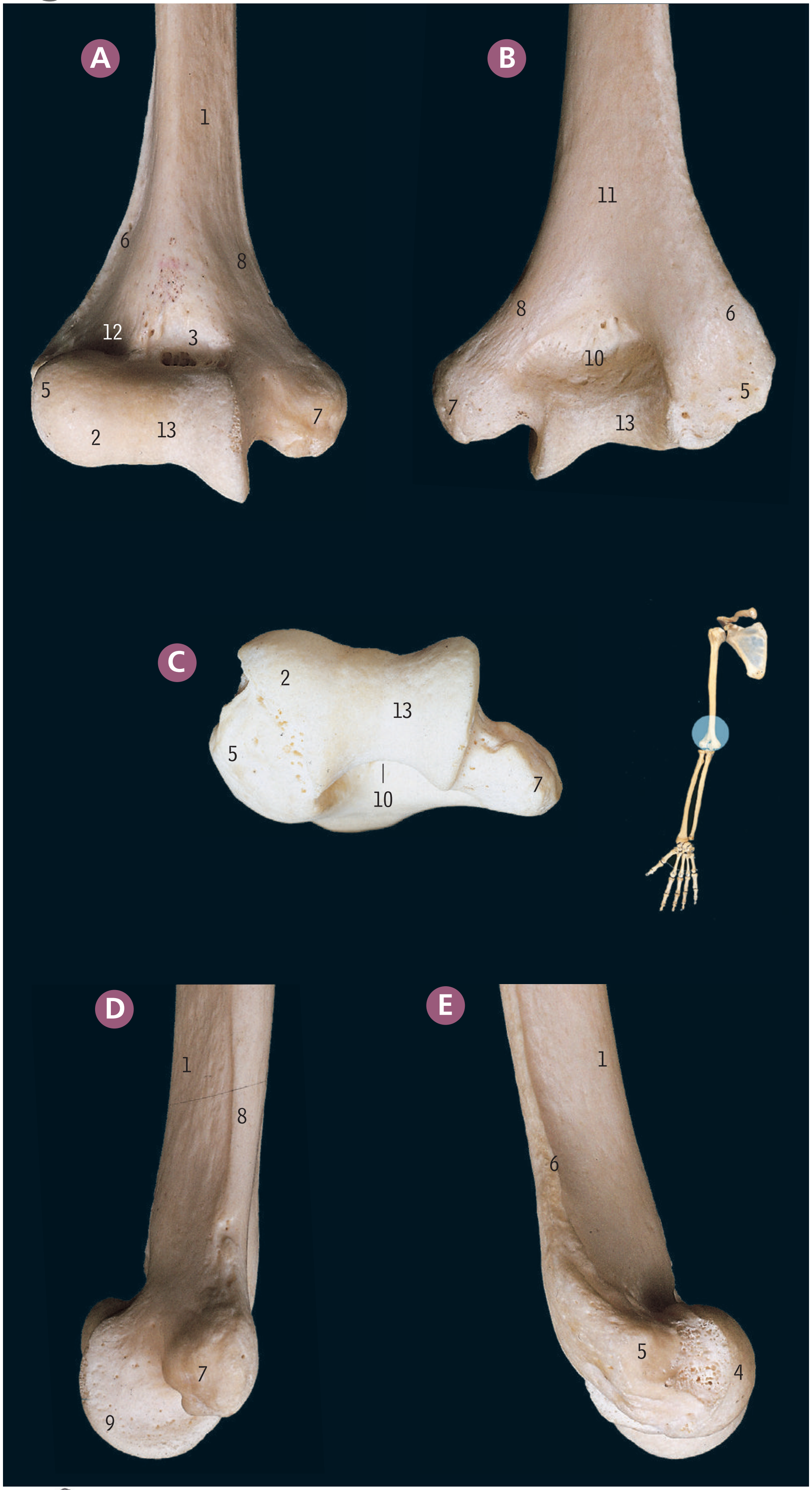

A from the front

B from behind

C from below

D from the medial side

E from the lateral side

1 Anterior surface
2 Capitulum
3 Coronoid fossa
4 Lateral edge of capitulum
5 Lateral epicondyle
6 Lateral supracondylar ridge
7 Medial epicondyle
8 Medial supracondylar ridge
9 Medial surface of trochlea
10 Olecranon fossa
11 Posterior surface
12 Radial fossa
13 Trochlea

The medial epicondyle (7) is more prominent than the lateral (5).

The medial part of the trochlea (13) is more prominent than the lateral part.

The olecranon fossa (10) on the posterior surface is deeper than the radial and coronoid fossae on the anterior surface (12 and 3).

Avulsion medial epicondyle, supracondylar spur, see pages 170–172.

Right humerus *attachments, lower end*

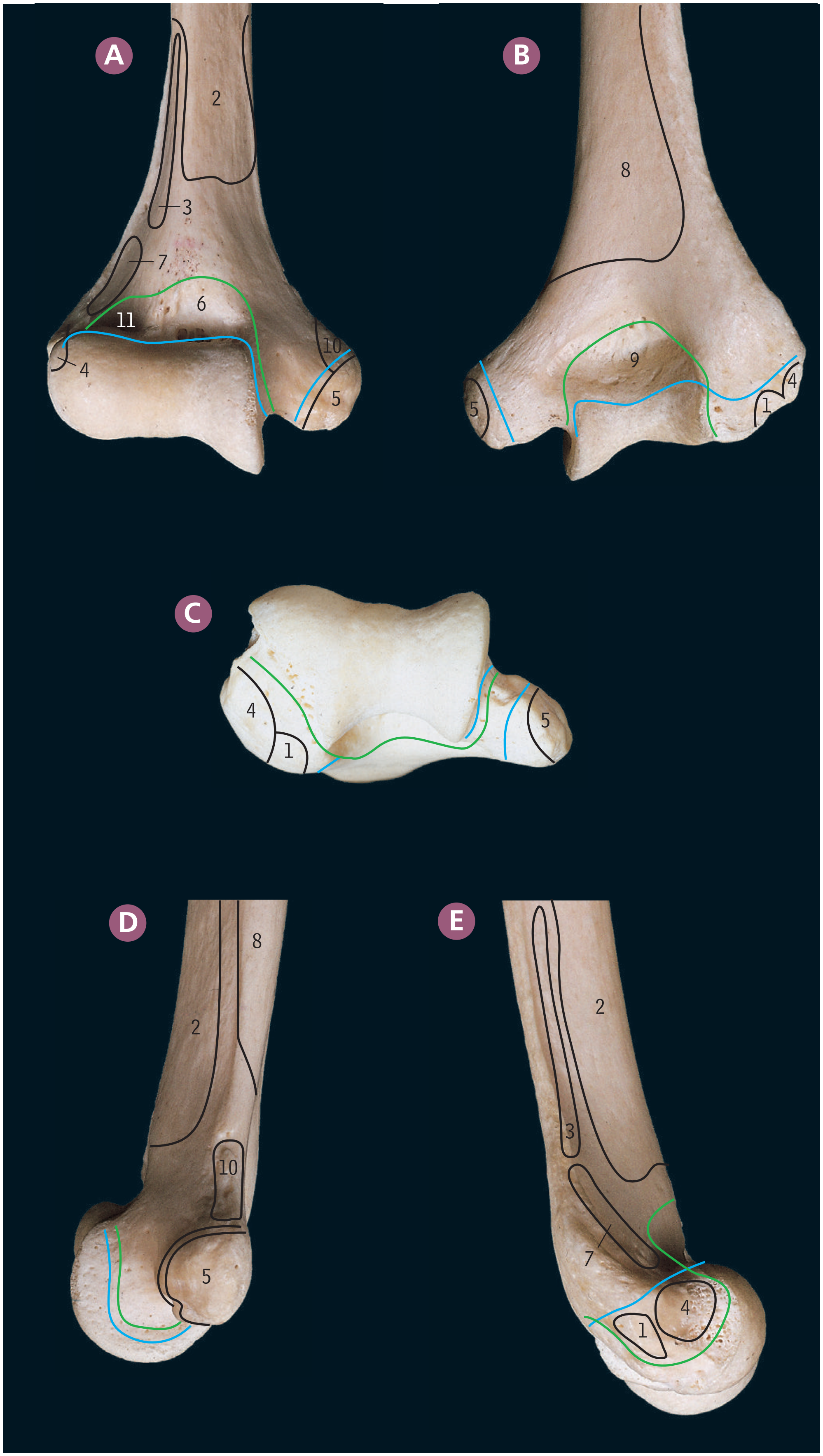

A from the front

B from behind

C from below

D from the medial side

E from the lateral side

Blue lines, epiphysial lines; green lines, capsular attachments of elbow joint

1 Anconeus
2 Brachialis
3 Brachioradialis
4 Common extensor origin
5 Common flexor origin
6 Coronoid fossa
7 Extensor carpi radialis longus
8 Medial head of triceps
9 Olecranon fossa
10 Pronator teres, humeral head
11 Radial fossa

Right radius
upper end

- **A** from the front
- **B** from behind
- **C** from the medial side
- **D** from the lateral side

1 Anterior border
2 Anterior oblique line
3 Anterior surface
4 Head
5 Interosseous border
6 Lateral surface
7 Neck
8 Posterior border
9 Posterior surface
10 Rough area for pronator teres
11 Tuberosity

Right radius
lower end

- **E** from the front
- **F** from behind
- **G** from the medial side
- **H** from the lateral side

1 Anterior surface
2 Dorsal tubercle
3 Groove for abductor pollicis longus
4 Groove for extensor carpi radialis brevis
5 Groove for extensor carpi radialis longus
6 Groove for extensor digitorum and extensor indicis
7 Groove for extensor pollicis brevis
8 Groove for extensor pollicis longus
9 Interosseous border
10 Lateral surface
11 Posterior surface
12 Styloid process
13 Ulnar notch

The lower end of the radius is concave anteriorly (at the lower label 1 in E), with the ulnar notch medially (G13) and the dorsal tubercle on the posterior surface (F2).

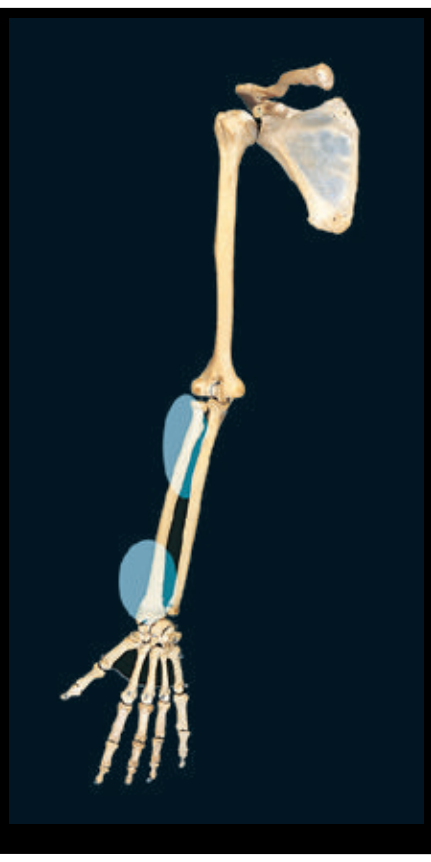

Right ulna *upper end*

A from the front

B from behind

C from the medial side

D from the lateral side

1. Anterior border
2. Anterior surface
3. Coronoid process
4. Interosseous border
5. Medial surface
6. Olecranon
7. Posterior border
8. Posterior surface
9. Radial notch
10. Supinator crest
11. Trochlear notch
12. Tuberosity

The trochlear notch (11) faces forwards, with the radial notch (9) on the lateral side.

Right ulna *lower end*

E from the front

F from behind

G from the medial side

H from the lateral side

1. Anterior surface
2. Groove for extensor carpi ulnaris
3. Head
4. Interosseous border
5. Medial surface
6. Posterior surface
7. Styloid process

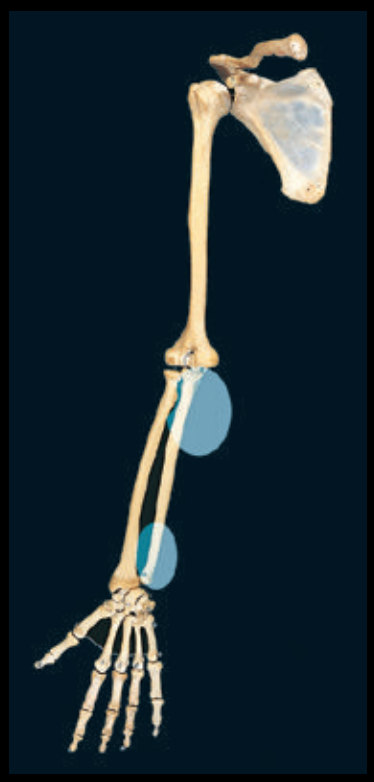

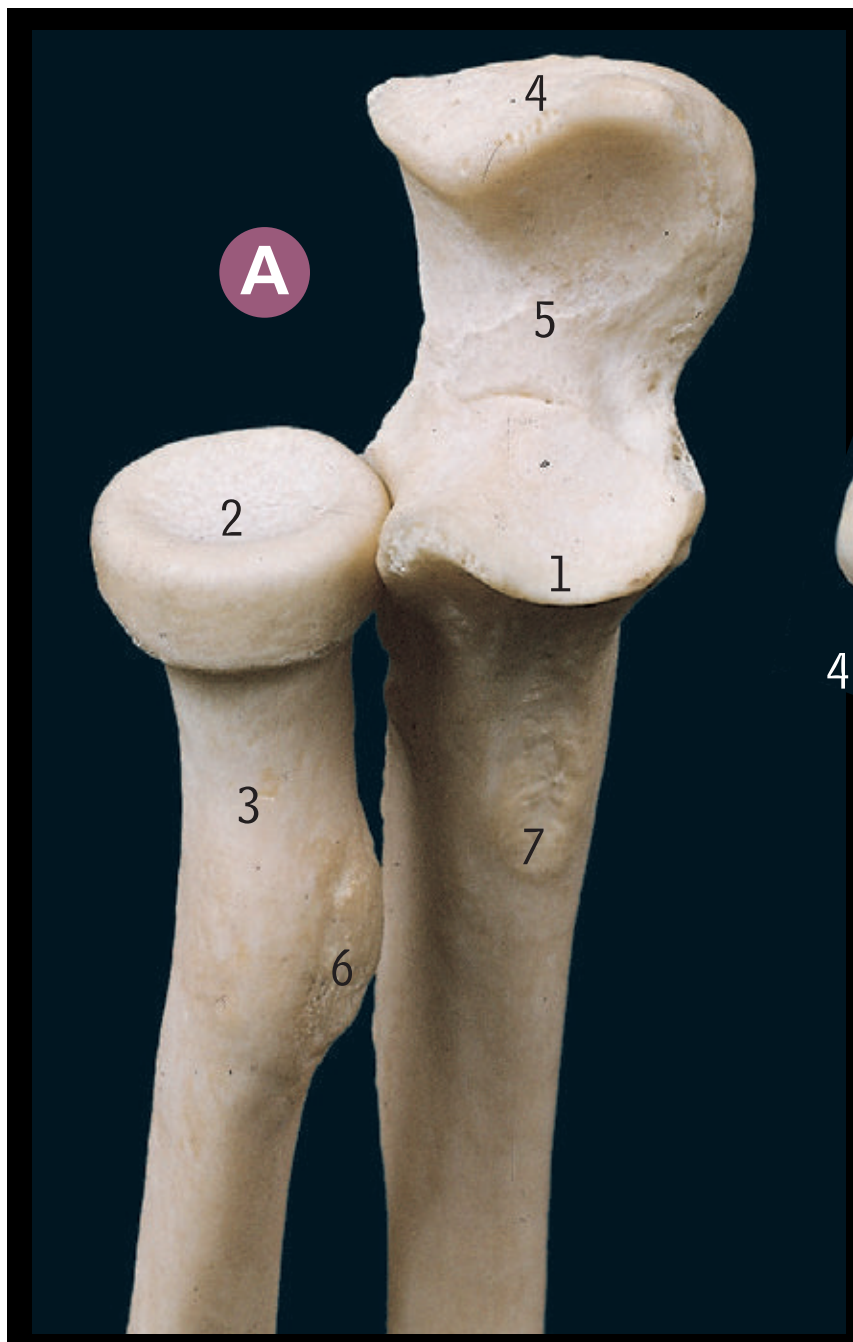

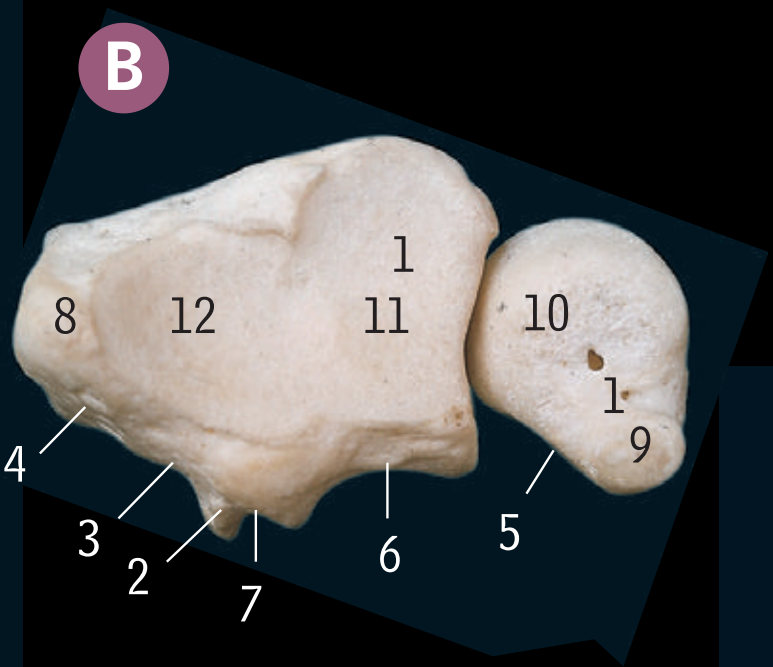

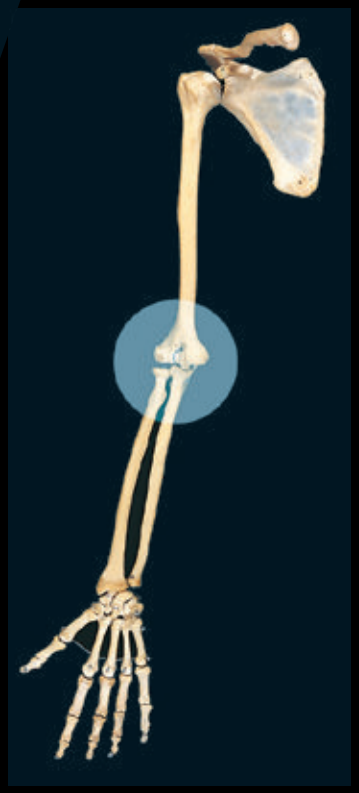

Ⓐ Right radius and ulna *upper ends, from above and in front*

1 Coronoid process of ulna
2 Head of radius
3 Neck of radius
4 Olecranon of ulna
5 Trochlear notch of ulna
6 Tuberosity of radius
7 Tuberosity of ulna

Ⓑ Right radius and ulna *lower ends, from below*

1 Attachment of articular disc
2 Dorsal tubercle
3 Groove for extensor carpi radialis brevis
4 Groove for extensor carpi radialis longus
5 Groove for extensor carpi ulnaris
6 Groove for extensor digitorum and extensor indicis
7 Groove for extensor pollicis longus
8 Styloid process of radius
9 Styloid process of ulna
10 Surface for disc
11 Surface for lunate
12 Surface for scaphoid

Right humerus, radius and ulna *articulation*

Ⓒ from the front

Ⓓ from behind

1 Capitulum of humerus
2 Coronoid process of ulna
3 Head of radius
4 Lateral epicondyle of humerus
5 Medial epicondyle of humerus
6 Olecranon of ulna
7 Radial notch of ulna
8 Trochlea of humerus

The elbow joint and the proximal radio-ulnar joint share a common synovial cavity.

Dislocation of the elbow, supracondylar fracture of the humerus, see pages 170–172.

Right radius and ulna *attachments*

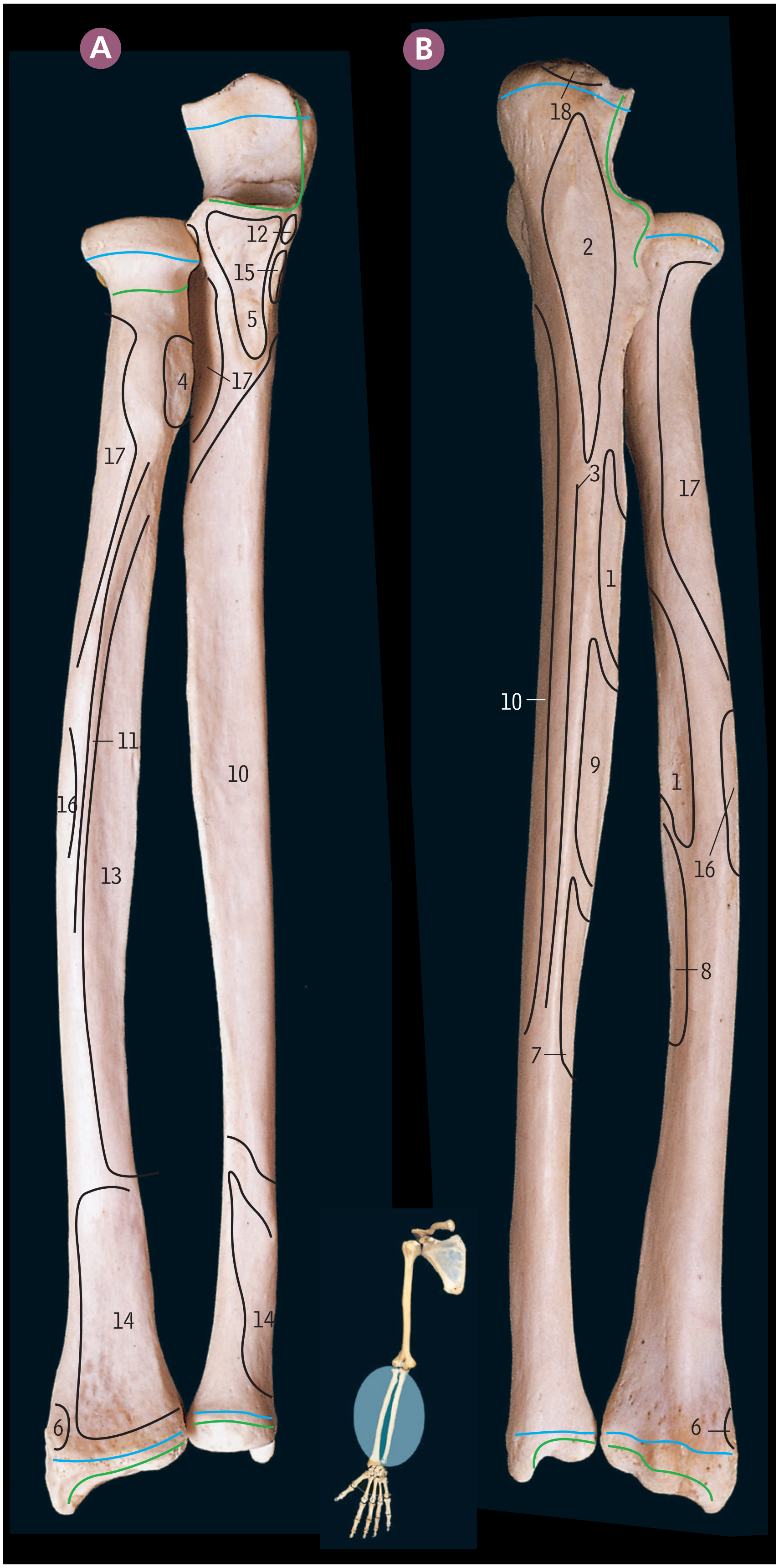

A **from the front**

B **from behind**

Blue lines, epiphysial lines; green lines, capsular attachments of elbow and wrist joints

1 Abductor pollicis longus
2 Anconeus
3 Aponeurotic attachment of flexor digitorum profundus, flexor carpi ulnaris and extensor carpi ulnaris
4 Biceps
5 Brachialis
6 Brachioradialis
7 Extensor indicis
8 Extensor pollicis brevis
9 Extensor pollicis longus
10 Flexor digitorum profundus
11 Flexor digitorum superficialis, radial head
12 Flexor digitorum superficialis, ulnar head
13 Flexor pollicis longus
14 Pronator quadratus
15 Pronator teres, ulnar head
16 Pronator teres
17 Supinator
18 Triceps

Abductor pollicis longus (1) and extensor pollicis brevis (8) are the only two muscles to have an origin from the posterior surface of the radius (although both extend on to the interosseous membrane and the abductor also has an origin from the posterior surface of the ulna). These muscles remain companions as they wind round the lateral side of the radius (page 152) and form the radial boundary of the anatomical snuffbox (pages 153 and 166).

In the young subject, the radius sometimes fractures across the lower epiphysis following an injury to the wrist. In the adult the term “Colles’ fracture” (page 123) refers to a transverse break across the lower radius within about 2.5 cm of the lower end of the bone. The ulnar styloid process is also often fractured.

Traction of forearm fractures, see pages 170–172.

Bones of the right hand

A palmar surface

B from the lateral side

C hamate from the medial side

D scaphoid, palmar surface

The scaphoid, lunate, triquetral and pisiform bones form the proximal row of carpal bones.

The trapezium, trapezoid, capitate and hamate bones form the distal row of carpal bones.

The tubercle (33) and waist (35) are the non-articular parts of the scaphoid and therefore contain nutrient foramina. A fracture across the waist may therefore interfere with the blood supply of the proximal pole of the bone and lead to avascular necrosis (see page 167). The waist of the scaphoid lies in the anatomical snuffbox; the tubercle may be palpated in front of the radial boundary of the snuffbox.

1 Base of fifth metacarpal
2 Base of first metacarpal
3 Base of middle phalanx of middle finger
4 Base of proximal phalanx of ring finger
5 Capitate
6 Distal phalanx of ring finger
7 Distal phalanx of thumb
8 Groove for deep branch of ulnar nerve
9 Hamate
10 Head of fifth metacarpal
11 Head of first metacarpal
12 Head of middle phalanx of middle finger
13 Head of proximal phalanx of ring finger
14 Hook of hamate
15 Lunate
16 Palmar surface, hamate
17 Pisiform
18 Proximal phalanx of index finger
19 Proximal phalanx of little finger
20 Proximal phalanx of thumb
21 Scaphoid
22 Shaft of second metacarpal
23 Shaft of fifth metacarpal
24 Shaft of first metacarpal
25 Shaft of middle phalanx of middle finger
26 Shaft of proximal phalanx of ring finger
27 Surface for capitate
28 Surface for lunate
29 Surface for triquetral
30 Trapezium
31 Trapezoid
32 Triquetral
33 Tubercle of scaphoid
34 Tubercle of trapezium
35 Waist of scaphoid

Bones of the right hand *dorsal surface*

1 Base of first metacarpal
2 Capitate
3 Distal phalanx of middle finger
4 Distal phalanx of thumb
5 Fifth metacarpal
6 Hamate
7 Head of first metacarpal
8 Lunate
9 Middle phalanx of middle finger
10 Proximal phalanx of middle finger
11 Proximal phalanx of thumb
12 Scaphoid
13 Shaft of first metacarpal
14 Styloid process of radius
15 Styloid process of ulna
16 Third metacarpal
17 Trapezium
18 Trapezoid
19 Triquetral

The wrist joint (properly called the radiocarpal joint) is the joint between (proximally) the lower end of the radius and the interarticular disc which holds the lower ends of the radius and the ulna together, and (distally) the scaphoid, lunate and triquetral bones.

The midcarpal joint is the joint between the proximal and distal rows of carpal bones (see pages 163 and 168).

The carpometacarpal joint of the thumb is the joint between the trapezium and the base of the first metacarpal.

Bar room fracture, Colles' fracture, dislocation of the finger, Smith's fracture, see *pages 170–172.*

Bones of the right hand *attachments*

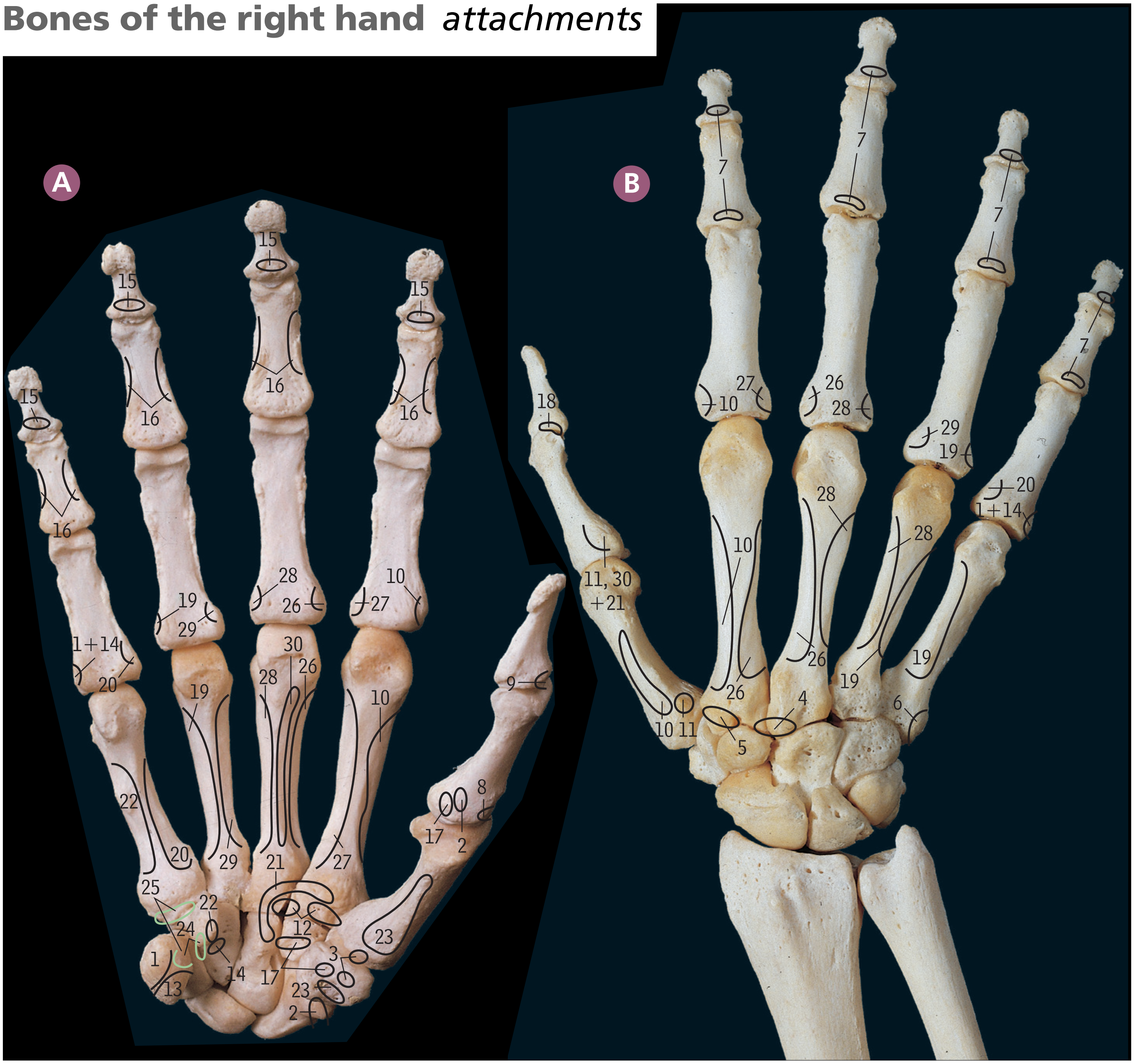

A **palmar surface**

B **dorsal surface**

Pale green lines, ligament attachments

1 Abductor digiti minimi
2 Abductor pollicis brevis
3 Abductor pollicis longus
4 Extensor carpi radialis brevis
5 Extensor carpi radialis longus
6 Extensor carpi ulnaris
7 Extensor expansion
8 Extensor pollicis brevis
9 Extensor pollicis longus
10 First dorsal interosseous
11 First palmar interosseous
12 Flexor carpi radialis
13 Flexor carpi ulnaris
14 Flexor digiti minimi brevis
15 Flexor digitorum profundus
16 Flexor digitorum superficialis
17 Flexor pollicis brevis
18 Flexor pollicis longus
19 Fourth dorsal interosseous
20 Fourth palmar interosseous
21 Oblique head of adductor pollicis
22 Opponens digiti minimi
23 Opponens pollicis
24 Pisohamate ligament
25 Pisometacarpal ligament
26 Second dorsal interosseous
27 Second palmar interosseous
28 Third dorsal interosseous
29 Third palmar interosseous
30 Transverse head of adductor pollicis

The metacarpophalangeal joints are the joints between the heads of the metacarpals and the bases of the proximal phalanges.

The interphalangeal joints are the joints between the head of one phalanx and the base of the adjoining phalanx.

The pisiform is a sesamoid bone in the tendon of flexor carpi ulnaris and is anchored by the pisohamate and pisometacarpal ligaments (24 and 25).

Dorsal interossei arise from the sides of two adjacent metacarpal bones (as at 26, from the sides of the second and third metacarpals); palmar interossei arise only from the metacarpal of their own finger (as at 27, from the second metacarpal). Compare with dissection B on page 166 and note that when looking at the palm, parts of the dorsal interossei can be seen as well as the palmar interossei, but when looking at the dorsum of the hand (as on page 166) only dorsal interossei are seen.

Digital development abnormality, fractured hamate, see pages 170–172.

Right upper limb bones *secondary centres of ossification*

A **scapula, upper lateral part**

B **clavicle, sternal end**

C D **humerus, upper and lower ends**

E F **radius, upper and lower ends**

G H **ulna, upper and lower ends**

I **first metacarpal and phalanges of thumb**

J **second metacarpal and phalanges of index finger**

Figures in years after birth, commencement of ossification → fusion. (P, puberty)

The first figure indicates the approximate date when ossification begins in the secondary centre, and the second figure (beyond the arrowhead) when the centre finally becomes fused with the rest of the bone. Single average dates have been given (both here and for the lower limb bone centres on pages 314 and 315) and although there may be considerable individual variations, the 'growing end' of the bone (when fusion occurs last) is constant. The dates in females are often a year or more earlier than in males.

Apart from the acromial, coracoid and subcoracoid centres illustrated (A), the scapula usually has other centres for the inferior angle, medial border, and the lower part of the rim of the glenoid cavity (all P → 20; see pages 137 and 169).

The clavicle is the first bone in the body to start to ossify (fifth week of gestation). It ossifies in membrane, but the ends of the bone have a cartilaginous phase of ossification; a secondary centre appearing at the sternal end (B) unites with the body at about the 25th year.

The centre illustrated at the upper end of the humerus (C) is the result of the union at 6 years of centres for the head (1 year), greater tubercle (3 years) and lesser tubercle (5 years).

At the lower end of the humerus (D) the centres for the capitulum, trochlea and lateral epicondyle fuse together before uniting with the shaft.

All the phalanges (as in J), and the first metacarpal (I) have a secondary centre at their proximal ends; the other metacarpals (as in J) have one at their distal ends.

All the carpal bones are cartilaginous at birth and none has a secondary centre. The largest, the capitate, is the first to begin to ossify (in the second month after birth), followed in a month or so by the hamate, with the triquetral at 3 years, lunate at 4 years, scaphoid, trapezoid and trapezium at 5 years and the pisiform last at 9 years or later. There are often variations in the above common pattern.

Right shoulder

surface markings, from the front

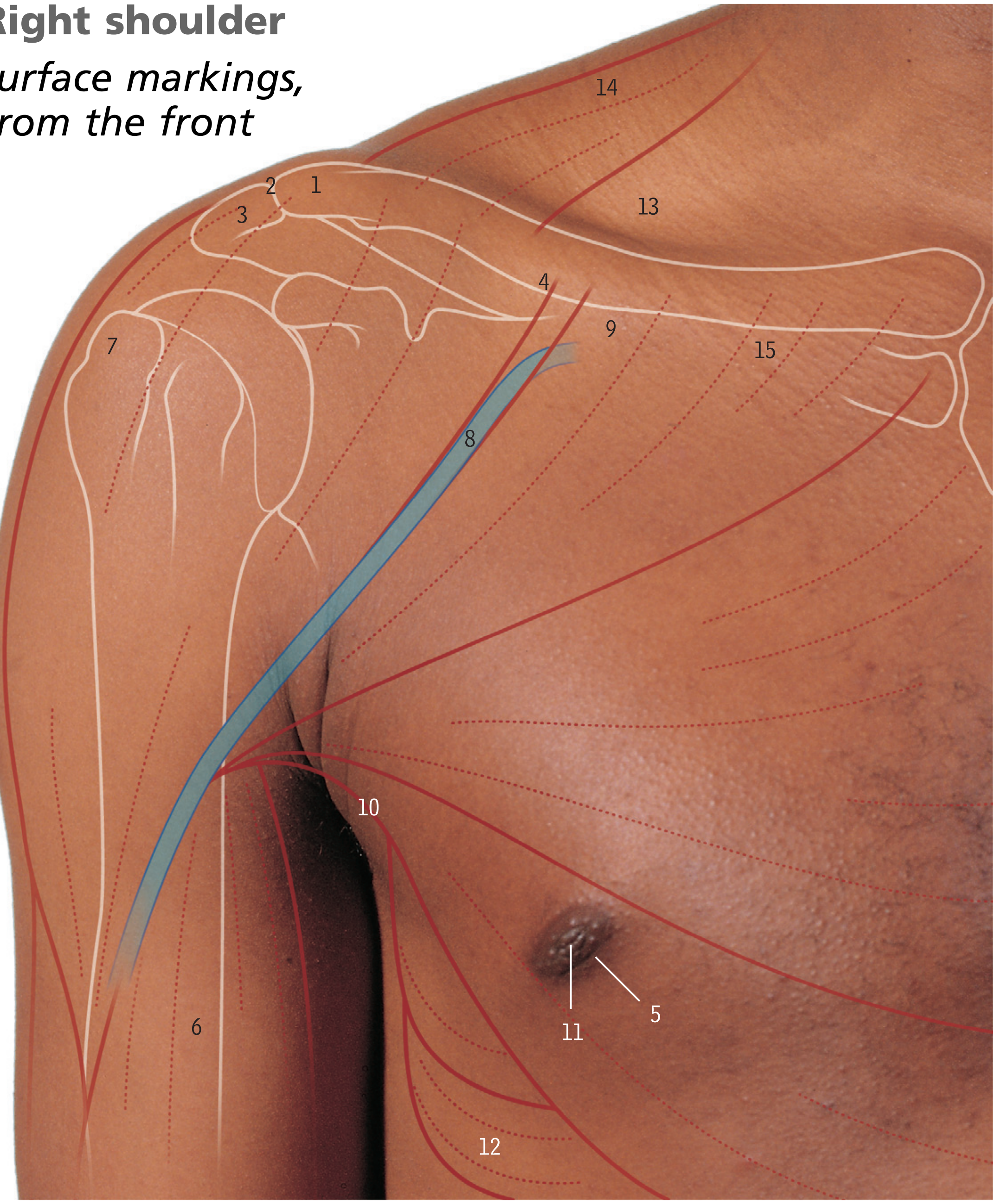

1 Acromial end of clavicle
2 Acromioclavicular joint
3 Acromion
4 Anterior margin of deltoid
5 Areola
6 Biceps
7 Deltoid overlying greater tubercle of humerus
8 Deltopectoral groove and cephalic vein
9 Infraclavicular fossa
10 Lower margin of pectoralis major
11 Nipple
12 Serratus anterior
13 Supraclavicular fossa
14 Trapezius
15 Upper margin of pectoralis major

The nipple in the male (11) normally lies at the level of the fourth intercostal space.

The lower border of pectoralis major (10) forms the anterior axillary fold.

Note that the most lateral bony point in the shoulder is the greater tubercle (7).

The clavicle is subcutaneous throughout its length. Its acromial end (1) at the acromioclavicular joint (2) lies at a slightly higher level than the acromion of the scapula (3). At the most lateral part of the shoulder, the deltoid overlies the humerus; the acromion of the scapula does not extend so far laterally. Compare the positions of the features noted here with the dissection on the next page.

Dislocation of humerus, sternoclavicular dislocation, see pages 170–172.

Right shoulder *superficial dissection*

Removal of skin and fascia displays the anterior musculature of the shoulder and thoracic wall.

1 Anterior layer of rectus sheath
2 Anterior perforating branches of intercostal neurovascular bundle
3 Biceps brachii muscle (long head)
4 Brachioradialis muscle
5 Cephalic vein
6 Cephalic vein in deltopectoral groove
7 Clavicle
8 Deltoid muscle
9 Latissimus dorsi muscle
10 Pectoralis major muscle, abdominal head
11 Pectoralis major muscle, clavicular head
12 Pectoralis major muscle, sternal head
13 Serratus anterior muscle
14 Triceps brachii muscle (lateral head)

Right shoulder
superficial dissection, from the front

Removal of skin and fascia displays branches of the supraclavicular nerve (6) crossing the clavicle (9), and the cephalic vein (7) lying in the deltopectoral groove between deltoid (13) and pectoralis major (11).

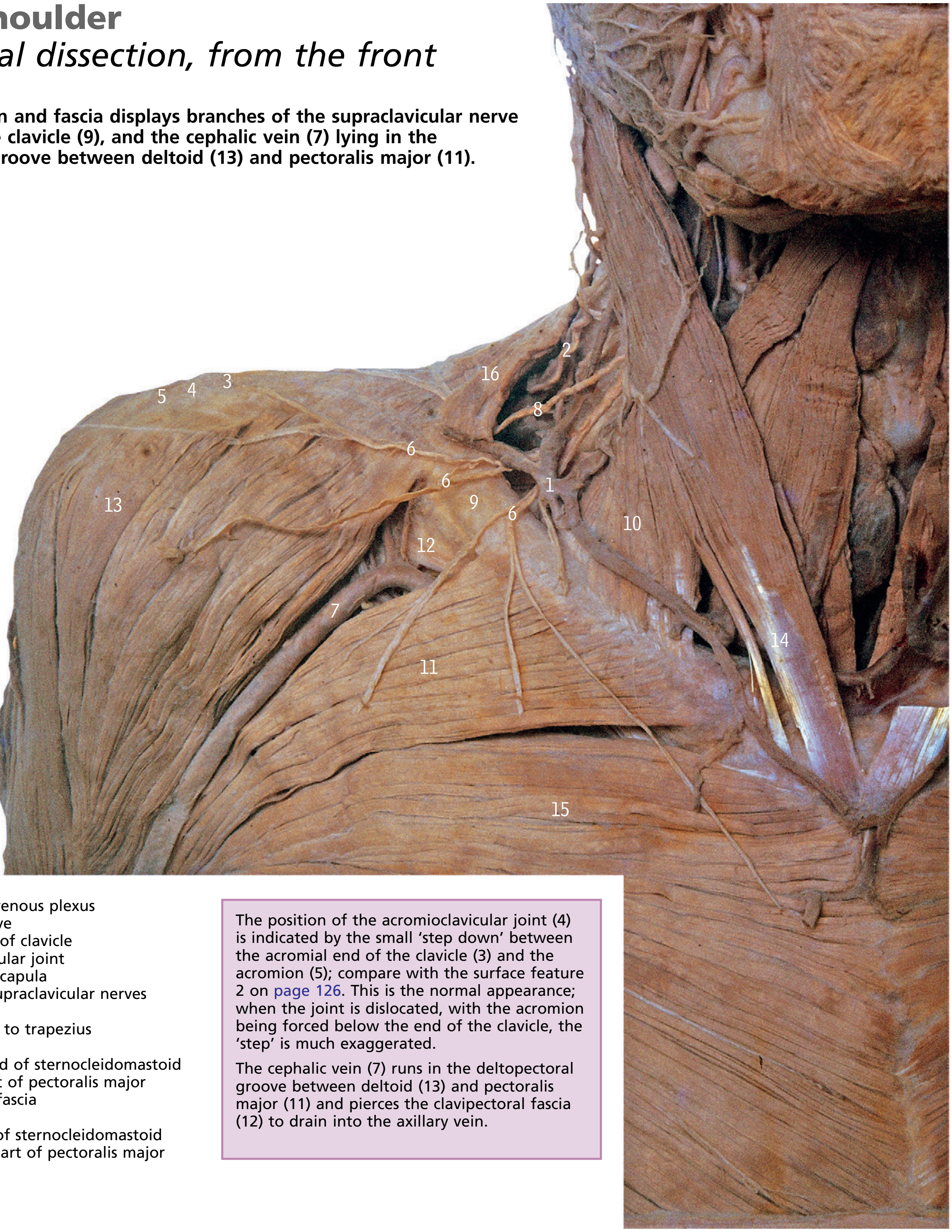

1 A superficial venous plexus
2 Accessory nerve
3 Acromial end of clavicle
4 Acromioclavicular joint
5 Acromion of scapula
6 Branches of supraclavicular nerves
7 Cephalic vein
8 Cervical nerve to trapezius
9 Clavicle
10 Clavicular head of sternocleidomastoid
11 Clavicular part of pectoralis major
12 Clavipectoral fascia
13 Deltoid
14 Sternal head of sternocleidomastoid
15 Sternocostal part of pectoralis major
16 Trapezius

The position of the acromioclavicular joint (4) is indicated by the small 'step down' between the acromial end of the clavicle (3) and the acromion (5); compare with the surface feature 2 on page 126. This is the normal appearance; when the joint is dislocated, with the acromion being forced below the end of the clavicle, the 'step' is much exaggerated.

The cephalic vein (7) runs in the deltopectoral groove between deltoid (13) and pectoralis major (11) and pierces the clavipectoral fascia (12) to drain into the axillary vein.

Right shoulder *deeper dissection, from the front*

1 Anterior circumflex humeral artery and musculocutaneous nerve
2 Axillary lymph nodes (enlarged)
3 Axillary vein
4 Branches of medial pectoral nerve
5 Branches of lateral pectoral nerve
6 Cephalic vein
7 Clavicle
8 Coracobrachialis
9 Coracoid process and acromial branch of thoracoacromial artery
10 Deltoid
11 First rib
12 Inferior belly of omohyoid (displaced upwards)
13 Intercostobrachial nerve
14 Internal jugular vein
15 Lateral thoracic artery
16 Long thoracic nerve (to serratus anterior)
17 Median nerve
18 Nerve to sternothyroid
19 Pectoral branch of thoracoacromial artery
20 Pectoralis major
21 Pectoralis minor
22 Phrenic nerve overlying scalenus anterior
23 Scalenus medius
24 Short head of biceps
25 Sternohyoid
26 Sternothyroid
27 Subclavian vein
28 Subclavius
29 Subscapularis
30 Suprascapular nerve
31 Tendon of long head of biceps
32 Trapezius
33 Trunks of brachial plexus

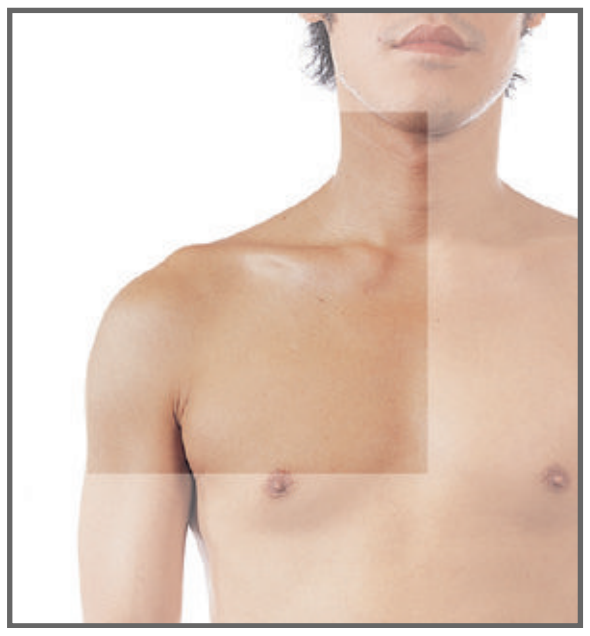

Most of deltoid (10) and pectoralis major (20) have been removed to show the underlying pectoralis minor (21) and its associated vessels and nerves. The clavipectoral fascia which passes between the clavicle (7) and the upper (medial) border of the pectoralis minor (21) has also been removed to show the axillary vein (3) receiving the cephalic vein (6) and continuing as the subclavian vein (27) as it crosses the first rib (11).

Shoulder arthroscopy

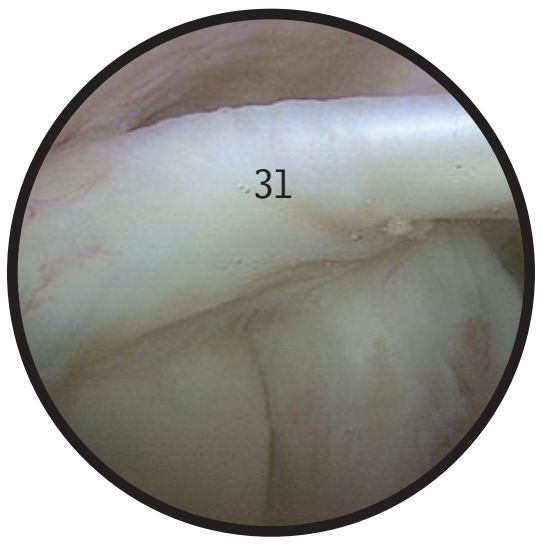

This shows the arthroscopic view of the right shoulder seen from behind. The supraspinatus tendon and the long head of biceps is in pristine condition. The anterior edge of the glenoid labrum shows some wear.

Klumpke's paralysis, see pages 170–172.

Right shoulder
surface markings, from behind

The arm is slightly abducted, and the inferior angle of the scapula (5) has been made to project backwards by attempting to flex the shoulder joint against resistance. Compare the features noted with the dissection opposite.

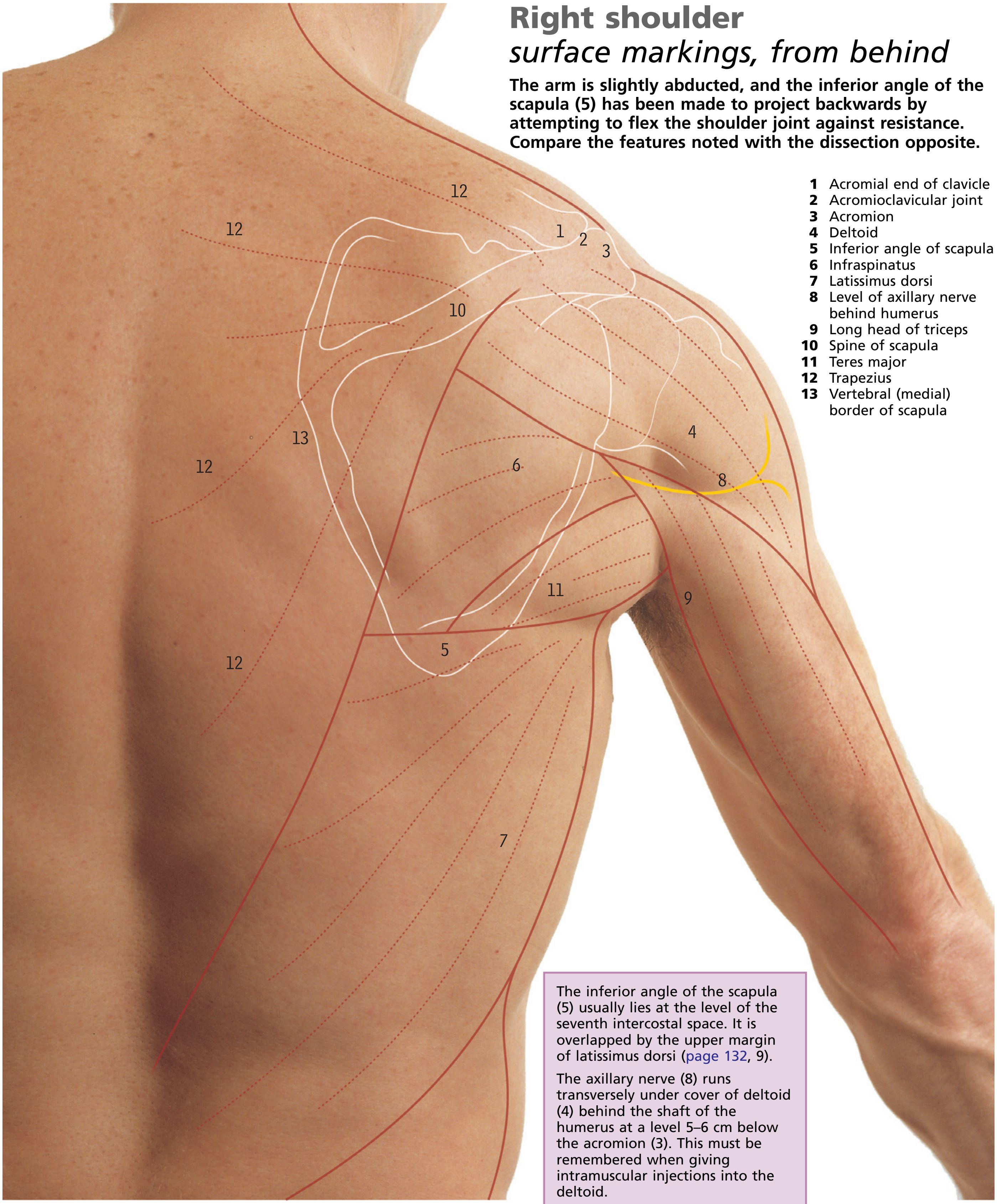

1 Acromial end of clavicle
2 Acromioclavicular joint
3 Acromion
4 Deltoid
5 Inferior angle of scapula
6 Infraspinatus
7 Latissimus dorsi
8 Level of axillary nerve behind humerus
9 Long head of triceps
10 Spine of scapula
11 Teres major
12 Trapezius
13 Vertebral (medial) border of scapula

The inferior angle of the scapula (5) usually lies at the level of the seventh intercostal space. It is overlapped by the upper margin of latissimus dorsi (page 132, 9).

The axillary nerve (8) runs transversely under cover of deltoid (4) behind the shaft of the humerus at a level 5–6 cm below the acromion (3). This must be remembered when giving intramuscular injections into the deltoid.

Latissimus dorsi (7; page 132, 7) and teres major (11; page 132, 16) form the lower boundary of the posterior wall of the axilla.

Right shoulder *superficial dissection, from behind*

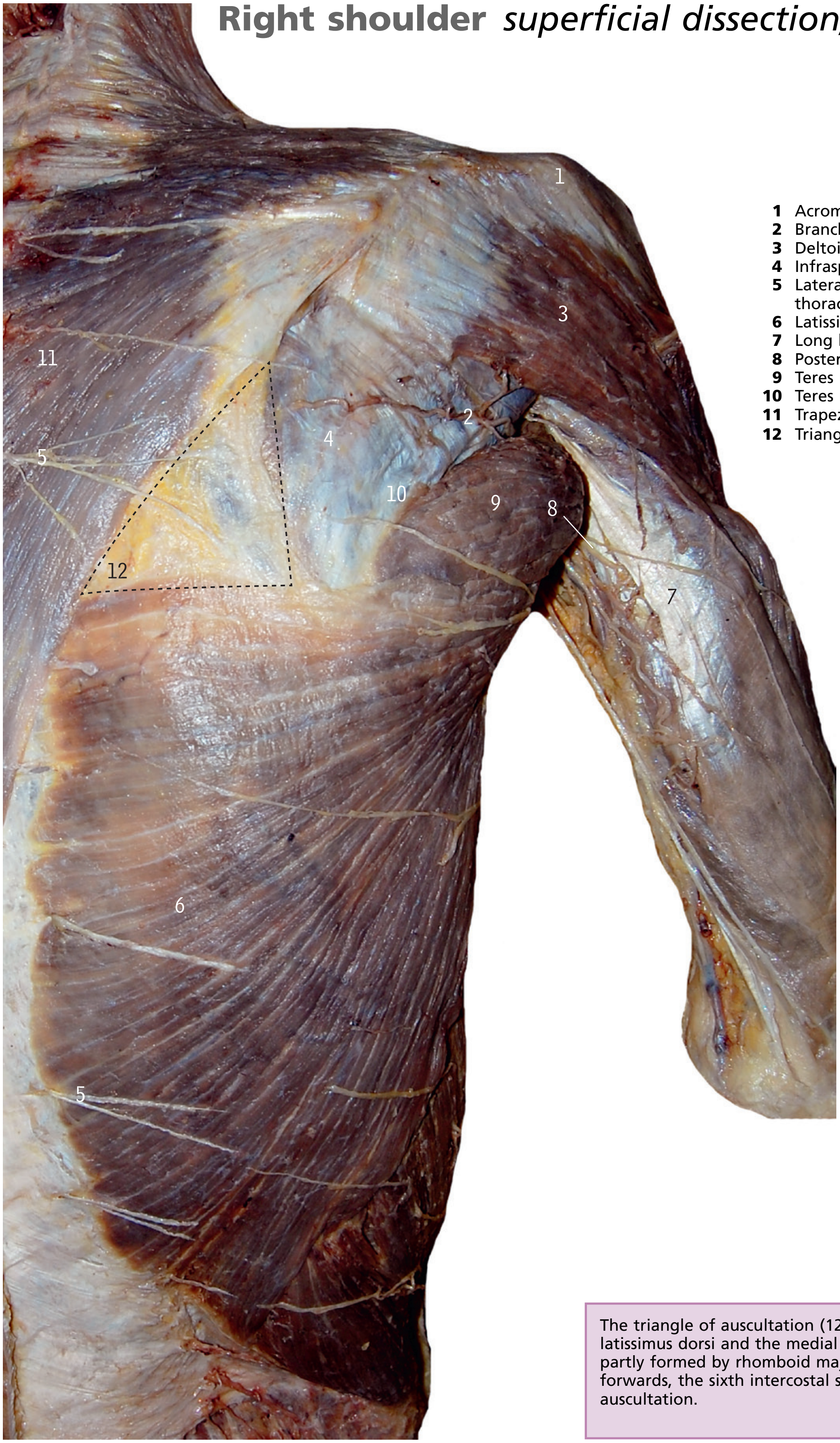

1 Acromion
2 Branches of circumflex scapular artery
3 Deltoid muscle
4 Infraspinatus fascia
5 Lateral cutaneous branches of dorsal rami of thoracic nerves
6 Latissimus dorsi muscle
7 Long head of triceps brachii muscle
8 Posterior cutaneous nerve to the arm
9 Teres major muscle
10 Teres minor muscle
11 Trapezius muscle
12 Triangle of auscultation

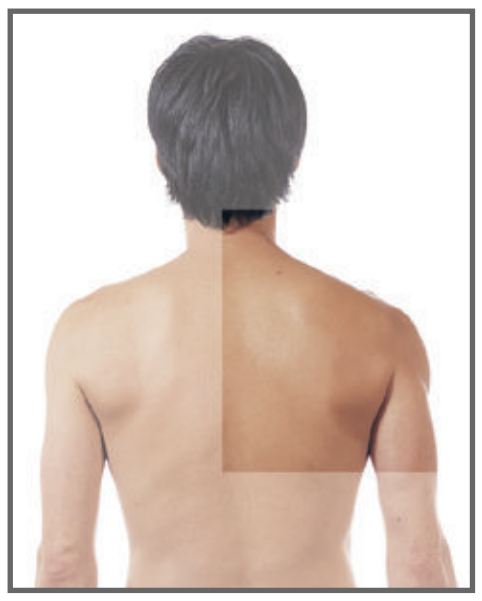

The triangle of auscultation (12) is bounded by the trapezius, latissimus dorsi and the medial border of the scapula; its floor is partly formed by rhomboid major. If the arms are brought forwards, the sixth intercostal space becomes available for auscultation.

Intramuscular injections, see pages 170–172.

Right shoulder *from behind, trapezius reflected*

1 Acromion
2 Branches of circumflex scapular artery
3 Deep branch of transverse cervical artery
4 Deltoid muscle
5 Erector spinae muscle
6 Infraspinatus muscle
7 Latissimus dorsi muscle
8 Levator scapulae muscle
9 Medial border of scapula
10 Rhomboid major muscle
11 Rhomboid minor muscle
12 Spinal accessory nerve
13 Spine of scapula
14 Splenius capitis muscle
15 Supraspinatus muscle
16 Teres major muscle
17 Teres minor muscle
18 Thoracic part of thoracolumbar fascia
19 Trapezius muscle (cut and reflected)

Shoulder joint injection, see pages 170–172.

A Right shoulder *from above and behind*

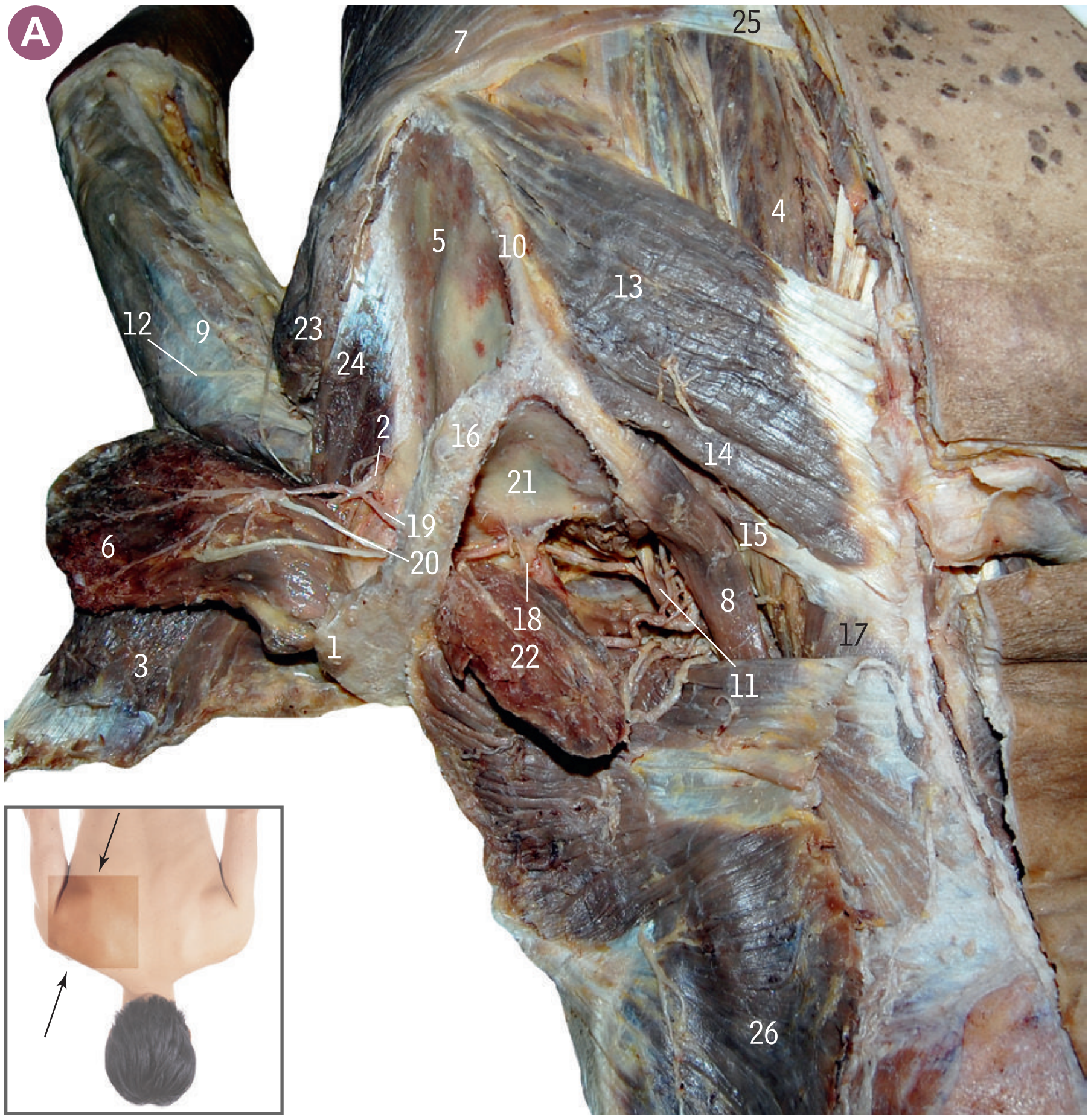

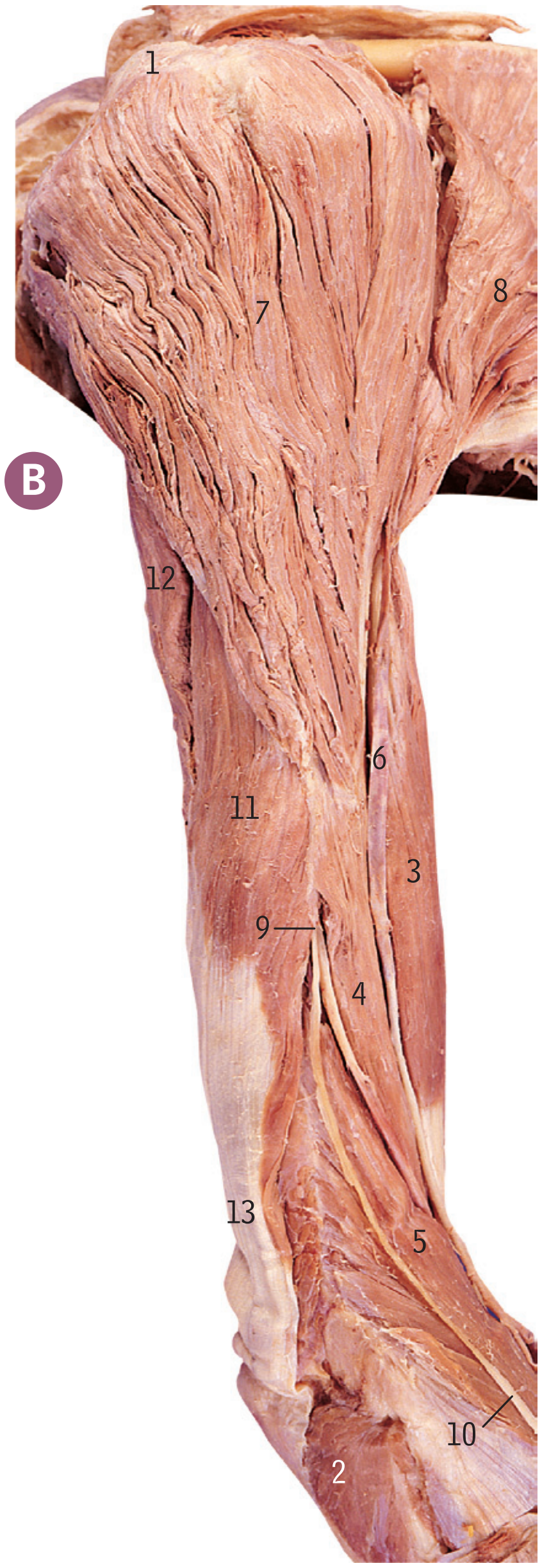

1 Acromion
2 Branches of circumflex scapular artery anastomosing with suprascapular artery
3 Deltoid muscle (cut and reflected)
4 Erector spinae muscle
5 Infraspinous fossa
6 Infraspinatus muscle (cut and reflected)
7 Latissimus dorsi muscle
8 Levator scapulae muscle
9 Long head of triceps brachii muscle
10 Medial border of scapula
11 Omohyoid muscle
12 Posterior cutaneous nerve to the arm
13 Rhomboid major muscle
14 Rhomboid minor muscle
15 Serratus posterior superior muscle
16 Spine of the scapula
17 Splenius capitis muscle
18 Superior transverse scapular ligament
19 Suprascapular artery
20 Suprascapular nerve
21 Supraspinous fossa
22 Supraspinatus muscle (cut and reflected)
23 Teres major muscle
24 Teres minor muscle
25 Thoracic part of thoracolumbar fascia
26 Trapezius muscle (cut and reflected)

B Right shoulder and upper arm *from the right*

Deltoid (7) extends over the tip of the shoulder to its attachment halfway down the lateral side of the shaft of the humerus. Biceps brachii (3) is on the front of the arm below pectoralis major (8) and triceps (11 and 12) is at the back.

1 Acromion
2 Anconeus
3 Biceps brachii
4 Brachialis
5 Brachioradialis
6 Cephalic vein
7 Deltoid
8 Pectoralis major
9 Radial nerve
10 Radial nerve, posterior cutaneous branch to the forearm
11 Triceps, lateral head
12 Triceps, long head
13 Triceps, tendon

Posterior dislocation of the shoulder, see pages 170–172.

Right shoulder *deep dissection of scapular region*

1 Acromion
2 Branches of circumflex scapular artery
3 Deltoid muscle (cut and reflected)
4 Erector spinae muscle
5 Infraspinatus muscle (cut and reflected)
6 Latissimus dorsi muscle
7 Levator scapulae muscle
8 Long head of triceps brachii muscle
9 Medial border of scapula
10 Posterior cutaneous nerve to the arm
11 Rhomboid major muscle
12 Rhomboid minor muscle
13 Suprascapular artery
14 Suprascapular nerve
15 Supraspinatus muscle (cut and reflected)
16 Teres major muscle
17 Teres minor muscle
18 Thoracic part of thoracolumbar fascia
19 Trapezius muscle (cut and reflected)

Right shoulder deep dissection of scapular region
as seen from above and behind

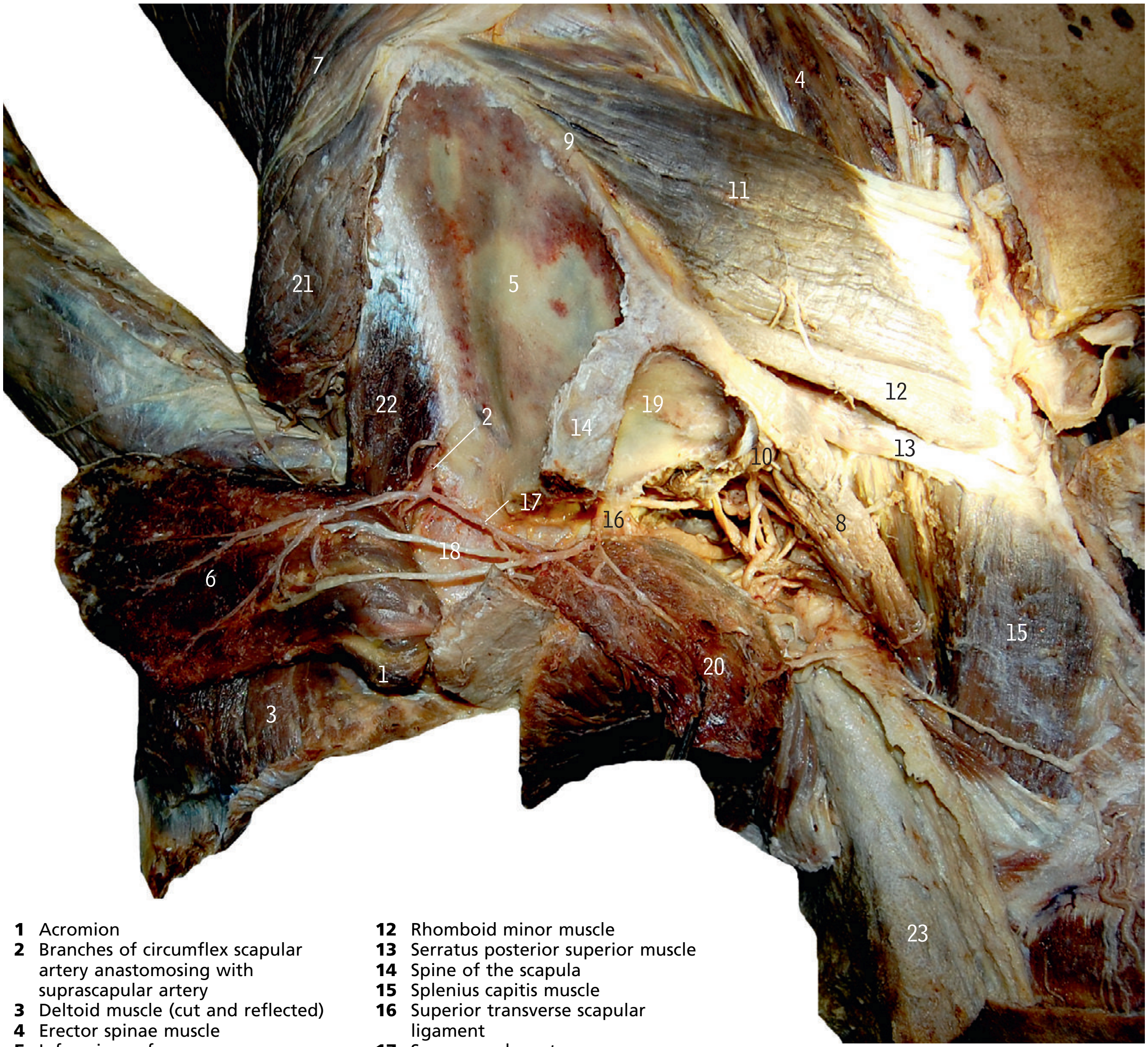

1 Acromion
2 Branches of circumflex scapular artery anastomosing with suprascapular artery
3 Deltoid muscle (cut and reflected)
4 Erector spinae muscle
5 Infraspinous fossa
6 Infraspinatus muscle (cut and reflected)
7 Latissimus dorsi muscle
8 Levator scapulae muscle
9 Medial border of scapula
10 Omohyoid muscle
11 Rhomboid major muscle
12 Rhomboid minor muscle
13 Serratus posterior superior muscle
14 Spine of the scapula
15 Splenius capitis muscle
16 Superior transverse scapular ligament
17 Suprascapular artery
18 Suprascapular nerve
19 Supraspinous fossa
20 Supraspinatus muscle (cut and reflected)
21 Teres major muscle
22 Teres minor muscle
23 Trapezius muscle (cut and reflected)

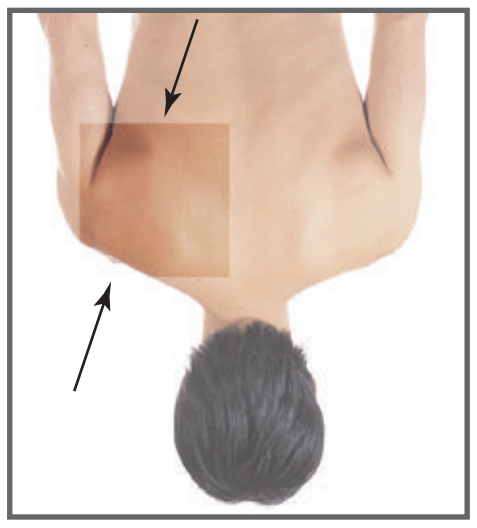

Scapular arterial anastomoses, see pages 170–172.

Right shoulder joint Ⓐ *cross section* Ⓑ *axial MR image*

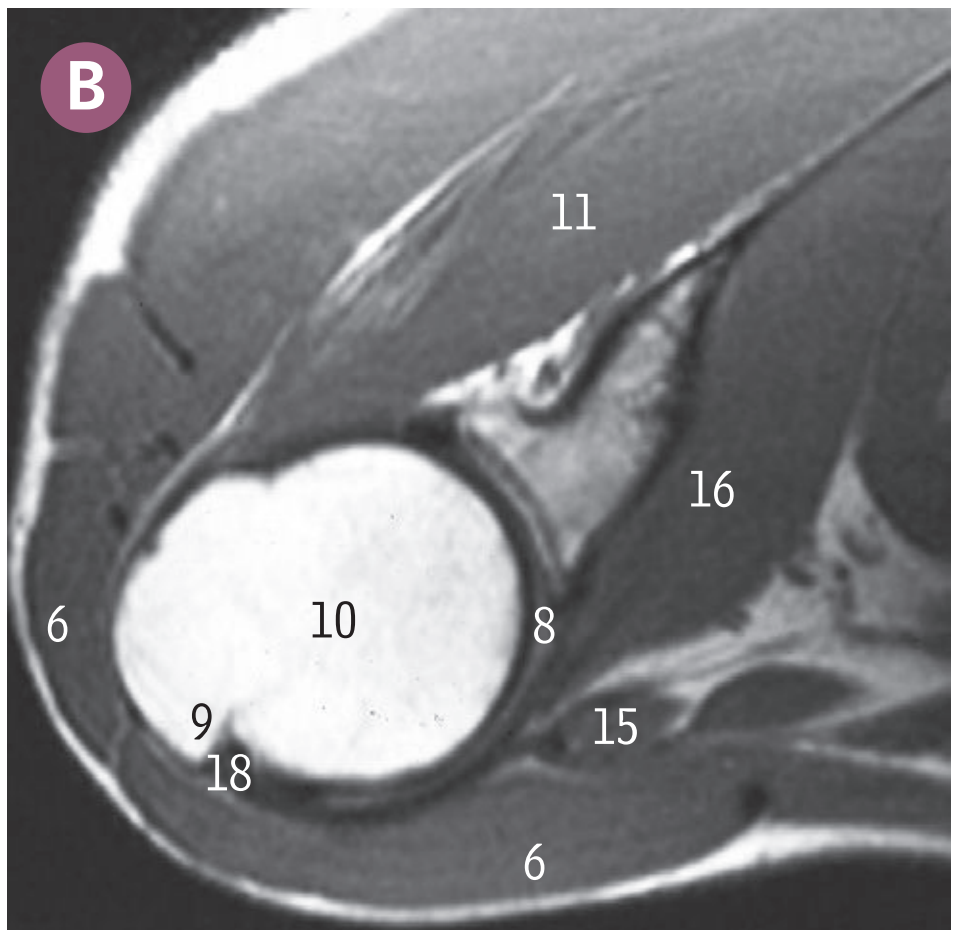

Viewed from below, this cadaveric section shows the articulation of the head of the humerus (10) with the glenoid cavity of the scapula (7). The tendon of the long head of biceps (18) lies in the groove between the greater and lesser tubercles of the humerus (9 and 12). Subscapularis (16) passes immediately in front of the joint, and infraspinatus (11) behind it. Compare the MR image in B with features in A.

1 Axillary artery
2 Capsule
3 Cephalic vein
4 Coracobrachialis
5 Cords of brachial plexus
6 Deltoid
7 Glenoid cavity
8 Glenoid labrum
9 Greater tubercle
10 Head of humerus
11 Infraspinatus
12 Lesser tubercle
13 Musculocutaneous nerve
14 Pectoralis major
15 Short head of biceps
16 Subscapularis
17 Suprascapular nerve and vessels
18 Tendon of long head of biceps in intertubercular groove

Right shoulder joint Ⓒ *from the front*

The synovial joint cavity inside the capsule (2) and the subacromial bursa (5) have been injected separately with green resin.

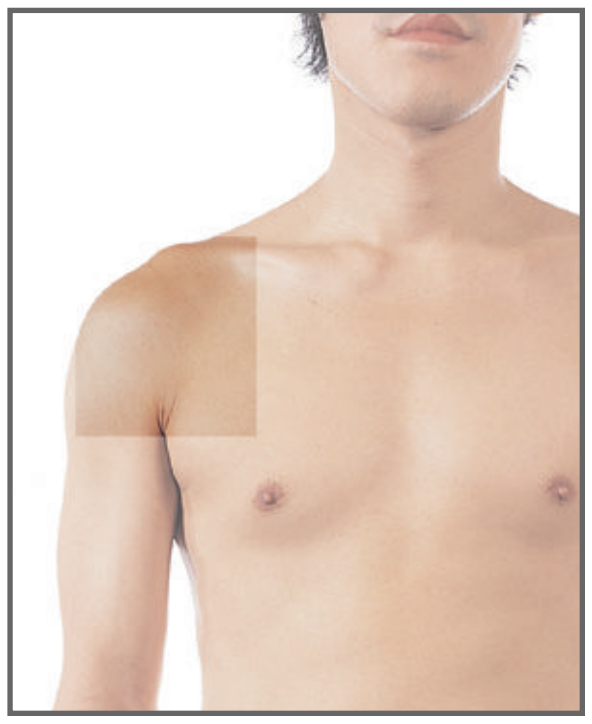

1 Acromioclavicular joint
2 Capsule of shoulder joint
3 Conoid ligament
4 Coracoacromial ligament
5 Subacromial bursa
6 Subscapularis bursa
7 Superior transverse scapular (suprascapular) ligament
8 Tendon of long head of biceps
9 Trapezoid ligament

Ⓓ Shoulder *coronal oblique MR arthrogram*

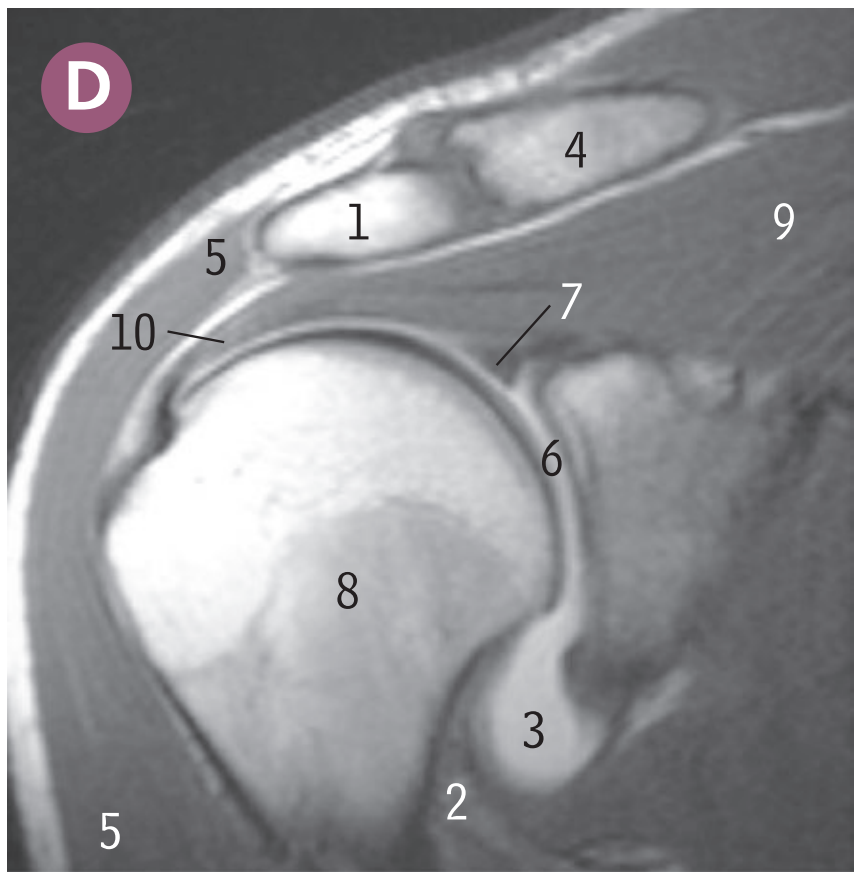

1 Acromion
2 Axillary nerve and circumflex humeral vessels
3 Axillary recess of shoulder joint
4 Clavicle
5 Deltoid
6 Glenoid cavity
7 Glenoid labrum
8 Humerus
9 Supraspinatus muscle
10 Supraspinatus tendon

E Right Shoulder *dissection, coronal section*

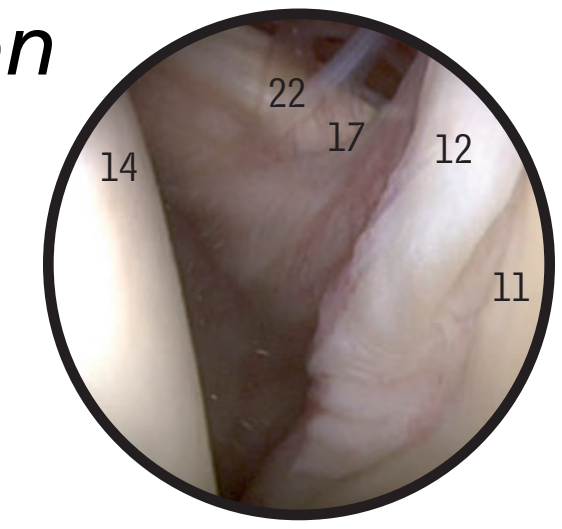

This is the first view of the shoulder on entering the joint from the posterior aspect with an arthroscope. The humerus head is on the left, the subscapularis tendon is in the middle and the glenoid and the surrounding labrum is on the right. The joint is slightly distracted with the aid of traction and also the fluid in the joint used in the arthroscopy.

G Right shoulder joint *opened from behind*

In this view, after removing all the posterior part of the capsule, the inner surface of the front of the capsule (4) is seen, with its reinforcing glenohumeral ligaments (15, 17 and 23).

F Right shoulder *radiograph*

anteroposterior projection in a 9-year-old child

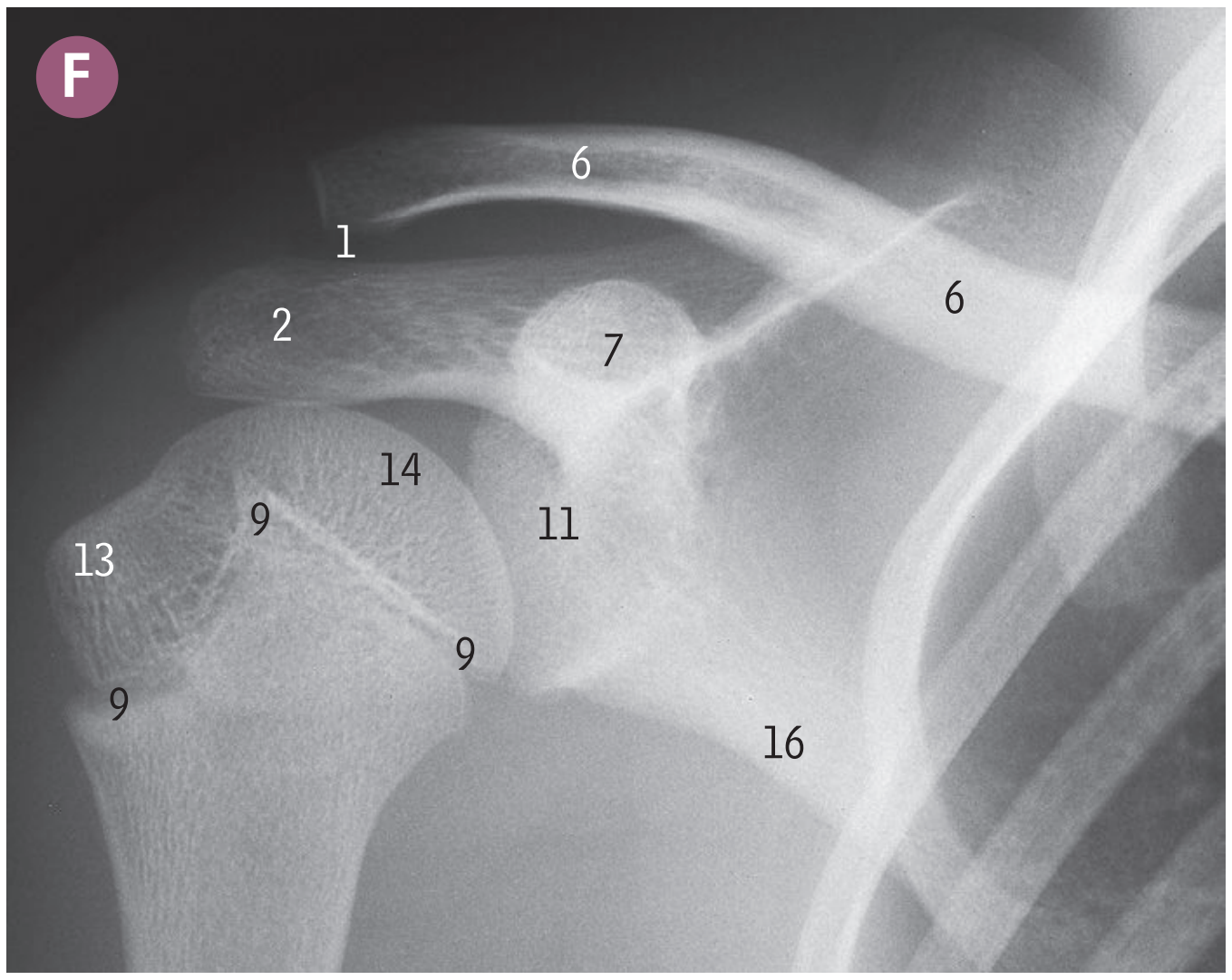

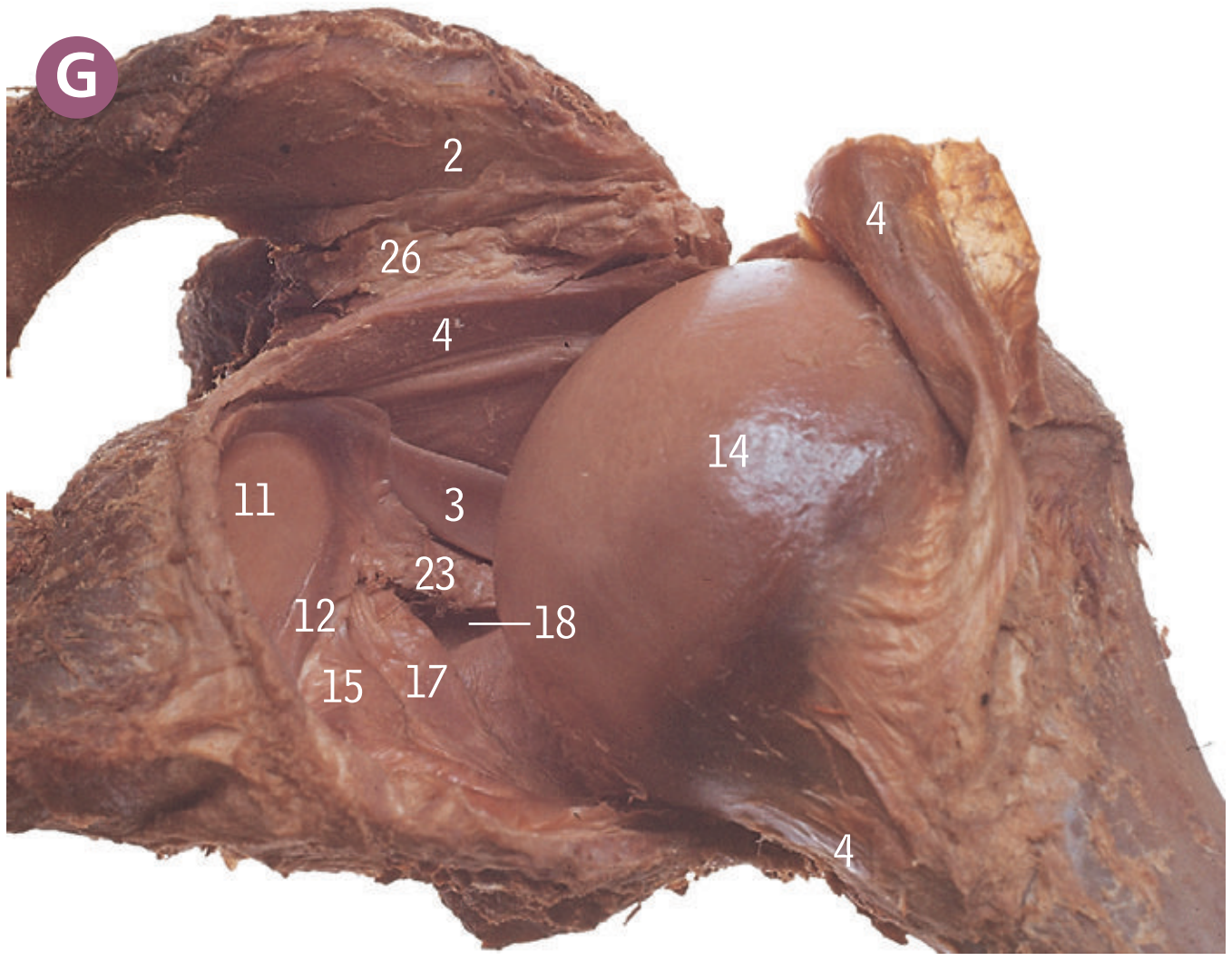

The joint cavity communicates with the subscapularis bursa through an opening between the superior and middle glenohumeral ligaments.

The tendon of the long head of biceps is continuous with the glenoid labrum.

1 Acromioclavicular joint
2 Acromion
3 Biceps, long head
4 Capsule
5 Circumflex scapular vessels
6 Clavicle
7 Coracoid process
8 Deltoid
9 Epiphysial line
10 Fibrocartilaginous disc
11 Glenoid cavity
12 Glenoid labrum
13 Greater tubercle
14 Head of humerus
15 Inferior glenohumeral ligament
16 Lateral border of scapula
17 Middle glenohumeral ligament
18 Opening into subscapularis bursa
19 Posterior circumflex humeral vessels
20 Profunda brachii vessels
21 Radial nerve
22 Subscapularis
23 Superior glenohumeral ligament
24 Suprascapular nerve
25 Suprascapular vessels
26 Supraspinatus
27 Supraspinatus tendon
28 Teres major
29 Triceps, lateral head

Bicipital tendinitis and rupture, calcific tendinitis, painful arc syndrome/rotator cuff tear, see pages 170–172.

Right axilla *anterior chest wall*

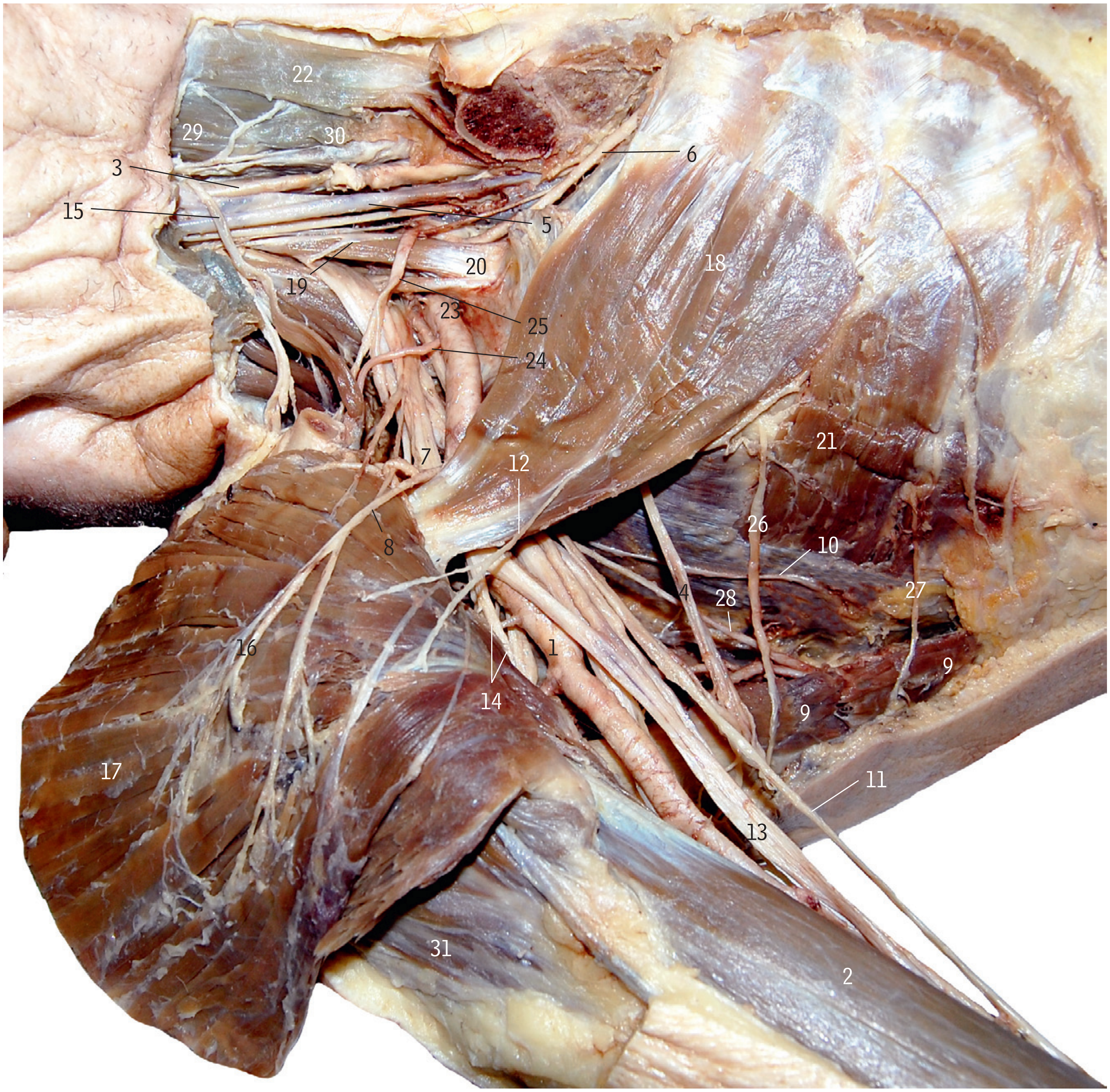

1 Axillary artery
2 Biceps brachii muscle
3 Common carotid artery
4 Intercostobrachial nerve
5 Internal jugular vein
6 Internal thoracic artery
7 Lateral cord of brachial plexus
8 Lateral pectoral nerve
9 Latissimus dorsi muscle
10 Long thoracic nerve
11 Medial cutaneous nerve to the forearm
12 Medial pectoral nerve
13 Median nerve
14 Musculocutaneous nerve
15 Omohyoid tendon
16 Pectoral branch of thoracoacromial trunk
17 Pectoralis major muscle (reflected)
18 Pectoralis minor muscle
19 Phrenic nerve
20 Scalenus anterior muscle
21 Serratus anterior muscle
22 Sternohyoid muscle
23 Subclavian artery
24 Suprascapular artery
25 Suprsascapular nerve
26 T3 spinal nerve
27 T4 spinal nerve
28 Thoracodorsal nerve
29 Thyrohyoid muscle
30 Thyroid gland
31 Triceps brachii muscle

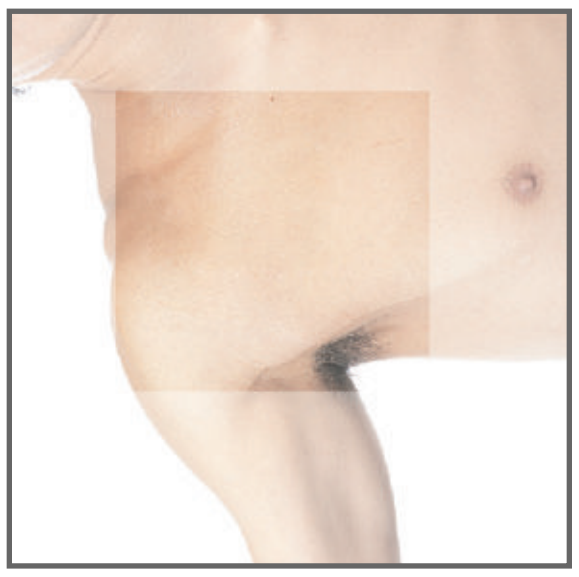

Axillary-subclavian vein thrombosis, cervical rib, see pages 170–172.

Right axilla and brachial plexus *from the front*

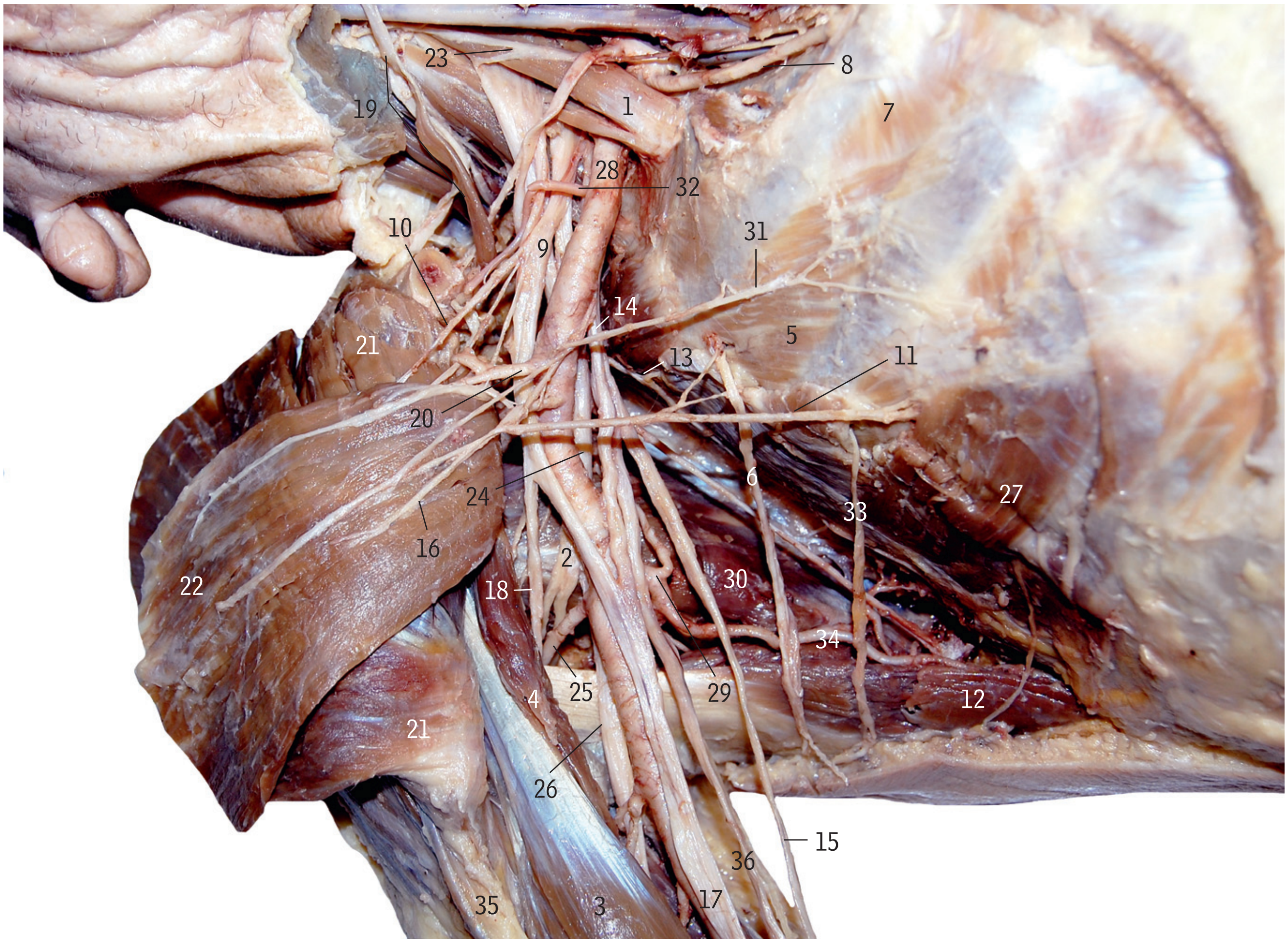

1 Anterior scalene muscle
2 Axillary nerve
3 Biceps brachii muscle
4 Coracobrachialis
5 External intercostal muscle
6 Intercostobrachial nerve
7 Internal intercostal muscle
8 Internal thoracic artery
9 Lateral cord of brachial plexus
10 Lateral pectoral nerve
11 Lateral thoracic artery
12 Latissimus dorsi muscle
13 Long thoracic nerve
14 Medial cord of brachial plexus
15 Medial cutaneous nerve to the forearm
16 Medial pectoral nerve
17 Median nerve
18 Musculocutaneous nerve
19 Omohyoid muscle
20 Pectoral branch of thoracoacromial trunk
21 Pectoralis major muscle (reflected)
22 Pectoralis minor muscle (reflected)
23 Phrenic nerve
24 Posterior cord of brachial plexus
25 Posterior circumflex humeral artery
26 Radial nerve
27 Serratus anterior muscle
28 Subclavian artery
29 Subscapular trunk
30 Subscapularis muscle
31 Superior thoracic artery
32 Suprascapular artery
33 T3 spinal nerve
34 Thoracodorsal artery
35 Triceps brachii muscle
36 Ulnar nerve

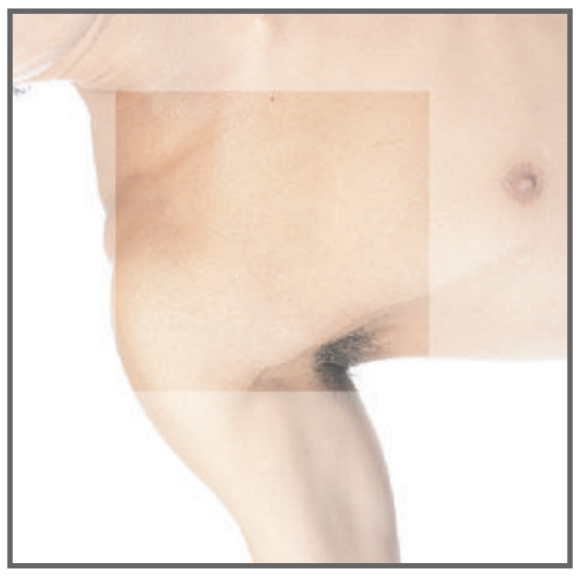

Erb's palsy, winging of the scapula, see pages 170–172.

Right brachial plexus *reflected to reveal arterial branches*

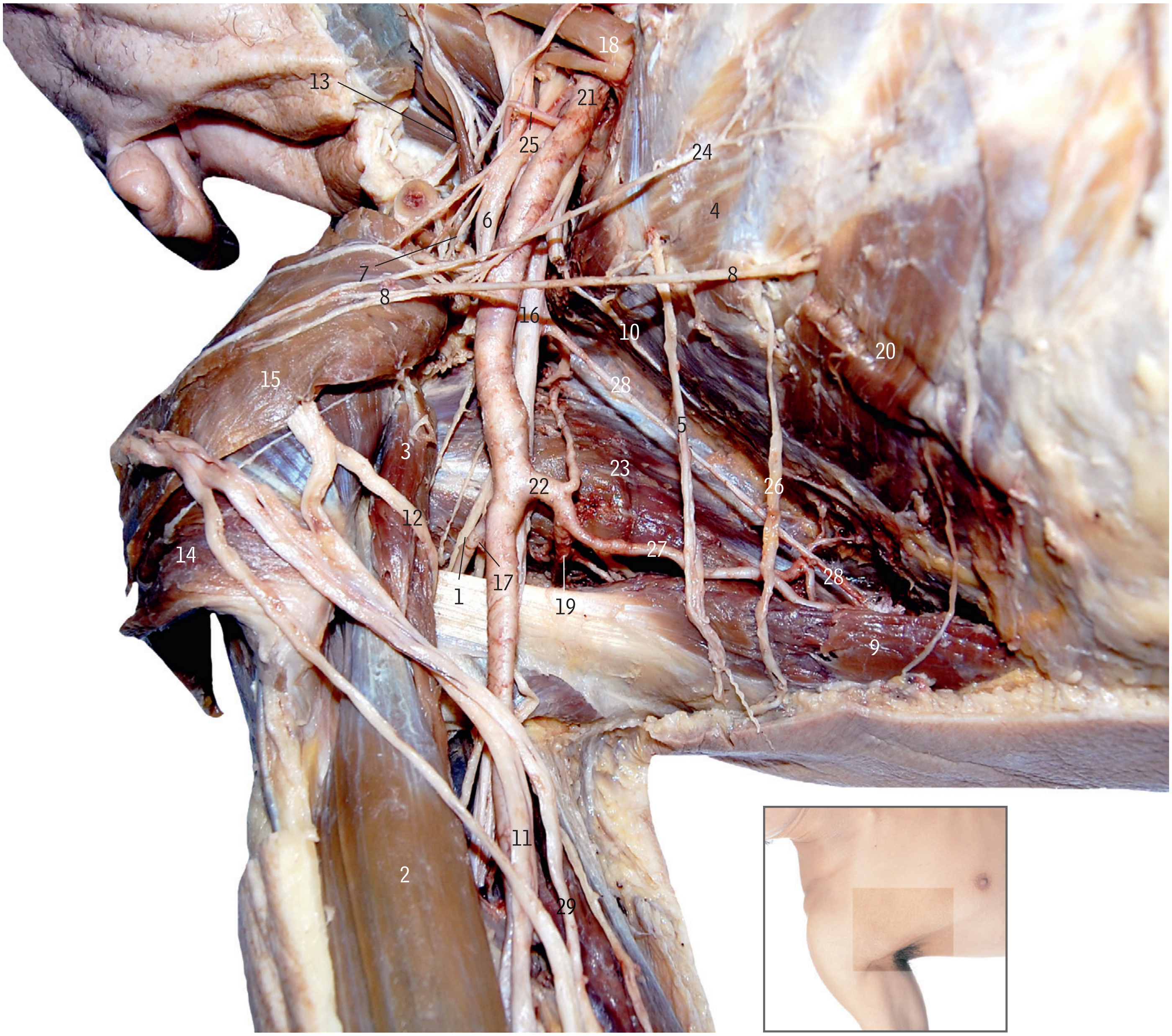

1 Axillary nerve
2 Biceps brachii muscle
3 Coracobrachialis muscle
4 External intercostal muscle
5 Intercostobrachial nerve
6 Lateral cord of brachial plexus
7 Lateral pectoral nerve
8 Lateral thoracic artery
9 Latissimus dorsi muscle
10 Long thoracic nerve
11 Median nerve
12 Musculocutaneous nerve
13 Omohyoid muscle
14 Pectoralis major muscle (reflected)
15 Pectoralis minor muscle (reflected)
16 Posterior cord of brachial plexus
17 Posterior circumflex humeral artery
18 Scalenus anterior muscle
19 Scapular circumflex artery
20 Serratus anterior muscle
21 Subclavian artery
22 Subscapular trunk
23 Subscapularis muscle
24 Superior thoracic artery
25 Suprascapular artery
26 T3 spinal nerve
27 Thoracodorsal artery
28 Thoracodorsal nerve
29 Ulnar nerve

Axillary artery aneurysm, vascular abnormalities, winging of the scapula, see pages 170–172.

Left brachial plexus and branches *from the front*

1 Axillary artery
2 Axillary nerve (passing through the quadrangular space)
3 Biceps brachii muscle
4 Circumflex scapular artery
5 Clavicle
6 Coracobrachialis muscle
7 Intercostobrachial nerve
8 Latissimus dorsi muscle
9 Long head of triceps brachii muscle
10 Long thoracic nerve
11 Lower subscapular nerve
12 Medial cutaneous nerve to the arm
13 Medial cutaneous nerve to the forearm
14 Medial pectoral nerve
15 Median nerve
16 Pectoral arteries
17 Pectoralis major muscle (reflected)
18 Pectoralis minor muscle (reflected)
19 Serratus anterior muscle
20 Subclavian vein (cut)
21 Subclavius muscle
22 Subscapular trunk
23 Subscapularis muscle
24 Superior thoracic artery
25 Thoracodorsal (middle subscapular) nerve
26 Thoracodorsal artery
27 Ulnar nerve
28 Upper subscapular nerve

Brachial plexus block, see pages 170–172.

Right brachial plexus and branches

In this front view of the plexus, all the blood vessels have been removed to show the cords of the plexus and their branches more clearly. Note the 'capital M' pattern formed by the musculocutaneous nerve (18), the lateral root of the median nerve (8), the median nerve itself (17), the medial root of the median nerve (16) and the ulnar nerve (26). In this specimen, the tendon of latissimus dorsi (9) is unusually broad and has become blended with the long head of triceps (10).

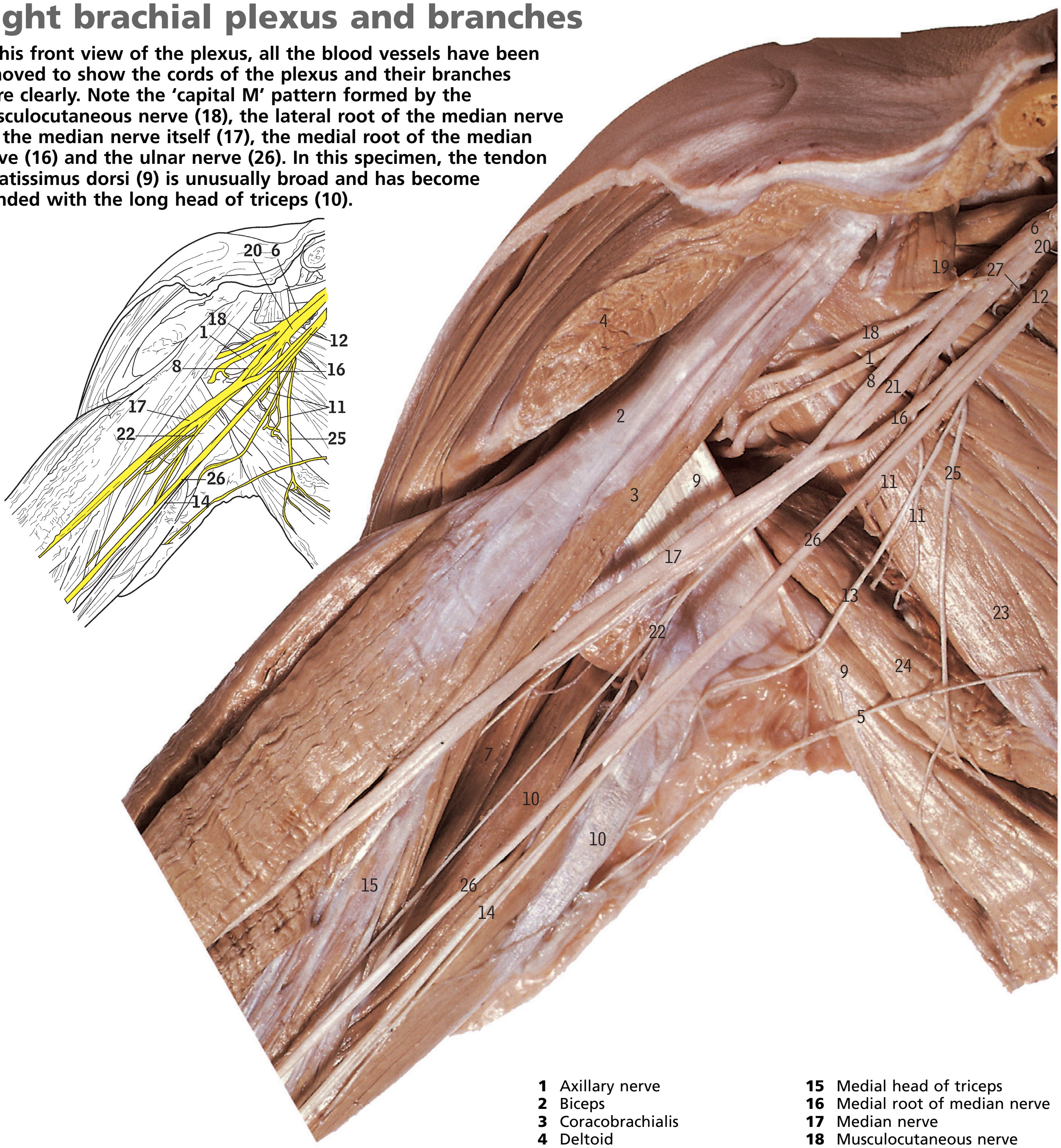

1 Axillary nerve
2 Biceps
3 Coracobrachialis
4 Deltoid
5 Intercostobrachial nerve
6 Lateral cord
7 Lateral head of triceps
8 Lateral root of median nerve
9 Latissimus dorsi
10 Long head of triceps
11 Lower subscapular nerves
12 Medial cord
13 Medial cutaneous nerve of arm
14 Medial cutaneous nerve of forearm
15 Medial head of triceps
16 Medial root of median nerve
17 Median nerve
18 Musculocutaneous nerve
19 Pectoralis minor and lateral pectoral nerve
20 Posterior cord
21 Radial nerve
22 Radial nerve branches to triceps
23 Subscapularis
24 Teres major
25 Thoracodorsal nerve
26 Ulnar nerve
27 Upper subscapular nerves

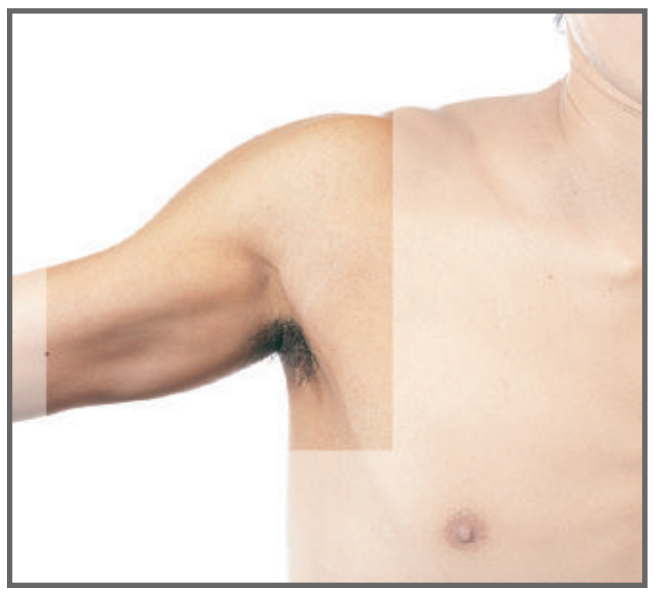

Dislocation of the shoulder, see pages 170–172.

A Right arm *vessels and nerves, from the front*

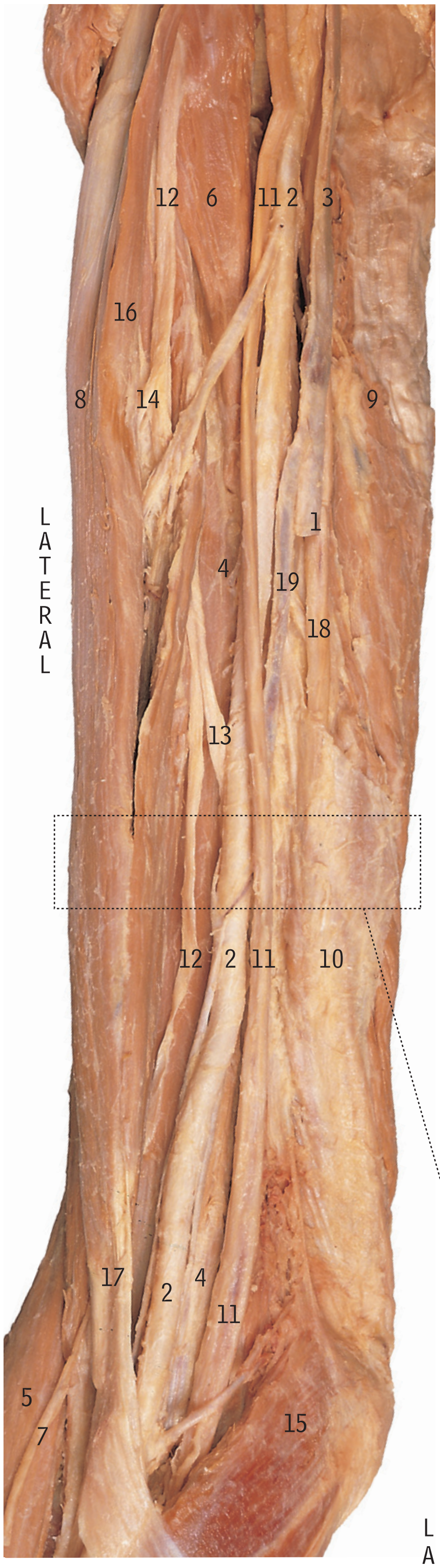

Biceps (16 and 8) has been turned laterally to show the musculocutaneous nerve (12) emerging from coracobrachialis (6), giving branches to biceps and brachialis (14 and 13) and becoming the lateral cutaneous nerve of the forearm (7) on the lateral side of the biceps tendon (17).

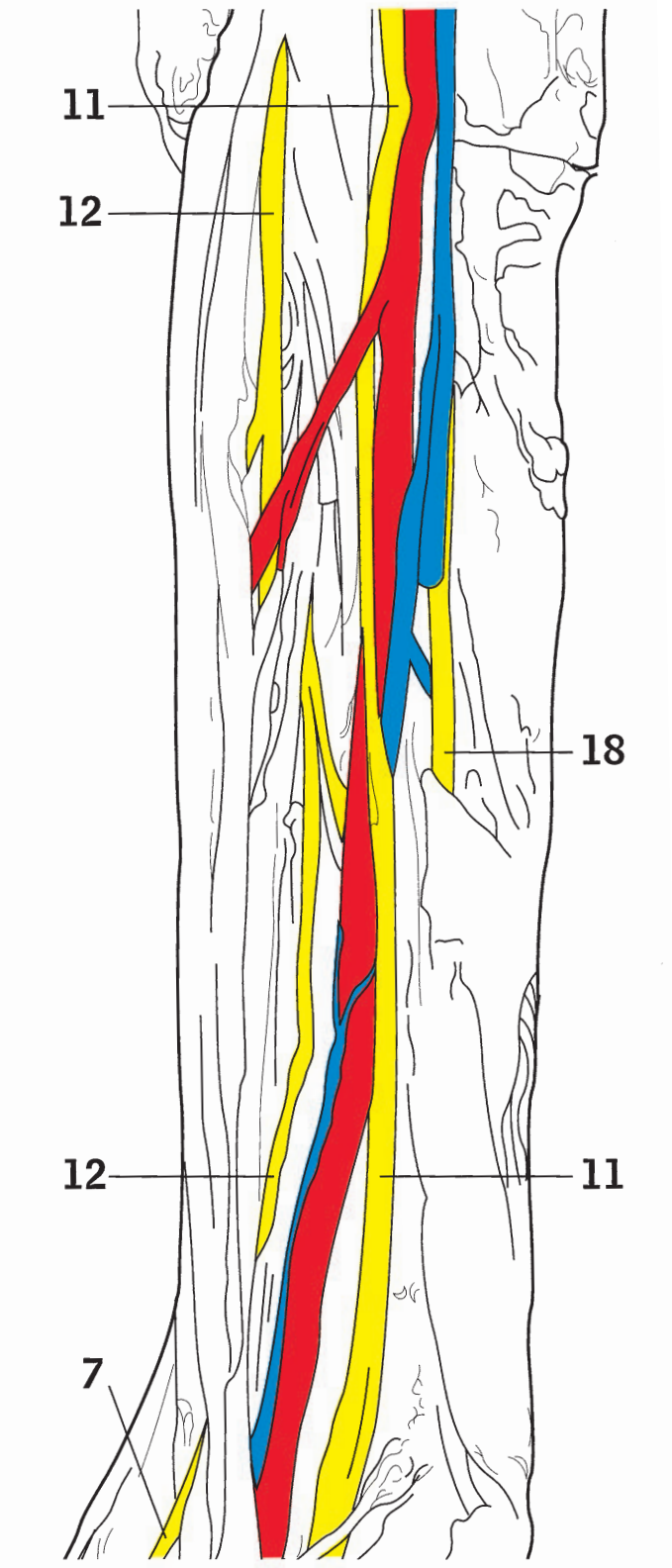

The median nerve (11) gradually crosses over in front of the brachial artery (2) from the lateral to the medial side. The ulnar nerve (18) passes behind the medial intermuscular septum (10), and the end of the basilic vein (1) is seen joining a vena comitans (19) of the brachial artery to form the brachial vein (3).

- **1** Basilic vein (cut end)
- **2** Brachial artery
- **3** Brachial vein
- **4** Brachialis
- **5** Brachioradialis
- **6** Coracobrachialis
- **7** Lateral cutaneous nerve of forearm
- **8** Long head of biceps
- **9** Long head of triceps
- **10** Medial intermuscular septum
- **11** Median nerve
- **12** Musculocutaneous nerve
- **13** Nerve to brachialis
- **14** Nerve to short head of biceps
- **15** Pronator teres
- **16** Short head of biceps
- **17** Tendon of biceps
- **18** Ulnar nerve
- **19** Vena comitans of brachial artery

The musculocutaneous nerve (A12) supplies coracobrachialis (A6), biceps (A16 and 8) and brachialis (A4), and at the level where the muscle fibres of biceps become tendinous (A17) it pierces the deep fascia to become the lateral cutaneous nerve of the forearm (A7).

The median nerve does not give off any muscular branches in the arm.

The ulnar nerve (A18) leaves the anterior compartment of the arm by piercing the medial intermuscular septum (A10), and does not give off any muscular branches in the arm.

B Right arm *cross-section, from below*

Looking from the elbow towards the shoulder, the section is taken through the middle of the arm. The musculocutaneous nerve (9) lies between brachialis (4) and biceps (2), and the median nerve (8) is on the medial side of the brachial artery (3) which has several venae comitantes adjacent (unlabelled). The ulnar nerve (13), with the superior ulnar collateral artery (11) beside it, is behind the median nerve (8) and the basilic vein (1). The radial nerve and the profunda brachii vessels (10) are in the posterior compartment at the lateral side of the humerus (6).

FRONT

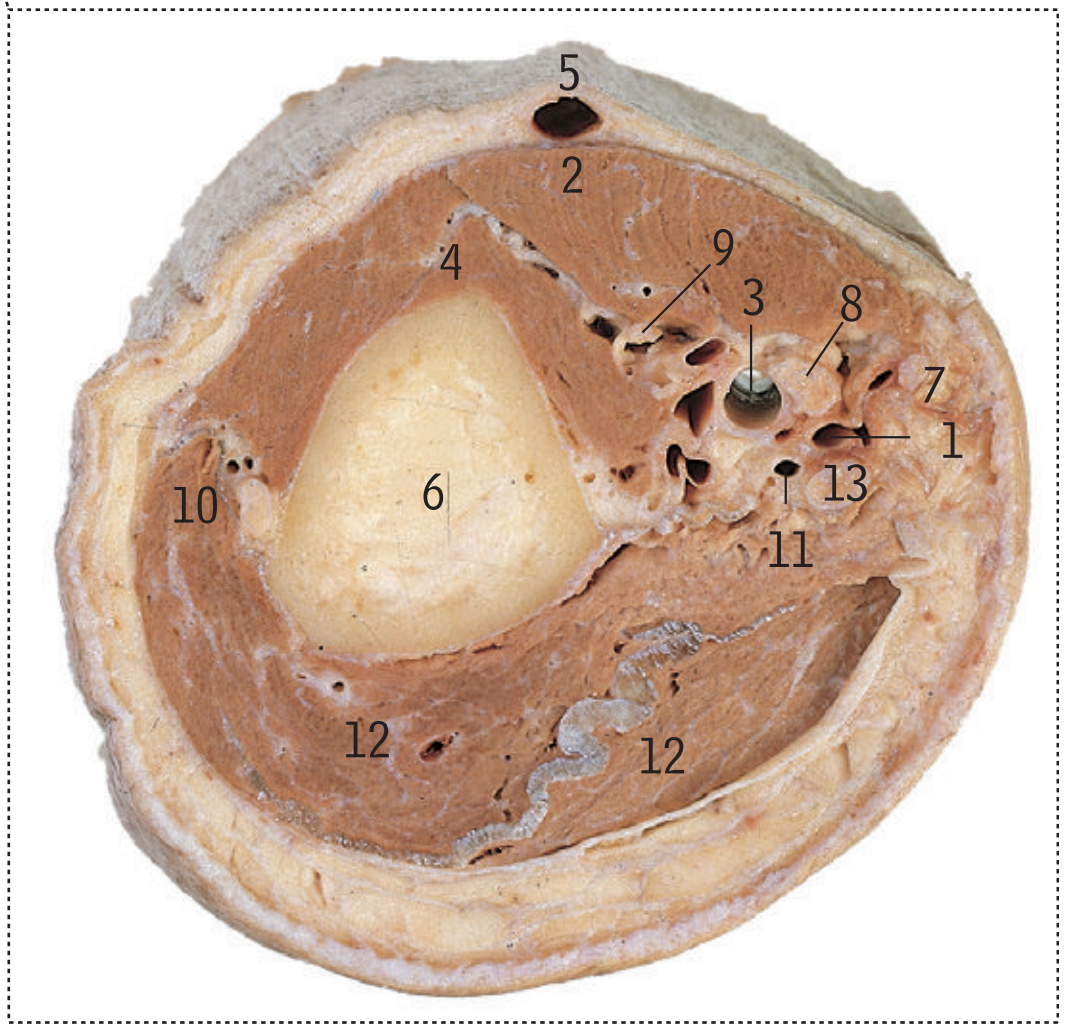

LATERAL

- **1** Basilic vein
- **2** Biceps
- **3** Brachial artery
- **4** Brachialis
- **5** Cephalic vein
- **6** Humerus
- **7** Medial cutaneous nerve of forearm
- **8** Median nerve
- **9** Musculocutaneous nerve
- **10** Radial nerve and profunda brachii vessels
- **11** Superior ulnar collateral artery
- **12** Triceps
- **13** Ulnar nerve

Volkmann's ischaemic contracture, see pages 170–172.

Right arm *posterior view*

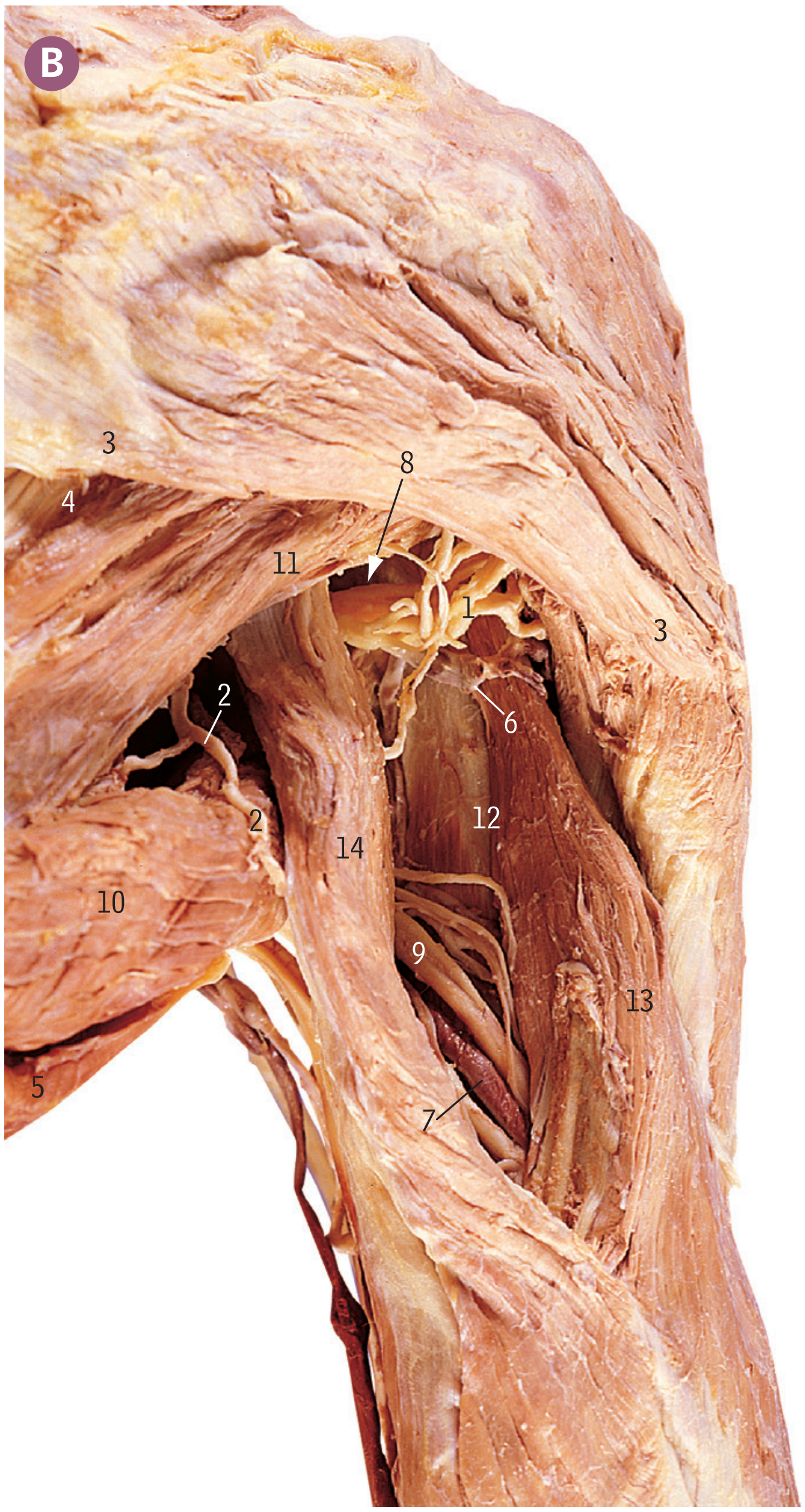

1 Axillary nerve
2 Circumflex scapular artery
3 Deltoid
4 Infraspinatus
5 Latissimus dorsi
6 Posterior circumflex humeral artery
7 Profunda brachii artery
8 Quadrangular space
9 Radial nerve in spiral groove
10 Teres major
11 Teres minor
12 Triangular space (lateral)
13 Triceps, lateral head
14 Triceps, long head
15 Ulnar nerve

A after removal of skin and subcutaneous fat

B after muscle separation to demonstrate spaces and neurovascular bundle

Radial nerve palsy, see pages 170–172.

C Left elbow *surface markings, from behind*

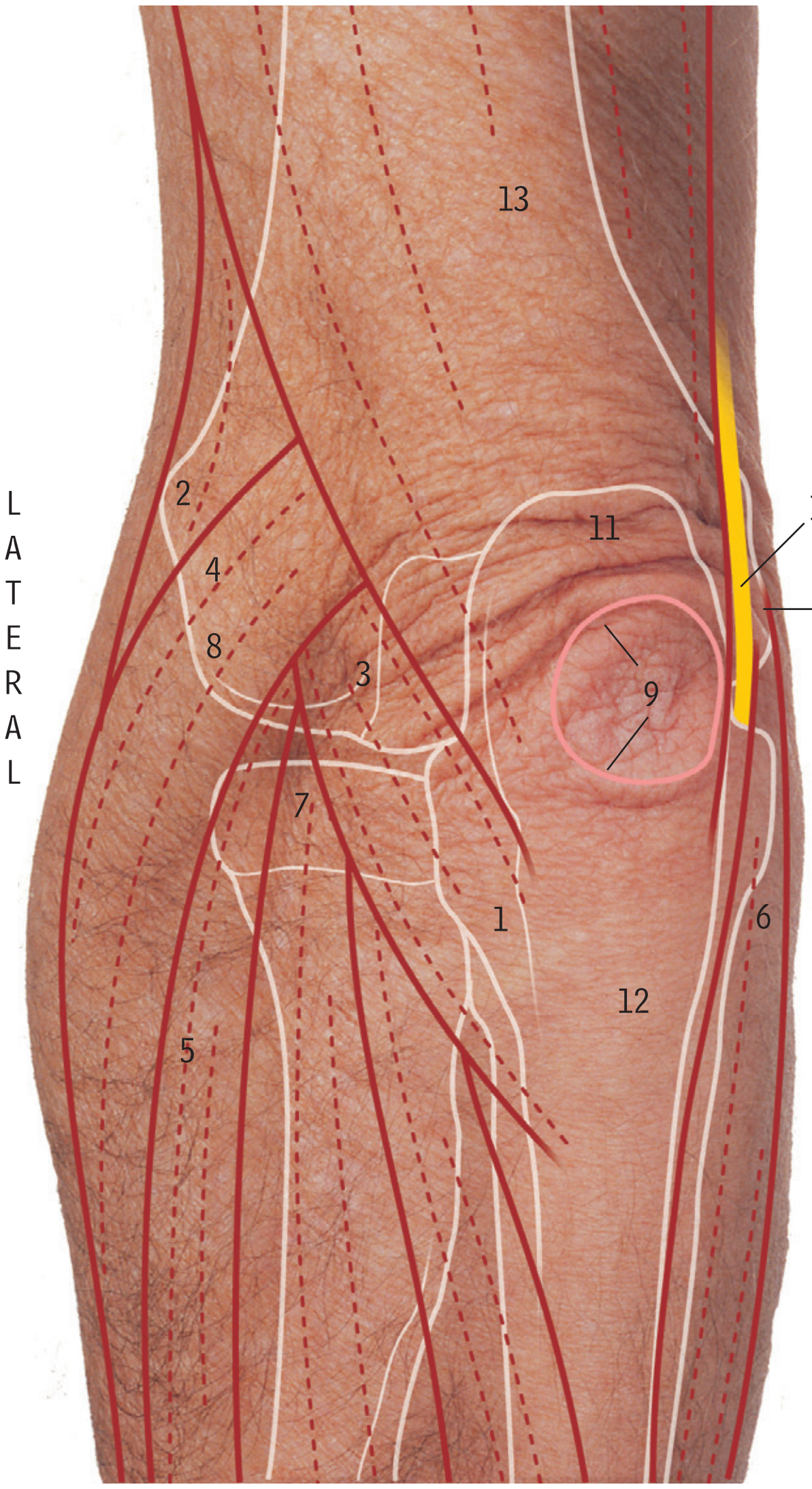

With the elbow fully extended, the extensor muscles (5, 4) form a bulge on the lateral side. In the adjacent hollow can be felt the head of the radius (7) and the capitulum of the humerus (3) which indicate the line of the humeroradial part of the elbow joint. The lateral and medial epicondyles of the humerus (8 and 10) are palpable on each side. Wrinkled skin lies at the back of the prominent olecranon of the ulna (11), and in this arm the margin of the olecranon bursa (9) is outlined. The most important structure in this region is the ulnar nerve (14) which is palpable as it lies in contact with the humerus behind the medial epicondyle (10). The posterior border of the ulna (12) is subcutaneous throughout its whole length.

1. **1** Anconeus
2. **2** Brachioradialis
3. **3** Capitulum of humerus
4. **4** Extensor carpi radialis longus
5. **5** Extensor muscles
6. **6** Flexor carpi ulnaris
7. **7** Head of radius
8. **8** Lateral epicondyle of humerus
9. **9** Margin of olecranon bursa
10. **10** Medial epicondyle of humerus
11. **11** Olecranon of ulna
12. **12** Posterior border of ulna
13. **13** Triceps
14. **14** Ulnar nerve

D Right elbow *medial view from behind*

1. **1** Biceps muscle
2. **2** Bicipital aponeurosis
3. **3** Brachial artery
4. **4** Common flexor origin
5. **5** Medial epicondyle
6. **6** Median artery
7. **7** Median nerve
8. **8** Muscular arterial branches to flexors of forearm
9. **9** Posterior ulnar recurrent artery
10. **10** Superior ulnar collateral artery
11. **11** Ulnar artery
12. **12** Ulnar nerve

Note: high division and persistent median artery.

Olecranon bursitis, triceps tendon reflex, ulnar nerve palsy, see pages 170–172.

Left elbow and radioulnar joint

A from the medial side **B** from the lateral side

Right elbow and radioulnar joint

D from the medial side **E** from the lateral side

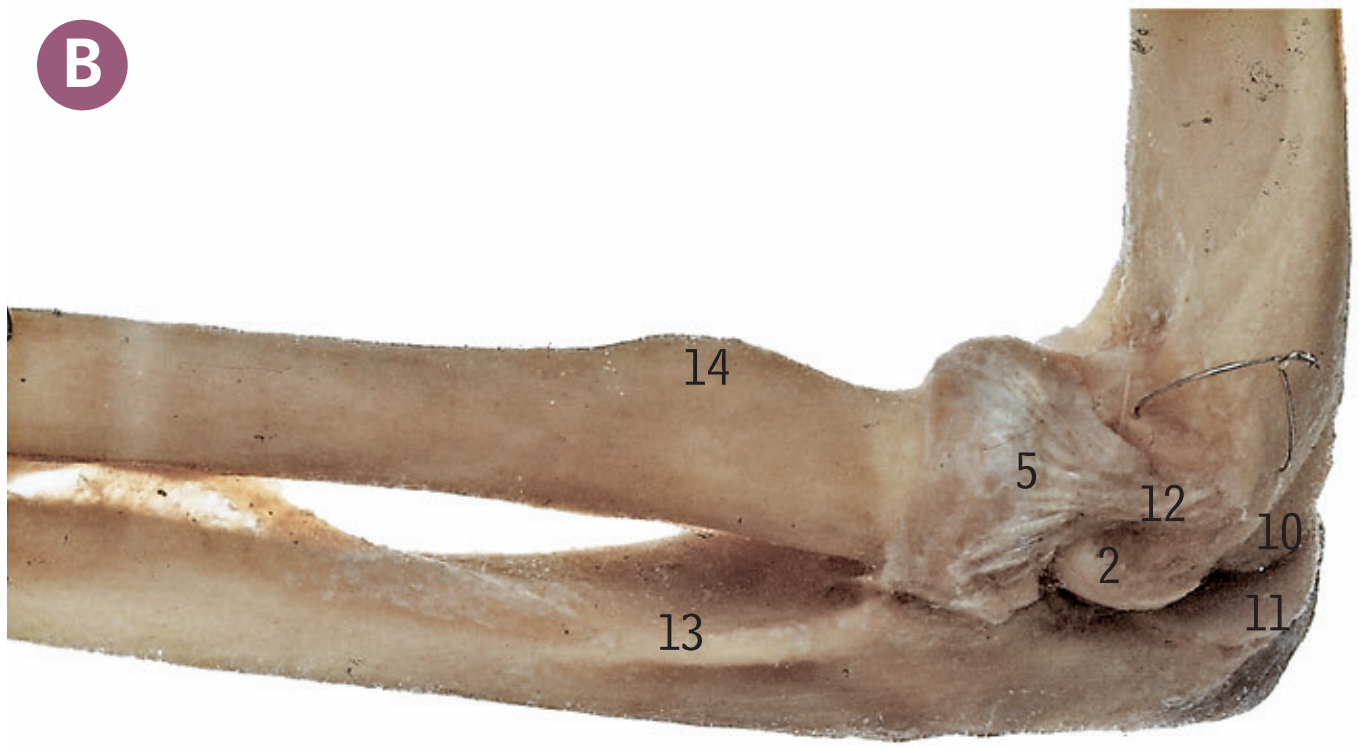

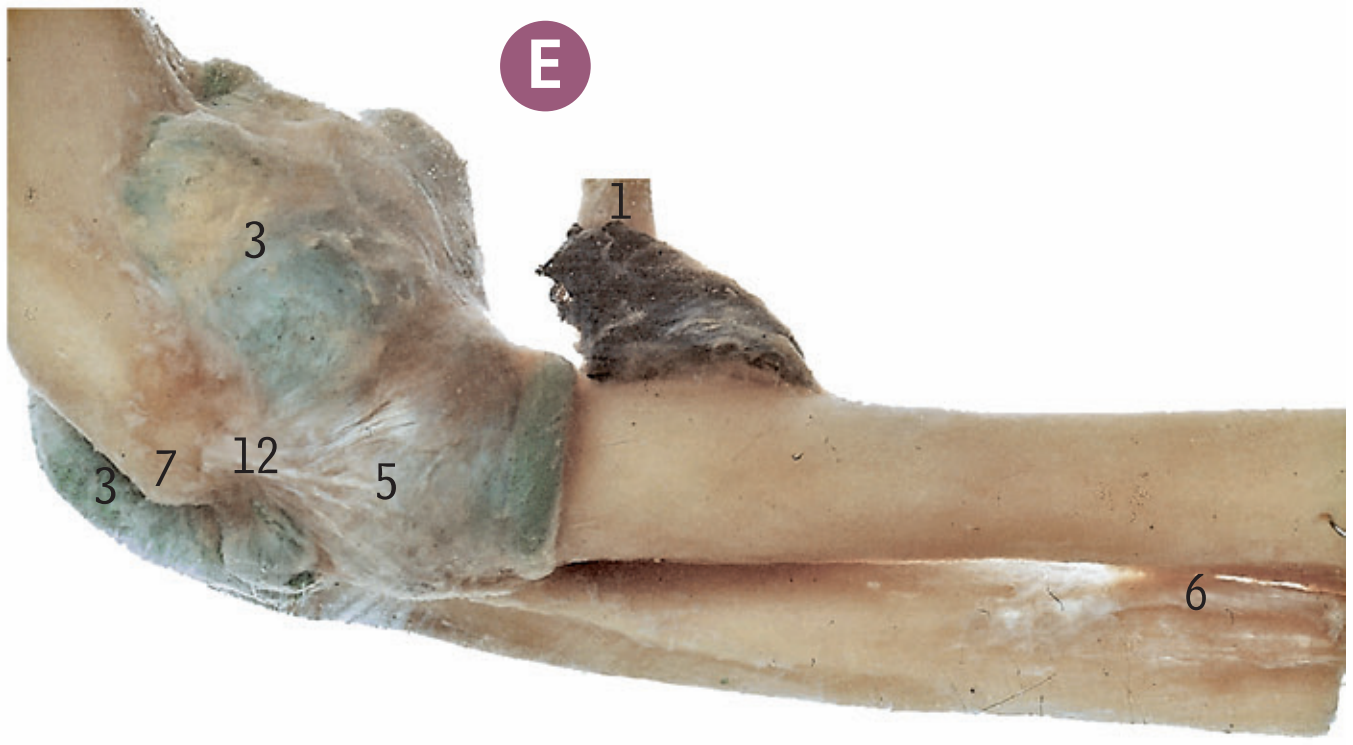

In A and B the forearm is flexed to a right angle. In D and E the forearm is partially flexed, and the synovial cavity within the capsule (3) and the bursa beneath the biceps tendon (1) have been injected with green resin.

1. Biceps tendon and underlying bursa
2. Capitulum
3. Capsule (distended)
4. Coronoid process of ulna
5. Head and neck of radius covered by annular ligament
6. Interosseous membrane
7. Lateral epicondyle
8. Medial epicondyle
9. Oblique cord
10. Olecranon fossa
11. Olecranon process of ulna
12. Radial collateral ligament
13. Supinator crest of ulna
14. Tuberosity of radius
15. Tuberosity of ulna
16. Ulnar collateral ligament: oblique band
17. Ulnar collateral ligament: posterior band
18. Ulnar collateral ligament: upper band

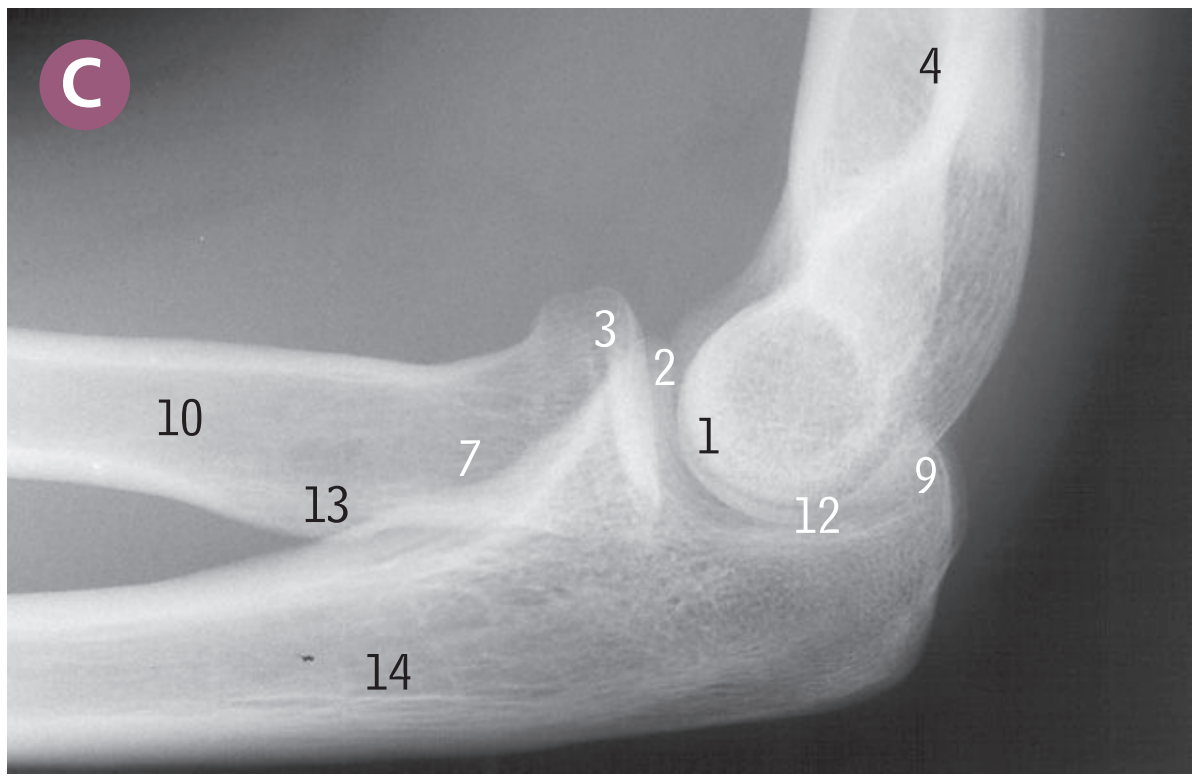

Elbow *radiographs*

C lateral projection

F AP projection

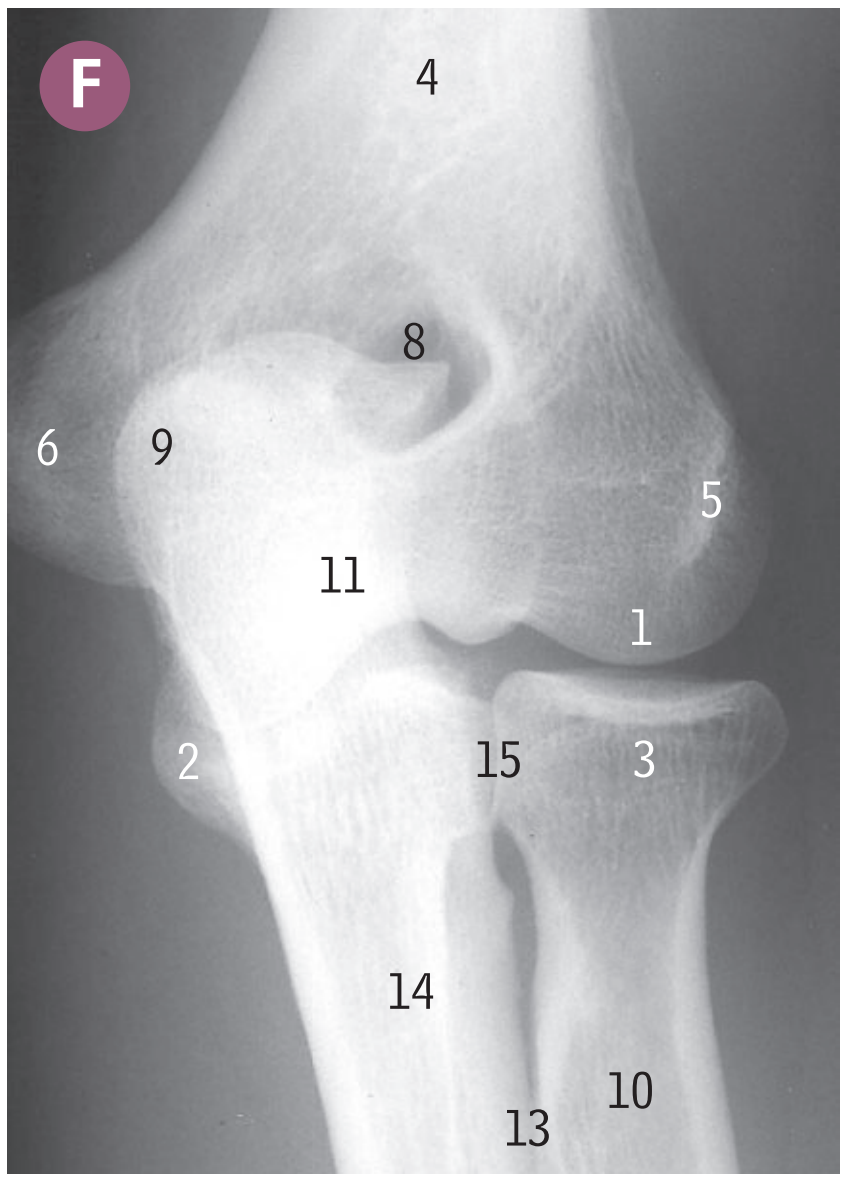

1. Capitulum of humerus
2. Coronoid process of ulna
3. Head of radius
4. Humerus
5. Lateral epicondyle of humerus
6. Medial epicondyle of humerus
7. Neck of radius
8. Olecranon fossa of humerus
9. Olecranon process of ulna
10. Radius
11. Trochlea of humerus
12. Trochlear notch of ulna
13. Tuberosity of radius
14. Ulna
15. Radioulnar joint

Dislocation of the radial head, see pages 170–172.

Left elbow joint

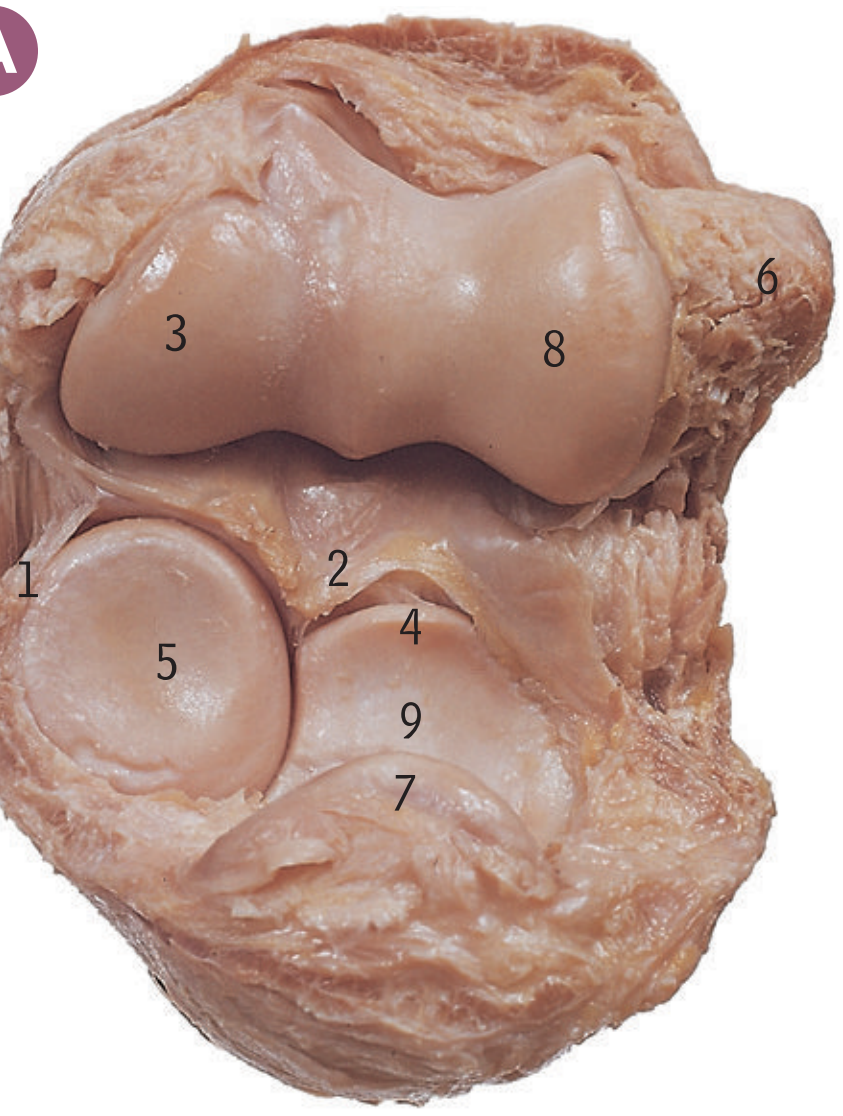

A opened from behind

The joint has been 'forced open' from behind: the capitulum (3) and trochlea (8) of the lower end of the humerus are seen from below with the forearm in forced flexion to show the upper ends of the radius and ulna (5 and 9) from above.

1 Annular ligament
2 Anterior part of capsule
3 Capitulum of humerus
4 Coronoid process of ulna
5 Head of radius
6 Medial epicondyle of humerus
7 Olecranon process of ulna
8 Trochlea of humerus
9 Trochlear notch of ulna

Left elbow

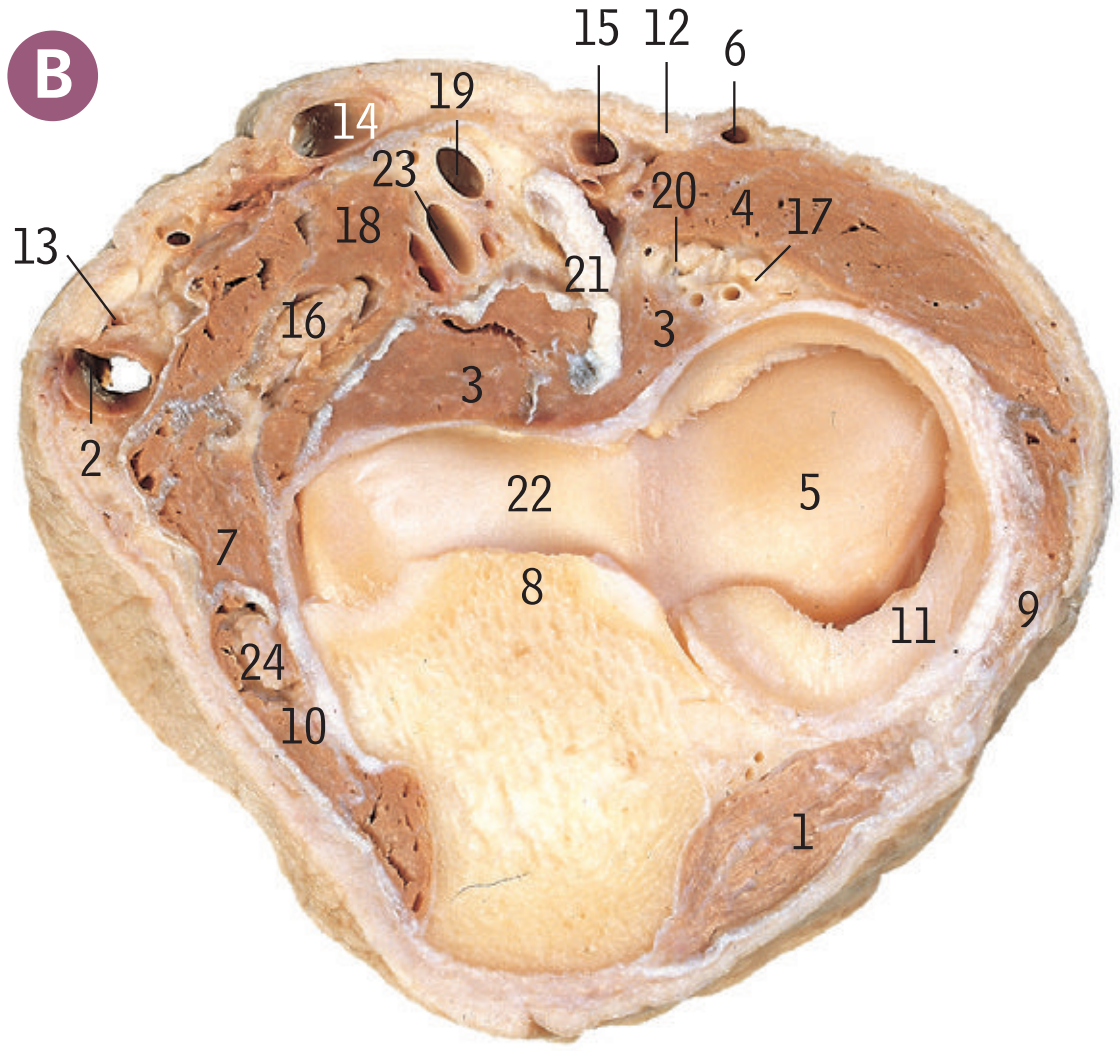

D Right elbow *coronal section*

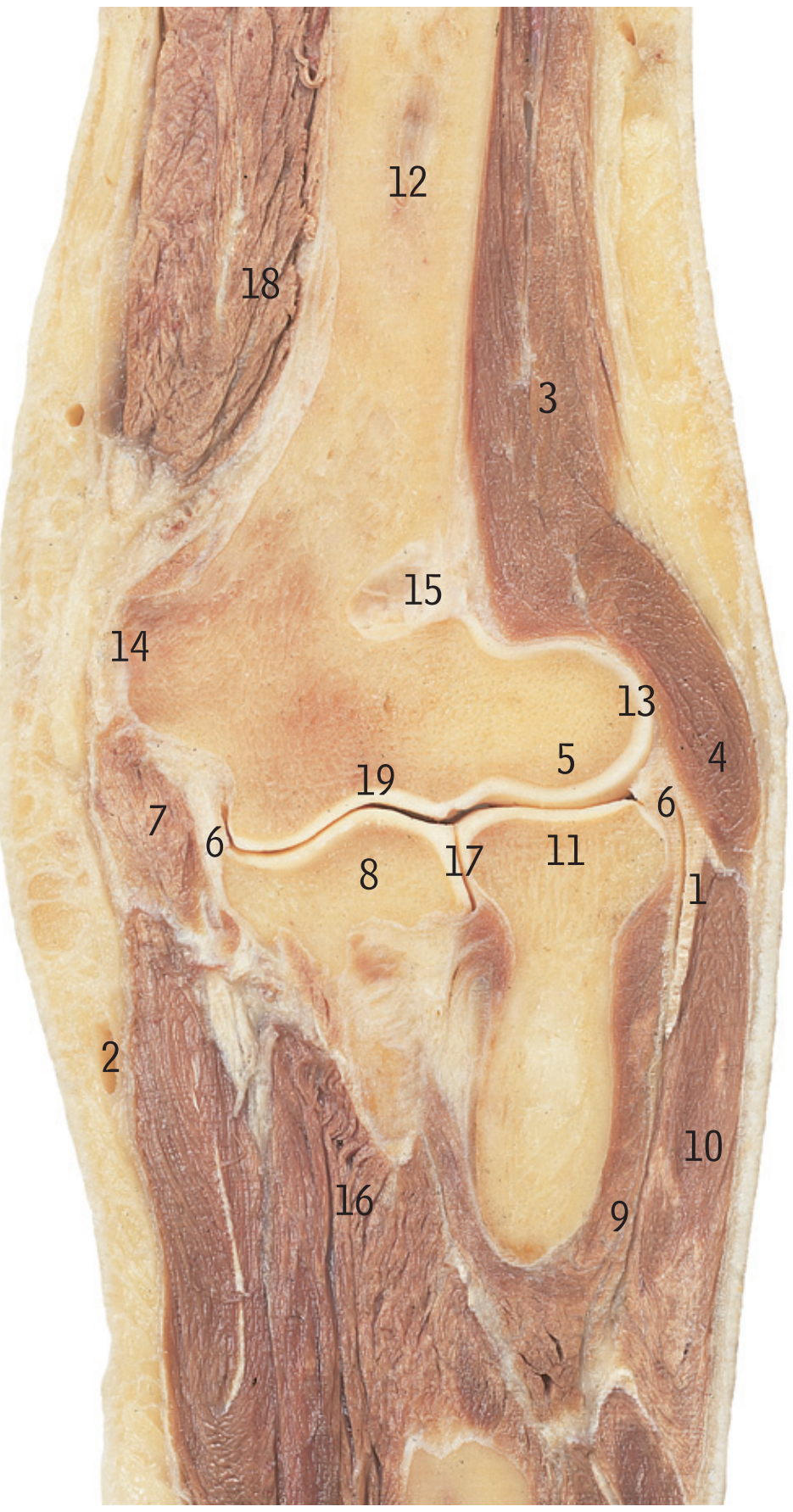

1 Annular ligament
2 Basilic vein
3 Brachialis
4 Brachioradialis
5 Capitulum of humerus
6 Capsule
7 Common flexor origin
8 Coronoid process of ulna
9 Extensor carpi radialis brevis
10 Extensor carpi radialis longus
11 Head of radius
12 Humerus
13 Lateral epicondyle
14 Medial epicondyle
15 Olecranon fossa
16 Pronator teres
17 Radio-ulnar joint, proximal
18 Triceps, medial head
19 Trochlea of humerus

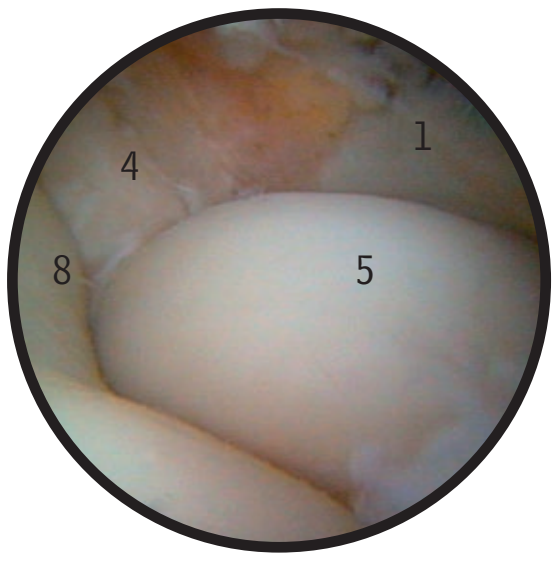

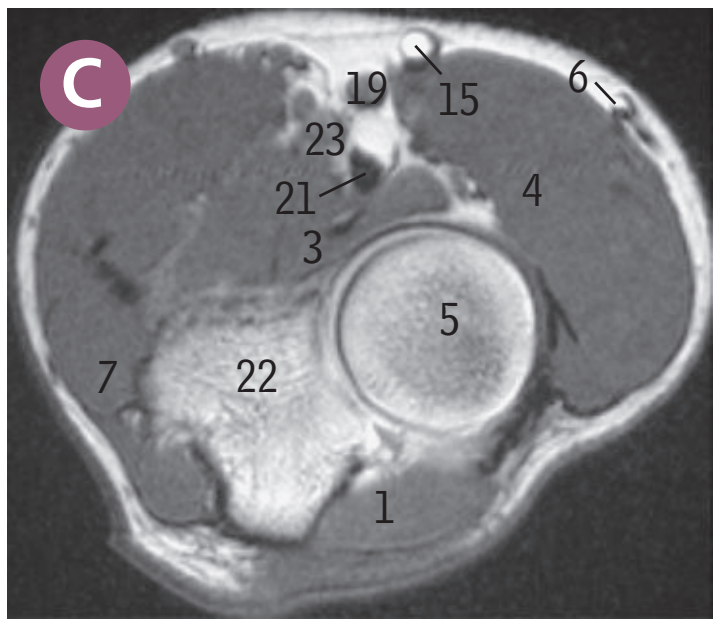

This is the arthroscopic view of an elbow joint. The view is from the superior aspect showing the orientation and the articulation of the radio-capitellar joint. Just distal to the radial head is the proximal edge of the annular ligament. The radial head is seen articulating with the coronoid process of the ulna.

B cross-section

C axial MR image

The section is viewed from below, looking towards the shoulder, and is just below the point where the brachial artery has divided into radial and ulnar arteries (19 and 23). The cut has passed immediately below the trochlea (22) and capitulum (5) of the humerus, and has gone through the coronoid process of the ulna (8). The radial nerve (20) and its posterior interosseous branch (17) lie between brachioradialis (4) and brachialis (3). The median nerve (16) is under the main part of pronator teres (18), and the ulnar nerve (24) is passing under flexor carpi ulnaris (10).

1 Anconeus
2 Basilic vein
3 Brachialis
4 Brachioradialis
5 Capitulum of humerus
6 Cephalic vein
7 Common flexor origin
8 Coronoid process of ulna
9 Extensor carpi radialis longus and brevis
10 Flexor carpi ulnaris
11 Fringe of synovial membrane
12 Lateral cutaneous nerve of forearm
13 Medial cutaneous nerve of forearm
14 Median basilic vein
15 Median cephalic vein
16 Median nerve
17 Posterior interosseous nerve
18 Pronator teres
19 Radial artery
20 Radial nerve
21 Tendon of biceps brachii
22 Trochlea of humerus
23 Ulnar artery
24 Ulnar nerve

Elbow arthroscopy, wrist arthroscopy, see pages 170–172.

Left cubital fossa A surface markings B superficial veins

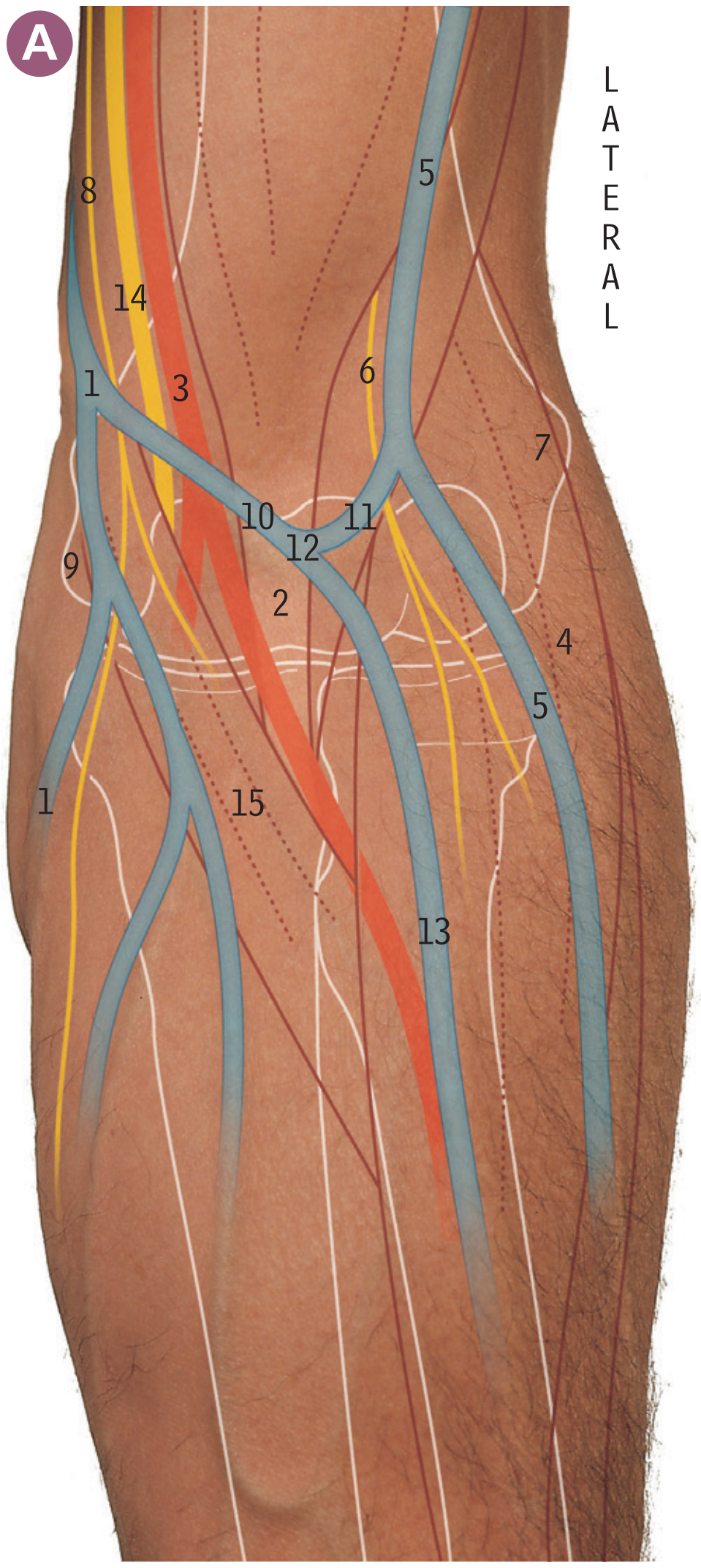

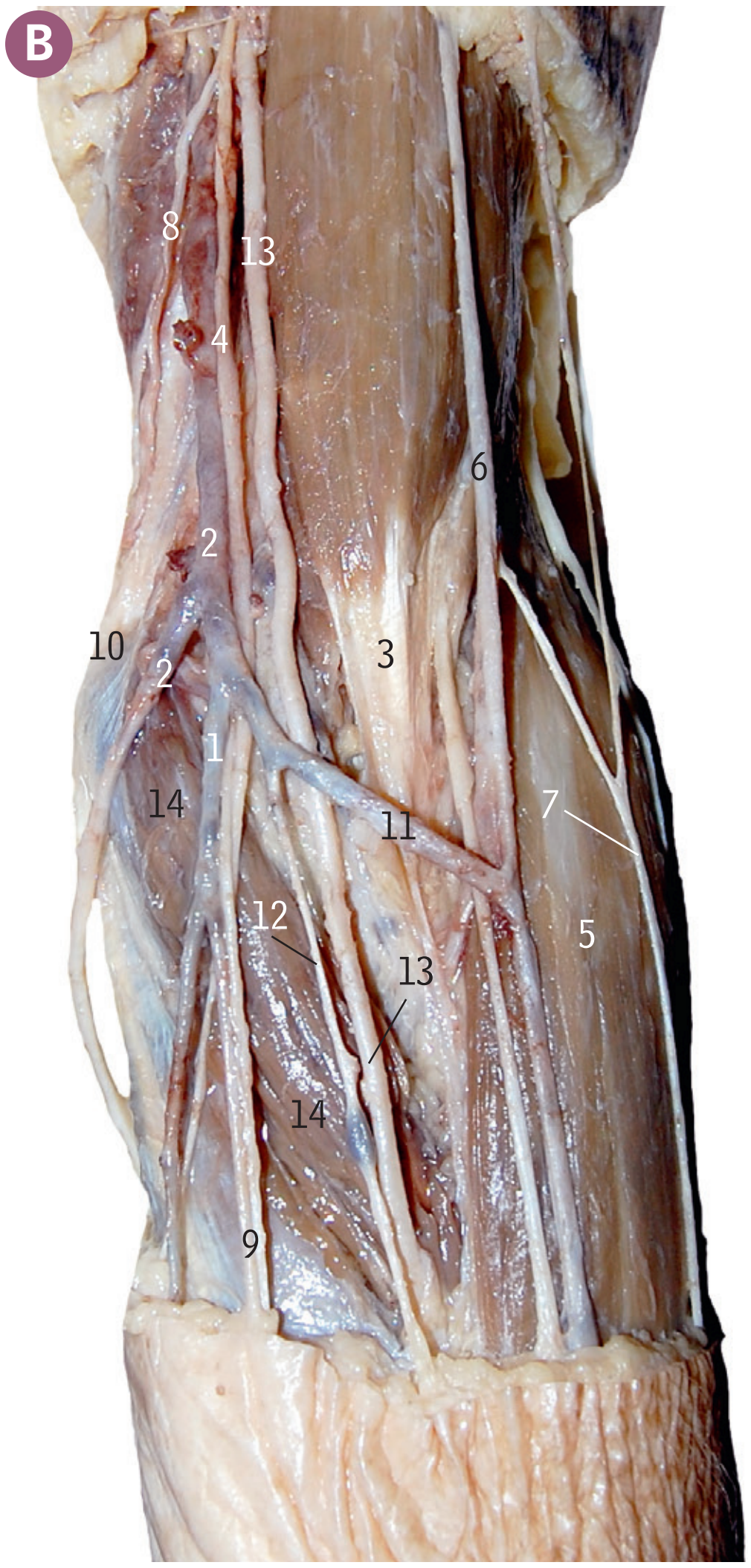

The superficial veins on the front of the elbow such as the cephalic (5) and basilic (1) and their intercommunicating tributaries are those most commonly used for intravenous injections and obtaining specimens of venous blood. The pattern of veins is typically M-shaped (as in A) or H-shaped (as in B), but there is much variation and it is not always possible or necessary to name every vessel.

The order of the structures in the cubital fossa from lateral to medial is: biceps tendon (2), brachial artery (3) and median nerve (14).

A

1 Basilic vein
2 Biceps tendon
3 Brachial artery
4 Brachioradialis
5 Cephalic vein
6 Lateral cutaneous nerve of forearm
7 Lateral epicondyle
8 Medial cutaneous nerve of forearm
9 Medial epicondyle
10 Median basilic vein
11 Median cephalic vein
12 Median cubital vein
13 Median forearm vein
14 Median nerve
15 Pronator teres

B

1 Accessory basilic vein
2 Basilic vein
3 Biceps brachii tendon
4 Brachial artery
5 Brachioradialis muscle
6 Cephalic vein
7 Lateral cutaneous nerve of forearm
8 Medial cutaneous nerve of arm
9 Medial cutaneous nerve of forearm
10 Medial epicondyle
11 Median cubital vein
12 Median forearm vein
13 Median nerve
14 Pronator teres muscle

Auscultation of the brachial pulse, biceps tendon reflex, golfer's elbow, tennis elbow, see pages 170–172.

Left elbow and upper forearm

C deeper dissection D deeper dissection of nerves and arteries

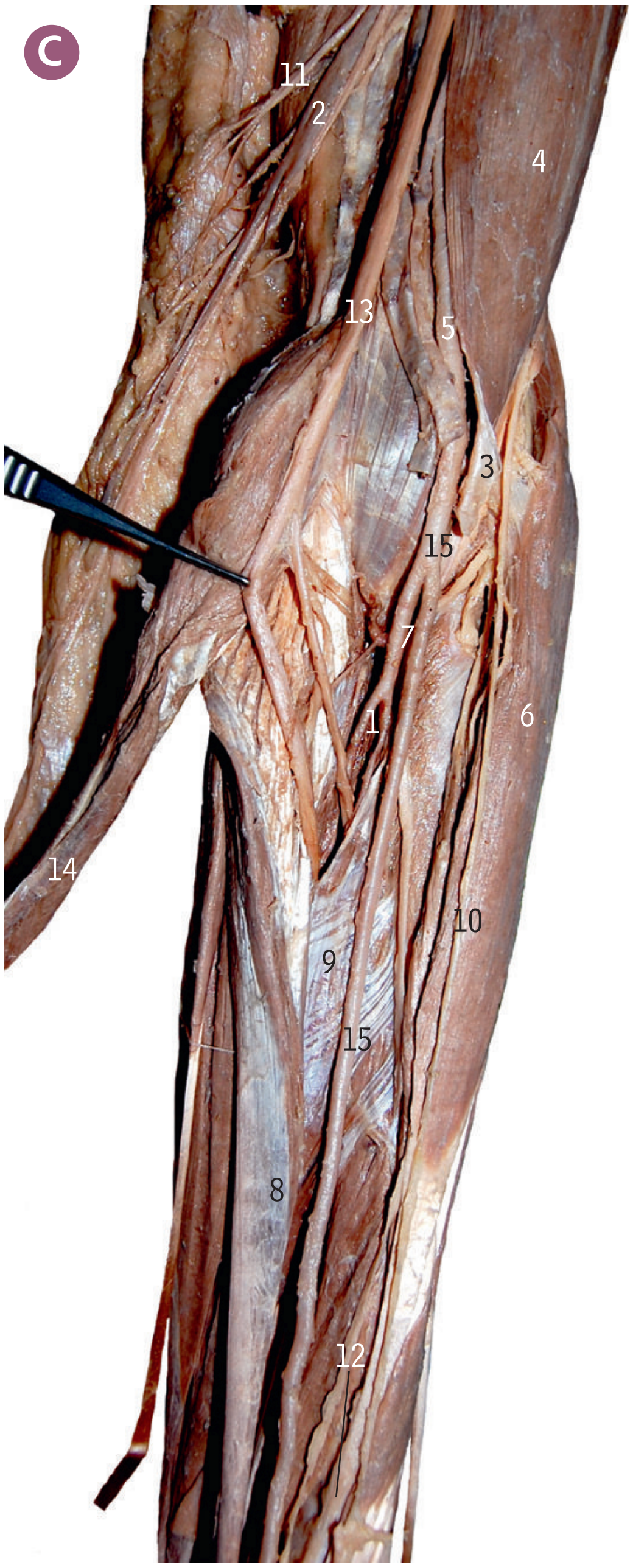

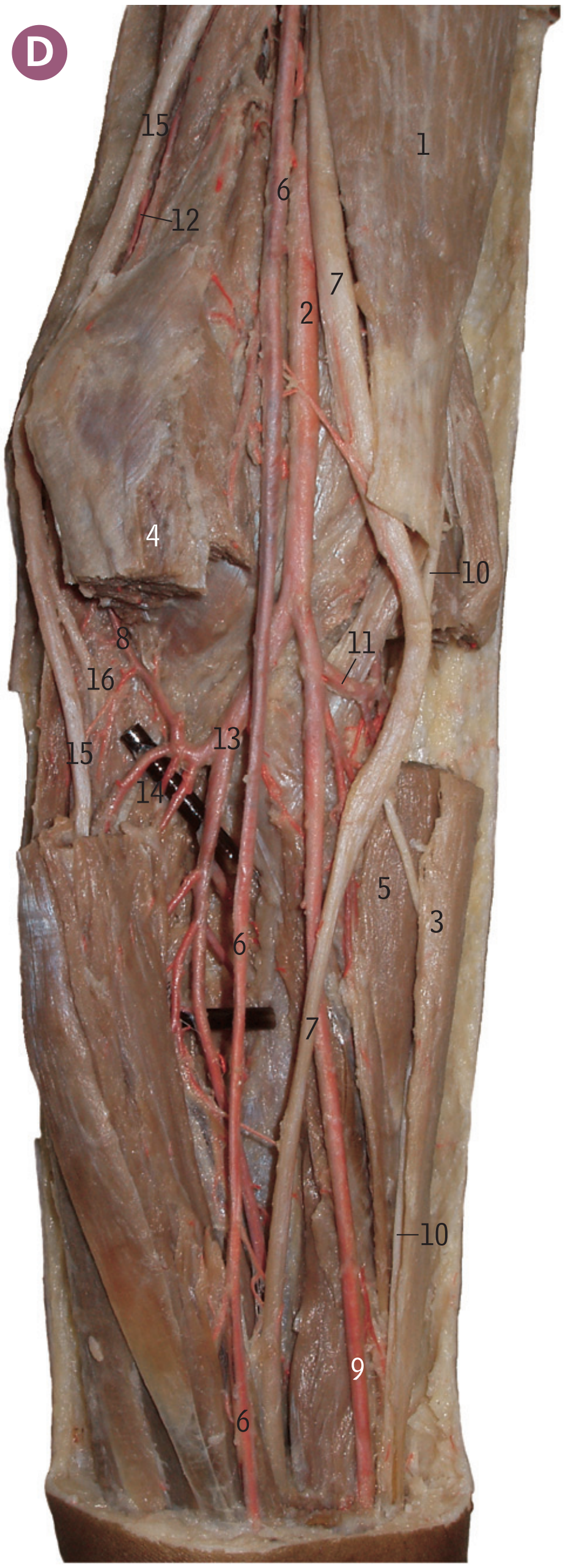

C

1. Anterior interosseous artery
2. Basilic vein
3. Biceps brachii aponeurosis, reflected
4. Biceps brachii muscle
5. Brachial artery
6. Brachioradialis muscle
7. Common interosseous artery
8. Flexor carpi ulnaris muscle
9. Flexor digitorum profundus muscle
10. Lateral cutaneous nerve of forearm
11. Medial cutaneous nerve of arm
12. Median nerve
13. Median nerve, reflected medially
14. Pronator teres muscle, reflected
15. Ulnar artery

D

1. Biceps
2. Brachial artery
3. Brachioradialis
4. Common flexor origin
5. Extensor carpi radialis longus
6. Median artery
7. Median nerve, pulled laterally
8. Posterior ulnar recurrent artery
9. Radial artery
10. Radial nerve, superficial branch
11. Radial recurrent artery
12. Superior ulnar collateral artery
13. Ulnar artery
14. Ulnar artery, branches to forearm flexors
15. Ulnar nerve
16. Ulnar nerve, branch to flexor carpi ulnaris

Note: high division and persistent median artery

Anterior interosseous nerve entrapment, arterial puncture at the elbow, see pages 170–172.



E Left forearm *superficial muscles, from the front*

Skin and fascia have been removed, but the larger superficial veins (1, 6 and 13) have been preserved. On the lateral side, the radial artery (21) is largely covered by brachioradialis (5). At the wrist the tendon of flexor carpi radialis (8) has the radial artery (21) on its lateral side; on its medial side is the median nerve (15), slightly overlapped from the medial side by the tendon of palmaris longus (18) (if present; it is absent in 13% of forearms).

1 Basilic vein
2 Biceps tendon
3 Bicipital aponeurosis
4 Brachial artery
5 Brachioradialis
6 Cephalic vein
7 Common flexor origin
8 Flexor carpi radialis
9 Flexor carpi ulnaris
10 Flexor digitorum superficialis
11 Flexor pollicis longus
12 Medial epicondyle
13 Median cubital vein
14 Median forearm vein
15 Median nerve
16 Palmar branch of median nerve
17 Palmar branch of ulnar nerve
18 Palmaris longus
19 Pronator quadratus
20 Pronator teres
21 Radial artery
22 Ulnar artery
23 Ulnar nerve

F Left forearm *deep muscles, from the front*

All vessels and nerves have been removed, together with the superficial muscles, to show the deep flexor group – flexor digitorum profundus (10), flexor pollicis longus (11) and pronator quadratus (13).

1 Abductor pollicis longus
2 Biceps
3 Brachialis
4 Brachioradialis
5 Common flexor origin
6 Extensor carpi radialis brevis
7 Extensor carpi radialis longus
8 Flexor carpi radialis
9 Flexor carpi ulnaris
10 Flexor digitorum profundus
11 Flexor pollicis longus
12 Flexor retinaculum
13 Pronator quadratus
14 Pronator teres
15 Supinator

Venepuncture of the upper limb, venous cutdown, see pages 170–172.

A Right cubital fossa and forearm *arteries*

The arteries have been injected, and after removal of most of the superficial muscles, the brachial artery (4) is seen dividing into the radial artery (18) and the ulnar artery (20). The radial artery gives off the radial recurrent (19) which runs upwards in front of supinator, giving branches to the carpal extensor muscles (10 and 9). The ulnar artery gives off the anterior and posterior ulnar recurrent vessels (2 and 15), and its common interosseous branch (8) is seen giving off the anterior interosseous (1) which passes down in front of the interosseous membrane between flexor pollicis longus (13) and flexor digitorum profundus (12).

1 Anterior interosseous artery overlying interosseous membrane
2 Anterior ulnar recurrent artery
3 Biceps tendon
4 Brachial artery
5 Brachialis
6 Brachioradialis
7 Common flexor origin
8 Common interosseous artery
9 Extensor carpi radialis brevis
10 Extensor carpi radialis longus
11 Flexor carpi ulnaris
12 Flexor digitorum profundus
13 Flexor pollicis longus
14 Medial epicondyle of humerus
15 Posterior ulnar recurrent artery
16 Pronator quadratus
17 Pronator teres
18 Radial artery
19 Radial recurrent artery overlying supinator
20 Ulnar artery

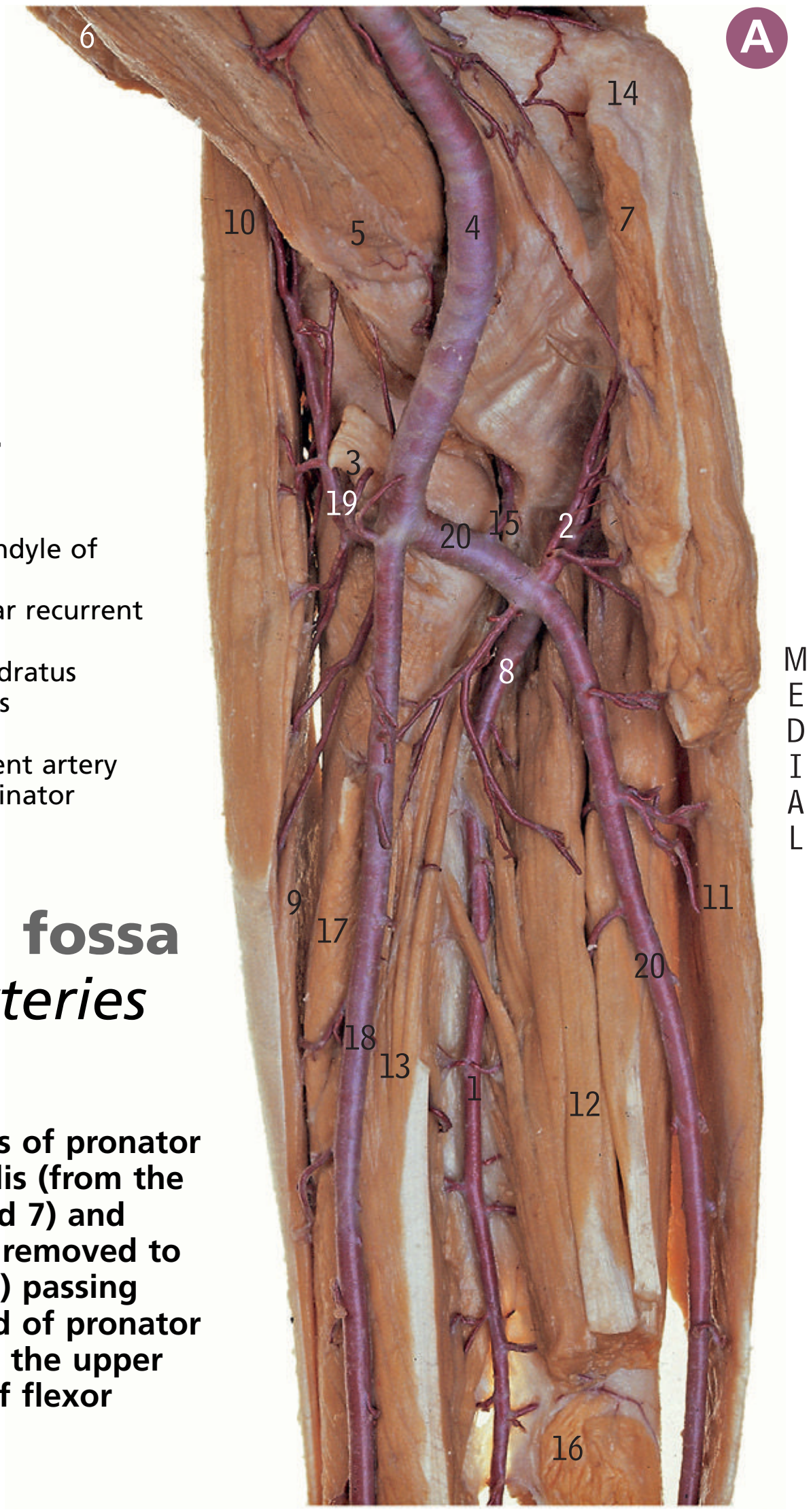

MEDIAL

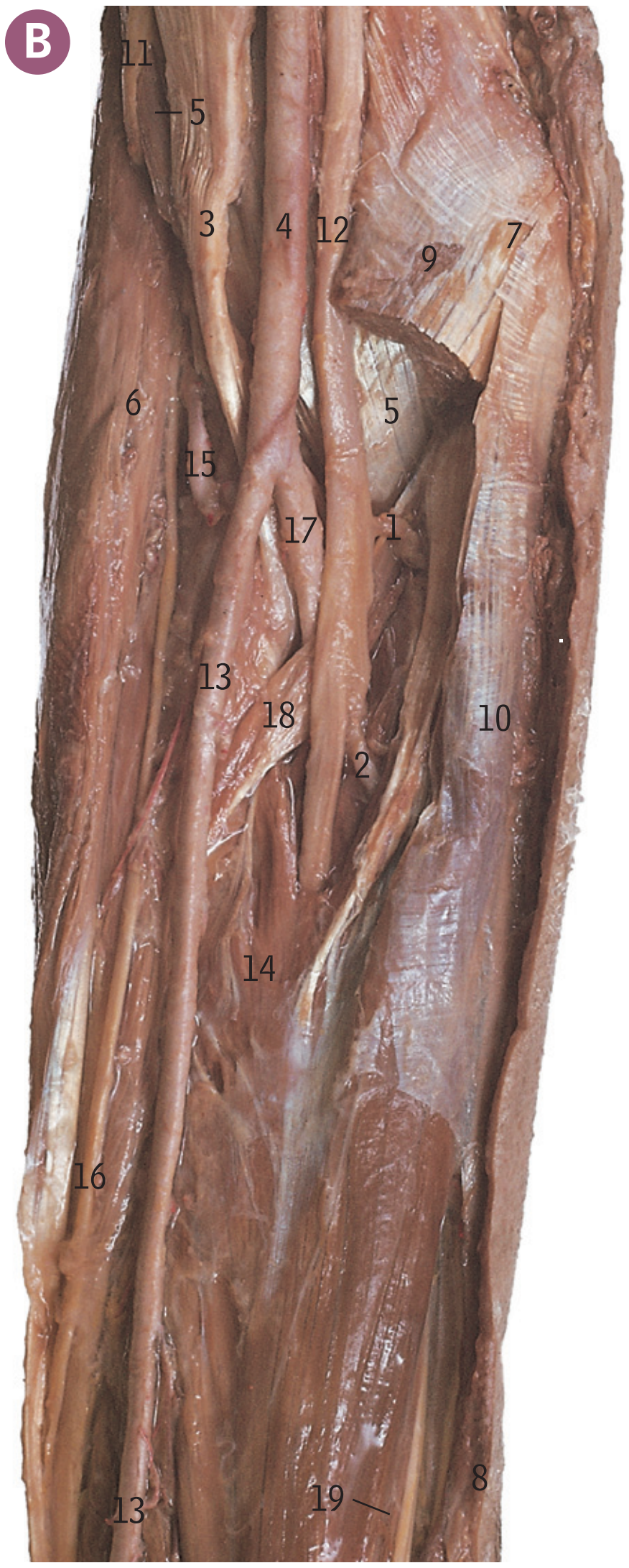

MEDIAL

B Right cubital fossa and forearm *arteries and nerves*

Most of the humeral origins of pronator teres and flexor carpi radialis (from the common flexor origin, 9 and 7) and palmaris longus have been removed to show the median nerve (12) passing superficial to the deep head of pronator teres (18) and then deep to the upper border of the radial head of flexor digitorum superficialis (14).

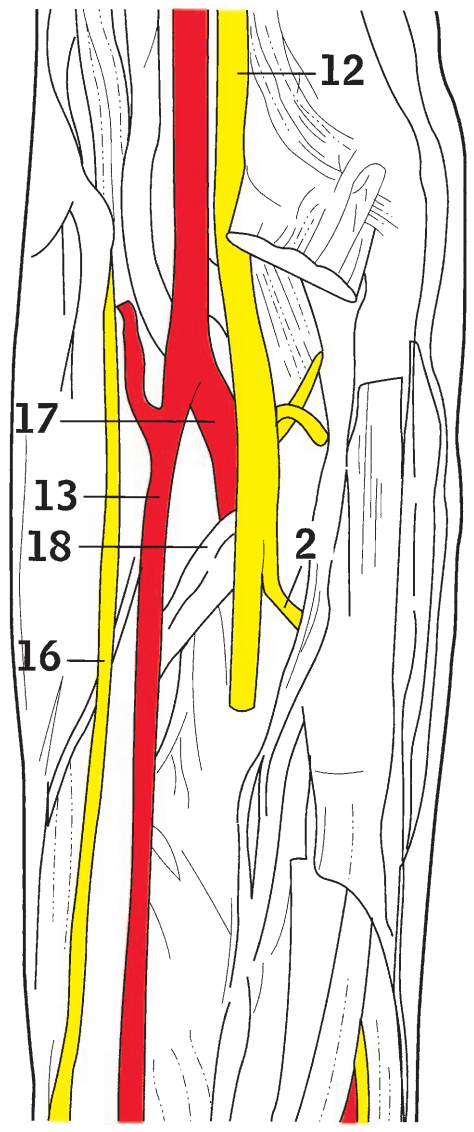

1 A muscular branch of median nerve
2 Anterior interosseous nerve
3 Biceps
4 Brachial artery
5 Brachialis
6 Brachioradialis (displaced laterally)
7 Common flexor origin
8 Flexor carpi ulnaris (displaced medially)
9 Humeral head of pronator teres
10 Humero-ulnar head of flexor digitorum superficialis
11 Lateral cutaneous nerve of forearm
12 Median nerve
13 Radial artery
14 Radial head of flexor digitorum superficialis
15 Radial recurrent artery
16 Superficial terminal branch of radial nerve overlying extensor carpi radialis longus
17 Ulnar artery
18 Ulnar head of pronator teres
19 Ulnar nerve and artery

Anterior interosseous nerve entrapment, Volkmann's ischaemic contracture, see pages 170–172.

Ⓐ Left elbow *from the lateral side*

With the forearm in mid-pronation and seen from the lateral side so that the radius (7) lies in front of the ulna, all muscles have been removed except supinator (8) to show its humeral and ulnar origins (see notes).

1. Annular ligament
2. Capitulum of humerus
3. Interosseous membrane
4. Lateral epicondyle
5. Posterior interosseous nerve
6. Radial collateral ligament
7. Radius
8. Supinator
9. Supinator crest of ulna

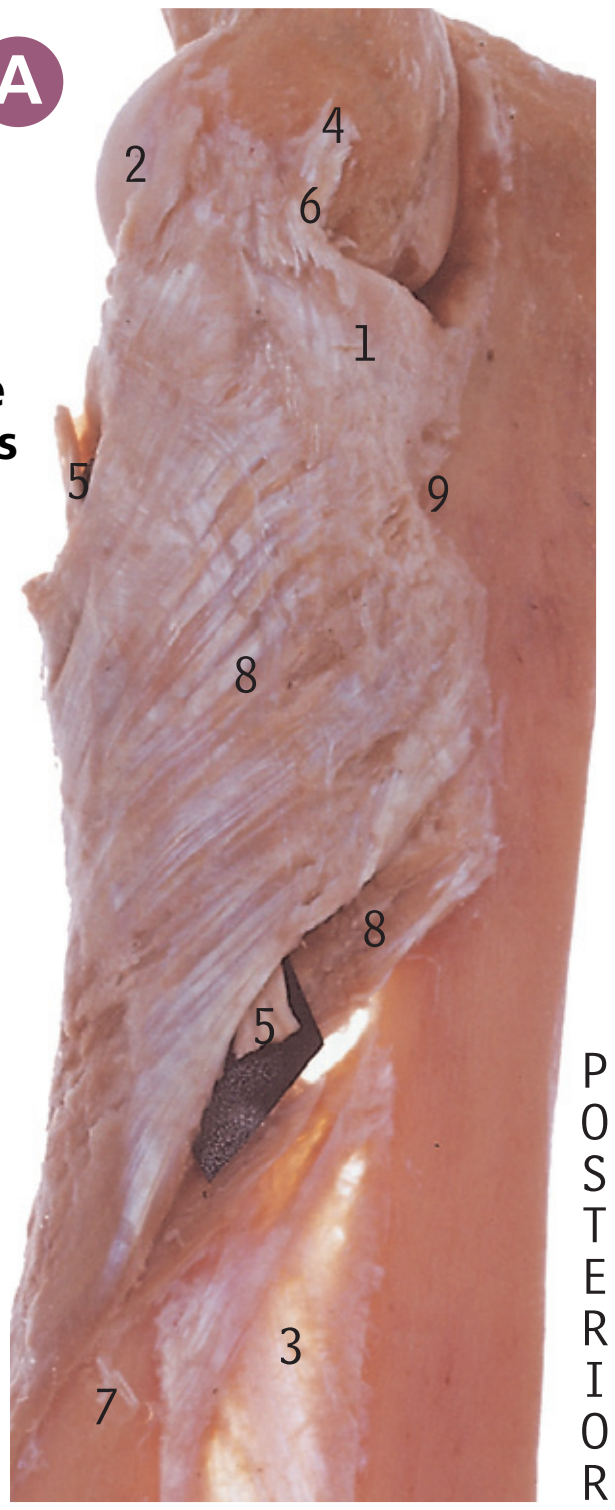

Ⓑ Left forearm *deep muscles, from the lateral side*

1. Abductor pollicis longus
2. Biceps brachii
3. Extensor carpi radialis brevis
4. Ext ensor carpi radialis longus (double)
5. Extensor indicis
6. Extensor pollicis brevis
7. Extensor pollicis longus
8. Extensor retinaculum
9. Flexor pollicis longus
10. Pronator teres
11. Supinator

Ⓒ Left forearm *posterior interosseous nerve, from behind*

1. Abductor pollicis longus
2. Branch of posterior interosseous artery
3. Extensor carpi radialis brevis
4. Extensor carpi radialis longus
5. Extensor carpi ulnaris
6. Extensor digitorum
7. Extensor indicis
8. Extensor pollicis brevis
9. Extensor pollicis longus
10. Extensor retinaculum
11. Posterior interosseous nerve
12. Supinator

The fibres of the interosseous membrane (A3) pass obliquely downwards from the radius (A7) to the ulna, so transmitting weight from the hand and radius to the ulna.

The supinator muscle (A8) arises from the lateral epicondyle of the humerus (A4), radial collateral ligament (A6), annular ligament (A1), supinator crest of the ulna (A9) and bone in front of the crest (page 119, D10), and an aponeurosis overlying the muscle. From these origins, the fibres wrap themselves round the upper end of the radius above the pronator teres attachment, to be attached to the lateral surface of the radius and extending anteriorly and posteriorly as far as the tuberosity of the radius.

Posterior interosseous nerve entrapment, see *pages 170–172.*

D

E

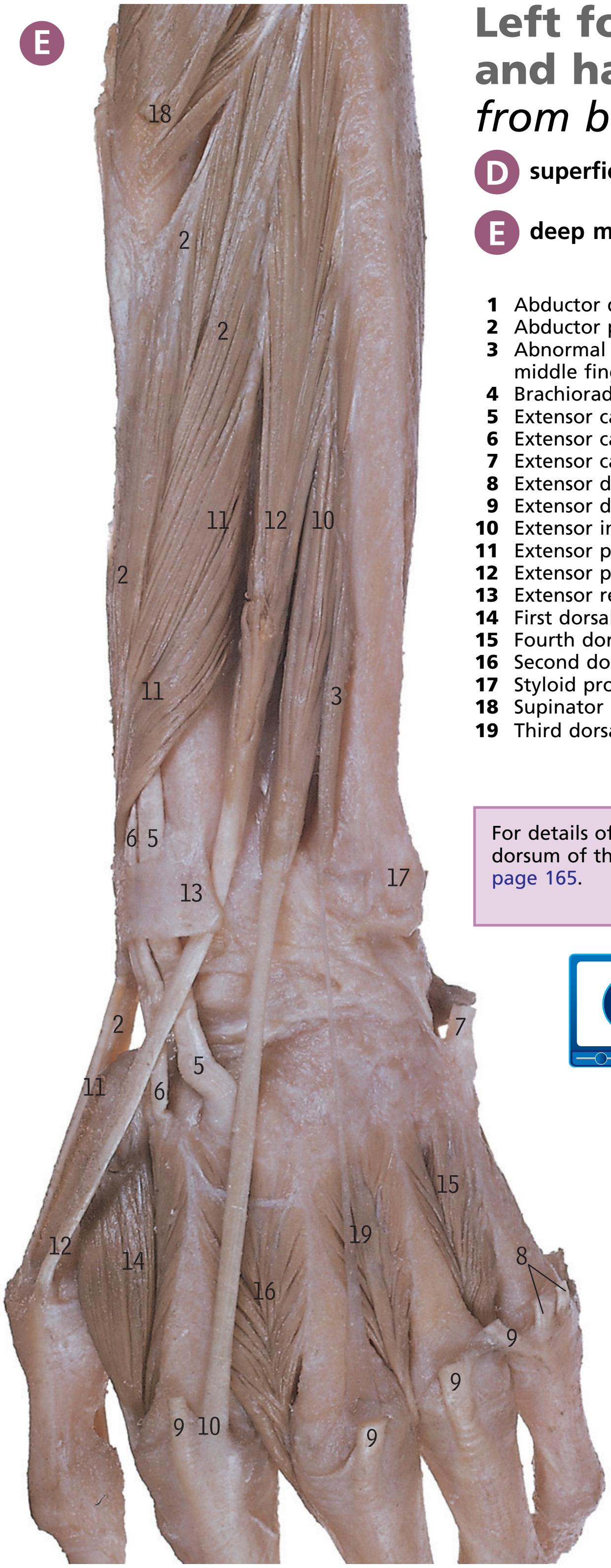

Left forearm and hand *from behind*

D superficial muscles

E deep muscles

1 Abductor digiti minimi
2 Abductor pollicis longus
3 Abnormal slip of 10 to middle finger
4 Brachioradialis
5 Extensor carpi radialis brevis
6 Extensor carpi radialis longus
7 Extensor carpi ulnaris
8 Extensor digiti minimi
9 Extensor digitorum
10 Extensor indicis
11 Extensor pollicis brevis
12 Extensor pollicis longus
13 Extensor retinaculum
14 First dorsal interosseous
15 Fourth dorsal interosseous
16 Second dorsal interosseous
17 Styloid process of ulna
18 Supinator
19 Third dorsal interosseous

For details of tendons on the dorsum of the hand, see page 165.

De Quervain's disease, wrist drop, see pages 170–172.

A Palm of left hand

1. Abductor digiti minimi
2. Abductor pollicis brevis
3. Adductor pollicis
4. Distal transverse crease
5. Distal wrist crease
6. Flexor carpi radialis
7. Flexor carpi ulnaris
8. Flexor digiti minimi brevis
9. Flexor pollicis brevis
10. Head of metacarpal
11. Hook of hamate
12. Level of deep palmar arch
13. Level of superficial palmar arch
14. Longitudinal crease
15. Median nerve
16. Middle wrist crease
17. Palmaris brevis
18. Palmaris longus
19. Pisiform
20. Proximal transverse crease
21. Proximal wrist crease
22. Radial artery
23. Thenar eminence
24. Ulnar artery and nerve

A

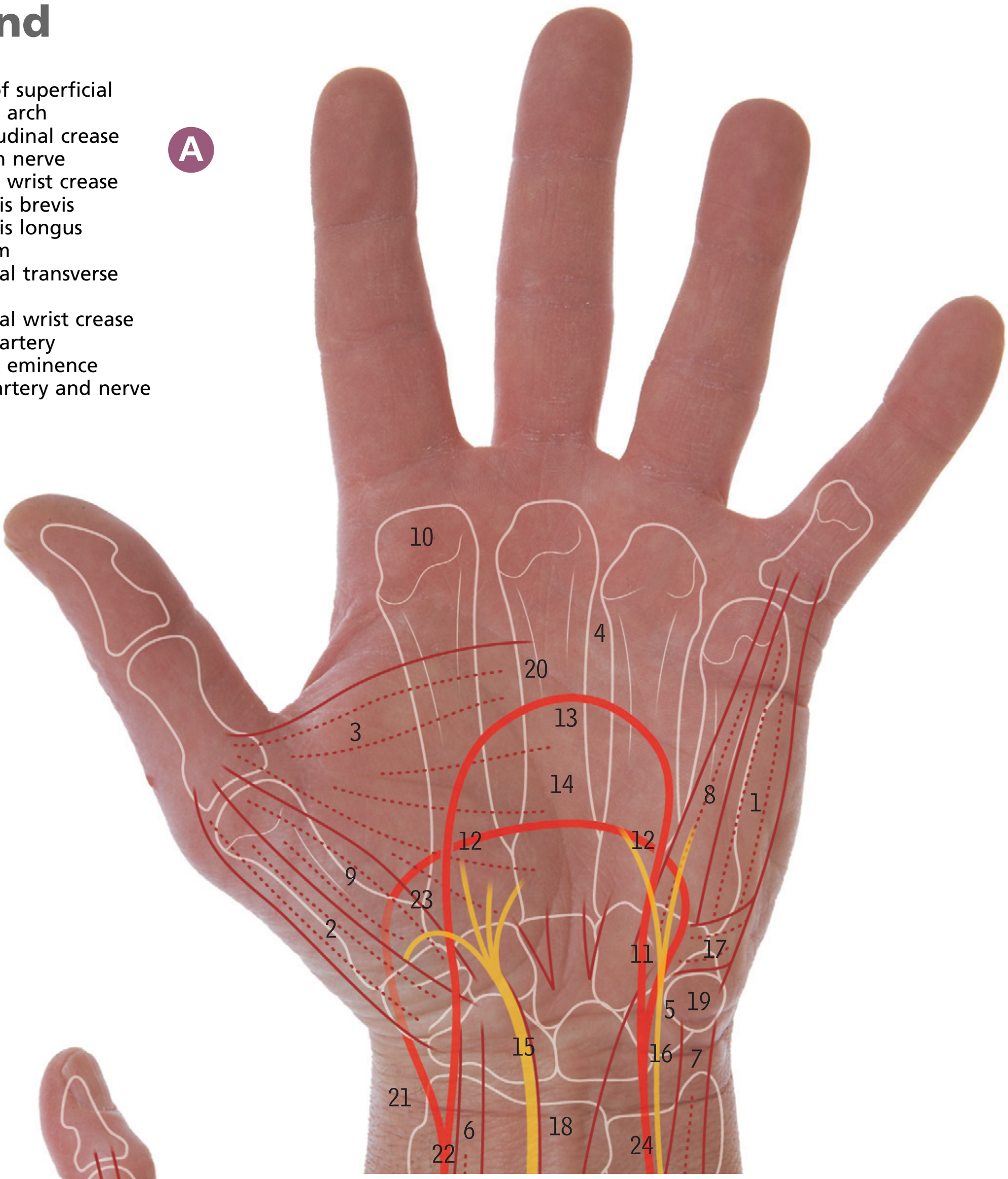

B

B Dorsum of left hand

The fingers are extended at the metacarpophalangeal joints, causing the extensor tendons of the fingers (2, 3 and 4) to stand out, and partially flexed at the interphalangeal joints. The thumb is extended at the carpometacarpal joint and partially flexed at the metacarpophalangeal and interphalangeal joints. The lines proximal to the bases of the fingers indicate the ends of the heads of the metacarpals and the level of the metacarpophalangeal joints. The anatomical snuffbox (1) is the hollow between the tendons of abductor pollicis longus and extensor pollicis brevis (5) laterally and extensor pollicis longus (6) medially.

1. Anatomical snuffbox
2. Extensor digiti minimi
3. Extensor digitorum
4. Extensor indicis
5. Extensor pollicis brevis and abductor pollicis longus
6. Extensor pollicis longus
7. Extensor retinaculum
8. First dorsal interosseous
9. Head of ulna
10. Styloid process of radius

Fingers *movements*

A **flexion of the metacarpophalangeal joints and flexion of the interphalangeal joints**

B **extension of the metacarpophalangeal joints and flexion of the interphalangeal joints**

C **extension of the metacarpophalangeal and interphalangeal joints**

When 'making a fist' with all finger joints flexed (A), the heads of the metacarpals (6) form the knuckles. To extend the metacarpophalangeal joints (B9) requires the activity of the long extensor tendons of the fingers, but to extend the interphalangeal joints (C10 and 5) as well requires the activity of the interossei and lumbricals, pulling on the dorsal extensor expansions. Only if the metacarpophalangeal joints remain flexed can the long extensors extend the interphalangeal joints.

1. Base of distal phalanx
2. Base of metacarpal
3. Base of middle phalanx
4. Base of proximal phalanx
5. Distal interphalangeal joint
6. Head of metacarpal
7. Head of middle phalanx
8. Head of proximal phalanx
9. Metacarpophalangeal joint
10. Proximal interphalangeal joint

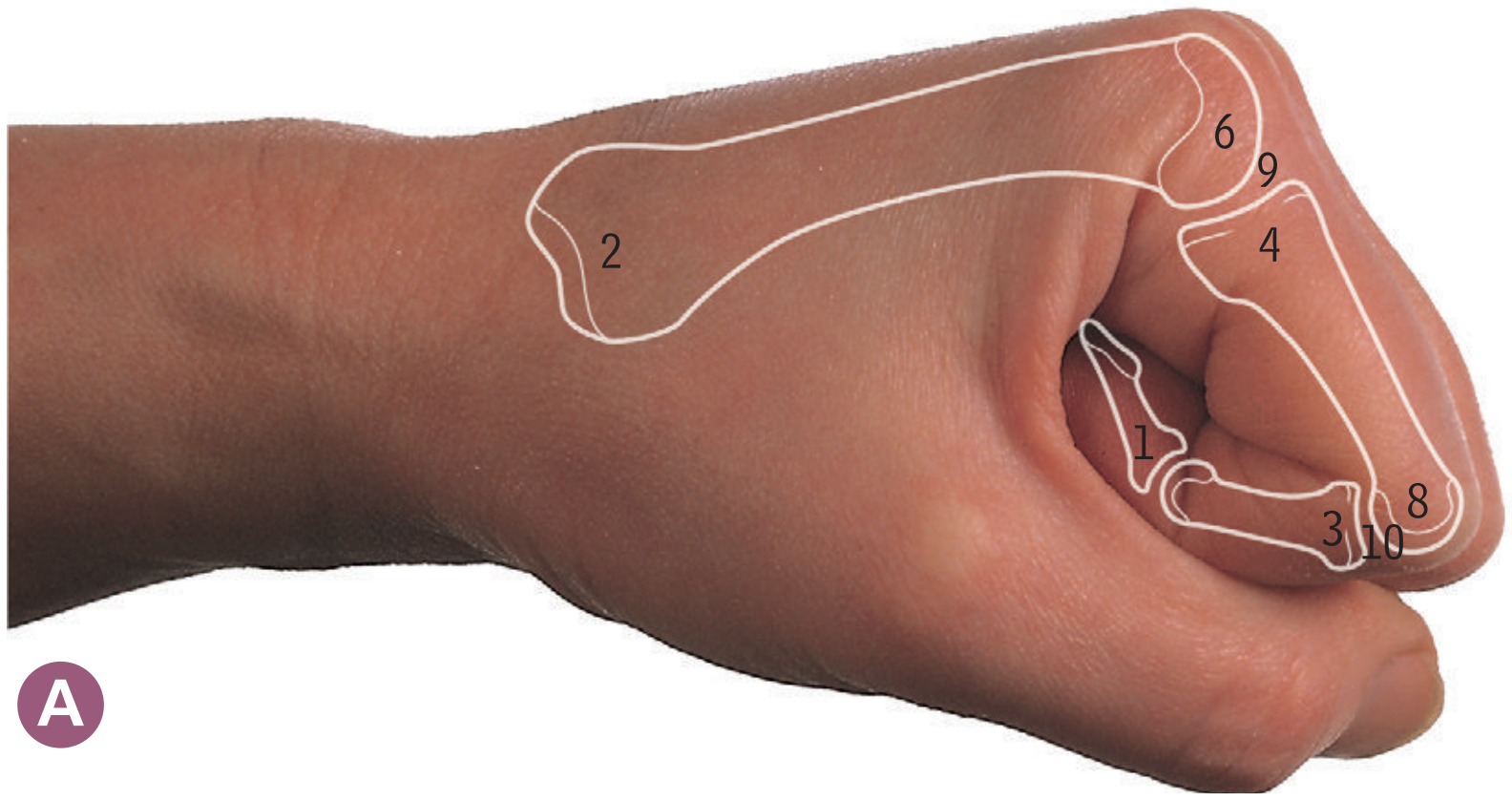

A

A Muscles producing movements at the metacarpophalangeal joints

Flexion: flexor digitorum profundus, flexor digitorum superficialis, lumbricals, interossei, with flexor digiti minimi brevis for the little finger and flexor pollicis longus, flexor pollicis brevis and the first palmar interosseous for the thumb.

Extension: extensor digitorum, extensor indicis (index finger) and extensor digiti minimi (little finger), with extensor pollicis longus and extensor pollicis brevis for the thumb.

Adduction: palmar interossei; when flexed, the long flexors assist.

Abduction: dorsal interossei and the long extensors, with abductor digiti minimi for the little finger.

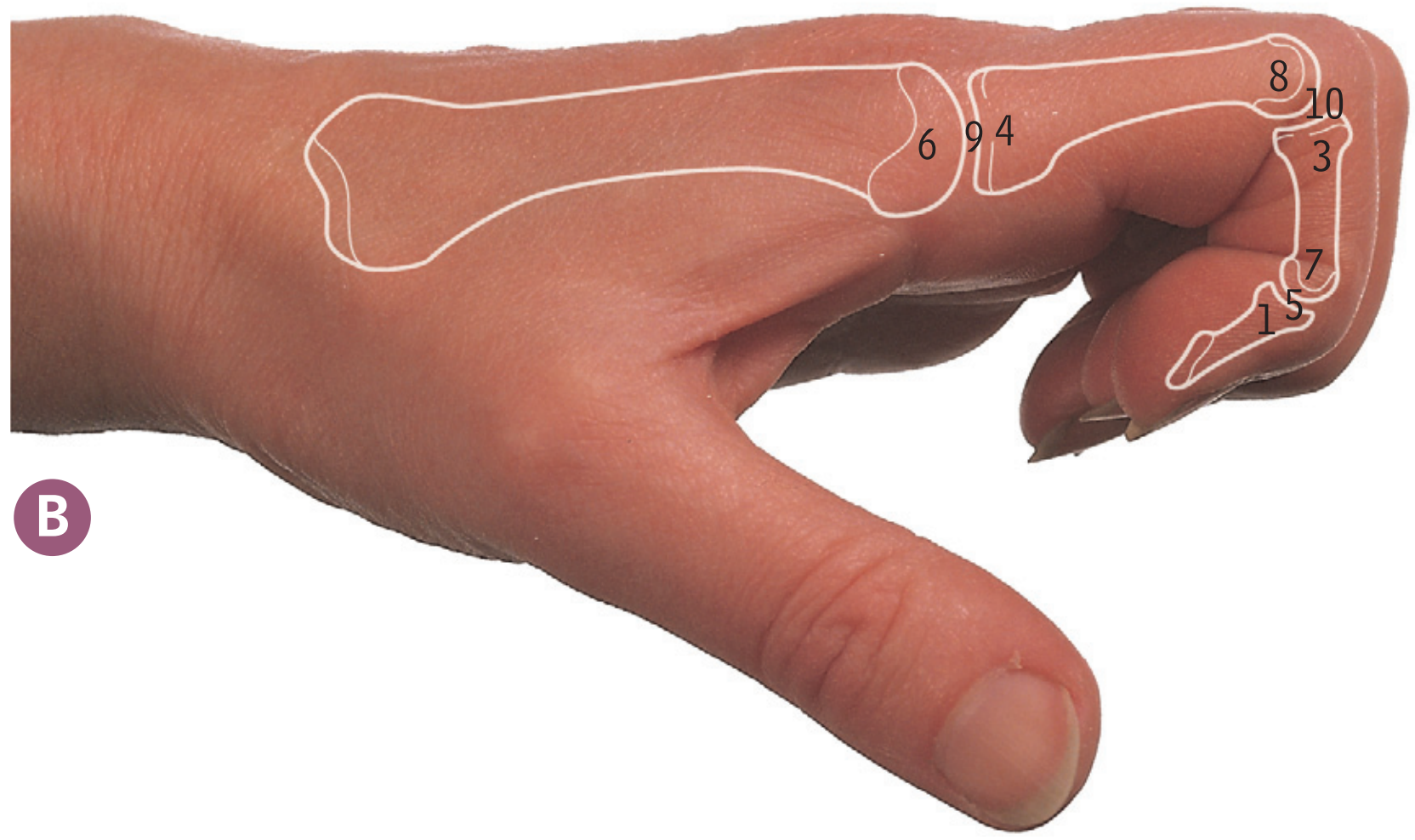

B

B Muscles producing movements at the interphalangeal joints

Flexion: at the proximal joints, flexor digitorum superficialis and flexor digitorum profundus; at the distal joints, flexor digitorum profundus. For the thumb, flexor pollicis longus.

Extension: with the metacarpophalangeal joints flexed, extensor digitorum, extensor indicis and extensor digiti minimi; with the metacarpophalangeal joints extended, interossei and lumbricals. For the thumb, extensor pollicis longus.

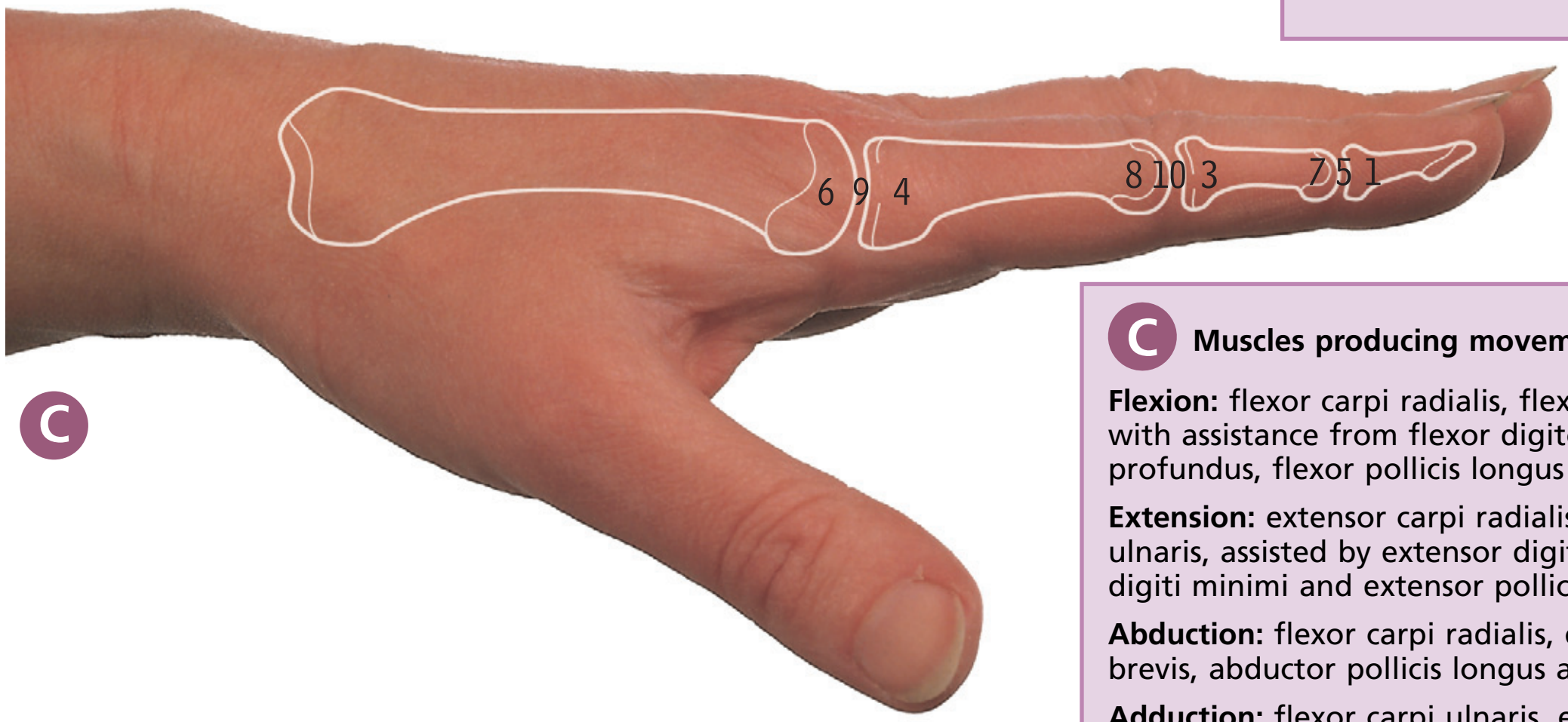

C

C Muscles producing movements at the wrist joint

Flexion: flexor carpi radialis, flexor carpi ulnaris, palmaris longus, with assistance from flexor digitorum superficialis, flexor digitorum profundus, flexor pollicis longus and abductor pollicis longus.

Extension: extensor carpi radialis longus and brevis, extensor carpi ulnaris, assisted by extensor digitorum, extensor indicis, extensor digiti minimi and extensor pollicis longus.

Abduction: flexor carpi radialis, extensor carpi radialis longus and brevis, abductor pollicis longus and extensor pollicis brevis.

Adduction: flexor carpi ulnaris, extensor carpi ulnaris.

Thumb *movements*

A **in the anatomical position**

B **in flexion**

C **in extension**

D **in abduction**

E **in opposition**

With the thumb in the anatomical position (A), the thumb nail is at right angles to the fingers because the first metacarpal is at right angles to the others (pages 123–124). This is a rather artificial position; in the normal position of rest, the thumb makes an angle of about 60° with the plane of the palm (i.e. it is partially abducted). Flexion (B) means bending the thumb across the palm, keeping the phalanges at right angles to the palm. Extension (C) is the opposite movement, away from the palm. In abduction (D) the thumb is lifted forwards from the plane of the palm, and continuation of this movement inevitably leads to opposition (E), with rotation of the first metacarpal, twisting the whole digit so that the pulp of the thumb can be brought towards the palm at the base of the little finger (or more commonly in everyday use, to contact or overlap any of the flexed fingers). Opposition is a combination of abduction with flexion and medial rotation at the carpometacarpal joint; it is not necessarily accompanied by flexion at the other thumb joints.

Muscles producing movements at the carpometacarpal joint of the thumb

Flexion: flexor pollicis brevis, opponens pollicis, and (when the other thumb joints are flexed) flexor pollicis longus.

Extension: abductor pollicis longus, extensor pollicis longus, extensor pollicis brevis.

Abduction: abductor pollicis brevis, abductor pollicis longus.

Adduction: adductor pollicis.

Opposition: opponens pollicis, flexor pollicis brevis, reinforced by adductor pollicis and flexor pollicis longus.

Palm of left hand

A palmar aponeurosis

Removal of the palmar skin reveals the palmar aponeurosis.

B after removal of palmar aponeurosis

Deeper dissection of the palm reveals the flexor retinaculum, the palmar branches of the median and ulnar nerves and the superficial palmar arch, flanked by the muscles of the thenar and hypothenar eminences.

A

B

1 Abductor pollicis brevis
2 Abductor digiti minimi
3 Adductor pollicis
4 Aponeurosis, central part
5 Aponeurosis, digital slips
6 Flexor carpi radialis
7 Flexor carpi ulnaris
8 Flexor digiti minimi brevis
9 Flexor pollicis brevis
10 Flexor retinaculum
11 Lumbrical
12 Median nerve
13 Median nerve, palmar branch
14 Median nerve, recurrent branch
15 Palmar digital vessels and nerves
16 Palmaris brevis
17 Radial artery
18 Superficial palmar arch
19 Superficial transverse metacarpal ligaments
20 Synovial sheaths of flexor tendons
21 Ulnar artery
22 Ulnar nerve

CT 3D reconstruction to show flexor digitorum profundus tendons

Arteriovenous fistula, Dupuytren's contracture, see pages 170–172.

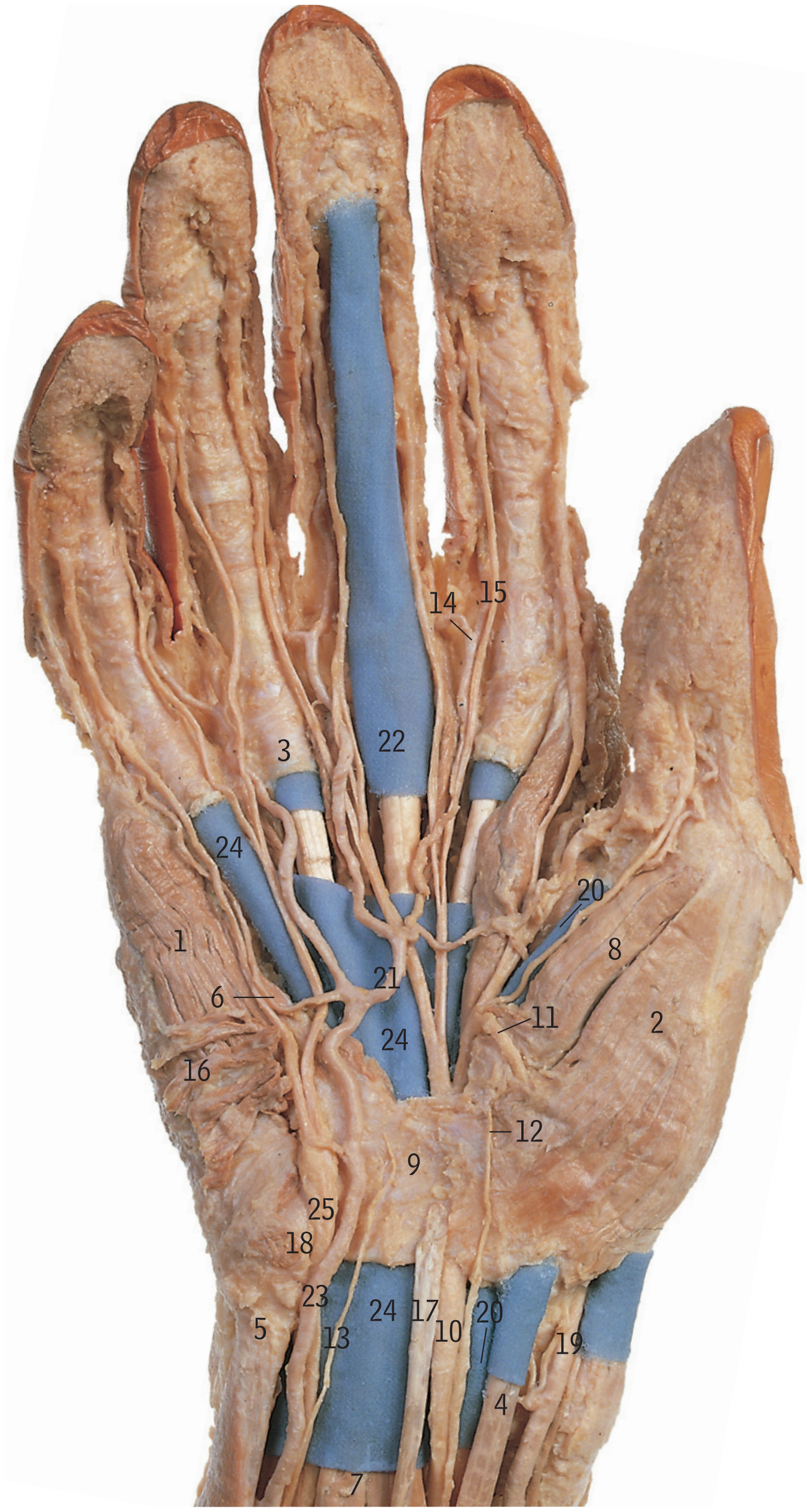

A Palm of right hand *with synovial sheaths*

The synovial sheaths of the wrist and fingers have been emphasised by blue tissue. On the middle finger, the fibrous flexor sheath has been removed (but retained on the other fingers, as at 3) to show the whole length of the synovial sheath (22). On the index and ring fingers, the synovial sheath projects slightly proximal to the fibrous sheath. The synovial sheath of the little finger is continuous with the sheath surrounding the finger flexor tendons under the flexor retinaculum (the ulnar bursa, 24), and the sheath of flexor pollicis longus is the radial bursa (20), which also continues under the retinaculum (9).

1 Abductor digiti minimi
2 Abductor pollicis brevis
3 Fibrous flexor sheath
4 Flexor carpi radialis
5 Flexor carpi ulnaris
6 Flexor digiti minimi brevis
7 Flexor digitorum superficialis
8 Flexor pollicis brevis
9 Flexor retinaculum
10 Median nerve
11 Muscular (recurrent) branch of median nerve
12 Palmar branch of median nerve
13 Palmar branch of ulnar nerve
14 Palmar digital artery
15 Palmar digital nerve
16 Palmaris brevis
17 Palmaris longus
18 Pisiform bone
19 Radial artery
20 Radial bursa and flexor pollicis longus
21 Superficial palmar arch
22 Synovial sheath
23 Ulnar artery
24 Ulnar bursa
25 Ulnar nerve

In the carpal tunnel (beneath the flexor retinaculum), one synovial sheath envelops the eight tendons of flexor digitorum superficialis and profundus (A24), another envelops the flexor pollicis longus tendon (A20), and flexor carpi radialis (in its own compartment of the flexor retinaculum) has its own sheath also (A4). The synovial sheaths for flexor carpi radialis and flexor pollicis longus extend as far as the tendon insertions.

The sheath of the long finger flexors is continuous with the digital synovial sheath of the little finger, but is *not* continuous with the digital synovial sheaths of the ring, middle or index fingers; these fingers have their own synovial sheaths whose proximal ends project slightly beyond the *fibrous* sheaths within which the digital *synovial* sheaths lie.

The muscular (recurrent) branch (A11) of the median nerve usually supplies abductor pollicis brevis, flexor pollicis brevis and opponens pollicis, but of all the muscles in the body flexor pollicis brevis (A8) is the one most likely to have an anomalous supply: in about one-third of hands by the median nerve, in another third by the ulnar nerve, and in the rest by both the median and ulnar nerves.

B Right index finger *long tendons, vincula and relations*

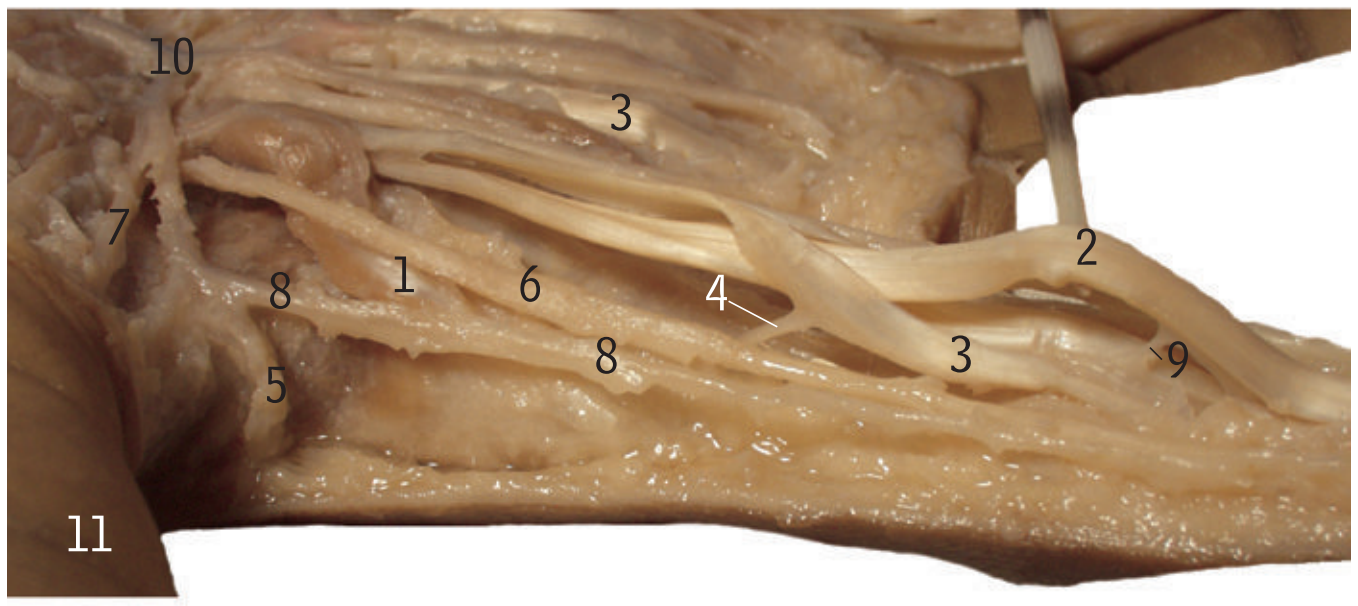

1 First lumbrical muscle
2 Flexor digitorum profundus
3 Flexor digitorum superficialis
4 Long vinculum of superficialis tendon
5 Metacarpal arterial branch
6 Palmar digital nerve
7 Princeps pollicis artery
8 Radialis indicis artery
9 Short vinculum of profundus tendon
10 Superficial palmar arterial arch
11 Thumb

Digital nerve block, hand infections, mallet finger, see pages 170–172.

Left wrist and hand

A palmar surface B axial MR image

A

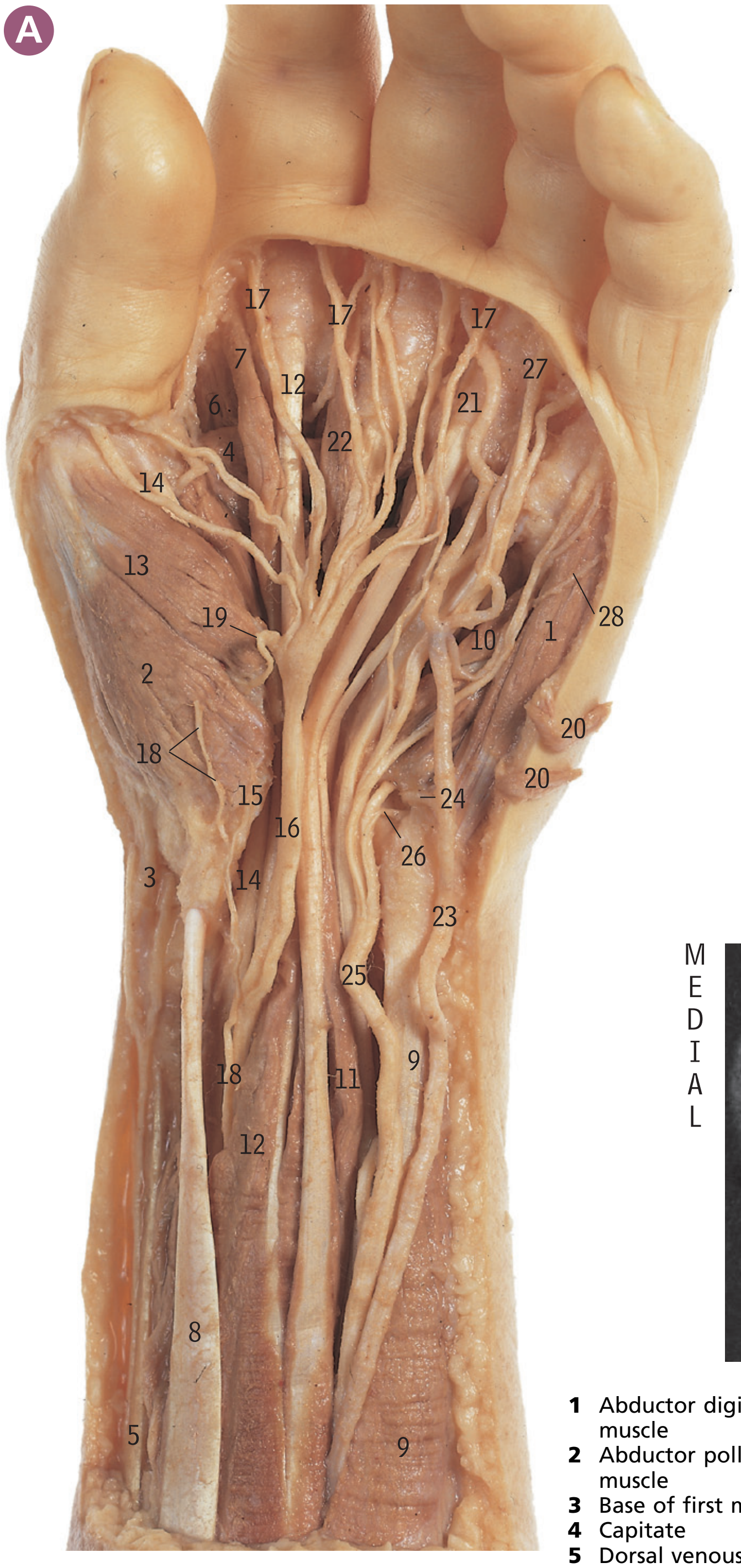

Parts of the fibrous flexor sheaths of the fingers (A21) have also been excised to show the contained tendons of flexor digitorum superficialis (A12) and flexor digitorum profundus (A11). In the palm, the lumbrical muscles (A7 and 22) arise from the profundus tendons. Compare features in the MR image with the dissection.

1 Abductor digiti minimi
2 Abductor pollicis brevis
3 Abductor pollicis longus
4 Adductor pollicis
5 Brachioradialis
6 First dorsal interosseous
7 First lumbrical
8 Flexor carpi radialis
9 Flexor carpi ulnaris
10 Flexor digiti minimi brevis
11 Flexor digitorum profundus
12 Flexor digitorum superficialis
13 Flexor pollicis brevis
14 Flexor pollicis longus
15 Flexor retinaculum cut edge
16 Median nerve
17 Median nerve, digital branch
18 Median nerve, palmar cutaneous branch
19 Median nerve, recurrent branch
20 Palmaris brevis
21 Remaining parts of fibrous flexor sheath
22 Second lumbrical
23 Ulnar artery
24 Ulnar artery, deep branch
25 Ulnar nerve
26 Ulnar nerve, deep branch
27 Ulnar nerve, digital branch
28 Ulnar nerve, muscular branch

The lumbrical muscles have no bony attachments. They arise from the tendons of flexor digitorum profundus (A11) – the first and second (A7 and A22) from the tendons of the index and middle fingers respectively, and the third and fourth from adjacent sides of the middle and ring, and ring and little fingers respectively. Each is attached distally to the radial side of the dorsal digital expansion of each finger (page 166).

MEDIAL

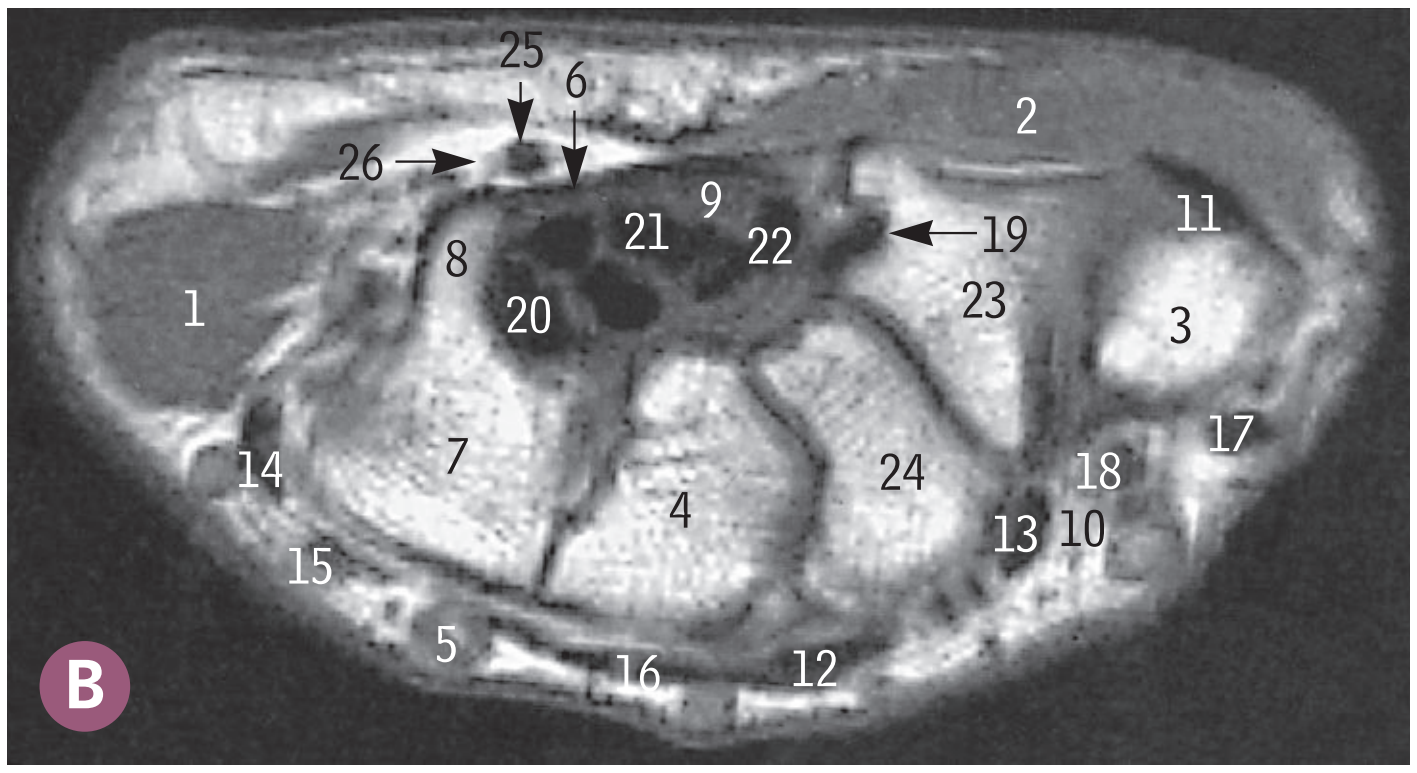

LATERAL

1 Abductor digiti minimi muscle
2 Abductor pollicis brevis muscle
3 Base of first metacarpal
4 Capitate
5 Dorsal venous arch
6 Flexor retinaculum
7 Hamate
8 Hook of hamate
9 Median nerve
10 Radial artery
11 Tendon of abductor pollicis longus muscle
12 Tendon of extensor carpi radialis brevis muscle
13 Tendon of extensor carpi radialis longus muscle
14 Tendon of extensor carpi ulnaris muscle
15 Tendon of extensor digiti minimi muscle
16 Tendon of extensor digitorum muscle
17 Tendon of extensor pollicis brevis muscle
18 Tendon of extensor pollicis longus muscle
19 Tendon of flexor carpi radialis muscle
20 Tendon of flexor digitorum profundus muscle
21 Tendon of flexor digitorum superficialis muscle
22 Tendon of flexor pollicis longus muscle
23 Trapezium
24 Trapezoid
25 Ulnar artery
26 Ulnar nerve

Carpal tunnel syndrome, median nerve palsy, see pages 170–172.

Superficial palmar arch

A *incomplete in the left hand*

B *complete in the right hand*

In two-thirds of hands, the superficial palmar arch is not complete (as in A29). In the other third, it is usually completed by the superficial palmar branch of the radial artery (B30).

In the palm the superficial arterial arch (29) and its branches (as at 1) lie superficial to the common palmar digital nerves (22 and 7), but on the fingers the palmar digital nerves (as at 3) lie superficial (anterior) to the palmar digital arteries (as at 2).

1 A common palmar digital artery
2 A palmar digital artery
3 A palmar digital nerve
4 Abductor digiti minimi
5 Abductor pollicis brevis
6 Abductor pollicis longus
7 Common palmar digital branch of ulnar nerve
8 Common origin of 28 and 26
9 Deep branch of ulnar artery
10 Deep branch of ulnar nerve
11 Deep palmar arch
12 First lumbrical
13 Flexor carpi radialis
14 Flexor carpi ulnaris and pisiform
15 Flexor digitorum profundus
16 Flexor digitorum superficialis
17 Flexor pollicis brevis
18 Flexor pollicis longus
19 Flexor retinaculum
20 Fourth lumbrical
21 Median nerve
22 Median nerve dividing into common palmar digital branches
23 Muscular (recurrent) branch of median nerve
24 Opponens digiti minimi
25 Palmaris brevis
26 Princeps pollicis artery
27 Radial artery
28 Radialis indicis artery
29 Superficial palmar arch
30 Superficial palmar branch of radial artery
31 Ulnar artery
32 Ulnar nerve

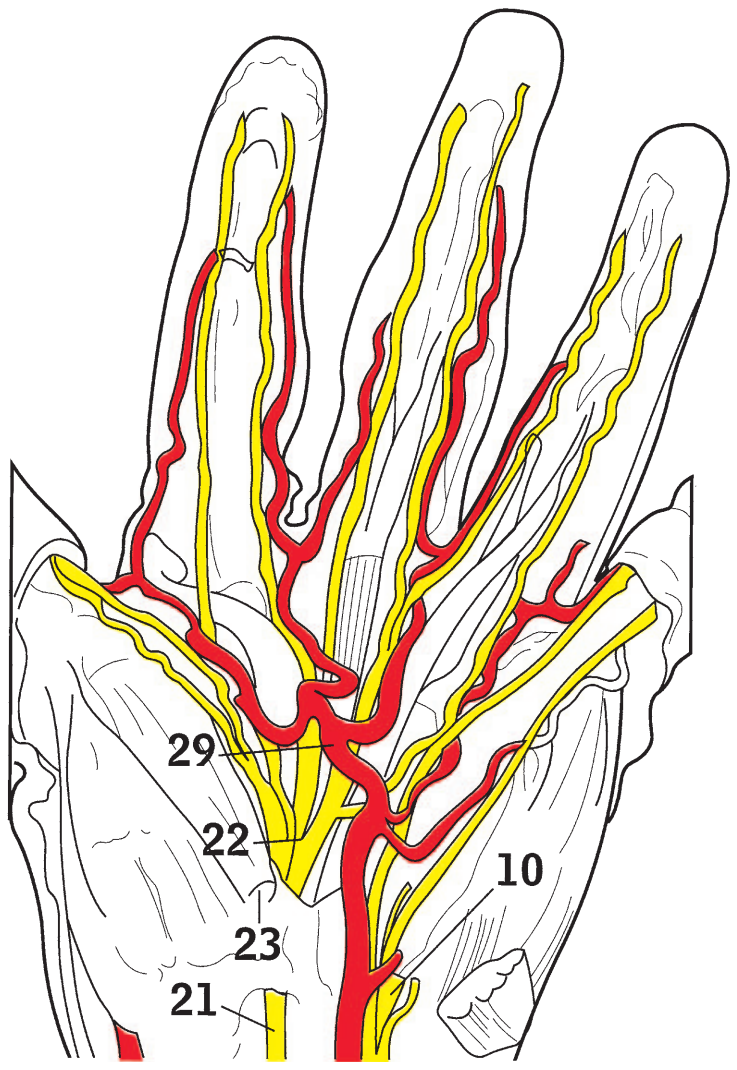

A

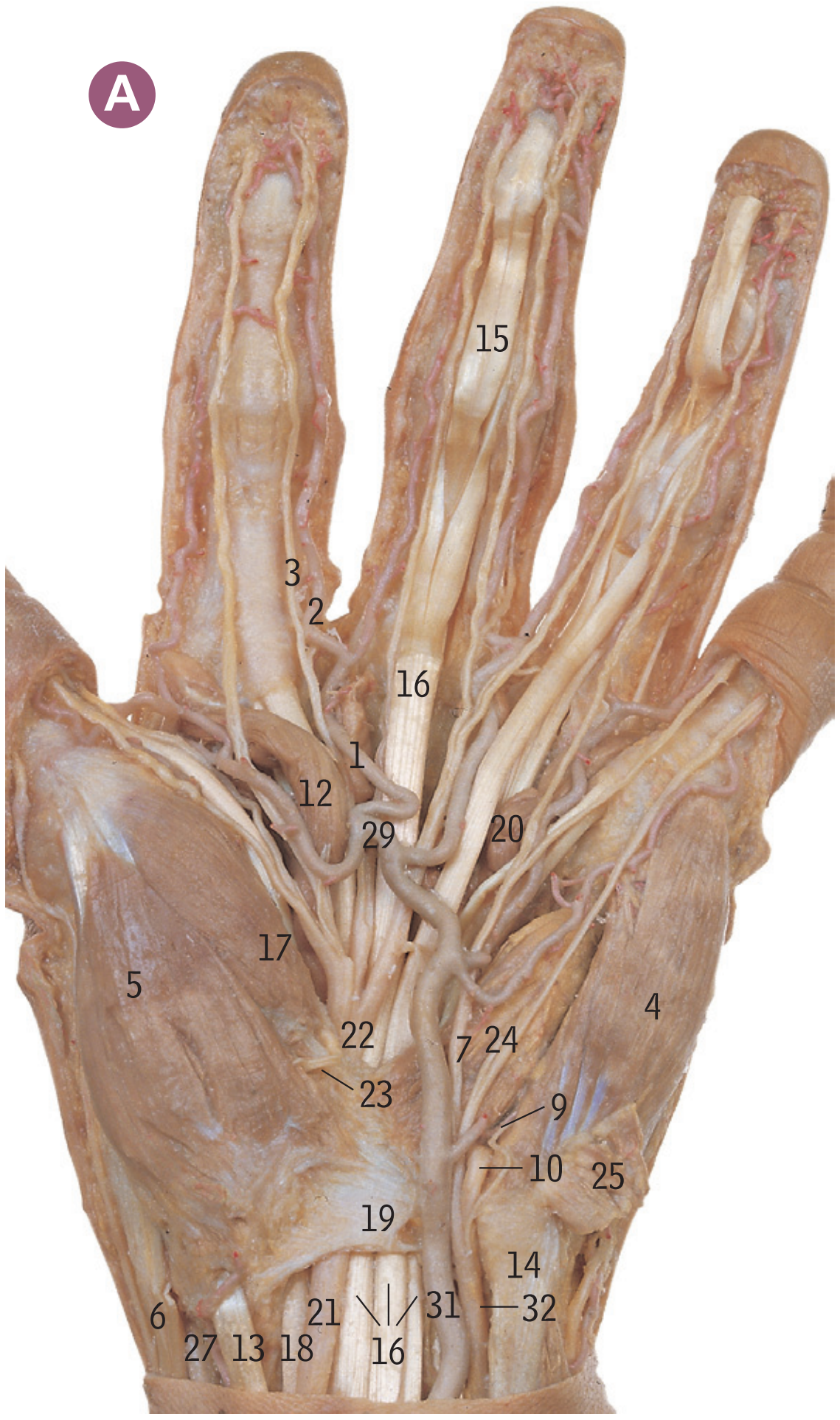

B

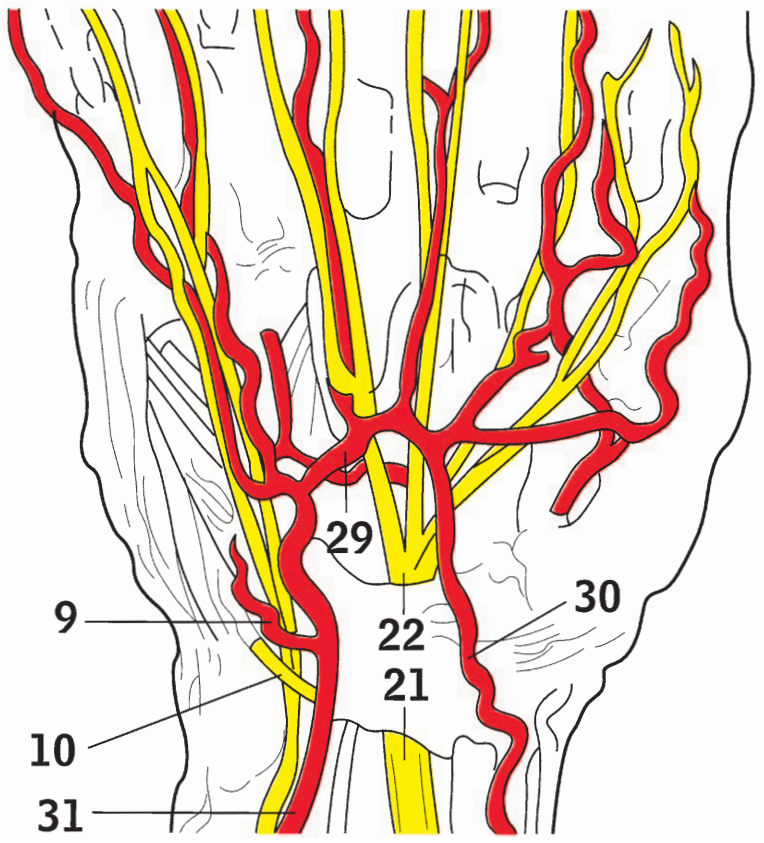

Arterial puncture at the wrist, Guyon's canal syndrome, see pages 170–172.

Palm of right hand

C deep palmar arch D arteriogram of palmar arteries

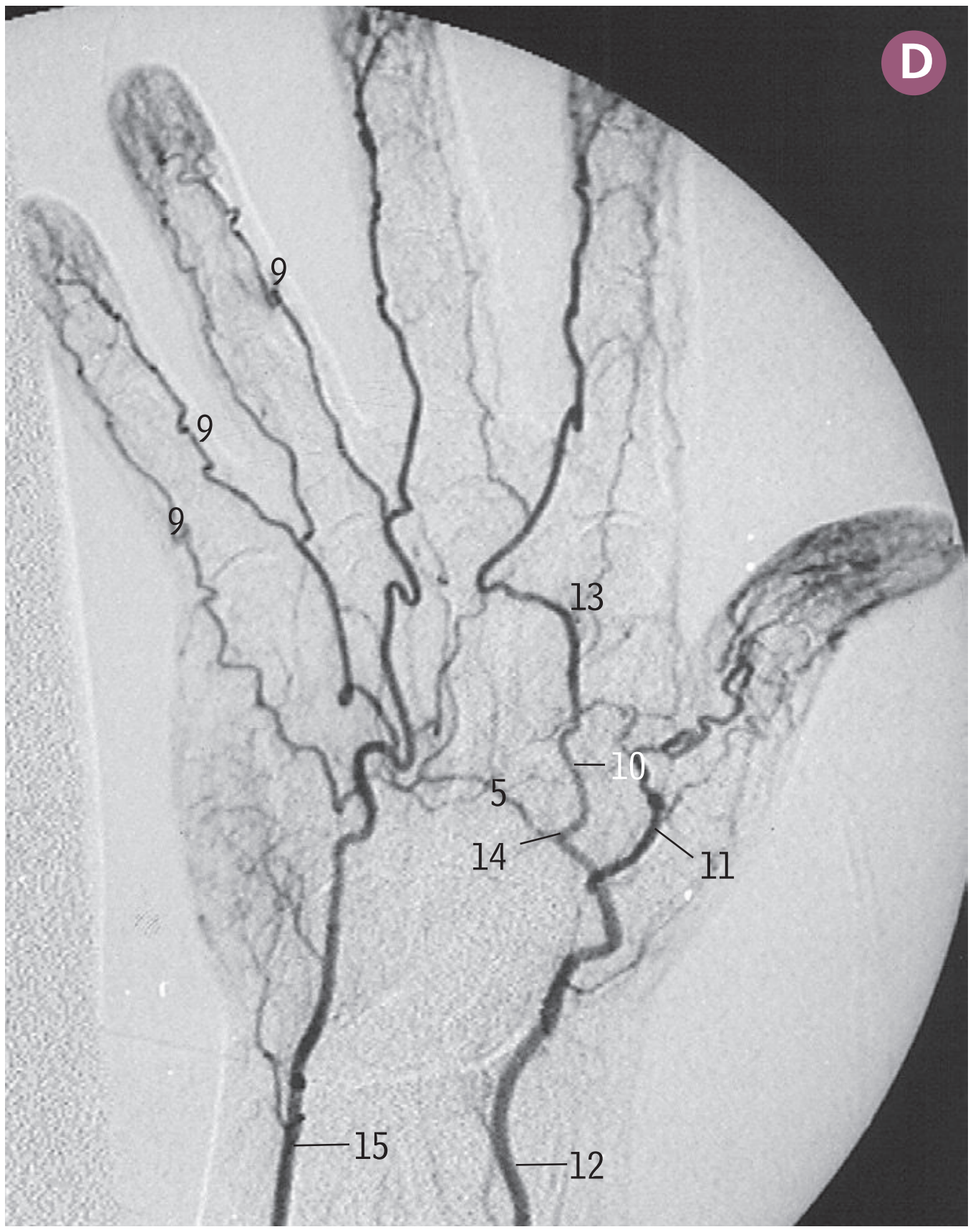

Most muscles and tendons have been removed and the arteries have been distended by injection. The deep palmar arch (5) is seen giving off the palmar metacarpal arteries (10) which join the common palmar digital arteries (3) from the superficial arch. Compare C with the vessels in the arteriogram.

1 Abductor pollicis longus
2 Branch of anterior interosseous artery to anterior carpal arch
3 Common palmar digital arteries (from superficial arch)
4 Deep branch of ulnar artery
5 Deep palmar arch
6 Flexor carpi radialis
7 Flexor carpi ulnaris and pisiform
8 Head of ulna
9 Palmar digital arteries
10 Palmar metacarpal arteries
11 Princeps pollicis artery
12 Radial artery
13 Radialis indicis artery (anomalous origin)
14 Superficial palmar branch of radial artery
15 Ulnar artery

Trigger finger, see pages 170–172.

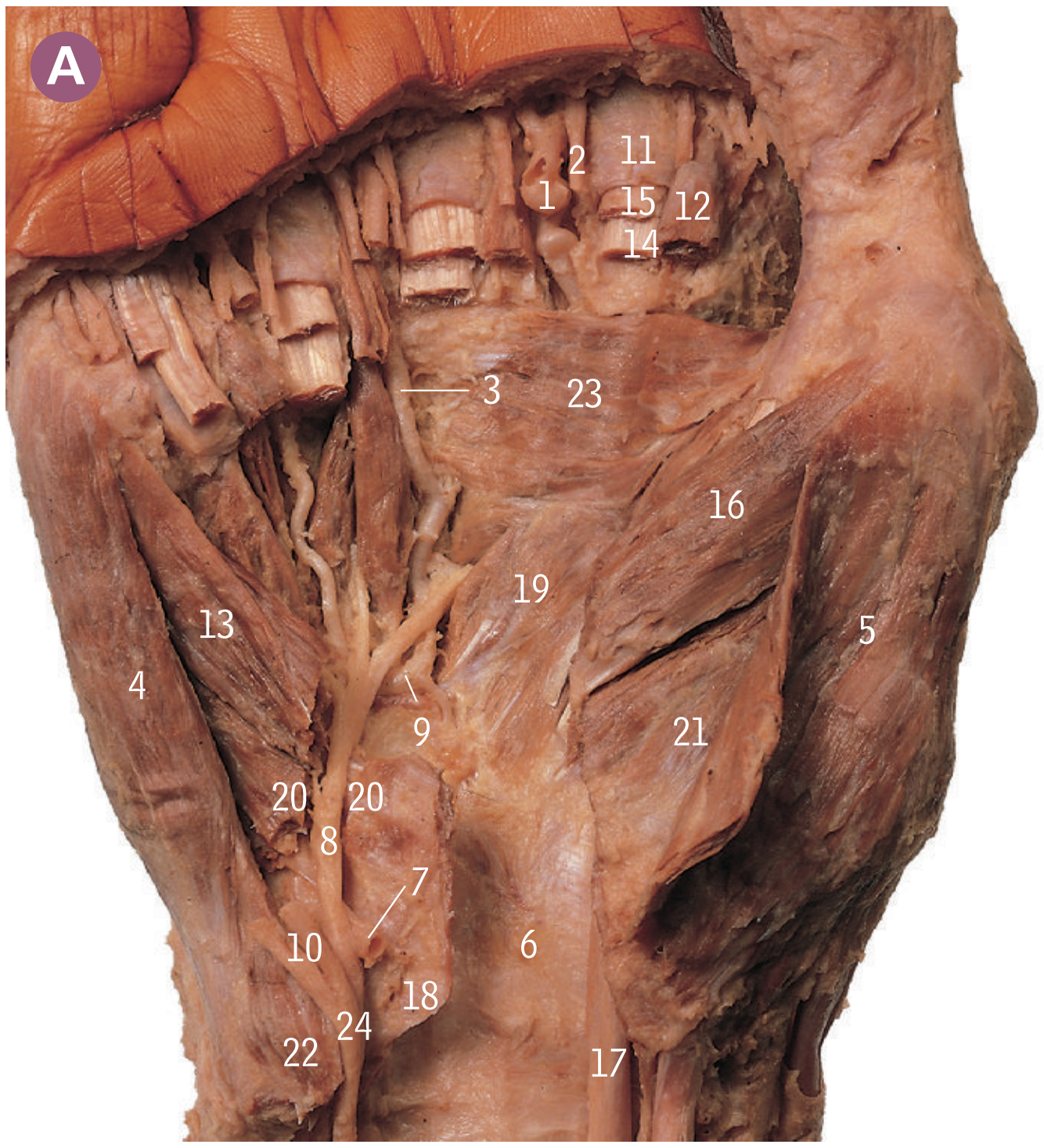

A Palm of right hand

deep branch of the ulnar nerve

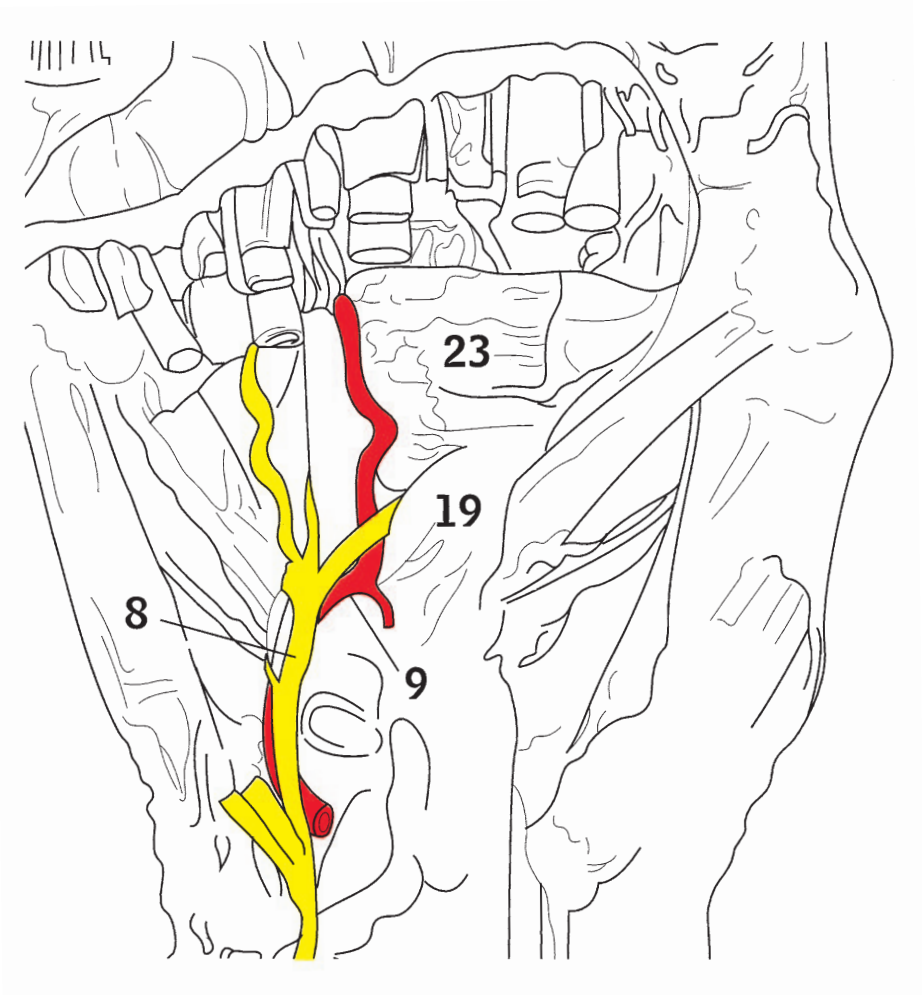

The long flexor tendons (15 and 14) and lumbricals (12) have been cut off near the heads of the metacarpals, and parts of the hypothenar muscles removed to show the deep branches of the ulnar nerve and artery (8 and 7) running into the palm and curling laterally to pass between the transverse and oblique heads of adductor pollicis (23 and 19).

1 A common palmar digital artery
2 A palmar digital nerve
3 A palmar metacarpal artery
4 Abductor digiti minimi
5 Abductor pollicis brevis
6 Carpal tunnel
7 Deep branch of ulnar artery
8 Deep branch of ulnar nerve
9 Deep palmar arch
10 Digital branches of ulnar nerve
11 Fibrous flexor sheath
12 First lumbrical
13 Flexor digiti minimi brevis
14 Flexor digitorum profundus
15 Flexor digitorum superficialis
16 Flexor pollicis brevis
17 Flexor pollicis longus
18 Flexor retinaculum (cut edge)
19 Oblique head of adductor pollicis
20 Opponens digiti minimi
21 Opponens pollicis
22 Pisiform
23 Transverse head of adductor pollicis
24 Ulnar nerve

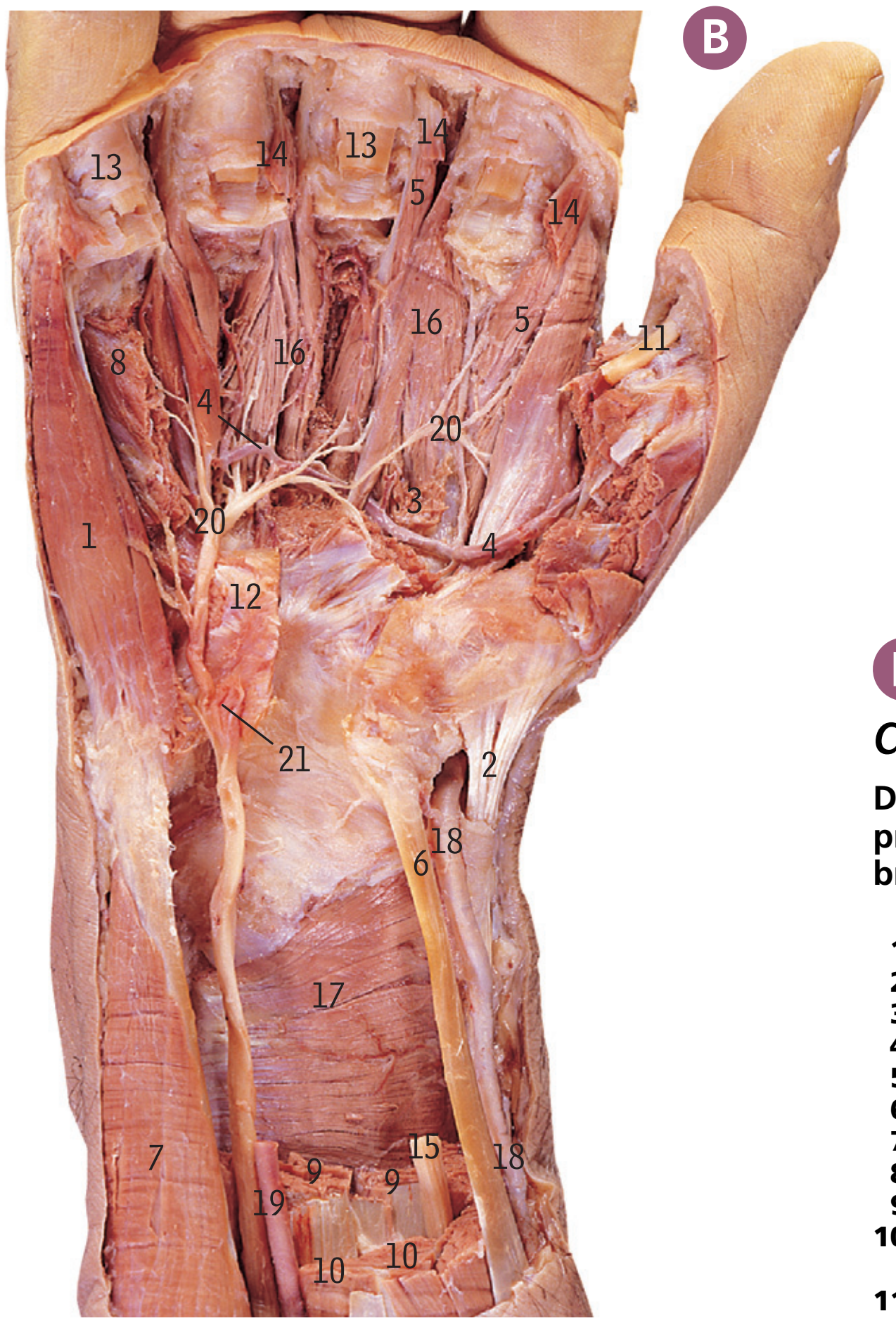

B Palm of right hand

deep dissection

Deep to the adductor pollicis and the flexor tendons lie the pronator quadratus proximally and the extensive deep palmar branches of the ulnar nerve and deep palmar arch distally.

1 Abductor digiti minimi
2 Abductor pollicis longus
3 Adductor pollicis – cut
4 Deep palmar arch
5 Dorsal interossei
6 Flexor carpi radialis
7 Flexor carpi ulnaris
8 Flexor digiti minimi – cut
9 Flexor digitorum profundus – cut
10 Flexor digitorum superficialis – cut
11 Flexor pollicis longus
12 Flexor retinaculum – cut
13 Flexor tendon sheaths
14 Lumbrical – cut
15 Median nerve – cut
16 Palmar interossei
17 Pronator quadratus
18 Radial artery
19 Ulnar artery – cut
20 Ulnar nerve, deep branches to intrinsic hand muscles
21 Ulnar nerve, superficial branch (cut at wrist)

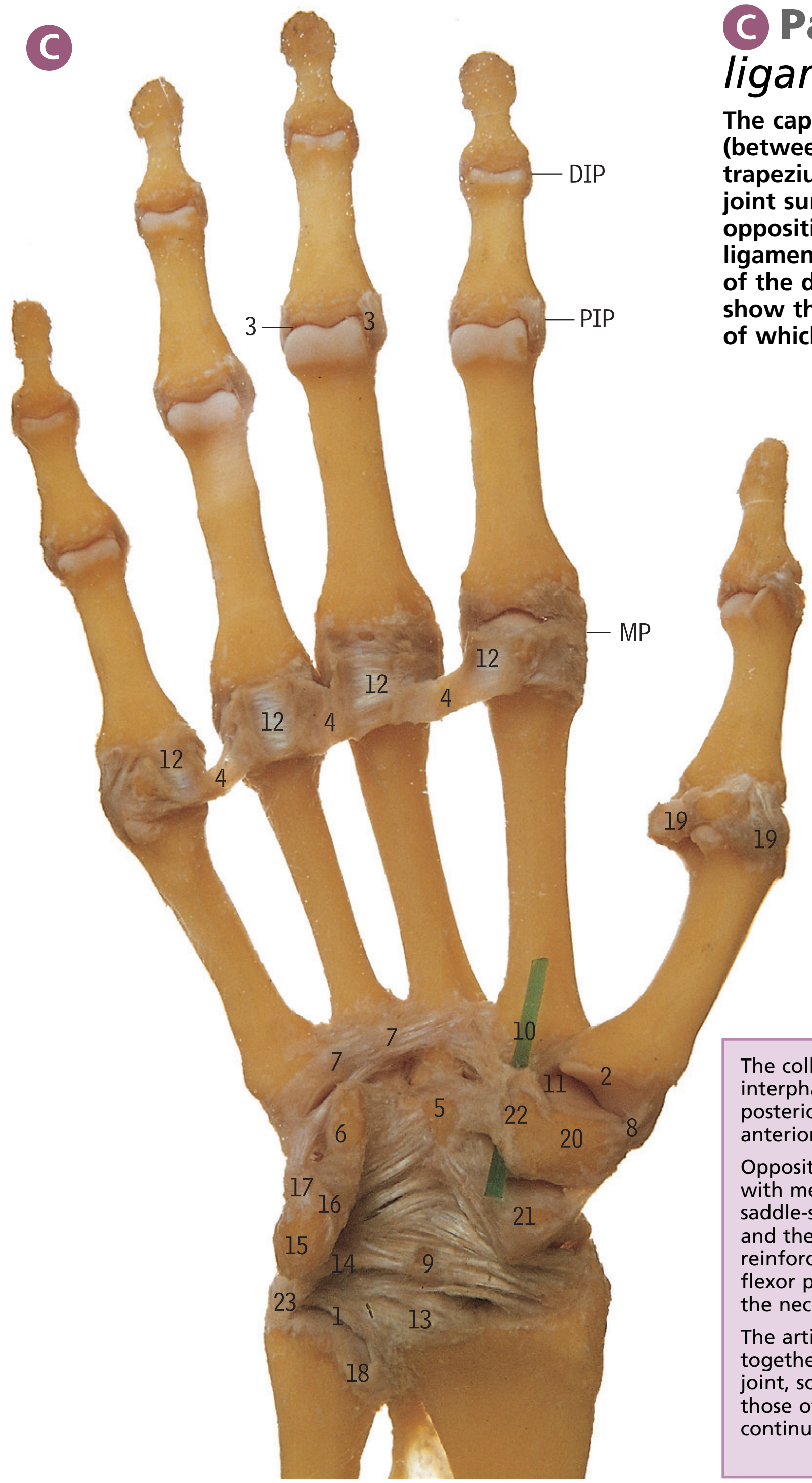

DIP distal interphalangeal joint
PIP proximal interphalangeal joint
MP metacarpophalangeal joint

C Palm of right hand
ligaments and joints

The capsule of the carpometacarpal joint of the thumb (between the base of the first metacarpal and the trapezium) has been removed, to show the saddle-shaped joint surfaces, which allow the unique movement of opposition of the thumb to occur. The palmar and lateral ligaments (11 and 8) of the joint remain intact. The capsule of the distal radio-ulnar joint has also been removed to show the articular disc, but the wrist joint, the ulnar part of which lies distal to the disc, has not been opened.

1 Articular disc of distal radio-ulnar joint
2 Base of first metacarpal
3 Collateral ligament of interphalangeal joint
4 Deep transverse metacarpal ligament
5 Head of capitate
6 Hook of hamate
7 Interosseous metacarpal ligament
8 Lateral ligament of carpometacarpal joint of thumb
9 Lunate
10 Marker in groove on trapezium for flexor carpi radialis tendon
11 Palmar ligament of carpometacarpal joint of thumb
12 Palmar ligament of metacarpophalangeal joint with groove for flexor tendon
13 Palmar radiocarpal ligament
14 Palmar ulnocarpal ligament
15 Pisiform
16 Pisohamate ligament
17 Pisometacarpal ligament
18 Sacciform recess of capsule of distal radio-ulnar joint
19 Sesamoid bones of flexor pollicis brevis tendons (with adductor pollicis on ulnar side)
20 Trapezium
21 Tubercle of scaphoid
22 Tubercle of trapezium
23 Ulnar collateral ligament of wrist joint

The collateral ligaments of the metacarpophalangeal and interphalangeal joints (D2, C3) pass obliquely forwards from the posterior part of the side of the head of the proximal bone to the anterior part of the side of the base of the distal bone.

Opposition of the thumb is a combination of flexion and abduction with medial rotation of the first metacarpal (page 156). The saddle-shape of the joint between the base of the first metacarpal and the trapezium, together with the way that the capsule and its reinforcing ligaments are attached to the bones, ensures that when flexor pollicis brevis and opponens pollicis contract they produce the necessary metacarpal rotation.

The articular disc (1) holds the lower ends of the radius and ulna together, and separates the distal radio-ulnar joint from the wrist joint, so that the cavities of these joints are not continuous (unlike those of the elbow and proximal radio-ulnar joints, which have one continuous cavity – page 146).

D Right index finger
metacarpophalangeal (MP) joint, from the radial side

Part of the capsule has been removed to define the collateral ligament (2).

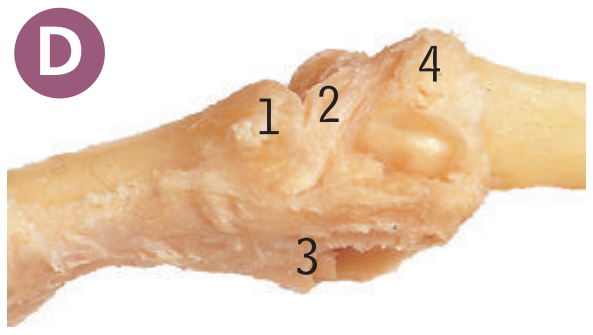

1 Base of proximal phalanx
2 Collateral ligament
3 Fibrous flexor sheath
4 Head of second metacarpal

Gamekeeper's thumb, see pages 170–172.

Dorsum of left hand

A *Radial side view of 'Anatomical snuff box'*

The boundaries of the "anatomical snuff box" are the tendons of extensor pollicis brevis (14) and abductor pollicis longus (23) muscles laterally, and the tendon of extensor pollicis longus (15) muscle medially. The base of the snuffbox triangle is bounded by the styloid process of the radius, and in its floor lies the scaphoid bone. In this image the cephalic vein traverses the roof of the snuffbox.

A B

1 Abductor digiti minimi
2 Cephalic vein
3 Digital branches of superficial radial nerve over porcupine quill
4 Dorsal carpal arch
5 Dorsal digital artery
6 Dorsal digital vein
7 Dorsal metacarpal artery
8 Extensor carpi radialis brevis
9 Extensor carpi radialis longus
10 Extensor carpi ulnaris
11 Extensor digiti minimi
12 Extensor digitorum
13 Extensor indicis
14 Extensor pollicis brevis
15 Extensor pollicis longus
16 Extensor retinaculum
17 First dorsal interosseous
18 First dorsal interosseous artery
19 Fourth dorsal interosseous
20 Radial artery, dorsal branch
21 Radialis indicis artery
22 Second dorsal interosseous
23 Skin overlying abductor pollicis longus
24 Superficial radial nerve
25 Superficial radial nerve, cutaneous branch
26 Third dorsal interosseous
27 Ulnar nerve, dorsal cutaneous branch

B Dorsum of left hand

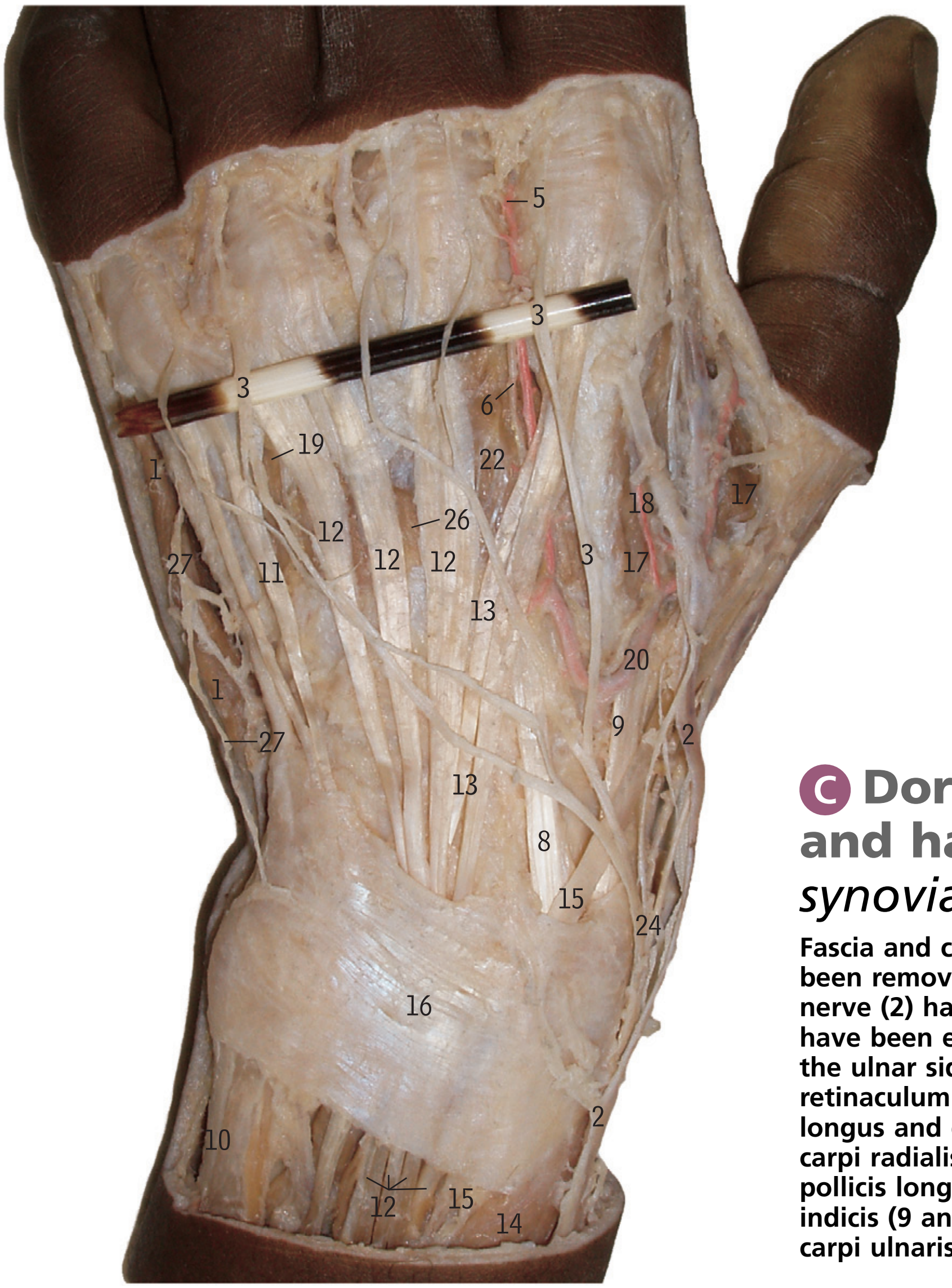

C Dorsum of right wrist and hand
synovial sheaths

Fascia and cutaneous branches of the ulnar nerve have been removed; the extensor reticulum (13) and the radial nerve (2) have been preserved and the synovial sheaths have been emphasised by blue tissue. From the radial to the ulnar side, the six compartments of the extensor retinaculum contain the tendons of: (a) abductor pollicis longus and extensor pollicis brevis (1 and 11); (b) extensor carpi radialis longus and brevis (6 and 5); (c) extensor pollicis longus (12); (d) extensor digitorum and extensor indicis (9 and 10); (e) extensor digiti minimi (8); (f) extensor carpi ulnaris (7).

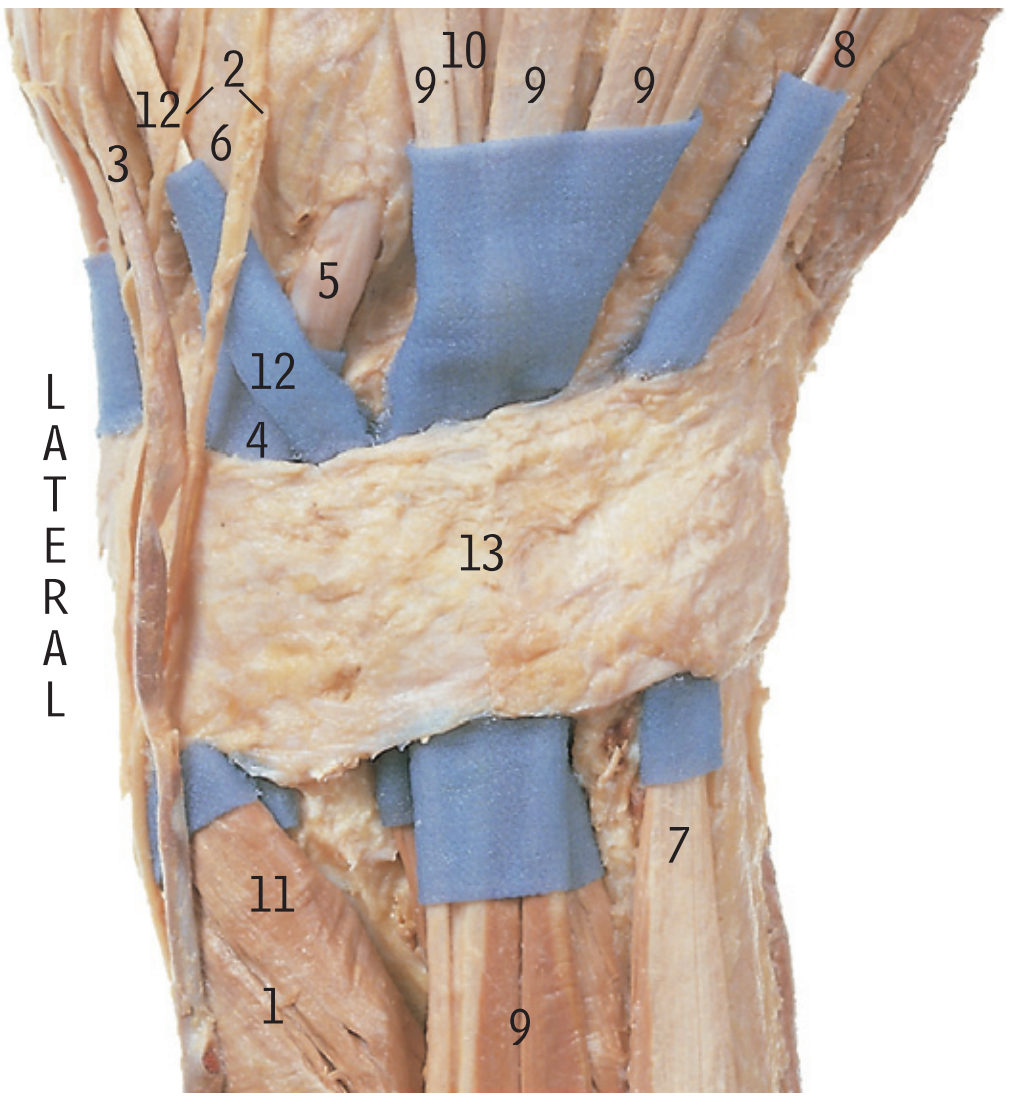

C

1 Abductor pollicis longus
2 Branches of radial nerve
3 Cephalic vein
4 Common sheath for 5 and 6
5 Extensor carpi radialis brevis
6 Extensor carpi radialis longus
7 Extensor carpi ulnaris
8 Extensor digiti minimi
9 Extensor digitorum
10 Extensor indicis
11 Extensor pollicis brevis
12 Extensor pollicis longus
13 Extensor retinaculum

Nail abnormalities, wrist ganglion, see pages 170–172.

A Dorsum of right hand *arteries*

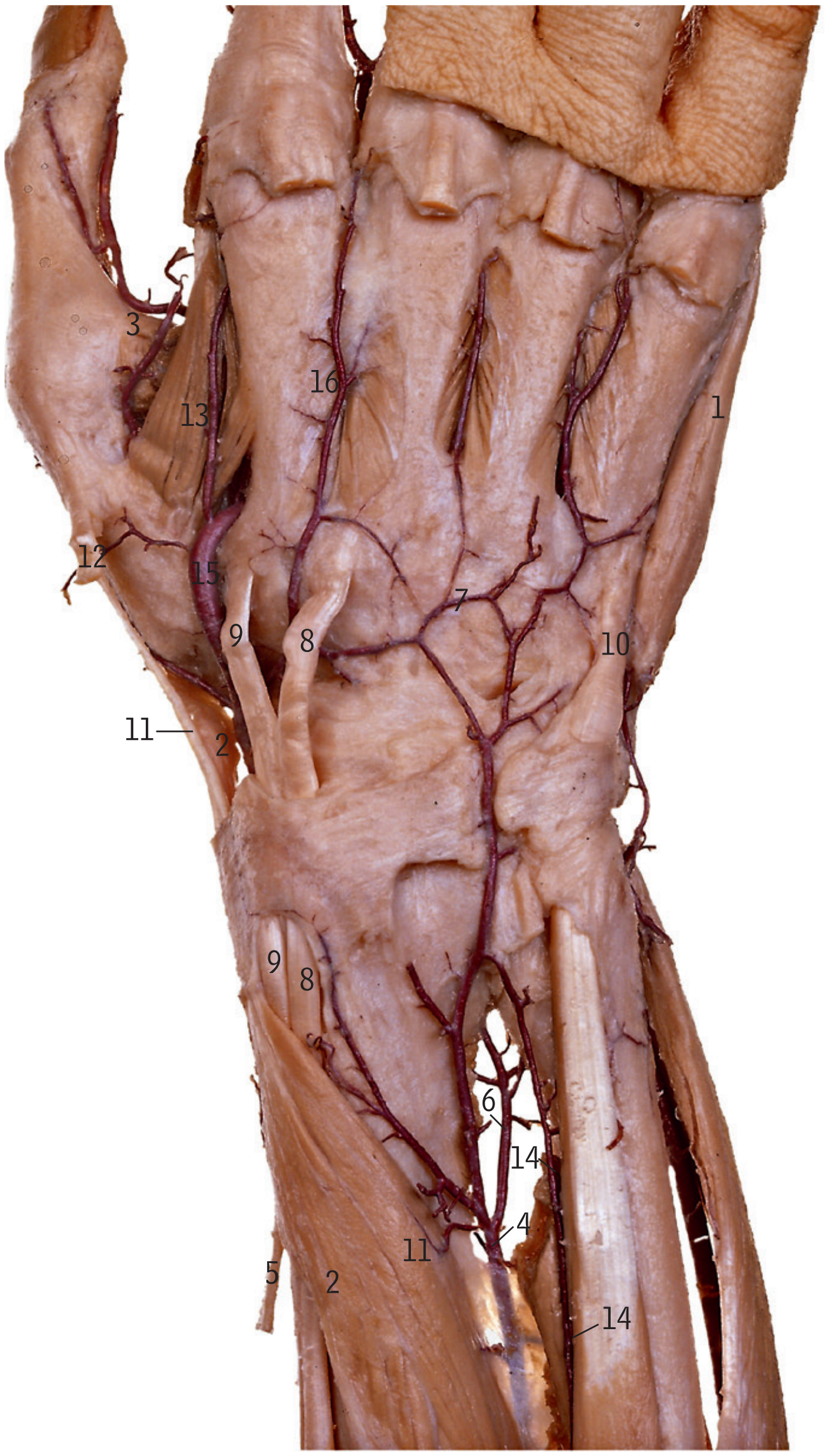

The arteries have been injected and the long finger tendons removed to display the dorsal carpal arch (7) and dorsal metacarpal arteries (as at 13 and 16). Above the wrist pronator quadratus has been removed to show the branch (6) of the anterior interosseous artery (4), which continues towards the palm; the anterior interosseous itself passes to the dorsal surface to join the posterior interosseous artery (14).

B Left ring finger *extensor expansion (dorsal digital expansion)*



A

1. Abductor digiti minimi
2. Abductor pollicis longus
3. Adductor pollicis and branch of princeps pollicis artery
4. Anterior interosseous artery
5. Brachioradialis
6. Branch of anterior interosseous artery to anterior carpal arch
7. Dorsal carpal arch
8. Extensor carpi radialis brevis
9. Extensor carpi radialis longus
10. Extensor carpi ulnaris
11. Extensor pollicis brevis
12. Extensor pollicis longus
13. First dorsal interosseous and first dorsal metacarpal artery
14. Posterior interosseous artery
15. Radial artery
16. Second dorsal interosseous and second dorsal metacarpal artery

B

1. Common extensor tendon
2. Deep transverse metacarpal ligament
3. Dorsal digital expansion
4. Dorsal interosseous muscle
5. Dorsal interosseous muscle, phalangeal attachment
6. Extensor digitorum tendon
7. Lateral conjoined extensor tendon
8. Lateral tendon "wing tendon"
9. Lumbrical muscle
10. Oblique interosseous fibres
11. Palmar interosseous muscle
12. Retinacular ligament, transverse band
13. Terminal conjoint extensor tendon
14. Transverse ligament
15. Triangular ligament

Three tendons pass to different levels of the thumb: abductor pollicis longus (A2) to the base of the first metacarpal, extensor pollicis brevis (A11) to the base of the proximal phalanx, and extensor pollicis longus (A12) to the base of the distal phalanx.

A Dorsum of right hand *ligaments and joints*

Most joint capsules have been removed, including the radial parts of the wrist joint capsule, thus showing the articulation between the scaphoid (6) and the lower end of the radius (7).

1 Dorsal radiocarpal ligament
2 Fifth metacarpal
3 First metacarpal
4 Hamate
5 Radial collateral ligament of wrist joint
6 Scaphoid
7 Styloid process of radius
8 Styloid process of ulna
9 Triquetral

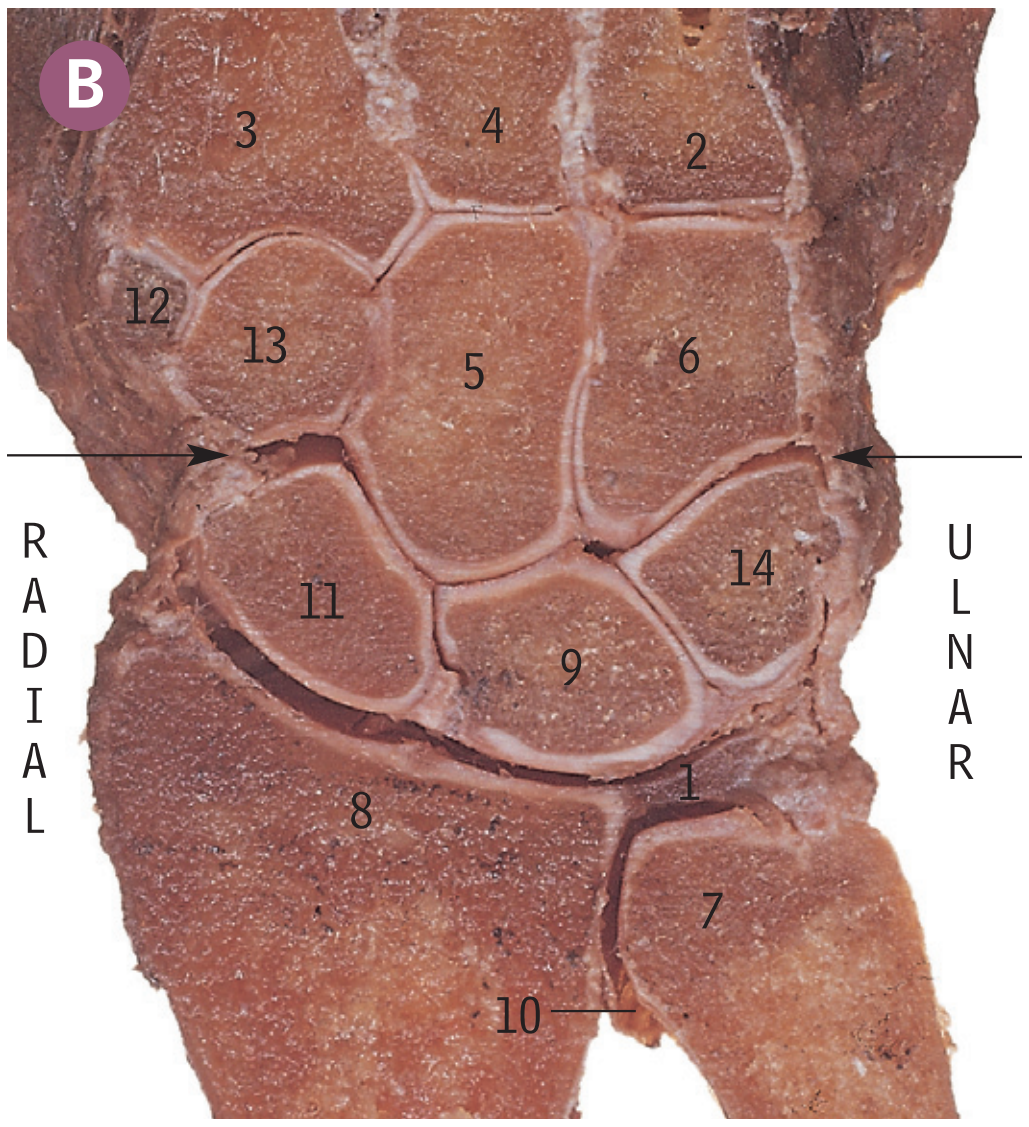

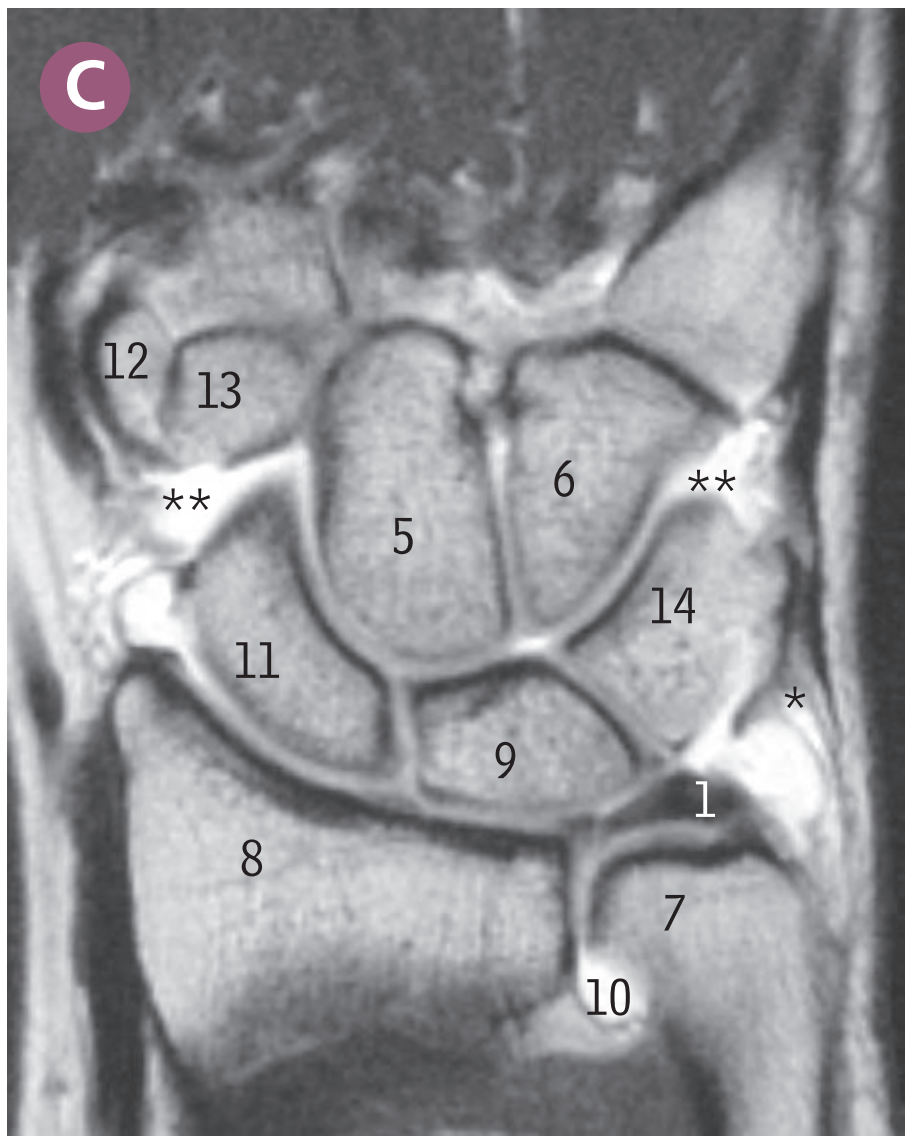

Viewed from the dorsal surface, the section has passed through the wrist near this surface, and the first and fifth metacarpals have not been included in the cut. The arrows between the two rows of carpal bones indicate the line of the midcarpal joint. Compare the MR image with the section.

Right wrist *coronal section*

B dissection

C coronal MR arthrogram

1 Articular disc (triangular fibrocartilage)
2 Base of fourth metacarpal
3 Base of second metacarpal
4 Base of third metacarpal
5 Capitate
6 Hamate
7 Head of ulna
8 Lower end of radius
9 Lunate
10 Sacciform recess of distal radio-ulnar joint
11 Scaphoid
12 Trapezium
13 Trapezoid
14 Triquetral
***** Normal vascular penetration of triangular fibrocartilage peripherally
****** Contrast in midcarpal joint indicates abnormal communication between radiocarpal and midcarpal joints

Avascular necrosis of the scaphoid, dislocation of the lunate, see pages 170–172.

Right midcarpal and wrist joints
A *midcarpal joint, opened up in forced flexion*
B *wrist joint, opened up in forced extension*

BACK OF RIGHT THUMB EDGE

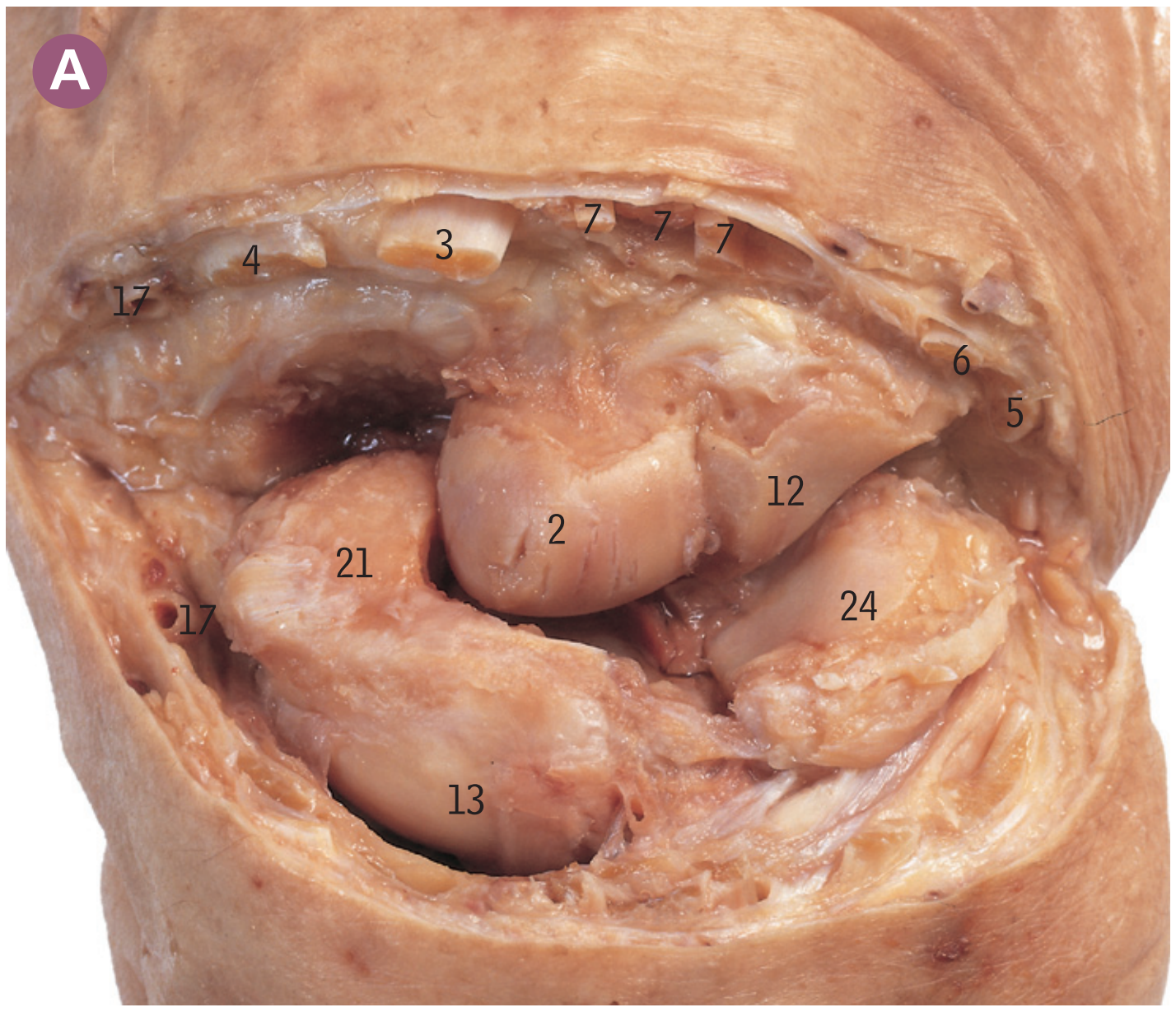

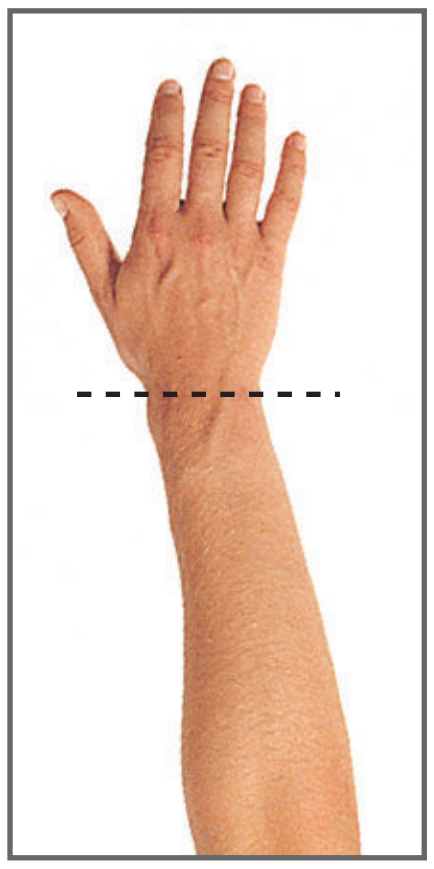

FRONT OF RIGHT THUMB EDGE

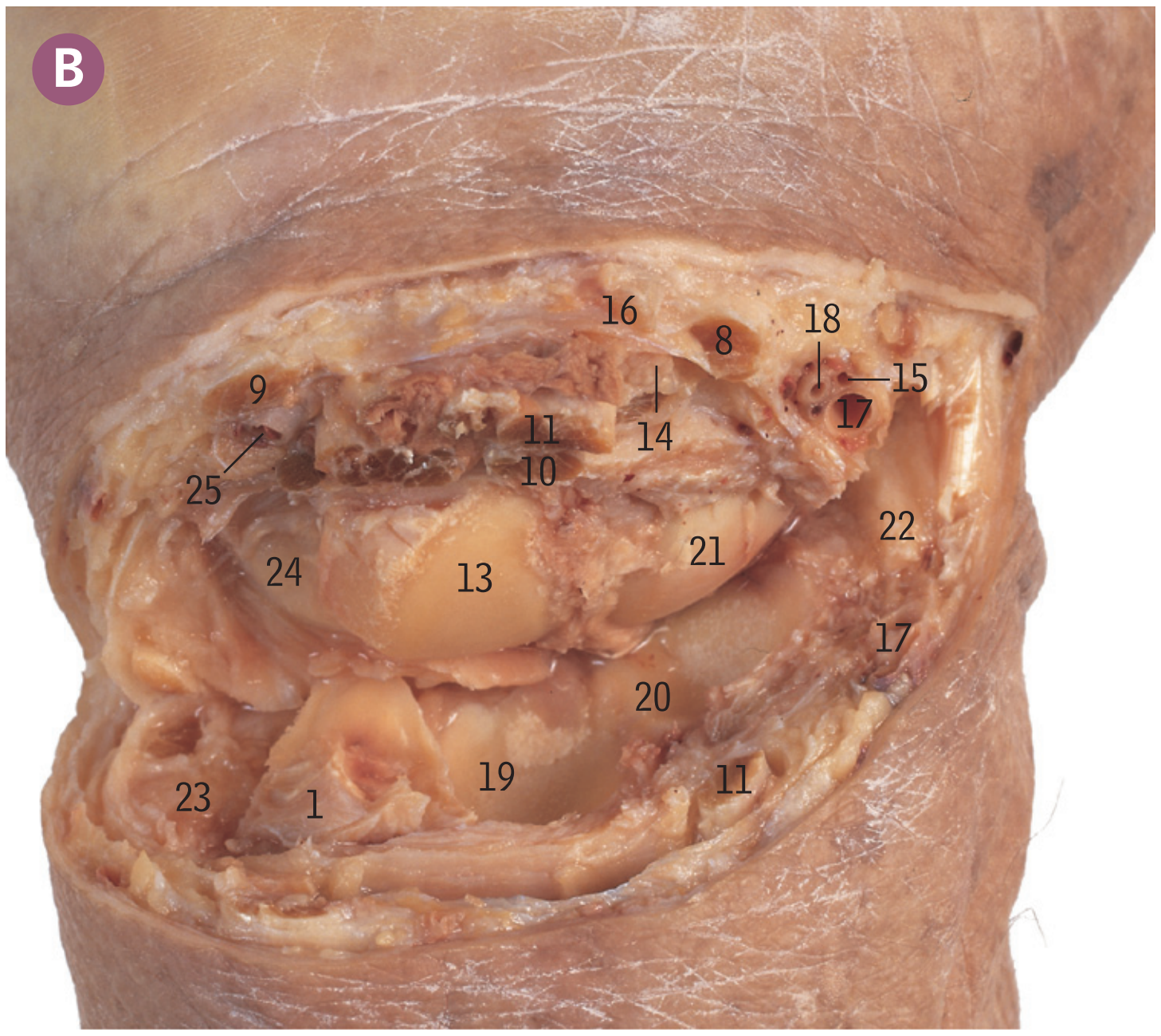

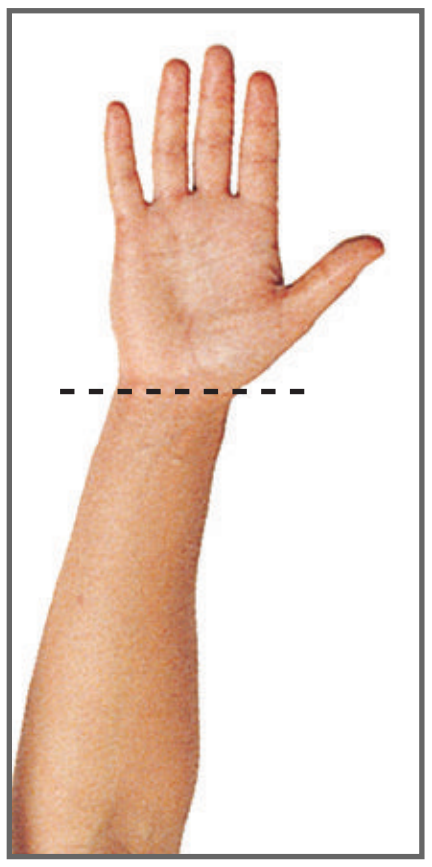

1 Articular disc
2 Capitate
3 Extensor carpi radialis brevis
4 Extensor carpi radialis longus
5 Extensor carpi ulnaris
6 Extensor digiti minimi
7 Extensor digitorum
8 Flexor carpi radialis tendon
9 Flexor carpi ulnaris tendon
10 Flexor digitorum profundus tendon
11 Flexor digitorum superficialis tendon
12 Hamate
13 Lunate
14 Median nerve
15 Palmar arch vein
16 Palmaris longus tendon
17 Radial artery
18 Radial artery, palmar arch branch
19 Radial surface for lunate
20 Radial surface for scaphoid
21 Scaphoid
22 Styloid process of radius
23 Styloid process of ulna
24 Triquetral
25 Ulnar artery

Both joints have been opened up (far beyond the normal range of movement) in order to demonstrate the bones of the joint surfaces. The wrist joint in B has been forced open in extension. A has been forced open in flexion. The proximal (wrist joint) surfaces of the scaphoid (21), lunate (13) and triquetral (24) are seen in B, and their distal (midcarpal joint) surfaces in A.

Wrist and hand *radiographs*

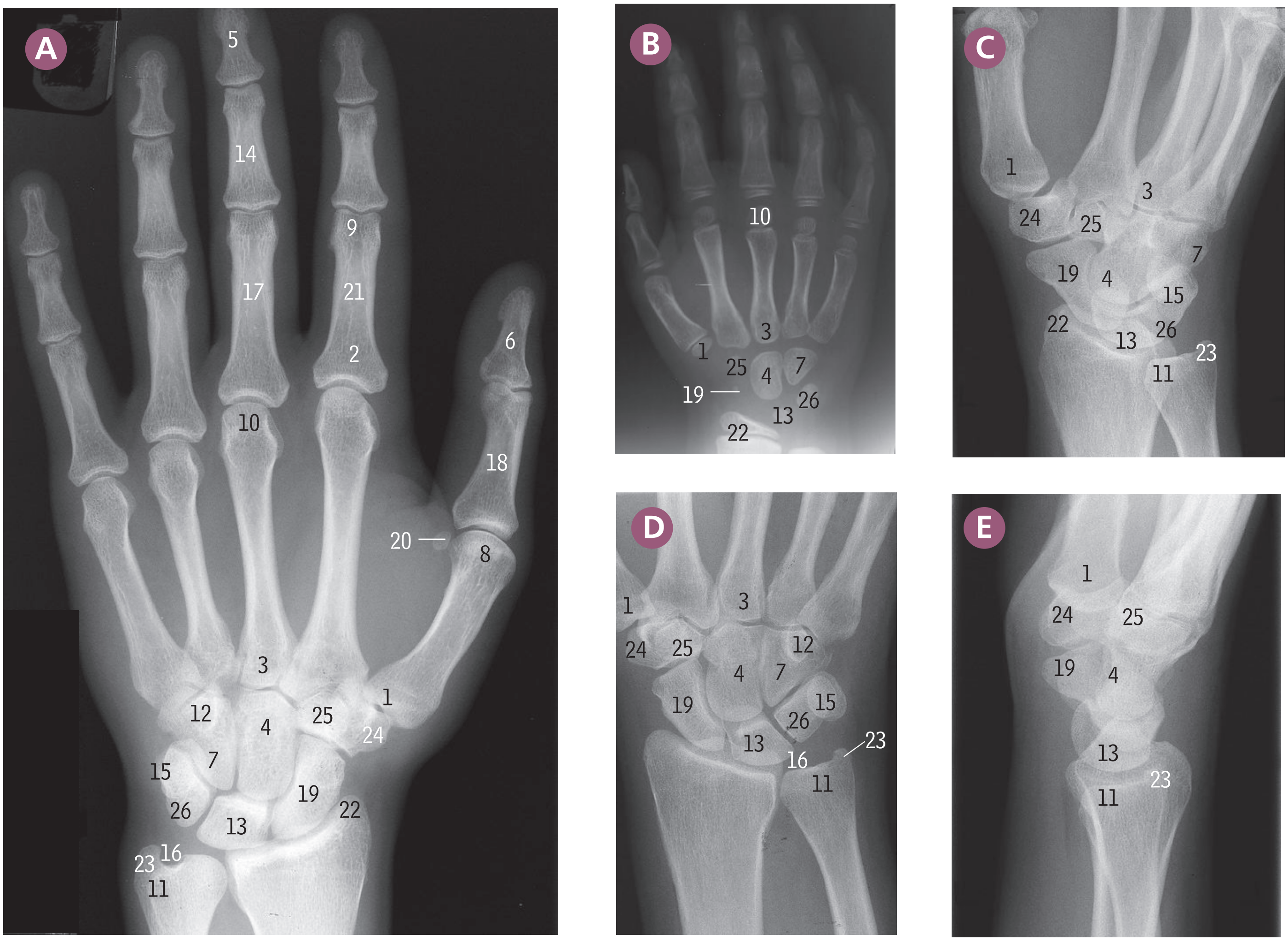

A dorsopalmar projection

B of a 4-year-old child

C oblique projection

D posteroanterior projection

E lateral projection

The epiphysis at the lower end of the radius appears on a radiograph at 2 years and in the ulna at 6 years. The first carpal bone to appear is the capitate at 1 year.

Compare the epiphyses of the metacarpals and phalanges seen in B with the bony specimens in J and K on page 125.

1 Base of first metacarpal
2 Base of phalanx
3 Base of third metacarpal
4 Capitate
5 Distal phalanx of middle finger
6 Distal phalanx of thumb
7 Hamate
8 Head of first metacarpal
9 Head of phalanx
10 Head of third metacarpal
11 Head of ulna
12 Hook of hamate
13 Lunate
14 Middle phalanx of middle finger
15 Pisiform
16 Position of articular disc (triangular fibrocartilage)
17 Proximal phalanx of middle finger
18 Proximal phalanx of thumb
19 Scaphoid
20 Sesamoid bone in flexor pollicis brevis
21 Shaft of phalanx
22 Styloid process at lower end of radius
23 Styloid process of ulna
24 Trapezium
25 Trapezoid
26 Triquetral

Upper limb

Clinical thumbnails, see website for details and further clinical images to download into your own notes.

Accessory ossicles

Acromioclavicular separation

Anterior interosseous nerve entrapment

Arterial puncture at the elbow

Arterial puncture at the wrist

Arteriovenous fistula

Auscultation of the brachial pulse

Avascular necrosis of the scaphoid

Avulsion medial epicondyle

Axillary artery aneurysm

Axillary-subclavian vein thrombosis

Bar room fracture

Biceps tendon reflex

Bicipital tendinitis and rupture

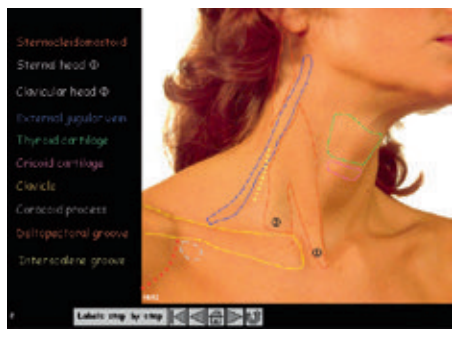
Brachial plexus block

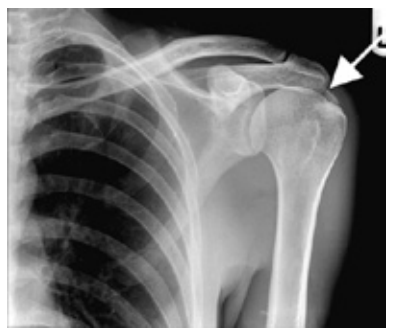
Calcific tendinitis

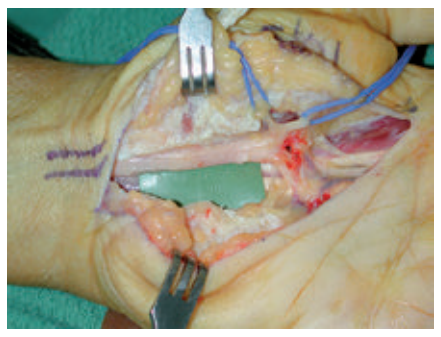
Carpal tunnel syndrome

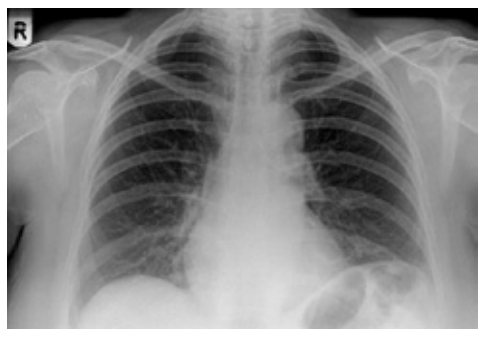
Cervical rib

Colles' fracture

de Quervain's disease

Digital development abnormality

Digital nerve block

Dislocation of the elbow

Dislocation of the finger

Dislocation of humerus

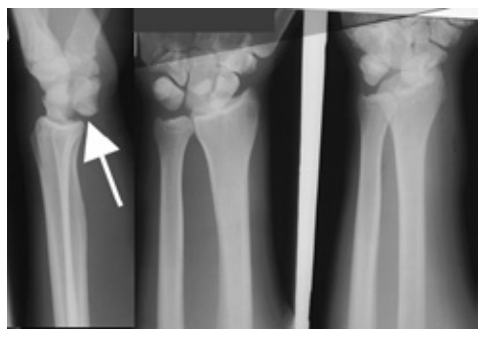
Dislocation of the lunate

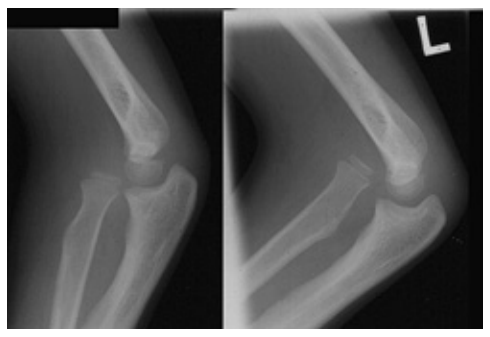
Dislocation of the radial head

Dupuytren's contracture

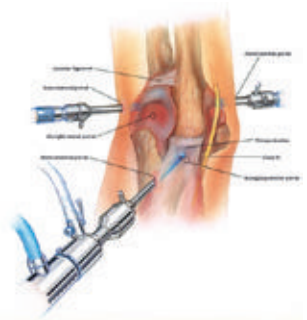
Elbow arthroscopy

Erb's palsy

Fractured clavicle

Fractured hamate

Fractured scapula

Gamekeeper's thumb

Golfer's elbow – injection

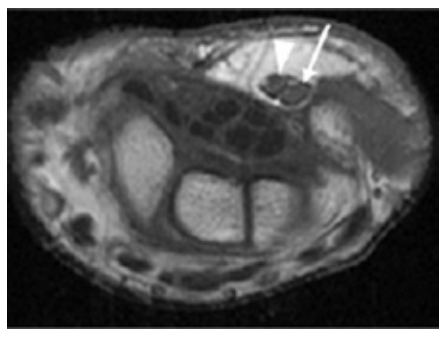
Guyon's canal syndrome

Hand infections

Intramuscular injection – deltoid

Klumpke's paralysis


Mallet finger

Median nerve palsy

Nail abnormalities

Olecranon bursitis

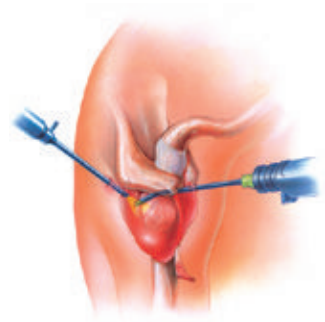
Painful arc syndrome/ rotator cuff tear

Posterior dislocation of the shoulder

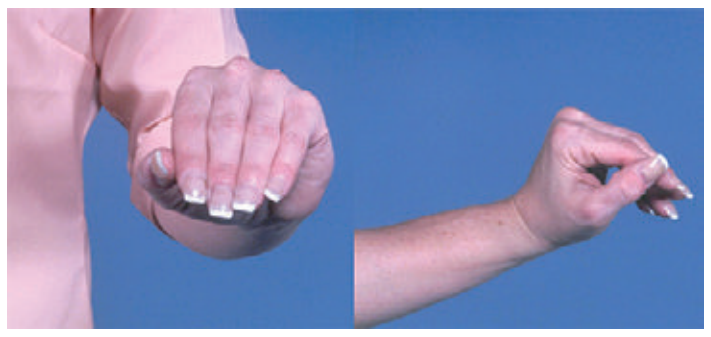
Posterior interosseous nerve entrapment

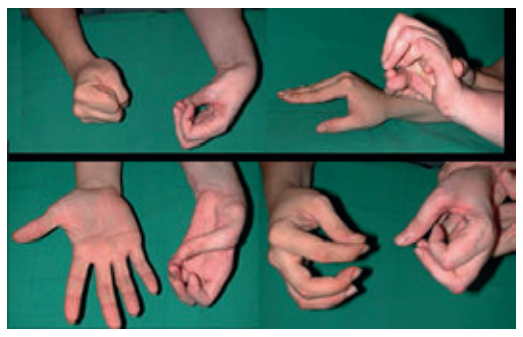
Radial nerve palsy

Scapular arterial anastomoses

Shoulder joint injection

Smith's fracture

Sternoclavicular dislocation

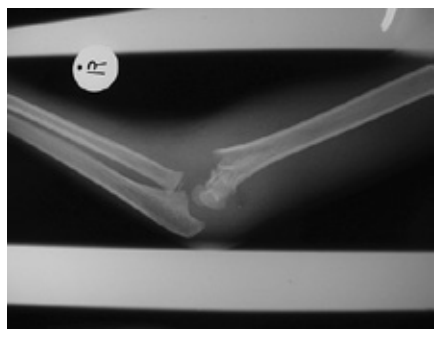
Supracondylar fracture of the humerus

Supracondylar spur

Tennis elbow

Traction of forearm fractures

Triceps tendon reflex

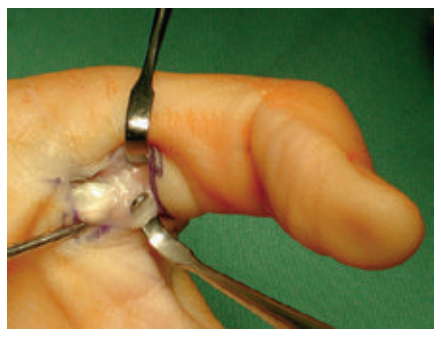
Trigger finger

Ulnar nerve palsy

Vascular abnormalities

Venepuncture of the upper limb

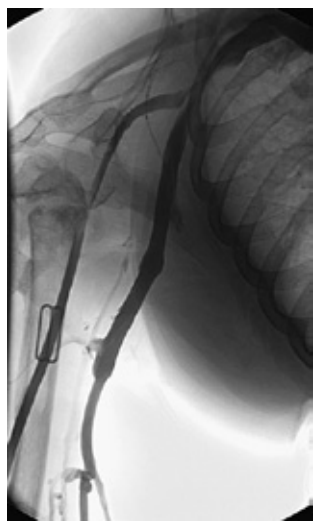
Venous cutdown

Volkmann's ischaemic contracture

Winging of the scapula

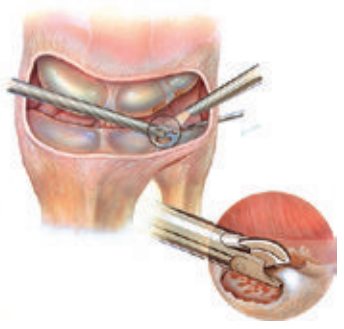
Wrist arthroscopy

Wrist drop

Wrist ganglion

Thorax

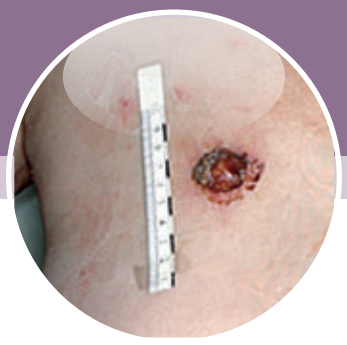
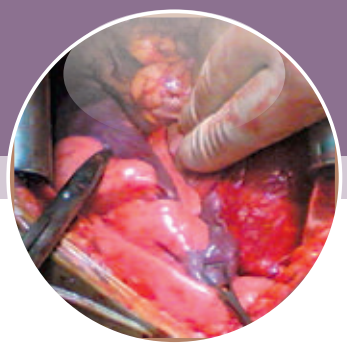

4

Thorax (A) *surface anatomy, from the front*
(B) *axial skeleton, from behind*
(C) *3D CT reconstruction of thorax*

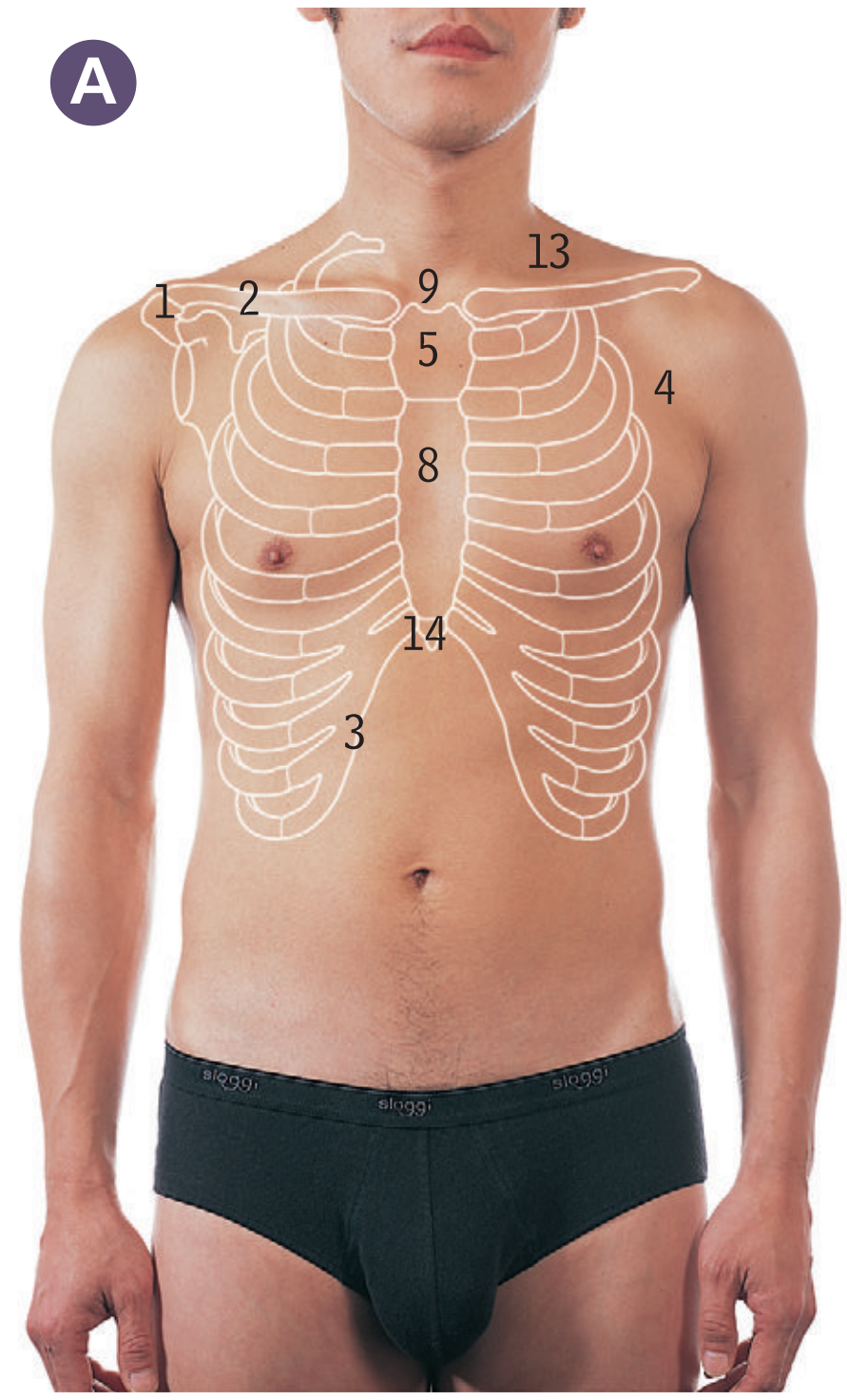

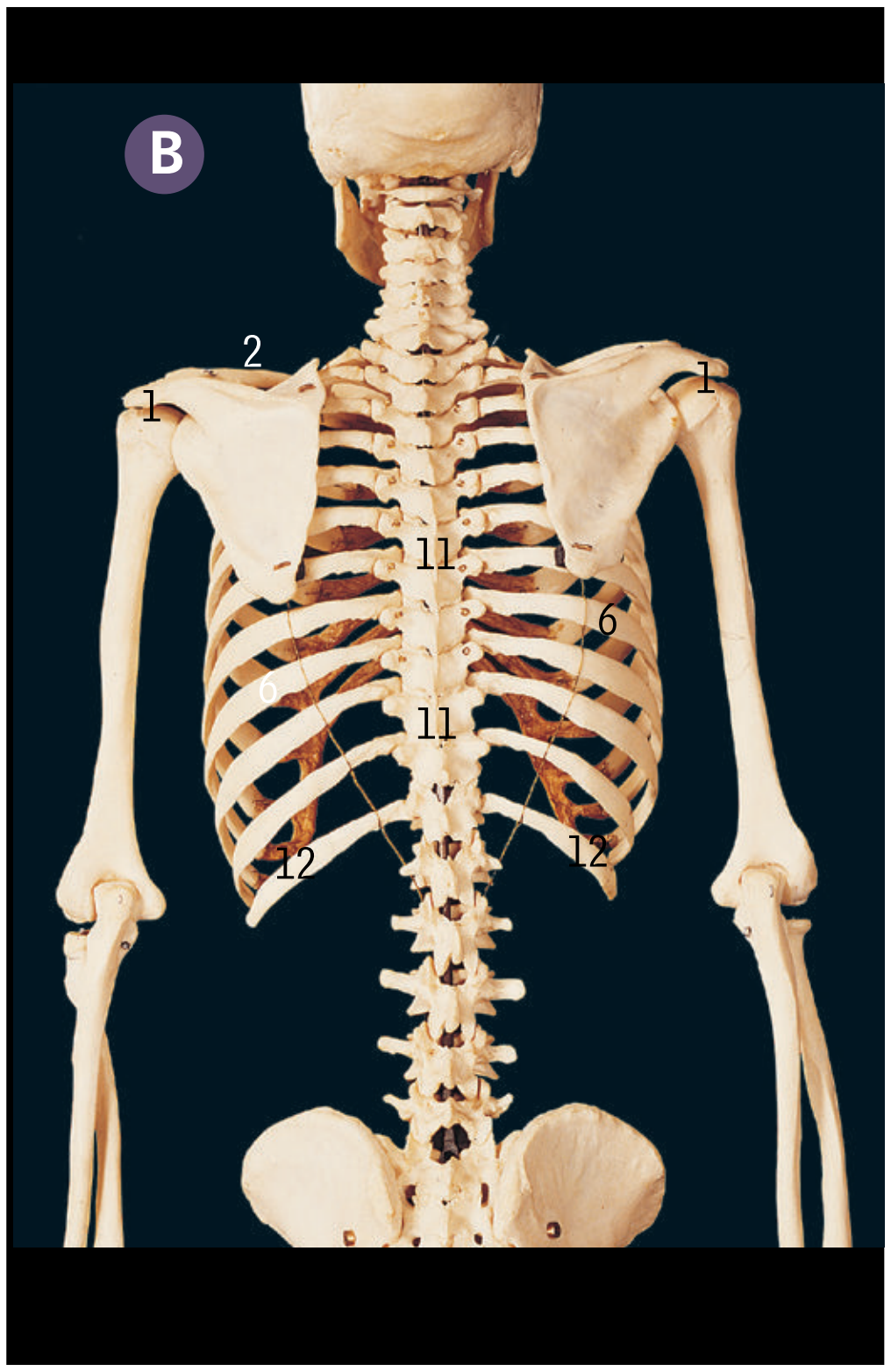

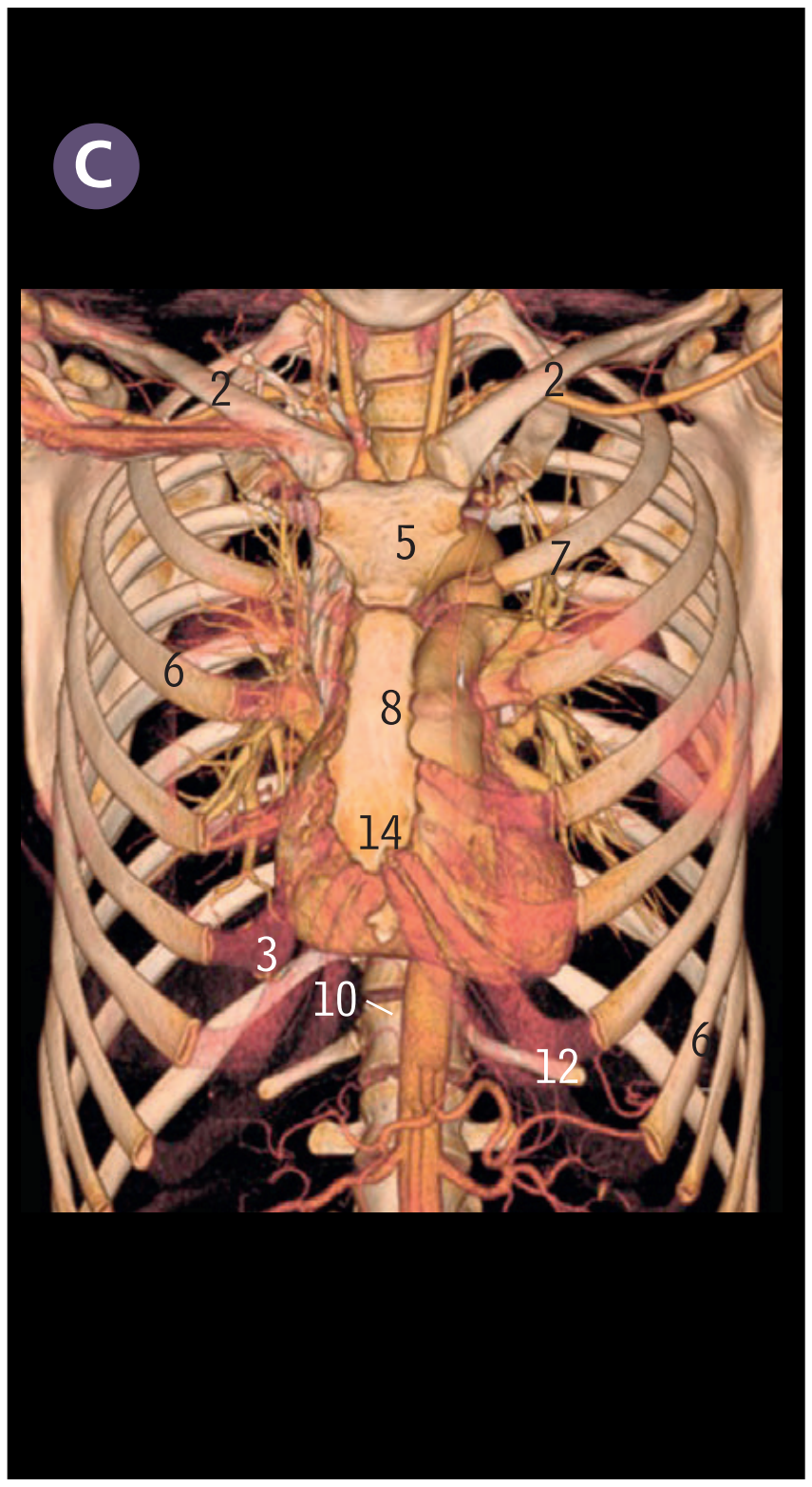

1 Acromion
2 Clavicle
3 Costal margin
4 Deltopectoral groove
5 Manubrium
6 Rib
7 Second rib
8 Sternal body
9 Suprasternal notch
10 Thoracic vertebra, body
11 Thoracic vertebra, spine
12 Twelfth rib
13 Trapezius
14 Xiphisternum

A
10
6
1
5
5
6
10
9
3
7
8
4
9
B
1
10
6
5
2
10
6
5
9
9
C
23
24
17
5
18
4
D
18
17
3
3
22
1
6
20
F
13
2
19
16
7
8
12
E
3
17
3
18
5
1
20
6
G
21
14
10
11
9
15

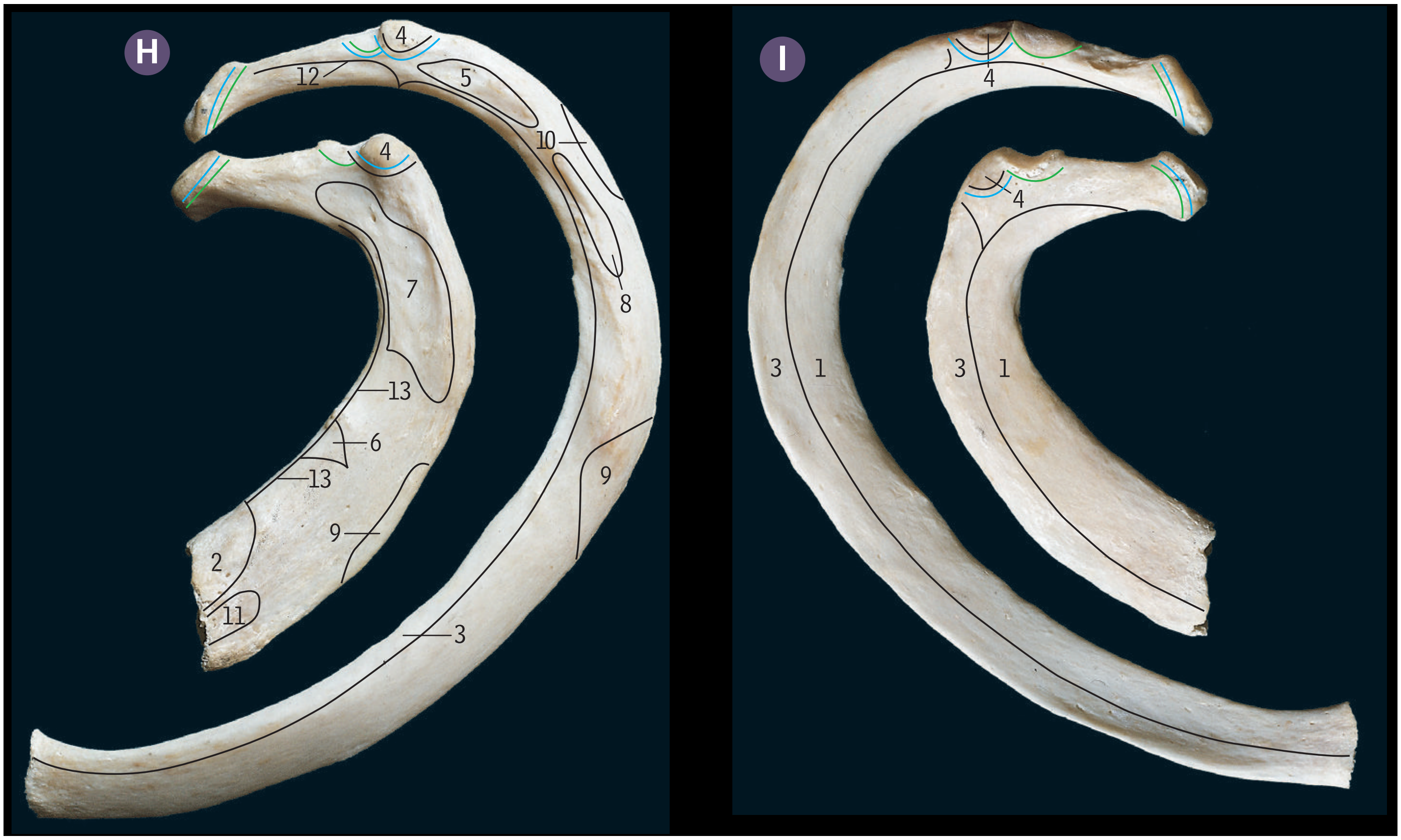

Left first rib (inner) and second rib (outer)

A **from above**

B **from below**

1. Angle
2. Costal groove
3. Groove for subclavian artery and first thoracic nerve
4. Groove for subclavian vein
5. Head
6. Neck
7. Scalene tubercle
8. Serratus anterior tuberosity
9. Shaft
10. Tubercle

Ribs and relationships

C **a typical rib and vertebra articulated, from above**

D **the left fifth rib from behind (a typical upper rib)**

E **the left seventh rib from behind (a typical lower rib)**

F **the left twelfth rib from the front, with attachments**

G **the left twelfth rib from behind, with attachments**

1. Angle of rib
2. Area covered by pleura
3. Articular facet of head
4. Articular facet of transverse process
5. Articular part of tubercle
6. Costal groove
7. Costotransverse ligament
8. Diaphragm
9. Erector spinae
10. External intercostal
11. External oblique
12. Head
13. Internal intercostal
14. Latissimus dorsi
15. Levator costae
16. Line of pleural reflexion
17. Neck of rib
18. Non-articular part of tubercle
19. Quadratus lumborum
20. Shaft of rib
21. Serratus posterior inferior
22. Tubercle
23. Upper costal facet of head of rib
24. Upper costal facet of vertebral body

The atypical ribs are the first, second, tenth, eleventh and twelfth.

The **first rib** has a head with one facet (A5), a prominent tubercle (A10), no angle and no costal groove. The shaft has superior and inferior surfaces.

The **second rib** has a head with two facets (B5), an angle (B1) near the tubercle (B10), a broad costal groove (B2) posteriorly, and an external surface facing upwards and outwards with the inner surface facing correspondingly downwards and inwards.

The **twelfth rib** has a head with one facet (F12) but there is no tubercle, no angle and no costal groove. The shaft tapers at its end (the ends of all other ribs widen slightly).

Left first rib (inner) and second rib (outer), attachments

H **from above**

I **from below**

Blue lines, epiphysial lines; green lines, capsule attachments of costovertebral joints

1. Area covered by pleura
2. Costoclavicular ligament
3. Intercostal muscles and membranes
4. Lateral costotransverse ligament
5. Levator costae
6. Scalenus anterior
7. Scalenus medius
8. Scalenus posterior
9. Serratus anterior
10. Serratus posterior superior
11. Subclavius
12. Superior costotransverse ligament
13. Suprapleural membrane

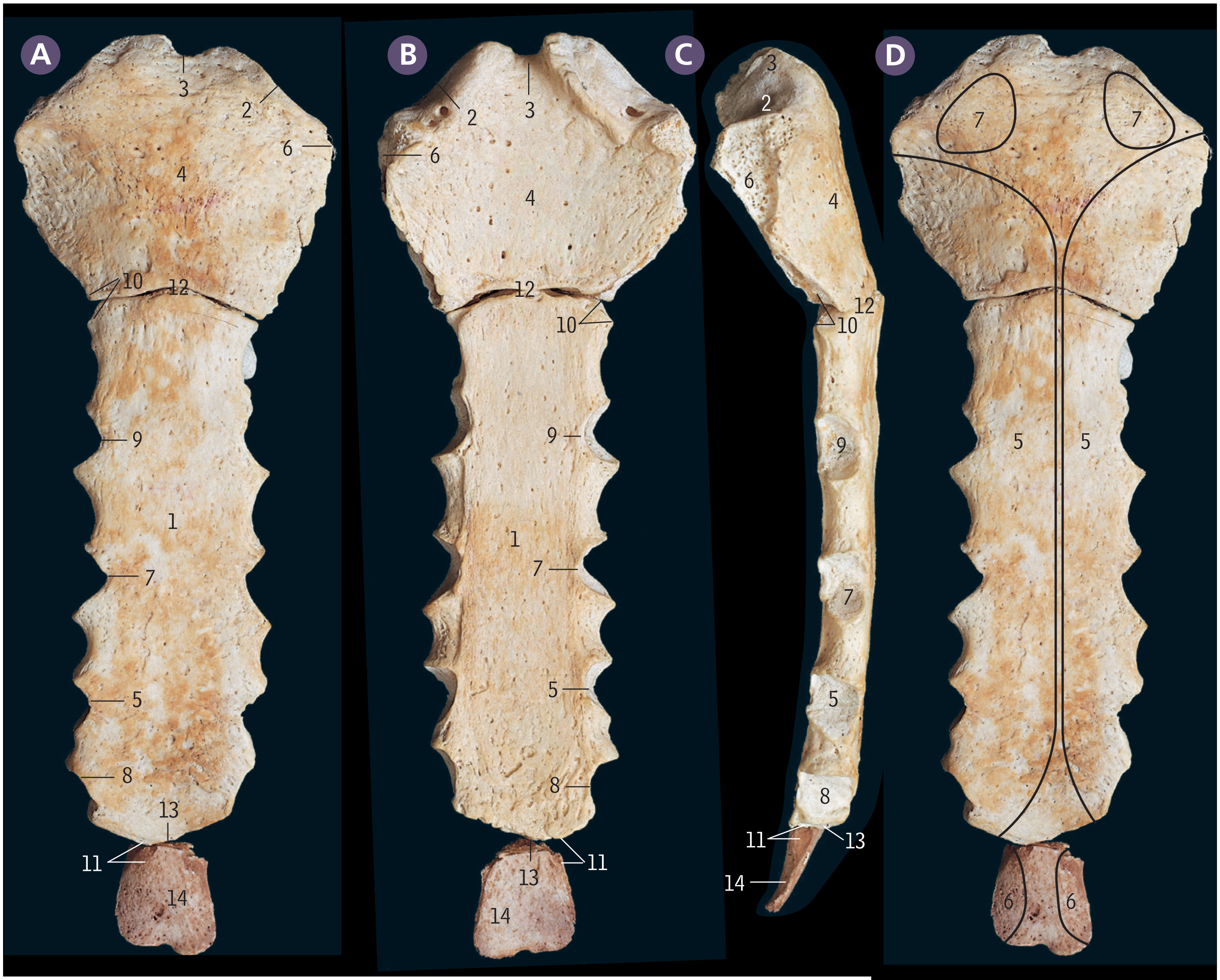

Sternum

A from the front

B from behind

C from the right

1 Body
2 Clavicular notch
3 Jugular notch
4 Manubrium
5 Notch for fifth costal cartilage
6 Notch for first costal cartilage
7 Notch for fourth costal cartilage
8 Notch for sixth costal cartilage
9 Notch for third costal cartilage
10 Notches for second costal cartilage
11 Notches for seventh costal cartilage
12 Sternal angle and manubriosternal joint
13 Xiphisternal joint
14 Xiphoid process

The sternum consists of the manubrium (4), body (1) and xiphoid process (14).

The body of the sternum (1) is formed by the fusion of four sternebrae, the sites of the fusion sometimes being indicated by three slight transverse ridges.

The manubrium (4) and body (1) are bony but the xiphoid process (14), which varies considerably in size and shape, is cartilaginous although it frequently shows some degree of ossification.

The manubriosternal and xiphisternal joints (12 and 13) are both symphyses, the surfaces being covered by hyaline cartilage and united by a fibrocartilaginous disc.

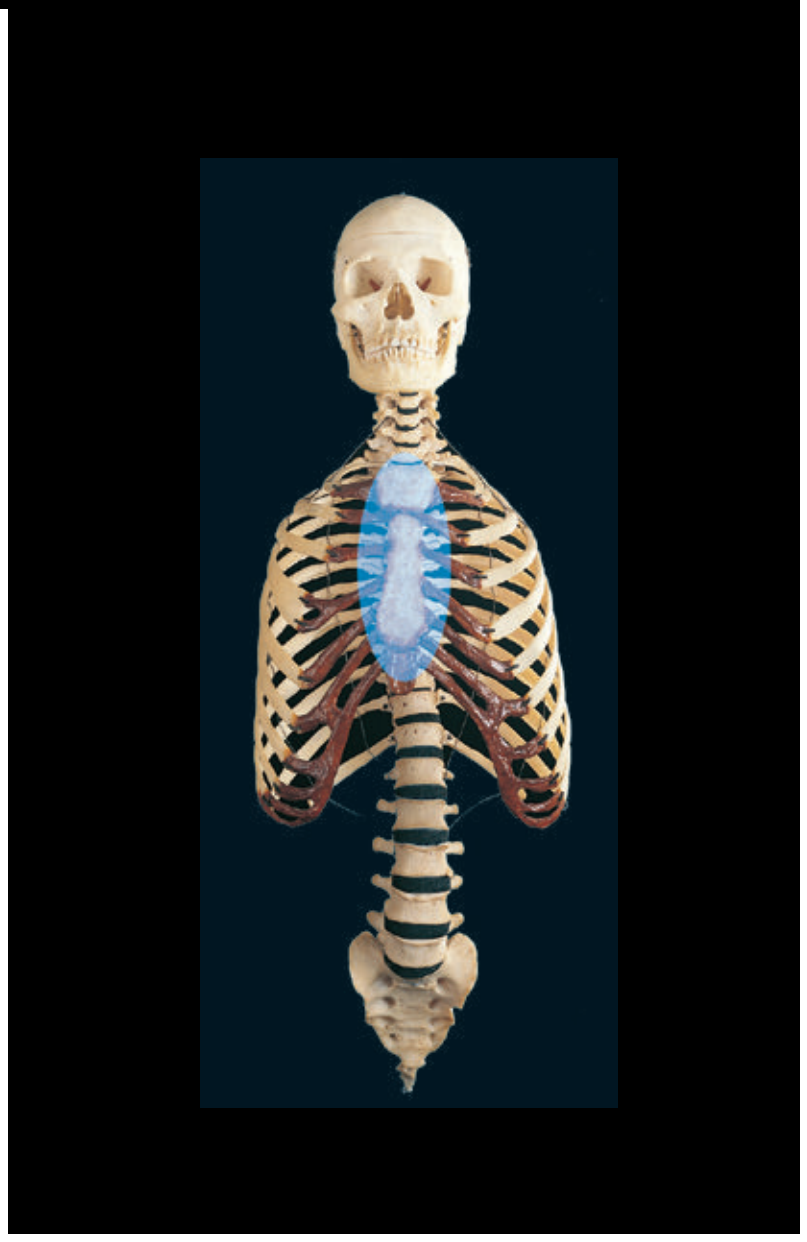

Median sternotomy, sternal variants, see pages 215–216.

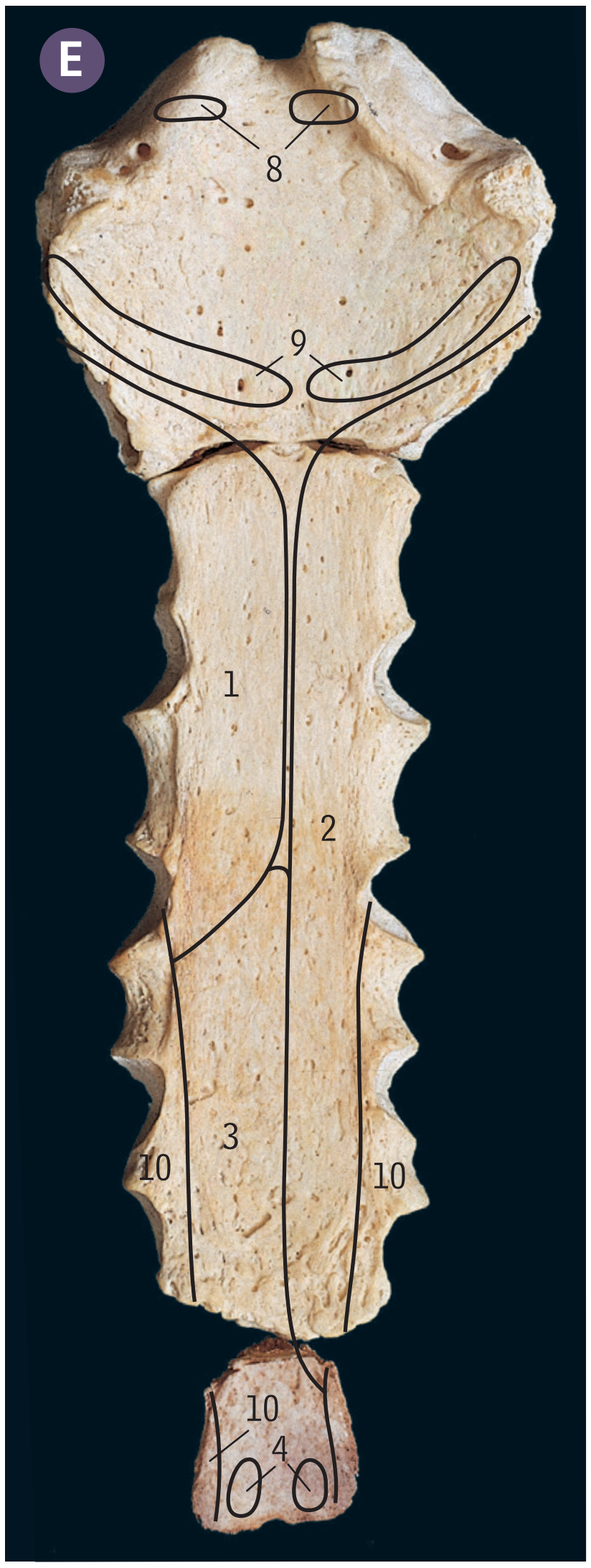

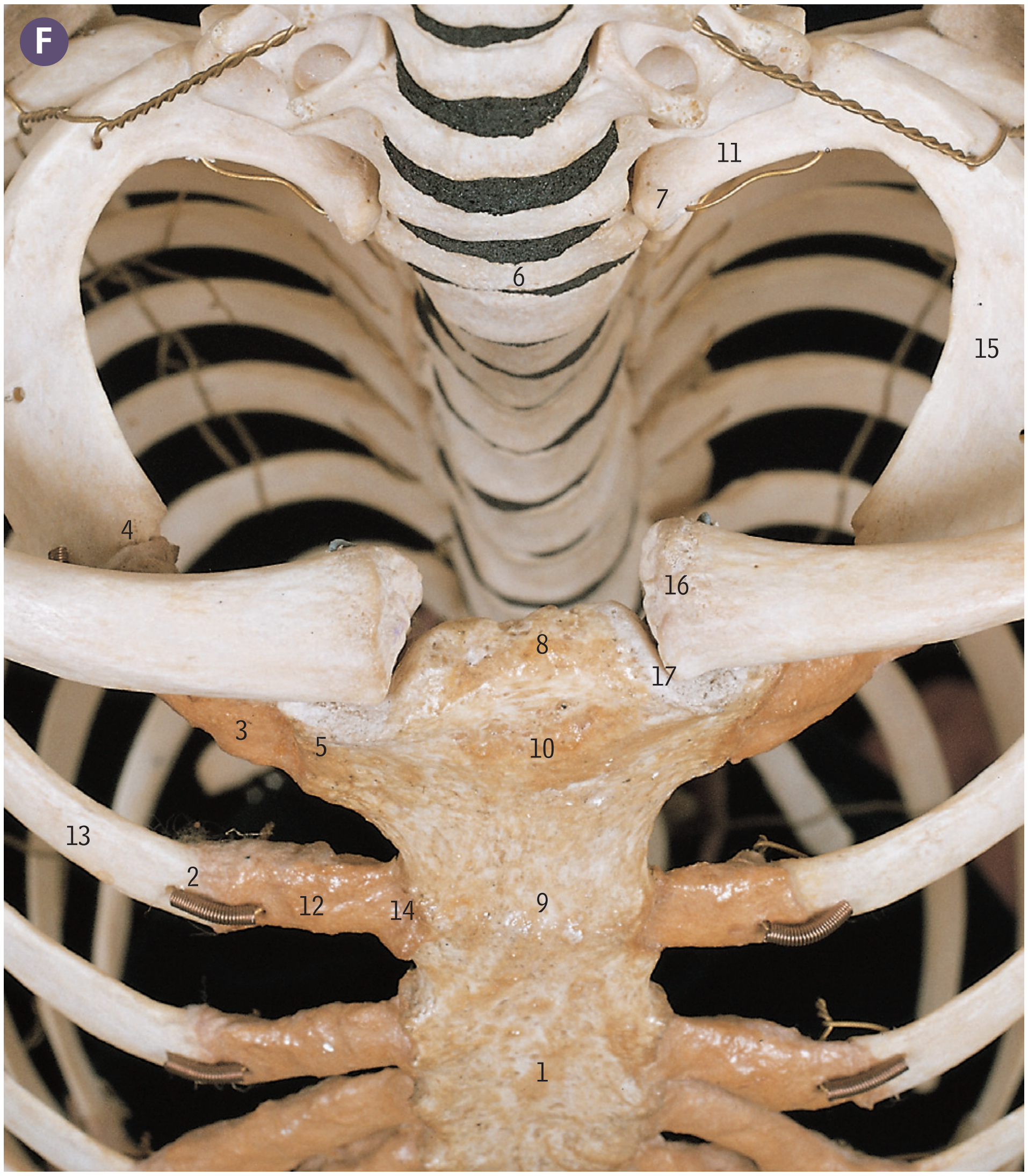

Sternum attachments

D from the front

E from behind

1. Area covered by left pleura
2. Area covered by right pleura
3. Area in contact with pericardium
4. Diaphragm
5. Pectoralis major
6. Rectus abdominis
7. Sternocleidomastoid
8. Sternohyoid
9. Sternothyroid
10. Transversus thoracis

The two pleural sacs are in contact from the levels of the second to fourth costal cartilages (E2 and 1).

F **Thoracic inlet** *in an articulated skeleton, from above and in front*

The thoracic inlet or outlet (upper aperture of the thorax) is approximately the same size and shape as the outline of the kidney, and is bounded by the first thoracic vertebra (6), first ribs (15), and costal cartilages (3) and the upper border of the manubrium of the sternum (jugular notch, 8). It does not lie in a horizontal plane but slopes downwards and forwards.

The second costal cartilage (12) joins the manubrium and body of the sternum (10 and 1) at the level of the manubriosternal joint (9). This is an important landmark, since the joint line is palpable as a ridge at the slight angle between the manubrium and body, and the second costal cartilage and rib can be identified lateral to it. Other ribs can be identified by counting down from the second.

1. Body of sternum
2. Costochondral joint
3. First costal cartilage
4. First costochondral joint
5. First sternocostal joint
6. First thoracic vertebra
7. Head of first rib
8. Jugular notch
9. Manubriosternal joint (angle of Louis)
10. Manubrium of sternum
11. Neck of first rib
12. Second costal cartilage
13. Second rib
14. Second sternocostal joint
15. Shaft of first rib
16. Sternal end of clavicle
17. Sternoclavicular joint

Costochondral pathology, flail chest, see pages 215–216.

Heart, left pleura and lung *surface markings, in the female*

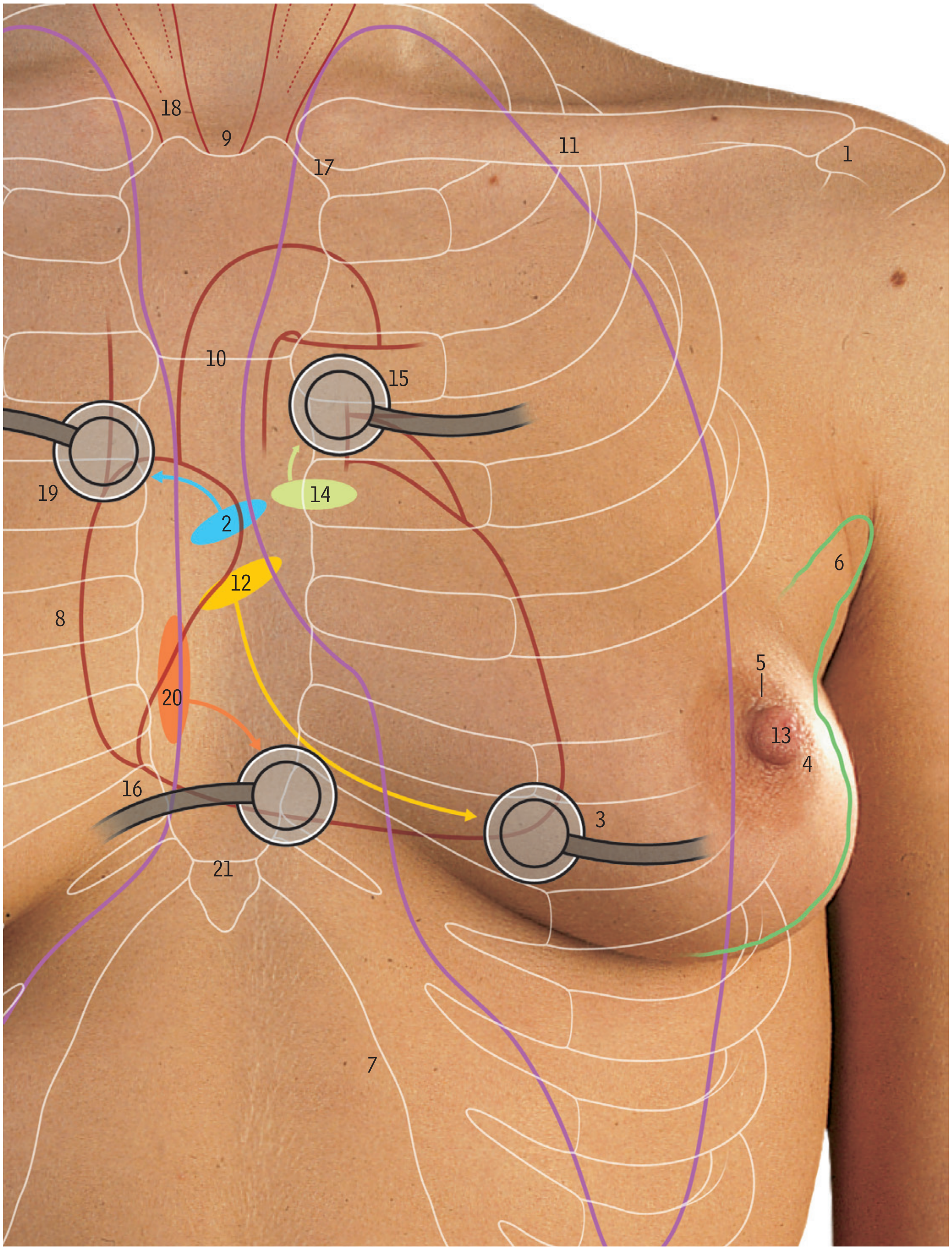

Brown line, heart; purple line, pleura; green line, axillary tail of breast

The positions of the four heart valves are indicated by coloured ellipses, and the sites where the sounds of the corresponding valves are best heard with the stethoscope are shown.

The manubriosternal joint (10) is palpable and a guide to identifying the second costal cartilage (15) which joins the sternum at this level (see page 177, F9, 14 and 12).

The pleura and lung extend into the neck for 2.5 cm above the medial third of the clavicle.

In the midclavicular line the lower limit of the *pleura* reaches the eighth costal cartilage, in the midaxillary line it reaches the tenth rib, and at the lateral border of the erector spinae muscle it crosses the twelfth rib. The lower border of the *lung* is about two ribs higher than the pleural reflection.

Behind the sternum, the pleural sacs are adjacent to one another in the midline from the level of the second to fourth costal cartilages, but then diverge owing to the mass of the heart on the left.

1 Acromioclavicular joint
2 Aortic valve
3 Apex of heart
4 Areola of breast
5 Areolar glands of breast
6 Axillary tail of breast (of Spence)
7 Costal margin (at eighth costal cartilage)
8 Fourth costal cartilage
9 Jugular notch
10 Manubriosternal joint
11 Midpoint of clavicle
12 Mitral valve
13 Nipple of breast
14 Pulmonary valve
15 Second costal cartilage
16 Sixth costal cartilage
17 Sternoclavicular joint
18 Sternocleidomastoid
19 Third costal cartilage
20 Tricuspid valve
21 Xiphisternal joint

Auscultation of heart sounds, see pages 215–216.

Female breast *mammary gland*

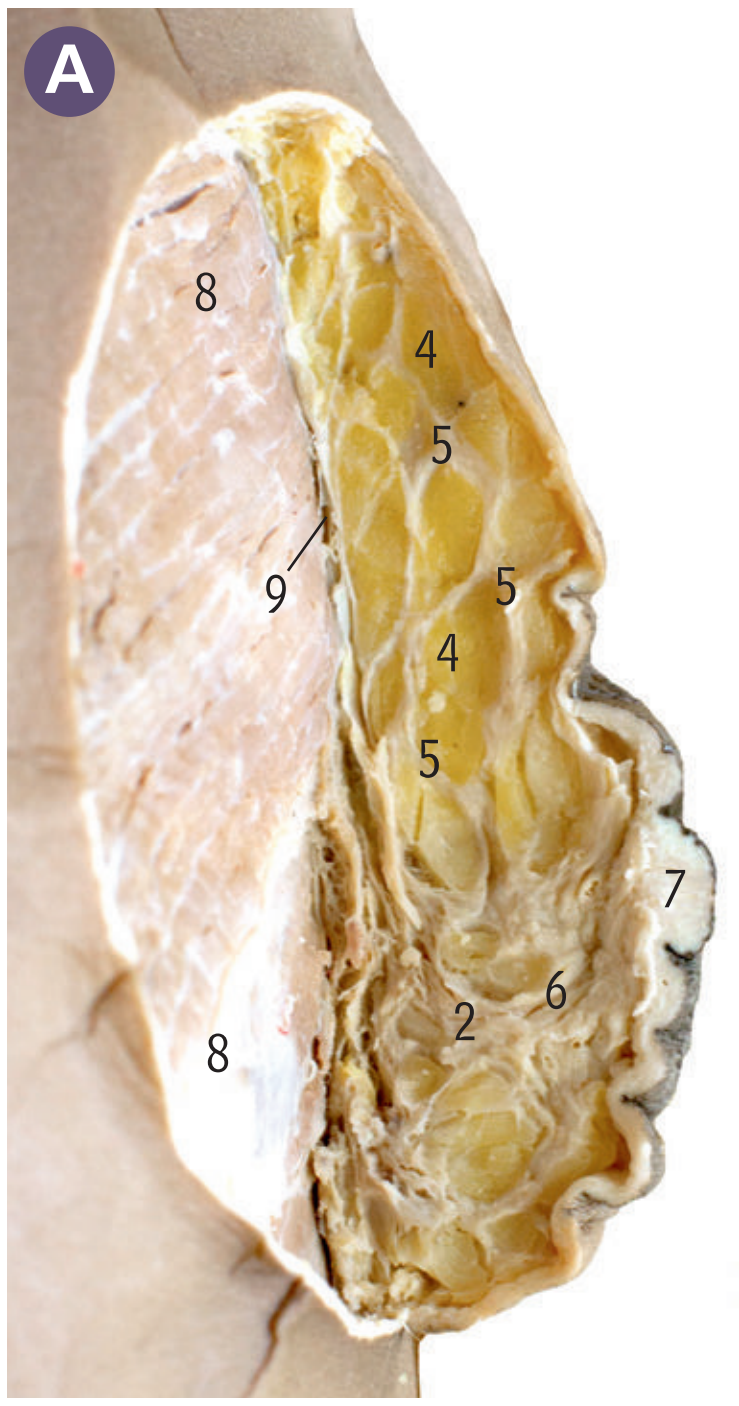

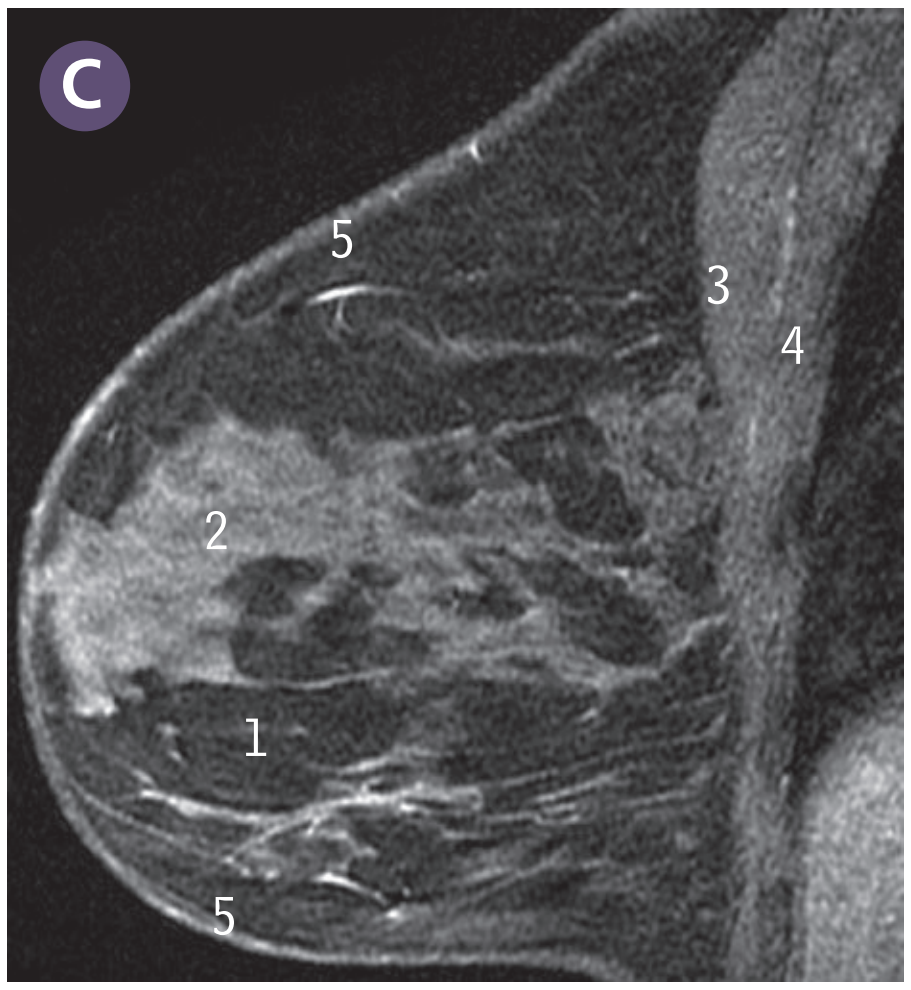

A **median parasagittal section**

B **dissection of areola, nipple and breast tissue**

C **MR sagittal breast**

1 Ampulla of lactiferous duct
2 Condensed glandular tissue
3 Fascia over pectoralis major muscle
4 Fat
5 Fibrous septum
6 Lactiferous duct
7 Nipple
8 Pectoralis major muscle
9 Retromammary space

1 Adipose tissue
2 Fibroglandular tissue
3 Pectoralis major muscle
4 Pectoralis minor muscle
5 Skin

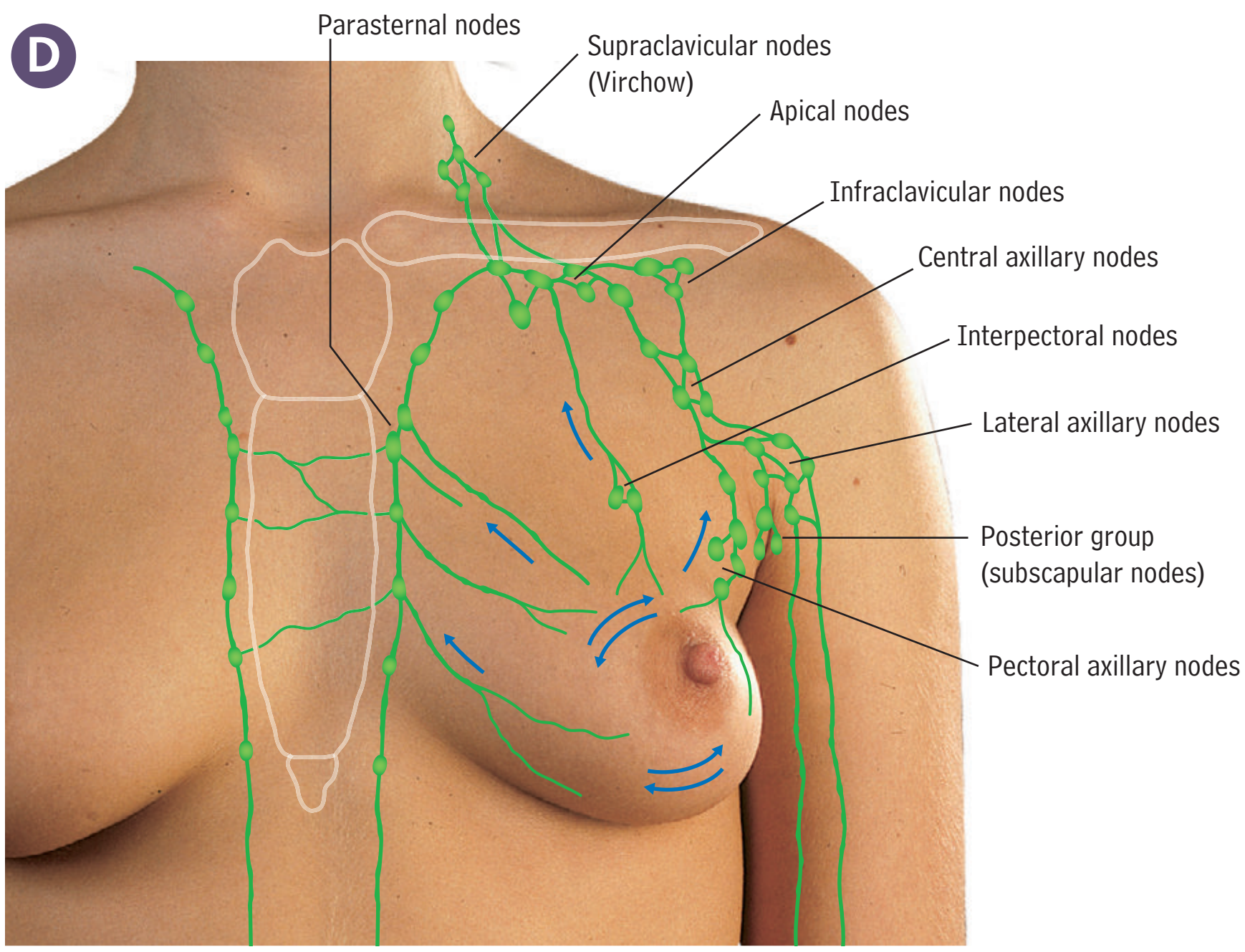

D Breast *lymph drainage*

There is a diffuse network of anastomosing lymphatic channels within the breast, including the overlying skin, and *lymph in any part may travel to any other part*. Larger channels drain most of the lymph to axillary nodes, but some from the medial part pass through the thoracic wall near the sternum to parasternal nodes adjacent to the internal thoracic vessels. These are the commonest and initial sites for cancerous spread, but other nodes may be involved (especially in the later spread of disease); these include infraclavicular and supraclavicular (deep cervical) nodes, nodes in the mediastinum, and nodes in the abdomen (via the diaphragm and rectus sheath). Spread to the opposite breast may also occur.

Breast examination, breast abnormalities, carcinoma of the breast, mastectomy, orange-peel skin, see pages 215–216.

A Right side of the thorax *from behind with the arm abducted*

With the arm fully abducted, the medial (vertebral) border of the scapula (5) comes to lie at an angle of about 60° to the vertical, and indicates approximately the line of the oblique fissure of the lung (interrupted line).

1 Deltoid
2 Fifth intercostal space
3 Inferior angle of scapula
4 Latissimus dorsi
5 Medial border of scapula
6 Spine of scapula
7 Spinous process of third thoracic vertebra
8 Teres major
9 Trapezius

The line of the oblique fissure of the lung runs from the level of the spine of the third thoracic vertebra (7) to the sixth costal cartilage at the lateral border of the sternum (see B). With the arm fully abducted, the vertebral border of the scapula (5) is a good guide to the direction of this fissure.

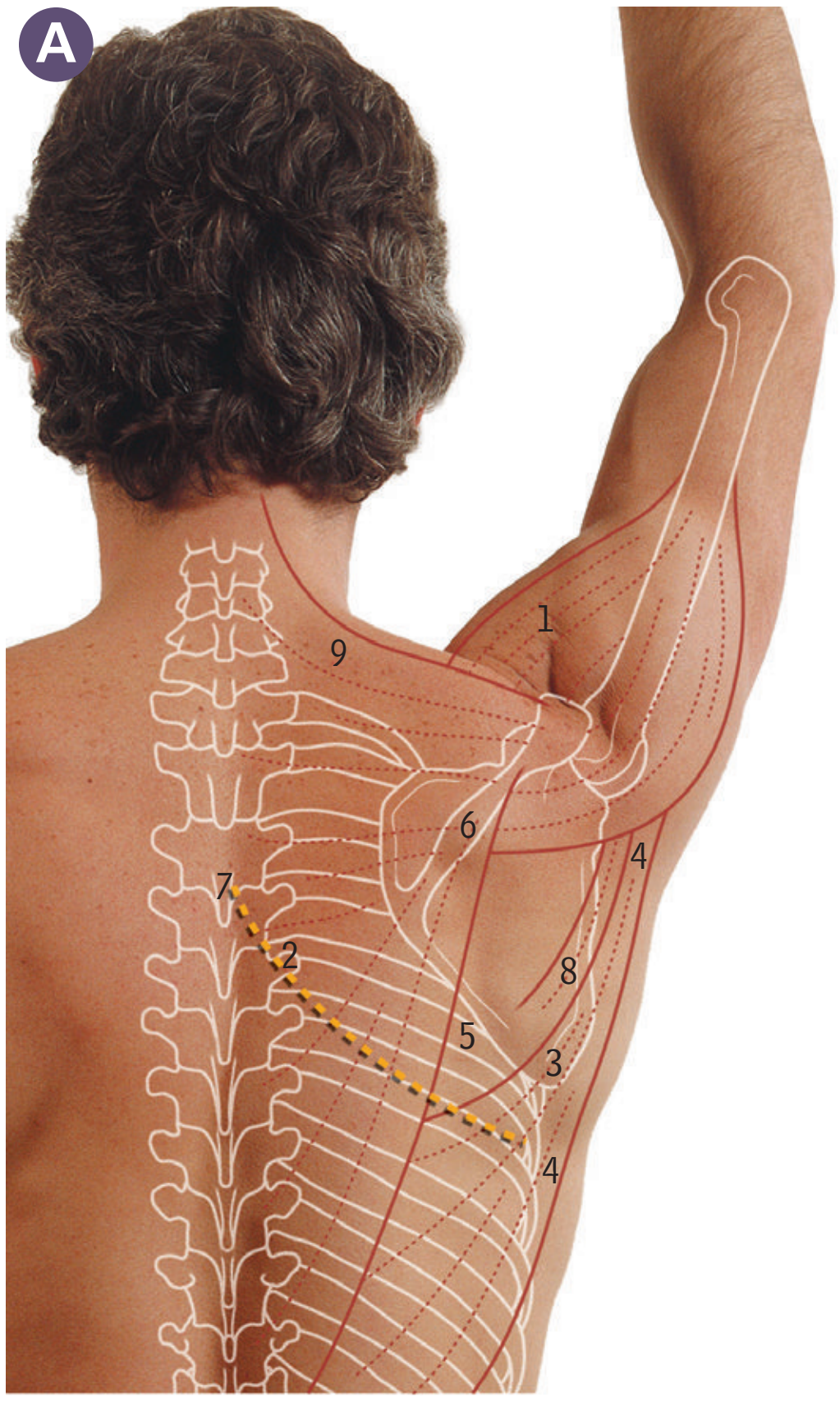

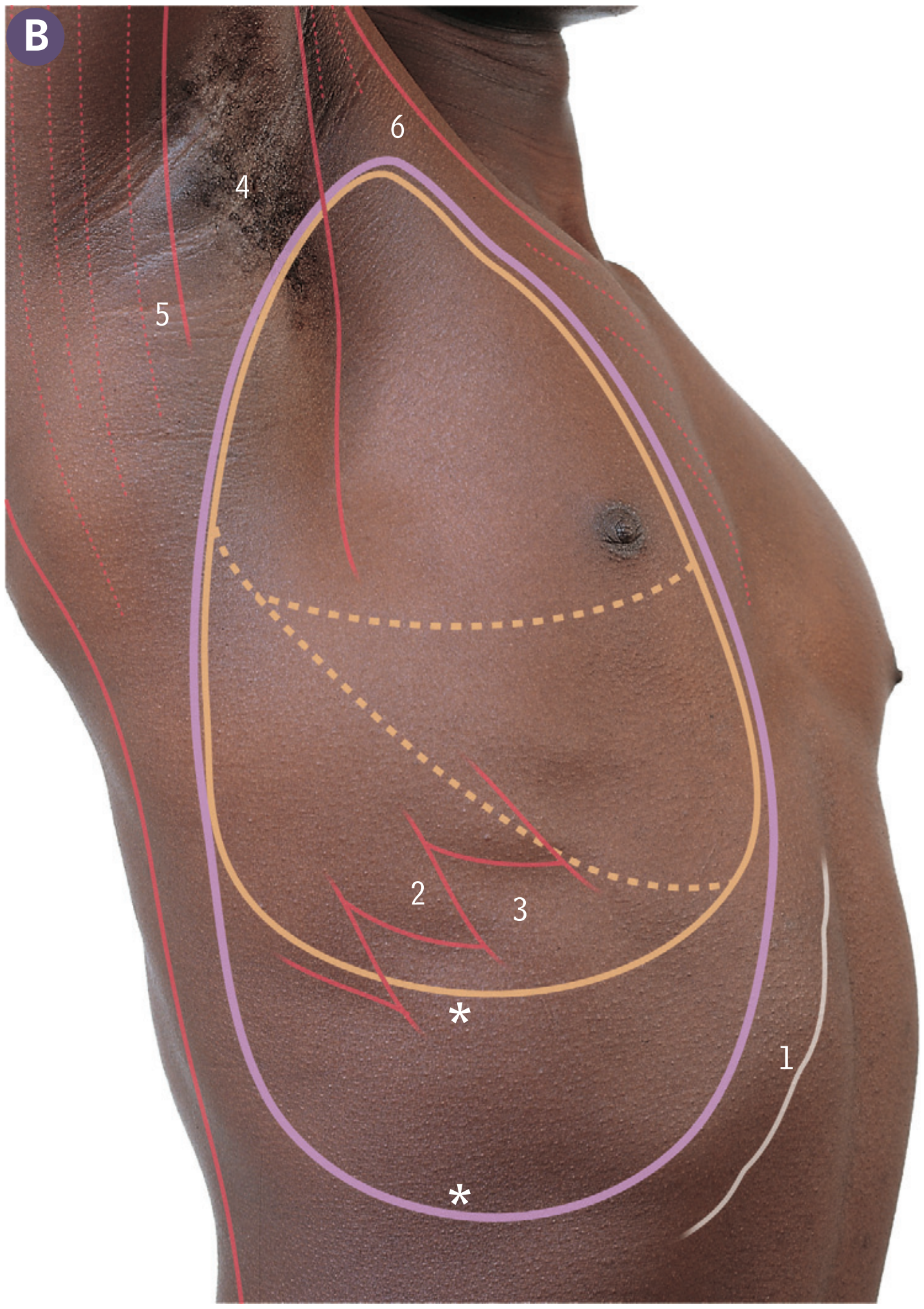

B Right side of the thorax *surface markings, from the right, with the arm abducted*

The purple line indicates the extent of the pleura, and the solid orange line the lower limit of the lung; note the gap between the two at the lower part of the thorax, indicating the costodiaphragmatic recess of pleura, which does not contain any lung. The transverse and oblique fissures of the lung are represented by the interrupted orange lines.

1 Costal margin
2 Digitations of serratus anterior
3 External oblique
4 Floor of axilla
5 Latissimus dorsi
6 Pectoralis major

The transverse fissure of the right lung is represented by a line drawn horizontally backwards from the fourth costal cartilage until it meets the line of the oblique fissure (described in A) running forwards to the sixth costal cartilage. The triangle so outlined indicates the middle lobe of the lung, with the superior lobe above it and the inferior lobe below and behind it. It is the area covered by the right breast.

On the left side, where the lung has only two lobes, superior and inferior, there is no transverse fissure; the surface marking for the oblique fissure is similar to that on the right.

* The asterisks represent the places where the lower edges of the lung and pleura cross the eighth and tenth ribs, respectively in the mid-axillary line.

Anterior chest wall muscles of the thorax

from the front

1 External intercostal muscle
2 External intercostal membrane
3 Internal intercostal muscle
4 Pectoralis minor muscle
5 Second costal cartilage
6 Second rib
7 Sixth costal cartilage
8 Sternal angle (Louis)
9 Xiphoid process

The fibres of the **external intercostal muscles** (1) run downwards and medially, and near the costochondral junctions (as between 5 and 6) give place to the anterior intercostal membrane (here removed); these are thin sheets of connective tissue through which the underlying internal intercostal muscles (3) can be seen.

The fibres of the **internal intercostal muscles** (3) run downwards and laterally. At the front, they are covered by the anterior intercostal membranes, and at the back of the thorax they give place to the posterior intercostal membranes. The different directions of the muscle fibres enable the two muscle groups to be distinguished – down and medially for the externals (1), down and laterally for the internals (3).

The seventh costal cartilage is the lowest to join the sternum and together with the eighth, ninth and tenth cartilages forms the costal margin.

Coronal CT of chest

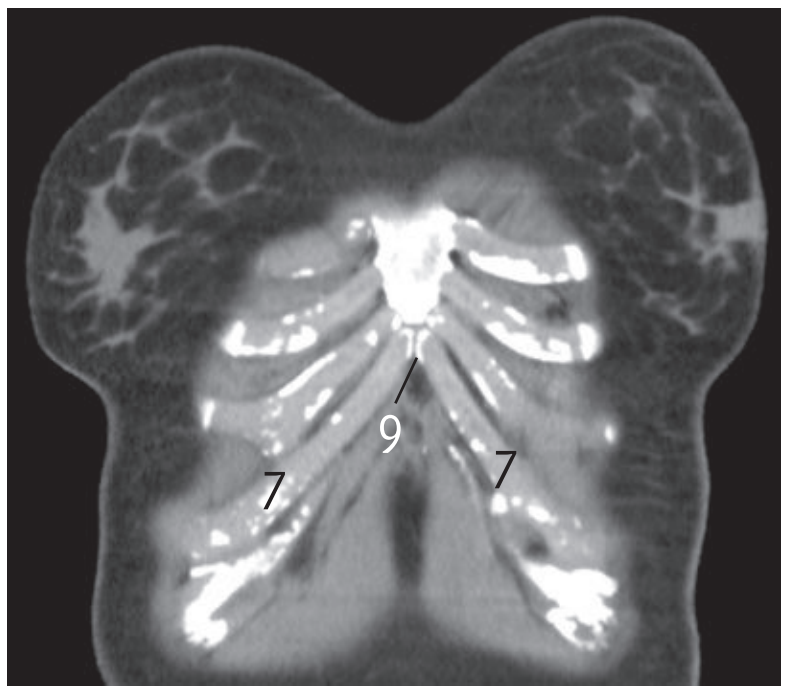

Flail chest, see pages 215–216.

Muscles of the thorax *right intercostal muscles*

A from the outside

B from the inside

1. Eighth rib
2. External intercostal
3. Fifth intercostal nerve
4. Fifth posterior intercostal artery
5. Fifth posterior intercostal vein
6. Fifth rib
7. Fourth rib
8. Innermost intercostal
9. Internal intercostal
10. Pleura
11. Seventh rib
12. Sixth intercostal nerve
13. Sixth rib

The **internal intercostal muscles** are continuous posteriorly with the posterior intercostal membranes which are covered up by the medial ends of the external intercostals (as at 2).

A



B



In A, each intercostal space has been dissected to a different depth, showing from above downwards an external intercostal muscle (2), internal intercostal (9), innermost intercostal (8) and pleura (10). The main intercostal vessels and nerve lie between the internal and innermost muscles; the nerve (12) is seen in the sixth interspace immediately below the sixth rib (13) and lying on the outer surface of the innermost intercostal (8), but the artery and vein are under cover of the costal groove. The vessels as well as the nerve are seen in the fifth intercostal space when this is dissected from the inside of the thorax, as in B; here the pleura and innermost intercostal muscle have been removed, and the vessels (5 and 4) and fifth intercostal nerve (3) lie against the inner surface of the internal intercostal (9).

Intercostal nerve block, see pages 215–216.

Muscles of the thorax

A *internal view thorax, from behind (inside view)*

B *left lower intercostal muscles*

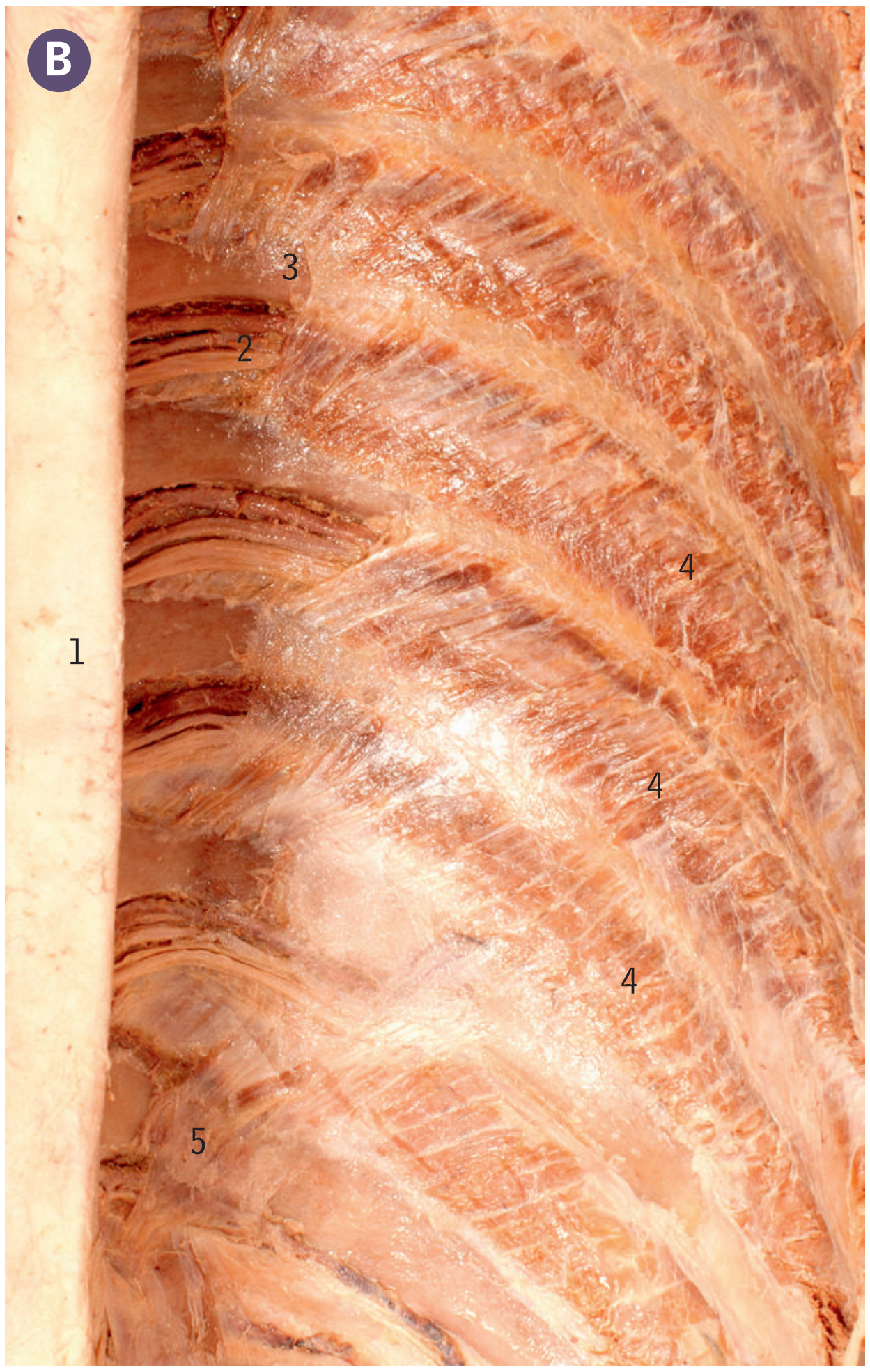

This view of the internal surface of the thoracic wall shows the posterior surface of the right half of the sternum and adjacent wall, with the pleura removed. The internal thoracic artery (4) is seen passing deep to the slips of transversus thoracis (9, previously called sternocostalis).

1 Anterior intercostal vein
2 Body of sternum
3 Innermost intercostal membrane
4 Internal intercostal muscle
5 Internal thoracic artery
6 Internal thoracic veins
7 Second rib
8 Sixth rib
9 Slips of transversus thoracis muscle
10 Sternal angle (Louis)
11 Xiphoid process

This view of the lower left hemithorax is seen from the right and in front, with the pleura, vessels and nerves removed, and shows part of the innermost layer of thoracic wall muscles (4).

1 Descending thoracic aorta
2 Eighth intercostal neurovascular bundle
3 Eighth rib
4 Innermost intercostal muscle
5 Twelfth rib

Costochondral pathology, see pages 215–216.

Lungs, pericardium and pleura *from the front*

1 Costodiaphragmatic recess
2 Diaphragm
3 Fibrous pericardium
4 Inferior lobe of left lung
5 Inferior lobe of right lung
6 Intercostal muscles
7 Line of anterior reflection of left pleura
8 Line of anterior reflection of right pleura
9 Middle lobe of right lung
10 Oblique fissure of left lung
11 Oblique fissure of right lung
12 Parietal pericardium
13 Parietal diaphragmatic pleura
14 Sternocleidomastoid
15 Second rib
16 Seventh rib
17 Superior lobe of left lung
18 Superior lobe of right lung
19 Thymic remnants, see page 360
20 Transverse fissure of right lung
21 Visceral pericardium overlying myocardium
22 Visceral pleura

Cardiopulmonary resuscitation (CPR), thymus, see pages 215–216.

Heart and pericardium

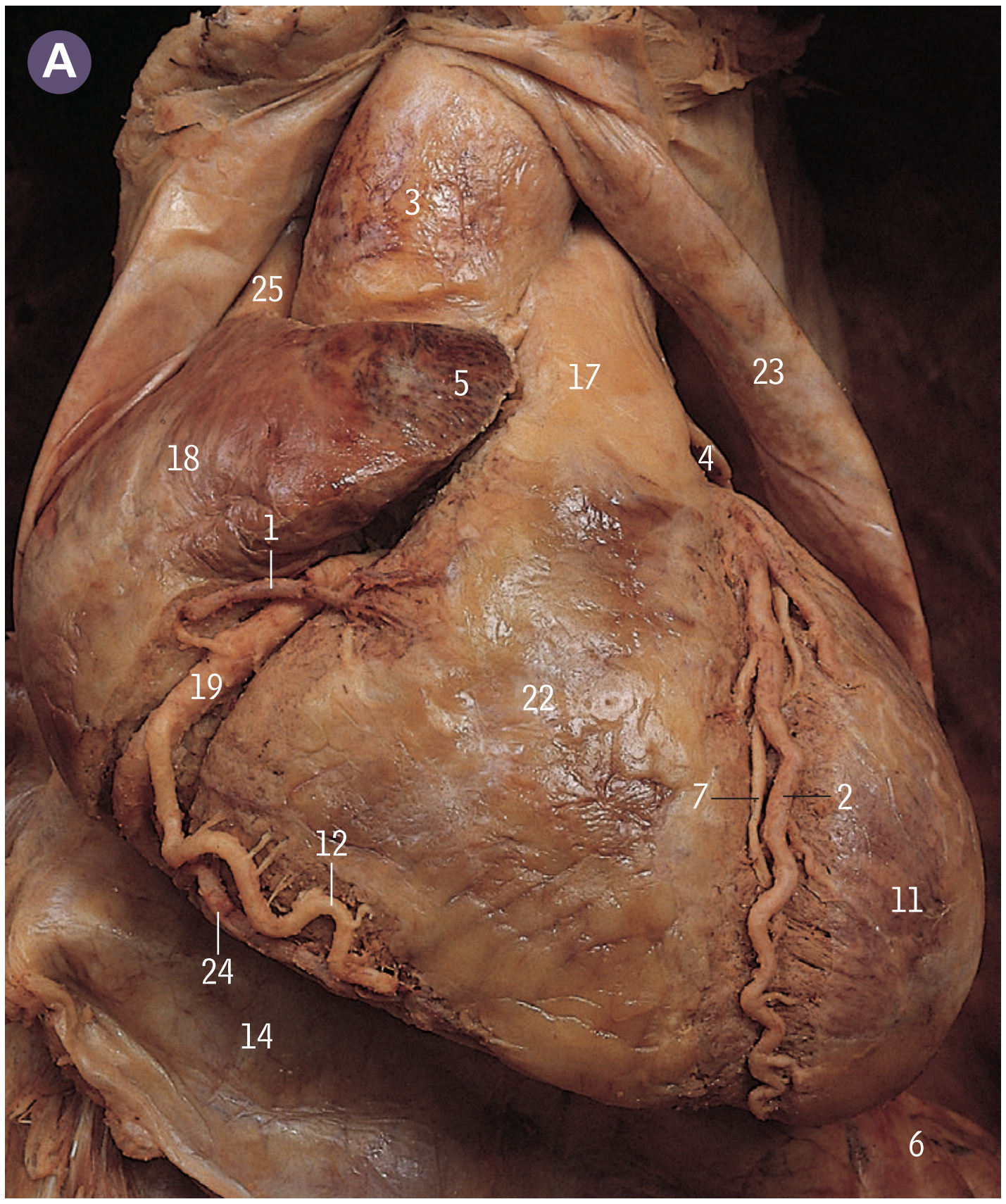

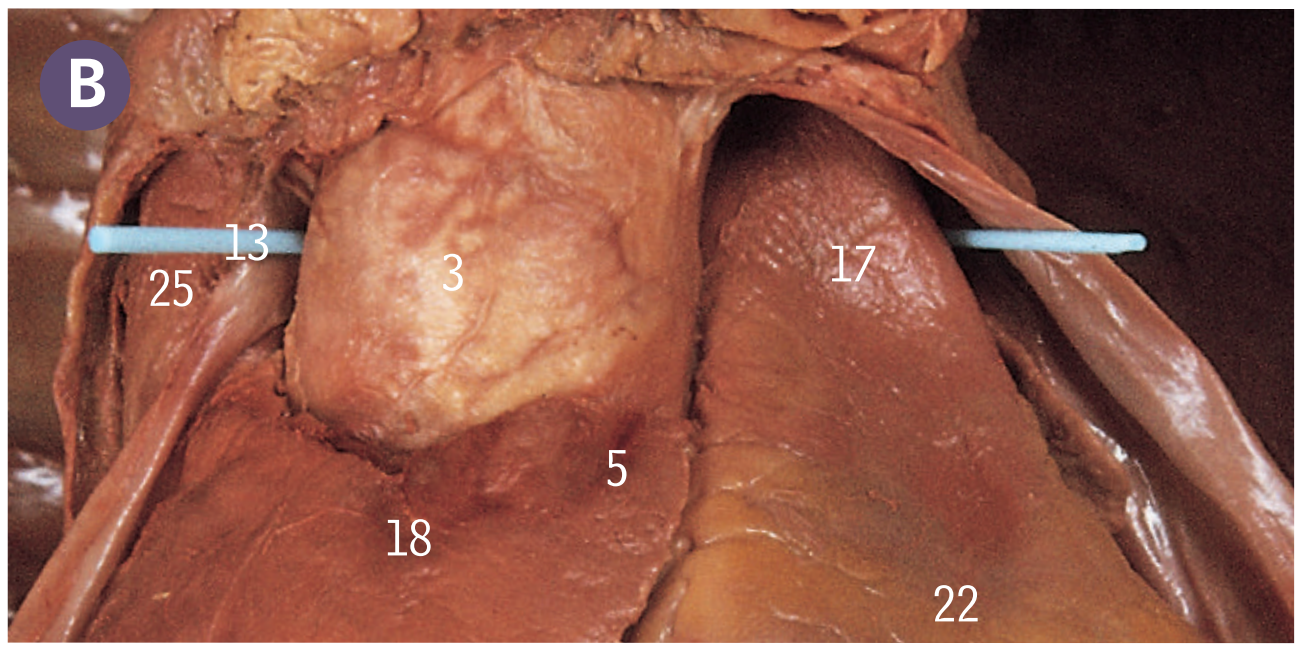

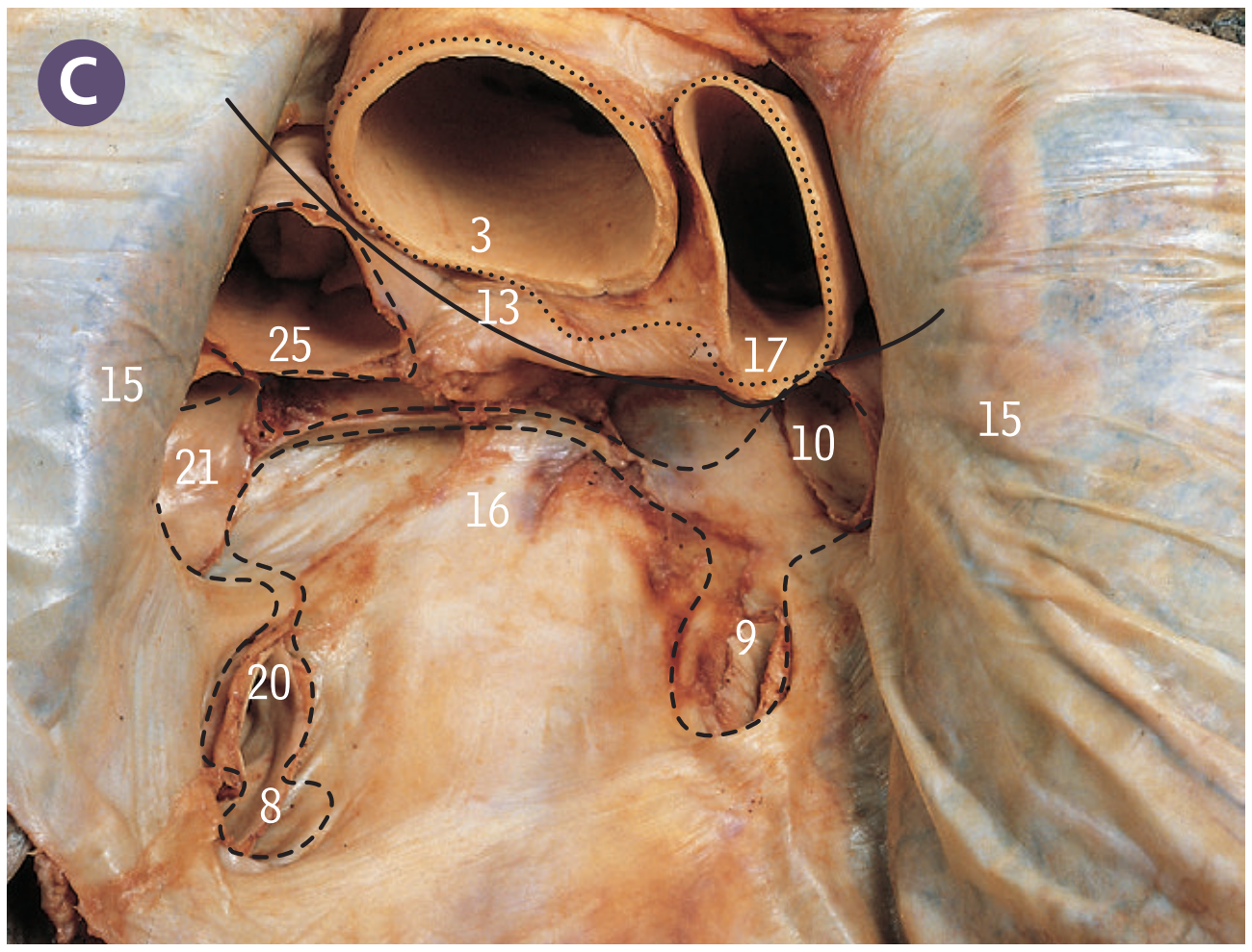

A from the front

B with marker in the transverse sinus

C oblique sinus after removal of the heart

1 Anterior cardiac vein
2 Anterior interventricular branch of left coronary artery
3 Ascending aorta
4 Auricle of left atrium
5 Auricle of right atrium
6 Diaphragm
7 Great cardiac vein
8 Inferior vena cava
9 Left inferior pulmonary vein
10 Left superior pulmonary vein
11 Left ventricle
12 Marginal branch of right coronary artery
13 Marker in transverse sinus
14 Pericardium fused with central tendon of diaphragm
15 Pericardium turned laterally over lung
16 Posterior wall of pericardial cavity and oblique sinus
17 Pulmonary trunk
18 Right atrium
19 Right coronary artery
20 Right inferior pulmonary vein
21 Right superior pulmonary vein
22 Right ventricle
23 Serous pericardium overlying fibrous pericardium (turned laterally)
24 Small cardiac vein
25 Superior vena cava

The **right border of the heart** is formed by the right atrium (A18).

The **left border** is formed mostly by the left ventricle (A11) with at the top the uppermost part (infundibulum) of the right ventricle (A22) and the tip of the left auricle (A4).

The **inferior border** is formed by the right ventricle (A22) with a small part of the left ventricle at the apex.

Anterior interventricular branch of left coronary artery = **left anterior descending (LAD)** as often used by clinicians.

In A, the pericardium has been incised and turned back (23) to display the anterior surface of the heart. The pulmonary trunk (17) leaves the right ventricle (22) in front and to the left of the ascending aorta (3), which is overlapped by the auricle (5) of the right atrium (18). The superior vena cava (25) is to the right of the aorta and still largely covered by pericardium. The anterior interventricular branch (2) of the left coronary artery and the great cardiac vein (7) lie in the interventricular groove between the right and left ventricles (22 and 11), and the right coronary artery (19) is in the atrioventricular groove between the right ventricle (22) and right atrium (18). In B, only the upper part of another heart is shown, with a marker in the transverse sinus, the space behind the aorta (3) and pulmonary trunk (17). In C, the heart has been removed from the pericardium, leaving the orifices of the great vessels. The dotted line indicates the attachment of the single sleeve of serous pericardium surrounding the aorta (3) and pulmonary trunk (17). The interrupted line indicates the attachment of another more complicated but still single sleeve of serous pericardium surrounding all the other six great vessels (the four pulmonary veins, 10, 9, 20 and 21, and the superior and inferior venae cavae, 25 and 8). The narrow interval between the two sleeves is the transverse sinus; the solid line in C indicates the path of the marker in B. The area of the pericardium (16) between the pulmonary veins and limited above by the reflection of the serious pericardium on to the back of the heart is the oblique sinus.

Cardiac tamponade, pericardial effusion, see pages 215–216.

Heart *with blood vessels injected* A *from the front* B *from behind*

A

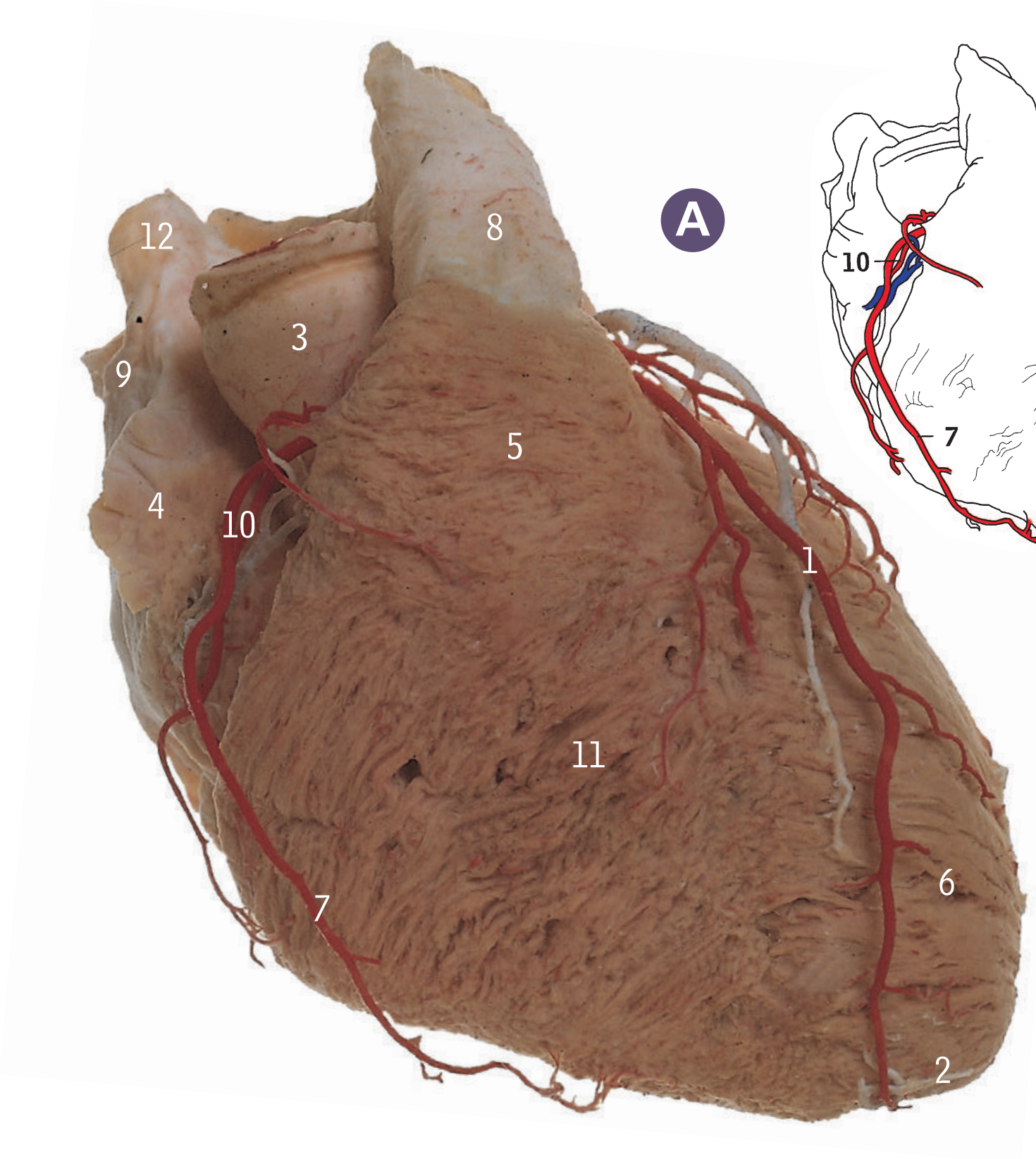

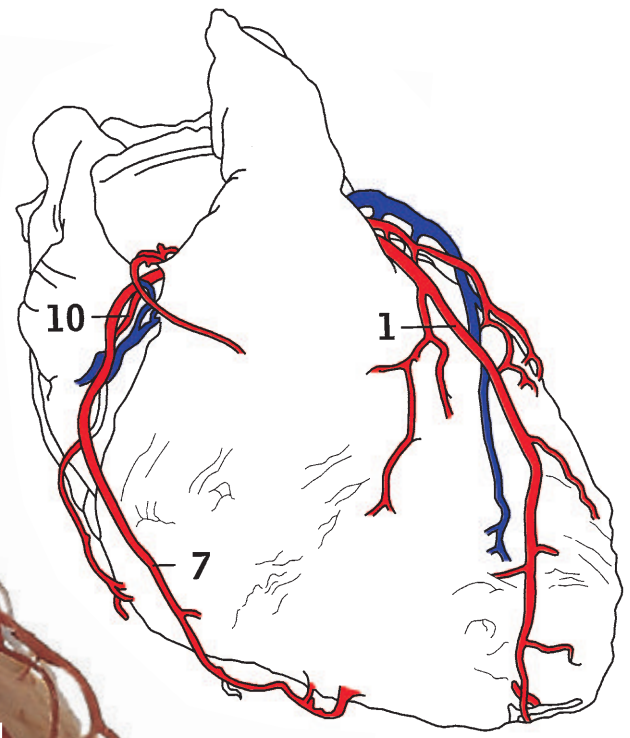

The coronary arteries have been injected with red latex and the cardiac veins with grey latex. The pulmonary trunk (8) passes upwards from the infundibulum (5) of the right ventricle (11), and at its commencement it is just in front and to the left of the ascending aorta (3).

1 Anterior interventricular branch of left coronary artery and great cardiac vein in interventricular groove
2 Apex
3 Ascending aorta
4 Auricle of right atrium (displaced laterally)
5 Infundibulum of right ventricle (conus arteriosus)
6 Left ventricle
7 Marginal branch of right coronary artery
8 Pulmonary trunk
9 Right atrium
10 Right coronary artery in anterior atrioventricular groove
11 Right ventricle
12 Superior vena cava

The *sternocostal* surface of the heart is the *anterior* surface (as seen in A on page 185 and A here) formed mainly by the right ventricle (A11, D7), with parts of the left ventricle (A6) and right atrium (A9 and D10).

The *apex* of the heart (A2) is formed by the left ventricle.

The *base* of the heart is the *posterior* surface, formed mainly by the left atrium (B8) with a small part of the right atrium (B13).

The *inferior* surface is the *diaphragmatic* surface, formed by the two ventricles (mainly the left) (B10 and B15).

Anterior interventricular branch of left coronary artery = *left anterior descending (LAD)* as often used by clinicians.

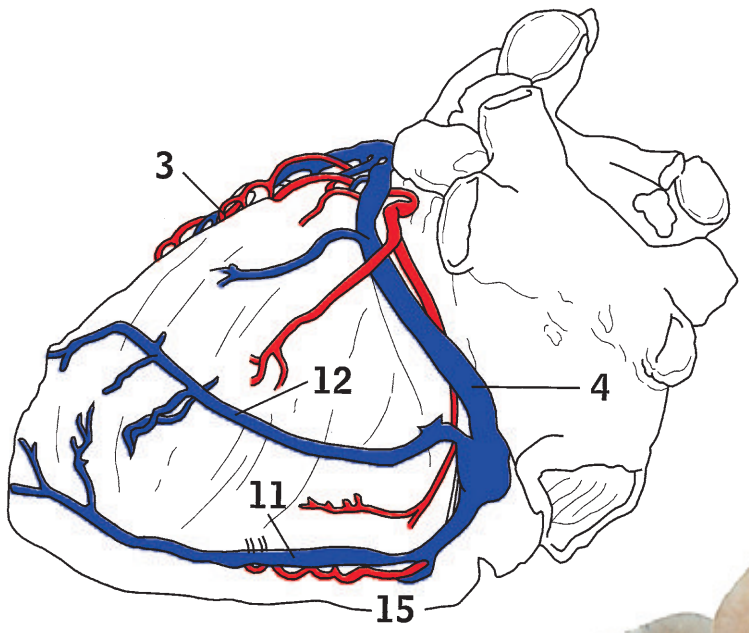

B

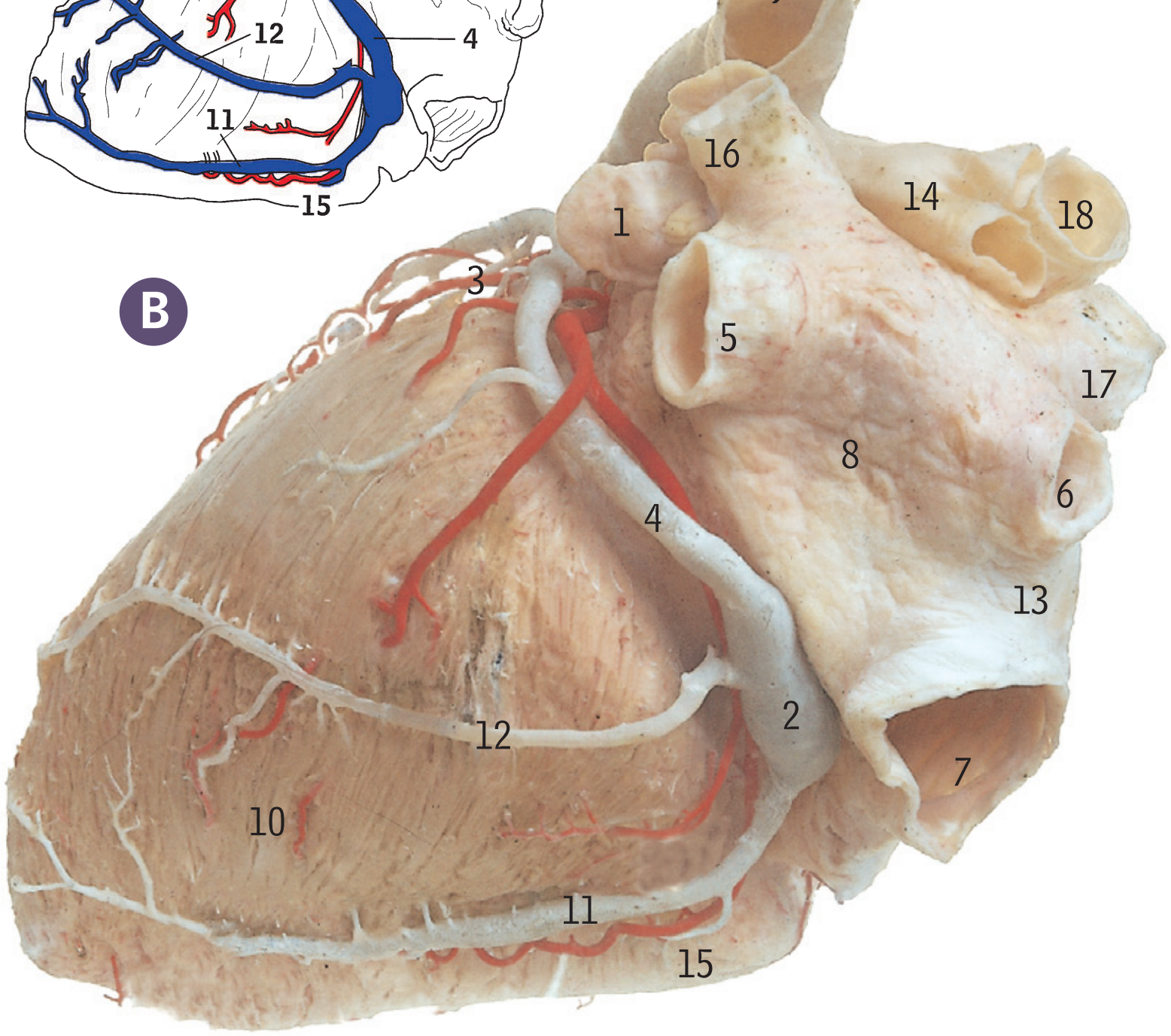

1 Auricle of left atrium
2 Coronary sinus in posterior atrioventricular groove
3 Great cardiac vein and anterior interventricular branch of left coronary artery
4 Great cardiac vein and circumflex branch of left coronary artery
5 Inferior left pulmonary vein
6 Inferior right pulmonary vein
7 Inferior vena cava
8 Left atrium
9 Left pulmonary artery
10 Left ventricle
11 Middle cardiac vein and posterior interventricular branch of right coronary artery in posterior interventricular groove
12 Posterior vein of left ventricle
13 Right atrium
14 Right pulmonary artery
15 Right ventricle
16 Superior left pulmonary vein
17 Superior right pulmonary vein
18 Superior vena cava

Coronary artery bypass grafting (CABG), myocardial infarction, see *pages 215–216.*

C Right atrium *from the front and right*

The anterior wall has been incised near its left margin and reflected to the right, showing on its internal surface the vertical crista terminalis (2) and horizontal pectinate muscles (7). The fossa ovalis (3) is on the interatrial septum, and the opening of the coronary sinus (6) is to the left of the inferior vena caval opening (4).

1 Auricle
2 Crista terminalis
3 Fossa ovalis
4 Inferior vena cava
5 Limbus
6 Opening of coronary sinus
7 Pectinate muscles
8 Position of atrioventricular node
9 Position of intervenous tubercle (lower)
10 Superior vena cava
11 Tricuspid valve
12 Valve of coronary sinus (Thebesian valve)
13 Valve of inferior vena cava (Eustachian valve)

The fossa ovalis (3) forms part of the interatrial septum, and is part of the embryonic primary septum.

The limbus (5), which forms the margin of the fossa ovalis (3), represents the lower margin of the embryonic secondary septum. Before the primary and secondary septa fuse (at birth), the gap between them forms the foramen ovale.

The sinuatrial node (SA node, not illustrated) is embedded in the anterior wall of the atrium at the upper end of the crista terminalis, just below the opening of the superior vena cava.

The atrioventricular node (AV node, 8) is embedded in the interatrial septum, just above and to the left of the opening of the coronary sinus (6).

D Right ventricle *from the front*

1 Anterior cusp of tricuspid valve
2 Anterior papillary muscle
3 Ascending aorta
4 Auricle of right atrium
5 Chordae tendineae
6 Inferior vena cava
7 Infundibulum of right ventricle (conus arteriosus)
8 Posterior papillary muscle
9 Pulmonary trunk
10 Right atrium
11 Septomarginal trabeculation (moderator band)
12 Septal papillary muscle (of conus)
13 Superior vena cava

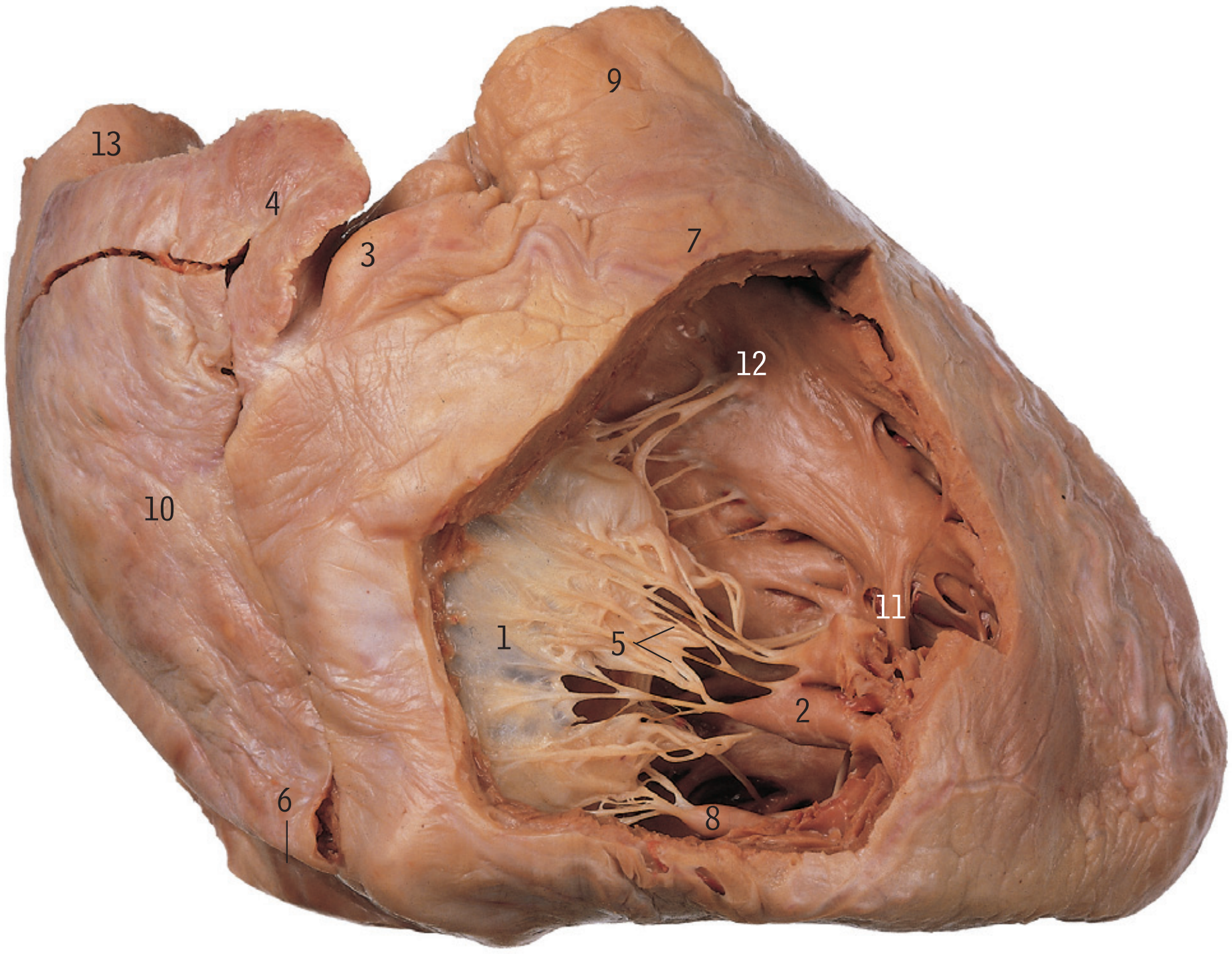

The septomarginal trabeculum (11), which conducts part of the right limb of the atrioventricular bundle from the interventricular septum (13) to the anterior papillary muscle (2), was formerly known as the moderator band.

The chordae tendineae (5) connect the cusps of the tricuspid valve to the papillary muscles.

Artificial cardiac pacemaker, cardiac pacemaker, left ventricular enlargement, see pages 215–216.

A Left ventricle
from the left and below

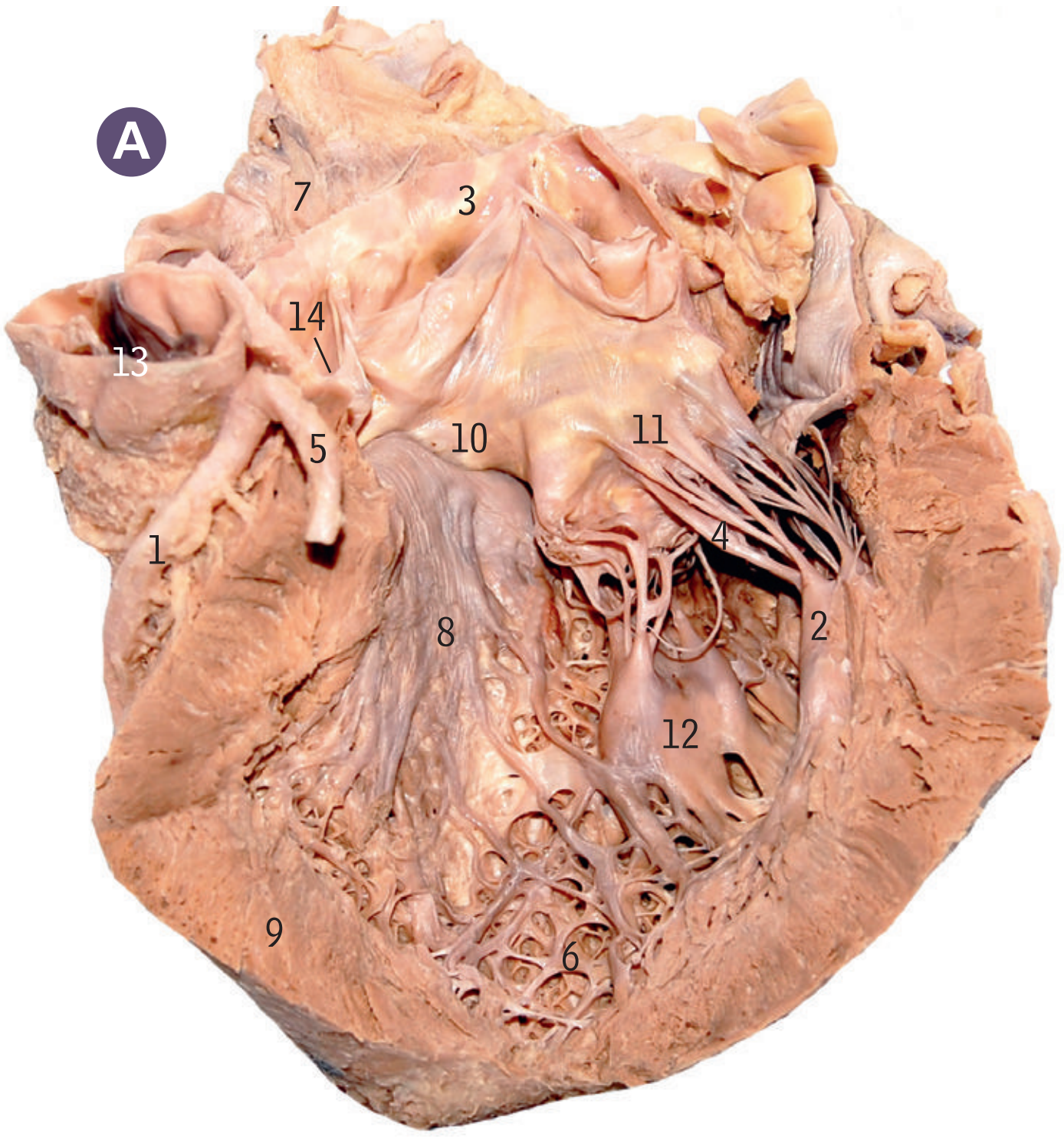

1 Anterior interventricular artery
2 Anterolateral papillary muscle
3 Aorta
4 Chordae tendineae
5 Circumflex coronary artery
6 Coarse trabeculations
7 Left atrium
8 Left bundle branch
9 Left ventricle open
10 Membranous septum
11 Mitral valve
12 Posteromedial papillary muscle
13 Pulmonary valve
14 Right coronary orifice

B Heart
coronal section of the ventricles

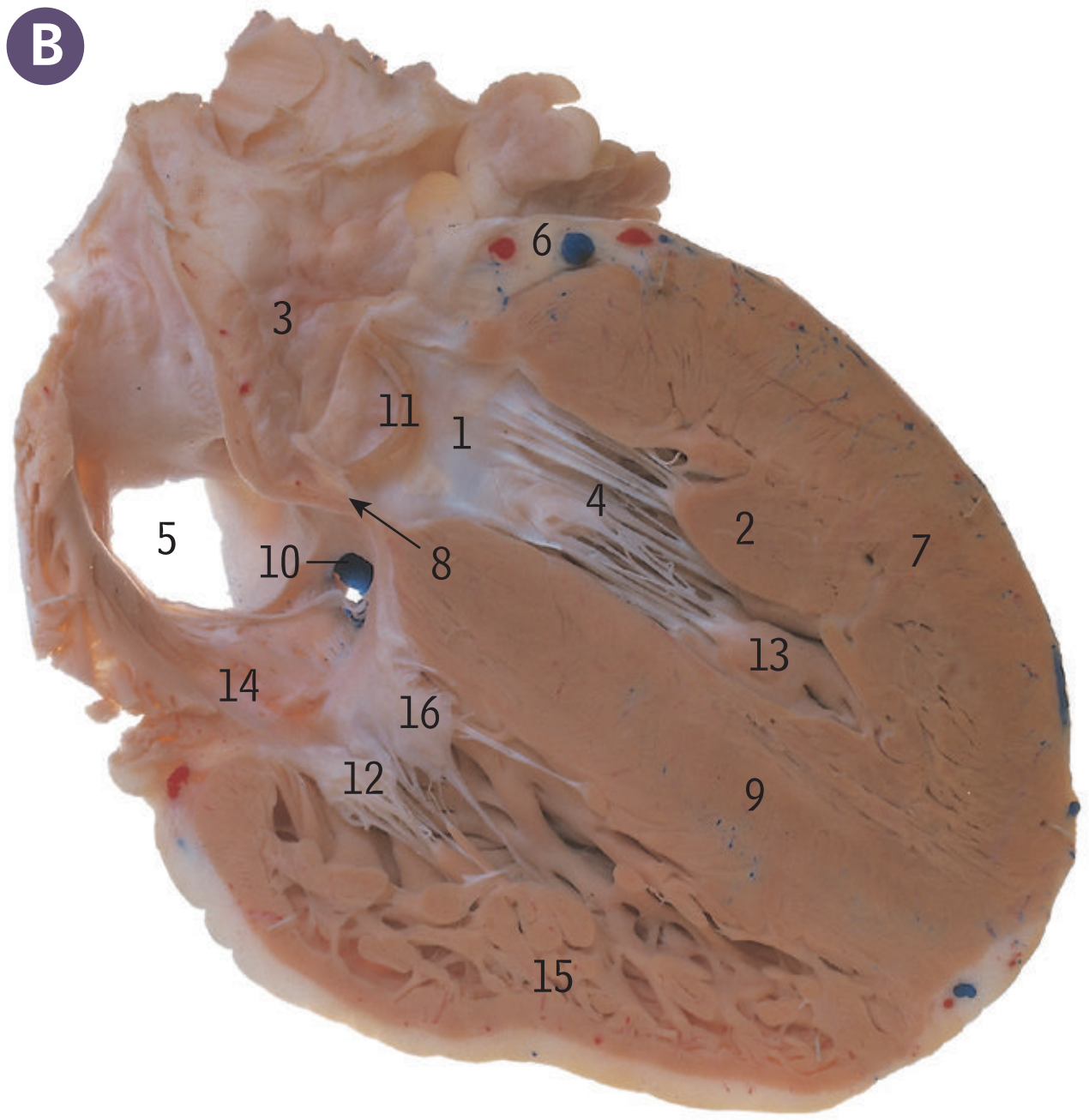

The heart has been cut in two in the coronal plane, and this is the posterior section seen from the front, looking towards the back of both ventricles. The section has passed immediately in front of the anterior cusp of the mitral valve (1) and the posterior cusp of the aortic valve (11).

The cusps of the aortic and pulmonary valves are here given their official names but some English texts use slightly different alternatives, as follows:

	Official	English
Aortic	Right	Anterior
	Left	Left posterior
	Posterior	Right posterior
Pulmonary	Left	Posterior
	Anterior	Left anterior
	Right	Right anterior

1 Anterior cusp of mitral valve
2 Anterolateral papillary muscle
3 Ascending aorta
4 Chordae tendineae
5 Inferior vena cava
6 Left coronary artery branches and great cardiac vein
7 Left ventricular wall
8 Membranous part of interventricular septum
9 Muscular part of interventricular septum
10 Opening of coronary sinus
11 Posterior cusp of aortic valve
12 Posterior cusp of tricuspid valve
13 Posterior papillary muscle
14 Right atrium
15 Right ventricular wall
16 Septal cusp of tricuspid valve

Mitral valve disease, see pages 215–216.

C

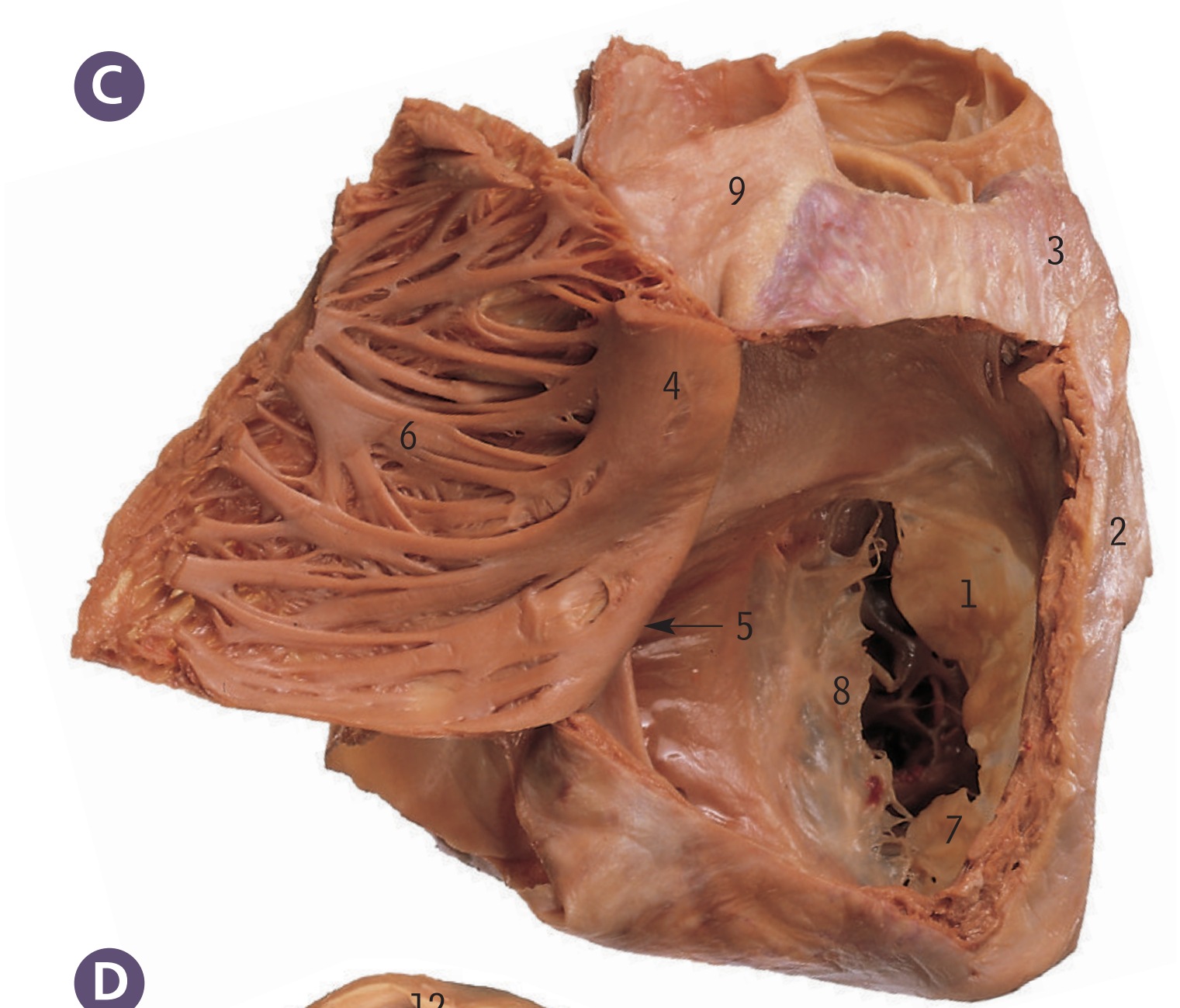

C Tricuspid valve *from the right atrium*

The atrium has been opened by incising the anterior wall (2) and turning the flap outwards so that the atrial surface of the atrioventricular orifice is seen, guarded by the three cusps of the tricuspid valve – anterior (1), posterior (7) and septal (8).

1 Anterior cusp of tricuspid valve
2 Anterior wall of right atrium
3 Auricle of right atrium
4 Crista terminalis
5 Interatrial septum
6 Pectinate muscles
7 Posterior cusp of tricuspid valve
8 Septal cusp of tricuspid valve
9 Superior vena cava

> The posterior cusp (7) of the tricuspid valve is the smallest.

D

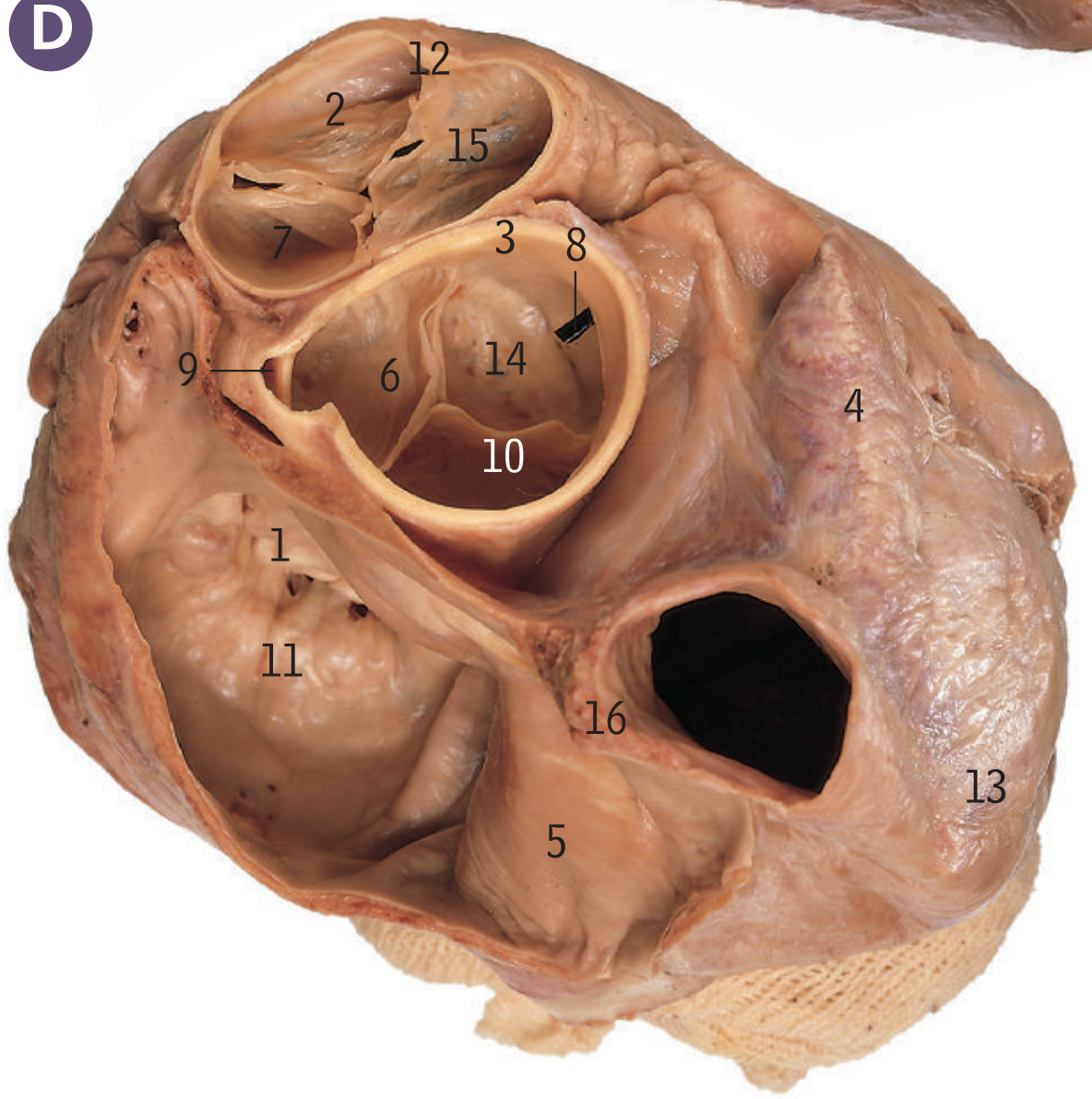

D Pulmonary, aortic and mitral valves *from above*

The pulmonary trunk (12) and ascending aorta (3) have been cut off immediately above the three cusps of the pulmonary and aortic valves (7, 2 and 15, and 14, 10 and 6). The upper part of the left atrium (5) has been removed to show the upper surface of the mitral valve cusps (11 and 1).

1 Anterior cusp of mitral valve
2 Anterior cusp of pulmonary valve
3 Ascending aorta
4 Auricle of right atrium
5 Left atrium
6 Left cusp of aortic valve
7 Left cusp of pulmonary valve
8 Marker in ostium of right coronary artery
9 Ostium of left coronary artery
10 Posterior cusp of aortic valve
11 Posterior cusp of mitral valve
12 Pulmonary trunk
13 Right atrium
14 Right cusp of aortic valve
15 Right cusp of pulmonary valve
16 Superior vena cava

E

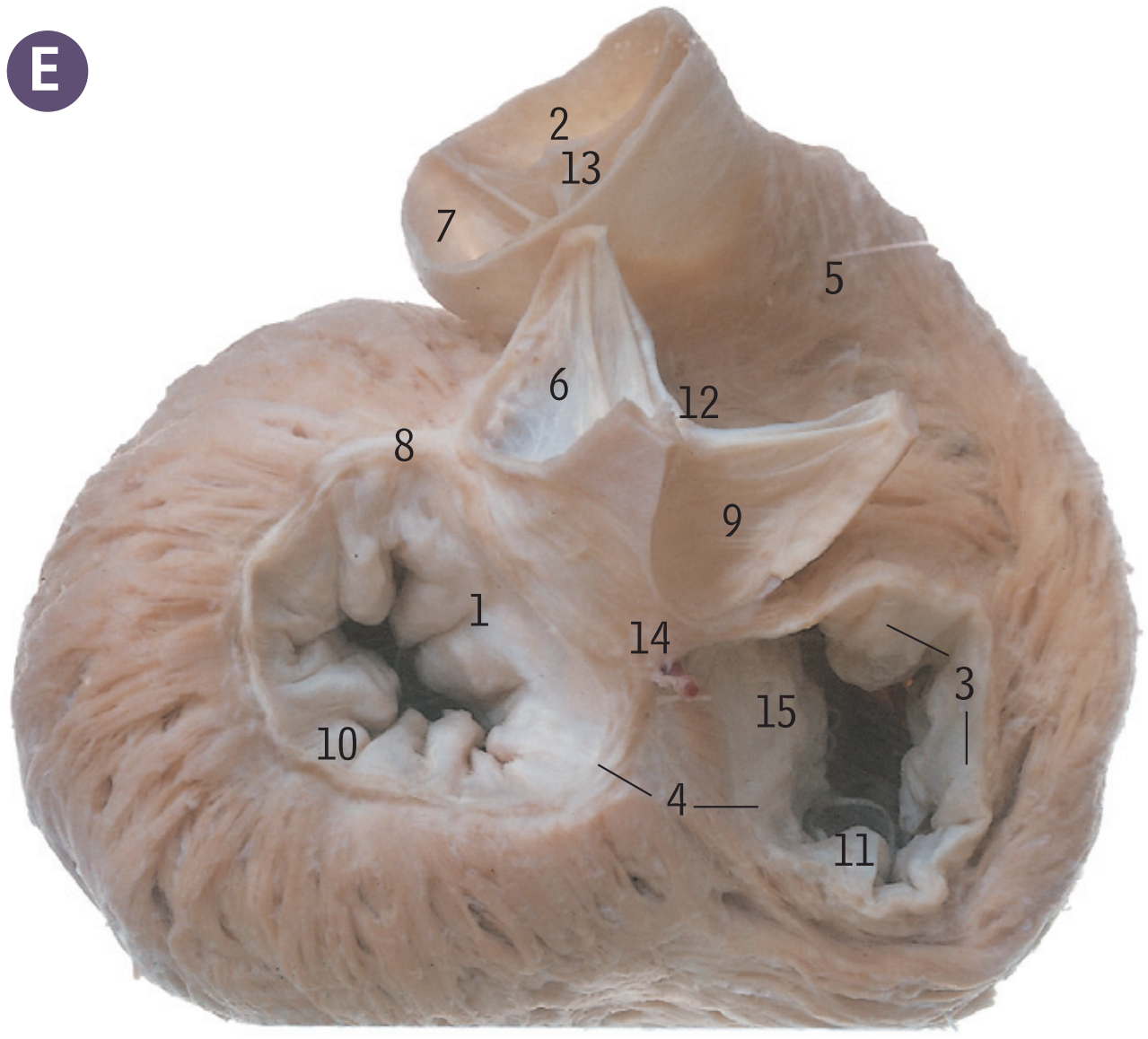

E Heart *fibrous framework*

The heart is seen from the right and behind after removing both atria, looking down on to the fibrous rings (4) that surround the mitral and tricuspid orifices and form the attachments for the bases of the valve cusps. The cusps of the pulmonary valve (7, 2 and 13) are seen at the top of the infundibulum of the right ventricle (5), and the aortic valve cusps (12, 9 and 6) have been dissected out from the beginning of the ascending aorta.

1 Anterior cusp of mitral valve
2 Anterior cusp of pulmonary valve
3 Anterior cusp of tricuspid valve
4 Fibrous ring
5 Infundibulum of right ventricle
6 Left cusp of aortic valve
7 Left cusp of pulmonary valve
8 Left fibrous trigone
9 Posterior cusp of aortic valve
10 Posterior cusp of mitral valve
11 Posterior cusp of tricuspid valve
12 Right cusp of aortic valve
13 Right cusp of pulmonary valve
14 Right fibrous trigone
15 Septal cusp of tricuspid valve

Coronary arteries

A left coronary arteriogram, lateral projection

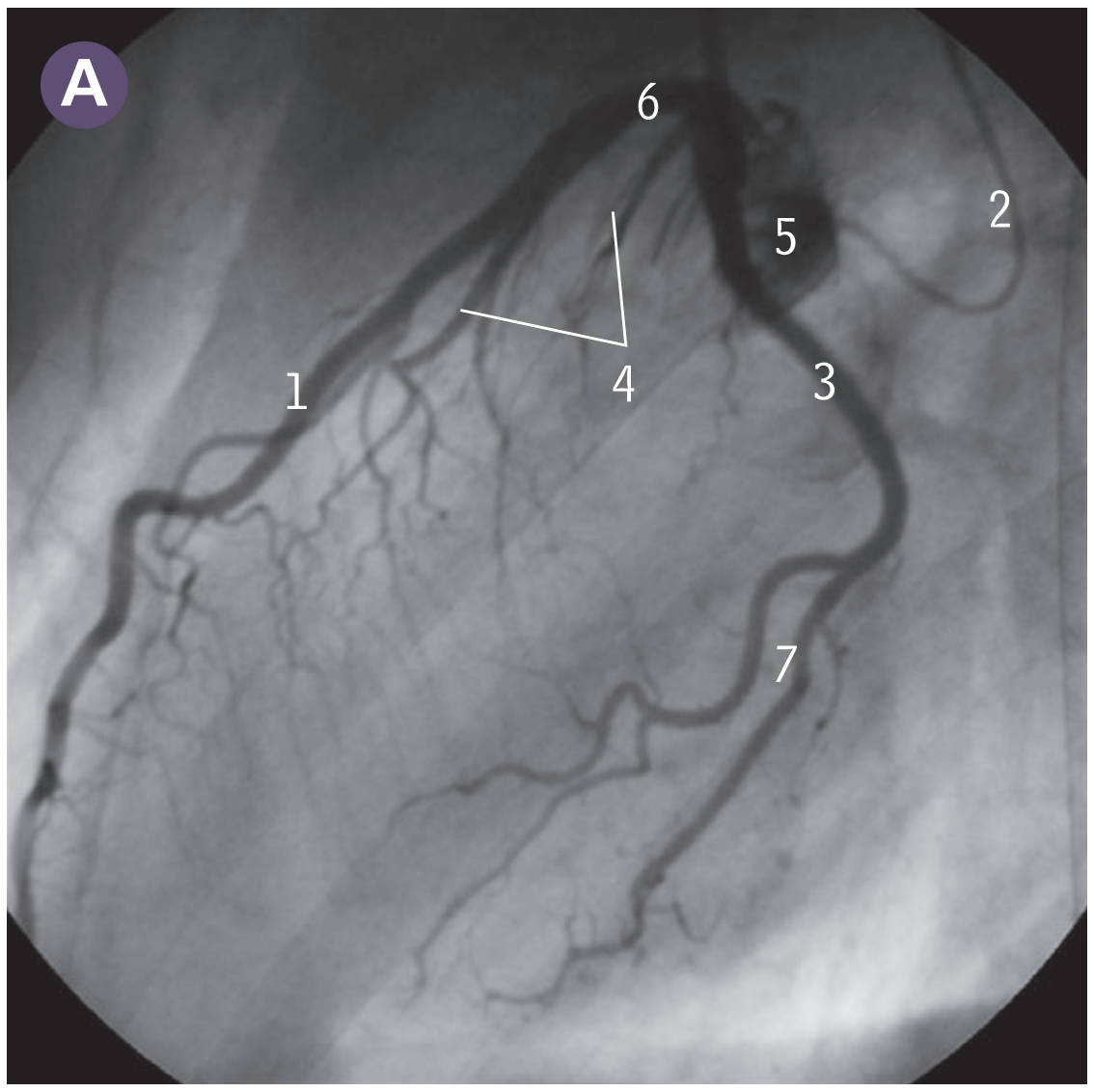

1 Anterior interventricular artery
2 Catheter in ascending aorta
3 Circumflex artery
4 Diagonal branches
5 Left coronary sinus (Valsalva)
6 Left main stem
7 Marginal artery

B right coronary arteriogram, left anterior oblique projection

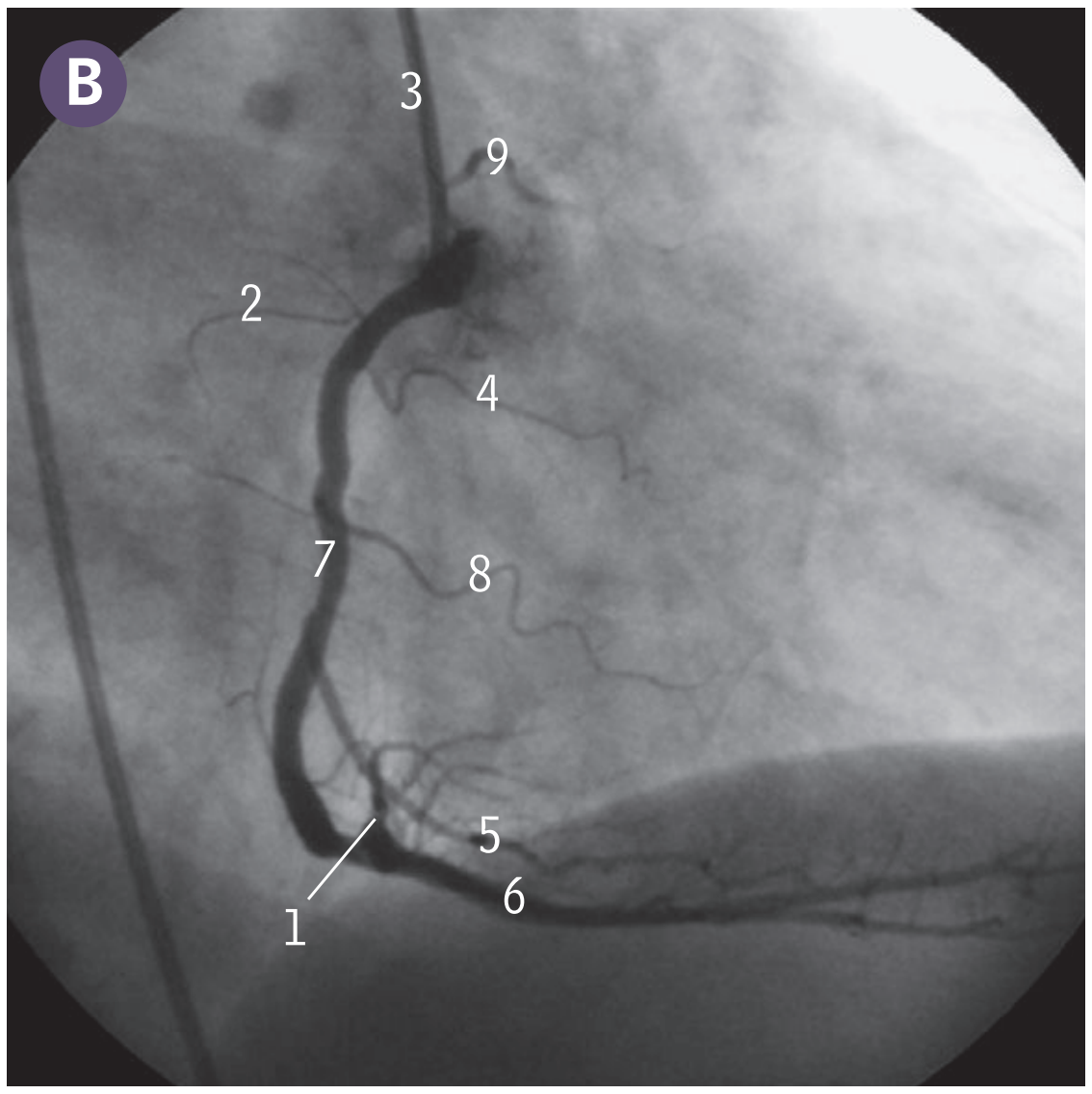

1 Atrio-ventricular nodal branch
2 Atrial branch
3 Catheter at aortic root
4 Conus artery
5 Marginal branch right coronary artery
6 Posterior interventricular artery
7 Right coronary artery
8 Right ventricular branch
9 Sinu-atrial nodal branch

C cast of the coronary arteries, from the front

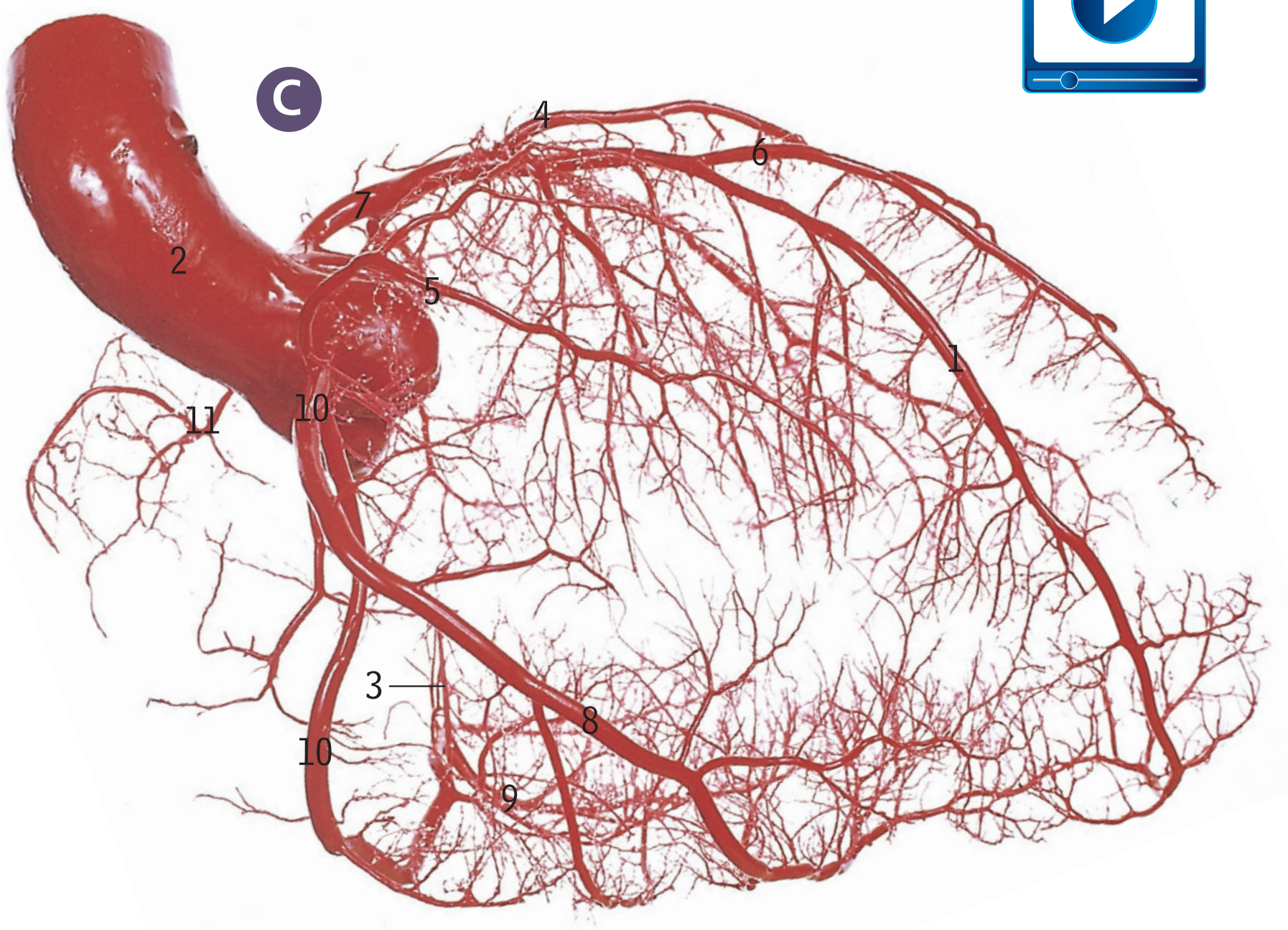

1 Anterior interventricular artery
2 Ascending aorta
3 Atrioventricular nodal artery
4 Circumflex artery
5 Conal artery
6 Diagonal artery
7 Left main stem
8 Marginal branch of right coronary artery
9 Posterior interventricular branch of right coronary artery
10 Right coronary artery
11 Sinu-atrial nodal branch

The interventricular branches are often called by clinicians the descending branches (anterior interventricular, left anterior descending; posterior interventricular, posterior descending).

Angina pectoris, coronary angiography, see pages 215–216.

D Coronary arteries *3D CT reconstruction*

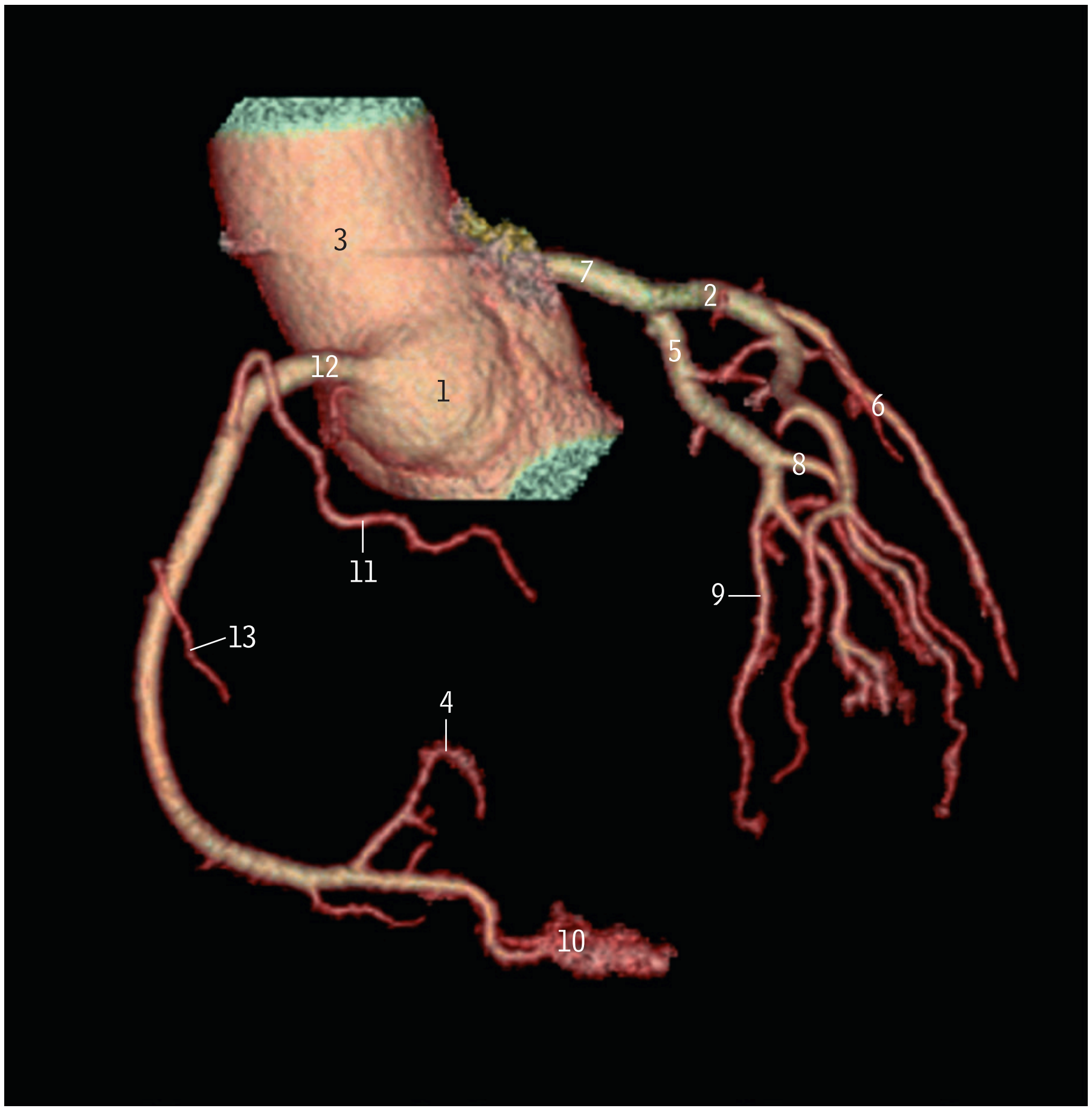

1. Anterior aortic sinus
2. Anterior interventricular, left anterior descending branch, left coronary artery (LAD)
3. Aorta, ascending
4. Atrioventricular nodal artery
5. Circumflex branch, left coronary artery
6. Diagonal artery
7. Left coronary main stem
8. Marginal artery, left coronary artery
9. Obtuse marginal branch, left coronary artery
10. Posterior interventricular branch, right coronary artery
11. Right conal artery
12. Right coronary artery
13. Right ventricular branch, right coronary artery

E Cast of the heart and great vessels *from below and behind*

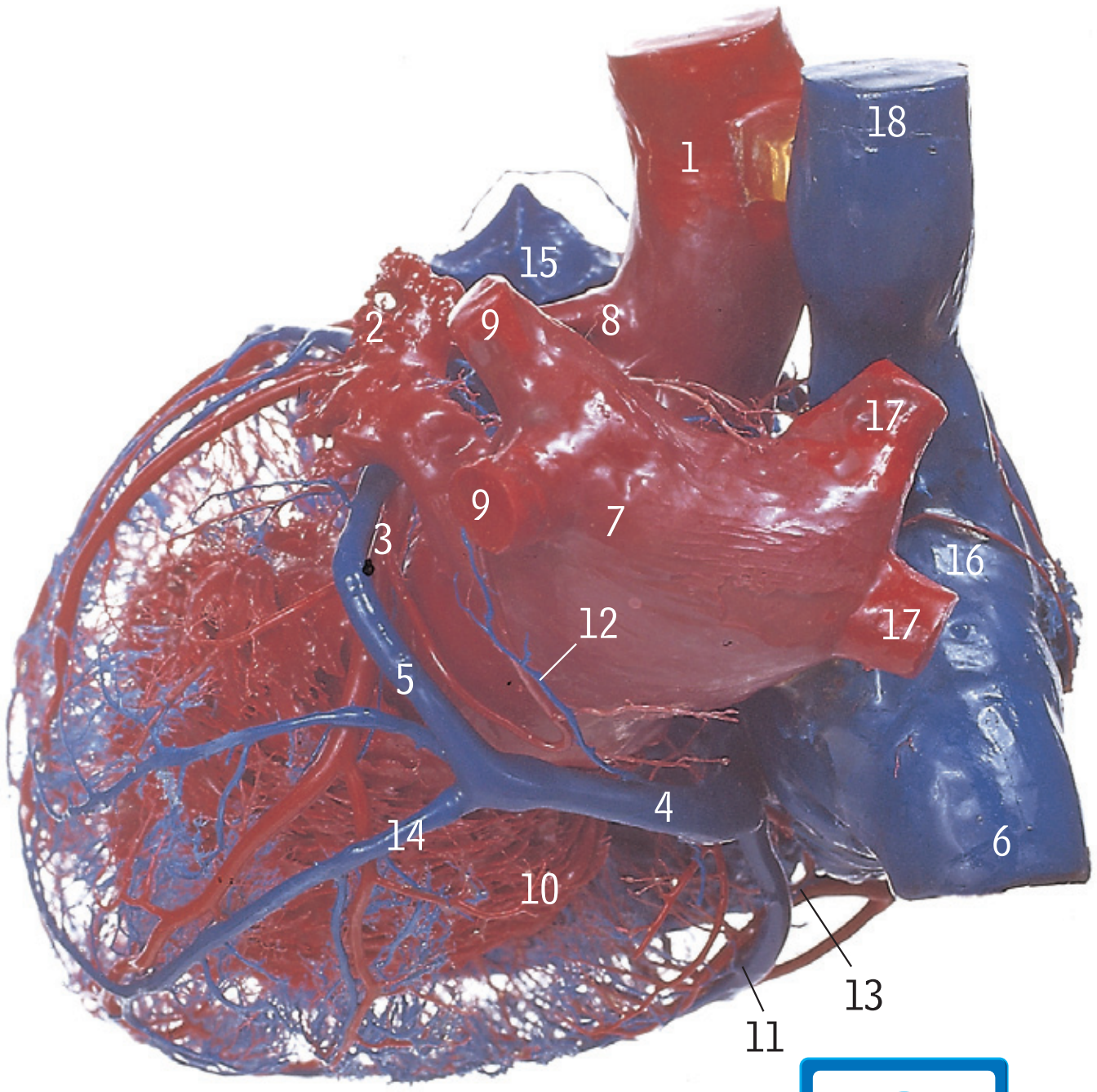

This cast shows the coronary sinus (4) in the atrioventricular groove, and various tributaries (see notes).

1. Ascending aorta
2. Auricle of left atrium
3. Circumflex branch of left coronary artery
4. Coronary sinus
5. Great cardiac vein
6. Inferior vena cava
7. Left atrium
8. Left coronary artery
9. Left pulmonary veins
10. Left ventricle
11. Middle cardiac vein
12. Oblique vein of left atrium
13. Posterior interventricular branch of right coronary artery
14. Posterior vein of left ventricle
15. Pulmonary trunk
16. Right atrium
17. Right pulmonary veins
18. Superior vena cava

The base of the heart is its posterior surface, formed largely by the left atrium (E7). Note that the base is not the part of the heart which joins the superior vena cava, aorta and pulmonary trunk; this part has no special name.

The very small oblique vein of the left atrium (E12) marks the point where the great cardiac vein (E5) becomes the coronary sinus (E4), but in E, the junction is unusually far to the right so that the posterior vein of the left ventricle (E14) joins the great cardiac vein (E5) instead of the coronary sinus itself.

The coronary sinus (E4), which receives most of the venous blood from the heart, lies in the posterior part of the atrioventricular groove between the left atrium and left ventricle and opens into the right atrium.

The coronary sinus normally receives as tributaries the great cardiac vein (E5), middle cardiac vein (E11), and the small cardiac vein, the posterior vein of the left ventricle (E14) and the oblique vein of the left atrium (E12).

Coronary abnormalities, dextrocardia, see pages 215–216.

A Right lung root and mediastinal pleura

This is the view of the right side of the mediastinum after removing the lung but with the parietal pleura still intact.

1 Azygos vein
2 Branch of right pulmonary artery to superior lobe
3 Branches of sympathetic trunk to greater splanchnic nerve
4 Diaphragm
5 Inferior vena cava
6 Neck of first rib
7 Oesophagus
8 Pericardium over right atrium
9 Pleura, costal
10 Right inferior pulmonary vein
11 Right phrenic nerve
12 Right principal bronchus
13 Right pulmonary artery
14 Right subclavian artery
15 Right superior pulmonary vein
16 Right vagus nerve
17 Sixth right posterior intercostal vessels under parietal pleura
18 Superior lobe bronchus
19 Superior vena cava
20 Sympathetic trunk and ganglion

B Right lung root and mediastinum

In a similar specimen to A, most of the pleura has been removed to display the underlying structures. The azygos vein (1) arches over the structures forming the lung root to enter the superior vena cava (24). The highest structures in the lung root are the artery (2) and bronchus (14) to the superior lobe of the lung. The right superior pulmonary vein (18) is in front of the right pulmonary artery, with the right inferior pulmonary vein (12) the lowest structure in the root. Above the arch of the azygos vein the trachea (28), with the right vagus nerve (19) in contact with it, lies in front of the oesophagus (8). Part of the first rib has been cut away to show the structures lying in front of its neck (5), the sympathetic trunk (27), supreme intercostal vein (22), superior intercostal artery (20) and the ventral ramus of the first thoracic nerve. The right recurrent laryngeal nerve hooks underneath the right subclavian artery (16). The right phrenic nerve (13) runs down over the superior vena cava (24) and the pericardium overlying the right atrium (9), and pierces the diaphragm (4) beside the inferior vena cava. Contributions from the sympathetic trunk (3) pass over the sides of vertebral bodies superficial to posterior intercostal arteries and veins (as at 20 and 21) to form the greater splanchnic nerve. The lower part of the oesophagus (8) behind the lung root and heart has the azygos vein (1) on its right side.

Surgical emphysema, see pages 215–216.

B

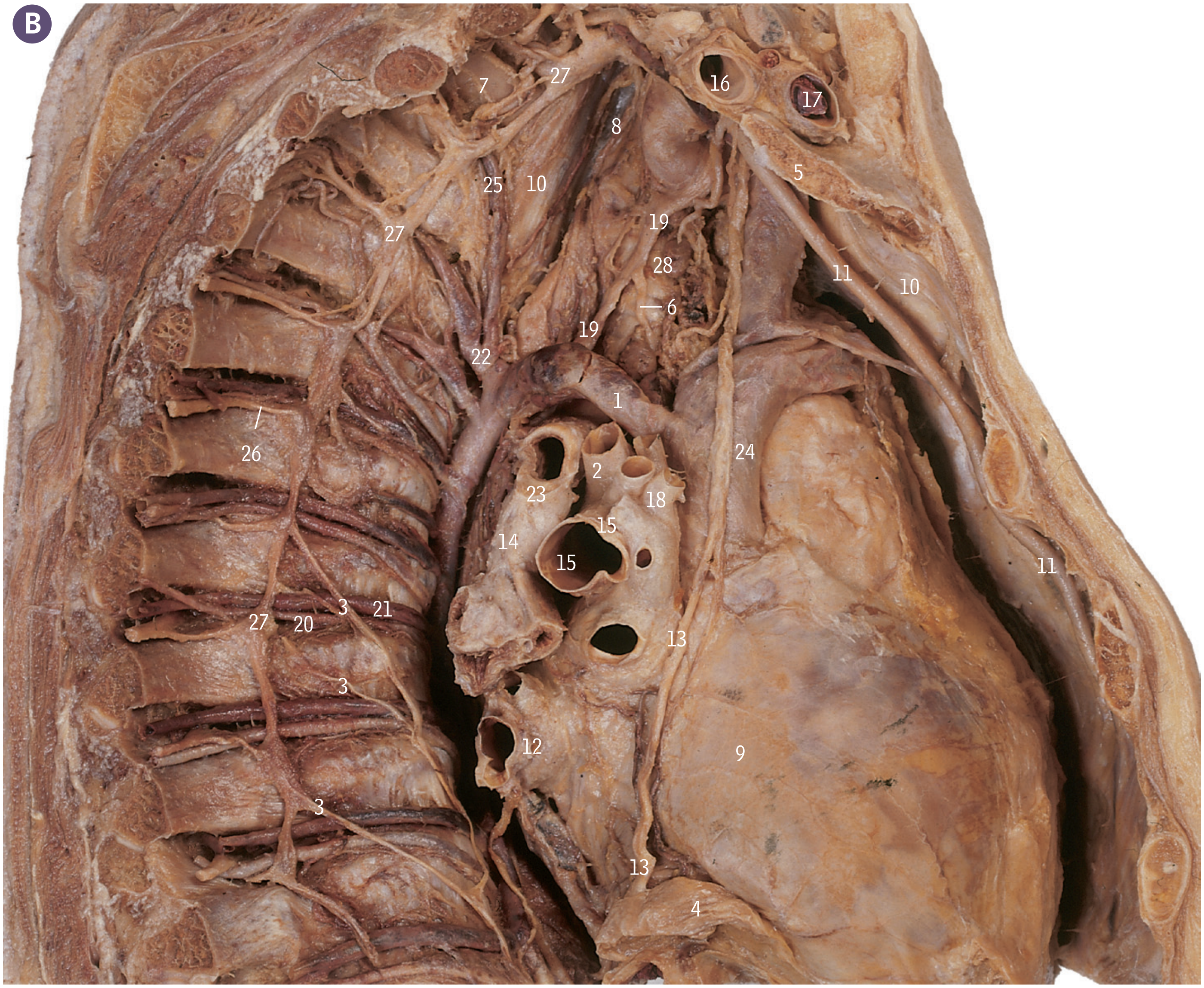

C

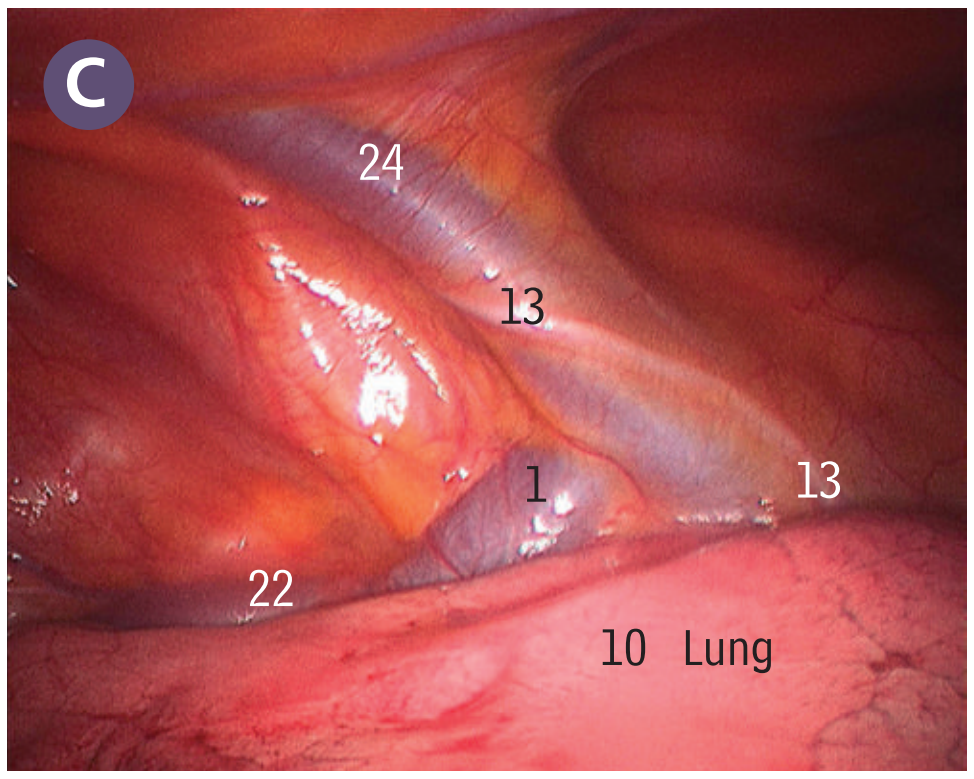

D

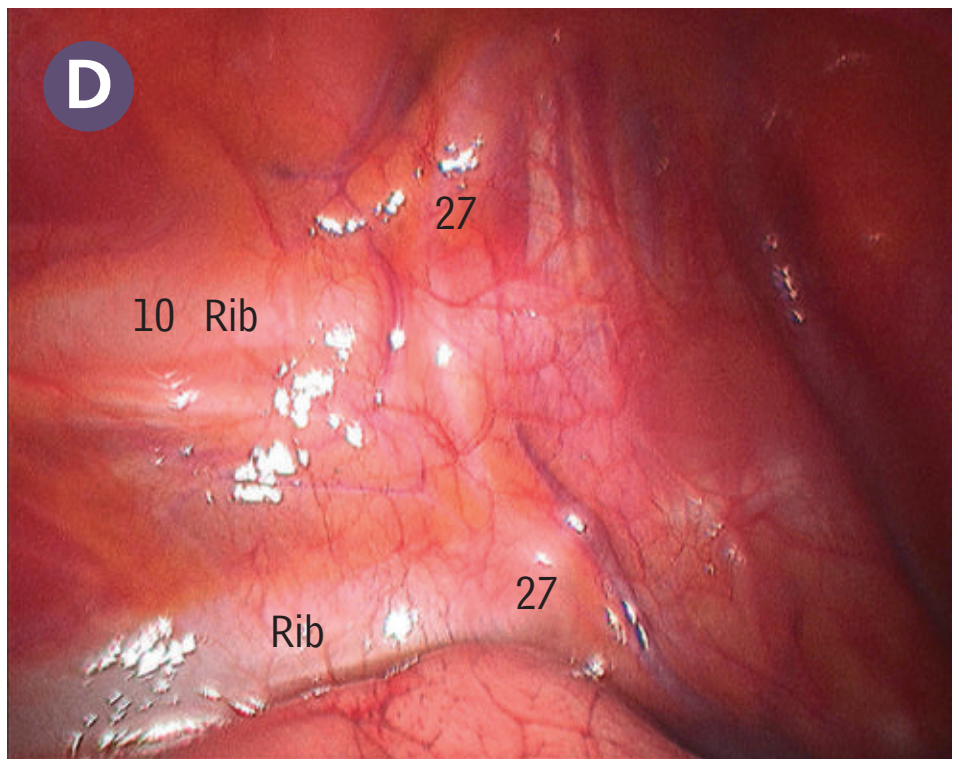

C D Thoracoscopies

1. Azygos vein (arch)
2. Branch of right pulmonary artery to superior lobe
3. Branches of sympathetic trunk to greater splanchnic nerve
4. Diaphragm
5. First rib (sectioned)
6. Inferior cardiac branches of vagus nerve
7. Neck of first rib
8. Oesophagus
9. Pericardium over right atrium
10. Pleura
11. Right internal thoracic artery
12. Right inferior pulmonary vein
13. Right phrenic nerve
14. Right principal bronchus
15. Right pulmonary artery
16. Right subclavian artery
17. Right subclavian vein (NB thrombus)
18. Right superior pulmonary vein
19. Right vagus nerve
20. Sixth right posterior intercostal artery
21. Sixth right posterior intercostal vein
22. Superior intercostal vein
23. Superior lobe bronchus
24. Superior vena cava
25. Supreme intercostal vein
26. Sympathetic rami communicantes
27. Sympathetic trunk and ganglion
28. Trachea

Pleural effusion, thoracoscopy, transthoracic sympathectomy, see pages 215–216.

Left lung root and mediastinal pleura

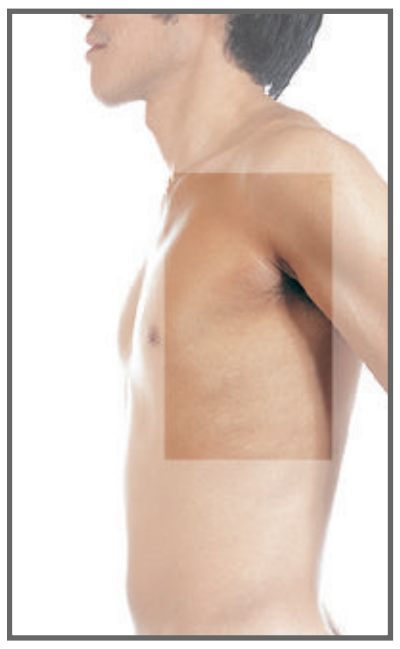

1 Arch of aorta
2 Diaphragm
3 Left inferior pulmonary vein
4 Left phrenic nerve and pericardiophrenic vessels
5 Left principal bronchus
6 Left pulmonary artery
7 Left superior intercostal vein
8 Left superior pulmonary vein
9 Left vagus nerve
10 Mediastinal pleura and pericardium overlying left ventricle
11 Oesophagus
12 Thoracic aorta, descending

Left parasagittal CT

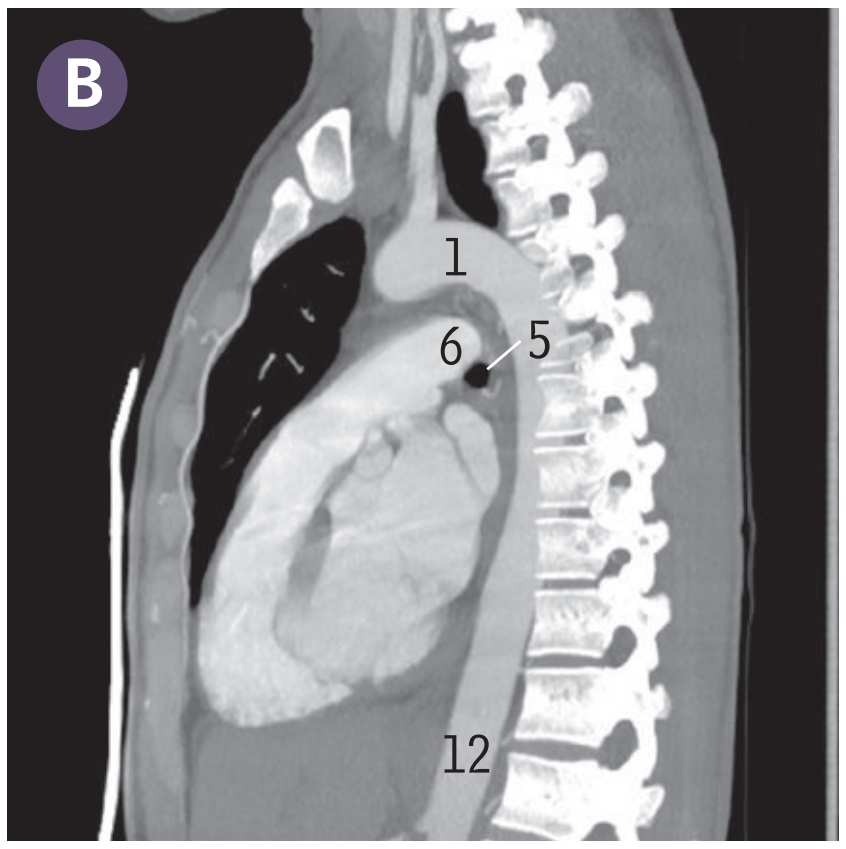

On the left side above the diaphragm, the lower end of the oesophagus lies in a triangle bounded by the diaphragm below (2), the heart in front (10) and the descending aorta behind (12).

This is the view of the left side of the mediastinum after removing the lung but with the parietal pleura still intact. Compare the features seen here with those in the dissection opposite (a different specimen), from which the pleura has been removed.

Pneumothorax, thoracic aortic aneurysm, see pages 215–216.

Left lung root and mediastinum

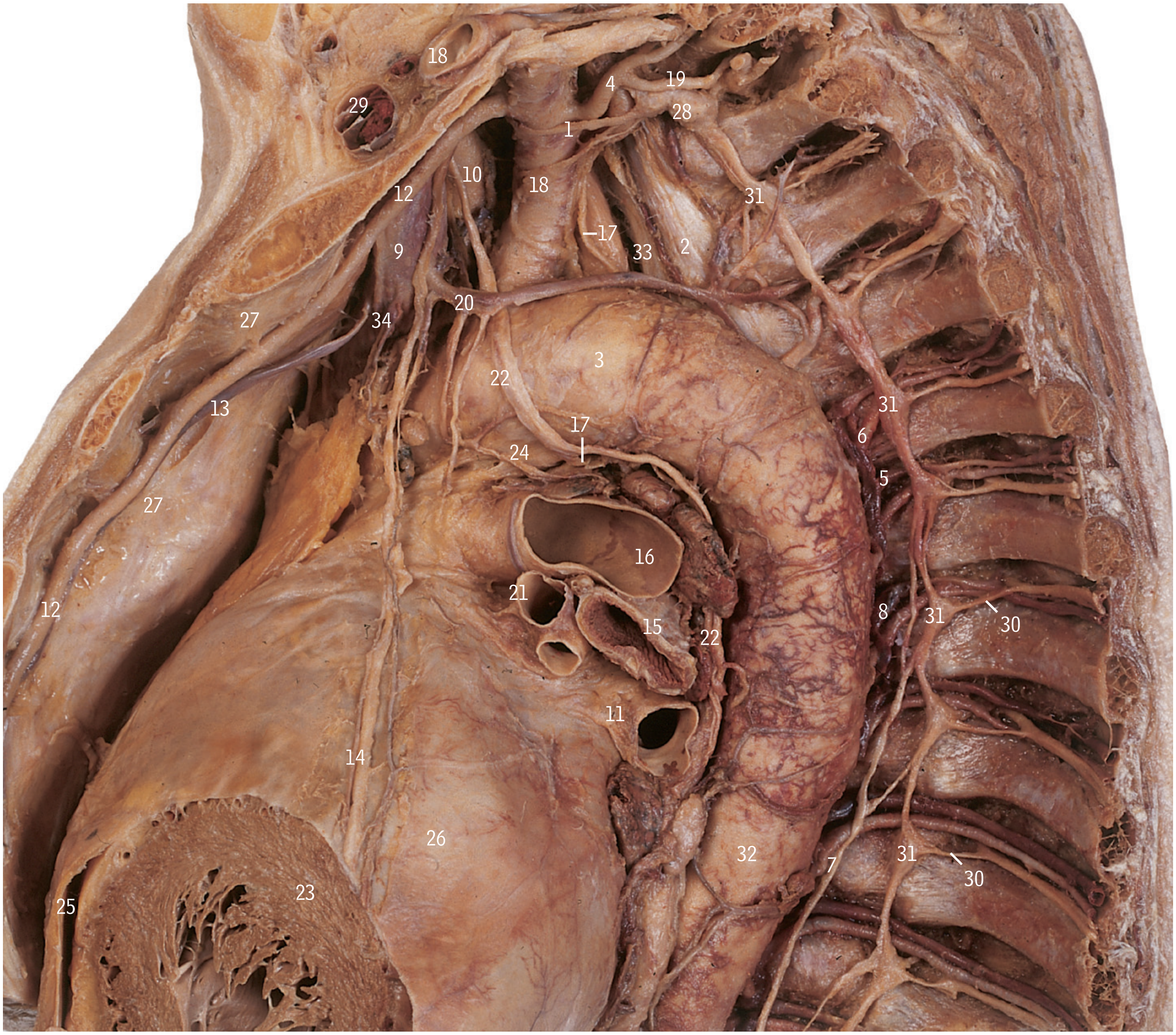

1 Ansa subclavia
2 Anterior longitudinal ligament
3 Arch of aorta
4 Costocervical trunk
5 Fifth left posterior intercostal vein
6 Fourth left posterior intercostal artery
7 Greater splanchnic nerve
8 Hemi-azygos vein
9 Left brachiocephalic vein
10 Left common carotid artery
11 Left inferior pulmonary vein
12 Left internal thoracic artery
13 Left internal thoracic vein
14 Left phrenic nerve and pericardiophrenic vessels
15 Left principal bronchus
16 Left pulmonary artery
17 Left recurrent laryngeal nerve
18 Left subclavian artery
19 Left superior intercostal artery
20 Left superior intercostal vein
21 Left superior pulmonary vein
22 Left vagus nerve
23 Left ventricle (NB thick-walled cavity)
24 Ligamentum arteriosum
25 Pericardial cavity (space)
26 Pericardium overlying left ventricle
27 Pleura (cut edge)
28 Stellate ganglion
29 Subclavian vein
30 Sympathetic rami communicantes
31 Sympathetic trunk and ganglion
32 Thoracic aorta
33 Thoracic duct (page 209)
34 Thymic veins (page 360)

Coarctation of the aorta, subclavian arterial stent, see pages 215–216.

Axial CT images *with contrast*

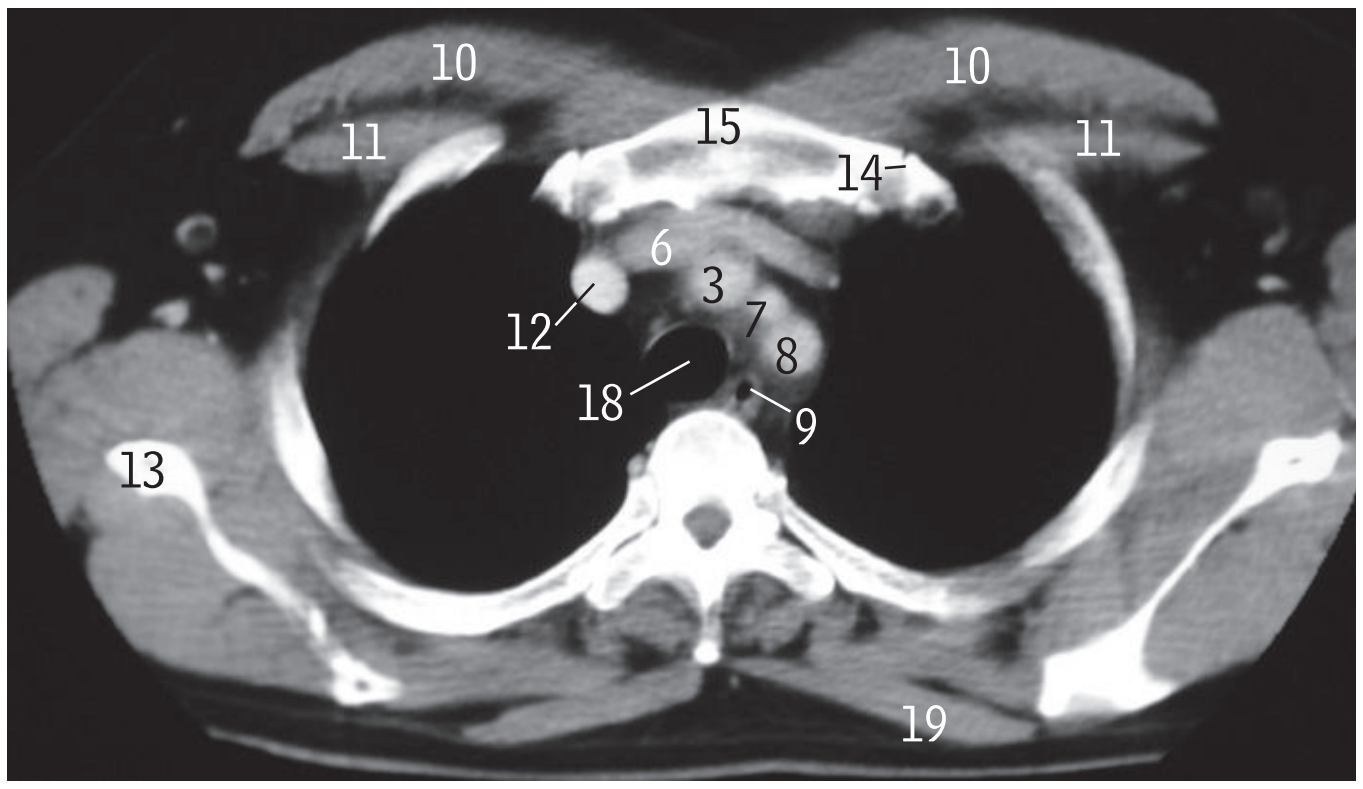

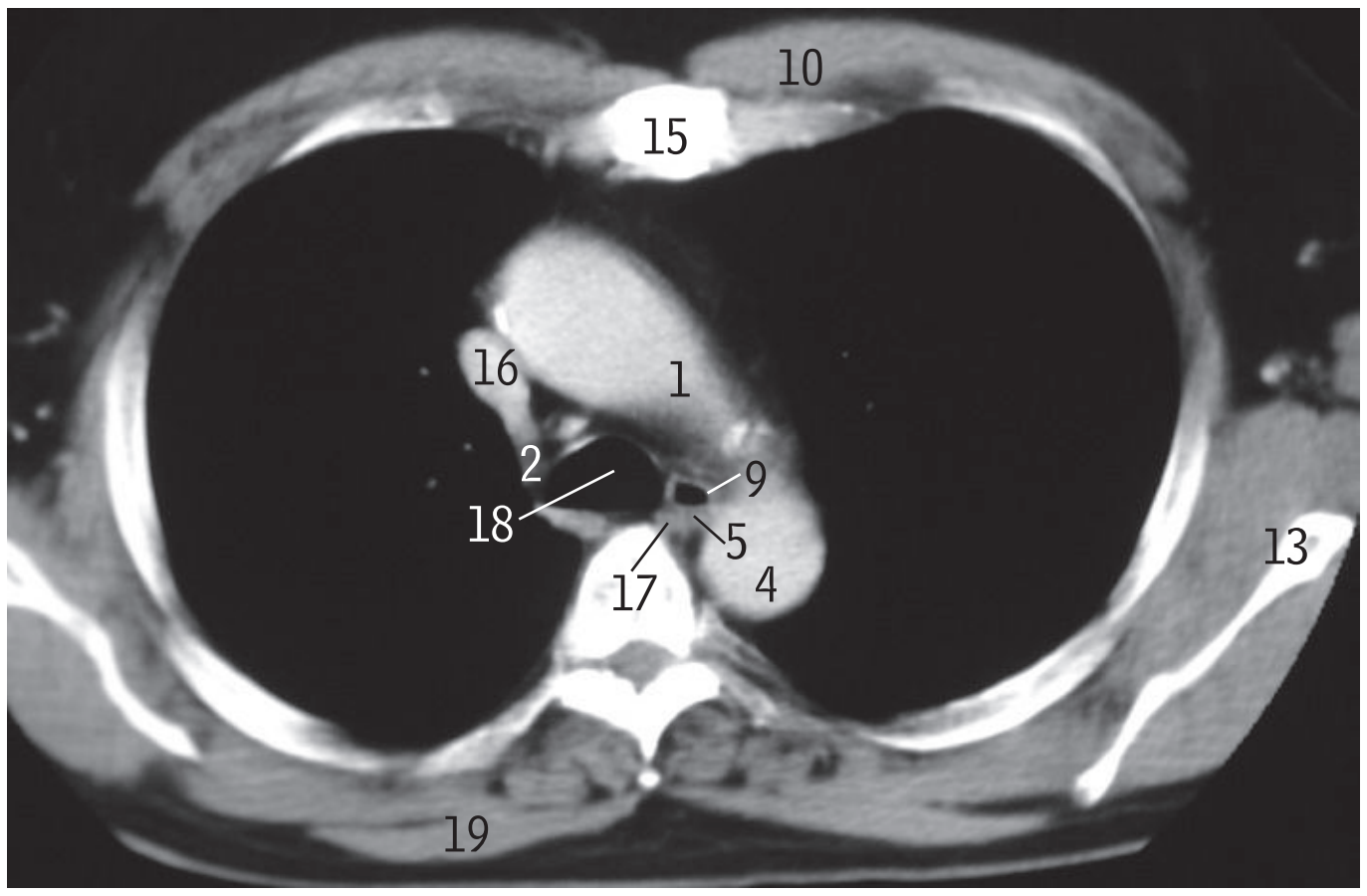

A *Level of T2*

B *Level of T4*

1 Arch aorta
2 Azygos vein
3 Brachiocephalic trunk (artery)
4 Descending aorta
5 Hemi-azygos vein
6 Left brachiocephalic vein
7 Left common carotid artery
8 Left subclavian artery
9 Oesophagus
10 Pectoralis major
11 Pectoralis minor
12 Right brachiocephalic vein
13 Scapula
14 Sternoclavicular joint
15 Sternum
16 Superior vena cava
17 Thoracic duct
18 Trachea
19 Trapezius

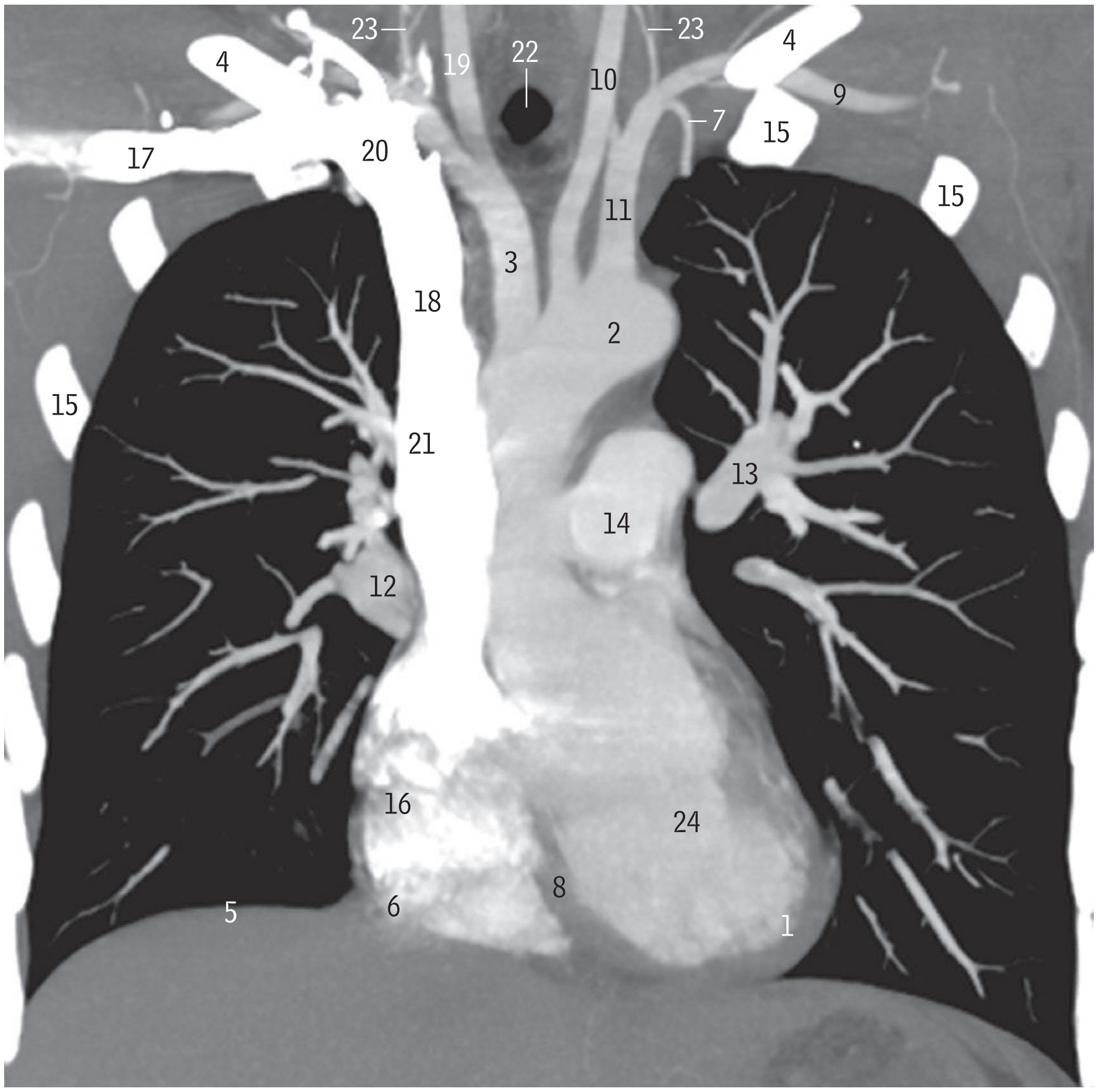

C Thorax *coronal 64 slice CT reconstruction – venous phase*

1 Apex of heart
2 Arch of aorta
3 Brachiocephalic trunk
4 Clavicle
5 Dome of diaphragm, right
6 Inferior vena cava
7 Internal thoracic artery
8 Interventricular septum
9 Left axillary artery
10 Left common carotid artery
11 Left subclavian artery
12 Pulmonary artery, right
13 Pulmonary artery, upper lobe branch
14 Pulmonary trunk
15 Ribs
16 Right atrium
17 Right axillary vein
18 Right brachiocephalic vein
19 Right common carotid artery
20 Right subclavian vein
21 Superior vena cava
22 Trachea
23 Vertebral artery
24 Ventricle, left

Phrenic nerve palsy, see pages 215–216.

Cast of the lower trachea and bronchi

A vertical from the front B oblique from the left

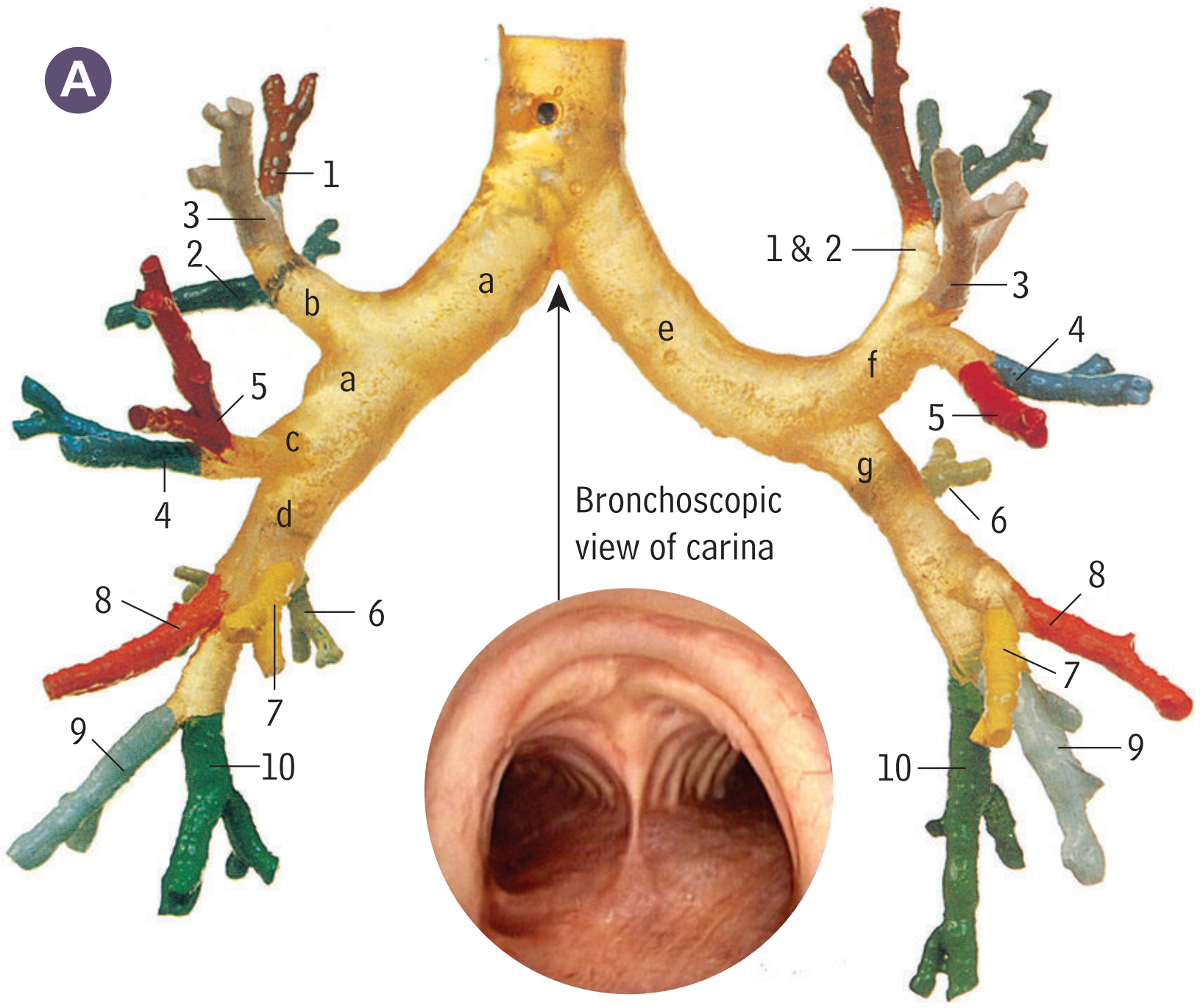

The principal and lobar bronchi are labelled with letters; the segmental bronchi are labelled with their conventional numbers. In the side view in B, the cast has been tilted to avoid overlap, and the right side is more anterior than the left.

Right lung
Lobar bronchi
a Principal
b Superior lobe
c Middle lobe
d Inferior lobe

Segmental bronchi
Superior lobe
1 Apical
2 Posterior
3 Anterior

Middle lobe
4 Lateral
5 Medial

Inferior lobe
6 Apical (superior)
7 Medial basal
8 Anterior basal
9 Lateral basal
10 Posterior basal

Left lung
e Principal
f Superior lobe
g Inferior lobe

Superior lobe
1 & 2 Apicoposterior
3 Anterior
4 Superior lingular
5 Inferior lingular

Inferior lobe
6 Apical (superior)
7 Medial basal
8 Anterior basal
9 Lateral basal
10 Posterior basal

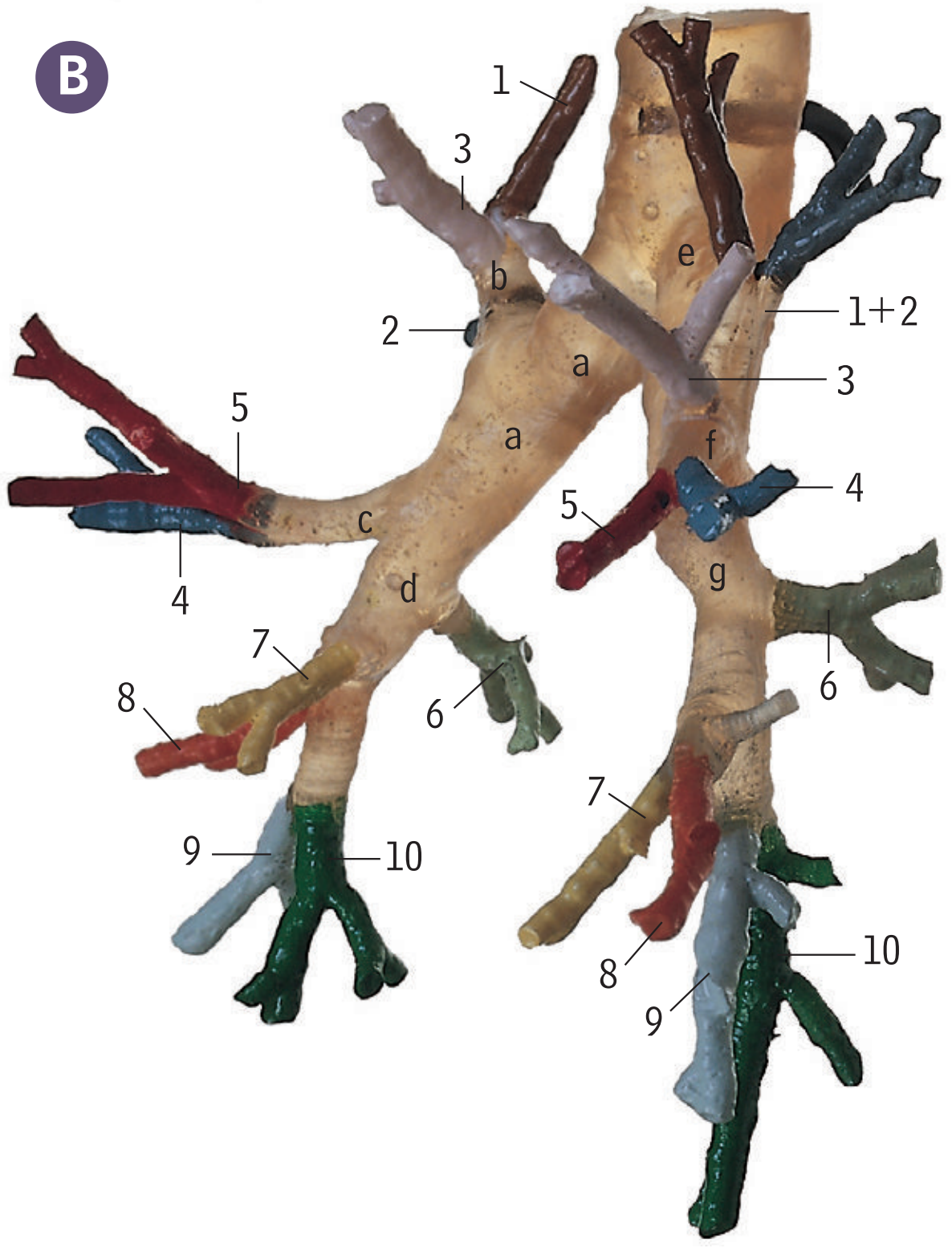

The trachea divides into right and left principal bronchi (a and e).

The right principal bronchus (a) is shorter, wider and more vertical than the left (e).

The left principal bronchus (e) is longer and narrower and lies more transversely than the right. Foreign bodies are therefore more likely to enter the right principal bronchus than the left.

The right principal bronchus (a) gives off a superior lobe bronchus (b) and then enters the hilum of the right lung before dividing into middle and inferior lobe bronchi (c and d).

The left principal bronchus (e) enters the hilum of the lung before dividing into superior and inferior lobe bronchi (f and g).

The branches of the lobar bronchi are called segmental bronchi and each supplies a segment of lung tissue – bronchopulmonary segment. The segmental bronchi and the bronchopulmonary segments have similar names, and the ten segments of each lung are officially numbered (as here and page 198) as well as being named.

The segmental bronchi of the left and right lungs are essentially similar except that the apical and posterior bronchi of the superior lobe of the left lung arise from a common stem, thus called the apicoposterior bronchus and labelled here as 1 and 2; also there is no middle lobe of the left lung, and so the corresponding segments bear similar numbers; and the medial basal bronchus (7) of the left lung usually arises in common with the anterior basal (8).

The apical (superior) bronchus of the inferior lobe (6) of both lungs is the first or highest bronchus to arise from the posterior surface of the bronchial tree, as illustrated in B. When lying on the back fluid may therefore gravitate into this bronchus.

Cast of the bronchial tree

The bronchi and bronchopulmonary segments have been coloured and labelled with their conventional numbers.

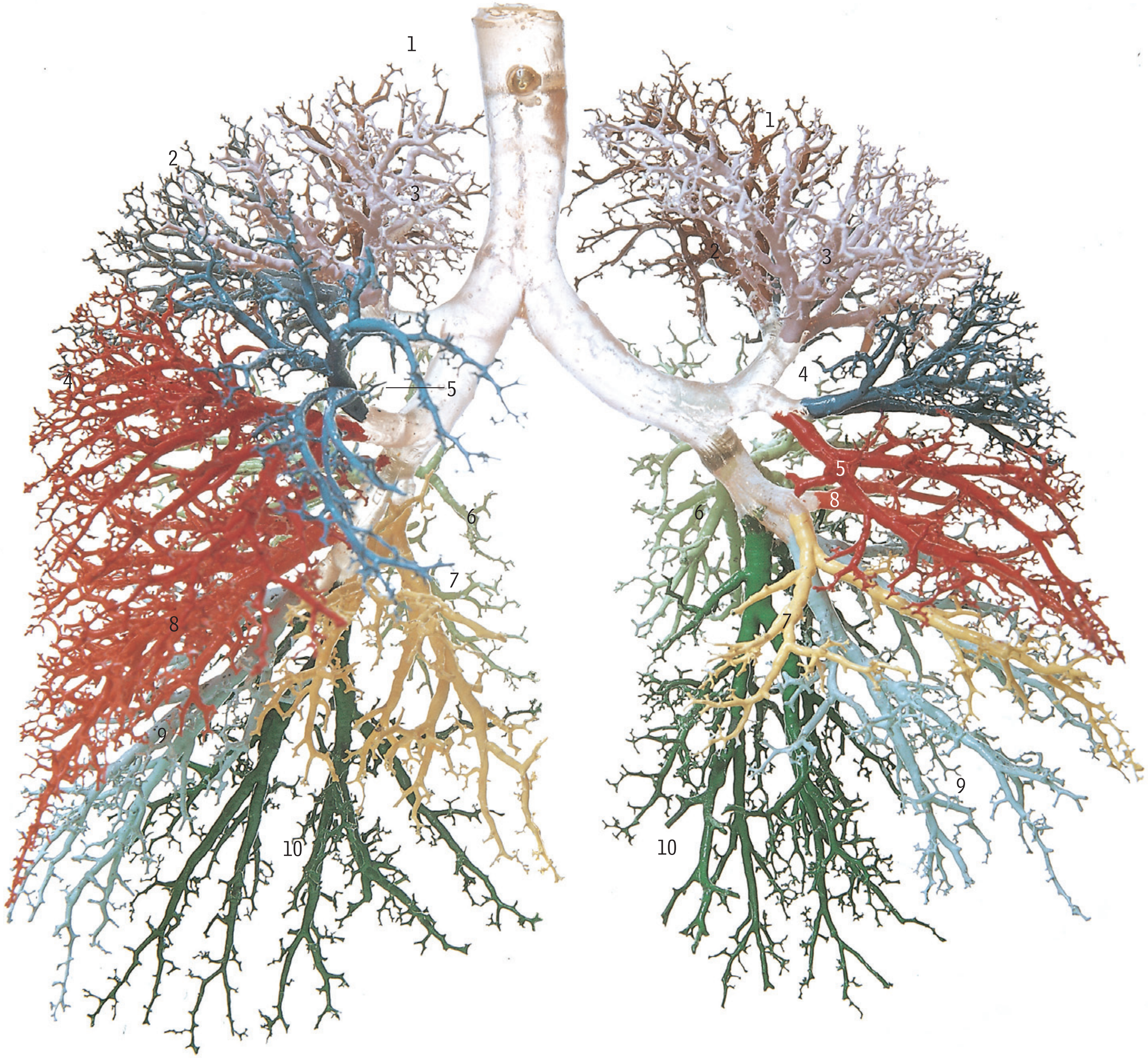

Right lung

Superior lobe
1 Apical
2 Posterior
3 Anterior

Middle lobe
4 Lateral
5 Medial

Inferior lobe
6 Apical (superior)
7 Medial basal
8 Anterior basal
9 Lateral basal
10 Posterior basal

Left lung

Superior lobe
1 Apical
2 Posterior
3 Anterior
4 Superior lingular
5 Inferior lingular

Inferior lobe
6 Apical (superior)
7 Medial basal (cardiac)
8 Anterior basal
9 Lateral basal
10 Posterior basal

Bronchoscopy, empyema, see pages 215–216.

Bronchopulmonary segments of the right lung

A

B

A from the front
B from behind

Superior lobe
- **1** Apical
- **2** Posterior
- **3** Anterior

Middle lobe
- **4** Lateral
- **5** Medial

Inferior lobe
- **6** Apical (superior)
- **7** Medial basal
- **8** Anterior basal
- **9** Lateral basal
- **10** Posterior basal

A subapical (subsuperior) segmental bronchus and bronchopulmonary segment are present in over 50% of lungs; in this specimen, this additional segment is shown in white.

The posterior basal segment (10) is coloured with two different shades of yellow ochre.

Bronchopulmonary segments of the left lung

C

D

C from the front
D from behind

Superior lobe
- **1** Apical
- **2** Posterior
- **3** Anterior
- **4** Superior lingular
- **5** Inferior lingular

Inferior lobe
- **6** Apical (superior)
- **7** Medial basal (cardiac)
- **8** Anterior basal
- **9** Lateral basal
- **10** Posterior basal

The apical and posterior segments (1 and 2) are both coloured green, having been filled from the common apicoposterior bronchus (see page 197).

A Bronchopulmonary segments of the right lung *from the lateral sides*

B Right bronchogram

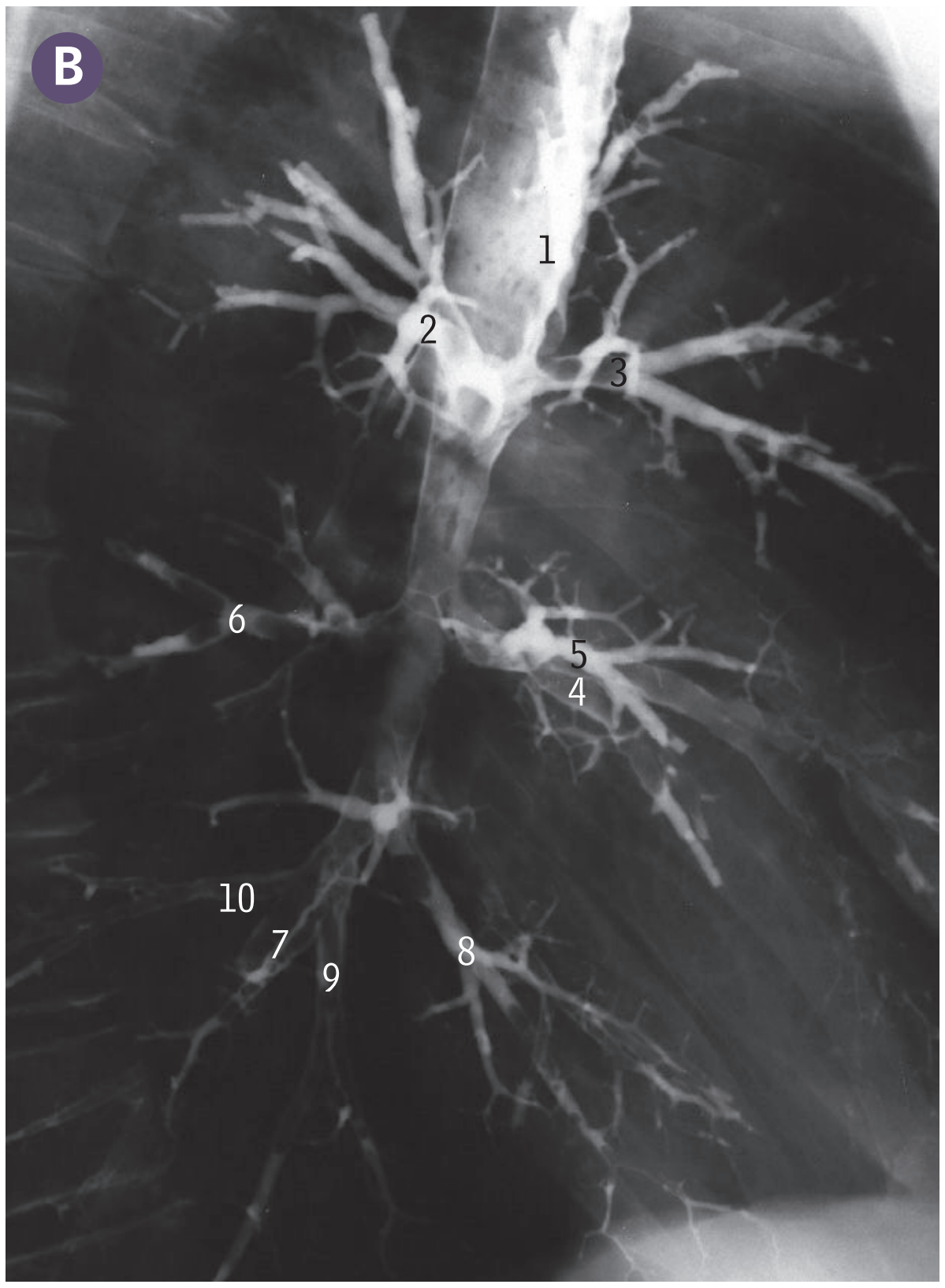

Coronal CT, lung windows*

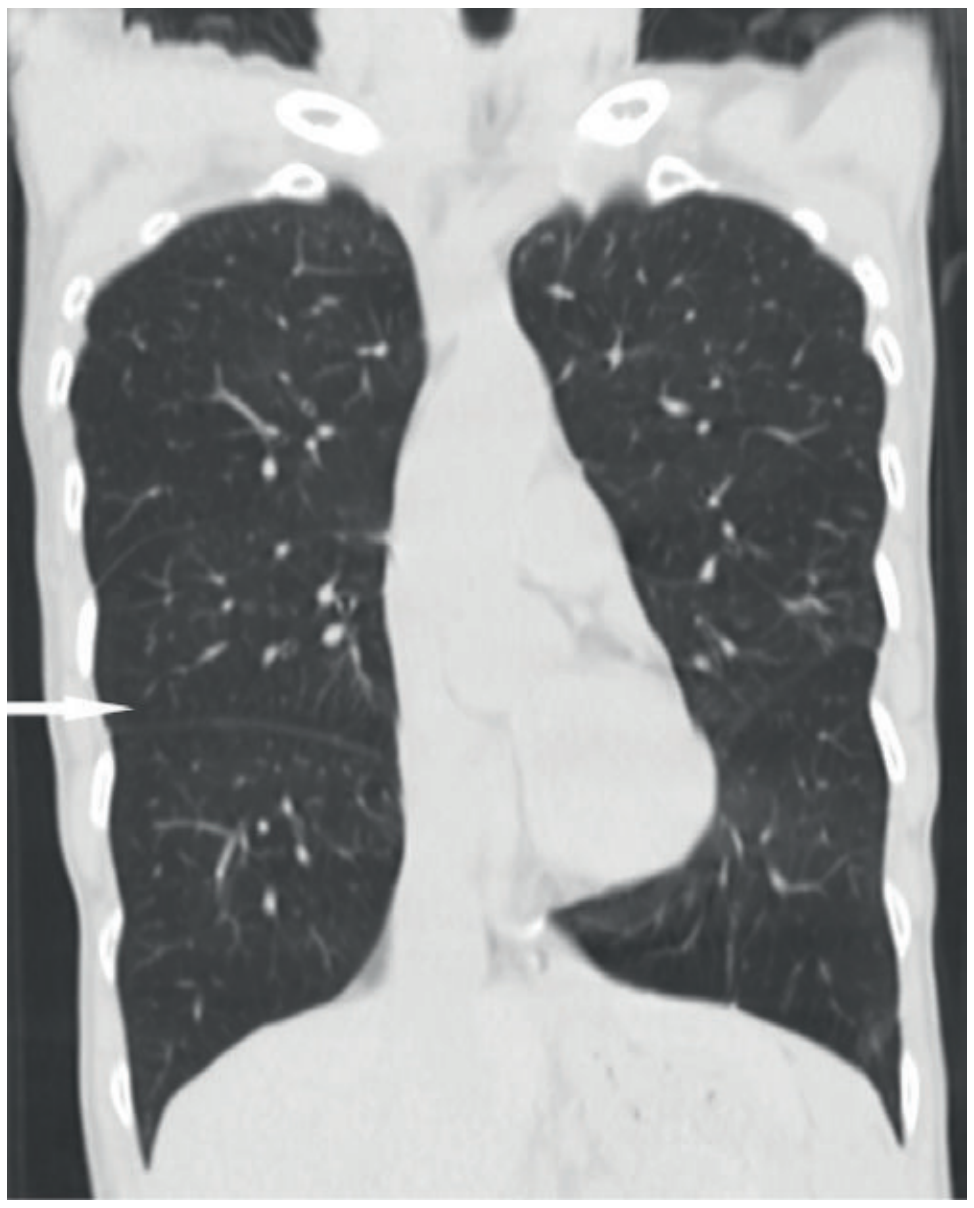

*Arrow shows horizontal fissure.

Superior lobe
- **1** Apical
- **2** Posterior
- **3** Anterior

Middle lobe
- **4** Lateral
- **5** Medial

Inferior lobe
- **6** Apical (superior)
- **7** Medial basal
- **8** Anterior basal
- **9** Lateral basal
- **10** Posterior basal

The medial basal segment (7) is not seen in the view in A.

The posterior basal segment in A (10) is coloured with two different shades of green.

Empyema, see pages 215–216.

C Bronchopulmonary segments of the left lung *from the lateral side*

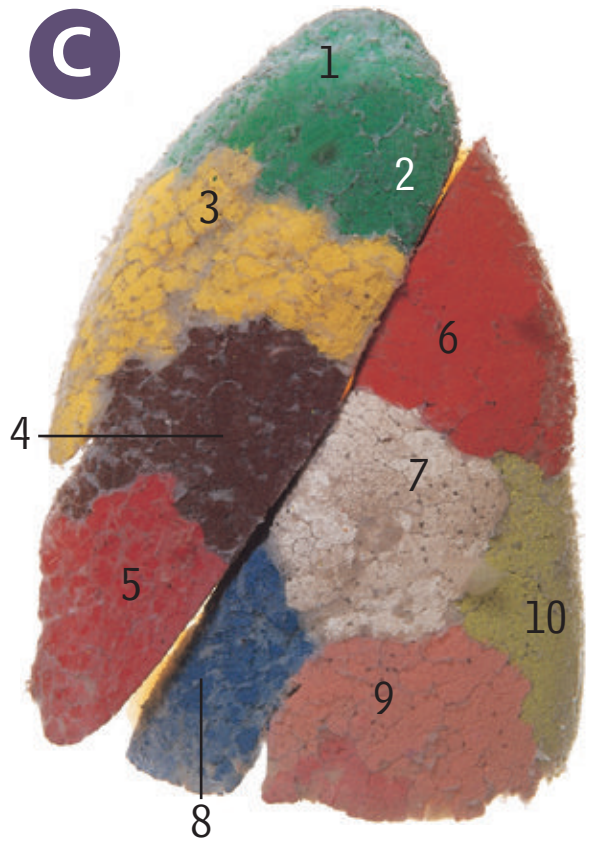

Superior lobe
1 Apical
2 Posterior
3 Anterior
4 Superior lingular
5 Inferior lingular

Inferior lobe
6 Apical (superior)
7 Medial basal (cardiac)
8 Anterior basal
9 Lateral basal
10 Posterior basal

The apical and posterior segments (1 and 2) are both coloured green, having been filled from the common apicoposterior bronchus (see page 199, D).

D Left bronchogram

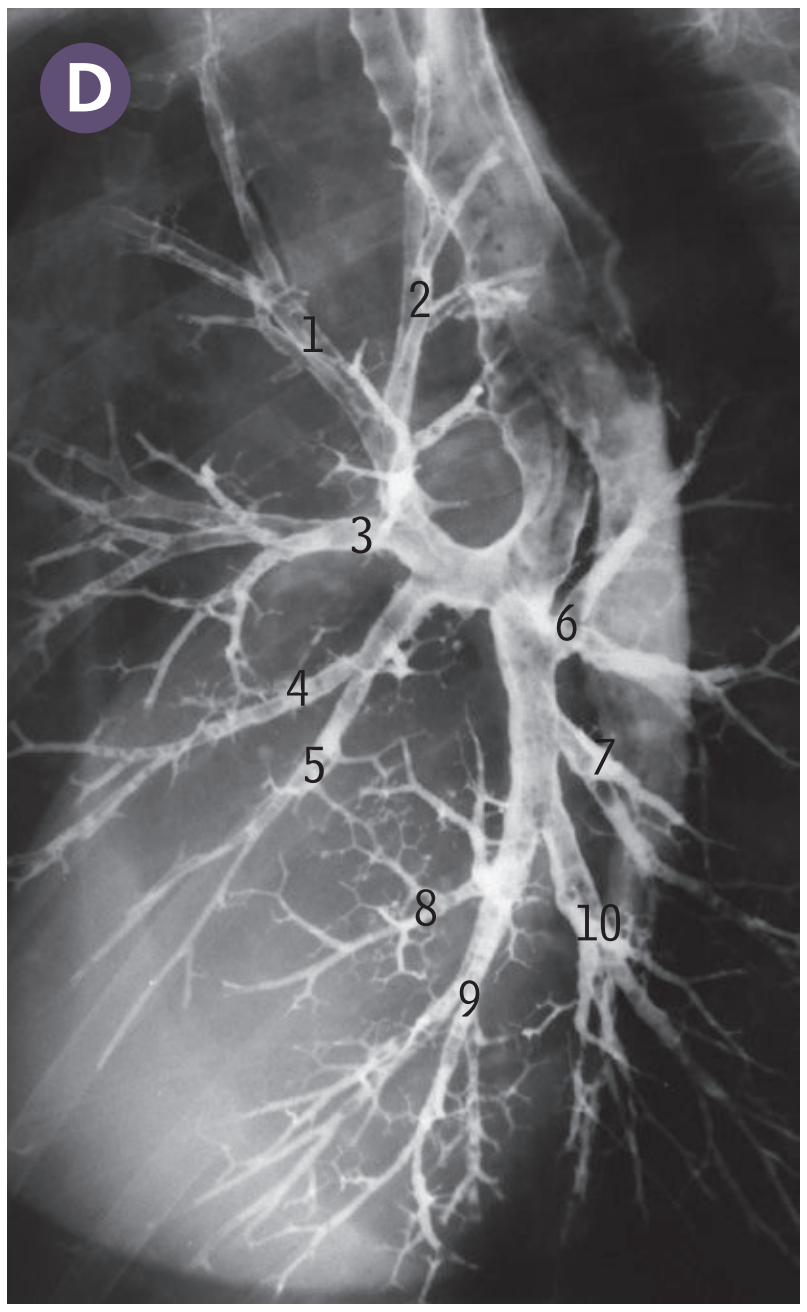

E Lungs, detailed dissections to show bronchopulmonary segments of left lung

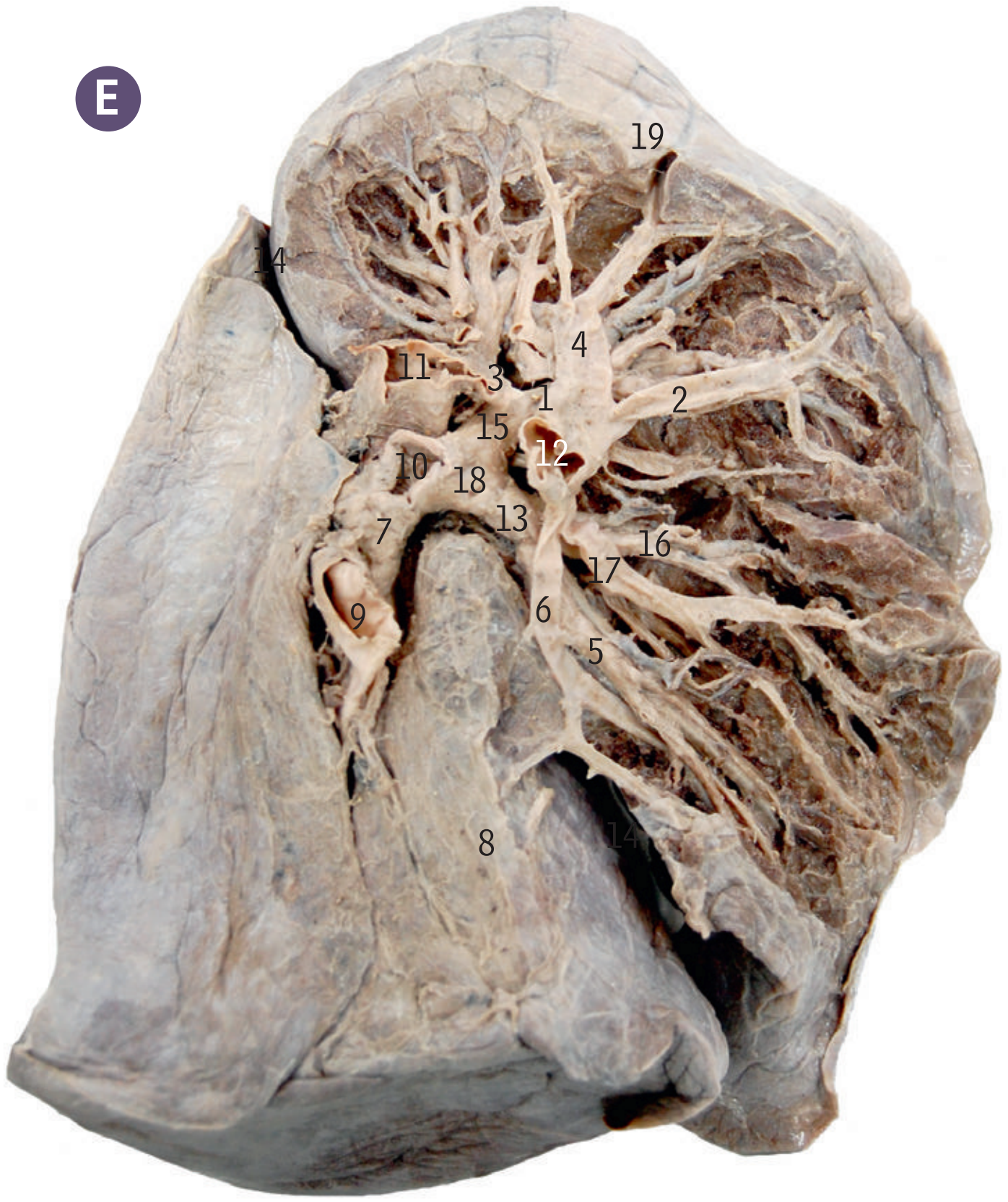

1 Anterior segmental bronchi
2 Anterior segmental vein
3 Apicoposterior segmental bronchi
4 Apicoposterior segmental vein
5 Inferior lingular segmental bronchus
6 Inferior lingular segmental vein
7 Inferior lobar bronchus
8 Inferior lobe
9 Left inferior pulmonary vein
10 Left main bronchus
11 Left pulmonary artery
12 Left superior pulmonary vein
13 Lingular bronchus
14 Oblique fissure
15 Superior division bronchus
16 Superior lingular segmental bronchus
17 Superior lingular segmental vein
18 Superior lobar bronchus
19 Superior lobe

Sagittal CT, lung windows*

*Arrows show oblique fissure.

Haemothorax, see pages 215–216.

A Cast of the bronchial tree and pulmonary vessels *from the front*

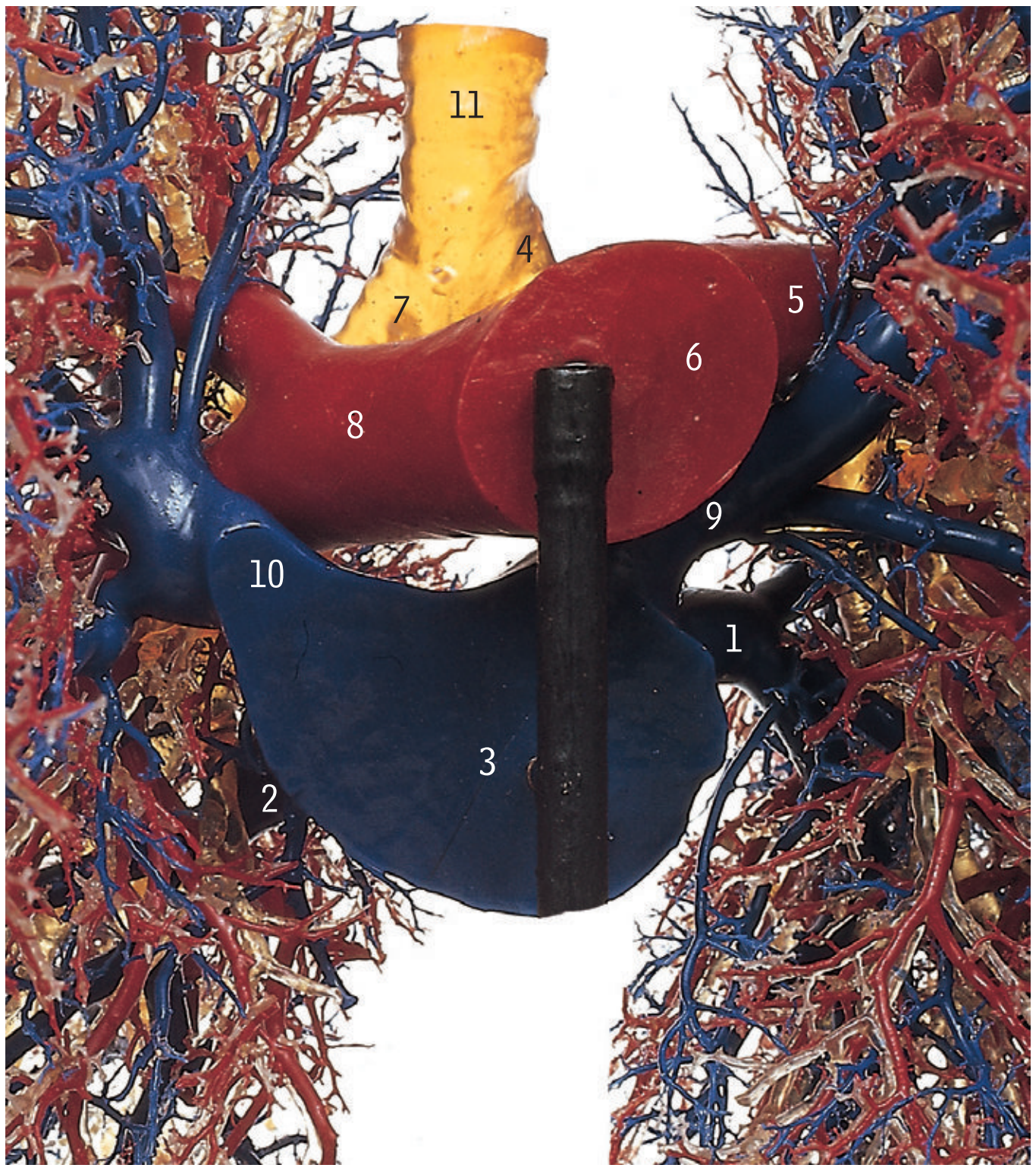

The pulmonary trunk (6) divides into the left and right pulmonary arteries (5 and 8), and these vessels have been injected with red resin. The four pulmonary veins (9, 1, 2 and 10) which drain into the left atrium (3) have been filled with blue resin. Note that in the living body the pulmonary veins are filled with oxygenated blood from the lungs and would normally be represented by a red colour; similarly the pulmonary arteries contain deoxygenated blood and should be represented by a blue colour.

- **1** Inferior left pulmonary vein
- **2** Inferior right pulmonary vein
- **3** Left atrium
- **4** Left principal bronchus
- **5** Left pulmonary artery
- **6** Pulmonary trunk
- **7** Right principal bronchus
- **8** Right pulmonary artery
- **9** Superior left pulmonary vein
- **10** Superior right pulmonary vein
- **11** Trachea

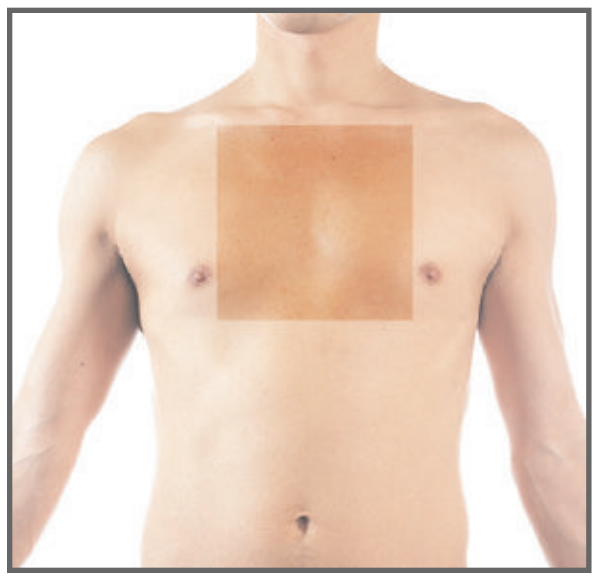

B Lung roots and bronchial arteries *right side from above*

The thorax has been sectioned transversely at the level of the third thoracic vertebra (17), just above the arch of the aorta (1) whose three larger branches have been removed (8, 6 and 3), and lung tissue at the hilum has been dissected away from above. The oesophagus (10) and trachea (19) have been tilted forwards to show one of the bronchial arteries (11).

- **1** Arch of aorta
- **2** Azygos vein
- **3** Brachiocephalic trunk
- **4** Inferior lobe artery
- **5** Inferior lobe bronchus
- **6** Left common carotid artery
- **7** Left recurrent laryngeal nerve
- **8** Left subclavian artery
- **9** Middle lobe bronchus
- **10** Oesophagus
- **11** Right bronchial artery
- **12** Right principal bronchus
- **13** Right pulmonary artery
- **14** Right vagus nerve
- **15** Superior lobe bronchus
- **16** Superior vena cava
- **17** Third thoracic vertebra
- **18** Thoracic duct
- **19** Trachea
- **20** Tributary of inferior pulmonary vein

Carcinoma of the oesophagus, pulmonary embolism, see pages 215–216.

C Cast of the pulmonary arteries and bronchi *from the front*

D Pulmonary arteriogram

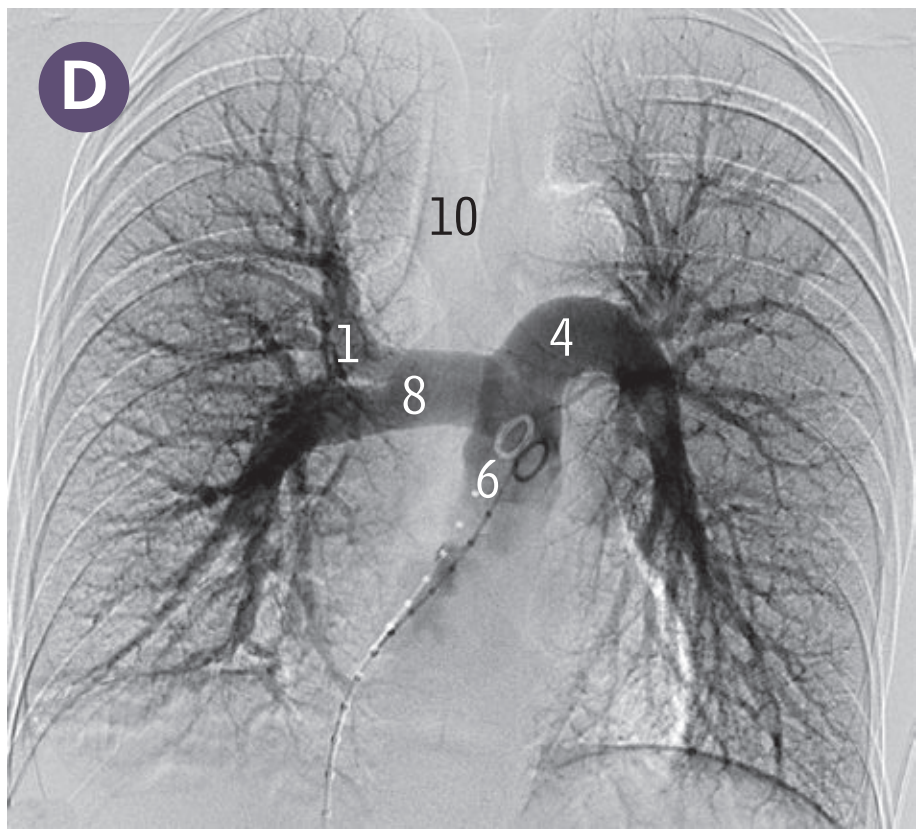

The upper part of the pulmonary trunk (6) is seen end-on after cutting off the lower part, and the bifurcation of the trunk into the left (4) and right (8) pulmonary arteries is in front of the beginning of the left main bronchus (3). In the living body, these pulmonary vessels contain deoxygenated blood and would normally be represented by a blue colour, but here they have been filled with red resin. Compare the vessels in the cast with those in the arteriogram D.

1. Branch of right pulmonary artery to superior lobe
2. Inferior lobe bronchus
3. Left principal bronchus
4. Left pulmonary artery
5. Middle lobe bronchus
6. Pulmonary trunk
7. Right principal bronchus
8. Right pulmonary artery
9. Superior lobe bronchus
10. Trachea

E Cast of the bronchi and bronchial arteries *from the front*

Part of the aorta (1 and 10) has been injected with red resin to fill the bronchial arteries. These vessels normally run behind the bronchi and their branches but in this specimen, they are in front.

1. Arch of aorta
2. Inferior lobe bronchus
3. Left principal bronchus
4. Middle lobe bronchus
5. Origin of lower left bronchial artery
6. Origin of right bronchial artery
7. Origin of upper left bronchial artery
8. Right principal bronchus
9. Superior lobe bronchus
10. Thoracic aorta
11. Trachea

A Right lung *medial surface*

In the hardened dissecting room specimen, adjacent structures make impressions on the medial surface of the lung. The most prominent feature on the right side is the groove for the azygos vein (3), above and behind the structures of the lung root (9, 2 and 1).

1 Branches of right principal bronchus
2 Branches of right pulmonary artery
3 Groove for azygos vein
4 Groove for first rib
5 Groove for subclavian artery
6 Groove for subclavian vein
7 Groove for superior vena cava
8 Oesophageal and tracheal area
9 Right pulmonary veins
10 Transverse fissure

The upper end of the medial surface of the right lung lies against the oesophagus and trachea (A8) with only the pleura intervening, but on the left, the subclavian artery (B5) (and the left common carotid in front of it) keep the lung further away from these structures.

B Left lung *medial surface*

Compare with the right lung in A, and note the large size of the impression made by the aorta on the left lung (B3), in contrast to the smaller azygos groove on the right (A3).

1 Branches of left principal bronchus
2 Branches of left pulmonary artery
3 Groove for aorta
4 Groove for first rib
5 Groove for left subclavian artery
6 Left pulmonary veins
7 Lymph node, containing carbon
8 Pulmonary ligament

Carcinoma of the lung, mesothelioma, tuberculosis, see pages 215–216.

Lower neck and upper thorax *surface markings*

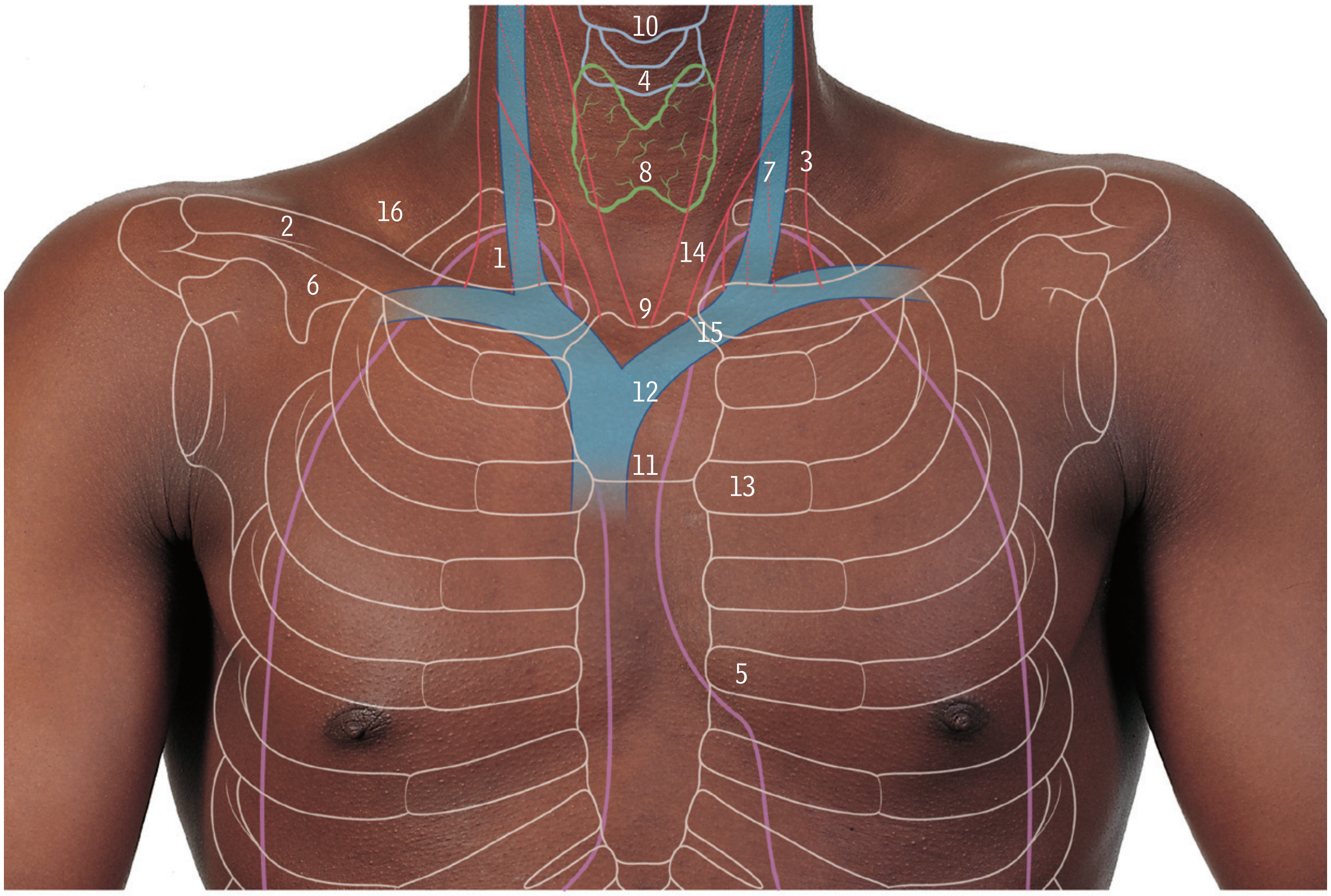

The purple line indicates the extent of the pleura and lung on each side; the apices of the pleura and lung (1) rise into the neck for about 3 cm above the medial third of the clavicle. The lower end of the internal jugular vein (7) lies behind the interval between the sternal (14) and clavicular (3) heads of sternocleidomastoid. Behind the sternoclavicular joint (15) the internal jugular and subclavian veins unite to form the brachiocephalic vein. The trachea (8) is felt in the midline above the jugular notch (9), and the arch of the cricoid cartilage (4) is 4–5 cm above the notch. The manubriosternal joint is at the level of the second costal cartilage (13) and opposite the lower border of the body of the fourth thoracic vertebra, and the horizontal plane through these points indicates the junction between the superior and inferior parts of the mediastinum. The left brachiocephalic vein passes behind the upper half of the manubrium to unite with the right brachiocephalic at the lower border of the right first costal cartilage (to form the superior vena cava). The midpoint of the manubrium (12) marks the highest level of the arch of the aorta and the origin of the brachiocephalic trunk. Compare many of the features mentioned here with the structures in the dissection on page 206.

1 Apex of pleura and lung
2 Clavicle
3 Clavicular head of sternocleidomastoid
4 Cricoid cartilage
5 Fourth costal cartilage
6 Infraclavicular fossa
7 Internal jugular vein
8 Isthmus of thyroid gland overlying trachea
9 Jugular notch (suprasternal)
10 Laryngeal prominence of the thyroid cartilage
11 Manubriosternal joint
12 Midpoint of manubrium of sternum
13 Second costal cartilage
14 Sternal head of sternocleidomastoid
15 Sternoclavicular joint
16 Supraclavicular fossa

Coronal CT, venous phase of chest showing right (RBCV) and left (LBCV) brachiocephalic veins

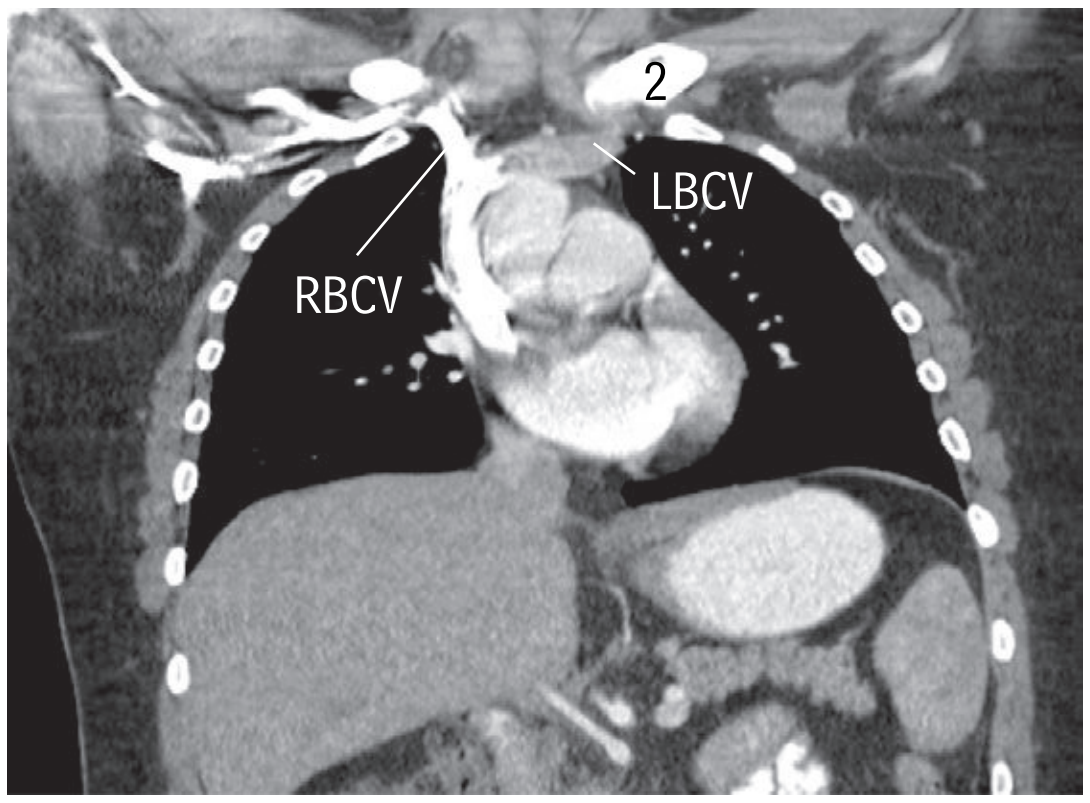

Superior vena cava obstruction, variations in great veins, see pages 215–216.

Thoracic inlet and mediastinum *from the front*

The anterior thoracic wall and the medial ends of the clavicles have been removed, but part of the parietal pleura (16) remains over the medial part of each lung. The right internal jugular vein has also been removed, displaying the thyrocervical trunk (32) and the origin of the internal thoracic artery (9). Inferior thyroid veins (7) run down over the trachea (33) to enter the left brachiocephalic vein (13). The thymus (31) has been dissected out from mediastinal fat; thymic veins (30) enter the left brachiocephalic vein, and an unusual thymic artery (1) arises from the brachiocephalic trunk (4).

The remains of the thymus (31) are in front of the pericardium, but in the child, where the thymus is much larger (see page 184), it may extend upwards in front of the great vessels as high as the lower part of the thyroid gland (12).

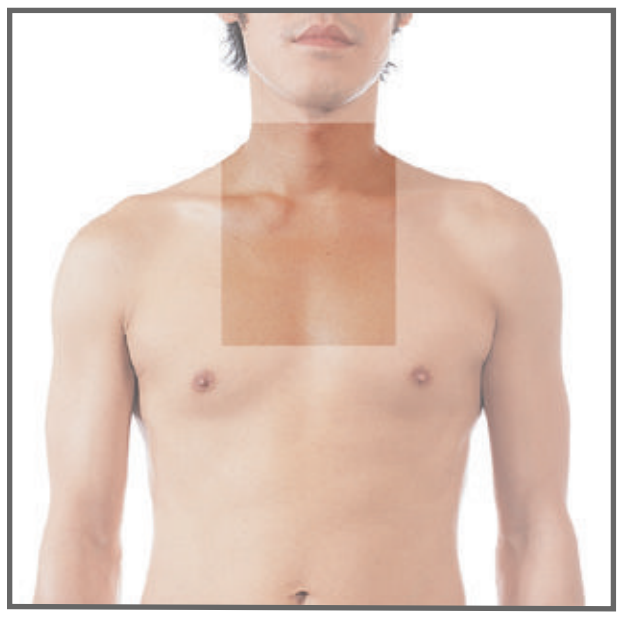

1 A thymic artery
2 Arch of cricoid cartilage
3 Ascending cervical artery
4 Brachiocephalic trunk
5 First rib cut edge
6 Inferior thyroid artery
7 Inferior thyroid veins
8 Internal jugular vein
9 Internal thoracic artery
10 Internal thoracic vein
11 Isthmus of thyroid gland
12 Lateral lobe of thyroid gland
13 Left brachiocephalic vein
14 Left common carotid artery
15 Left vagus nerve
16 Parietal pleura (cut edge) over lung
17 Phrenic nerve
18 Right brachiocephalic vein
19 Right common carotid artery
20 Right recurrent laryngeal nerve
21 Right subclavian artery
22 Right vagus nerve
23 Scalenus anterior
24 Subclavian vein
25 Superficial cervical artery
26 Superior vena cava
27 Suprascapular artery
28 Sympathetic trunk
29 Thoracic duct
30 Thymic veins
31 Thymus
32 Thyrocervical trunk
33 Trachea
34 Unusual cervical tributary of 18
35 Upper trunk of brachial plexus
36 Vertebral vein

Pancoast tumour, thoracic outlet syndromes, see pages 215–216.

Thoracic inlet and superior mediastinum
axilla and root of neck

1 Aortic arch
2 Axillary artery
3 Axillary vein
4 Biceps, short head
5 Brachiocephalic trunk
6 Clavicle (cut and removed)
7 Common carotid artery
8 Deltoid
9 First rib
10 Internal jugular vein
11 Internal thoracic artery
12 Left brachiocephalic vein
13 Medial cord, brachial plexus
14 Median nerve
15 Musculocutaneous nerve
16 Parietal pleural covering of chest wall
17 Pericardium, fibrous layer
18 Phrenic nerve
19 Radial nerve
20 Right brachiocephalic vein
21 Subclavian artery
22 Subclavian vein
23 Superior vena cava
24 Suprascapular artery
25 Suprascapular nerve
26 Thoracodorsal vein
27 Transverse cervical artery
28 Ulnar nerve
29 Upper trunk, brachial plexus
30 Vagus nerve
31 Visceral pleura covering lung

Bronchiectasis, sarcoidosis, see pages 215–216.

Thoracic inlet *right upper ribs, from below*

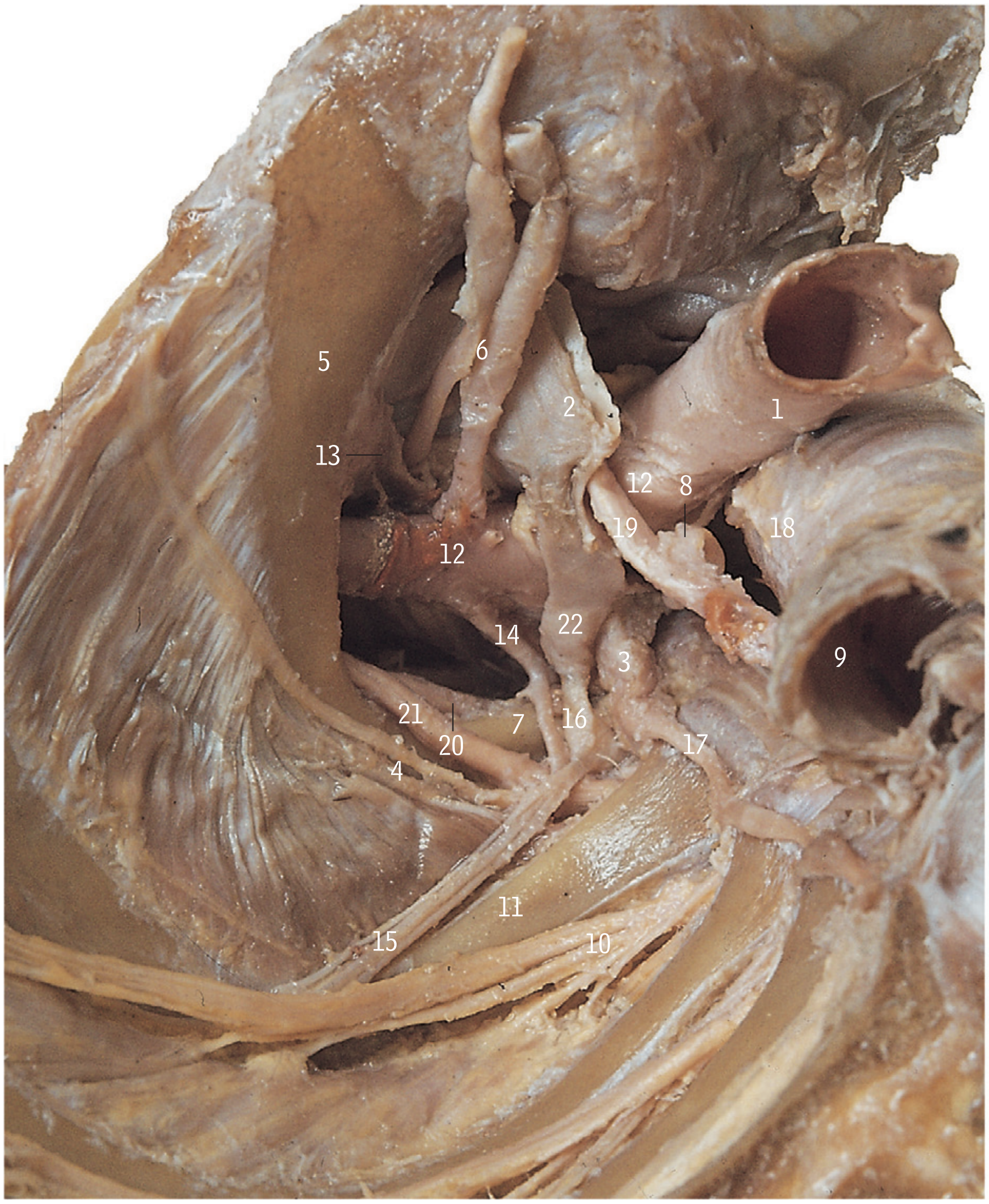

1 Brachiocephalic trunk
2 Brachiocephalic vein
3 Cervicothoracic (stellate) ganglion
4 First intercostal nerve
5 First rib
6 Internal thoracic vessels
7 Neck of first rib
8 Recurrent laryngeal nerve
9 Right principal bronchus
10 Second intercostal nerve
11 Second rib
12 Subclavian artery
13 Subclavian vein
14 Superior intercostal artery
15 Superior intercostal vein
16 Supreme intercostal vein (unusually large)
17 Sympathetic trunk
18 Trachea
19 Vagus nerve
20 Ventral ramus of eighth cervical nerve
21 Ventral ramus of first thoracic nerve
22 Vertebral vein

The neck of the first rib (7) is crossed in order from medial to lateral by the sympathetic trunk (17), supreme intercostal vein (16), superior intercostal artery (14) and the ventral ramus of the first thoracic nerve (21).

This is the view looking upwards into the right side of the thoracic inlet – the region occupied by the cervical pleura, here removed. The under-surface of most of the first rib (5) is seen from below, with the subclavian artery (12) passing over the top of it after giving off the internal thoracic branch (6) which runs towards the top of the picture (to the anterior thoracic wall), and the costocervical trunk whose superior intercostal branch (14) runs down over the neck of the first rib (7). The vertebral vein (22) has come down from the neck and is labelled on its posterior surface before entering the brachiocephalic vein (2, labelled at its opened cut edge). The vertebral vein receives an unusually large supreme intercostal vein (16). On its medial side is the sympathetic trunk (17) with the cervicothoracic ganglion (3). The neck of the first rib (7) has the ventral ramus of the first thoracic nerve (21) below it.

Catheterisation of subclavian vein, thoracic outlet syndromes, see pages 215–216.

Posterior mediastinum *from the right hand side of the chest*

1 Azygos arch
2 Azygos vein
3 Gray and white communicating rami
4 Greater splanchnic nerve
5 Intercostal artery
6 Intercostal nerve
7 Intercostal vein
8 Oesophageal plexus
9 Oesophagus
10 Phrenic nerve
11 Sympathetic chain
12 Sympathetic ganglion
13 Thoracic duct

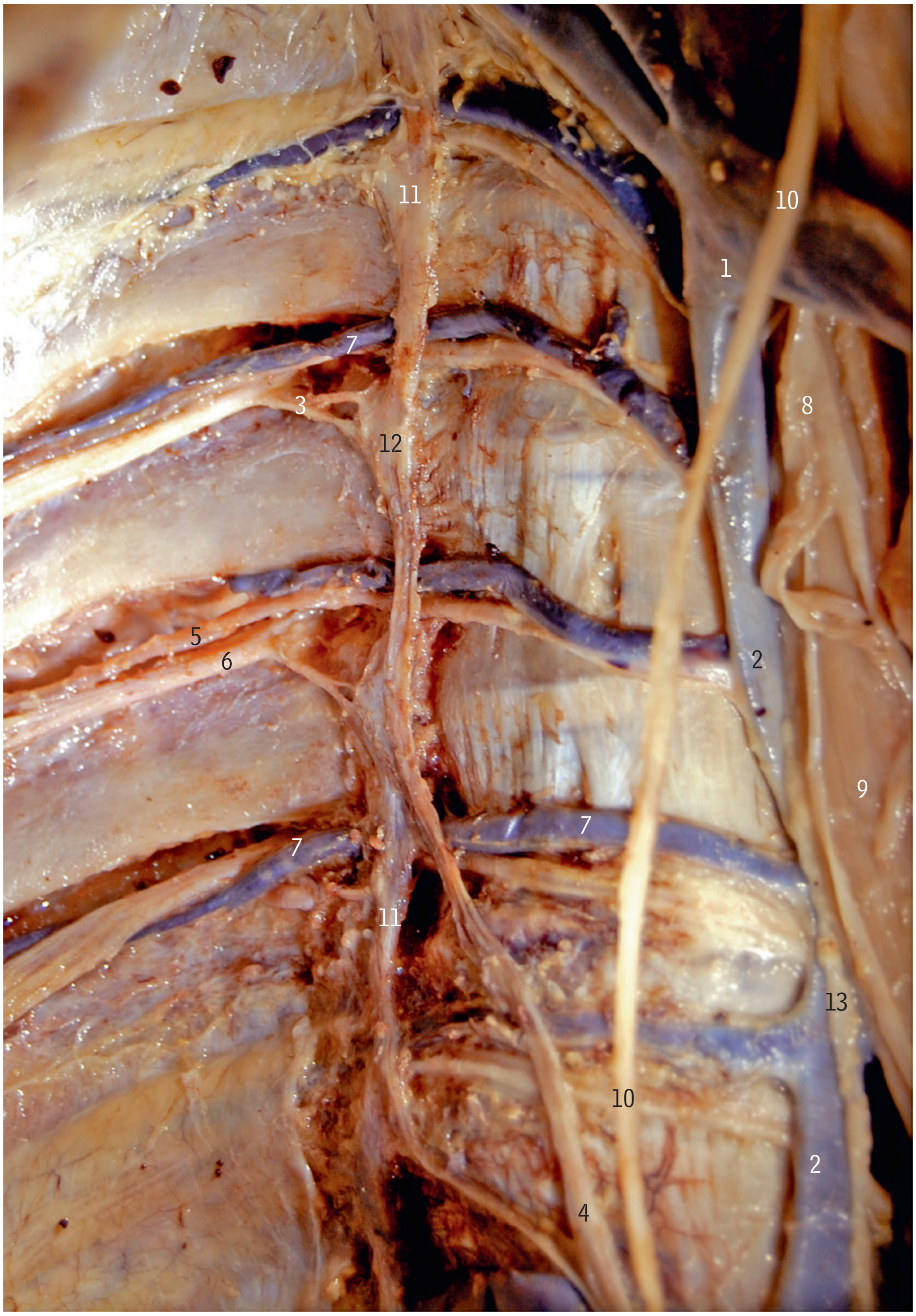

Azygos lobe, see pages 215–216.

A Oesophagus *lower thoracic part, from the front*

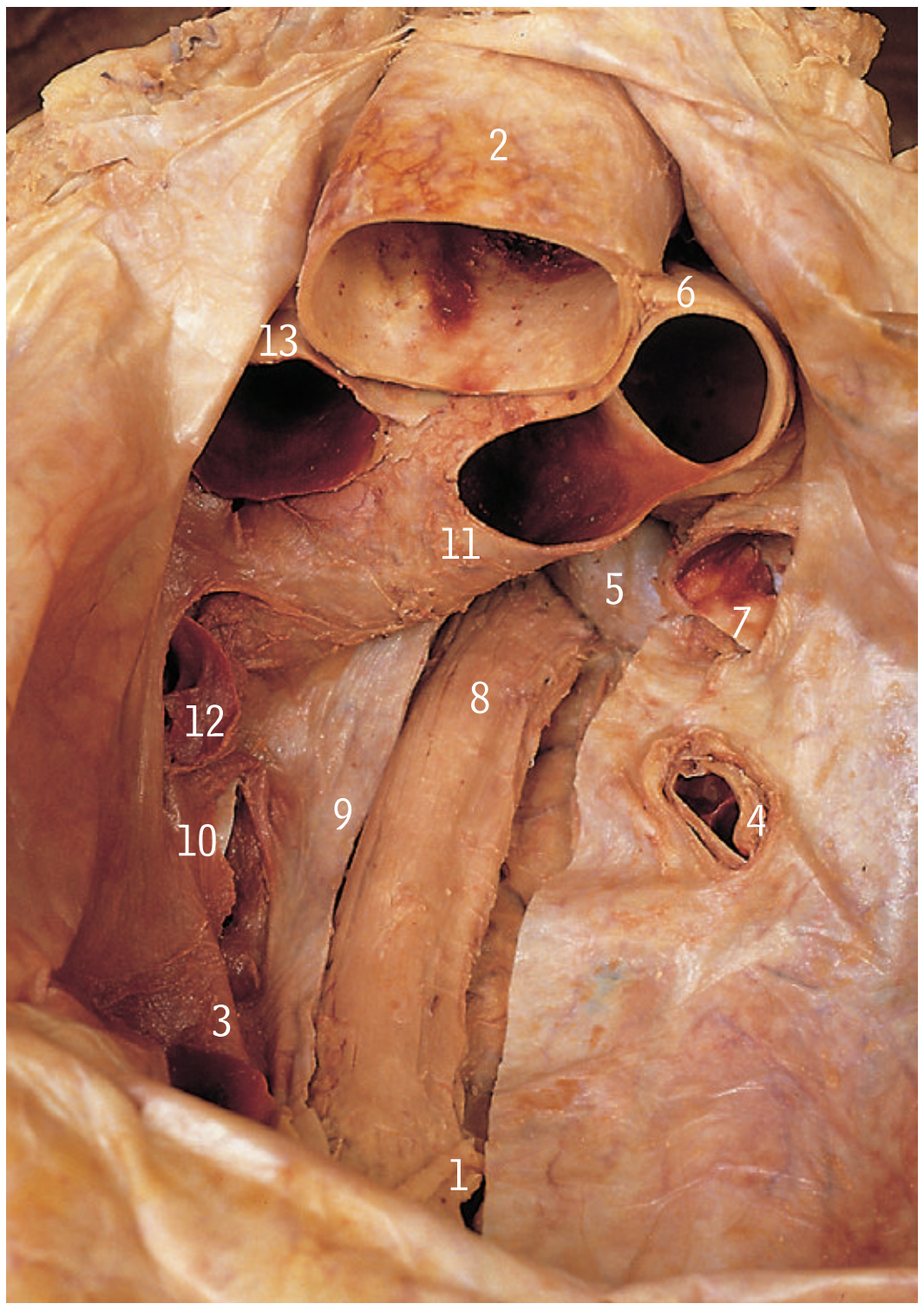

The heart has been removed from the pericardial cavity by transecting the great vessels, the pulmonary trunk being cut at the point where it divides into the two pulmonary arteries (11 and 6). Part of the pericardium (9) at the back has been removed to reveal the oesophagus (8). It is seen below the left principal bronchus (5) and is being crossed by the beginning of the right pulmonary artery (11).

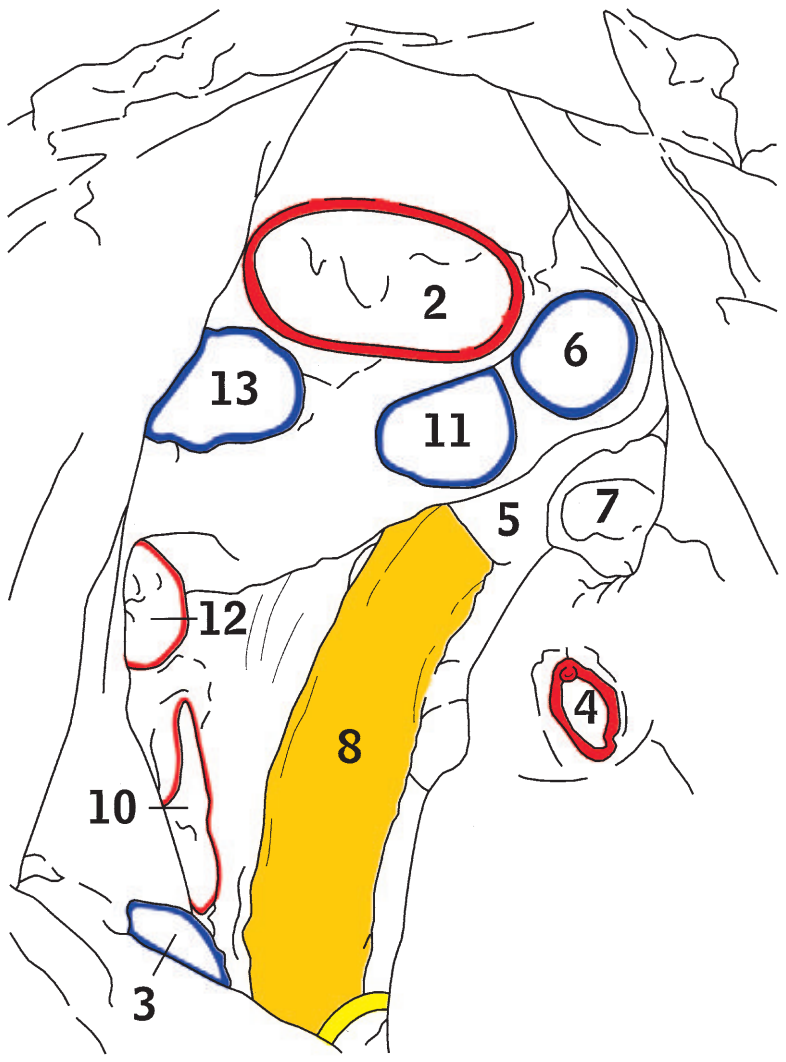

1. Anterior oesophageal trunk
2. Ascending aorta
3. Inferior vena cava
4. Left inferior pulmonary vein
5. Left principal bronchus
6. Left pulmonary artery
7. Left superior pulmonary vein
8. Oesophagus
9. Pericardium (cut edge)
10. Right inferior pulmonary vein
11. Right pulmonary artery
12. Right superior pulmonary vein
13. Superior vena cava

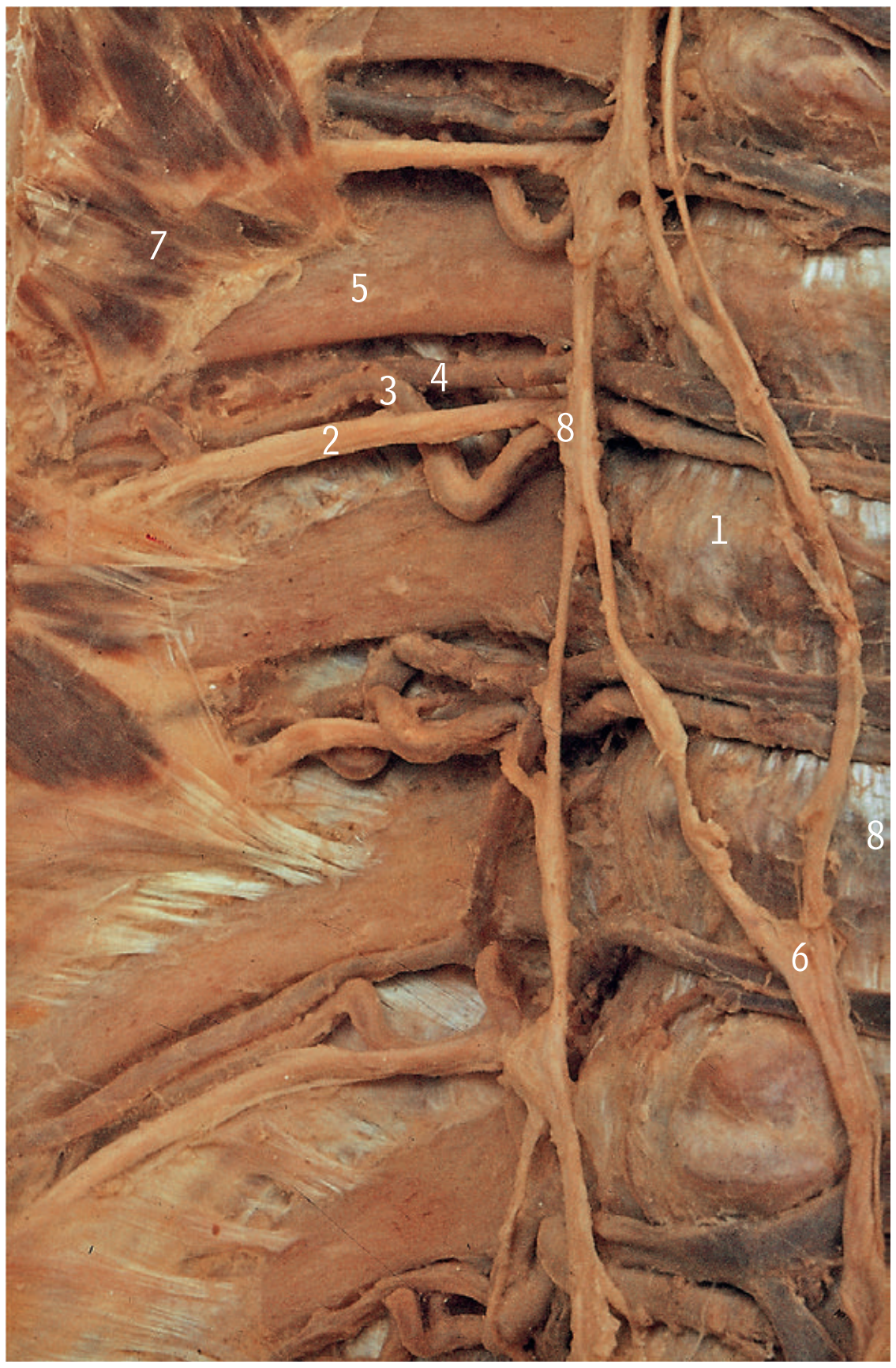

B Intercostal spaces *posterior internal view*

This dissection shows the medial ends of some intercostal spaces of the right side, viewed from the front and slightly from the right. The pleura has been removed, revealing subcostal muscles (7) laterally, the nerves and vessels (4, 3 and 2) in the intercostal spaces, and the sympathetic trunk (8) and greater splanchnic nerve (6) on the sides of the vertebral bodies (as at 1).

1. Body of ninth thoracic vertebra
2. Eighth intercostal nerve
3. Eighth posterior intercostal artery
4. Eighth posterior intercostal vein
5. Eighth rib
6. Greater splanchnic nerve
7. Subcostal muscle
8. Sympathetic trunk and ganglia

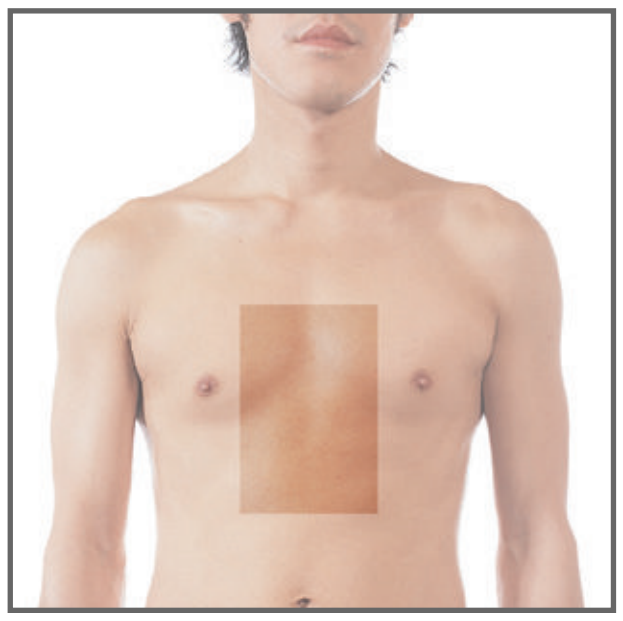

Intercostal drainage, see pages 215–216.

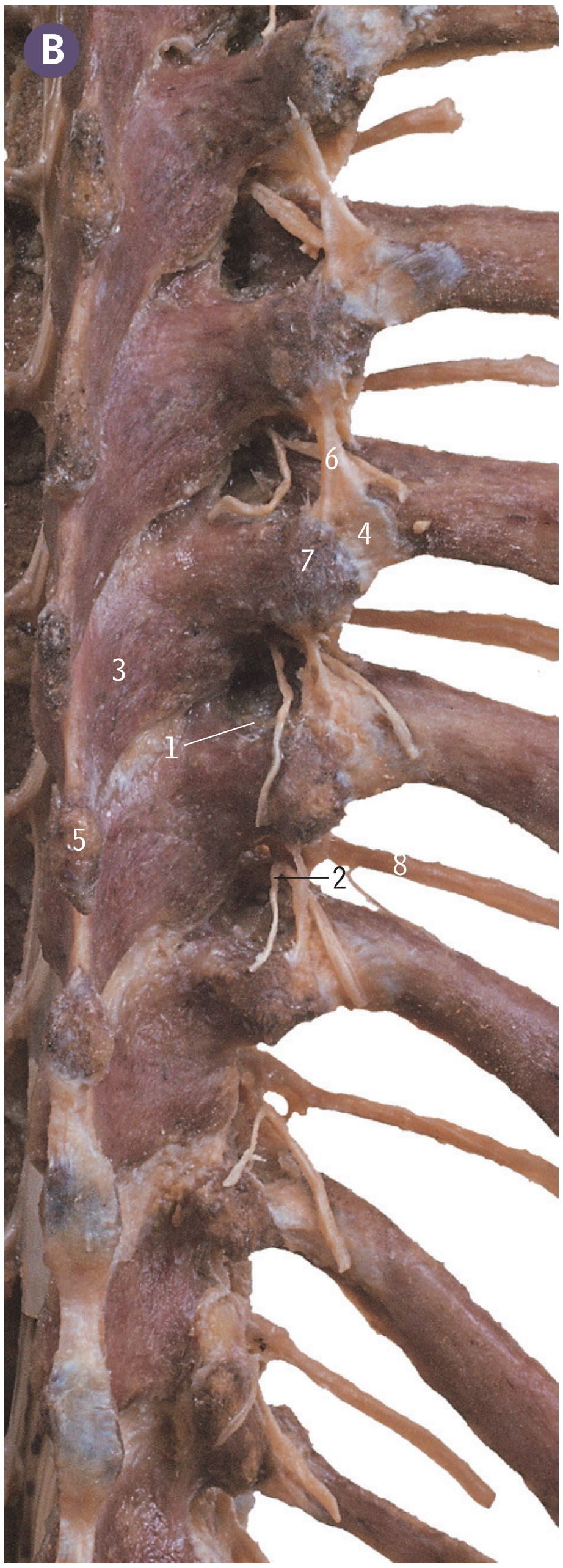

A Joints of the heads of the ribs *from the right*

In this part of the right mid-thoracic region, the ribs have been cut short beyond their tubercles, and the joints that the two facets of the head of a rib make with the facets on the sides of adjacent vertebral bodies and the intervening disc are shown, as at 4, 9 and 2, where the radiate ligament (4) covers the capsule of these small synovial joints.

1 Greater splanchnic nerve
2 Intervertebral disc
3 Neck of rib
4 Radiate ligament of head of rib
5 Rami communicantes
6 Superior costotransverse ligament
7 Sympathetic trunk
8 Ventral ramus of spinal nerve
9 Vertebral body

B Costotransverse joints *from behind*

In this view of the right half of the thoracic vertebral column from behind, costotransverse joints between the transverse processes of vertebrae and the tubercles of ribs are covered by the lateral costotransverse ligaments (as at 4). The dorsal rami of spinal nerves (2) pass medial to the superior costotransverse ligaments (6); ventral rami (8) run in front of these ligaments.

1 Costotransverse ligament
2 Dorsal ramus of spinal nerve
3 Lamina
4 Lateral costotransverse ligament
5 Spinous process
6 Superior costotransverse ligament
7 Transverse process
8 Ventral ramus of spinal nerve

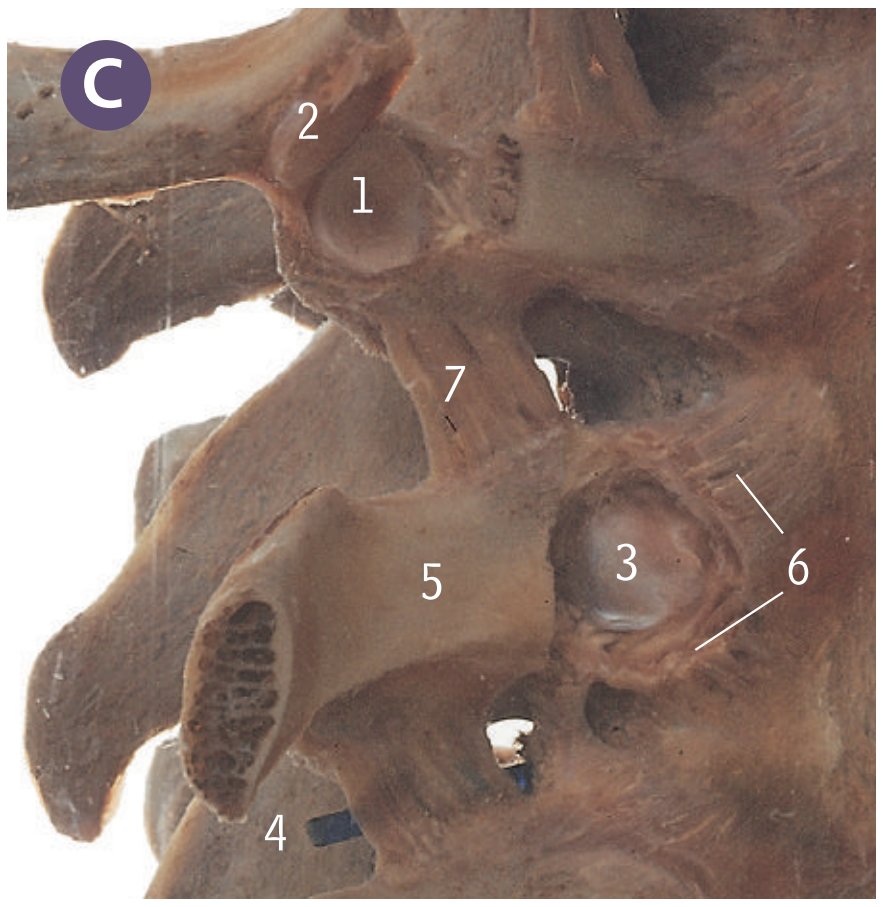

C Costovertebral joints *disarticulated, from the right*

In the upper part of the figure, the upper rib has been severed through its neck (5) and the part with the tubercle attached has been turned upwards after cutting through the capsule of the costotransverse joint, to show the articular facet of the tubercle (2) and the transverse process (1). The head of the lower rib has been removed after transecting the radiate ligament (6) and underlying capsule of the joint of the head of the rib (3).

1 Articular facet of transverse process
2 Articular facet of tubercle of rib
3 Cavity of joint of head of rib
4 Marker between anterior and posterior parts of superior costotransverse ligament
5 Neck of rib
6 Radiate ligament
7 Superior costotransverse ligament

Varicella-zoster virus infection – chest wall, see pages 215–216.

Cast of the aorta and associated vessels

A from the right B from the left

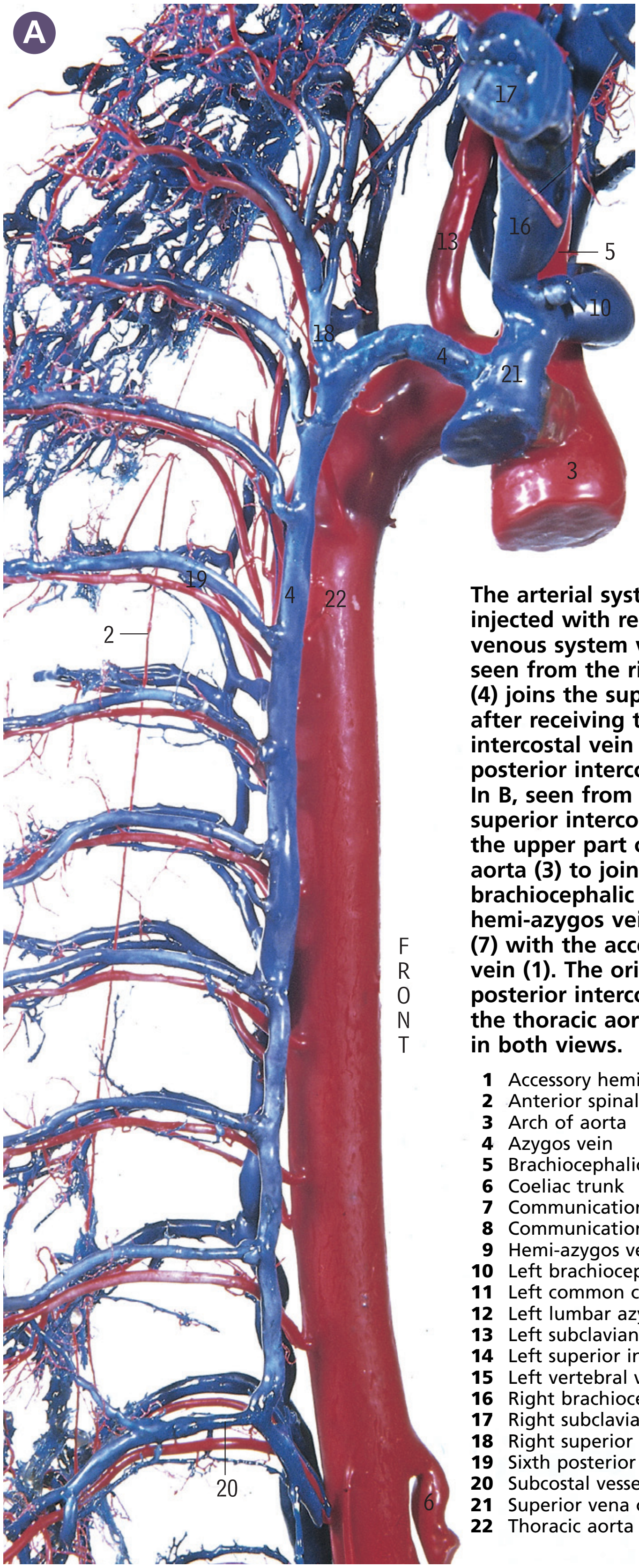

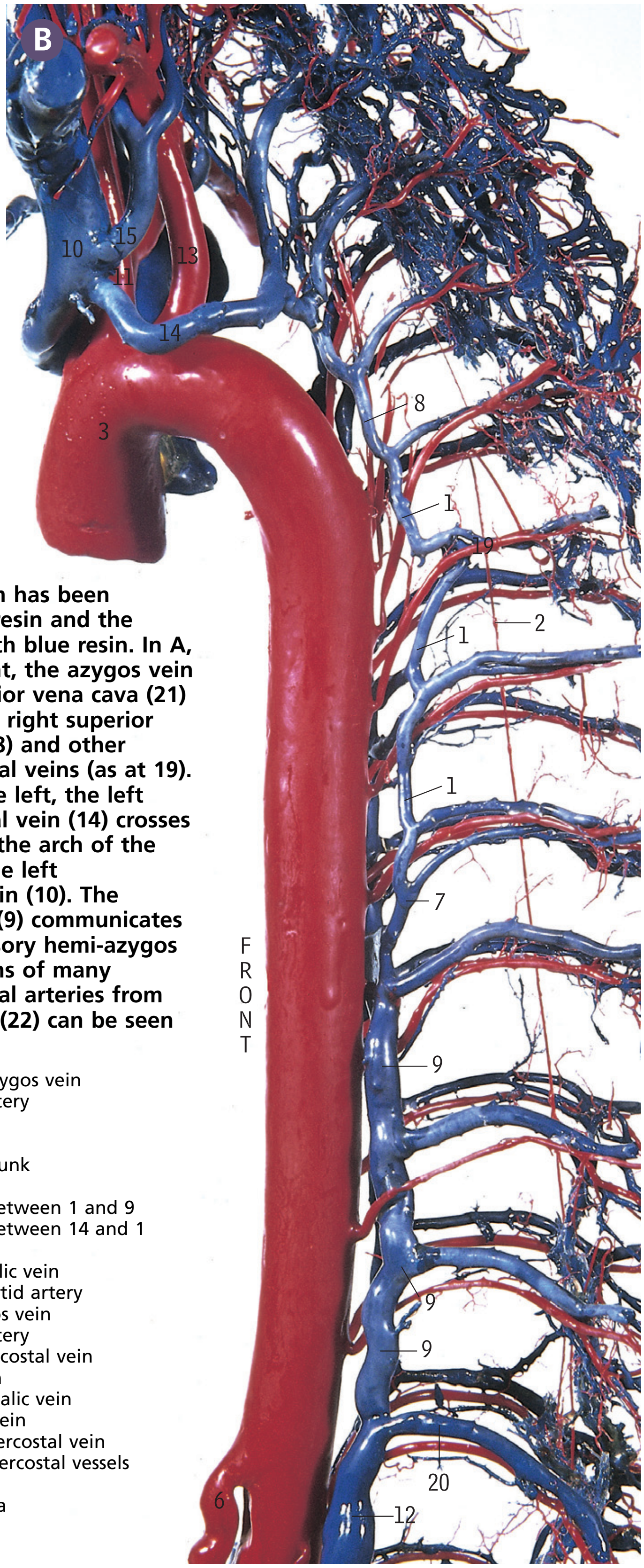

The arterial system has been injected with red resin and the venous system with blue resin. In A, seen from the right, the azygos vein (4) joins the superior vena cava (21) after receiving the right superior intercostal vein (18) and other posterior intercostal veins (as at 19). In B, seen from the left, the left superior intercostal vein (14) crosses the upper part of the arch of the aorta (3) to join the left brachiocephalic vein (10). The hemi-azygos vein (9) communicates (7) with the accessory hemi-azygos vein (1). The origins of many posterior intercostal arteries from the thoracic aorta (22) can be seen in both views.

1 Accessory hemi-azygos vein
2 Anterior spinal artery
3 Arch of aorta
4 Azygos vein
5 Brachiocephalic trunk
6 Coeliac trunk
7 Communication between 1 and 9
8 Communication between 14 and 1
9 Hemi-azygos vein
10 Left brachiocephalic vein
11 Left common carotid artery
12 Left lumbar azygos vein
13 Left subclavian artery
14 Left superior intercostal vein
15 Left vertebral vein
16 Right brachiocephalic vein
17 Right subclavian vein
18 Right superior intercostal vein
19 Sixth posterior intercostal vessels
20 Subcostal vessels
21 Superior vena cava
22 Thoracic aorta

Aortic dissection, variations in great arteries, see pages 215–216.

Diaphragm *from above*

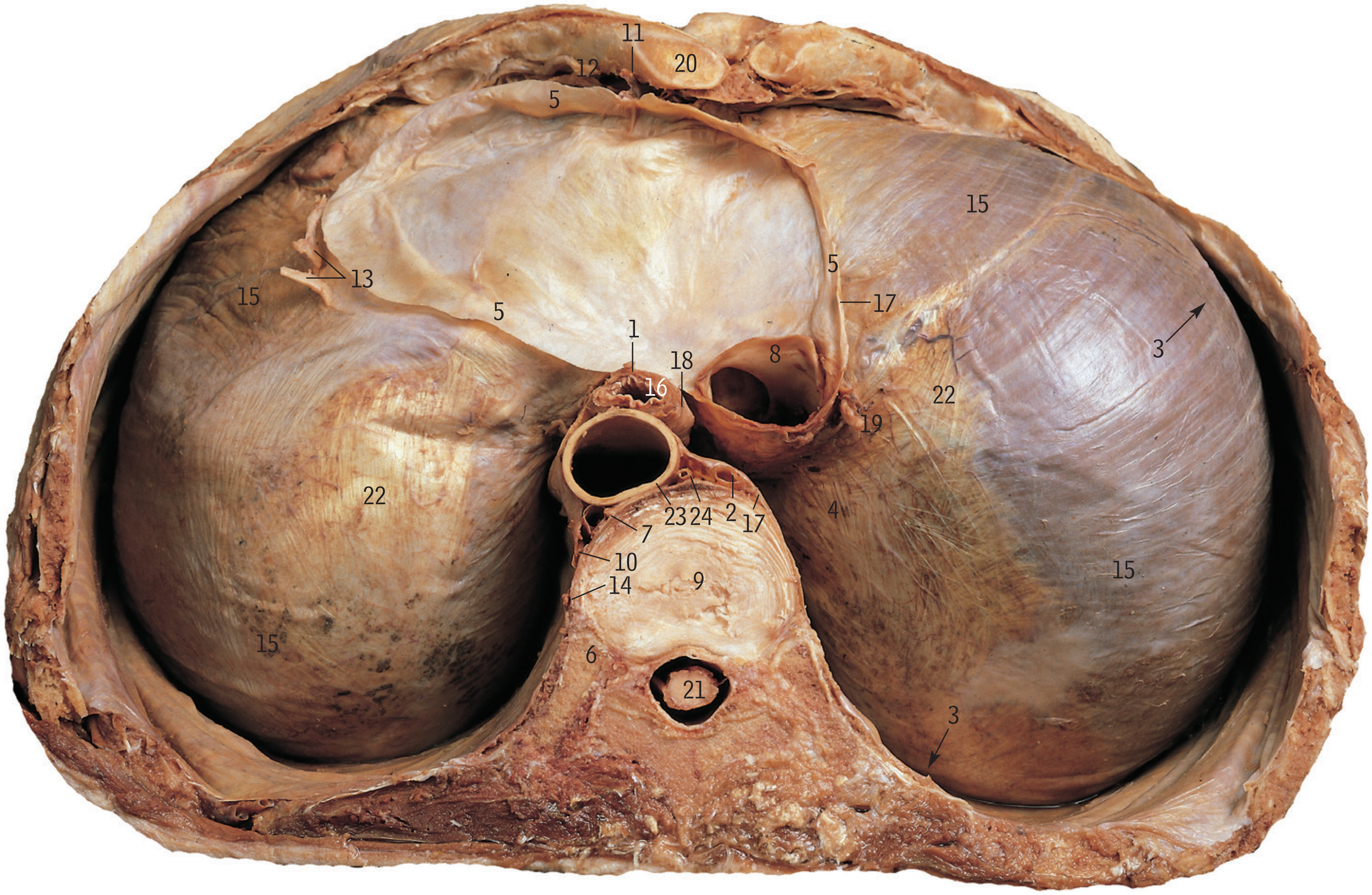

The thorax has been transected at the level of the disc between the ninth and tenth thoracic vertebrae.

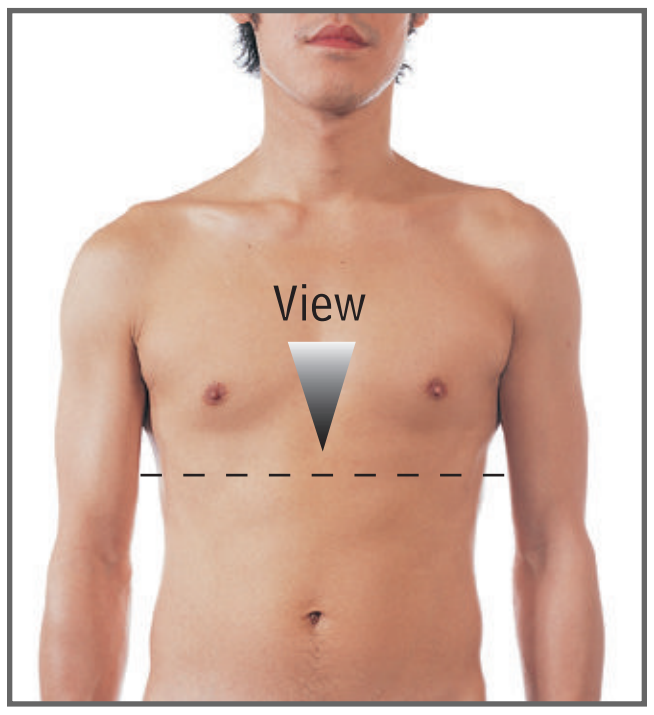

1. Anterior oesophageal plexus
2. Azygos vein
3. Costodiaphragmatic recess
4. Costomediastinal recess
5. Fibrous pericardium (cut edge)
6. Head of left ninth rib
7. Hemi-azygos vein
8. Inferior vena cava
9. Intervertebral disc
10. Left greater splanchnic nerve
11. Left internal thoracic artery
12. Left musculophrenic artery
13. Left phrenic nerve
14. Left sympathetic trunk
15. Muscle of diaphragm
16. Oesophagus
17. Pleura (cut edge)
18. Posterior oesophageal plexus
19. Right phrenic nerve
20. Seventh left costal cartilage
21. Spinal cord
22. Tendon of diaphragm
23. Thoracic aorta
24. Thoracic duct

According to the standard textbook description, the foramen for the vena cava is at the level of the disc between the eighth and ninth thoracic vertebrae, the oesophageal opening at the level of the tenth thoracic vertebra and the aortic opening opposite the twelfth thoracic vertebra. However, it is common for the oesophageal opening to be nearer the midline, as in this specimen (16), and the vena caval foramen (8) is lower than usual.

The vena caval foramen is in the tendinous part of the diaphragm and the oesophageal opening in the muscular part. The so-called aortic opening is not *in* the diaphragm but behind it (page 260).

The central tendon of the diaphragm has the shape of a trefoil leaf and has no bony attachment.

The right phrenic nerve (19) passes through the vena caval foramen in the tendinous part, but the left phrenic nerve (13) pierces the muscular part in front of the central tendon just lateral to the overlying pericardium.

The phrenic nerves are the *only motor* nerves to the diaphragm, including the crura. The supply from lower thoracic (intercostal and subcostal) nerves is purely sensory. Damage to one phrenic nerve completely paralyses its own half of the diaphragm.

Diaphragmatic hernia, gastro-oesophageal reflux, see pages 215–216.

Oesophageal radiographs *during a barium swallow*

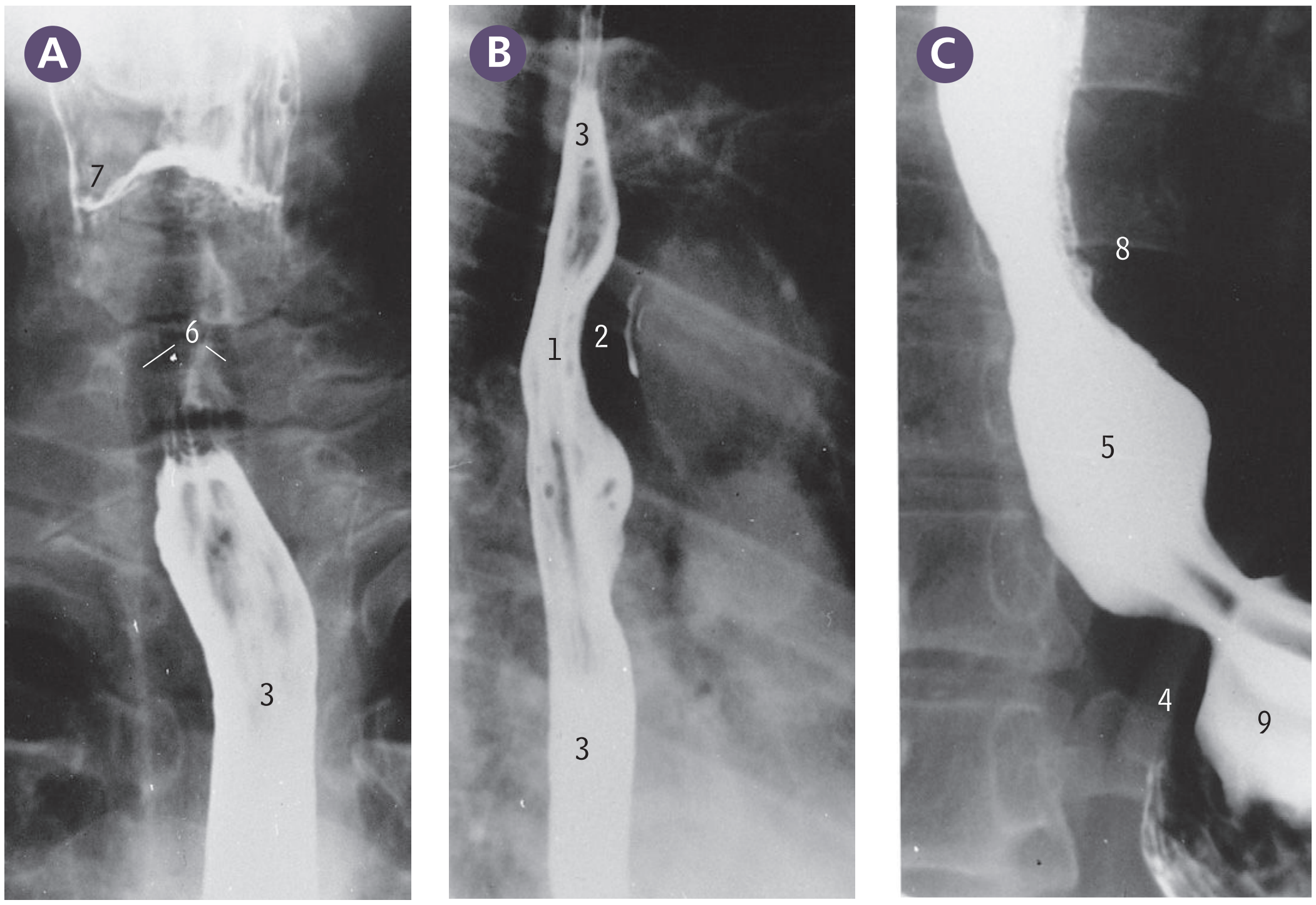

A lower pharynx and upper oesophagus

B middle part

C lower end

1 Aortic impression in oesophagus
2 Arch of aorta with plaque of calcification
3 Barium in oesophagus
4 Diaphragm
5 Lower thoracic oesophagus
6 Margins of trachea (translucent with contained air)
7 Piriform recess in laryngopharynx
8 Position of left atrium
9 Stomach

In A, viewed from the front, some of the barium paste adheres to the pharyngeal wall, outlining the piriform recesses (7), but most of it has passed into the oesophagus (3). In B, viewed obliquely from the left, the oesophagus is indented by the arch of the aorta (2) which shows some calcification in its wall – a useful aid to its identification. In C, there is some dilatation at the lower end of the thoracic oesophagus (5) and it is constricted where it passes through the diaphragm (4) to join the stomach (9). The left atrium of the heart (8) lies in front of the lower thoracic oesophagus (page 210, A8), but only when enlarged does the atrium cause an indentation in the oesophagus.

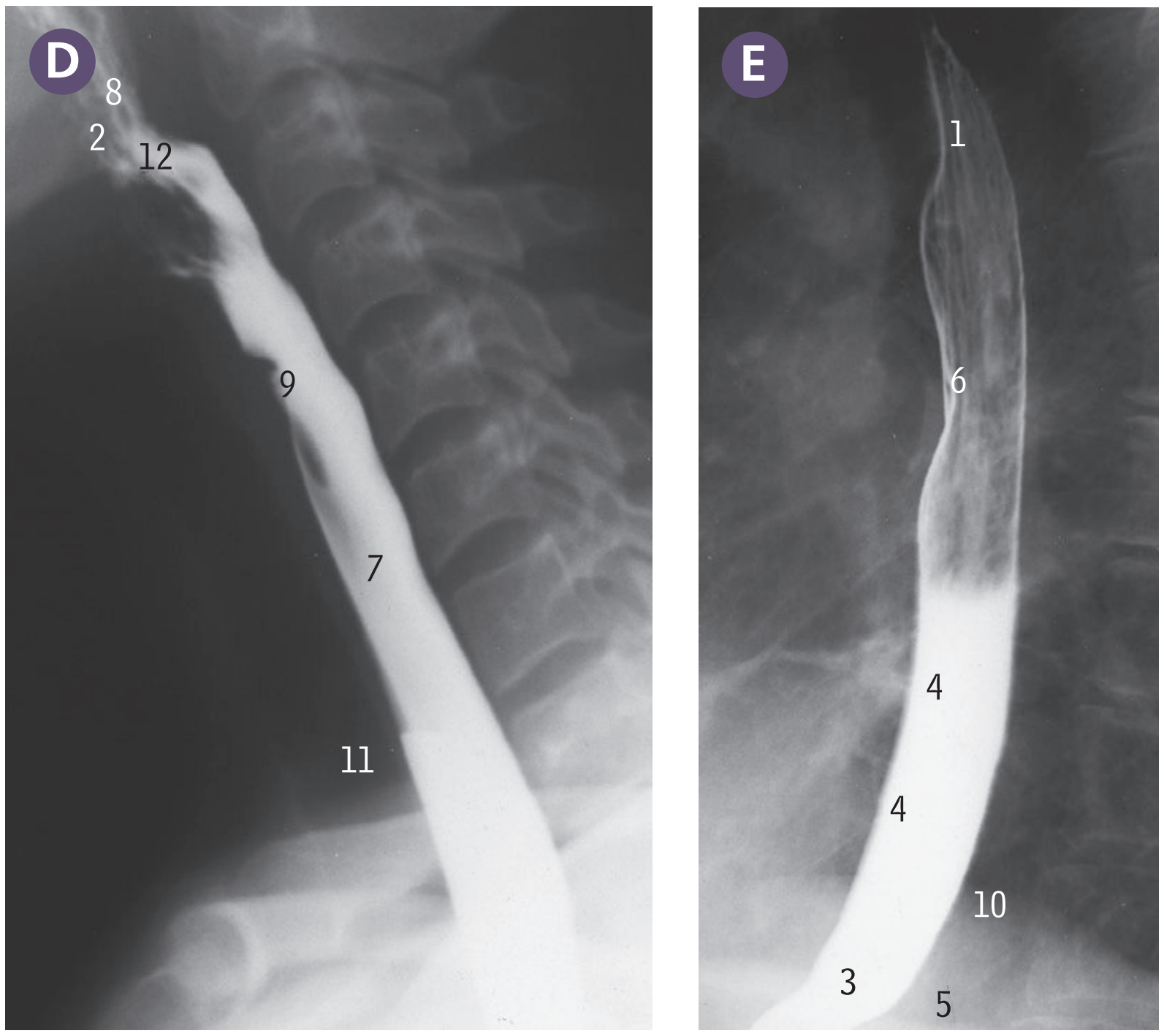

D cervical part

E thoracic part

1 Aortic arch impression
2 Base of tongue
3 Gastro-oesophageal junction
4 Left atrium position
5 Left hemidiaphragm
6 Left principal bronchus impression
7 Oesophagus
8 Oropharynx
9 Postcricoid venous plexus impression
10 Right hemidiaphragm
11 Trachea
12 Vallecula

Thorax

Clinical thumbnails, see website for details and further clinical images to download onto your own notes.

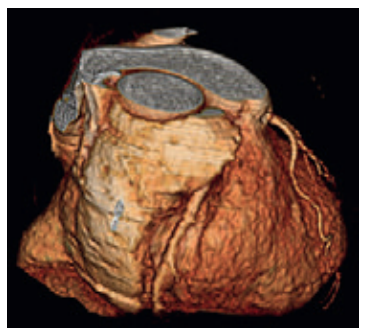
Angina pectoris

Aortic dissection

Artificial cardiac pacemaker

Auscultation of heart sounds

Azygos lobe

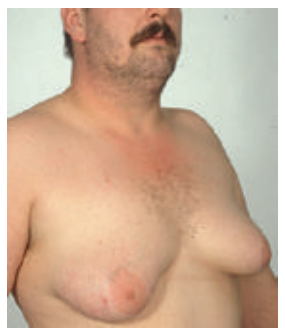
Breast abnormalities

Breast examination

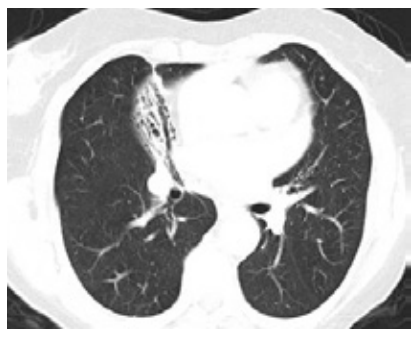
Bronchiectasis

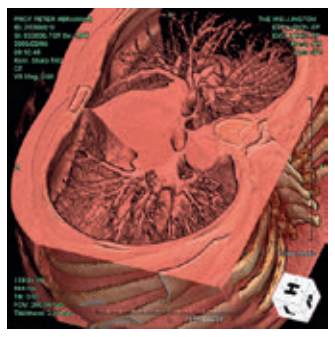
Bronchoscopy

Carcinoma of the breast

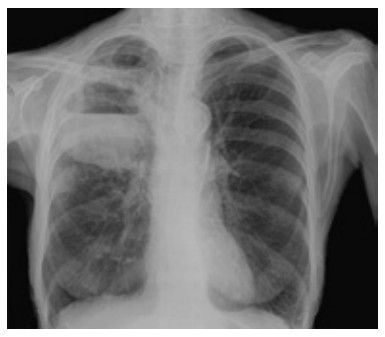
Carcinoma of the lung

Carcinoma of the oesophagus

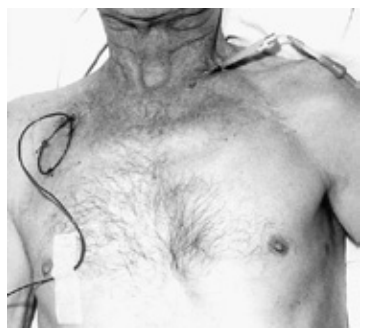
Cardiac pacemaker

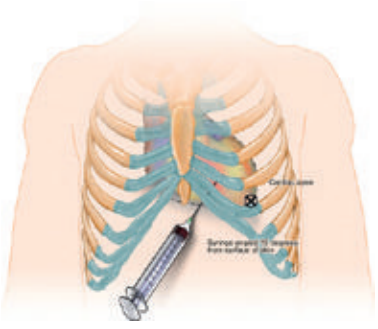
Cardiac tamponade

Cardiopulmonary resuscitation (CPR)

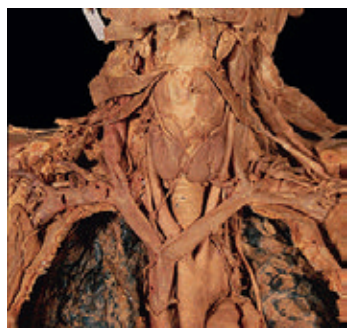
Catheterisation of subclavian vein

Coarctation of the aorta

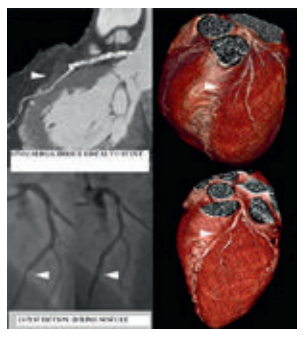
Coronary artery abnormalities

Coronary angiography

Coronary artery bypass grafting (CABG)

Costochondral pathology

Dextrocardia

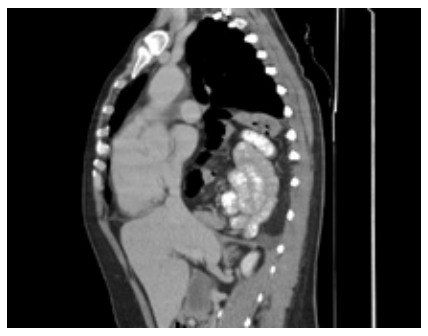
Diaphragmatic hernia

Empyema

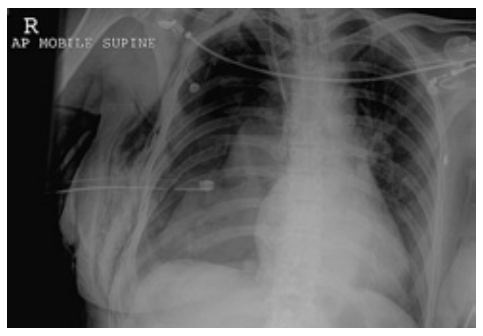
Flail chest

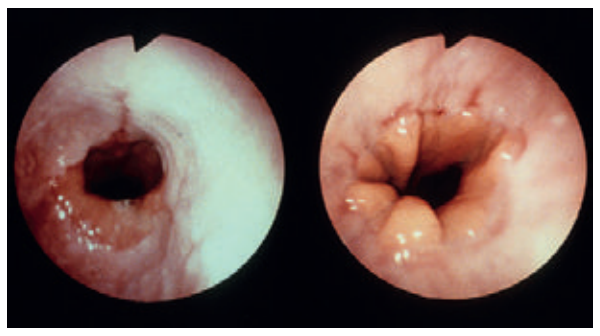
Gastro-oesophageal reflux

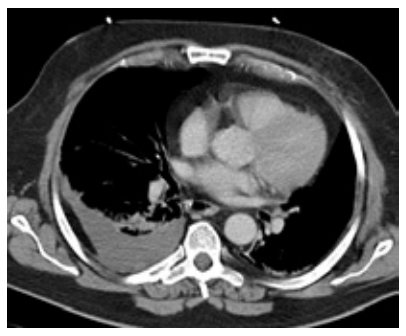
Haemothorax

Intercostal drainage

Intercostal nerve block

Left ventricular enlargement

Mastectomy

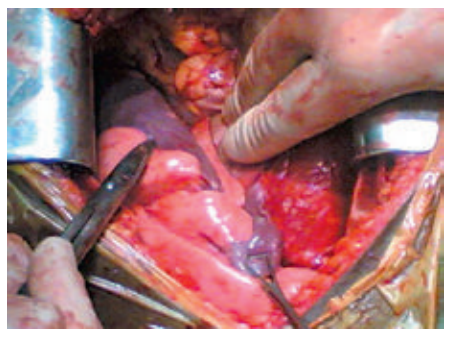
Median sternotomy

Mesothelioma

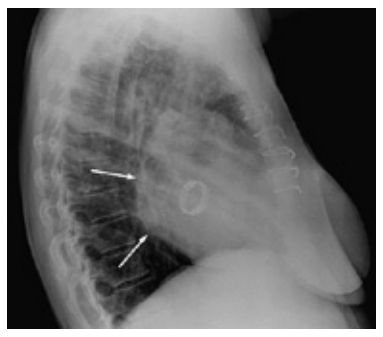
Mitral valve disease

Myocardial infarction

Orange peel texture of the skin and retraction of the nipple

Pancoast tumour

Pericardial effusion

Phrenic nerve palsy

Pleural effusion

Pneumothorax

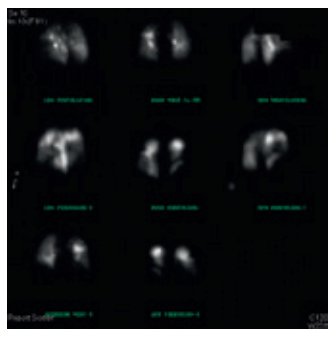
Pulmonary embolism

Sarcoidosis

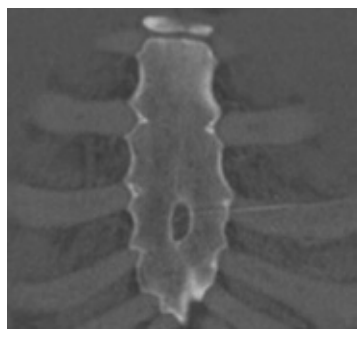
Sternal variants

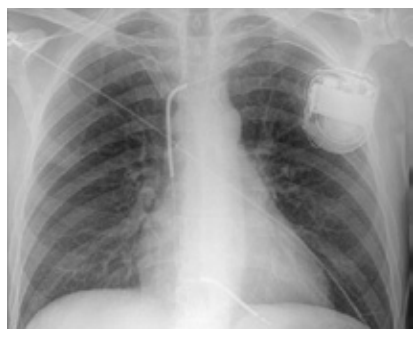
Subclavian arterial stent

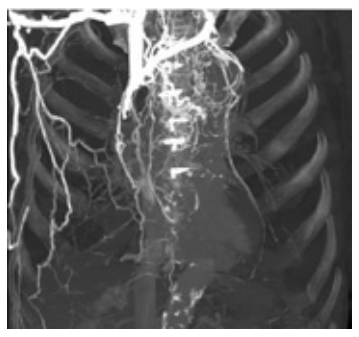
Superior vena cava obstruction

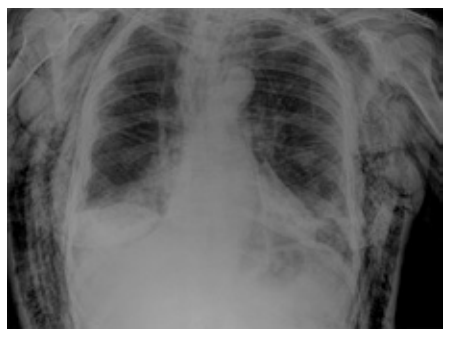
Surgical emphysema

Thoracic aortic aneurysm

Thoracic outlet syndromes

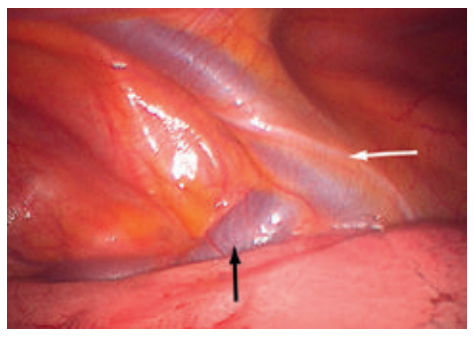
Thoracoscopy

Thymus

Transthoracic sympathectomy

Tuberculosis

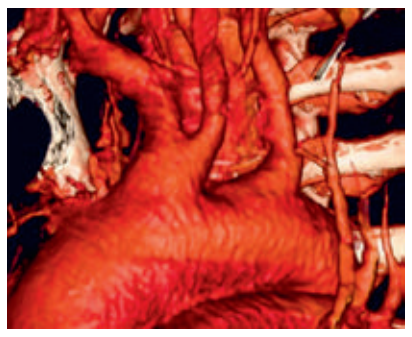
Variation in great arteries

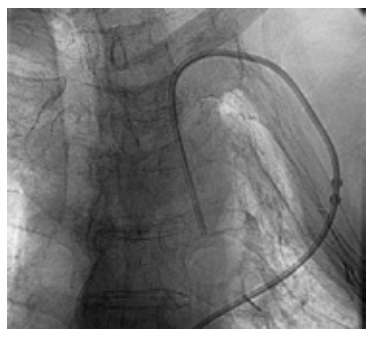
Variation in great veins

Varicella-zoster virus infection – chest wall

Abdomen and pelvis

5

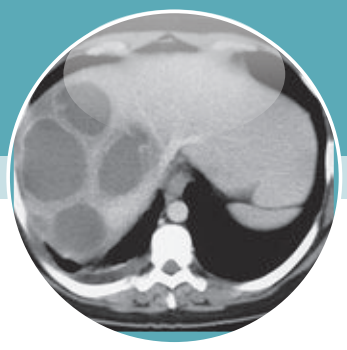

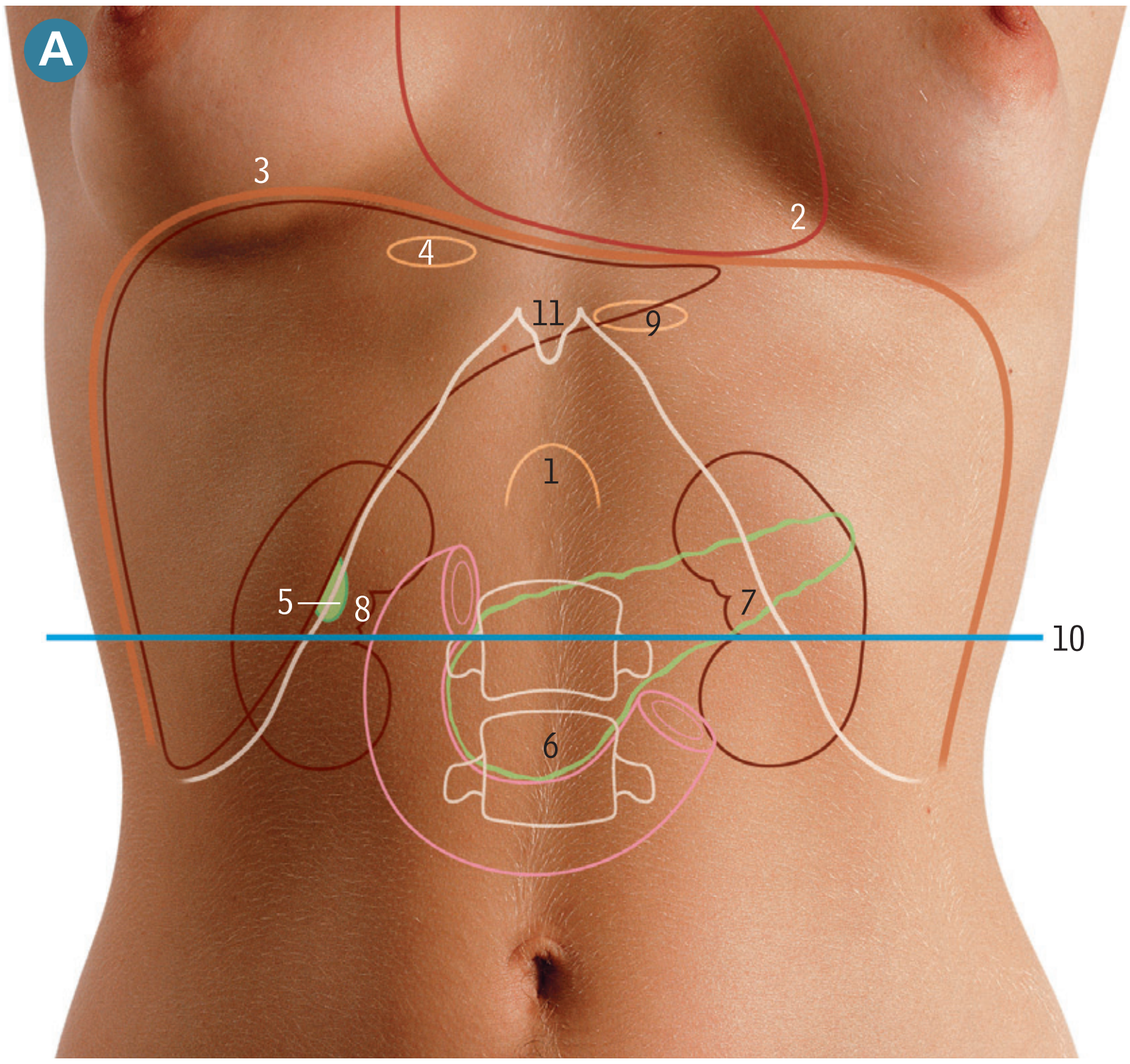

A Anterior abdominal wall *surface markings, above the umbilicus*

The solid white line indicates the costal margin. The blue line indicates the transpyloric plane. The C-shaped duodenum is outlined in pink, the kidneys and liver in brown and the pancreas in pale green.

1 Aortic opening in diaphragm
2 Apex of heart in fifth intercostal space
3 Dome of diaphragm and upper margin of liver
4 Foramen for inferior vena cava in diaphragm
5 Fundus of gall bladder, and junction of ninth costal cartilage and lateral border of rectus sheath
6 Head of pancreas and level of second lumbar vertebra
7 Hilum of left kidney
8 Hilum of right kidney
9 Oesophageal opening in diaphragm
10 Transpyloric plane
11 Xiphoid process

The transpyloric plane (10) lies midway between the jugular notch of the sternum and the upper border of the pubic symphysis, or approximately a hand's breadth below the xiphisternal joint (11), and level with the lower part of the body of the first lumbar vertebra.

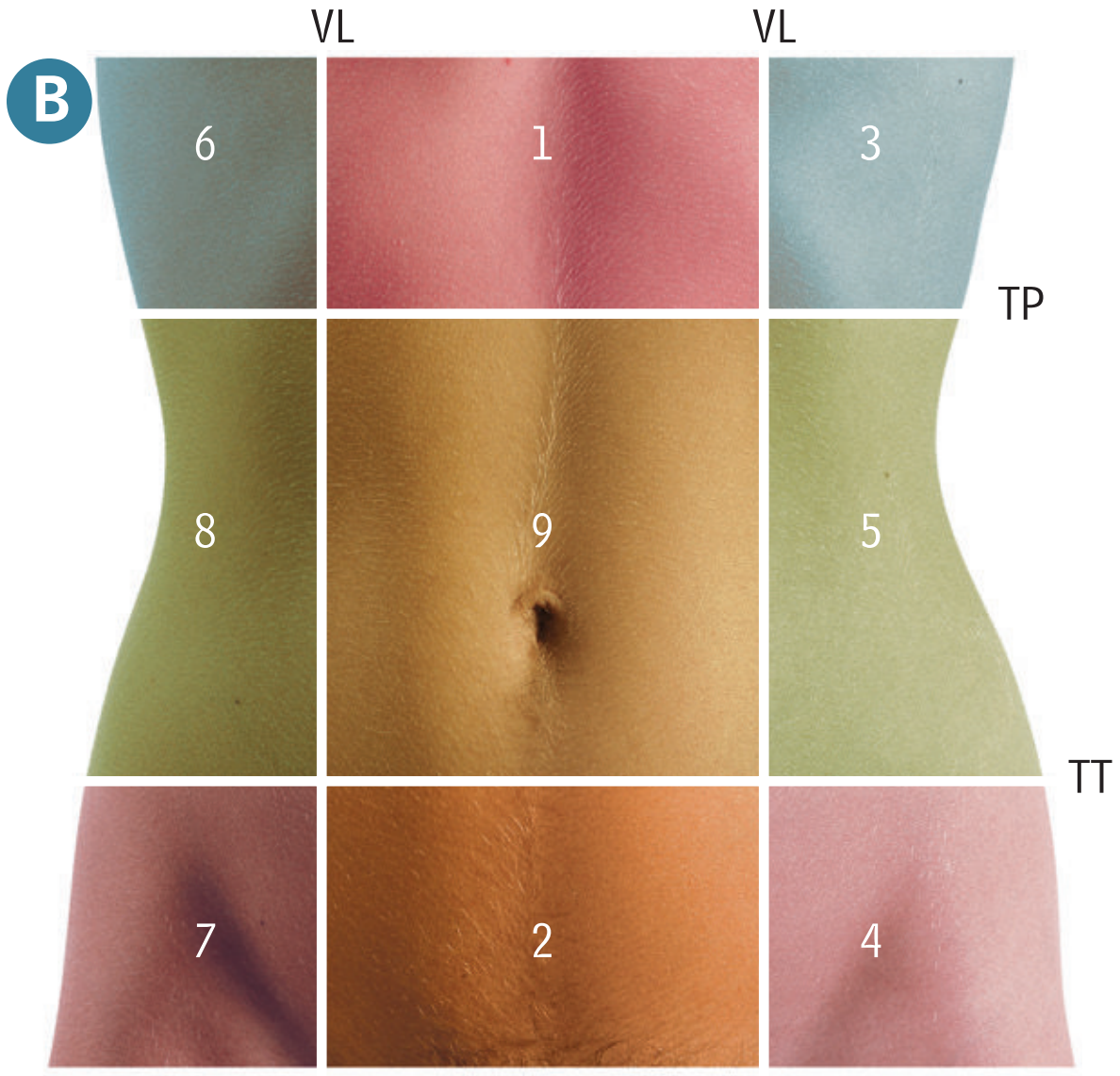

B Regions of the abdomen

The abdomen may be divided into regions by two vertical and two horizontal lines. The vertical lines (VL) pass through the midinguinal points: the upper horizontal line corresponds to the transpyloric plane (TP, A10), the lower line is drawn between the tubercles of the iliac crests (transtubercular [or supracristal] plane, TT).

1 Epigastric region
2 Hypogastrium or suprapubic region
3 Left hypochondrium
4 Left iliac region or iliac fossa
5 Left lumbar region
6 Right hypochondrium
7 Right iliac region or iliac fossa
8 Right lumbar region
9 Umbilical region

Varicella-zoster virus infection–abdominal wall, see pages 280–284.

A Anterior abdominal wall

1 Anterior cutaneous nerve (eighth intercostal)
2 Anterior cutaneous nerve (tenth intercostal)
3 Anterior layer internal oblique aponeurosis
4 External oblique aponeurosis
5 External oblique muscle
6 Ilioinguinal nerve
7 Iliotibial tract
8 Linea alba
9 Linea semilunaris
10 Mons pubis
11 Pectoralis major, abdominal part
12 Posterior layer internal oblique aponeurosis
13 Pyramidalis muscle
14 Rectus abdominis
15 Rectus sheath, anterior
16 Round ligament of uterus
17 Serratus anterior muscle
18 Superficial inguinal lymph node (horizontal group)
19 Superficial inguinal lymph node (vertical group)
20 Superficial inguinal ring
21 Superficial inguinal veins
22 Tendinous intersection of rectus abdominis
23 Umbilicus

The rectus sheath (A15) is formed by the internal oblique aponeurosis (A3), which splits at the lateral border of the rectus muscle (A9) into two layers. The posterior layer (A12) passes behind the muscle to blend with the aponeurosis of transversus abdominis (B19) to form the posterior wall of the sheath (B13), and the anterior layer (A3) passes in front of the muscle to blend with the external oblique aponeurosis (A4) as the anterior wall (A15).

The anterior and posterior walls of the sheath unite at the medial border of the rectus muscle to form the midline linea alba (A8, B11).

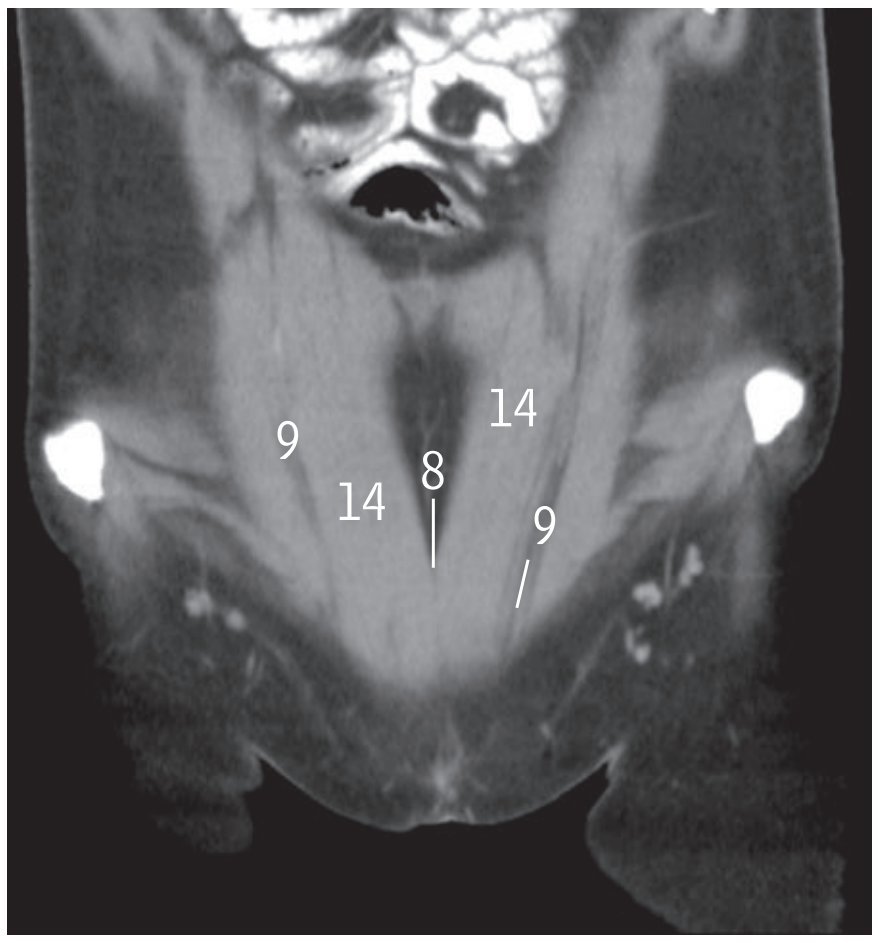

Coronal CT, anterior abdominal wall

Haematoma of the rectus sheath, Spigelian hernia, see pages 280–284.

B Rectus sheath

1 Anterior cutaneous nerve (tenth intercostal)
2 Anterior layer of internal oblique aponeurosis
3 Anterior wall of rectus sheath
4 Eighth rib
5 External oblique aponeurosis
6 External oblique muscle
7 Ilioinguinal nerve
8 Inferior epigastric vessels
9 Internal oblique aponeurosis
10 Internal oblique muscle
11 Linea alba
12 Mons pubis
13 Posterior wall of rectus sheath
14 Rectus abdominis
15 Rectus abdominis, reflected
16 Round ligament of uterus
17 Superficial inguinal lymph nodes
18 Tendinous intersection
19 Transversus abdominis
20 Umbilicus

Coronal CT

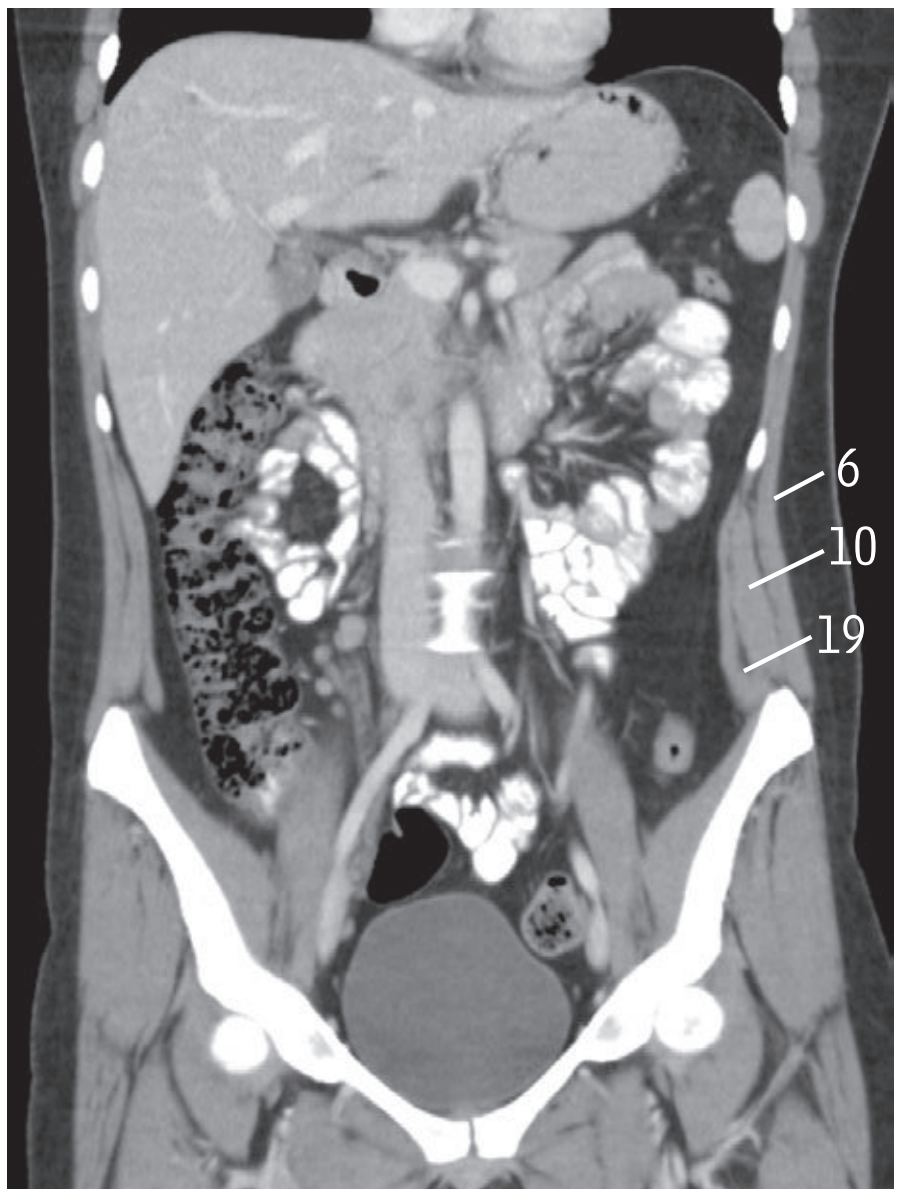

There is no posterior rectus sheath in the lower third of rectus abdominis, below the arcuate line (page 222, A1).

Cushing striations, see pages 280–284.

Groin in the male

1 Anterior cutaneous nerve (eleventh intercostal)
2 Anterior cutaneous nerve (twelfth intercostal)
3 Anterior rectus sheath (cut edge)
4 Ductus (vas) deferens
5 External oblique aponeurosis
6 Femoral artery
7 Femoral nerve
8 Femoral vein
9 Great saphenous vein
10 Hernial sac (indirect)
11 Iliacus muscle
12 Ilioinguinal nerve
13 Internal oblique muscle
14 Lateral circumflex femoral artery
15 Linea alba
16 Linea semilunaris
17 Lymphatic vessels
18 Rectus abdominis muscle
19 Sartorius muscle
20 Scrotal venous connections
21 Spermatic cord
22 Superficial inguinal lymph node
23 Suspensory ligament of penis
24 Umbilicus

The hernial sacs (10), shown here, are not trueherniae but extraperitoneal fat herniating through the superficial inguinal ring; often seen in the dissection room.

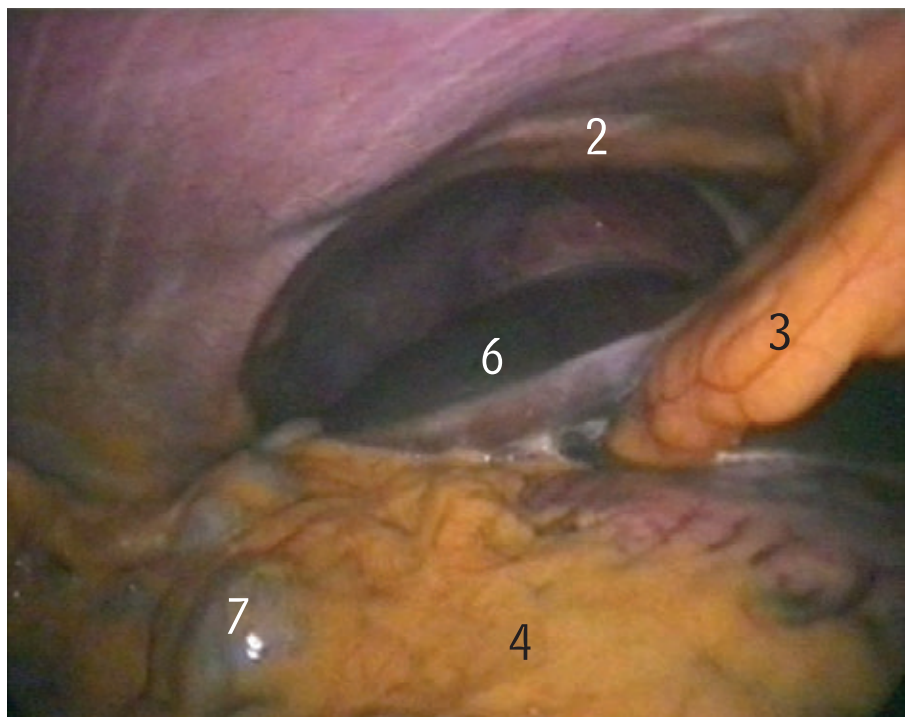

Laparoscopic view of upper abdominal cavity

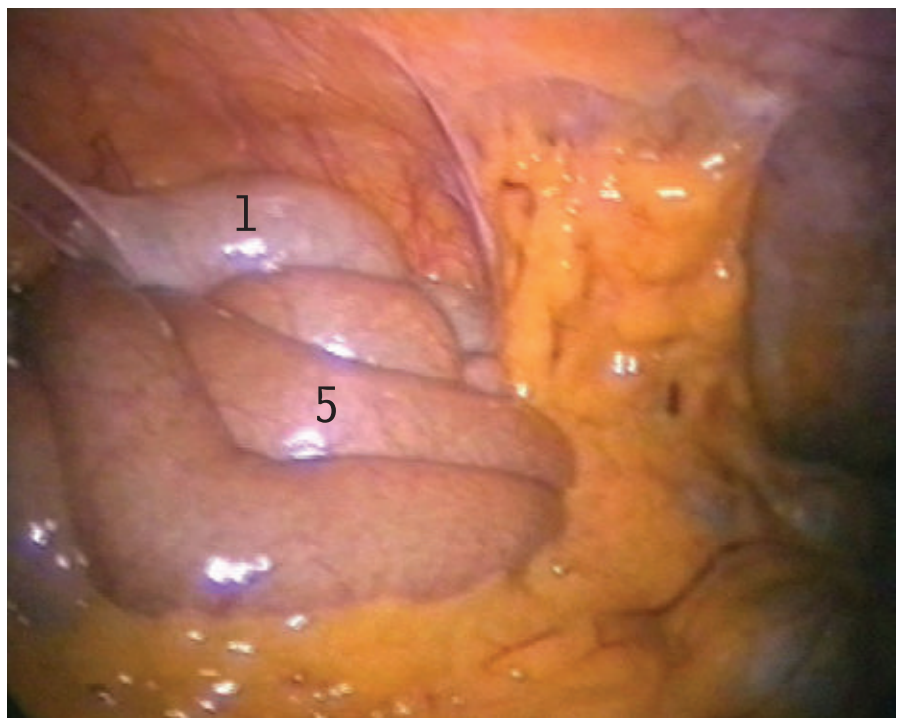

Laparoscopic view of lower abdominal cavity

1 Caecum
2 Diaphragm
3 Falciform ligament
4 Greater omentum
5 Ileum
6 Right lobe, liver
7 Transverse colon

Inguinal hernia repair, varicella-zoster virus infection–abdominal wall, see pages 280–284.

Adult anterior abdominal wall in the male *surface markings, right iliac fossa*

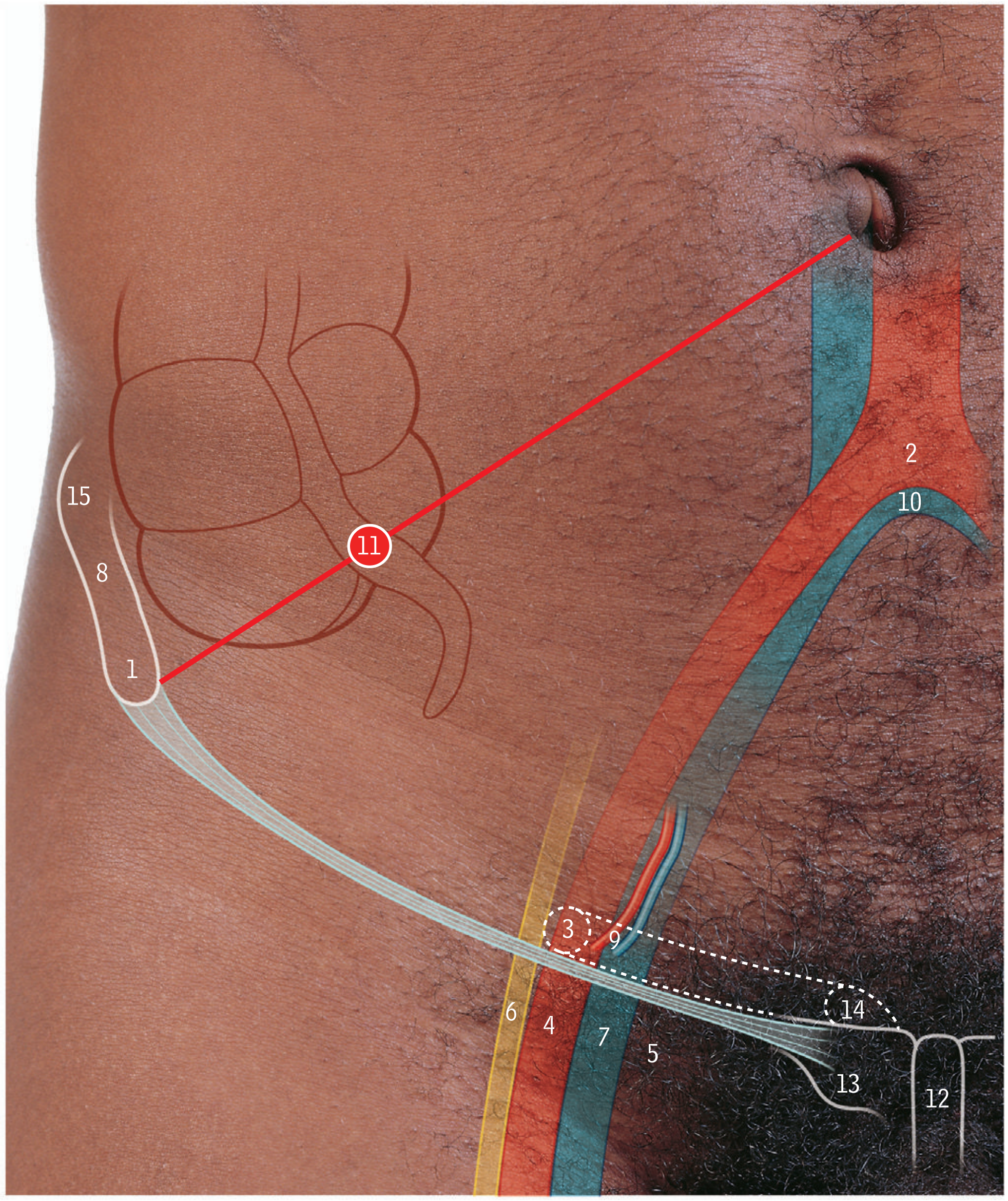

1 Anterior superior iliac spine
2 Bifurcation of aorta (fourth lumbar vertebra)
3 Deep inguinal ring
4 Femoral artery
5 Femoral canal
6 Femoral nerve
7 Femoral vein
8 Iliac crest
9 Inferior epigastric vessels
10 Lower end of inferior vena cava (fifth lumbar vertebra)
11 McBurney's point
12 Pubic symphysis
13 Pubic tubercle
14 Superficial inguinal ring
15 Tubercle of iliac crest

Cononal CT

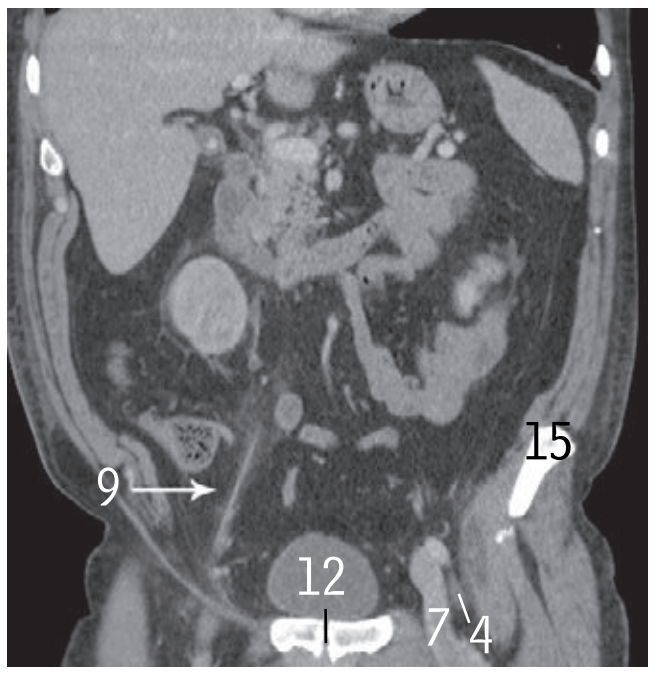

Sagittal CT

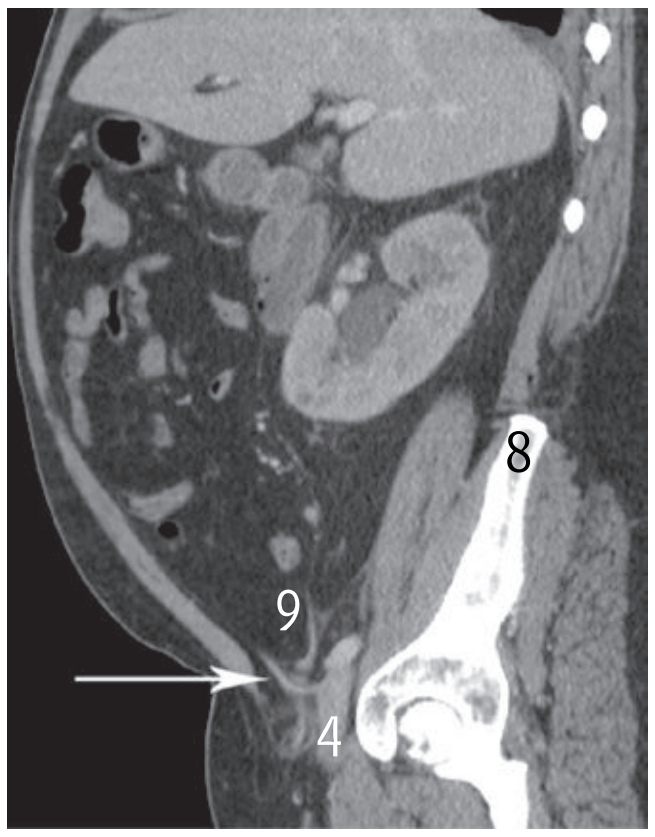

Arrows point to inferior epigastric artery

The caecum with the appendix opening into it from the left and the ascending colon continuing upwards from it are indicated by the brown line. The inguinal ligament, between the anterior superior iliac spine (1) and the pubic tubercle (13), is indicated by the light blue line. The femoral artery (4) has the femoral vein (7) on its medial side and the femoral nerve (6) on its lateral side. The femoral canal (5) is on the medial side of the vein. The deep inguinal ring (3) and inferior epigastric vessels (9) are above the femoral artery, while the superficial inguinal ring (14) is above and lateral to the pubic tubercle (13). McBurney's point (11) is a site on the surface of the anterior abdominal wall indicating the usual location of the base of the appendix internally. It lies one-third of the way along a line from the right anterior superior iliac spine to the umbilicus (red line).

The femoral artery (4, whose pulsation should normally be palpable) enters the thigh midway between the pubic symphysis (12) and the anterior superior iliac spine (1). This is often referred to as the midinguinal point.

Femoral hernia, McBurney's point, see pages 280–284.

A Adult anterior abdominal wall *umbilical folds, from behind*

This view of the peritoneal surface of the central region of the anterior abdominal wall shows the peritoneal folds raised by underlying structures. There is one fold above the umbilicus – the falciform ligament – and there are five below it: the median umbilical fold (7) in the midline, and a pair of medial and lateral umbilical folds on each side (6 and 4).

1 Arcuate line
2 Falciform ligament
3 Inguinal triangle (Hesselbach)
4 Lateral umbilical fold which contains the inferior epigastric vessels
5 Linea semilunaris
6 Medial umbilical fold
7 Median umbilical fold
8 Umbilicus

The inguinal triangle of Hesselbach is a naturally weak region between rectus abdominis and the inferior epigastric vessels. Direct inguinal hernias appear through this region.

B Fetal anterior abdominal wall *from behind*

1 Deep inguinal ring
2 Diaphragm
3 External oblique muscle
4 Falciform ligament
5 Inferior epigastric vessels
6 Internal oblique muscle
7 Left umbilical vein
8 Rectus abdominis muscle
9 Rectus sheath (posterior layer)
10 Testis (undescended)
11 Transversus abdominis muscle
12 Urachus
13 Umbilical arteries
14 Urinary bladder

Caput medusae, postnatal umbilical vein catheter, omphalocele, umbilical and paraumbilical hernia, see pages 280–284.

A Right deep inguinal ring in adult male
laparoscopic view

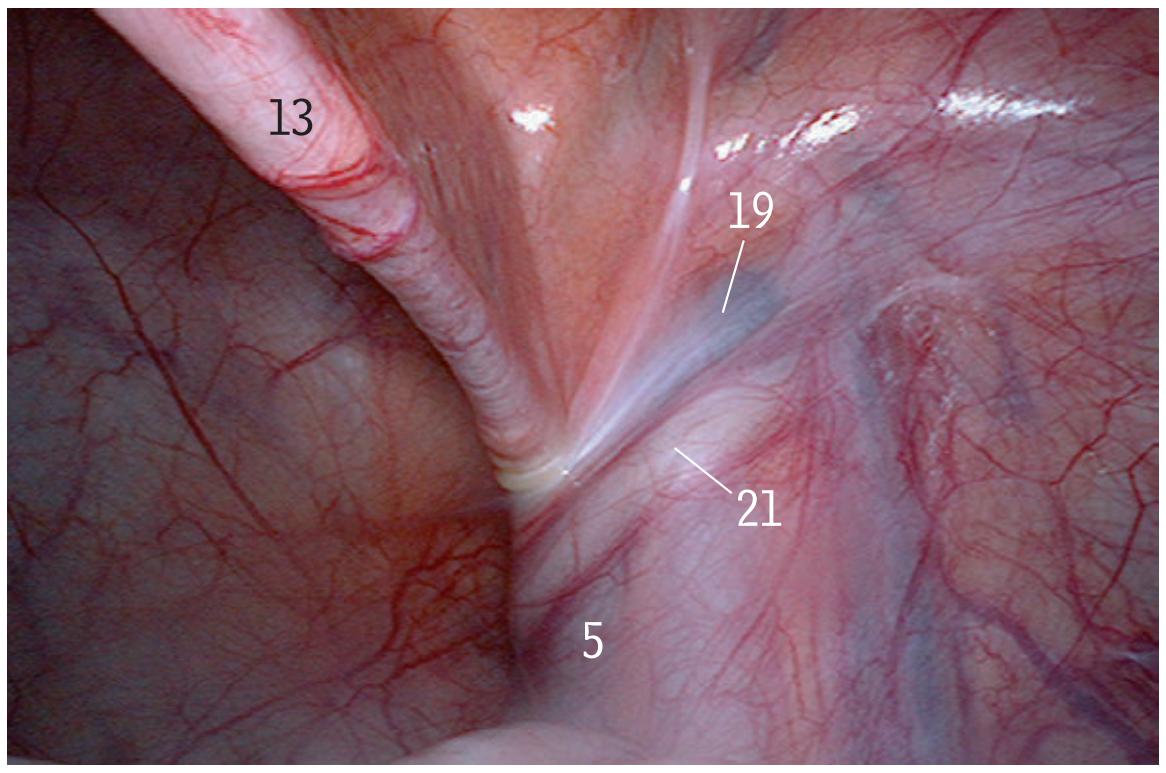

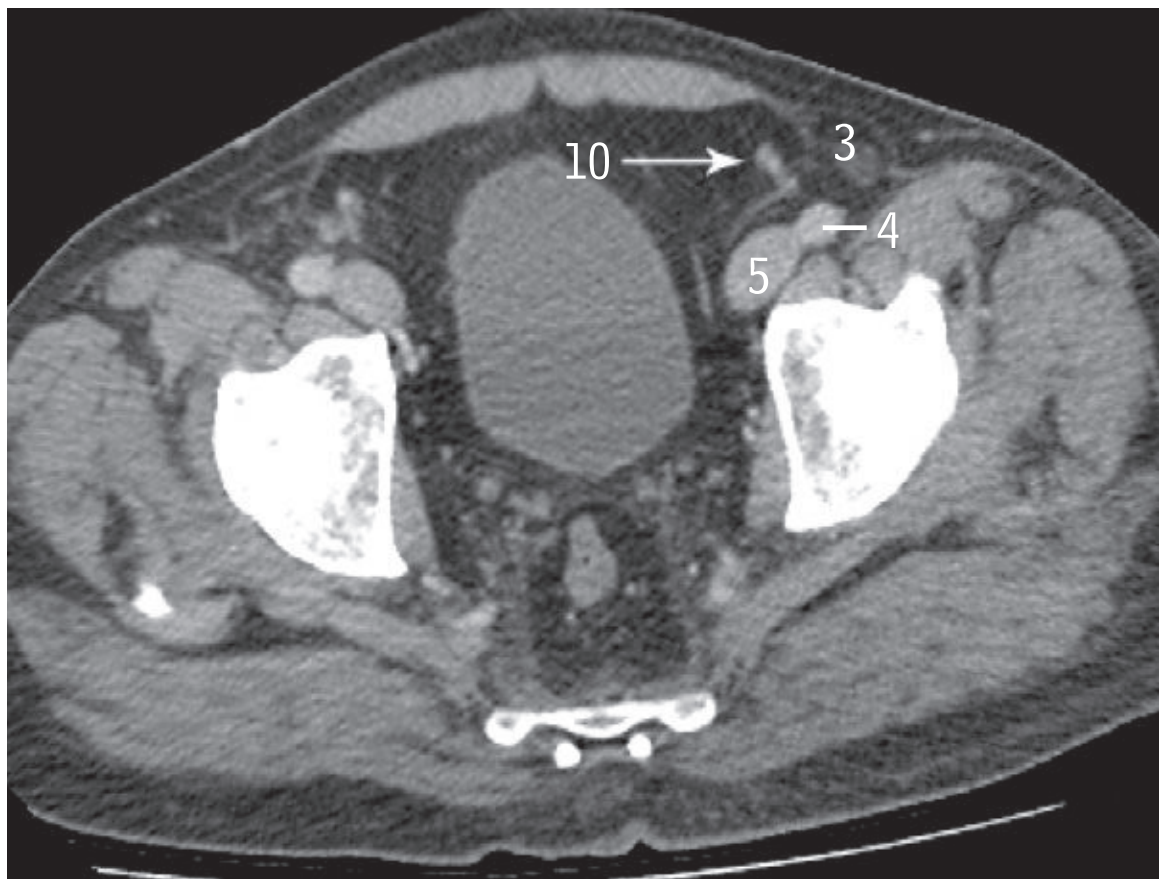

Axial CT, pelvis

B Anterior abdominal wall
abdominal view

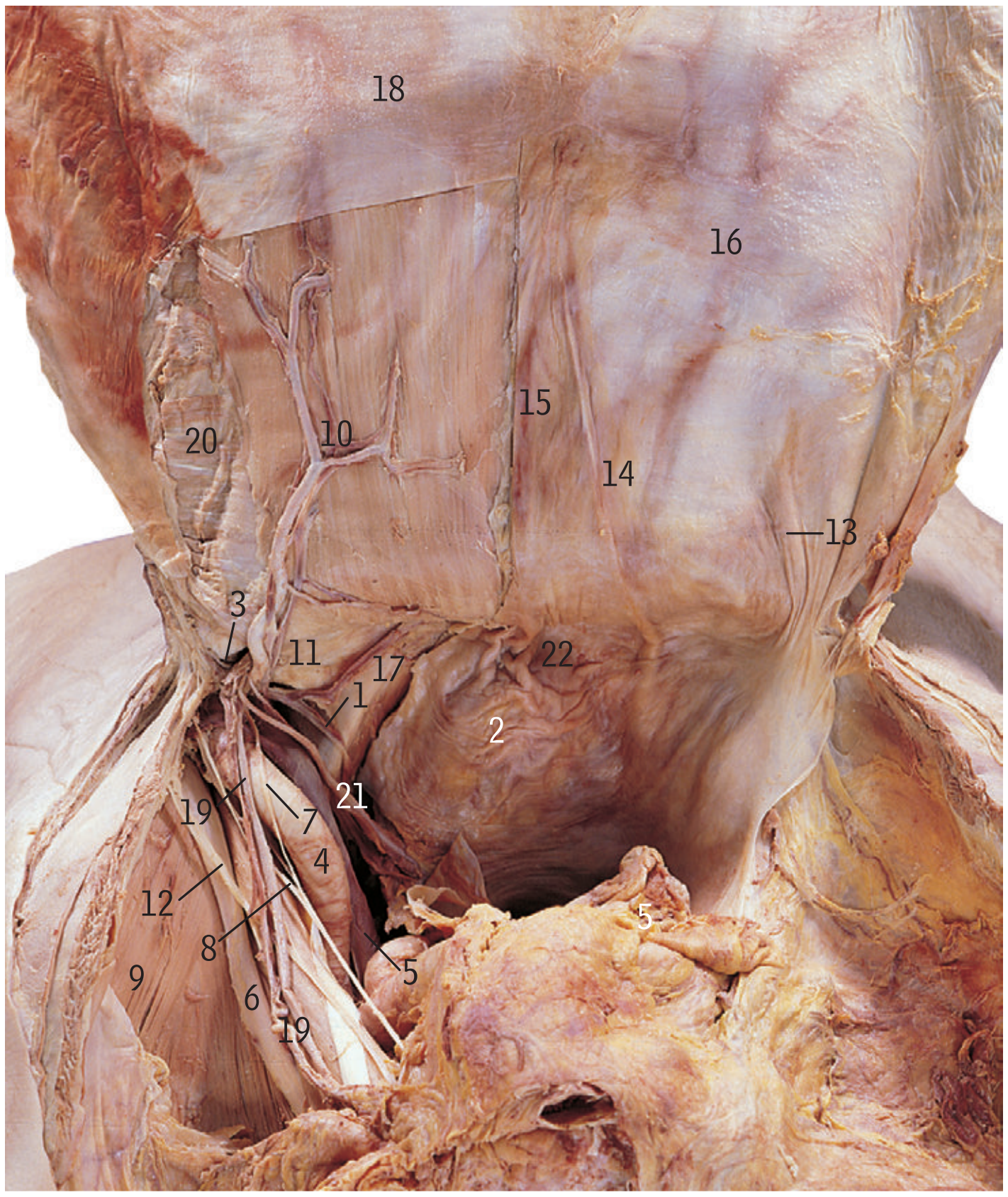

Abdominal viscera have been removed and the anterior abdominal wall detached laterally and reflected anteriorly and inferiorly to reveal the internal surface of the abdominal wall. The parietal peritoneum has been removed from the left side to show deeper structures in the pelvic and abdominal walls.

1 Accessory obturator artery
2 Bladder
3 Deep inguinal ring
4 External iliac artery
5 External iliac vein
6 Femoral nerve
7 Genitofemoral nerve, femoral branch
8 Genitofemoral nerve, genital branch
9 Iliacus
10 Inferior epigastric vessels
11 Inguinal triangle (Hesselbach)
12 Lateral cutaneous nerve of the thigh
13 Lateral umbilical fold (inferior epigastric vessels)
14 Medial umbilical fold (umbilical artery)
15 Median umbilical fold (urachus)
16 Parietal peritoneum
17 Pelvic brim
18 Posterior surface, rectus sheath
19 Testicular vessels
20 Transversus abdominis
21 Vas/ductus deferens
22 Visceral peritoneum, over bladder

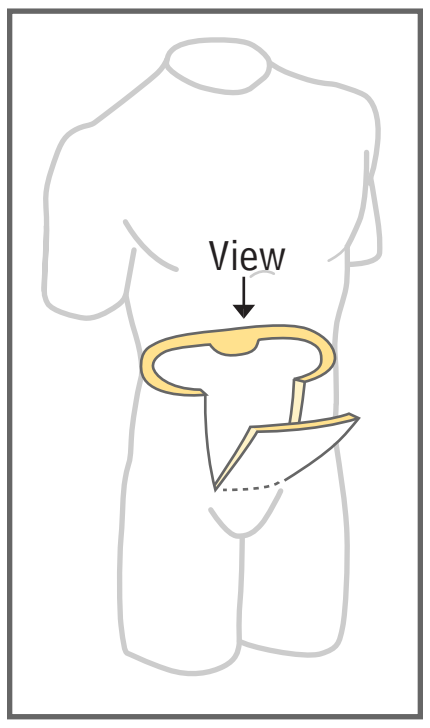

Inguinal hernia, indirect inguinal hernia, see pages 280–284.

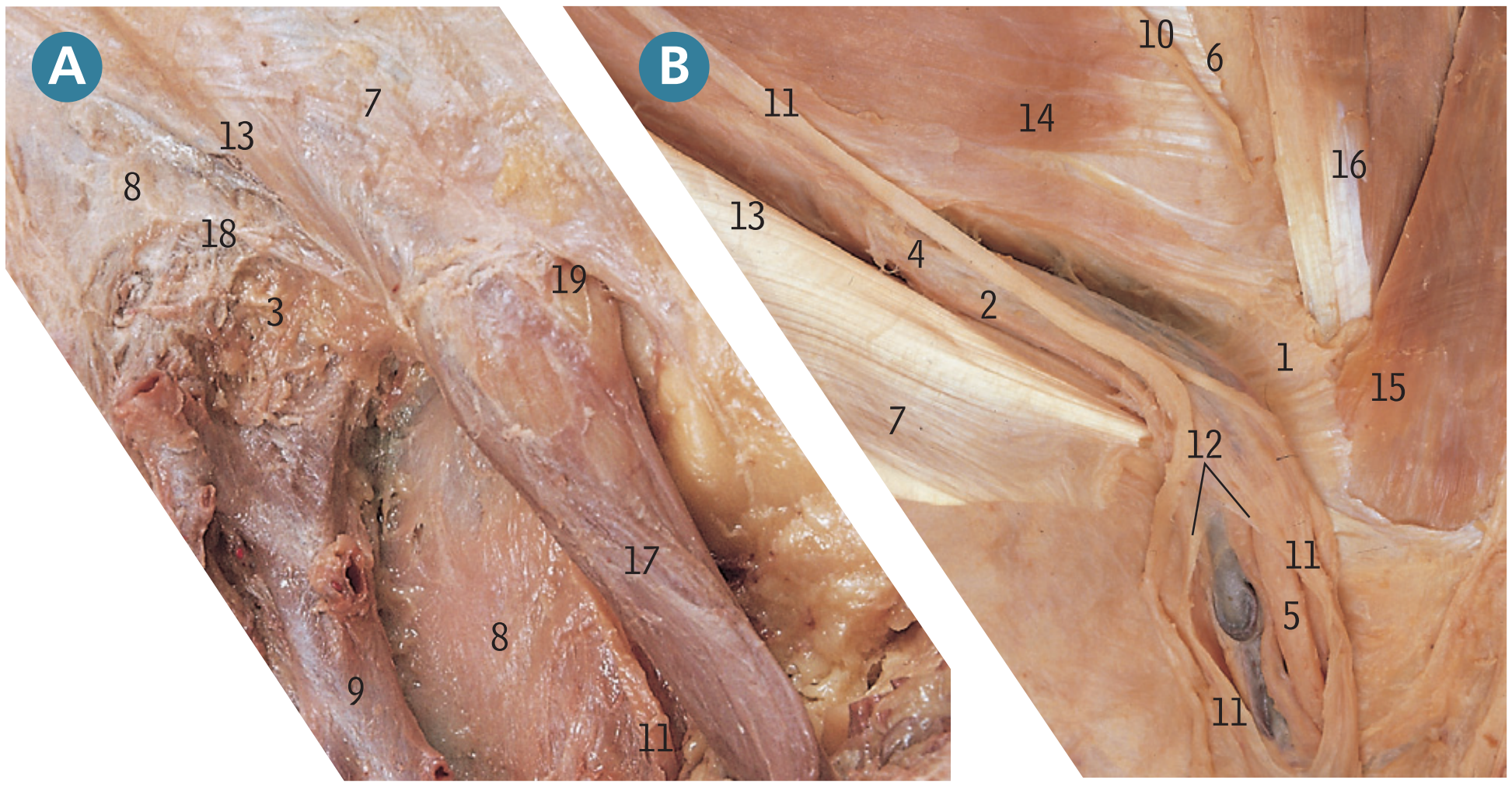

Right inguinal region *in the male*

A **superficial dissection**

B **with the external oblique aponeurosis and spermatic cord incised**

In A, the spermatic cord (17) is seen emerging from the superficial inguinal ring (19) and covered by the external spermatic fascia. In B, with the external oblique aponeurosis reflected and the anterior wall of the rectus sheath removed, the cord is emerging from the deep inguinal ring (4) with the cremasteric fascia (2) now the most superficial covering. All three coverings of the cord have been incised (12) to show the ductus/vas deferens (5).

1 Conjoint tendon
2 Cremasteric fascia and cremaster muscle over spermatic cord
3 Cribriform fascia
4 Deep inguinal ring
5 Ductus/vas deferens
6 Edge of rectus sheath
7 External oblique aponeurosis
8 Fascia lata
9 Great saphenous vein
10 Iliohypogastric nerve
11 Ilio-inguinal nerve
12 Incised margin of coverings of cord
13 Inguinal ligament
14 Internal oblique
15 Pyramidalis
16 Rectus abdominis
17 Spermatic cord
18 Upper margin of saphenous opening
19 Upper margin of superficial inguinal ring

Right inguinal region *in the female*

The external oblique aponeurosis (2) has been incised and reflected to show the position of the deep inguinal ring (7) which marks the lateral end of the inguinal canal. The round ligament of the uterus (9) emerges from the superficial inguinal ring (8), which marks the medial end of the canal, and becomes lost in the fat of the labium majus (3). The ilio-inguinal nerve (5) also passes through the canal and out of the superficial ring.

1 Conjoint tendon
2 External oblique aponeurosis
3 Fat of labium majus
4 Great saphenous vein
5 Ilio-inguinal nerve
6 Internal oblique
7 Position of deep inguinal ring
8 Position of superficial inguinal ring
9 Round ligament of uterus
10 Upper surface of inguinal ligament

In the female, the inguinal canal contains the round ligament of the uterus and the ilio-inguinal nerve.

The processus vaginalis is normally obliterated, but if it remains patent within the female inguinal canal, it is sometimes known as the canal of Nuck.

A Right deep inguinal ring and inguinal triangle *internal view*

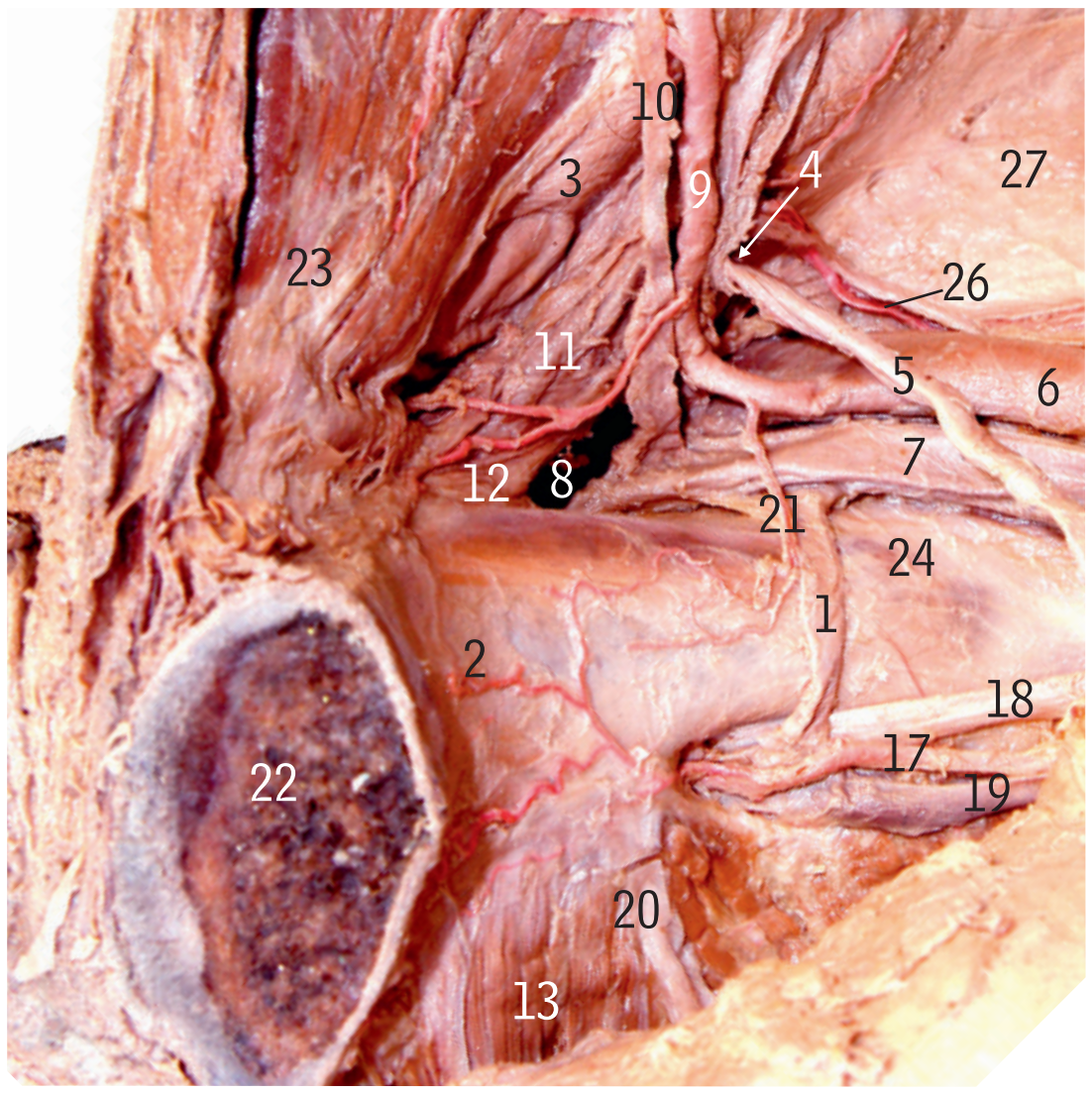

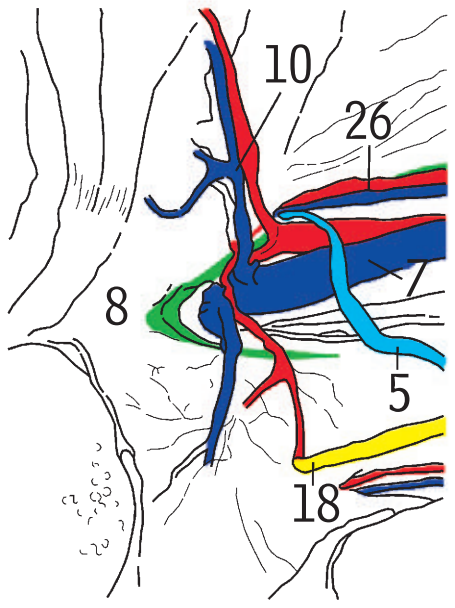

This is the view looking into the right half of the pelvis from the left, showing the posterior surface of the lower part of the anterior abdominal wall, above the pubic symphysis. The femoral ring (8), the entrance to the femoral canal, is below the medial end of the inguinal ligament (11). The inferior epigastric vessels (9, 10) lie medial to the deep inguinal ring (4).

The inguinal triangle (Hesselbach's triangle) is the area bounded laterally by the inferior epigastric vessels, medially by the lateral border of rectus abdominis and below by the inguinal ligament. A direct inguinal hernia passes forwards through this triangle, medial to the inferior epigastric vessels.

An indirect inguinal hernia passes through the deep inguinal ring lateral to the inferior epigastric vessels.

B Left deep inguinal ring in the male

internal peritoneal (view as seen at laparoscopy)

1 Abberant obturator vein
2 Body of pubis
3 Conjoint tendon
4 Deep inguinal ring
5 Ductus/vas deferens
6 External iliac artery
7 External iliac vein
8 Femoral ring
9 Inferior epigastric artery
10 Inferior epigastric vein
11 Inguinal ligament
12 Lacunar ligament
13 Levator ani muscle
14 Medial umbilical fold
15 Medial umbilical ligament
16 Median umbilical ligament
17 Obturator artery
18 Obturator nerve
19 Obturator vein
20 Origin of levator ani from fascia overlying obturator internus muscle
21 Pubic branches of the inferior epigastric vessels
22 Pubic ramus (transected)
23 Rectus abdominis muscle
24 Superior pubic ramus
25 Superior surface of bladder
26 Testicular vessels
27 Transversalis fascia overlying transversus abdominis muscle

Abdominal peritoneal folds *after removal of intra-abdominal organs, to show relations of ligaments and mesenteries*

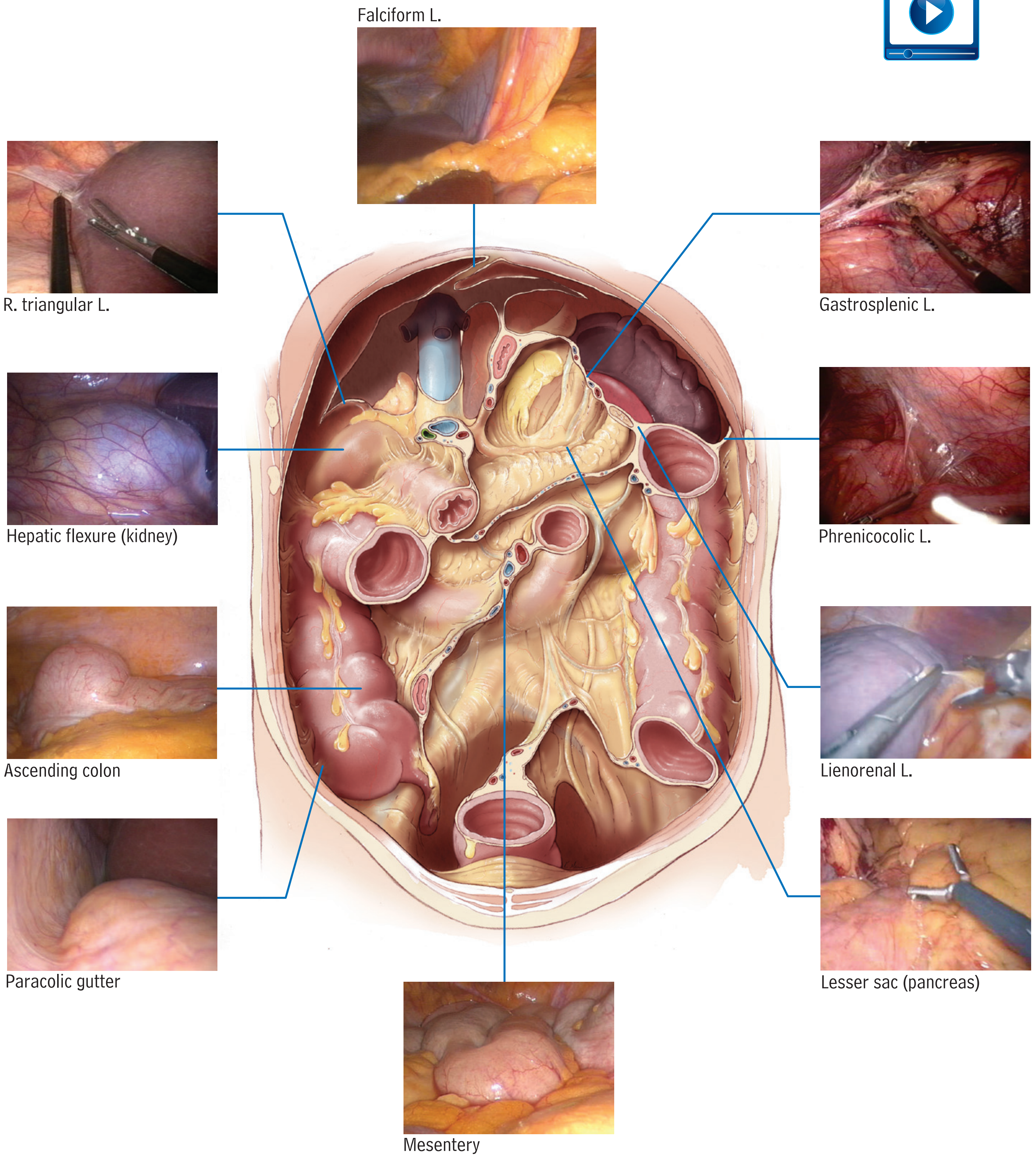

Drainage of subphrenic abscesses, peritoneal lavage, peritonitis, see pages 280–284.

Abdominal viscera *from the front*

1 Appendices epiploicae
2 Ascending colon
3 Descending colon
4 Falciform ligament
5 Greater omentum
6 Ligamentum teres hepatis (round ligament)
7 Liver
8 Parietal peritoneum on anterior abdominal wall
9 Rectus abdominis muscle, reflected laterally
10 Small intestine
11 Transverse colon

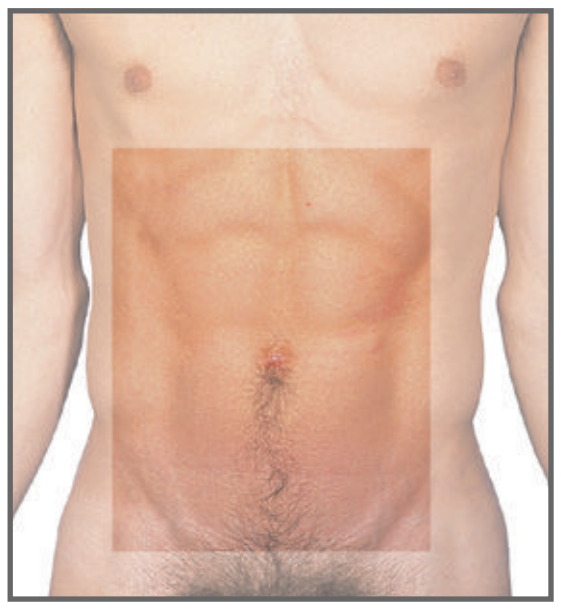

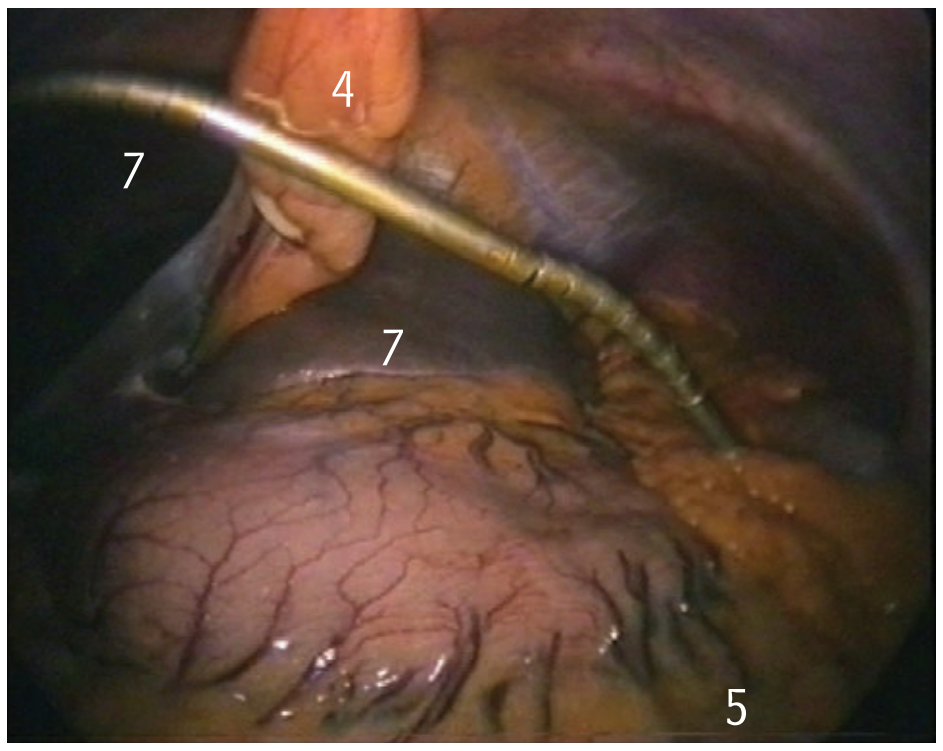

Laparoscopic view of upper abdominal viscera

For an explanation of peritoneal structures, see the diagrams on pages 226, 233.

Liver biopsy, situs inversus totalis, see pages 280–284.

Abdominal viscera *from the front*

1 Appendices epiploicae
2 Ascending colon
3 Descending colon
4 Greater omentum
5 Ligamentum teres hepatis in falciform ligament
6 Liver, left lobe
7 Rectus abdominis muscle, reflected laterally
8 Small intestine
9 Stomach
10 Stomach, greater curvature
11 Transverse colon

Cholecystectomy, see pages 280–284.

Abdominal viscera *from the front*

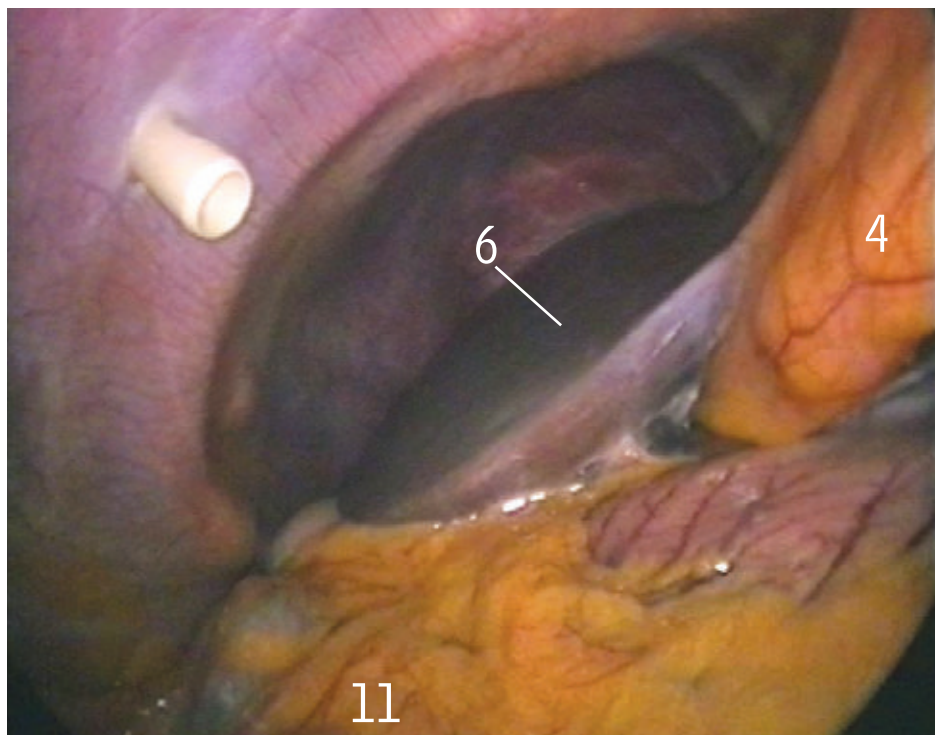

Laparoscopic view of abdominal viscera

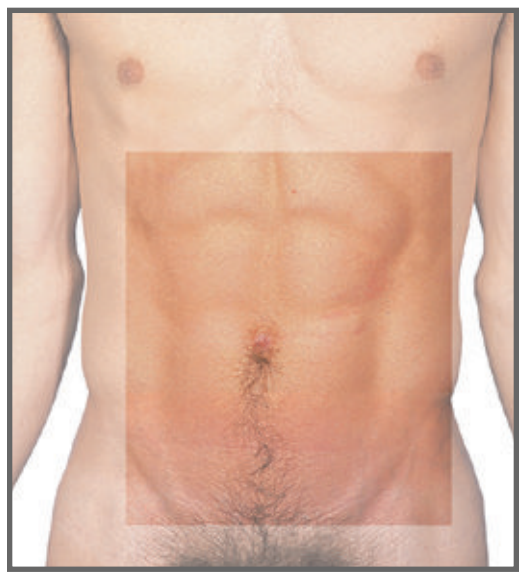

1. Appendices epiploicae
2. Ascending colon
3. Descending colon
4. Falciform ligament
5. Ligamentum teres hepatis
6. Liver, right lobe
7. Posterior surface of greater omentum
8. Rectus abdominis muscle, reflected laterally
9. Small intestine (ileum)
10. Small intestine (jejunum)
11. Transverse colon

The appendices epiploicae (1) are fat-filled appendages of peritoneum on the various parts of the colon (ascending, transverse, descending and sigmoid). They are not present on the small intestine or the rectum, and may be rudimentary on the caecum and appendix. In abdominal operations, they are one feature that helps to distinguish colon from other parts of the intestine.

Omental cake, see pages 280–284.

Lesser omentum and epiploic foramen

A *from the front* B *from the front and the right*

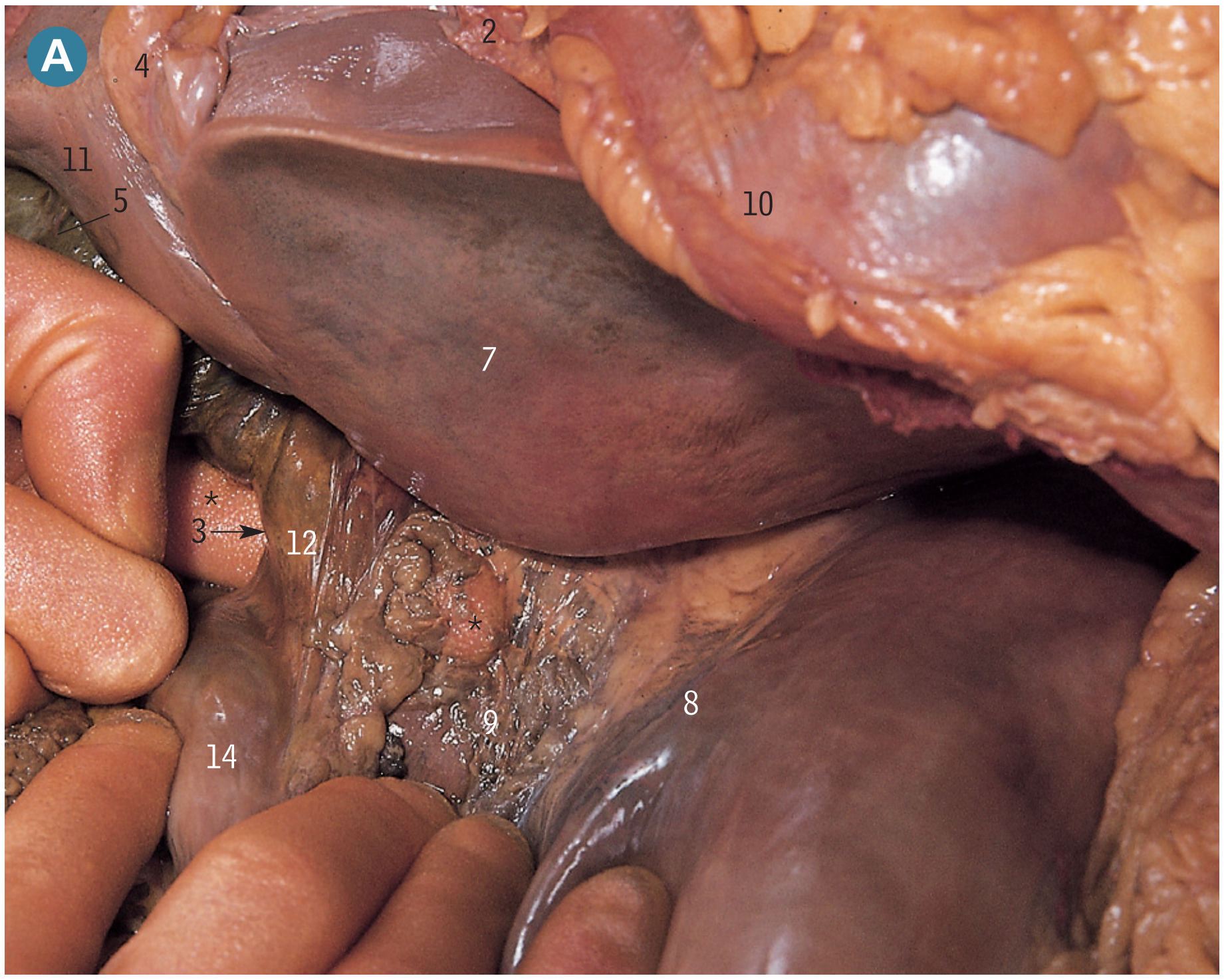

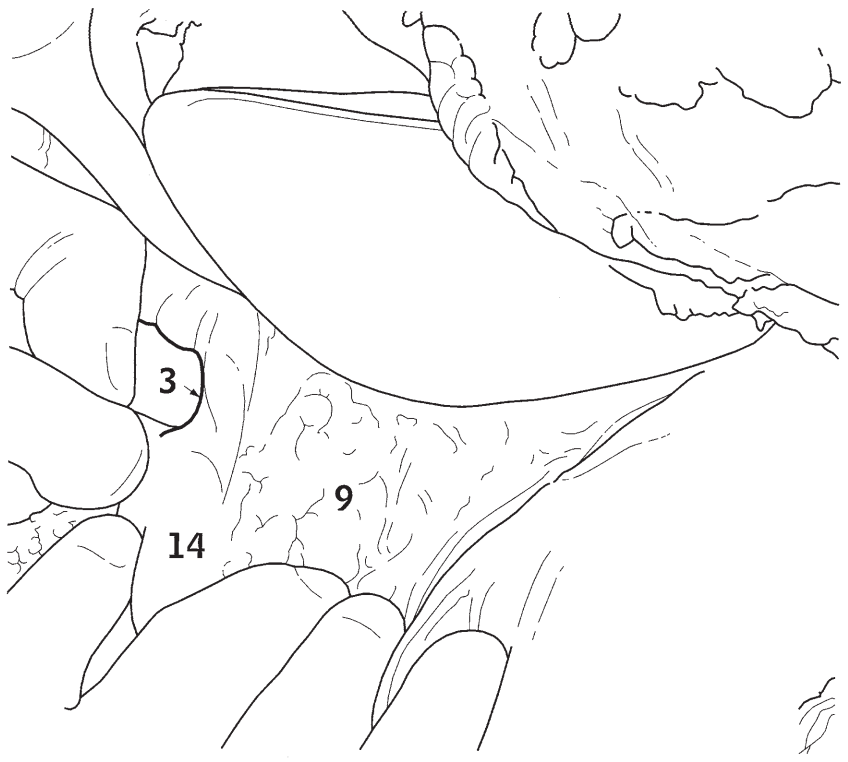

1 Descending (second) part of duodenum
2 Diaphragm
3 Epiploic foramen* (winslow)
4 Falciform ligament
5 Gall bladder
6 Inferior vena cava
7 Left lobe of liver
8 Lesser curvature of stomach
9 Lesser omentum
10 Pericardium
11 Quadrate lobe of liver
12 Right free margin of lesser omentum
13 Right lobe of liver
14 Superior (first) part of duodenum
15 Upper pole of right kidney

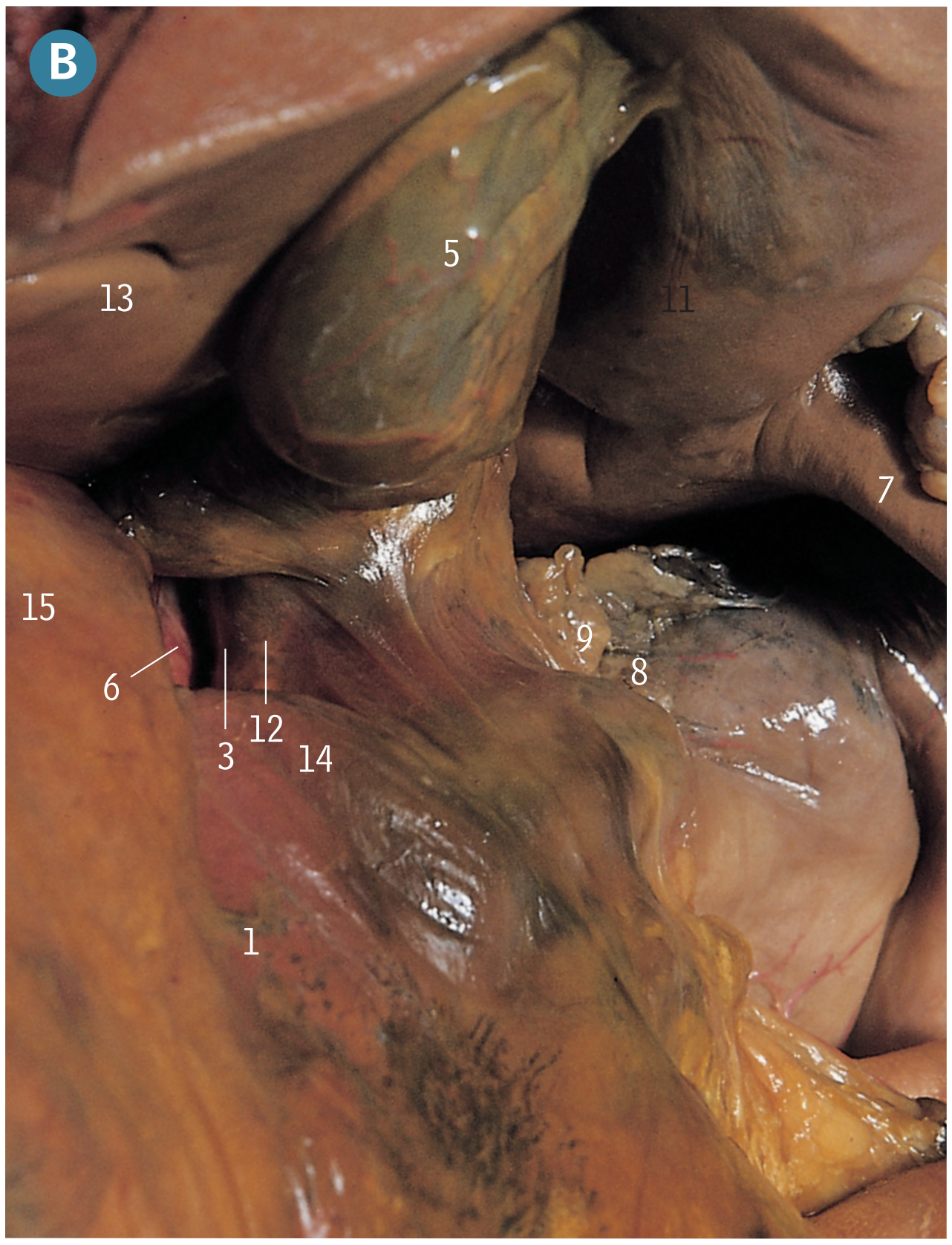

In A, a finger* has been placed in the epiploic foramen (3) behind the right free margin of the lesser omentum (12), and the tip can be seen in the lesser sac, through the transparent lesser omentum (9) which stretches between the liver (7) and the lesser curvature of the stomach (8). In the more lateral view in B, looking into the foramen from the right, the foramen (3) is identified between the right free margin of the lesser omentum (12) in front and the inferior vena cava (6) behind, above the first part of the duodenum (14).

The epiploic foramen (of Winslow, A3 and B3) is the communication between the general peritoneal cavity (sometimes called the greater sac) and the lesser sac (omental bursa), a space lined by peritoneum behind the stomach (A8 and B8) and lesser omentum (A9 and A12) and in front of parts of the pancreas and left kidney.

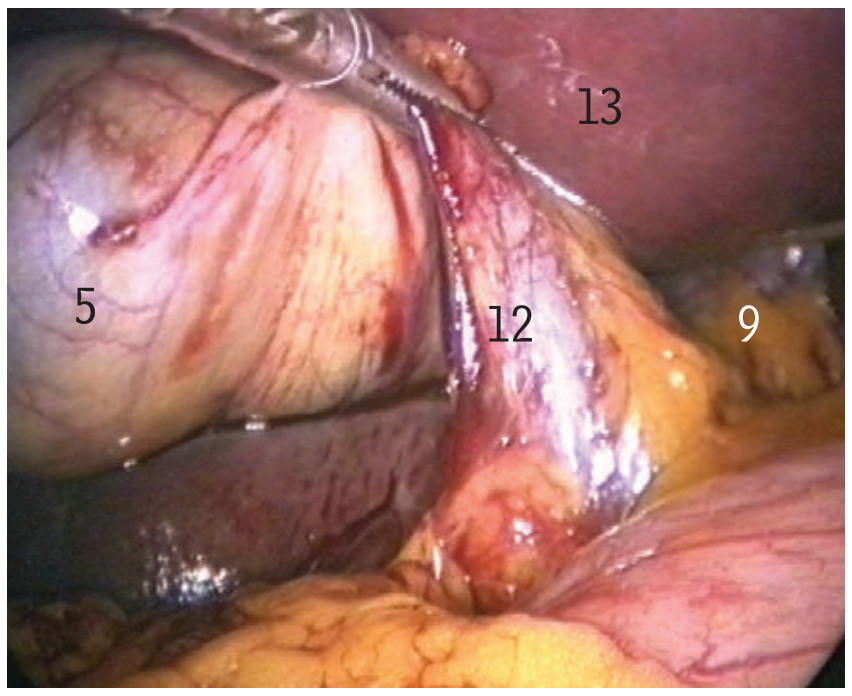

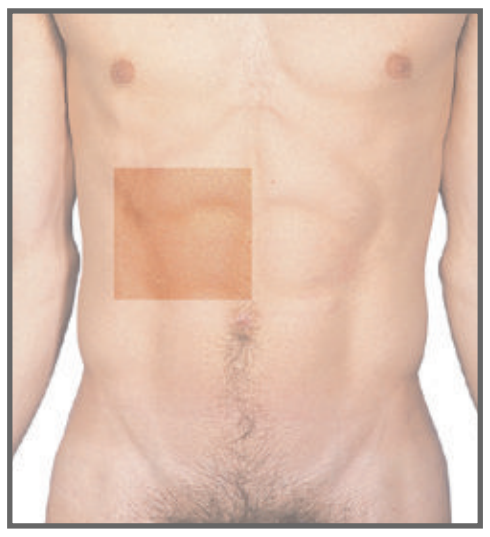

Laparoscopic view of lesser omentum (free margin)

A Upper abdominal viscera *from the front*

In this view the stomach, transverse colon (9) and greater omentum (5) have been lifted up to show the region of the duodenojejunal flexure (3).

1 Ascending colon
2 Coils of the small intestine
3 Duodenojejunal flexure
4 Duodenum, first part
5 Greater omentum
6 Jejenum
7 Mesentery
8 Parietal peritoneum on anterior abdominal wall, reflected superiorly
9 Transverse colon, reflected superiorly
10 Transverse mesocolon

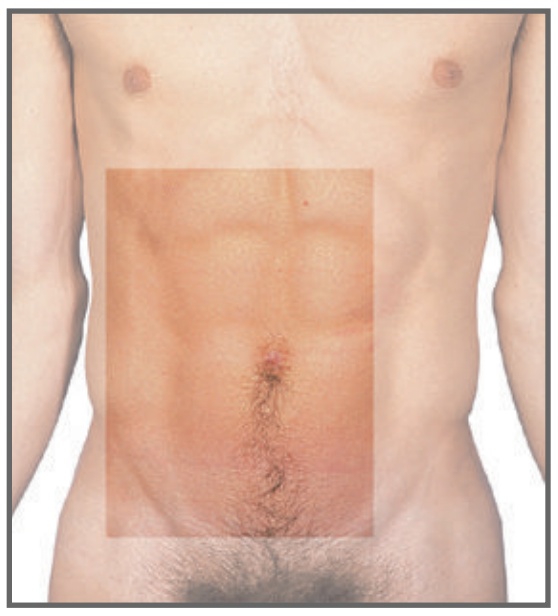

B Lesser sac in upper abdomen

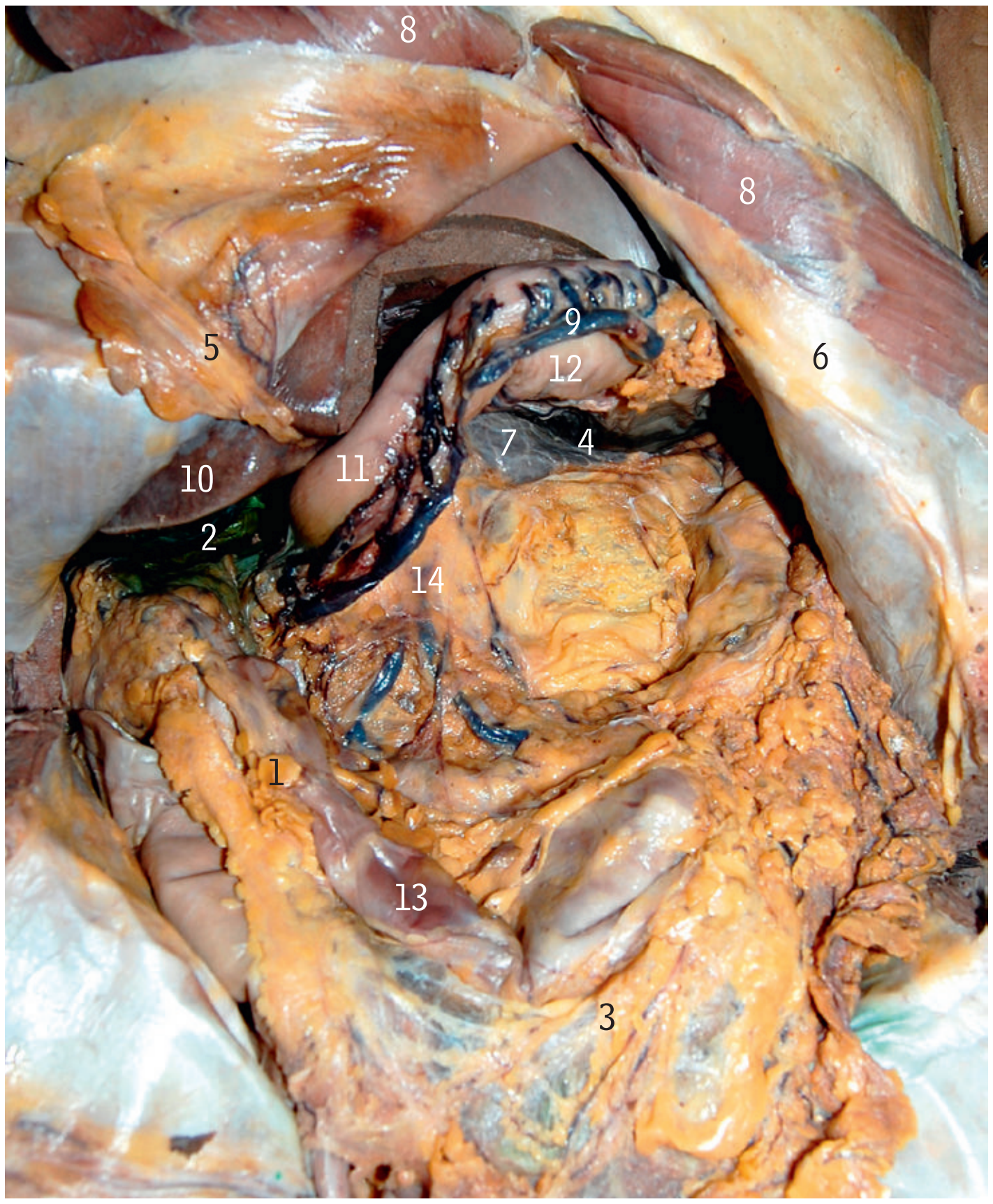

1 Appendices epiploicae
2 Gall bladder
3 Greater omentum, reflected inferiorly
4 Lesser sac (omental bursa)
5 Ligamentum teres hepatis in falciform ligament
6 Parietal peritoneum on anterior abdominal wall
7 Peritoneum of lesser sac overlying pancreas
8 Rectus abdominis muscle, reflected
9 Right and left gastro-epiploic veins
10 Right lobe of the liver
11 Stomach, greater curvature
12 Stomach, posterior surface
13 Transverse colon, reflected inferiorly
14 Transverse mesocolon

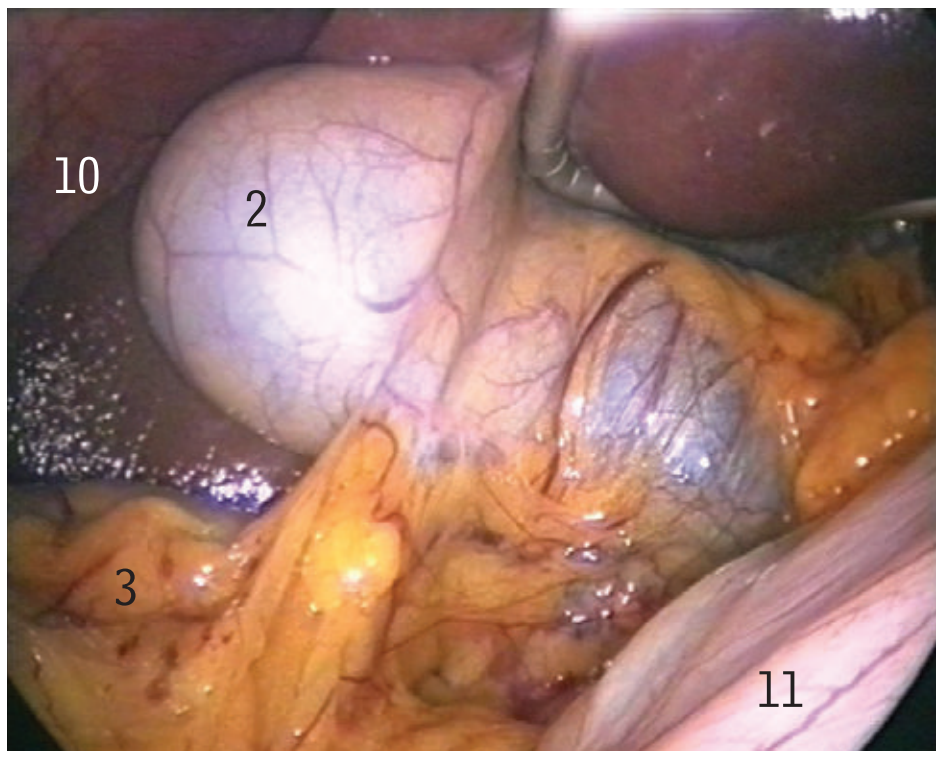

Laparoscopic view of gall bladder

Ascites, laparoscopy, see pages 280–284.

Mesentery and colon *from the front*

1 Appendices epiploicae
2 Appendix
3 Ascending colon
4 Caecum
5 Coils of small intestine
6 Distal ileum
7 Duodenojejunal junction
8 Greater omentum
9 Ileocaecal junction
10 Liver
11 Mesentery of small intestine
12 Mesoappendix
13 Parietal peritoneum on anterior abdominal wall
14 Proximal jejunum
15 Rectus abdominis muscle, reflected
16 Transverse colon

Diverticular disease, volvulus, see pages 280–284.

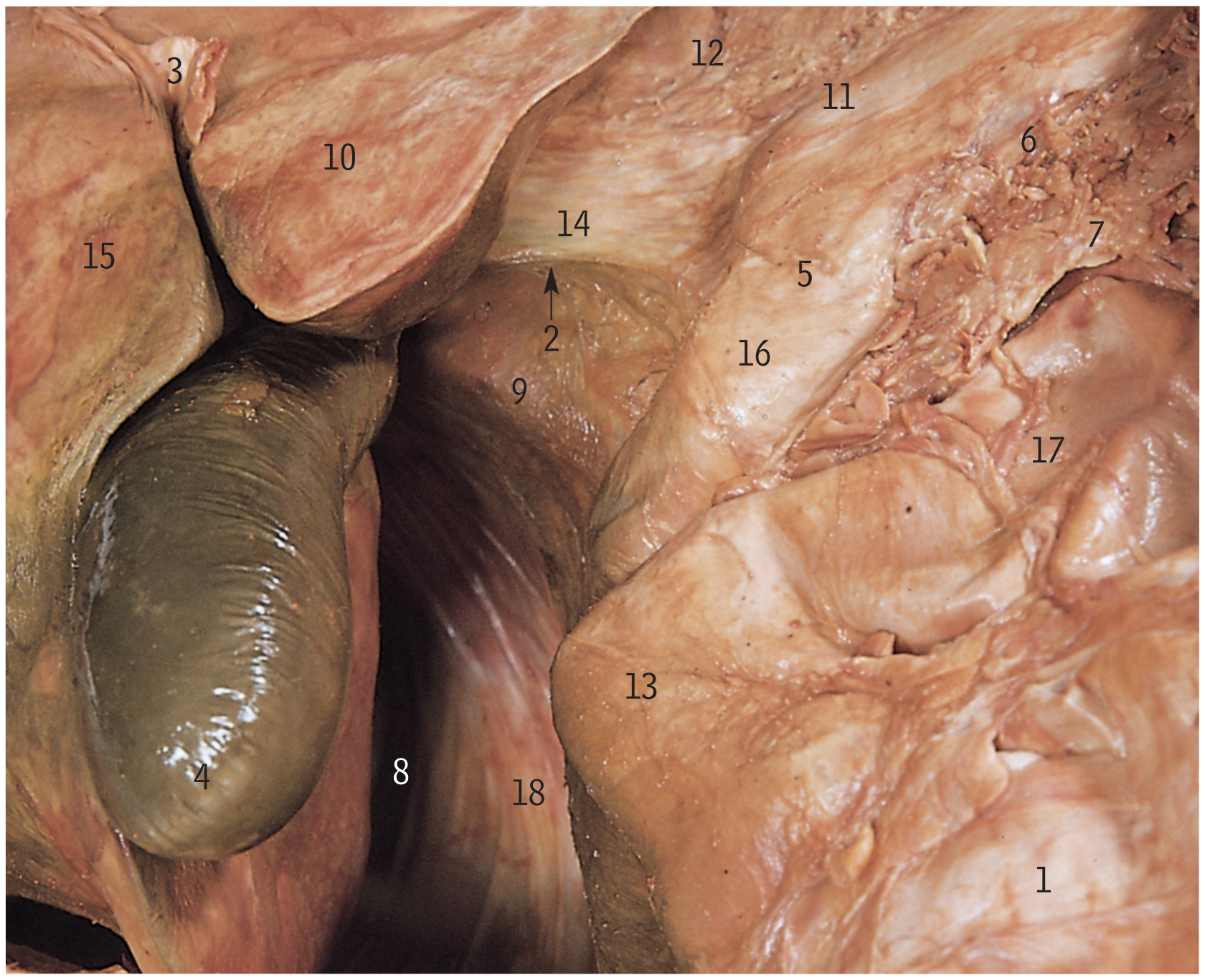

A Hepatorenal pouch of peritoneum *from the right and below*

With the body lying on its back and seen from the right, the liver (15) has been turned upwards (towards the left) to open up the gap between the liver and upper pole of the right kidney (18) – the hepatorenal pouch of peritoneum (8, Morison's pouch or the right subhepatic compartment of the peritoneal cavity).

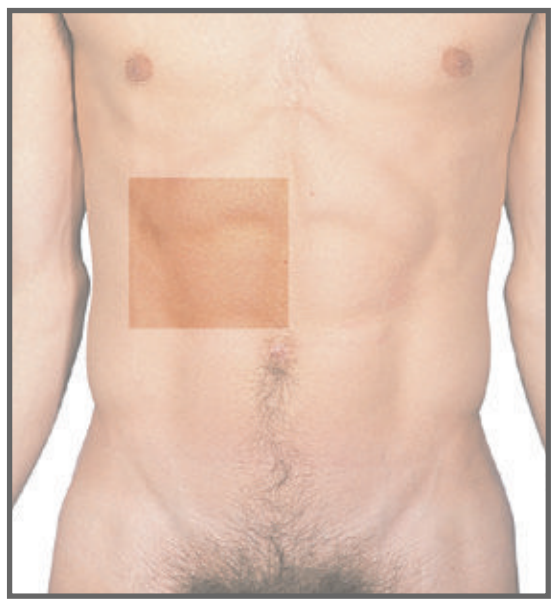

1 Ascending colon
2 Epiploic foramen (winslow)
3 Falciform ligament
4 Gall bladder
5 Gastroduodenal junction
6 Greater curvature of stomach
7 Greater omentum
8 Hepatorenal (Morison's) pouch
9 Inferior vena cava
10 Left lobe of liver
11 Lesser curvature of stomach
12 Lesser omentum overlying pancreas
13 Right colic (hepatic) flexure
14 Right free margin of lesser omentum
15 Right lobe of liver
16 Superior (first) part of duodenum
17 Transverse colon
18 Upper pole of right kidney

Diagrams of peritoneum *(see pages 227–232)*

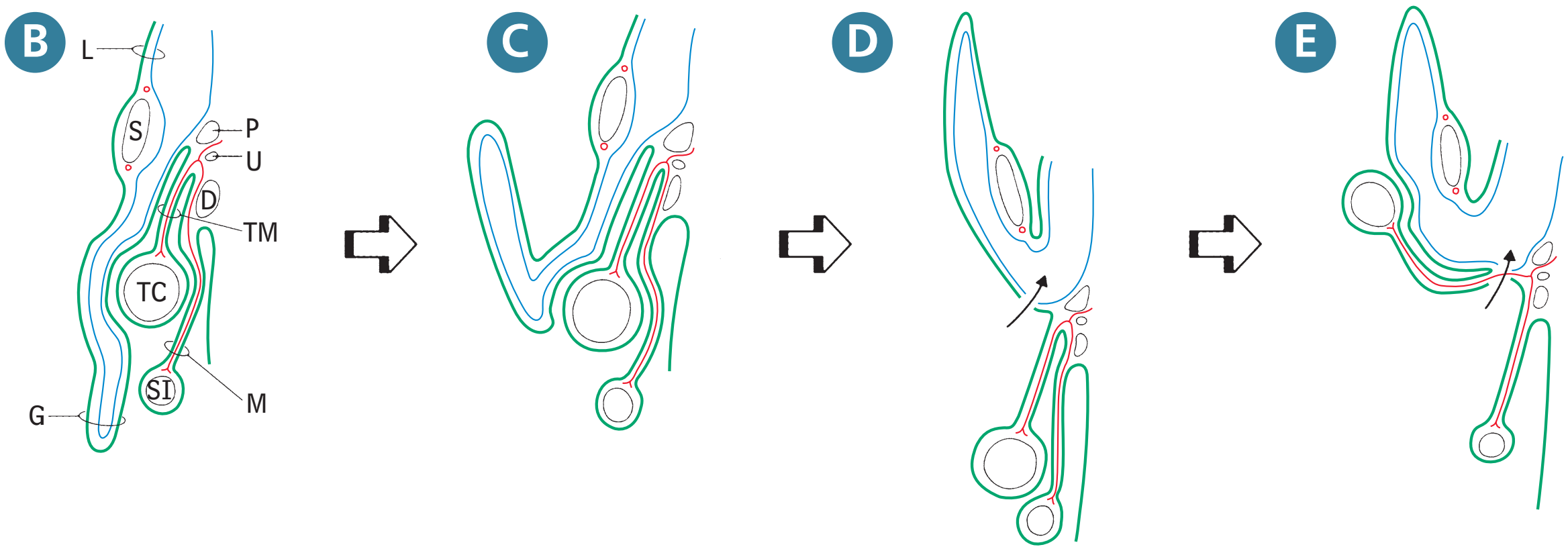

B normal position

C with the lower part of the greater omentum lifted up

D with the greater omentum lifted up and separated from the transverse mesocolon and colon, with an opening into the lesser sac

E with the greater omentum and transverse mesocolon and colon lifted up, with an opening into the lesser sac through the mesocolon

These drawings of a sagittal section through the middle of the abdomen, viewed from the left, illustrate theoretically how the peritoneum forms the lesser omentum (L, passing down to the stomach, S), greater omentum (G), transverse mesocolon (TM) passing to the transverse colon (TC), and the mesentery (M) of the small intestine (SI). The layer in blue represents the peritoneum of the lesser sac. The superior mesenteric artery passes between the head and uncinate process of the pancreas (P and U), and continues across the duodenum (D) into the mesentery (M) to the small intestine (SI), giving off the middle colic artery which runs in the transverse mesocolon (TM) to the transverse colon (TC). The greater omentum (G) is formed by four layers fused together and also fused with the front of the transverse mesocolon (TM, two layers) and transverse colon. On dissection, no separation between any layers is possible except between the greater omentum and the transverse mesocolon. The six layers between the stomach and transverse colon are sometimes collectively known as the gastrocolic omentum. B corresponds to the dissections on pages 227 and 228, C to page 229, D to page 231A, and E to page 231B. The small arrows in D and E indicate the layers cut to make artificial openings into the lesser sac.

Coeliac trunk

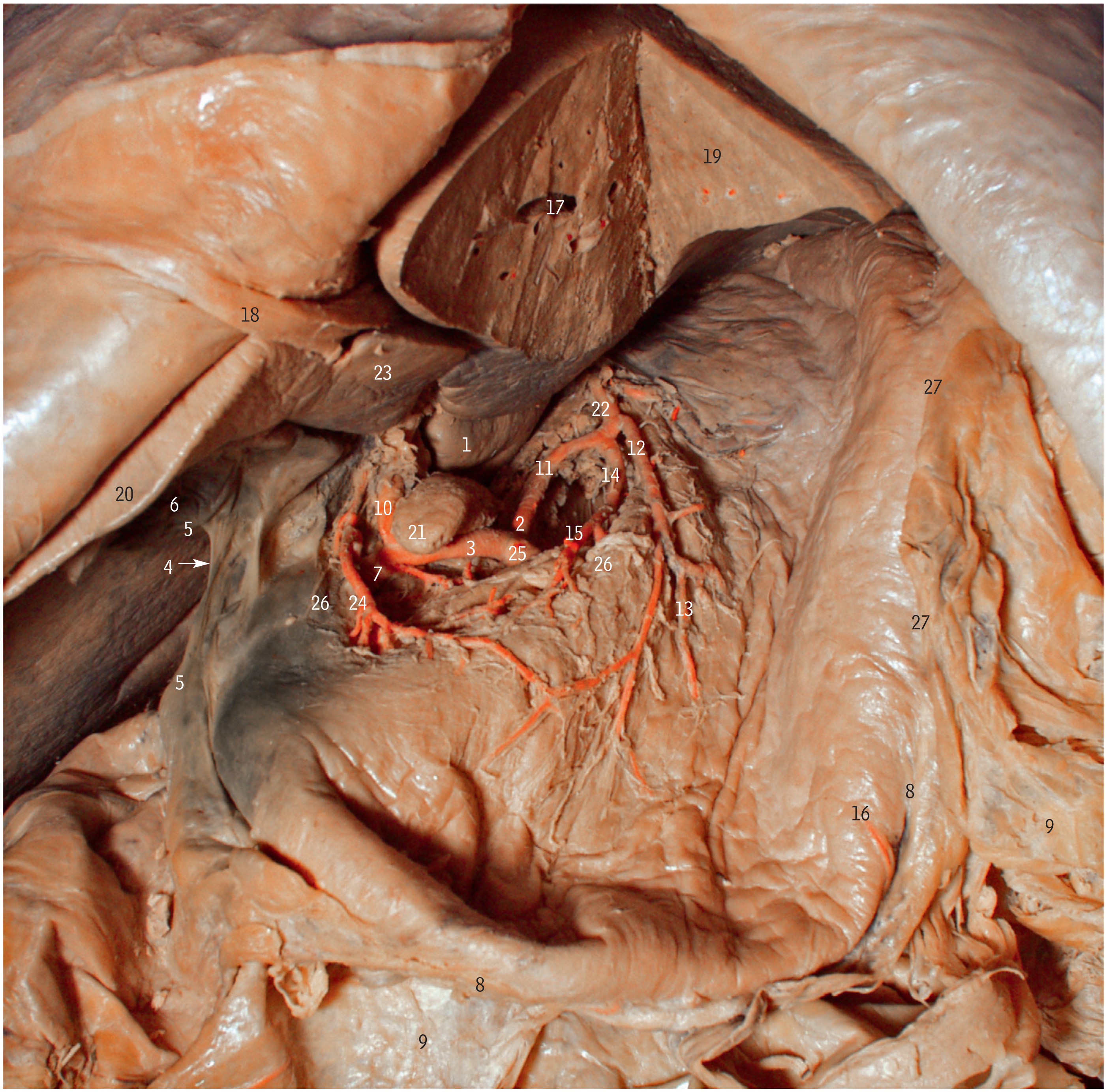

1 Caudate lobe of liver
2 Coeliac trunk
3 Common hepatic artery
4 Epiploic foramen – arrow
5 Free edge, lesser omentum
6 Gall bladder
7 Gastroduodenal artery
8 Greater curvature of stomach
9 Greater omentum
10 Hepatic artery, proper
11 Left gastric artery
12 Left gastric, anterior branch
13 Left gastric, anterior branch to body of stomach
14 Left gastric, posterior branch
15 Left gastric, posterior branch to lesser curvature of stomach
16 Left gastroepiploic vessels
17 Left portal vein
18 Ligamentum teres hepatis within falciform ligament
19 Liver, left lobe
20 Liver, right lobe
21 Lymph node, enlarged coeliac node
22 Oesophageal branch of left gastric artery
23 Quadrate lobe of liver
24 Right gastric artery, antral branch
25 Splenic artery
26 Stomach, lesser curvature
27 Visceral peritoneum, cut edge

Abdominal vasculature variations, carcinoma of the stomach, see pages 280–284.

Superior mesenteric vessels, origins

A duodenum and pancreas in situ

B duodenum reflected to reveal posterior relations of vessels

1 Aorta
2 Duodenum reflected and pinned
3 Duodenum, ascending (fourth) part
4 Duodenum, descending (second) part
5 Duodenum, horizontal (third) part
6 Falciform ligament
7 Gall bladder, fundus
8 Inferior mesenteric artery
9 Inferior mesenteric vein
10 Inferior vena cava
11 Jejunum, origin
12 Left gonadal vein
13 Left renal artery
14 Left renal vein
15 Liver, left lobe
16 Liver, Riedel's lobe
17 Liver, right lobe
18 Lymph nodes, moderately enlarged pre and para-aortic
19 Pancreas, body
20 Pancreas, head
21 Pancreas, tail
22 Pancreas, uncinate process
23 Renal cyst, benign
24 Right gonadal vein
25 Spleen
26 Splenic artery
27 Splenic vein
28 Subcostal nerve
29 Superior mesenteric artery
30 Superior mesenteric vein
31 Ureter

Inferior vena cava (IVC) obstruction, pancreatic pathology, pancreatitis, see pages 280–284.

Coeliac trunk, upper abdomen *detailed dissection*

The stomach has been sectioned to expose the dissected liver, biliary tree, pancreas, duodenum, and superior mesenteric vessels lying posterior to the stomach bed.

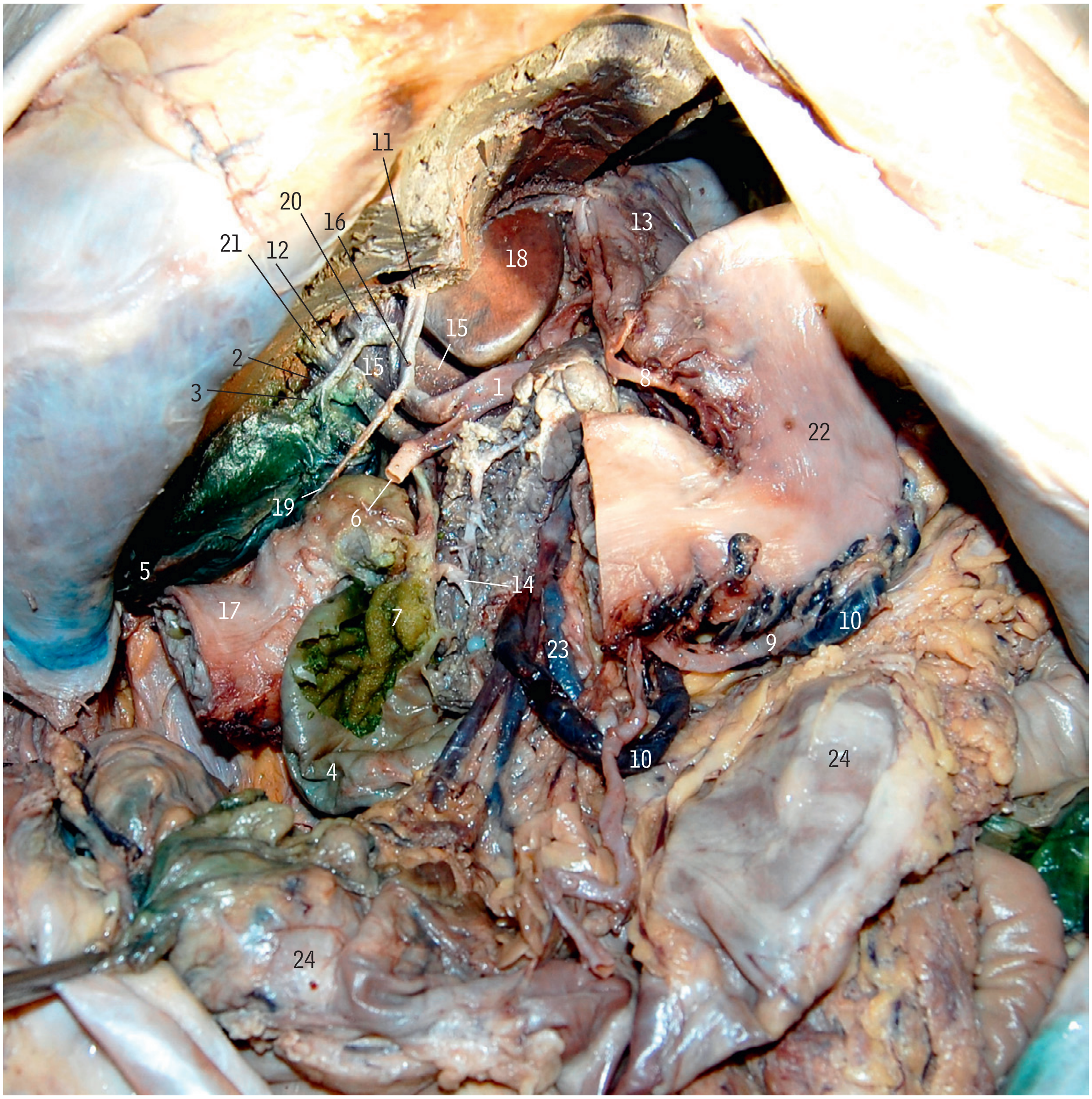

1 Common hepatic artery
2 Cystic artery
3 Cystic duct
4 Duodenum
5 Gall bladder
6 Gastroduodenal artery
7 Hepatopancreatic ampulla
8 Left gastric artery
9 Left gastroepiploic artery
10 Left gastroepiploic vein
11 Left hepatic artery
12 Left hepatic duct
13 Oesophagus
14 Pancreatic duct
15 Portal vein
16 Proper hepatic artery
17 Pylorus
18 Caudate lobe (liver)
19 Right gastric artery
20 Right hepatic artery
21 Right hepatic duct
22 Stomach
23 Superior mesenteric vein
24 Transverse colon

Pyloric stenosis (adult), see pages 280–284.

Coeliac trunk, upper abdomen *detailed dissection*

1 (Common) bile duct
2 Caudate lobe
3 Cut edge of the liver
4 Cystic duct
5 Fundus of gallbladder
6 Gastroduodenal artery
7 Greater curvature of stomach
8 Greater omentum
9 Left and right hepatic artery
10 Left and right hepatic duct
11 Left gastric artery
12 Lesser curvature of stomach
13 Pancreas
14 Parietal peritoneum on anterior abdominal wall, reflected laterally
15 Proper hepatic artery
16 Right gastro-omental artery
17 Right gastro-omental vein
18 Transverse colon

Superior mesenteric vessels

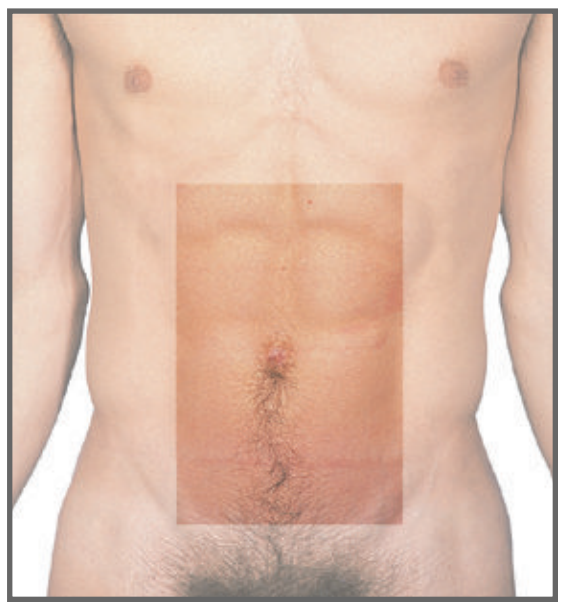

1 Third part of the duodenum
2 Anastomotic arcades
3 Appendicular artery
4 Appendix
5 Ascending colon
6 Caecum
7 Greater omentum
8 Ileocaecal junction
9 Ileocolic artery
10 Ileocolic vein
11 Ileum
12 Jejunal artery
13 Jejunal vein
14 Jejunum
15 Mesentery of the ileum
16 Middle colic artery
17 Right colic artery
18 Straight arteries
19 Superior mesenteric vein
20 Transverse colon

Meckel's diverticulum, see pages 280–284.

Inferior mesenteric vessels *from the front*

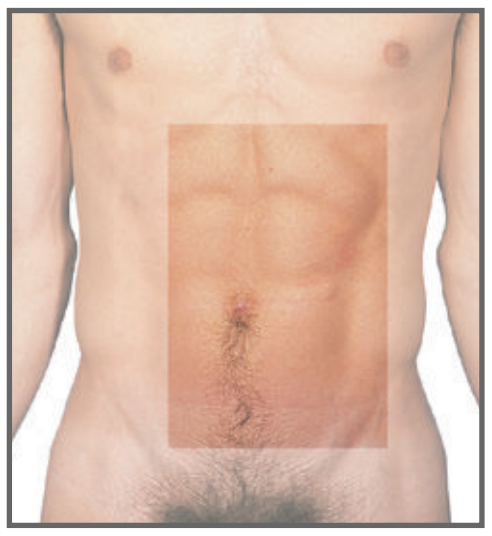

1 Abdominal aorta
2 Descending colon
3 Greater omentum
4 Ileum and jejunum
5 Inferior mesenteric artery
6 Left colic artery
7 Left common iliac artery
8 Marginal artery
9 Transverse abdominis
10 Renal artery
11 Renal vein
12 Right common iliac artery
13 Right kidney
14 Sigmoid arteries
15 Spleen
16 Superior hypogastric plexus
17 Superior rectal artery
18 Superior rectal vein
19 Transverse colon

Bowel ischaemia, see pages 280–284.

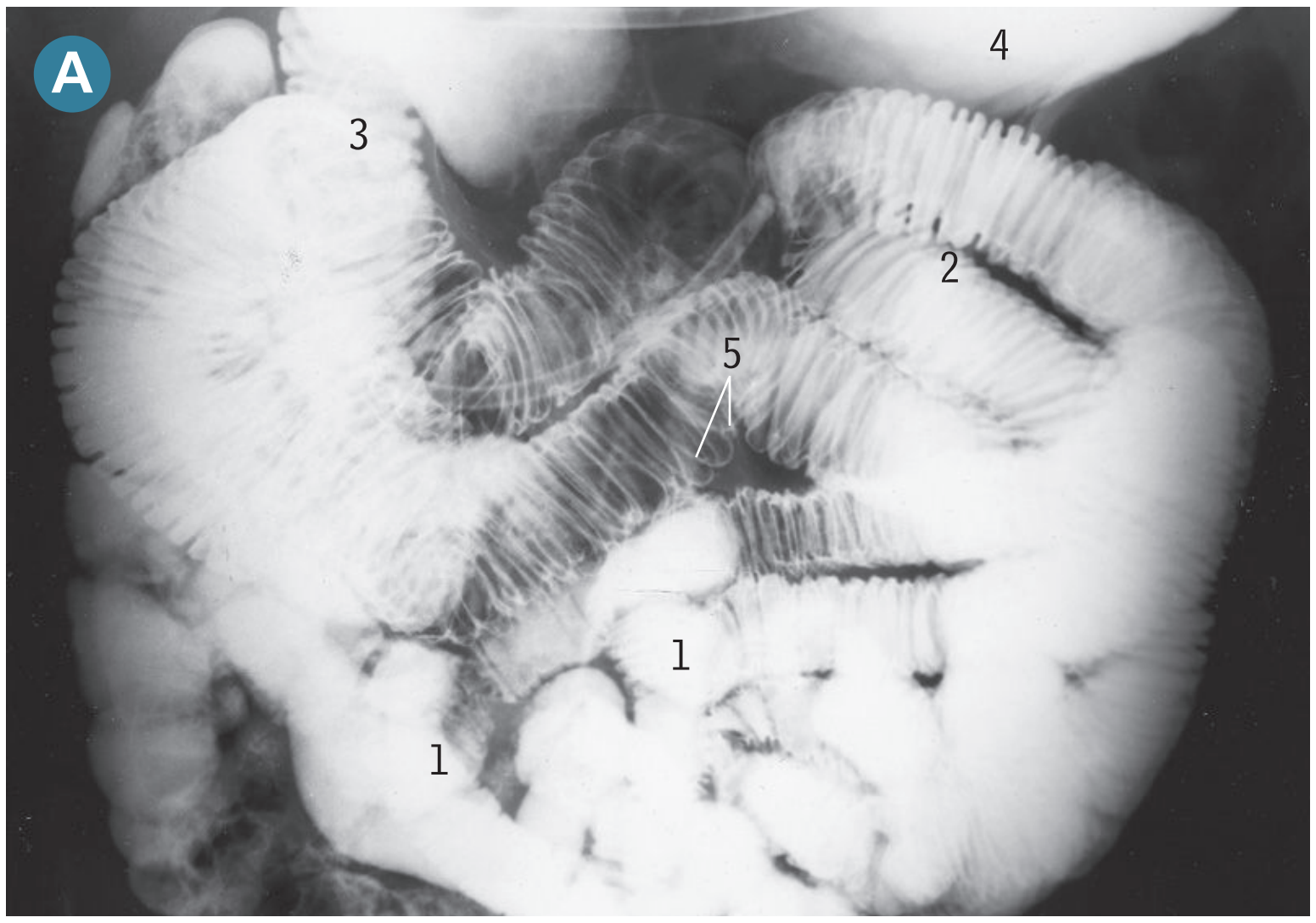

A Small bowel radiograph

enema via a tube in the duodenum

1 Coils of ileum
2 Coils of jejunum
3 Descending (second) part of duodenum
4 Stomach
5 Valvulae conniventes

B Large intestine radiograph

In this double-contrast barium enema (barium and air), the sacculations (haustrations, 9) of the various parts of the colon allow it to be distinguished from the narrower terminal ileum (11), which has become partly filled by barium flowing into it through this incompetent ileocaecal junction (5).

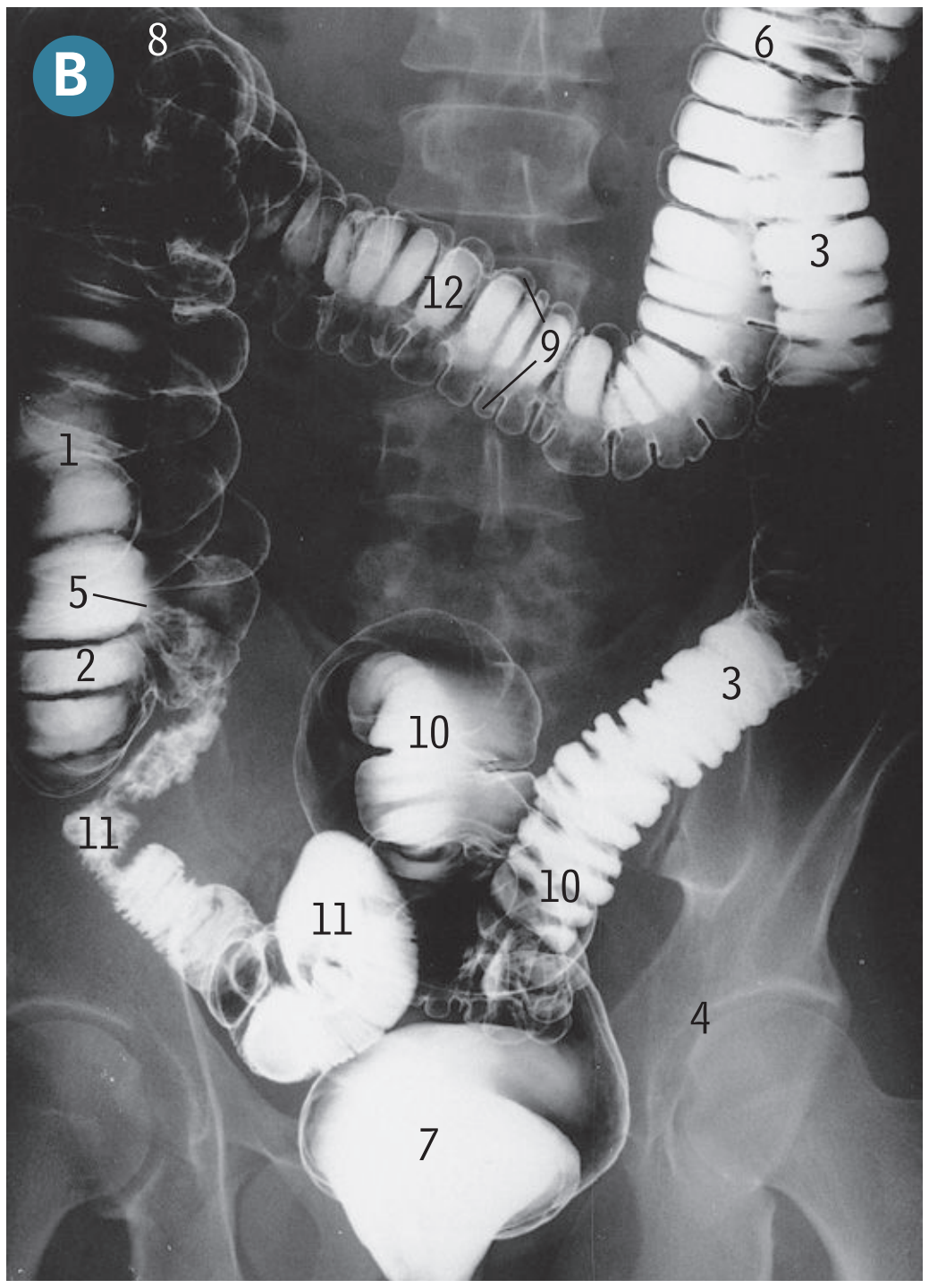

1 Ascending colon
2 Caecum
3 Descending colon
4 Hip joint
5 Ileocaecal junction
6 Left colic (splenic) flexure
7 Rectum
8 Right colic (hepatic) flexure
9 Sacculations
10 Sigmoid colon
11 Terminal ileum
12 Transverse colon

C 3D reconstruction CT 64 slice scan "3D scout scan from virtual colonoscopy"

Colonic stents, colostomy, rectosigmoid foreign bodies, see pages 280–284.

Stomach *with vessels and vagus nerves, from the front*

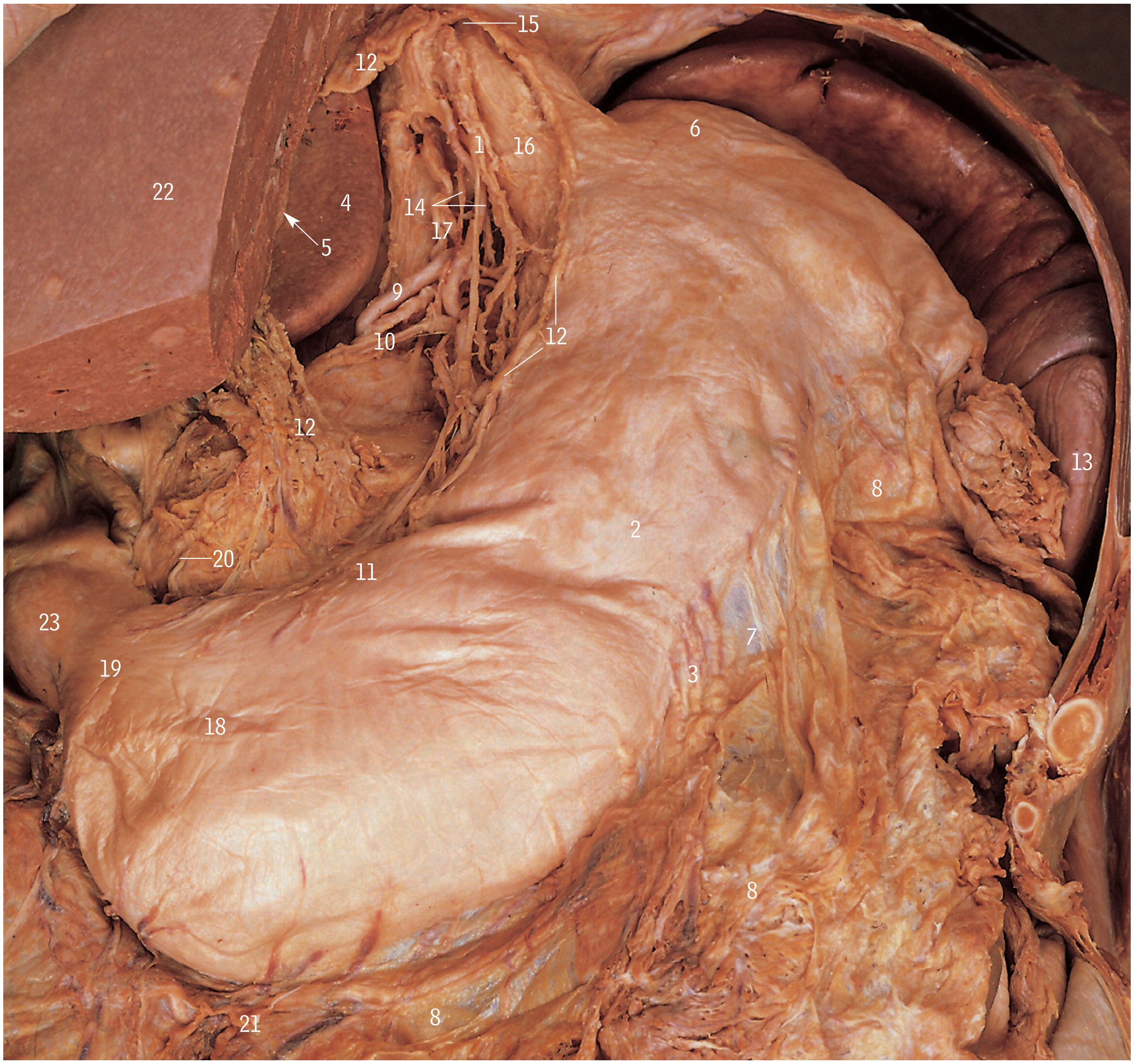

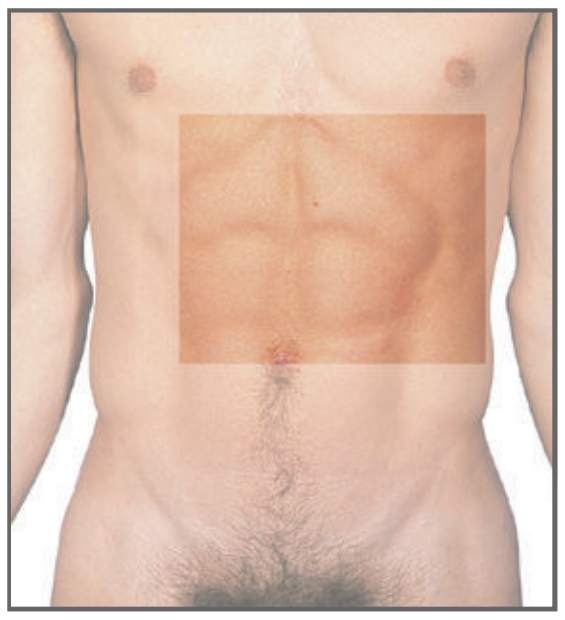

The anterior thoracic and abdominal walls and the left lobe of the liver have been removed, with part of the lesser omentum (12), to show the stomach (6, 2, 18 and 19) in its undisturbed position.

1 Anterior (left) vagal trunk
2 Body of stomach
3 Branches of left gastro-epiploic vessels
4 Caudate lobe of liver
5 Fissure for ligamentum venosum
6 Fundus of stomach
7 Greater curvature of stomach
8 Greater omentum
9 Left gastric artery
10 Left gastric vein
11 Lesser curvature of stomach
12 Lesser omentum (cut edge)
13 Lower end of spleen
14 Oesophageal branches of left gastric vessels
15 Oesophageal opening in diaphragm
16 Oesophagus
17 Posterior (right) vagal trunk
18 Pyloric antrum
19 Pyloric canal
20 Right gastric artery
21 Right gastro-epiploic vessels and branches
22 Right lobe of liver
23 Superior (first) part of duodenum

Oesophageal varices, vagotomy, see pages 280–284.

Upper abdomen **A** *stomach – barium meal*

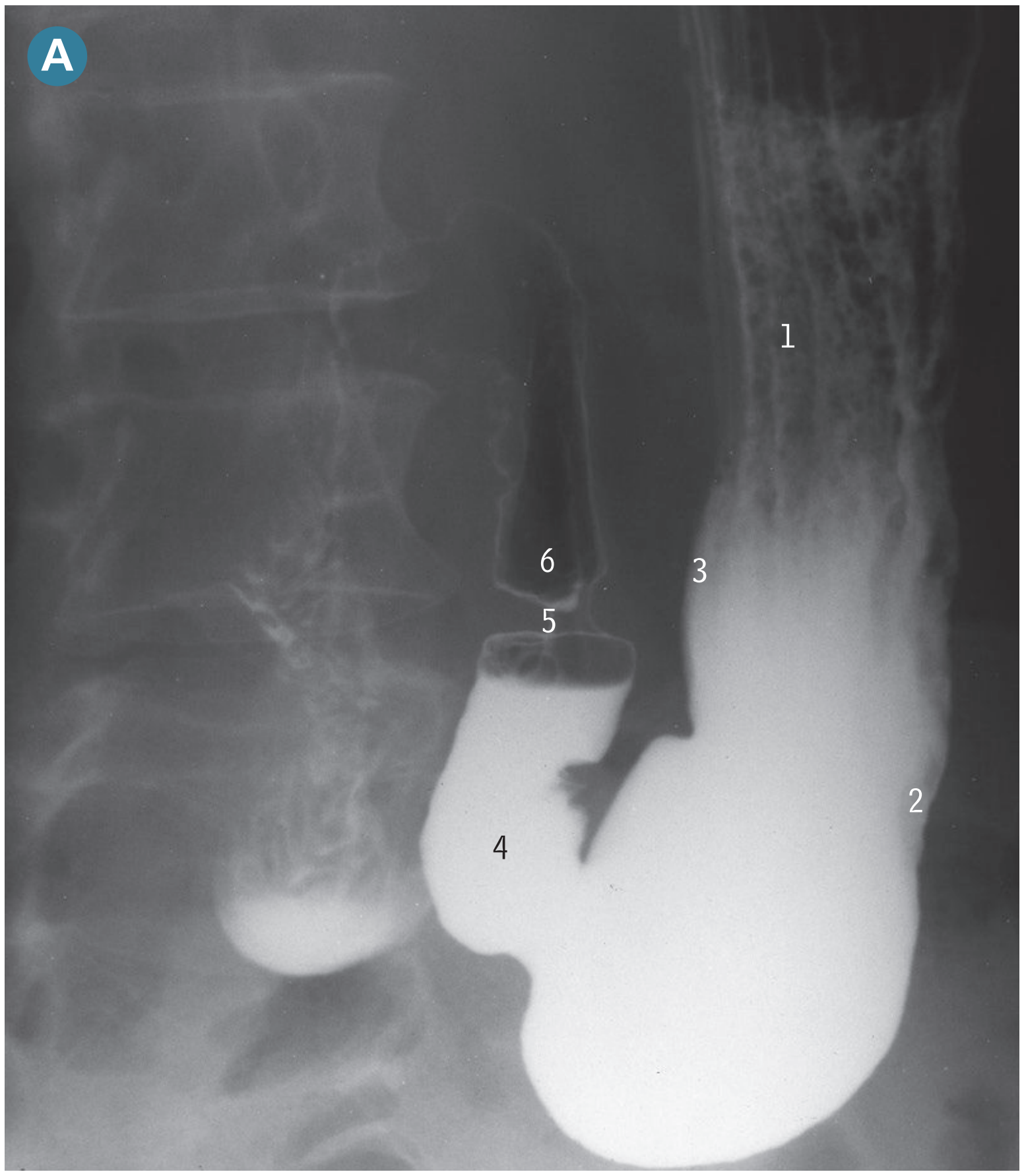

1 Body of stomach
2 Greater curvature of stomach
3 Lesser curvature of stomach
4 Pyloric antrum
5 Pyloric canal
6 Duodenal cap

SUPERIOR

LATERAL

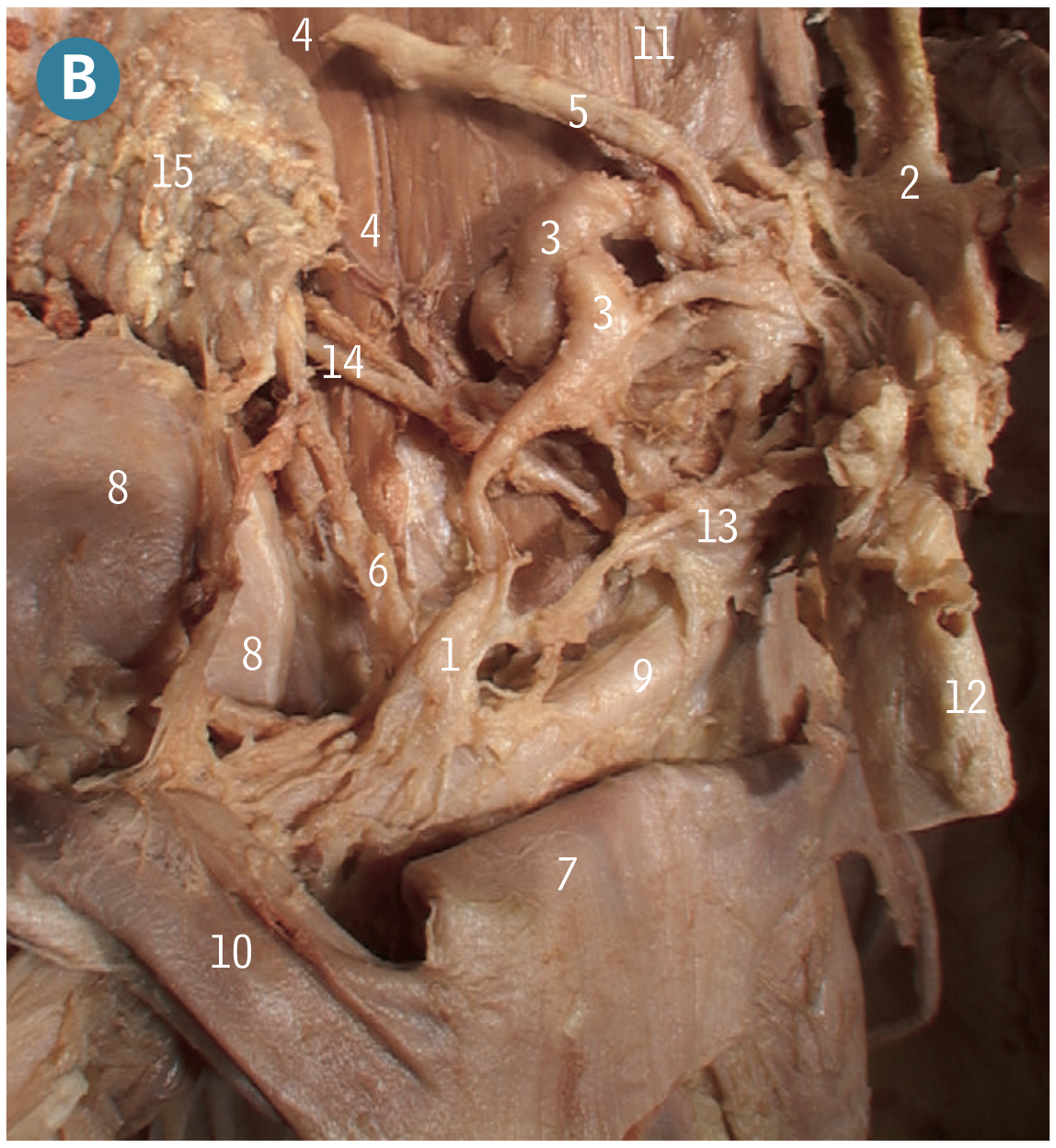

MEDIAL

INFERIOR

B *posterior wall – coeliac ganglion and relations*

1 Aorto-renal ganglion
2 Coeliac arterial trunk (reflected anteriorly)
3 Coeliac ganglion
4 Diaphragm
5 Inferior phrenic artery
6 Inferior suprarenal artery
7 Inferior vena cava (reflected inferiorly)
8 Kidney, right
9 Renal artery, right
10 Renal vein (reflected)
11 Right crus, diaphragm
12 Superior mesenteric artery
13 Superior mesenteric ganglion
14 Superior suprarenal artery
15 Suprarenal gland

Coeliac plexus block, gastric pacemaker, hiatus hernia, see pages 280–284.

A Pancreas, duodenum and superior mesenteric vessels

The stomach with its attached greater omentum has been lifted up.

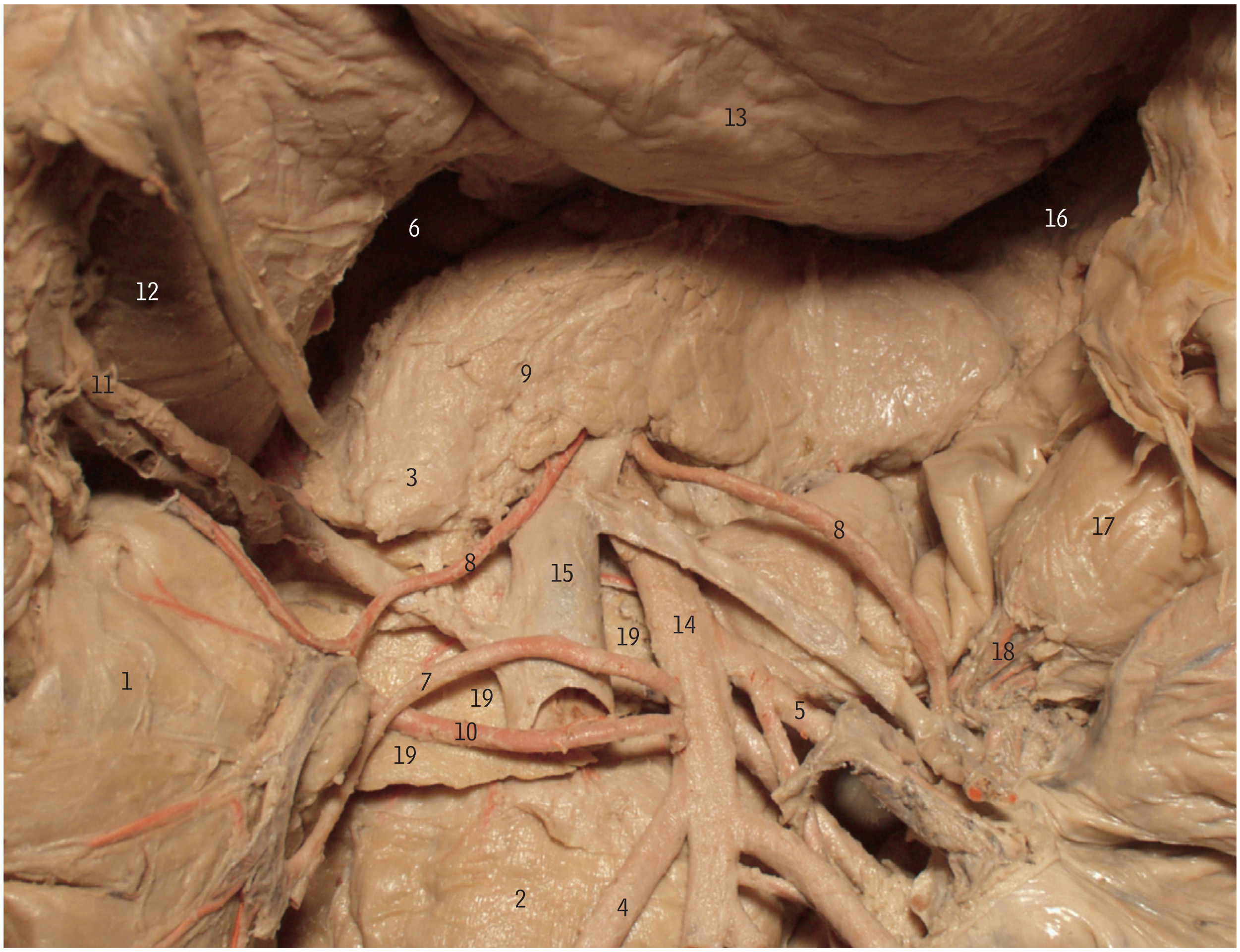

B Duodenal papilla

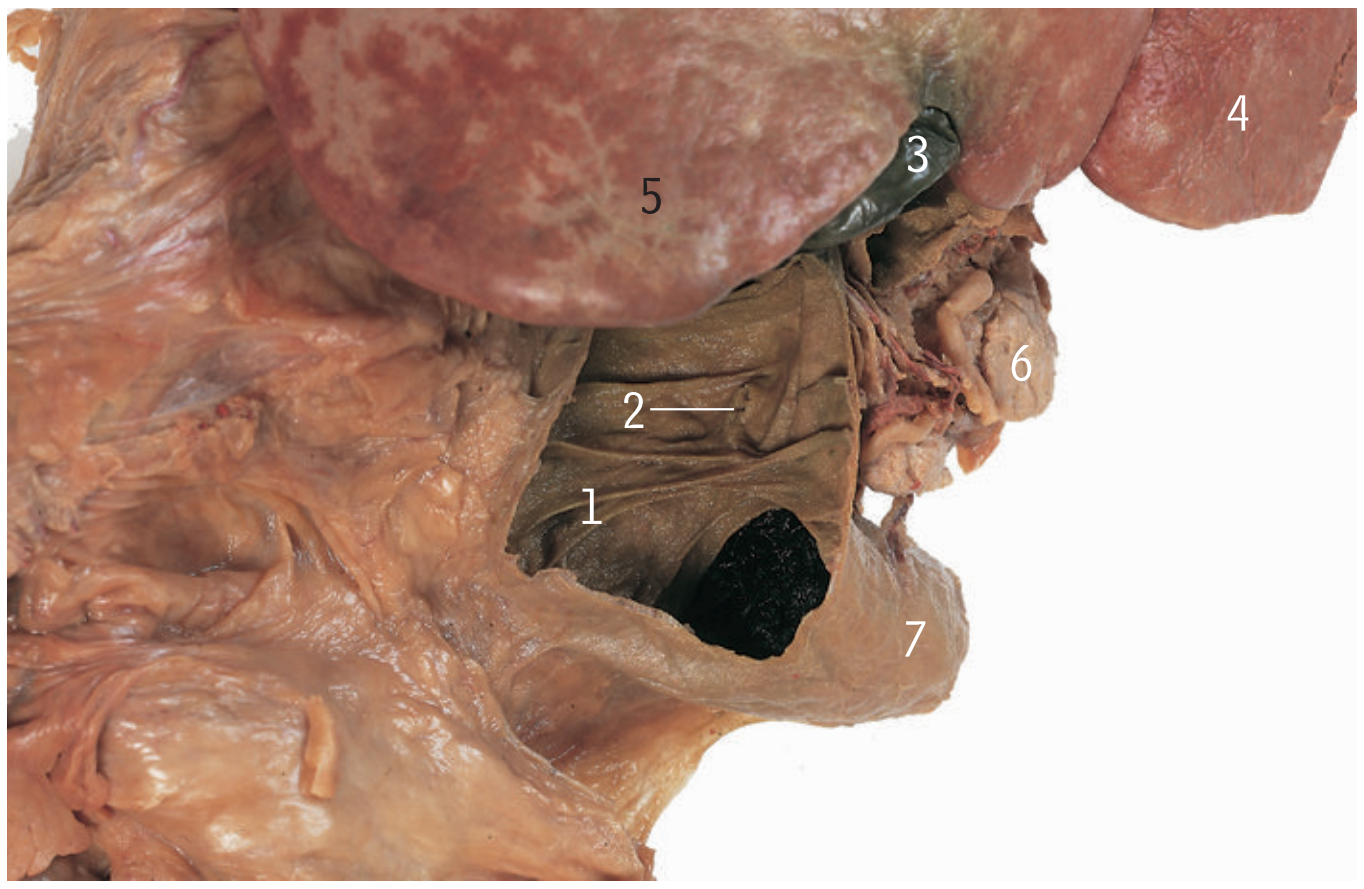

The anterior wall of the descending (second) part of the duodenum has been removed.

1. Circular folds of mucous membrane
2. Duodenal papilla
3. Gall bladder
4. Liver, left lobe
5. Liver, right lobe
6. Pancreas
7. Third part of duodenum

The stomach has been retracted superiorly to reveal the 'stomach bed.'

1. Ascending colon
2. Duodenum, third part
3. Head of pancreas
4. Ileocolic artery
5. Jejunal branch of superior mesenteric artery
6. Lesser sac
7. Middle colic artery
8. Middle colic artery, aberrant variation
9. Neck of pancreas
10. Right colic artery
11. Right gastroepiploic vessels
12. Stomach, antrum (reflected anteriorly)
13. Stomach, body
14. Superior mesenteric artery
15. Superior mesenteric vein
16. Tail of pancreas
17. Transverse colon
18. Transverse colon, artery and vein
19. Uncinate process of pancreas

Pancreatitis, see pages 280–284.

Liver *from the front*

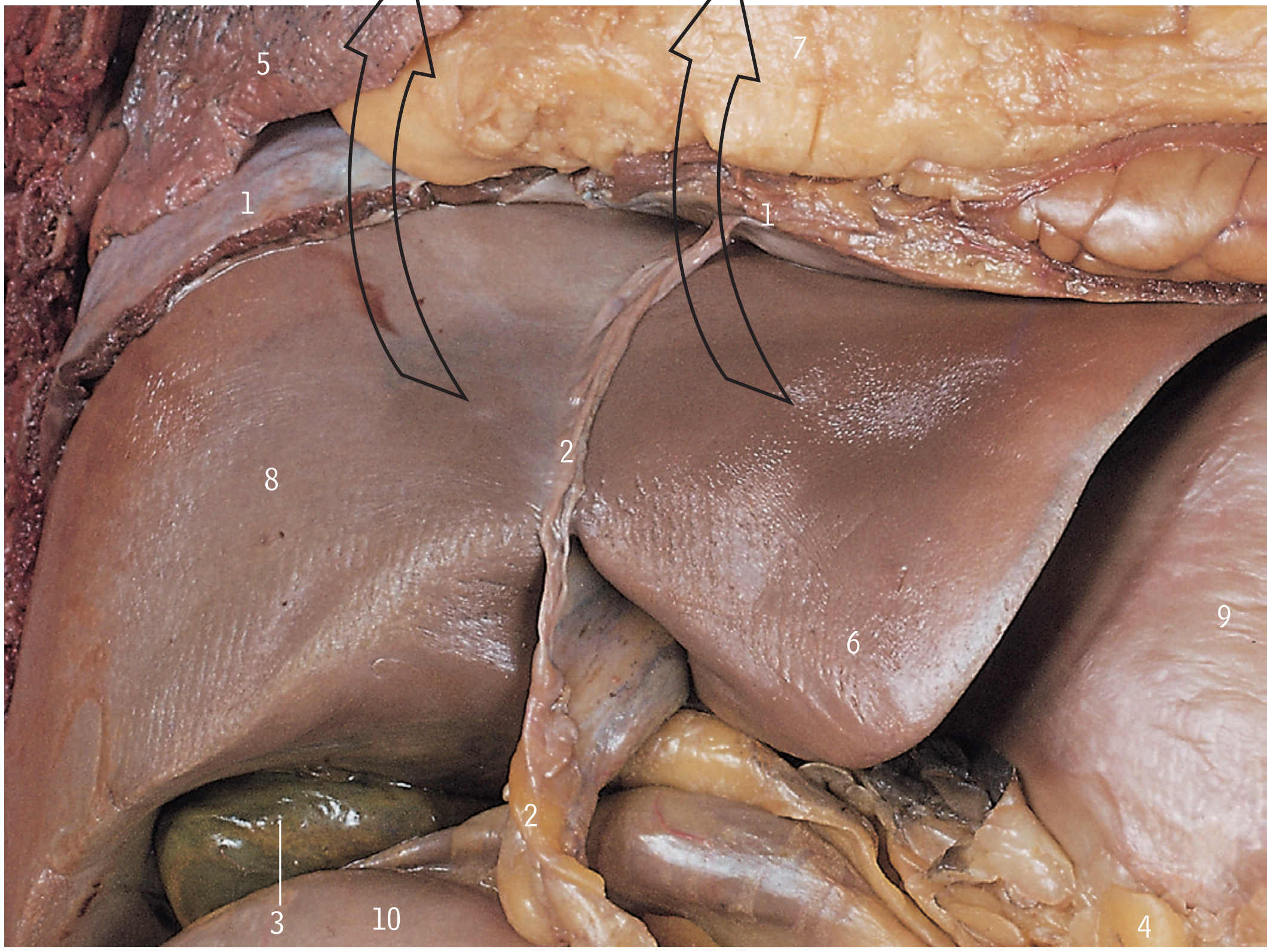

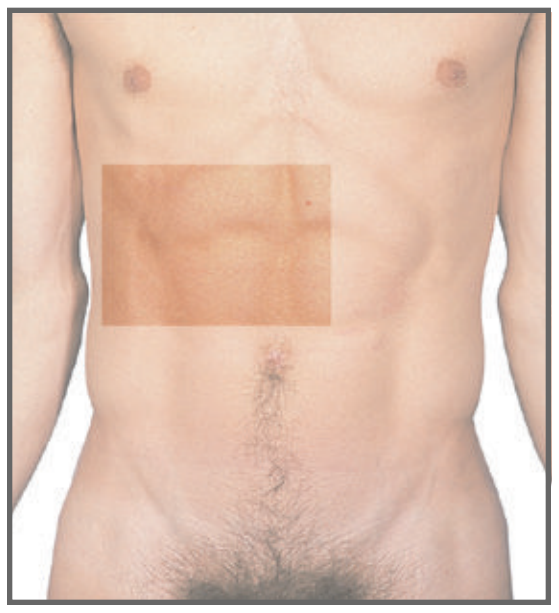

1 Diaphragm
2 Falciform ligament
3 Gall bladder, fundus
4 Greater omentum
5 Inferior lobe of right lung
6 Left lobe of liver
7 Pericardial fat
8 Right lobe of liver
9 Stomach
10 Transverse colon

For an explanation of peritoneal structures, see the diagrams on pages 220, 233.

The thoracic and abdominal walls and the anterior part of the diaphragm have been removed to show the undisturbed viscera. The liver (6 and 8) and stomach (9) are immediately below the diaphragm (1). The greater omentum (4) hangs down from the greater curvature (lower margin) of the stomach (9), overlying much of the small and large intestine but leaving some of the transverse colon (10) uncovered. The fundus (tip) of the gall bladder (3) is seen between the right lobe of the liver (8) and transverse colon (10). Arrows indicate the direction of liver reflection for the view on following page (page 245).

Coronal CT, upper abdomen

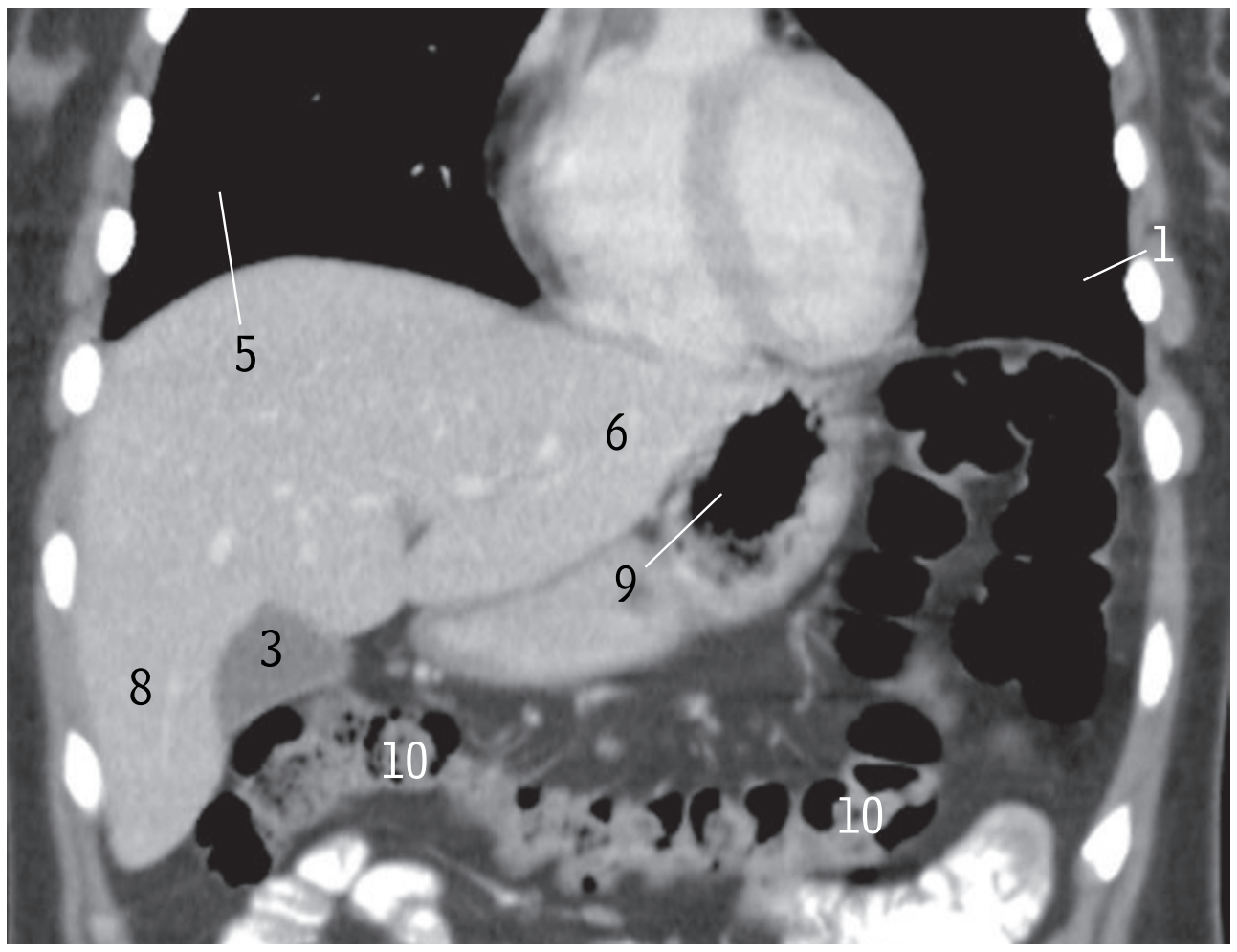

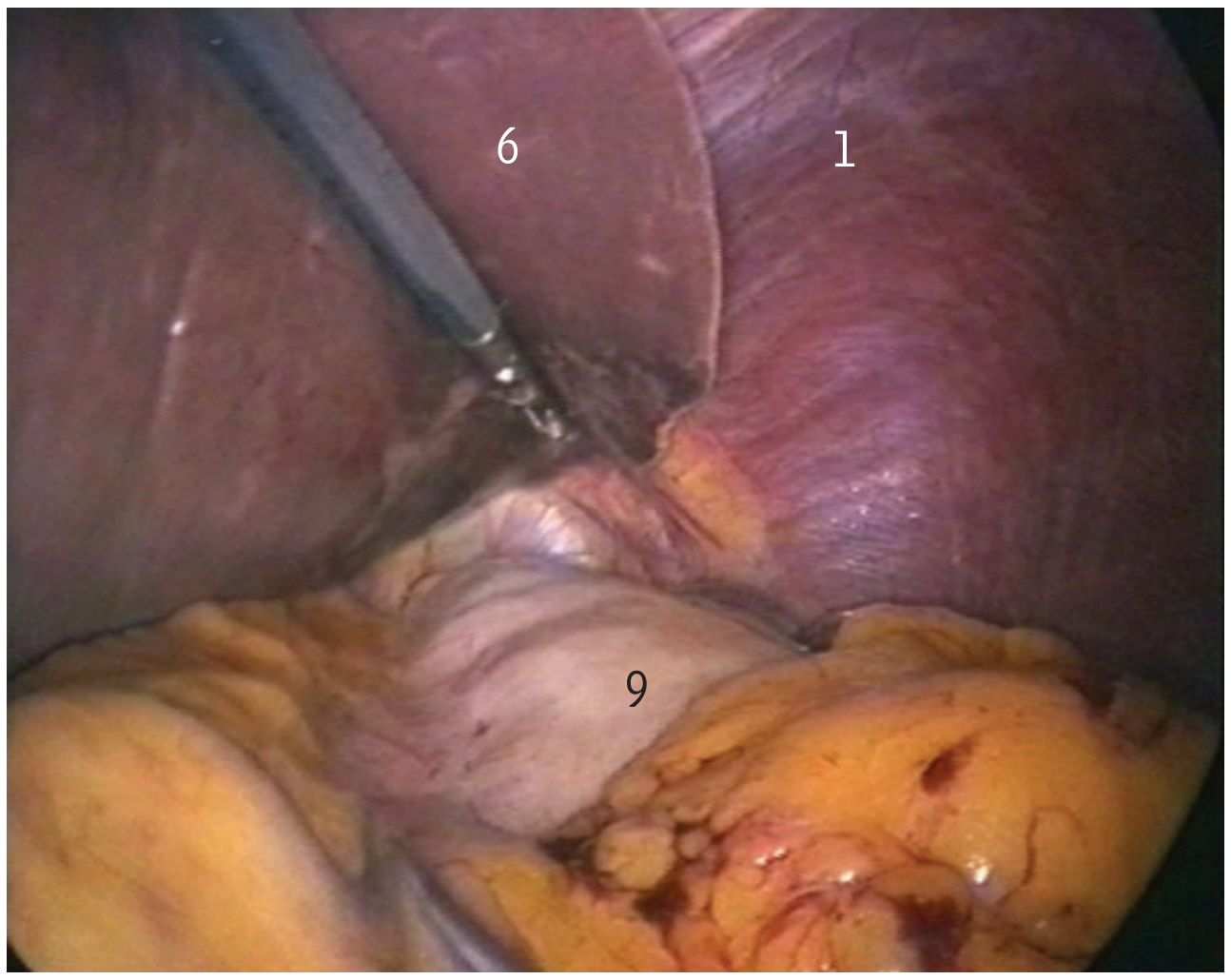

Laparoscopic view of upper abdominal viscera

Cirrhosis of liver, liver trauma, see pages 280–284.

Liver *from below and behind*

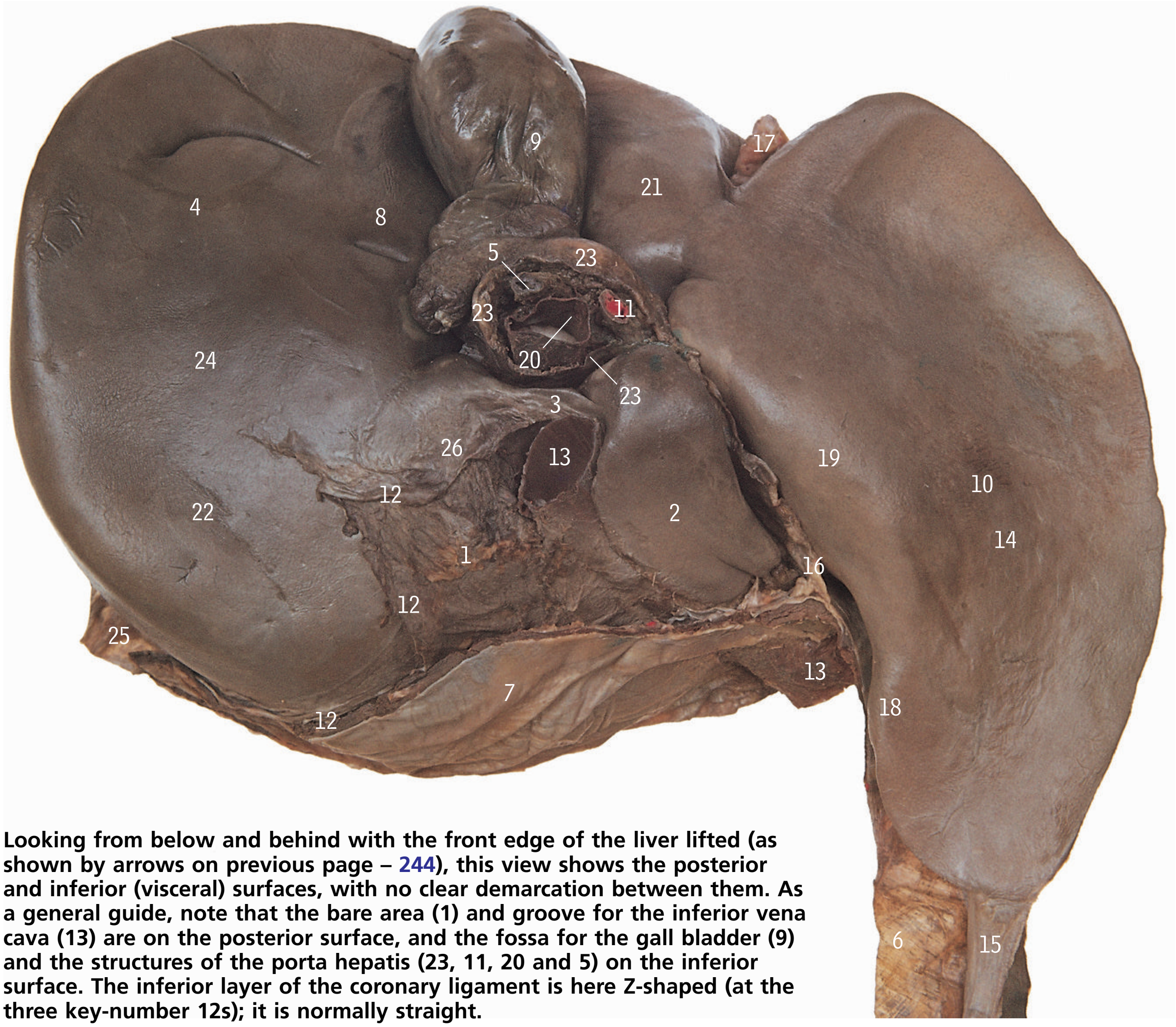

Looking from below and behind with the front edge of the liver lifted (as shown by arrows on previous page – 244), this view shows the posterior and inferior (visceral) surfaces, with no clear demarcation between them. As a general guide, note that the bare area (1) and groove for the inferior vena cava (13) are on the posterior surface, and the fossa for the gall bladder (9) and the structures of the porta hepatis (23, 11, 20 and 5) on the inferior surface. The inferior layer of the coronary ligament is here Z-shaped (at the three key-number 12s); it is normally straight.

1 Bare area
2 Caudate lobe
3 Caudate process
4 Colic impression
5 Common hepatic duct
6 Diaphragm
7 Diaphragm on part of bare area (obstructing view of superior layer of coronary ligament)
8 Duodenal impression
9 Gall bladder
10 Gastric impression
11 Hepatic artery
12 Inferior layer of coronary ligament
13 Inferior vena cava
14 Left lobe
15 Left triangular ligament
16 Lesser omentum in fissure for ligamentum venosum
17 Ligamentum teres and falciform ligament in fissure for ligamentum teres
18 Oesophageal groove
19 Omental tuberosity
20 Portal vein
21 Quadrate lobe
22 Renal impression
23 Right free margin of lesser omentum in porta hepatis
24 Right lobe
25 Right triangular ligament
26 Suprarenal impression

The caudate (2) and quadrate (21) lobes are classified anatomically as part of the right lobe (24), but functionally they belong to the left lobe (14), since they receive blood from the left branches of the hepatic artery and portal vein, and drain bile to the left hepatic duct.

Liver abscess, Riedel's lobe, see pages 280–284.

Cast of the liver, extrahepatic biliary tract and associated vessels *from below and behind*



Yellow, gall bladder and biliary tract
Red, hepatic artery and branches
Light blue, portal vein and tributaries
Dark blue, inferior vena cava, hepatic veins and tributaries

This view, like the one on page 245, shows the inferior and posterior surfaces, as looking into the abdomen from below with the lower border of the liver pushed up towards the thorax.

1 Bile duct
2 Body of gall bladder
3 Caudate lobe
4 Caudate process
5 Common hepatic duct
6 Cystic artery and veins
7 Cystic duct
8 Fissure for ligamentum teres
9 Fissure for ligamentum venosum
10 Fundus of gall bladder
11 Hepatic artery
12 Inferior vena cava
13 Left branch of hepatic artery overlying left branch of portal vein
14 Left gastric vein
15 Left hepatic duct
16 Left hepatic vein
17 Left lobe
18 Neck of gall bladder
19 Portal vein
20 Quadrate lobe
21 Right branch of hepatic artery overlying right branch of portal vein
22 Right gastric vein
23 Right lobe

A Endoscopic retrograde cholangiopancreatogram *ERCP*

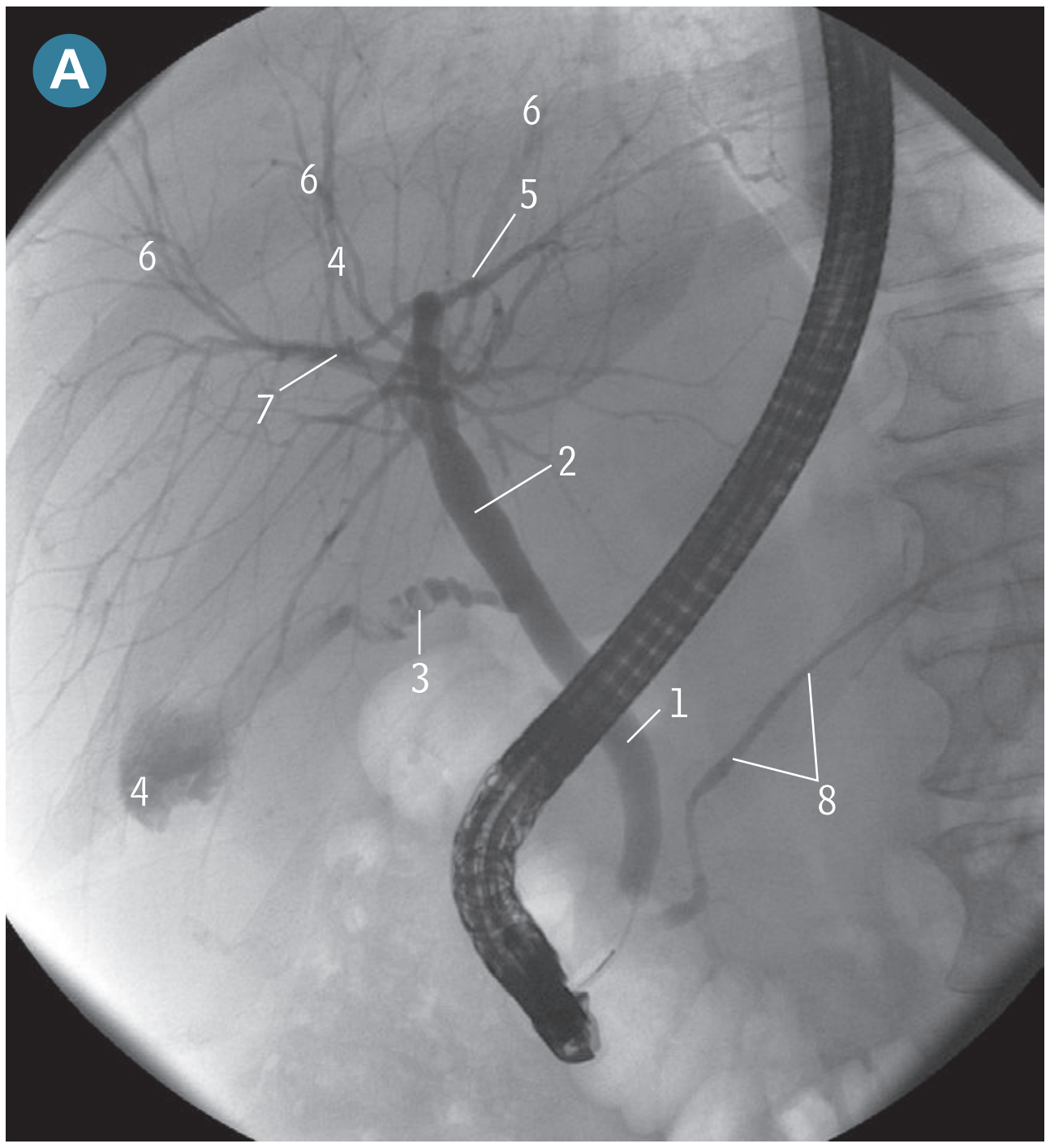

During an ERCP, an endoscope is passed through the mouth, pharynx, oesophagus and stomach into the duodenum, and through it, a cannula is introduced into the major duodenal papilla (page 243B) and bile duct so that contrast medium can be injected up the biliary tract. (The pancreatic duct can also be cannulated in this way.)

1 Common bile duct
2 Common hepatic duct
3 Cystic duct
4 Gall bladder
5 Left hepatic duct
6 Liver shadow and tributaries of hepatic ducts
7 Right hepatic duct
8 Pancreatic duct

B Pancreatic duct *ERCP*

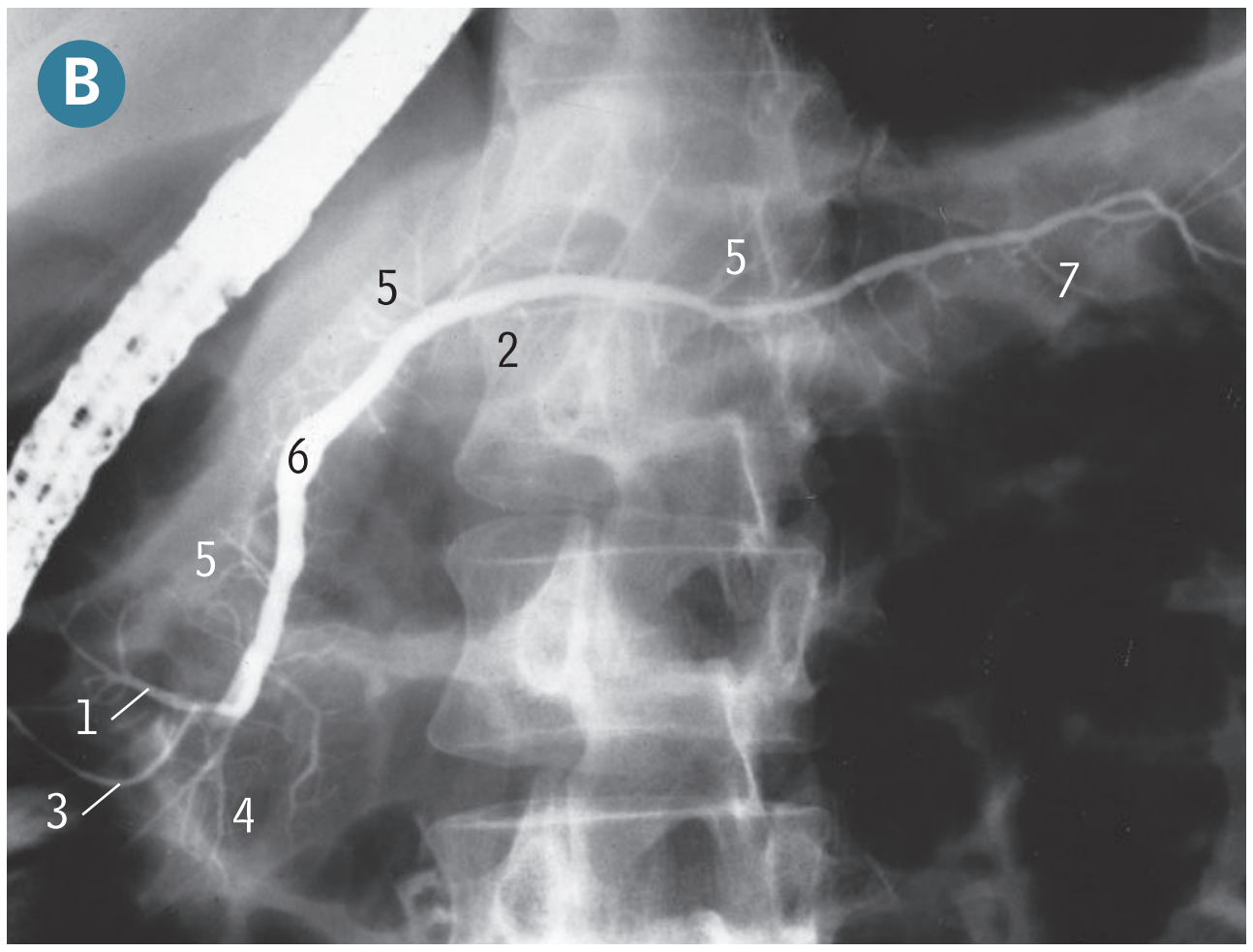

1 Accessory pancreatic duct (Santorini)
2 Body of pancreas
3 Cannula in ampulla (Vater)
4 Head of pancreas
5 Intralobular ducts of the pancreas
6 Pancreatic duct (Wirsung)
7 Tail of pancreas

C Magnetic resonance cholangiopancreatogram *MRCP*

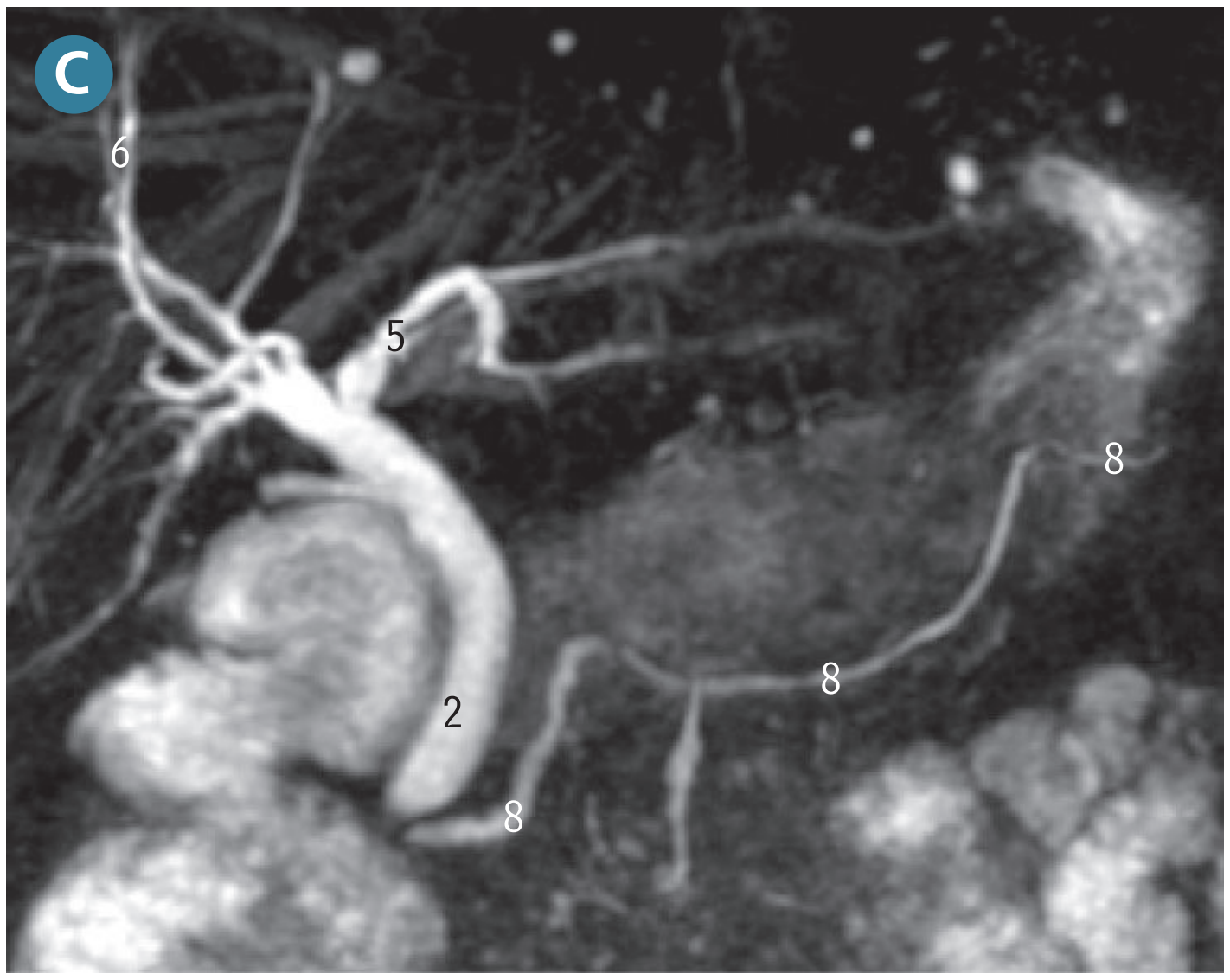

See label list for A.

Carcinoma of the pancreas, cholecystectomy, gallstones, see pages 280–284.

Cast of the portal vein and tributaries, and the mesenteric vessels *from behind*

1 Bile duct
2 Branches of middle colic vessels
3 Coeliac trunk
4 Ileocolic vessels
5 Inferior mesenteric artery
6 Inferior mesenteric vein
7 Left branch of hepatic artery
8 Left branch of portal vein
9 Left colic vessels
10 Left gastric artery and vein
11 Pancreatic duct
12 Pancreatic ducts in head of pancreas
13 Pancreaticoduodenal vessels
14 Portal vein
15 Right branch of hepatic artery
16 Right branch of portal vein
17 Right colic vessels
18 Sigmoid vessels
19 Splenic artery
20 Splenic vein
21 Superior mesenteric artery
22 Superior mesenteric vein

Coronal CT, abdomen

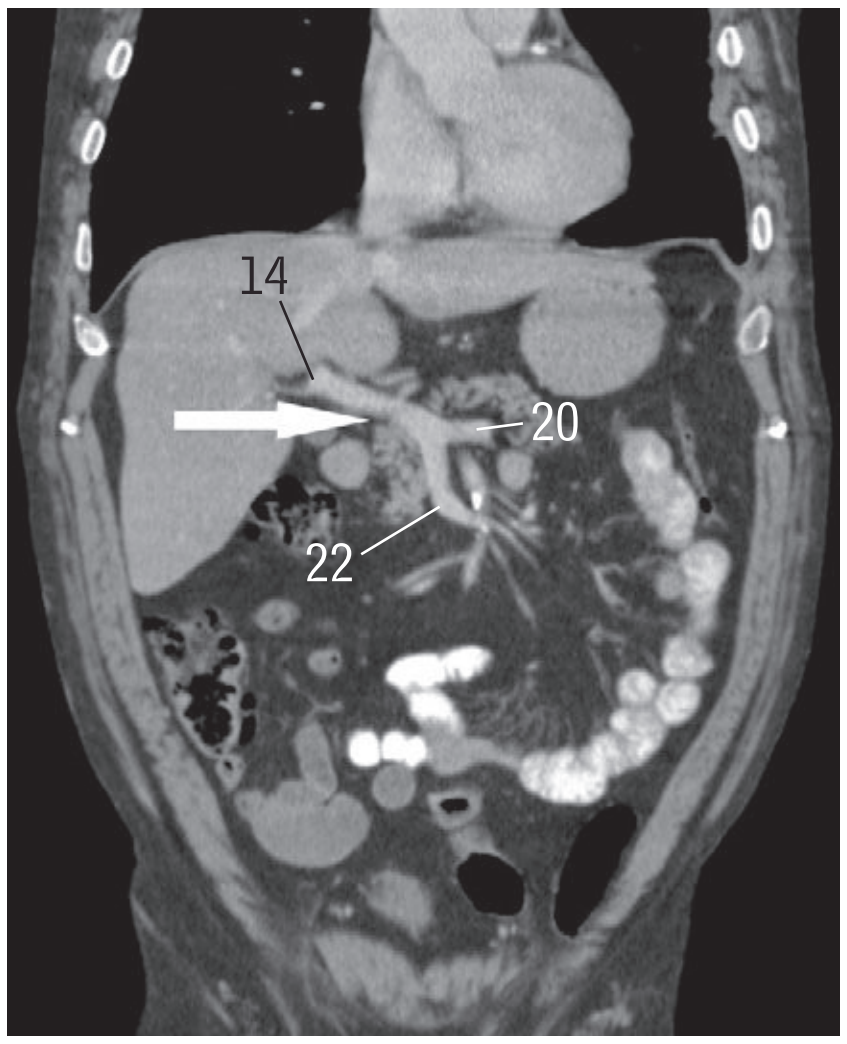

Yellow, biliary tract and pancreatic ducts; red, arteries; blue, portal venous system

In this posterior view (chosen in preference to the anterior view, where the many very small vessels to the intestines would have obscured the larger branches), the superior mesenteric vein (22) is seen continuing upwards to become the portal vein (14) after it has been joined by the splenic vein (20). In the porta hepatis, the portal vein divides into the left and right branches (8 and 16). Owing to removal of the aorta, the upper part of the inferior mesenteric artery (5) has become displaced slightly to the right and appears to have given origin to the ileocolic artery (4), but this is simply an overlap of the vessels; the origin of the ileocolic from the superior mesenteric is not seen in this view.

A Spleen *from the front*

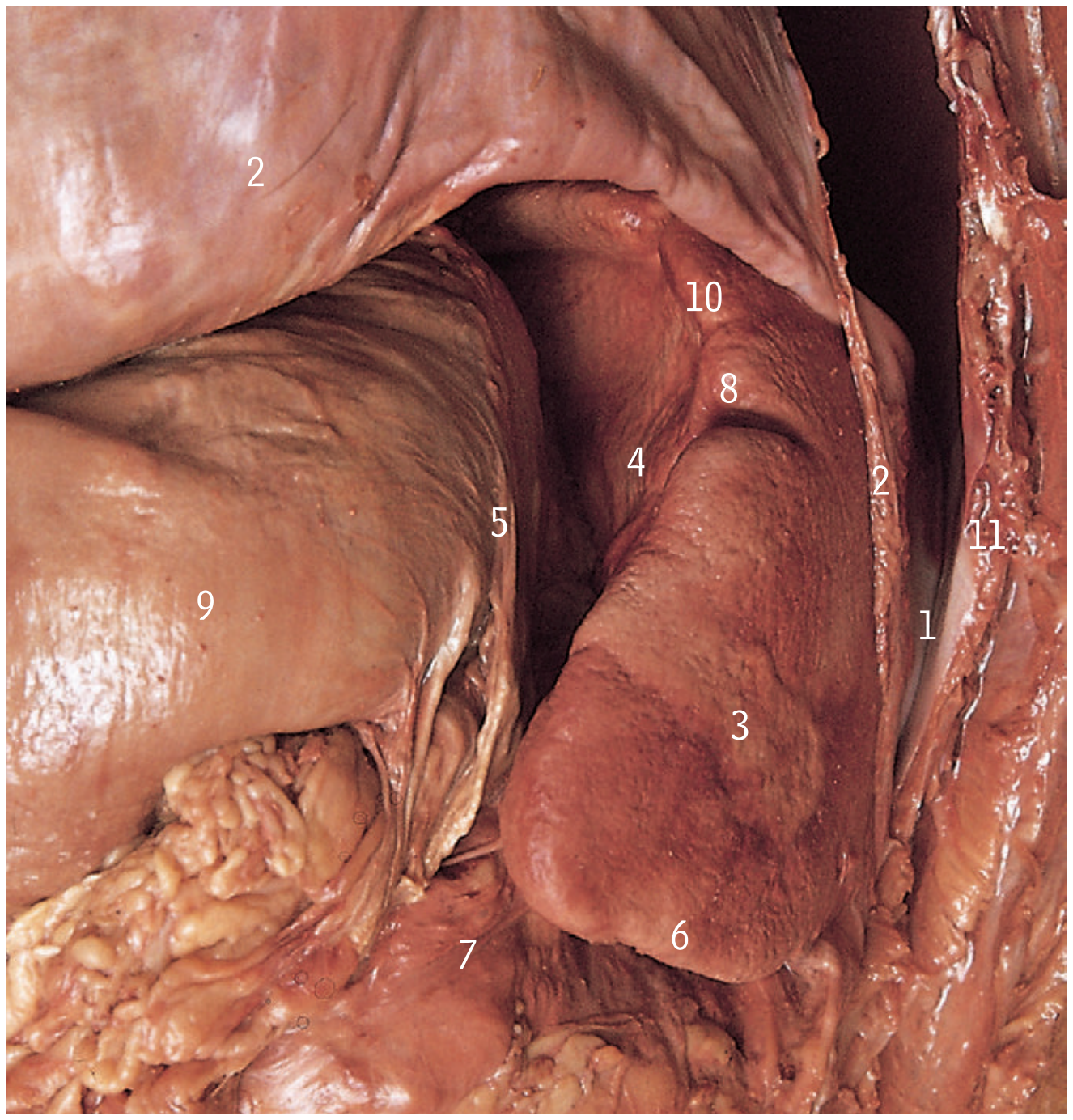

The left upper anterior abdominal and lower anterior thoracic walls have been removed and part of the diaphragm (2) turned upwards to show the spleen in its normal position, lying adjacent to the stomach (9) and colon (7), with the lower part against the kidney (D16 and 9, opposite).

The gastrosplenic ligament contains the short gastric and left gastro-epiploic branches of the splenic vessels.

The lienorenal ligament contains the tail of the pancreas and the splenic vessels.

Coronal CT

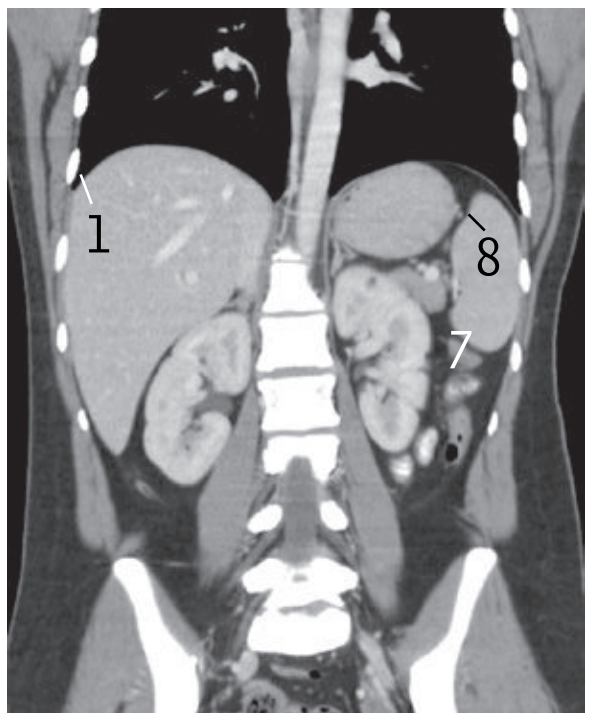

1 Costodiaphragmatic recess
2 Diaphragm
3 Diaphragmatic surface
4 Gastric impression
5 Gastrosplenic ligament
6 Inferior border
7 Left colic flexure
8 Splenic notch
9 Stomach
10 Superior border
11 Thoracic wall

B Spleen *visceral surface*

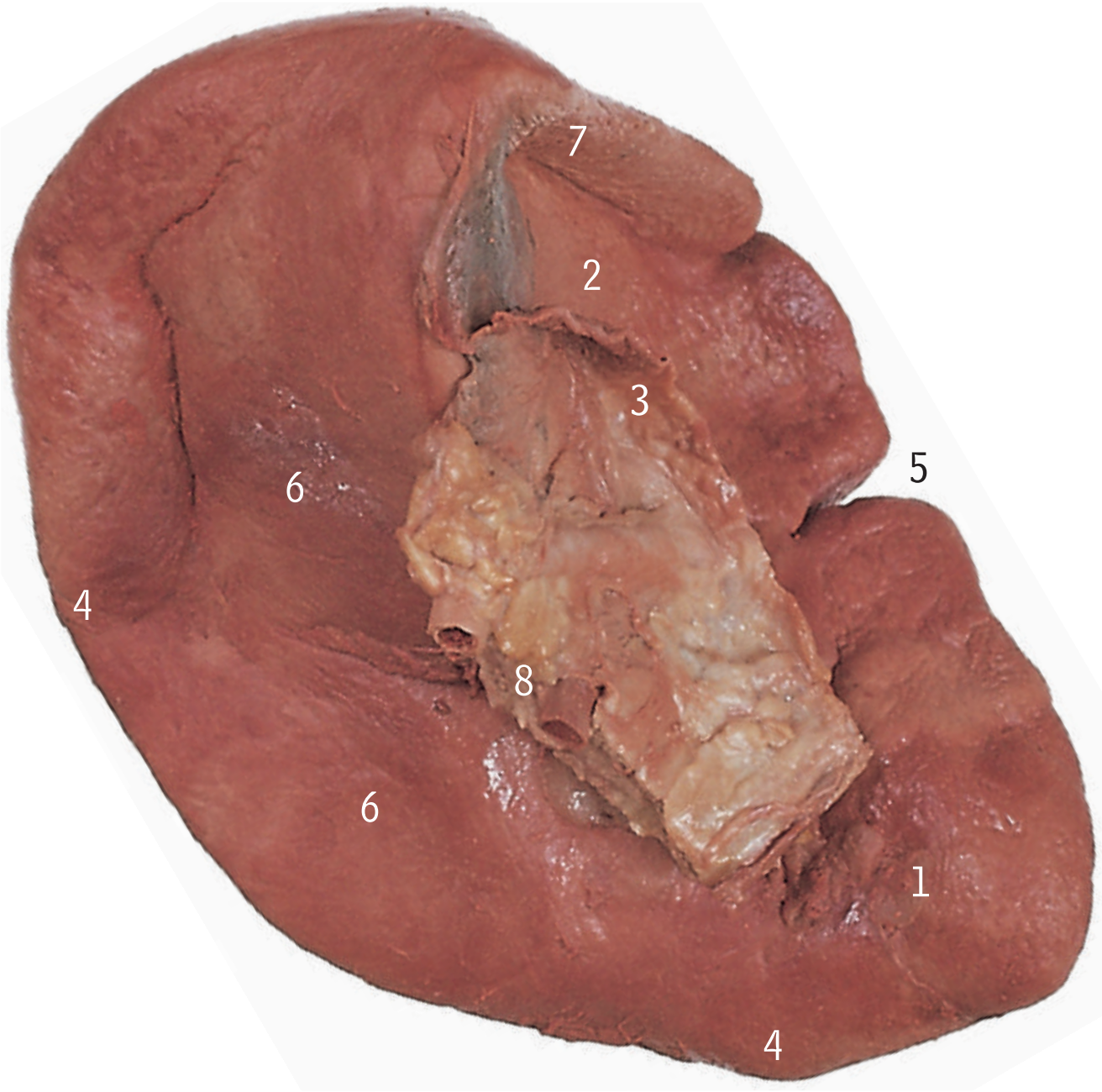

In B, the spleen has been removed and its visceral or medial surface is shown, with a small part of the gastrosplenic (3) and lienorenal (8) ligaments remaining attached.

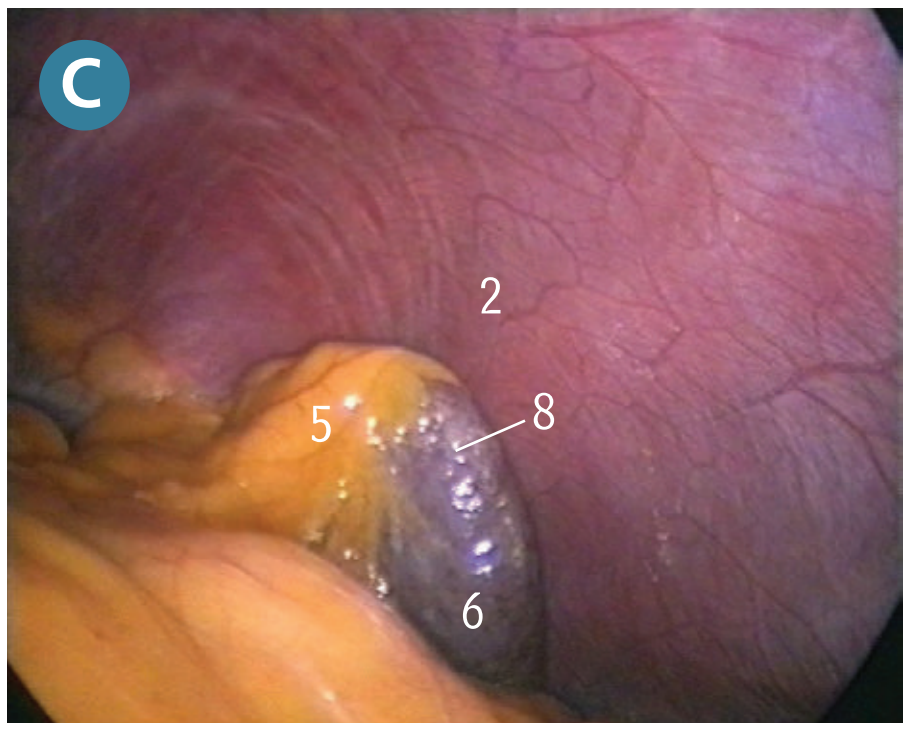

C Spleen *Laparoscopic view*

Labels refer to key in A.

1 Colic impression
2 Gastric impression
3 Gastrosplenic ligament containing short gastric and left gastro-epiploic vessels
4 Inferior border
5 Splenic notch
6 Renal impression
7 Superior border
8 Tail of pancreas and splenic vessels in lienorenal ligament

Ruptured spleen, splenic cysts, splenic infarct, splenectomy, splenomegaly, splenunculi, see pages 280–284.

D Spleen *in a transverse section of the left upper abdomen*

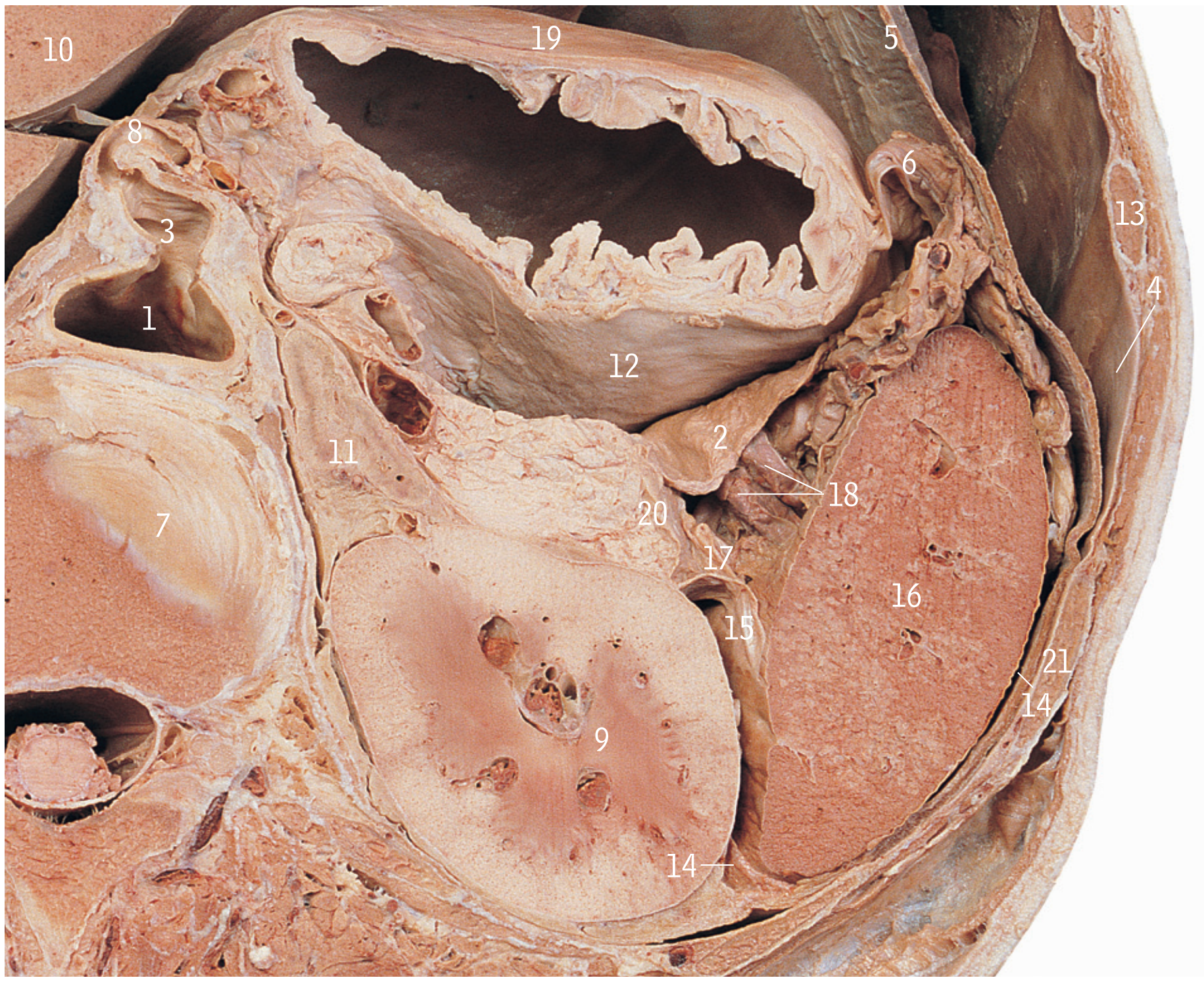

The section is at the level of the disc (7) between the twelfth thoracic and first lumbar vertebrae, and is viewed from below looking towards the thorax.

1 Abdominal aorta
2 Anterior layer of lienorenal ligament
3 Coeliac trunk
4 Costodiaphragmatic recess of pleura
5 Diaphragm
6 Gastrosplenic ligament
7 Intervertebral disc
8 Left gastric artery
9 Left kidney
10 Left lobe of liver
11 Left suprarenal gland
12 Lesser sac
13 Ninth rib
14 Peritoneum of greater sac
15 Posterior layer of lienorenal ligament
16 Spleen
17 Splenic artery
18 Splenic vein
19 Stomach
20 Tail of pancreas
21 Tenth rib

E Caecum *in sagittal section, interior view*

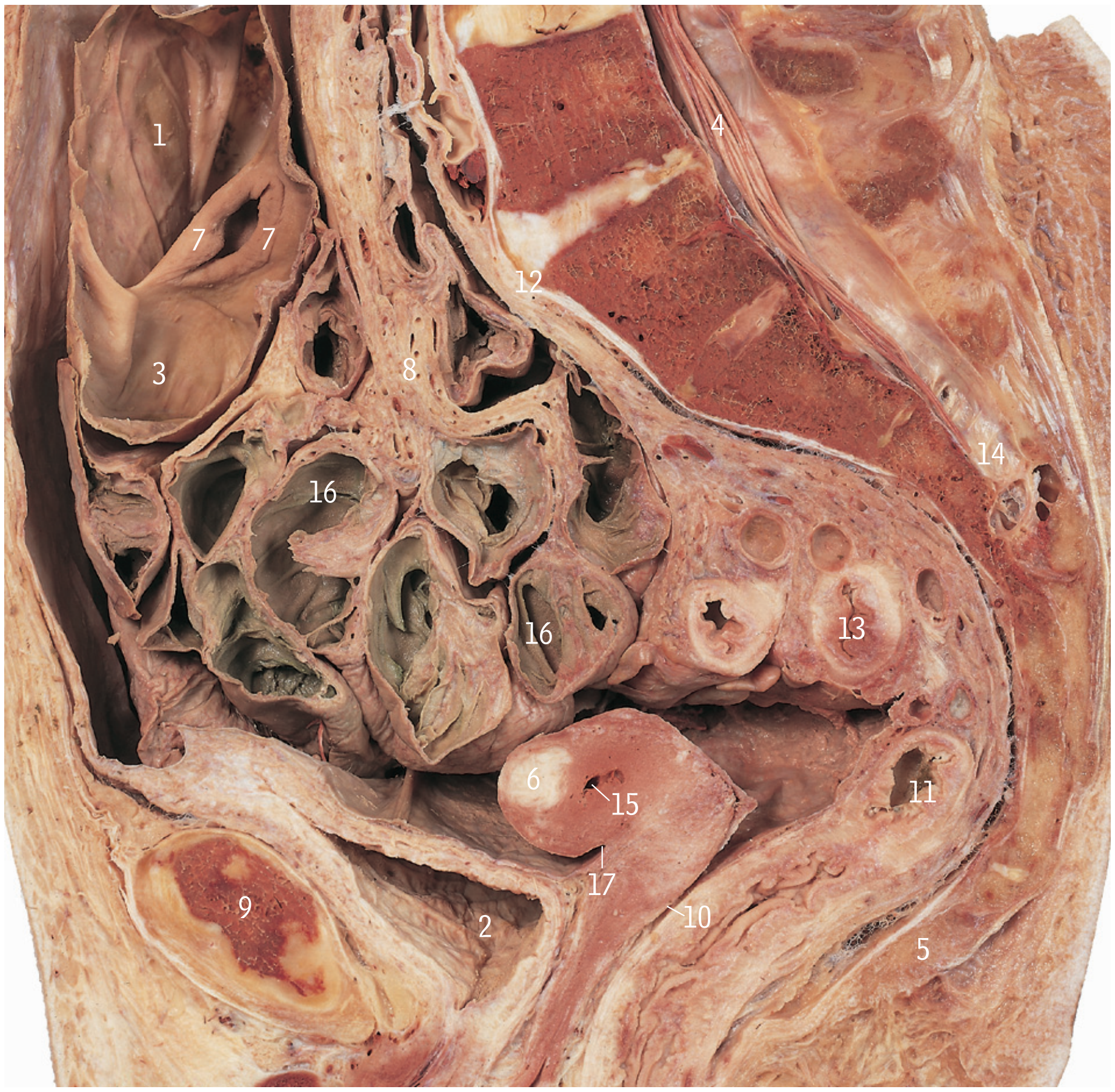

This is a median section of the female pelvis, right side viewed from the left. The caecal anterior wall has been cut open and reflected to show the lips of the ileocaecal valve (7).

1 Ascending colon
2 Bladder
3 Caecum
4 Cauda equina
5 Coccyx
6 Fibroid in uterine fundus
7 Lips of ileocaecal valve
8 Mesentery of small intestine
9 Pubic symphysis
10 Recto-uterine pouch (of Douglas)
11 Rectum
12 Sacral promontory
13 Sigmoid colon
14 Thecal sac termination
15 Uterine cavity
16 Valvulae conniventes
17 Vesico-uterine pouch

Carcinoma of the bladder, intussusception, see pages 280–284.

A Appendix, ileocolic artery and related structures *from the front*

Most of the peritoneum of the mesentery and posterior abdominal wall has been removed, and coils of small intestine (11) have been displaced to the right of the picture, to show the ileocolic artery (8), terminal ileum (15) and appendix (2) with its appendicular artery (1).

1. Appendicular artery in mesoappendix
2. Appendix
3. Ascending colon
4. Caecum
5. Descending (second) part of duodenum
6. Genitofemoral nerve
7. Ileal and caecal vessels
8. Ileocolic artery
9. Inferior vena cava
10. Lower pole of kidney
11. Mesentery and coils of jejunum and ileum
12. Mesoappendix
13. Psoas major
14. Right colic artery
15. Terminal part of ileum
16. Testicular artery
17. Testicular vein
18. Ureter

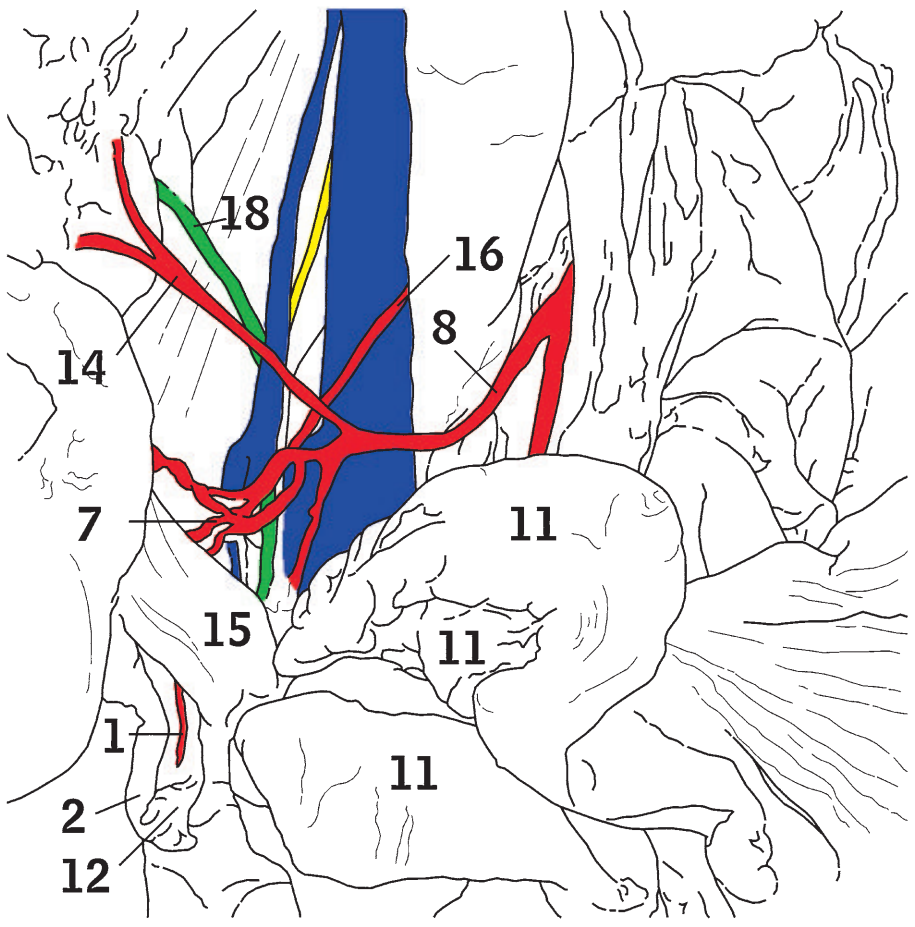

B Caecum and appendix *from the front*

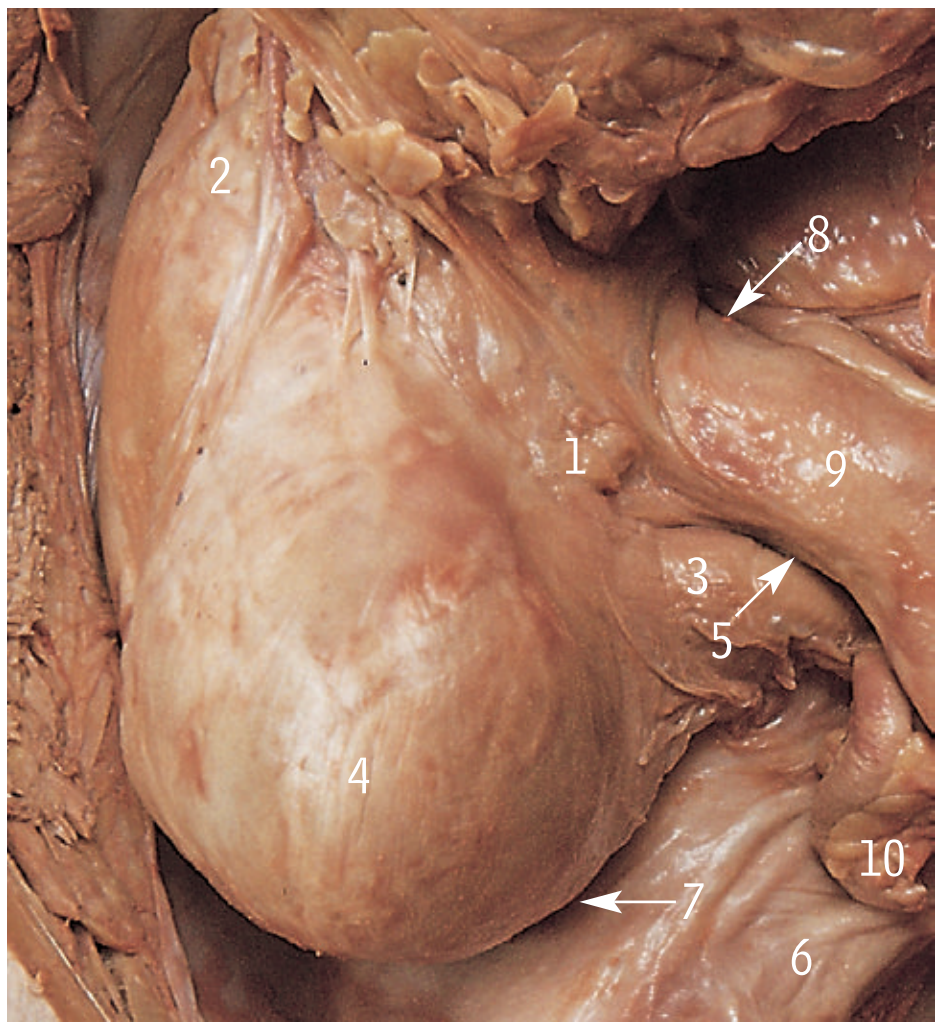

The terminal ileum (9) is seen joining the large intestine at the junction of the caecum (4) and ascending colon (2), and the appendix (3) joins the caecum just below the ileocaecal junction.

1. Anterior taenia coli
2. Ascending colon
3. Base of appendix
4. Caecum
5. Inferior ileocaecal recess
6. Peritoneum overlying external iliac vessels
7. Retrocaecal recess
8. Superior ileocaecal recess
9. Terminal ileum
10. Tip of appendix

Appendicitis, see pages 280–284.

Small intestine

C

D

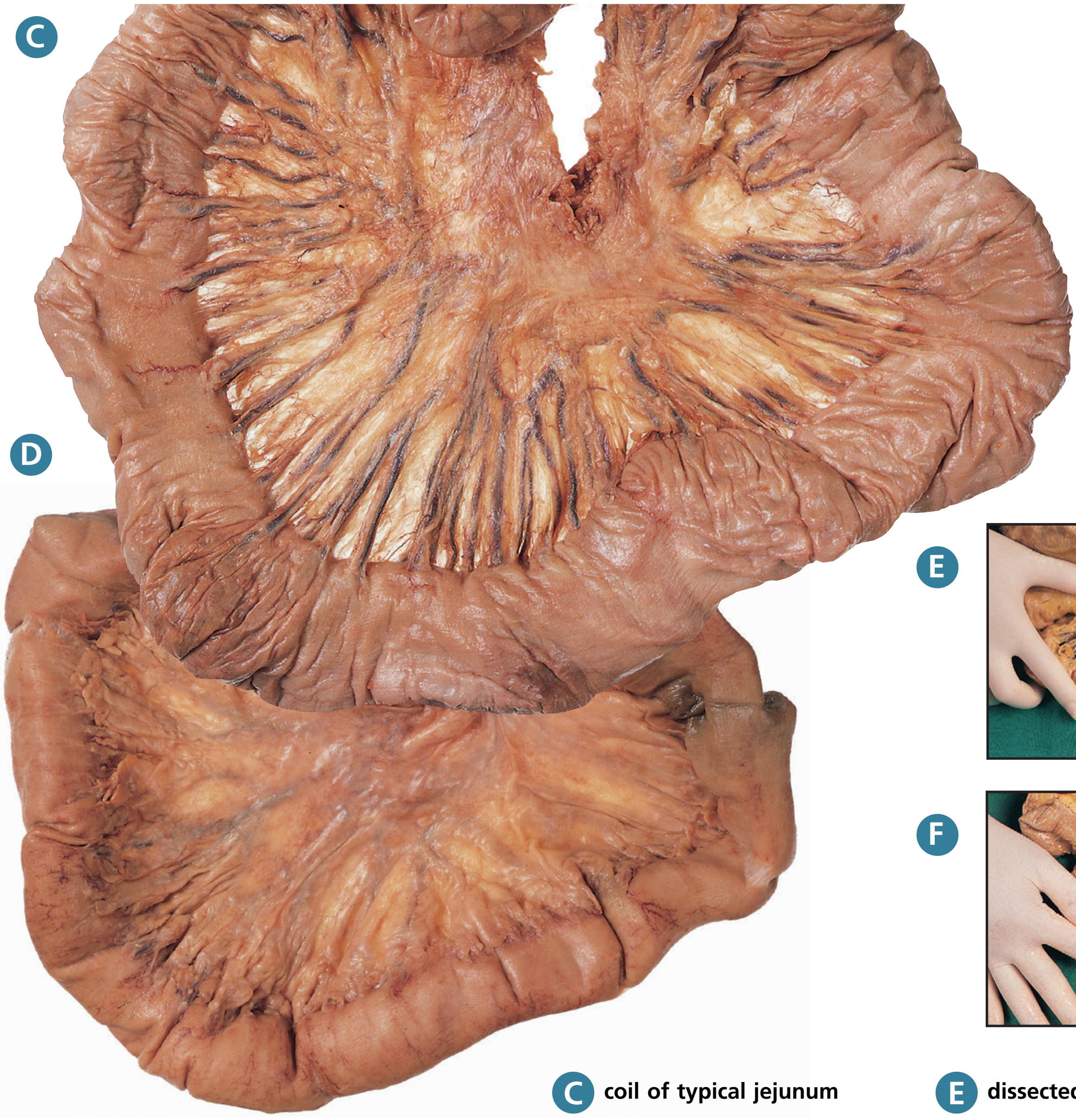

E

F

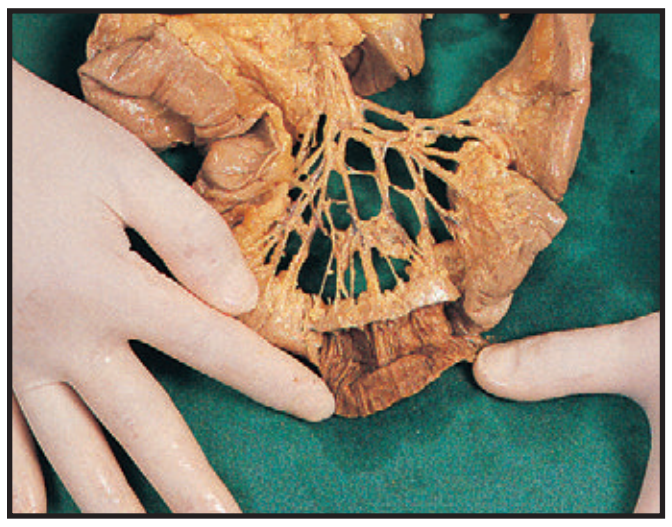

C coil of typical jejunum

D coil of typical ileum

E dissected jejunal vessels

F dissected ileal vessels

In the part of the mesentery supporting the jejunum in C, the vessels anastomose to form one or perhaps two vascular arcades (E) which give off long straight branches that run to the intestinal wall. The fat in the mesentery tends to be concentrated near the root, leaving areas or 'windows' near the gut wall that are devoid of fat. In the mesentery supporting the ileum in D, the vessels form several arcades with shorter branches (F), and there are no fat-free areas. The jejunal wall (C) is thicker than that of the ileum (D) and has a larger lumen. The jejunum also feels thicker, because the folds of its mucous membrane are more numerous than in the ileum.

Laparoscopic view of small intestine

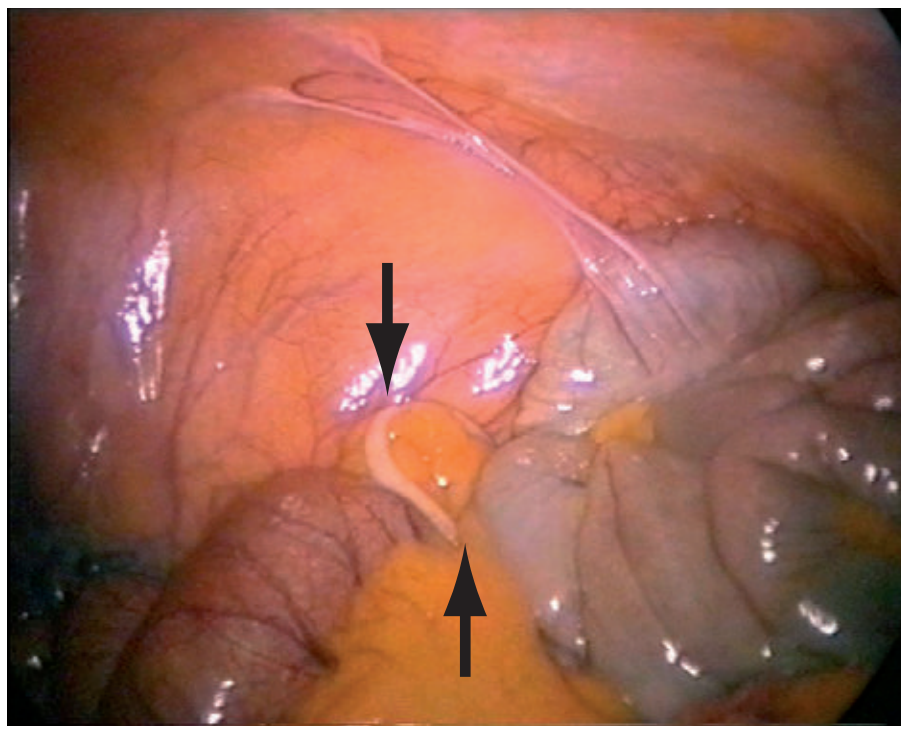

Laparoscopic view of appendix

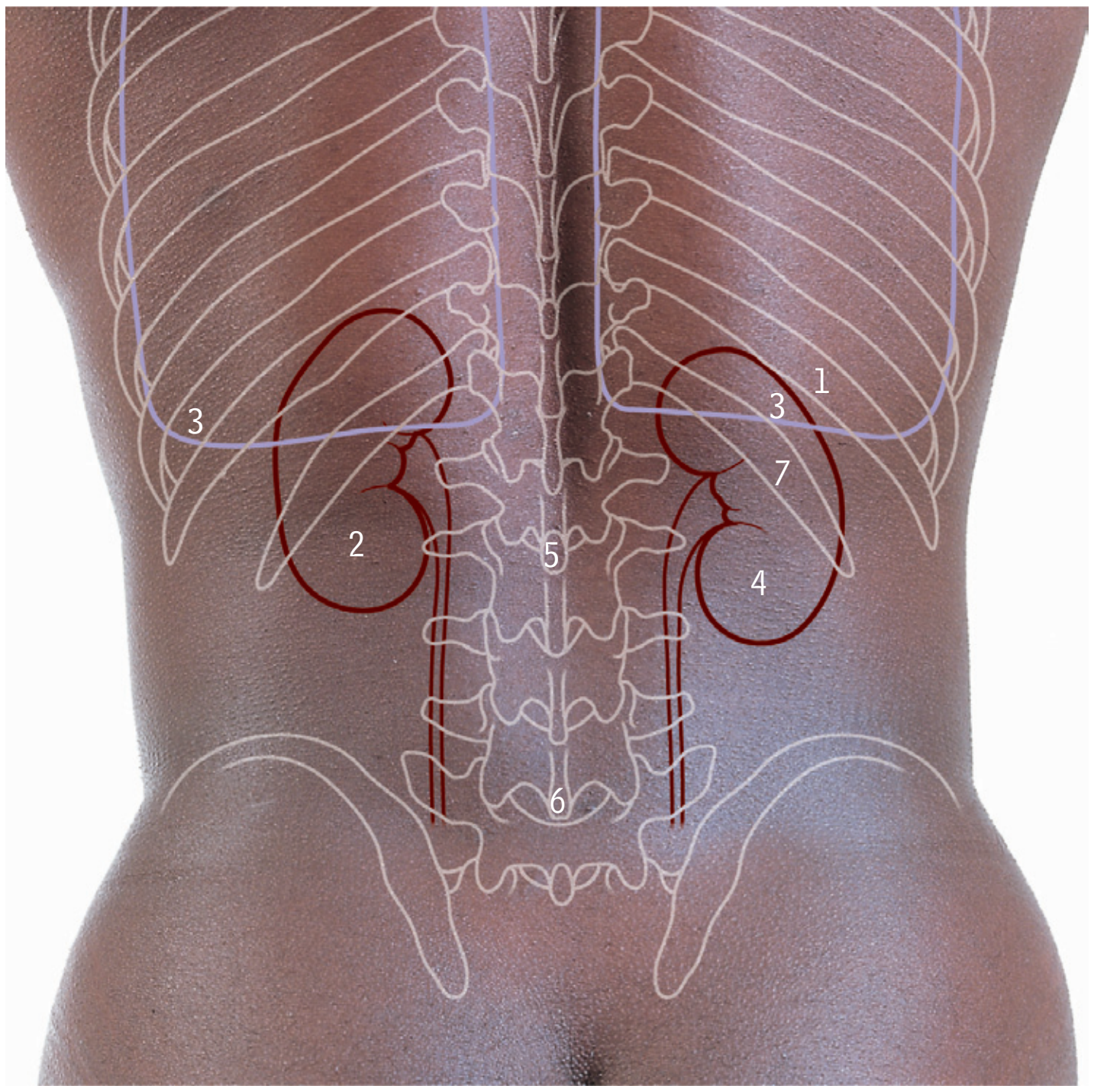

A Kidneys and ureters *surface markings, from behind*

The upper pole of the left kidney rises to the level of the eleventh rib, but the right kidney is slightly lower (due to the bulk of the liver on the right). The hilum of each kidney is 5 cm (2 in) from the midline. The lower edge of the costodiaphragmatic recess of the pleura crosses the twelfth rib; compare with the dissection below (B6).

1 Eleventh rib
2 Left kidney
3 Lower edge of pleura
4 Right kidney
5 Spinous process of first lumbar vertebra
6 Spinous process of fourth lumbar vertebra
7 Twelfth rib

B Right kidney *from behind*

Most thoracic and abdominal muscles have been removed to show the three nerves (9, 3 and 4) that lie behind the kidney (5). Much more important is the relationship of the upper part of the kidney to the pleura. A window has been cut in the parietal pleura above the twelfth rib (12) to open into the costodiaphragmatic recess (1), whose lower limit (6) runs transversely behind the kidney and in front of the obliquely placed twelfth rib.

1 Costodiaphragmatic recess of pleura
2 Extraperitoneal tissue
3 Iliohypogastric nerve
4 Ilio-inguinal nerve
5 Kidney
6 Lower edge of pleura
7 Psoas major
8 Subcostal artery
9 Subcostal nerve
10 Subcostal vein
11 Transverse process of second lumbar vertebra
12 Twelfth rib

Lumbar hernia, renal biopsy, see pages 280–284.

C Left kidney, suprarenal gland and related vessels *from the front*

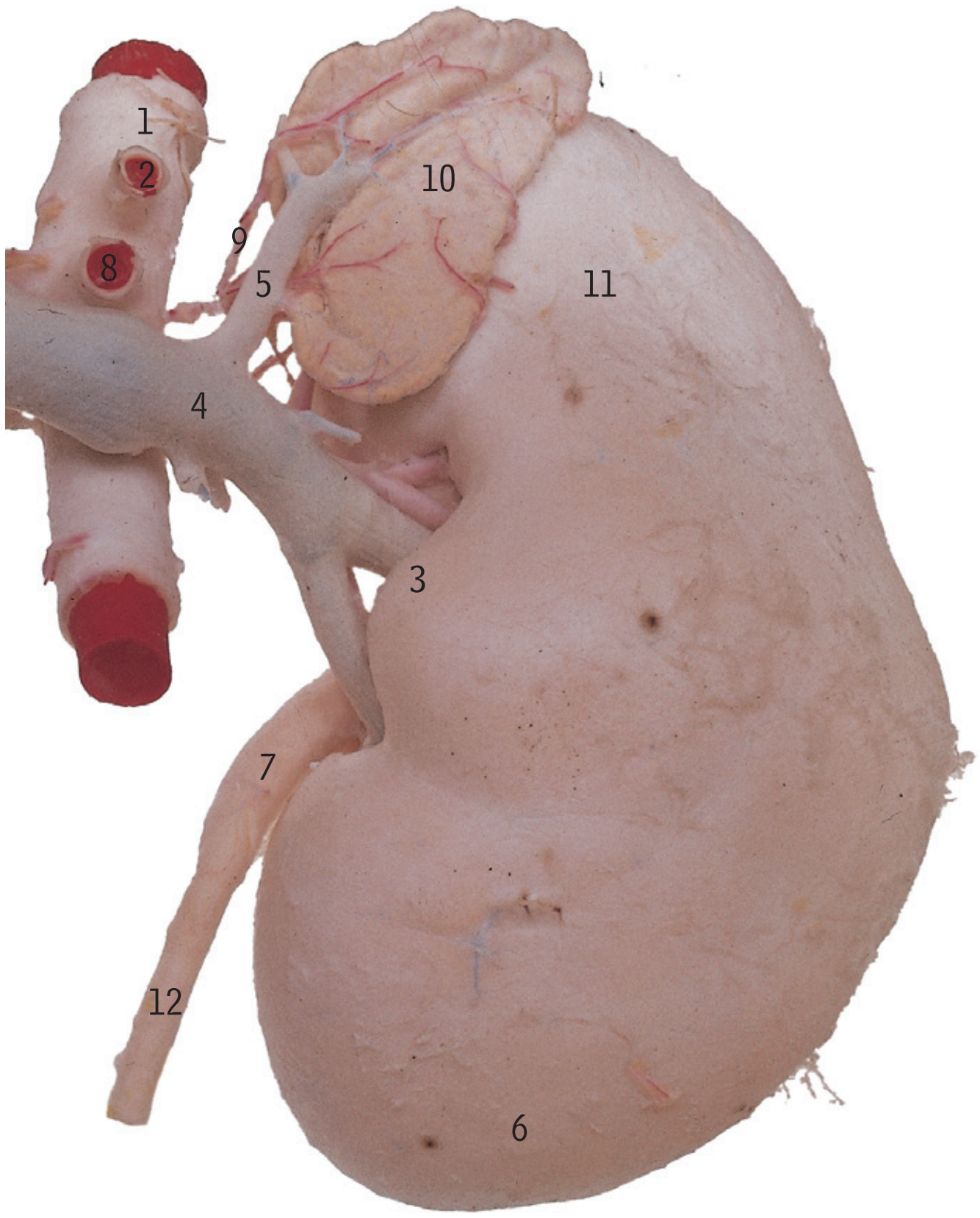

The vessels have been distended by injection of resin, and all fascia has been removed, but the suprarenal gland (10) has been retained in its normal position, lying against the medial side of the upper pole of the kidney (11).

1 Abdominal aorta
2 Coeliac trunk
3 Hilum of kidney
4 Left renal vein overlying renal artery
5 Left suprarenal vein
6 Lower pole of kidney
7 Pelvis of kidney
8 Superior mesenteric artery
9 Suprarenal arteries
10 Suprarenal gland
11 Upper pole of kidney
12 Ureter

D Right kidney, suprarenal gland and related vessels *from behind*

Similar to B, but note that this is the right kidney from behind, not the left; the hilum of each kidney faces medially.

1 Hilum of kidney
2 Inferior vena cava
3 Lower pole of kidney
4 Pelvis of kidney
5 Right inferior phrenic artery
6 Right renal artery
7 Suprarenal arteries
8 Suprarenal gland
9 Upper pole of kidney
10 Ureter

Adrenal gland pathology, see pages 280–284.

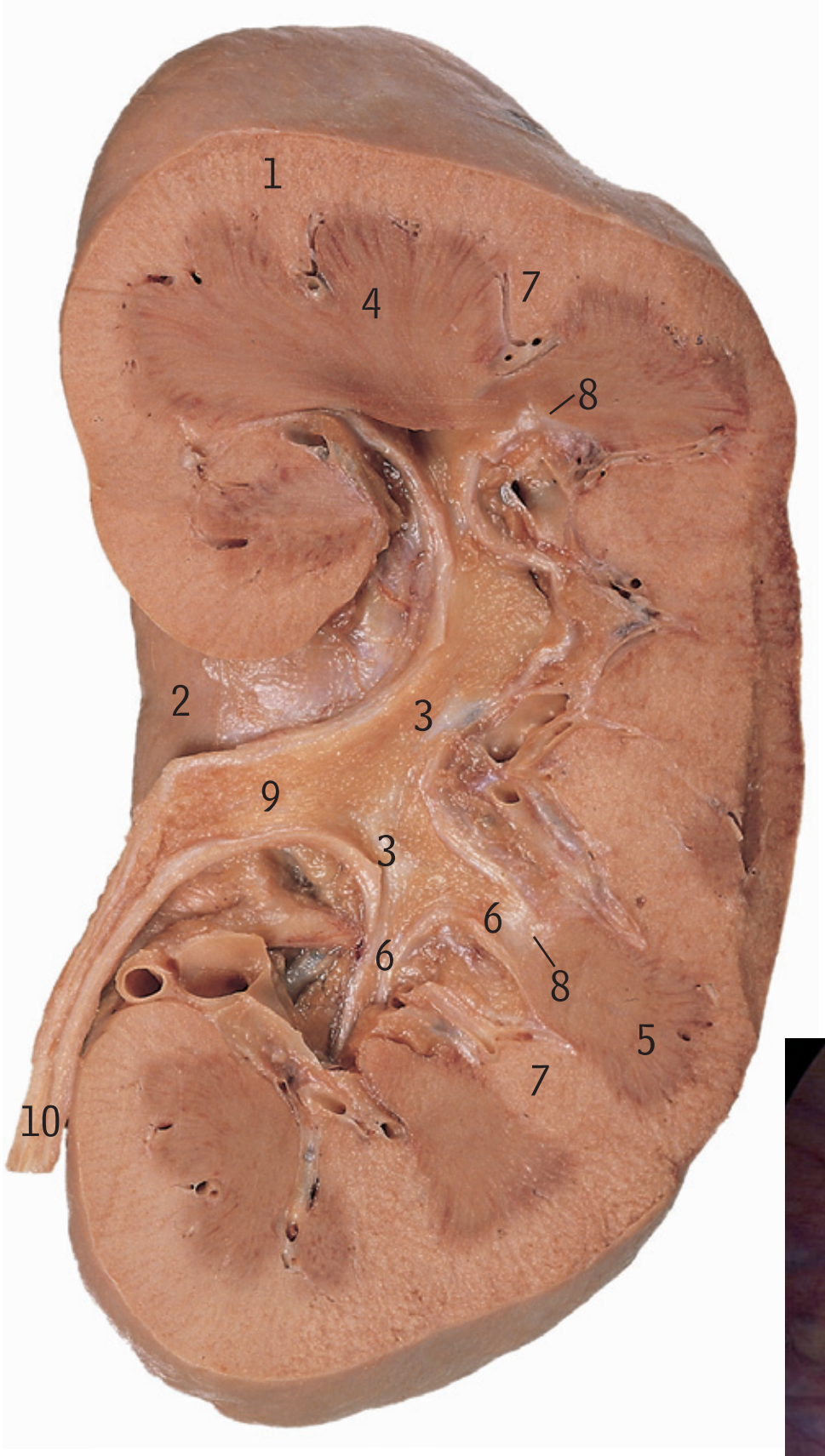

A Kidney *internal structure in longitudinal section*

The section is through the centre of the kidney and has included the renal pelvis (9) and beginning of the ureter (10). The major vessels in the hilum (2) have been removed.

1 Cortex
2 Hilum
3 Major calix
4 Medulla
5 Medullary pyramid
6 Minor calix
7 Renal column
8 Renal papilla
9 Renal pelvis
10 Ureter

The two or three major calices (3) unite to form the renal pelvis (9) which passes out through the hilum (2) to become the ureter (10), often with a slight narrowing at the junction. This is known as the pelvi-ureteric junction (PUJ) and is a site of renal stone obstruction.

Laparoscopic view of right kidney (NB peritoneal covering)

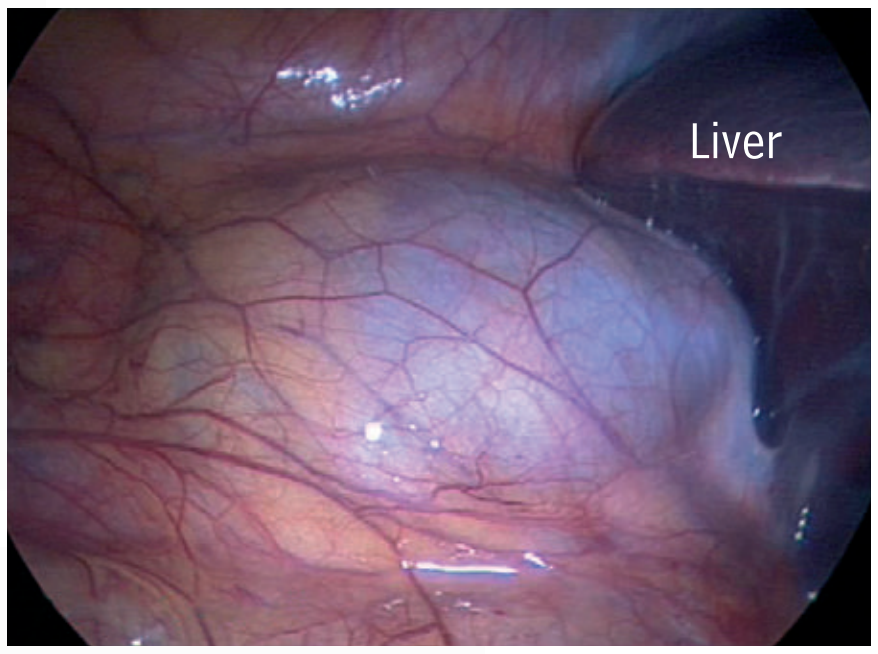

B Cast of the right kidney *from the front*

Red, renal artery
Yellow, urinary tract

The posterior division (8) of the renal artery (9) here passes behind the pelvis (7) and upper calix (upper 5), but all other vessels are in front of the urinary tract; hence this is a right kidney seen from the front (vein, artery, ureter from front to back, and the hilum on the medial side – see page 254), not a left kidney from behind.

1 Anterior division of the renal artery
2 Anterior inferior segment artery
3 Anterior superior segment artery (double)
4 Inferior segment artery
5 Major calix
6 Minor calix
7 Pelvis of kidney
8 Posterior division (forming posterior segment artery)
9 Renal artery
10 Superior segment artery
11 Ureter

C Cast of the aorta and kidneys *from the front*

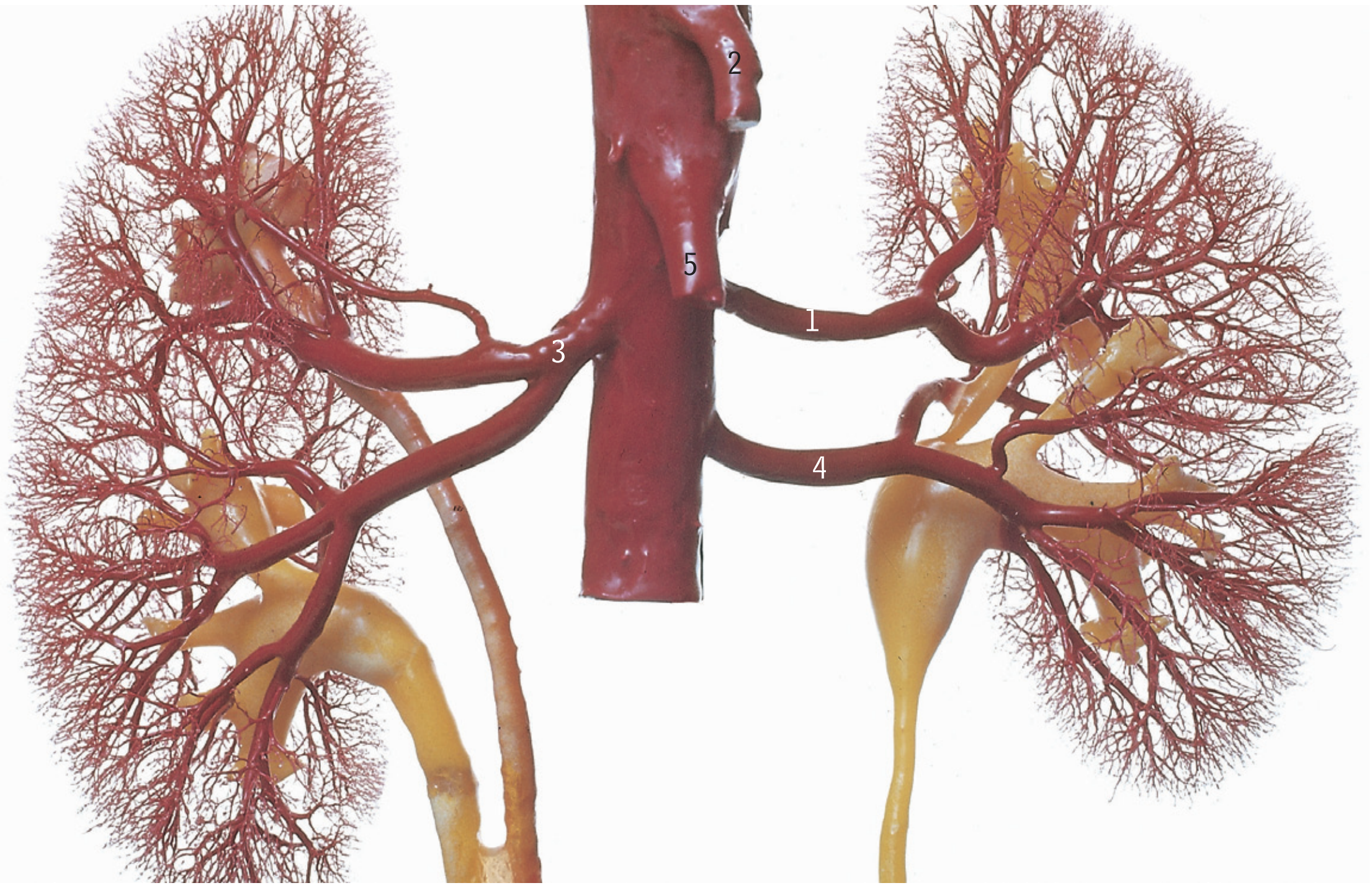

Red, arteries
Yellow, urinary tracts

1. **1** Accessory left renal artery
2. **2** Coeliac trunk
3. **3** Early branching of right renal artery
4. **4** Left renal artery
5. **5** Superior mesenteric artery

Accessory renal arteries represent segmental vessels that arise directly from the aorta. In this specimen, the left accessory vessel (C1) supplies the superior and anterior superior segments, leaving the 'normal' vessel to supply the posterior, anterior inferior and inferior segments.

On the right side, the ureters (unlabelled) are double, each arising from a separate set of calices. On the left, the arteries are double (1 and 4).

D Cast of the kidneys and great vessels *from the front*

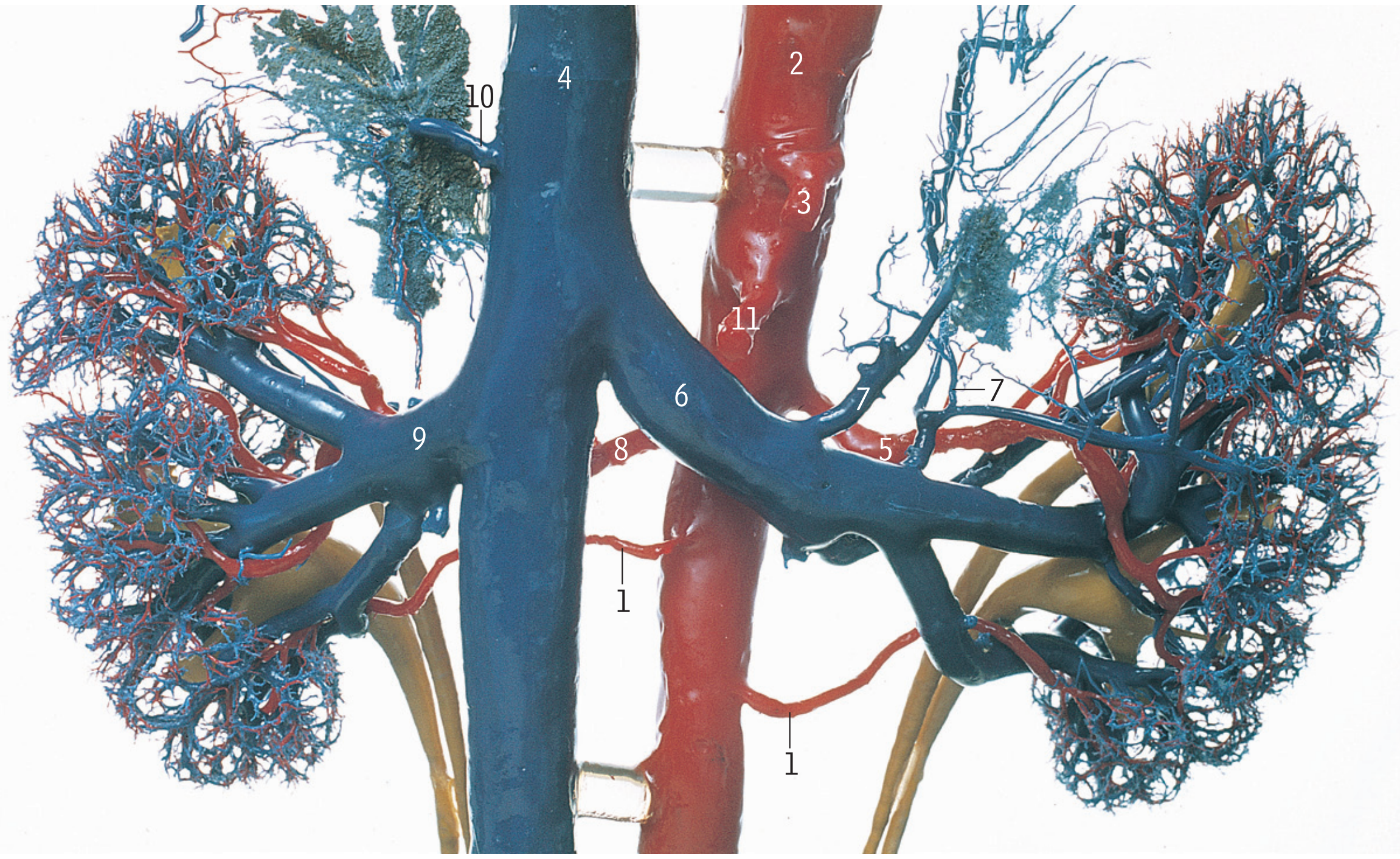

Red, arteries
Blue, veins
Yellow, urinary tracts

- **1** Accessory renal arteries
- **2** Aorta
- **3** Coeliac trunk
- **4** Inferior vena cava
- **5** Left renal artery
- **6** Left renal vein
- **7** Left suprarenal veins
- **8** Right renal artery
- **9** Right renal vein
- **10** Right suprarenal vein
- **11** Superior mesenteric artery

Here both kidneys show double ureters (unlabelled), and there are accessory renal arteries (1) to the lower poles of both kidneys. The suprarenal glands (also unlabelled) are outlined by their venous patterns, and the short right suprarenal vein (10) is shown draining directly to the inferior vena cava (4). On the left, there are two suprarenal veins (7), both draining to the left renal vein (6). See also page 257, A14, A9, A12.

Congenital kidney variants, see pages 280–284.

A Left kidney and suprarenal gland *from the front*

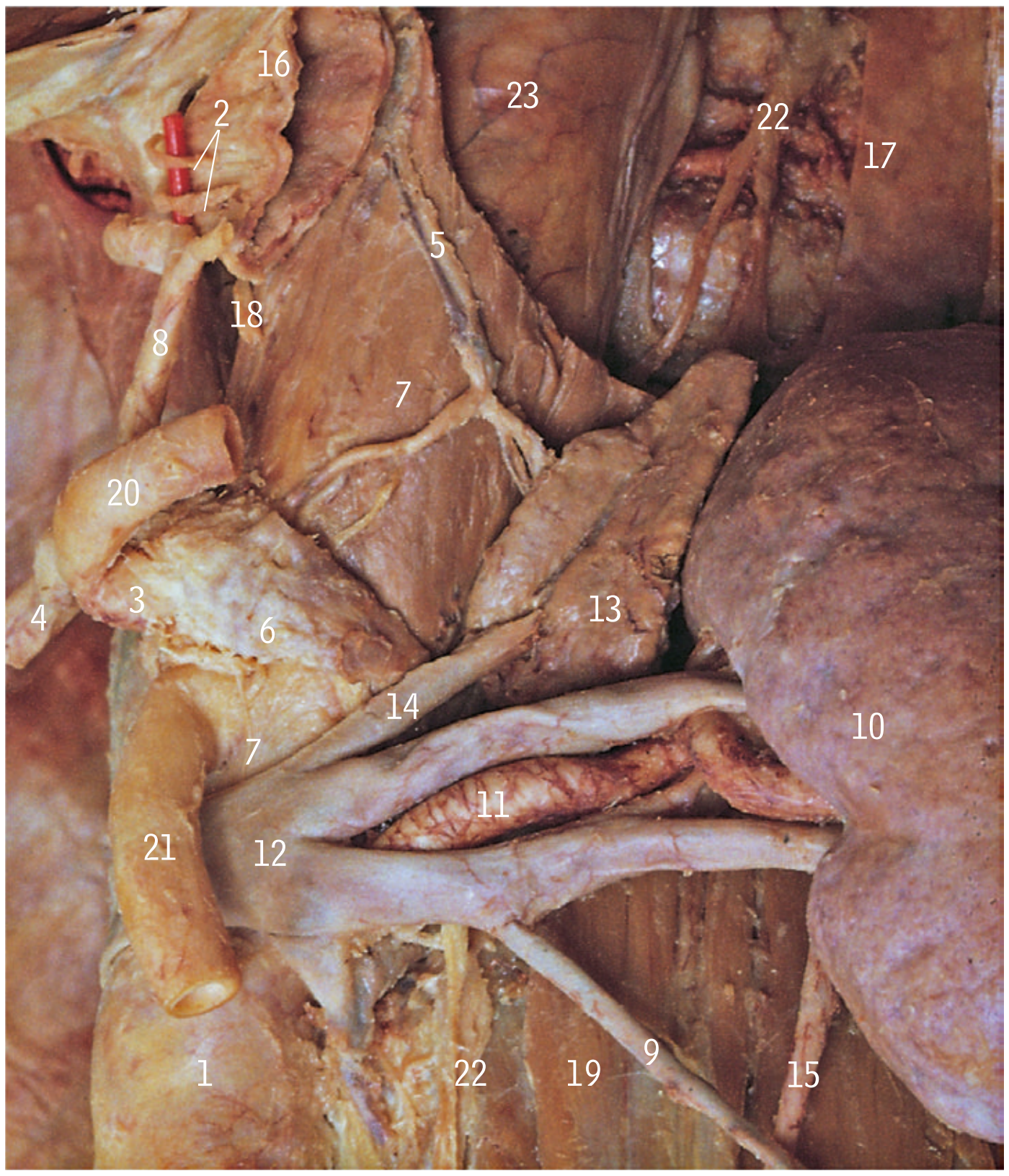

The left kidney (10) and suprarenal gland (13) are seen on the posterior abdominal wall. Much of the diaphragm has been removed but the oesophageal opening remains, with the end of the oesophagus (16) opening out into the cardiac part of the stomach and a (double) anterior vagal trunk (2) overlying the red marker. The posterior vagal trunk (18) is behind and to the right of the oesophagus. Part of the pleura has been cut away (17) to show the sympathetic trunk (22) on the side of the lower thoracic vertebrae. The left coeliac ganglion and the coeliac plexus (6) are at the root of the coeliac trunk (3).

1 Abdominal aorta
2 Anterior vagal trunk (double, over marker)
3 Coeliac trunk
4 Common hepatic artery
5 Inferior phrenic vessels
6 Left coeliac ganglion and coeliac plexus
7 Left crus of diaphragm
8 Left gastric artery
9 Left gonadal vein
10 Left kidney
11 Left renal artery
12 Left renal vein
13 Left suprarenal gland
14 Left suprarenal vein
15 Left ureter
16 Lower end of oesophagus
17 Pleura (cut edge)
18 Posterior vagal trunk
19 Psoas major
20 Splenic artery
21 Superior mesenteric artery
22 Sympathetic trunk
23 Thoracic aorta

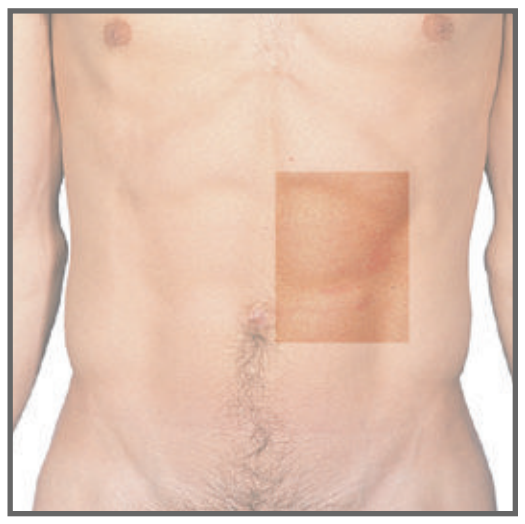

B Right kidney and renal fascia *in transverse section from below*

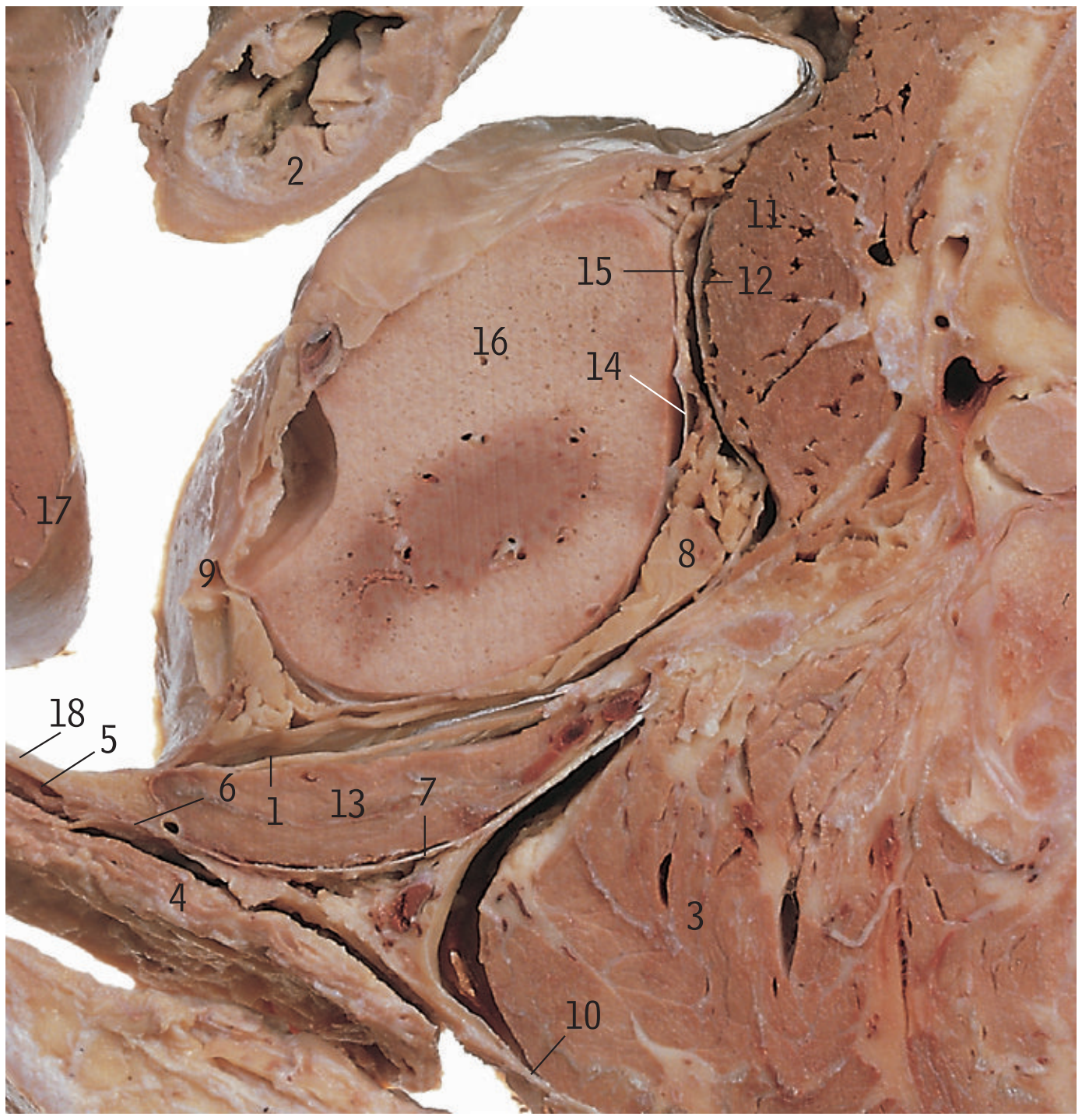

In the transverse section of the lower part of the right kidney (16), seen from below looking towards the thorax, the renal fascia (15) has been dissected out from the perirenal fat (8) and the kidney's own capsule (14). (There was a small cyst on the surface of this kidney.) The section also displays the three layers (10, 7 and 1) of the lumbar fascia (6).

1 Anterior layer of lumbar fascia
2 Coil of small intestine
3 Erector spinae
4 External oblique
5 Internal oblique
6 Lumbar fascia
7 Middle layer of lumbar fascia
8 Perirenal fat
9 Peritoneum
10 Posterior layer of lumbar fascia
11 Psoas major
12 Psoas sheath
13 Quadratus lumborum
14 Renal capsule
15 Renal fascia
16 Right kidney
17 Right lobe of liver
18 Transversus abdominis

Outside the kidney's own capsule (renal capsule, 14), there is a variable amount of fat (perirenal fat, 8) and outside this is a condensation of connective tissue forming the renal fascia (15).

Haemoperitoneum, nephrectomy, pneumoretroperitoneum, superior mesenteric artery syndrome, see pages 280–284.

Kidneys and suprarenal glands

A *dissection* B *right kidney and suprarenal gland, laparoscopic view*

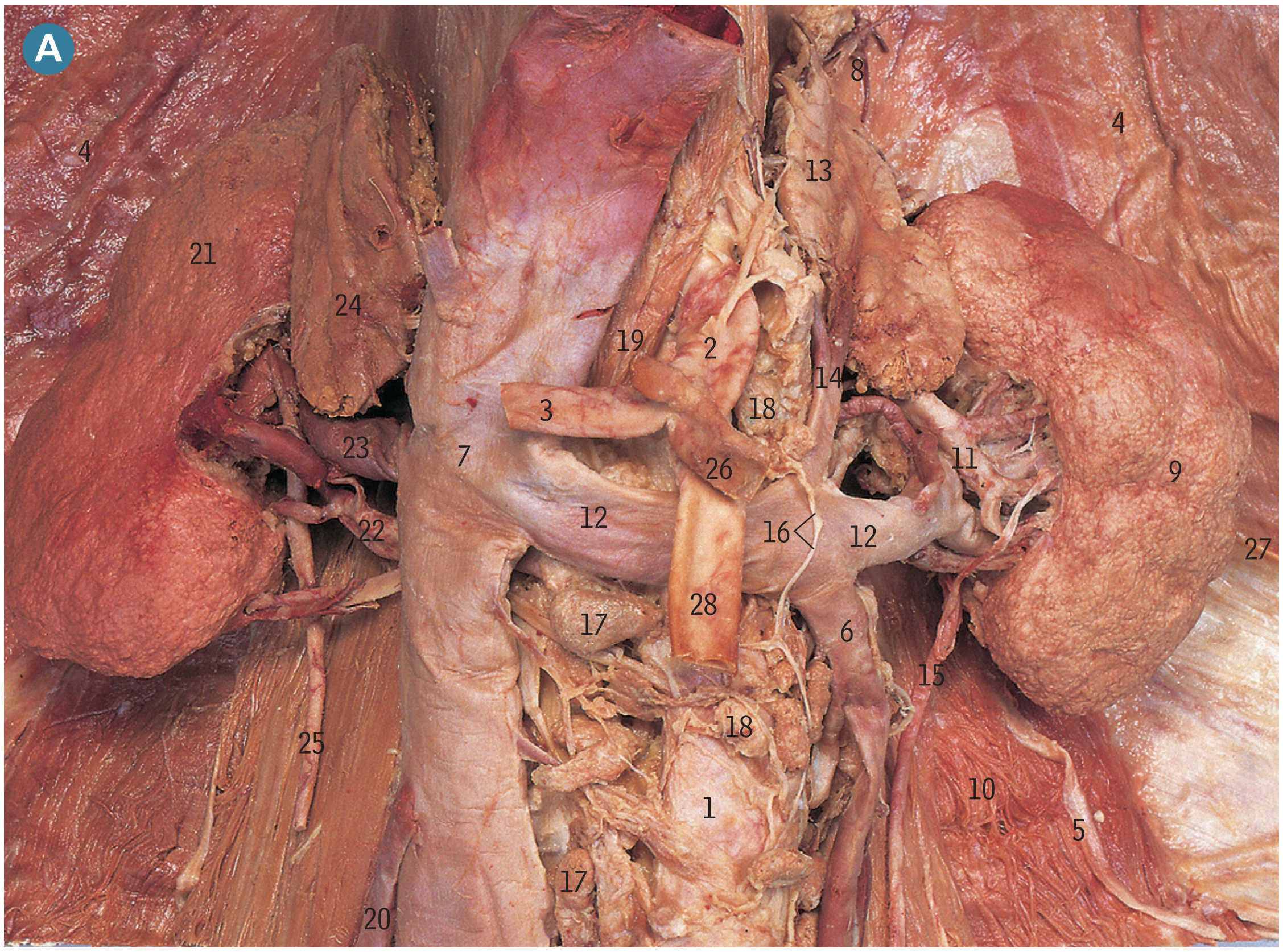

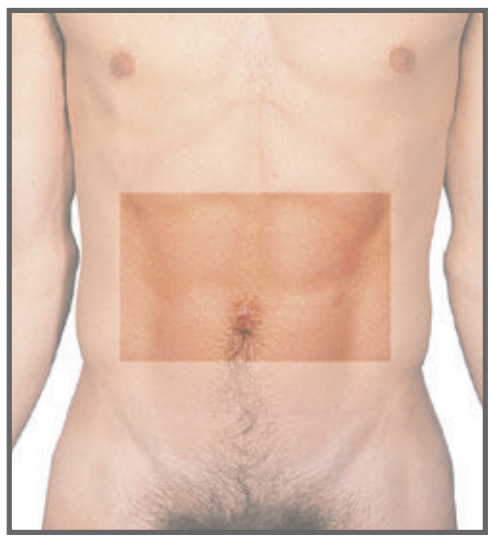

The kidneys (9 and 21) and suprarenal glands (13 and 24) are displayed on the posterior abdominal wall after the removal of all other viscera. The left renal vein (12) receives the left suprarenal (14) and gonadal (6) veins and then passes over the aorta (1) and deep to the superior mesenteric artery (28) to reach the inferior vena cava (7). In the hilum of the right kidney (21) a large branch of the renal artery (22) passes in front of the renal vein (23). The origins of the renal arteries from the aorta are not seen because they underlie the left renal vein (12) and inferior vena cava (7).

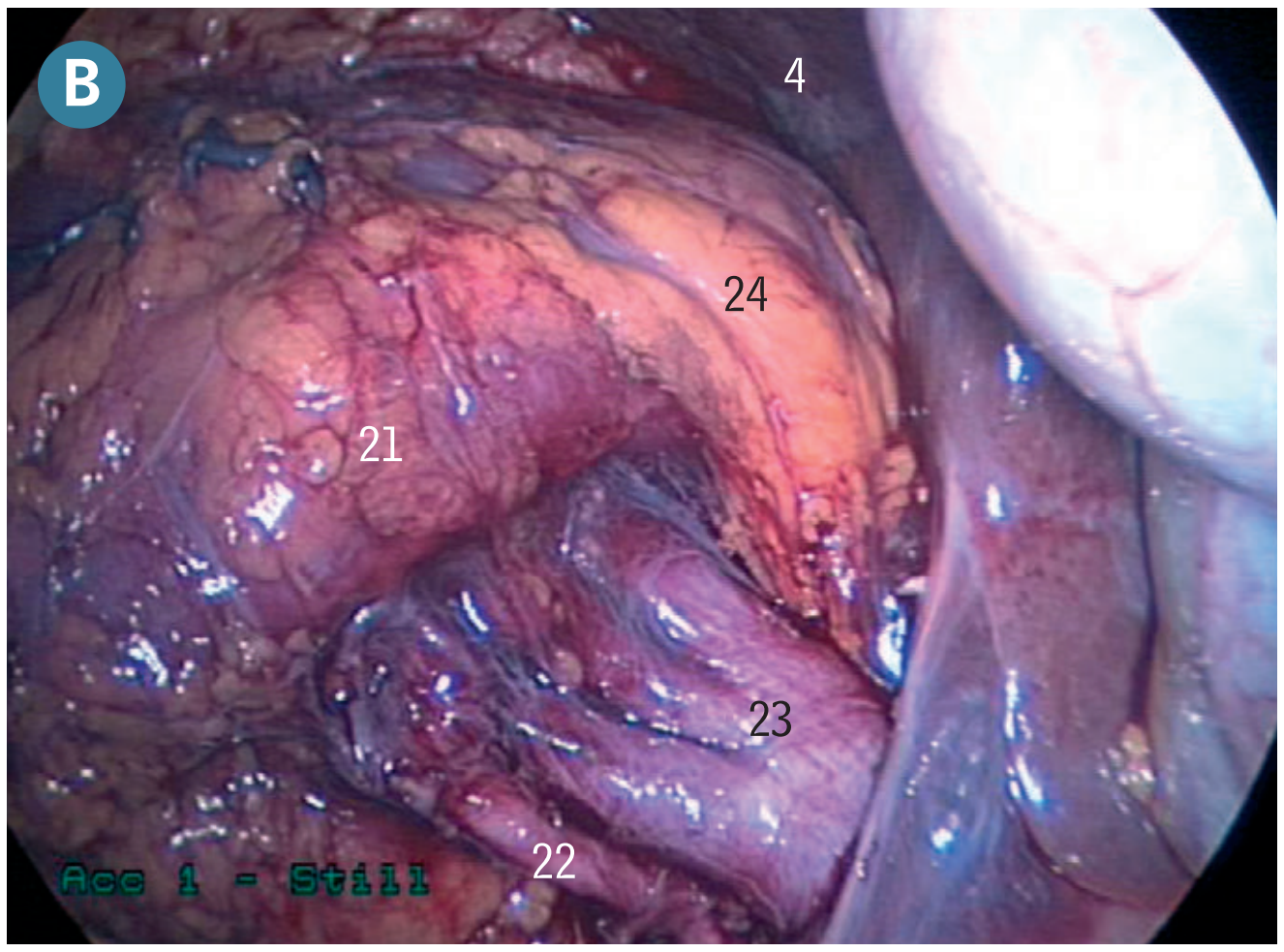

1 Abdominal aorta and aortic plexus
2 Coeliac trunk
3 Common hepatic artery
4 Diaphragm
5 First lumbar spinal nerve
6 Gonadal vein, left
7 Inferior vena cava
8 Left inferior phrenic vessels
9 Left kidney
10 Left psoas major
11 Left renal artery
12 Left renal vein
13 Left suprarenal gland
14 Left suprarenal vein
15 Left ureter
16 Lymphatic vessels
17 Para-aortic lymph nodes
18 Pre-aortic lymph nodes
19 Right crus of diaphragm
20 Right gonadal vein
21 Right kidney
22 Right renal artery
23 Right renal vein
24 Right suprarenal gland
25 Right ureter
26 Splenic artery
27 Subcostal nerve, left
28 Superior mesenteric artery

Aortic bruits, IVC duplication, renal carcinoma, retroperitoneal fibrosis, see pages 280–284.

C Intravenous urogram *IVU – 3D CT reconstruction*

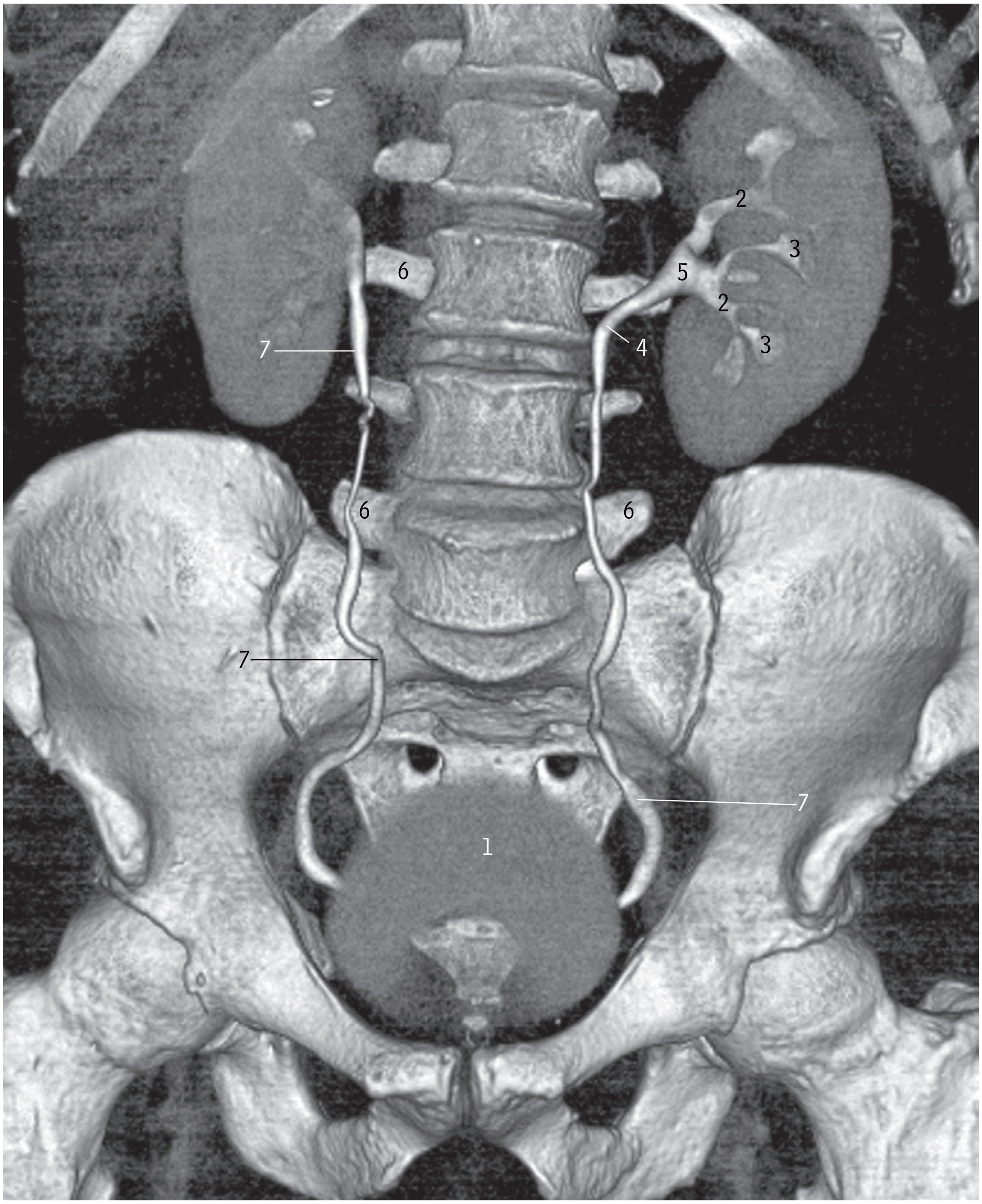

Contrast medium injected intravenously is excreted by the kidneys to outline the calices (3 and 2), renal pelvis (5) and the ureters (7) which enter the bladder (1) in the pelvis.

1 Bladder
2 Major calix
3 Minor calix
4 Pelvic-ureteric junction
5 Renal pelvis
6 Transverse processes of lumbar vertebrae
7 Ureter

The ureters normally lie near the tips of the transverse processes of the lumbar vertebrae and may kink over the psoas when the muscle is hypertrophied (e.g., in rowers and professional cyclists).

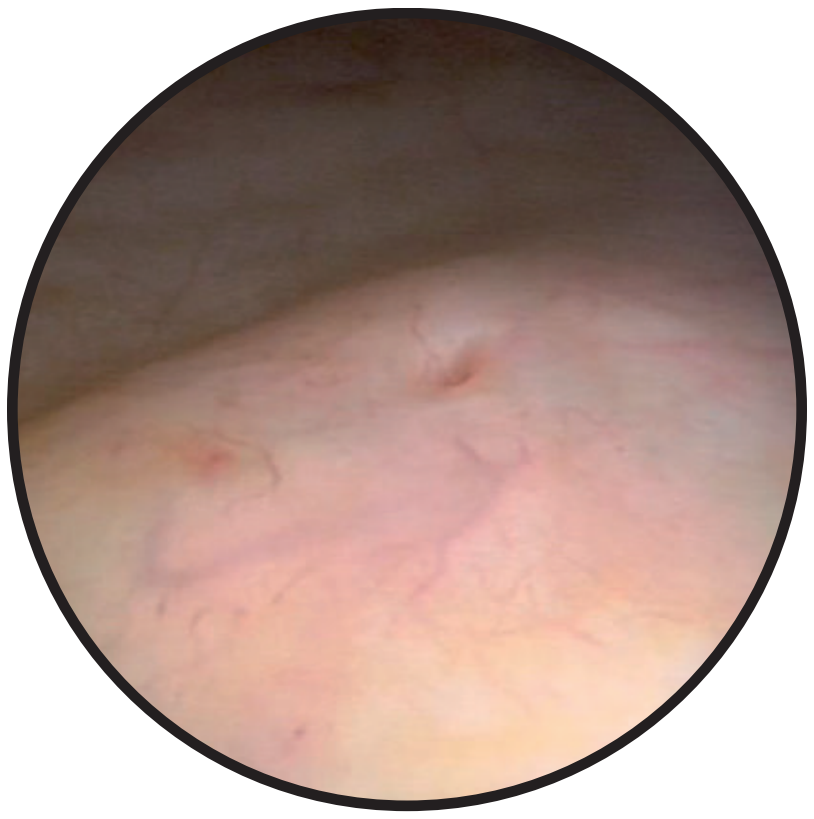

Cytoscopic view of the ureteric orifice

Abdominal aortic aneurysm, renal trauma, uretocele, urinary tract calculi, see pages 280–284.

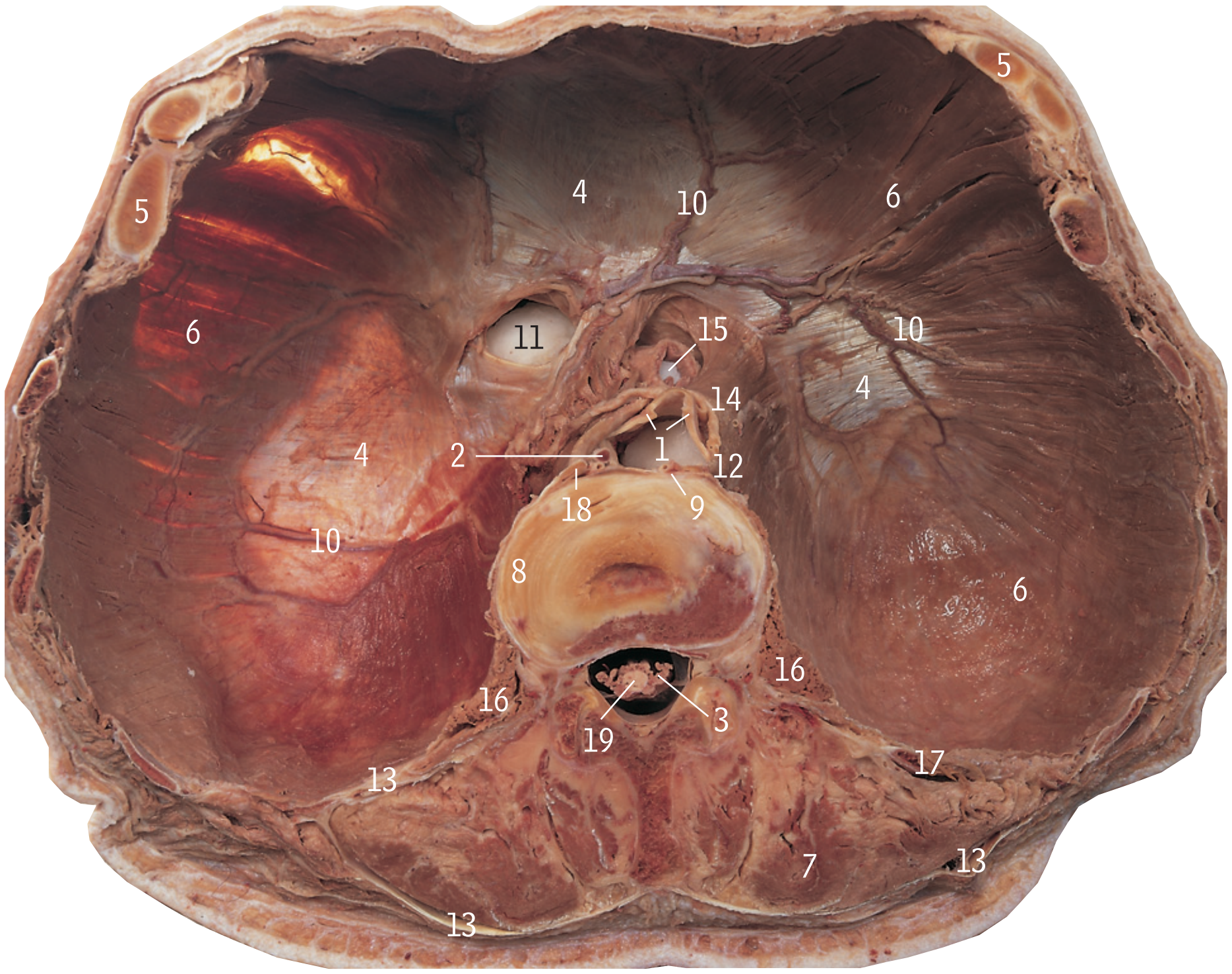

A Diaphragm *from below*

1 Aorta
2 Azygos vein
3 Cauda equina
4 Central tendon of diaphragm
5 Costal margin
6 Diaphragm
7 Erector spinae muscles
8 First lumbar intervertebral disc
9 Hemi-azygos vein
10 Inferior phrenic vessels
11 Inferior vena caval opening
12 Left crus
13 Lumbar fascia
14 Median arcuate ligament
15 Oesophageal opening (hiatus)
16 Psoas major
17 Quadratus lumborum
18 Right crus
19 Spinal cord

Fibres of the right crus (A18) form the right and left boundaries of the oesophageal opening or hiatus (A15).

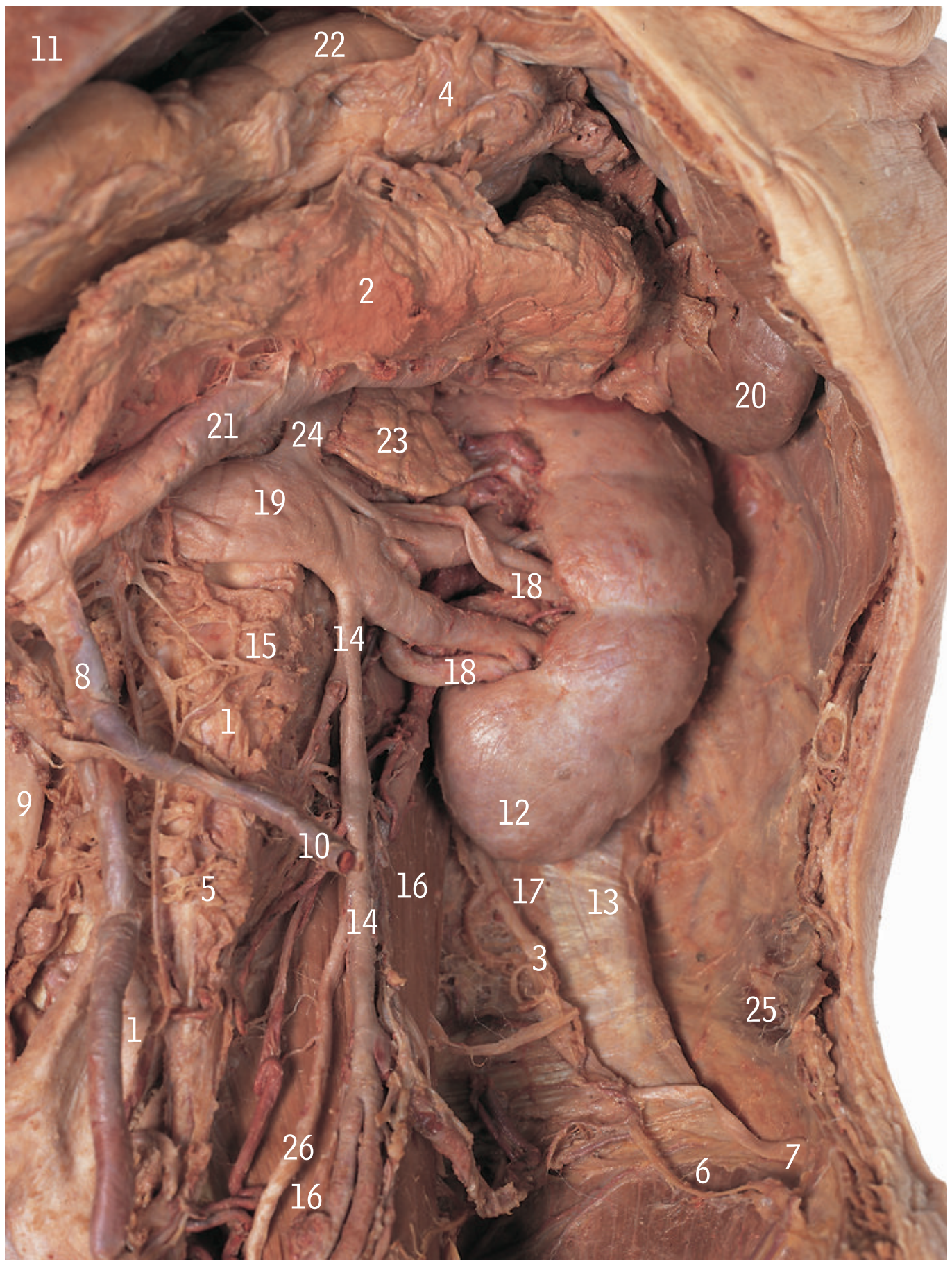

B Posterior abdominal wall *left side*

The structures on the posterior abdominal wall are here viewed from the front. The body of the pancreas (2) has been turned upwards to expose the splenic vein (21). The suprarenal gland (23) appears detached from the superior pole of the kidney (compared with A13 and 10, page 256).

1 Aorta and aortic plexus
2 Body of pancreas
3 First lumbar spinal nerve
4 Greater omentum
5 Hypogastric plexus
6 Ilio-inguinal nerve
7 Iliohypogastric nerve
8 Inferior mesenteric vein
9 Inferior vena cava
10 Left colic vein
11 Liver
12 Lower pole of kidney
13 Lumbar part of thoracolumbar fascia
14 Ovarian vein
15 Para-aortic lymph node
16 Psoas major
17 Quadratus lumborum
18 Renal artery
19 Renal vein
20 Spleen
21 Splenic vein
22 Stomach
23 Suprarenal gland
24 Suprarenal vein
25 Transversus abdominis
26 Ureter

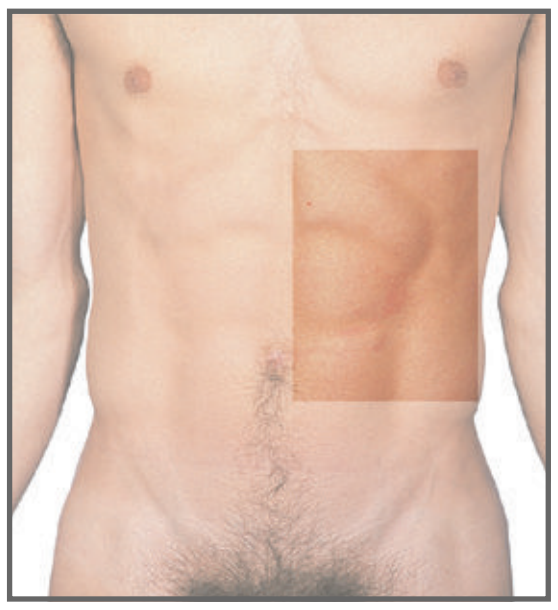

Nephrocalcinosis, retroperitoneal bleed, see pages 280–284.

Posterior abdominal and pelvic walls

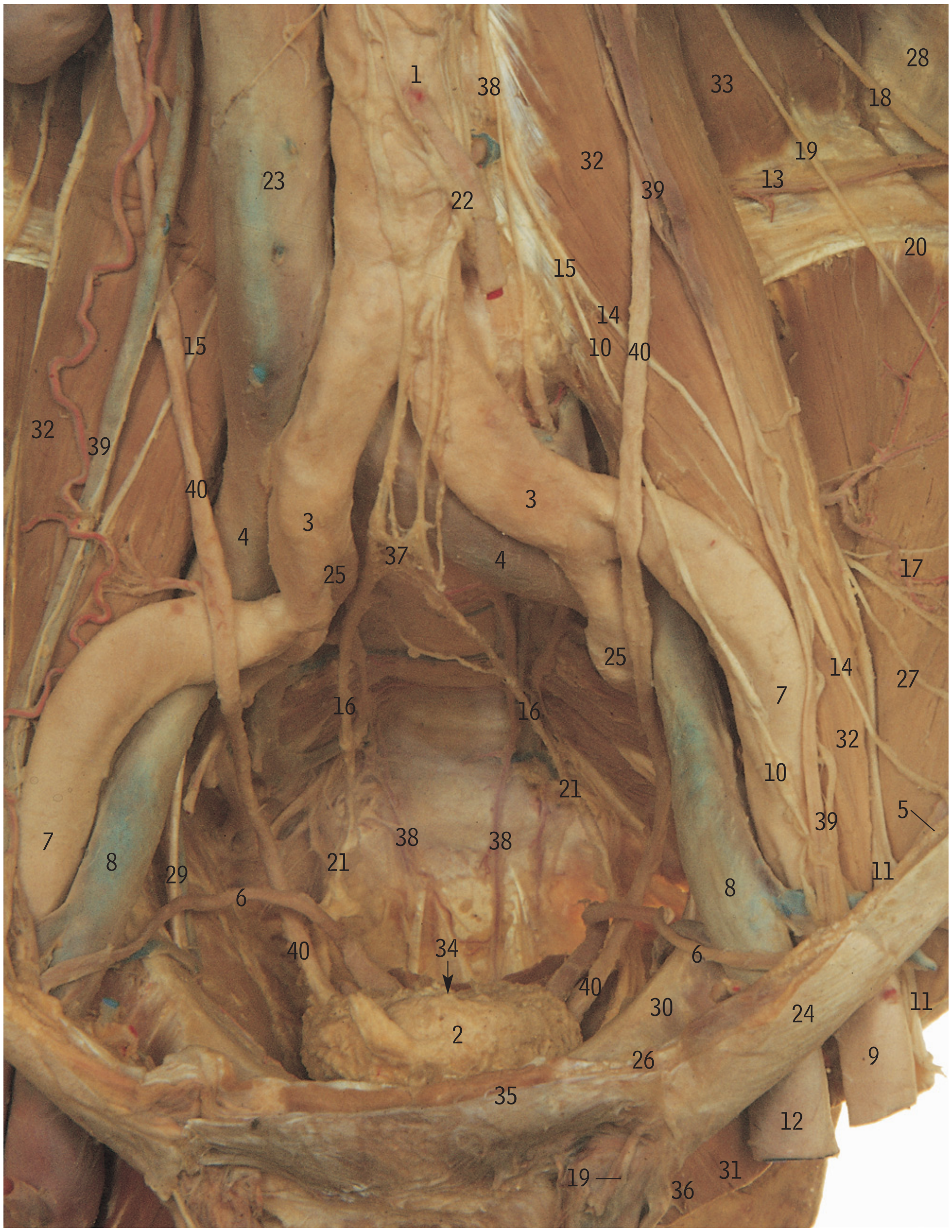

All peritoneum and viscera (except for the bladder, 2, ureter, 40, and ductus deferens or vas deferens, 6) have been removed, to display vessels and nerves.

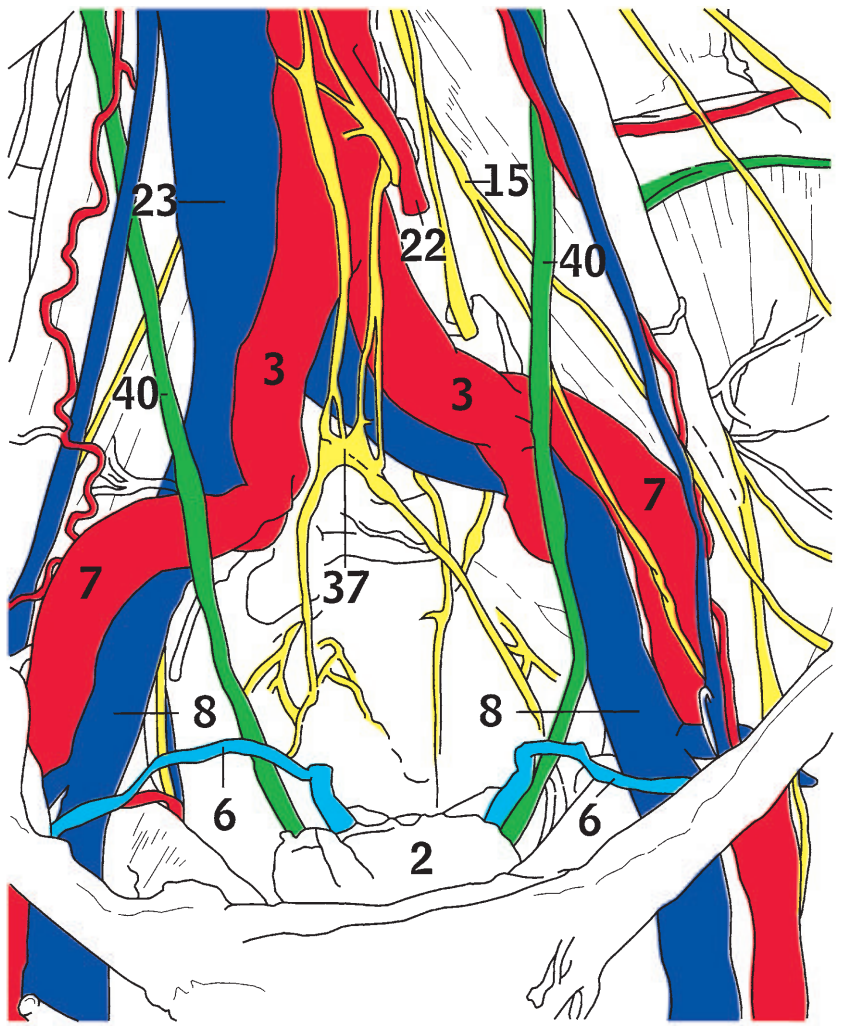

Pelvic arteriogram

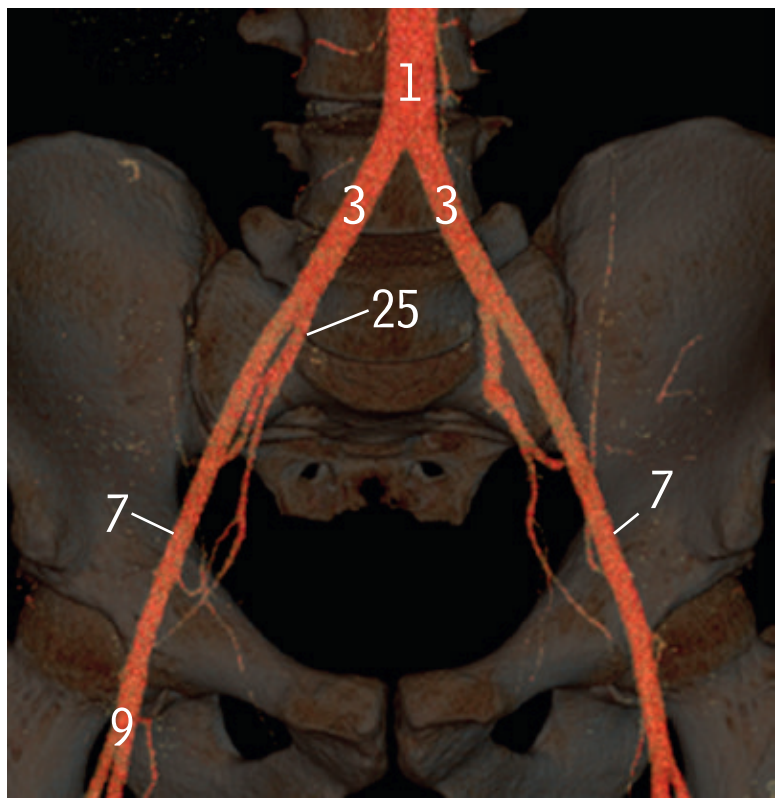

1 Aorta and aortic plexus
2 Bladder
3 Common iliac artery
4 Common iliac vein
5 Deep circumflex iliac artery
6 Ductus deferens
7 External iliac artery
8 External iliac vein
9 Femoral artery
10 Femoral branch of genitofemoral nerve
11 Femoral nerve
12 Femoral vein
13 Fourth lumbar artery
14 Genital branch of genitofemoral nerve
15 Genitofemoral nerve
16 Hypogastric nerve
17 Iliacus and branches from femoral nerve and iliolumbar artery
18 Iliohypogastric nerve
19 Ilio-inguinal nerve
20 Iliolumbar ligament
21 Inferior hypogastric (pelvic) plexus and pelvic splanchnic nerves
22 Inferior mesenteric artery and plexus
23 Inferior vena cava
24 Inguinal ligament
25 Internal iliac artery
26 Lacunar ligament
27 Lateral femoral cutaneous nerve arising from femoral nerve
28 Lumbar part of thoracolumbar fascia
29 Obturator nerve and vessels
30 Pectineal ligament
31 Position of femoral canal
32 Psoas major
33 Quadratus lumborum
34 Rectum (cut edge)
35 Rectus abdominis
36 Spermatic cord
37 Superior hypogastric plexus
38 Sympathetic trunk and ganglia
39 Testicular vessels
40 Ureter

Psoas abscess, see pages 280–284.

Left lumbar plexus *from the front*

The psoas major has been removed to show the constituent nerves of the lumbar plexus which are embedded within the muscle. Because of the removal of most of the anterolateral abdominal wall (except for the lowest parts of the external oblique, 1, internal oblique, 9, and transversus, 18), the iliohypogastric (6) and ilio-inguinal (7) nerves have fallen too far medially; they do not overlie iliacus (5).

1 External oblique
2 External oblique aponeurosis
3 Femoral nerve
4 Genitofemoral nerve
5 Iliacus
6 Iliohypogastric nerve
7 Ilio-inguinal nerve
8 Iliolumbar ligament
9 Internal oblique
10 Lateral femoral cutaneous nerve
11 Lumbosacral trunk
12 Obturator nerve
13 Quadratus lumborum
14 Rami communicantes
15 Superficial inguinal ring
16 Sympathetic trunk and ganglia
17 Third lumbar vertebra and anterior longitudinal ligament
18 Transversus abdominis
19 Upper surface of inguinal ligament
20 Ventral ramus of fifth lumbar nerve
21 Ventral ramus of first sacral nerve
22 Ventral ramus of fourth lumbar nerve

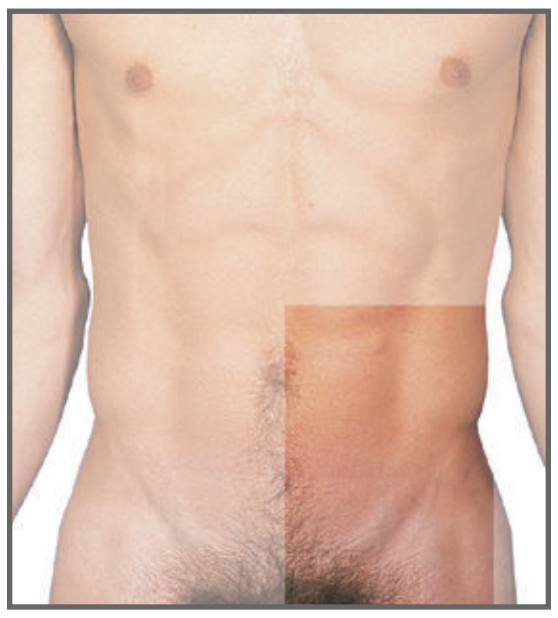

Lumbar sympathectomy, see pages 280–284.

A Muscles of the left pelvis and proximal thigh
slightly oblique anterior view

The anterior abdominal wall, most viscera and fasciae have been removed. Segments of the external iliac/femoral vessels and the inferior margin of the external oblique aponeurosis (inguinal ligament) have been retained to assist orientation.

1 Adductor brevis
2 Adductor longus
3 Anterior superior iliac spine
4 Coccygeus
5 Disc, fifth lumbar
6 External iliac artery
7 Femoral artery
8 Femoral nerve
9 Femoral vein
10 Gracilis
11 Iliacus
12 Inferior epigastric artery, origin
13 Inguinal ligament
14 Lumbosacral trunk
15 Obturator internus
16 Obturator nerve
17 Pectineus
18 Piriformis
19 Psoas major
20 Rectus femoris
21 Sacral plexus
22 Sartorius
23 Tendinous arch of levator ani
24 Tensor fasciae latae
25 Vastus lateralis

The anterior superior iliac spine (3) and the pubic tubercle, which give attachment to the ends of the inguinal ligament (13), are important palpable landmarks in the inguinal region (see page 224).

The part of obturator internus (15) *above* the attachment of levator ani is part of the lateral wall of the pelvic cavity, while the part *below* the attachment is in the perineum and forms part of the lateral wall of the ischio-anal (ischiorectal) fossa (pages 277 and 279).

Piriformis (18) passes out of the pelvis into the gluteal region through the *greater* sciatic foramen *above* the ischial spine, while obturator internus (15) passes out through the *lesser* sciatic foramen *below* the ischial spine.

Muscles of the left half of the pelvis

B Male pelvis

The fascia overlying the obturator internus (15) has been removed down to the tendinous origin of the levator ani (11 and 20), a urethral catheter (arrow) indicates the position of the sphincter urethrae, and the plane of section passes through the bulbocavernosus (asterisks).

1. Adductor longus
2. Adductor magnus
3. Anterior superior iliac spine
4. Branch of fourth sacral nerve
5. Coccygeus
6. Coccyx
7. Fascia over obturator internus
8. Femoral vein
9. Gracilis
10. Iliacus
11. Iliococcygeus part of levator ani
12. Inguinal ligament
13. Ischial spine
14. Lacunar ligament
15. Obturator internus, pierced by obturator nerve
16. Piriformis
17. Promontory of sacrum
18. Psoas major
19. Pubic symphysis
20. Pubococcygeus part of levator ani
21. Rectum
22. Sacral canal with cyst
23. Sartorius
24. Tendinous arch of levator ani

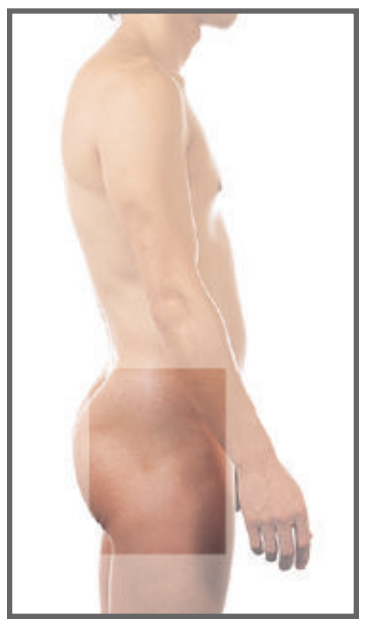

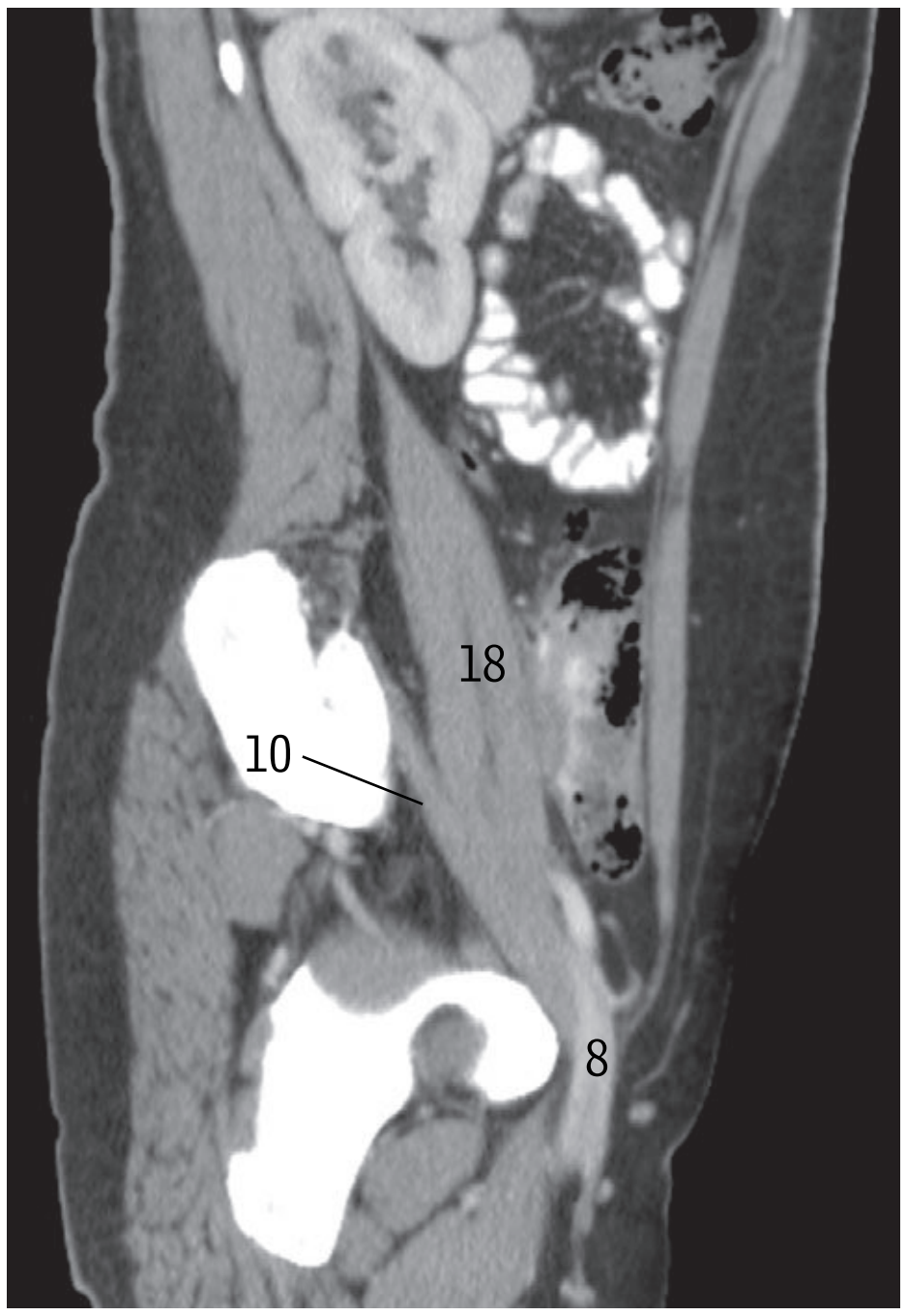

Left parasagittal CT of abdomen and pelvis

Inguinal lymphadenopathy, see pages 280–284.

A Right spermatic cord and testis

B Right testis, epididymis and penis *from the right*

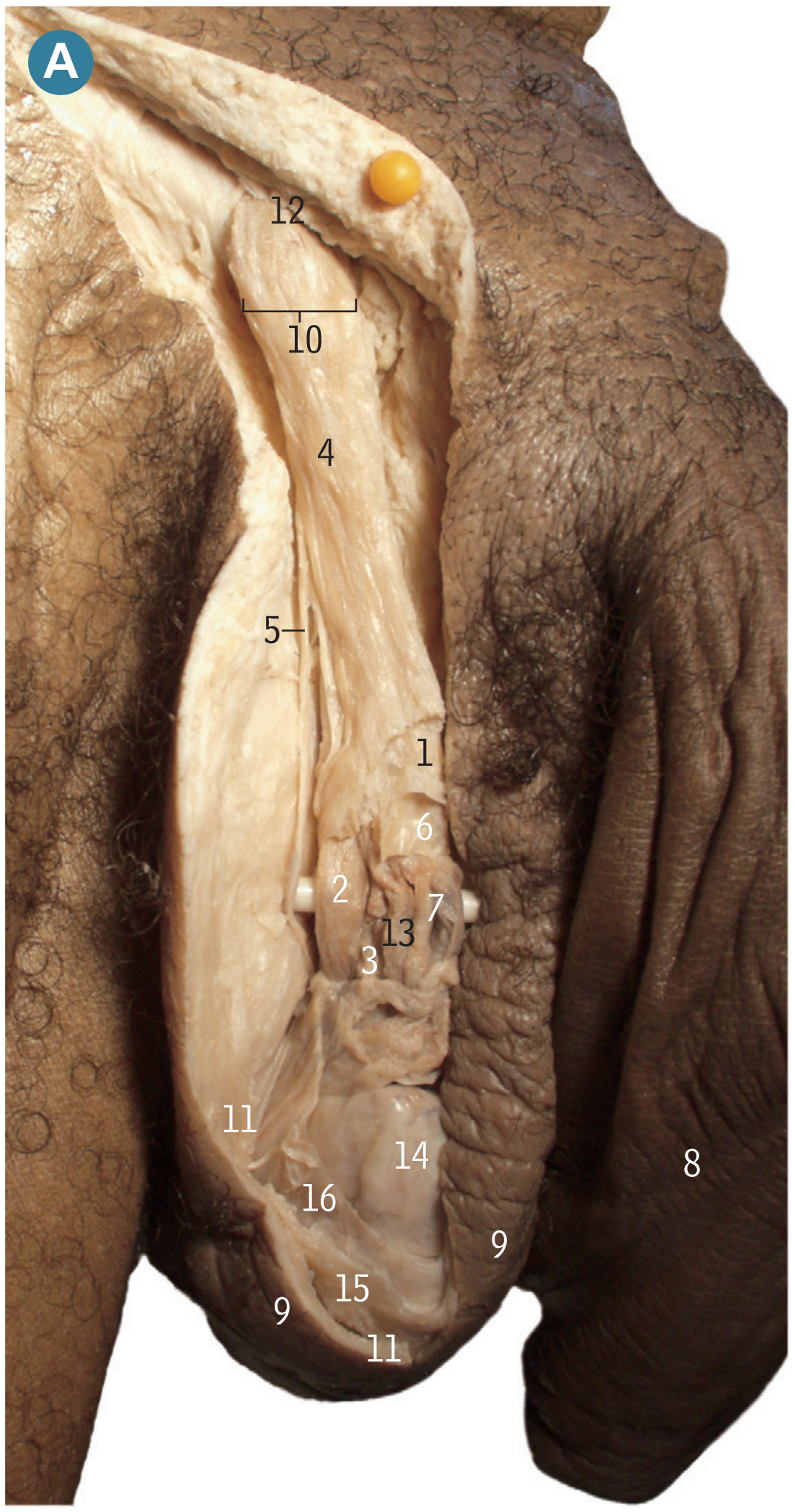

1 Cremasteric fascia
2 Ductus deferens
3 Ductus deferens, artery
4 External spermatic fascia
5 Ilio-inguinal nerve
6 Internal spermatic fascia
7 Pampiniform venous plexus
8 Penis
9 Scrotal sac
10 Spermatic cord
11 Superficial fascia with dartos muscle fibres
12 Superficial inguinal ring
13 Testicular artery
14 Tunica albuginea
15 Tunica vaginalis, parietal layer
16 Tunica vaginalis, visceral layer

1 Appendix epididymis
2 Body of epididymis
3 Body of penis
4 Corona of glans
5 Ductus deferens
6 External urethral orifice
7 Foreskin
8 Glans penis
9 Head of epididymis
10 Lateral superficial vein
11 Pampiniform venous plexus
12 Sac of tunica vaginalis
13 Scrotal sac
14 Spermatic cord
15 Superficial dorsal artery
16 Superficial dorsal nerve
17 Superficial dorsal vein
18 Superficial scrotal (dartos) fascia
19 Tail of epididymis
20 Testis
21 Tunica vaginalis, parietal
22 Tunica vaginalis, visceral, overlying tunica albuginea

Circumcision, Fournier's gangrene, hydrocele, phimosis and paraphimosis, scrotal swellings, varicoceles, vasectomy, see pages 280–284.

Male pelvis *left half of a midline sagittal section*

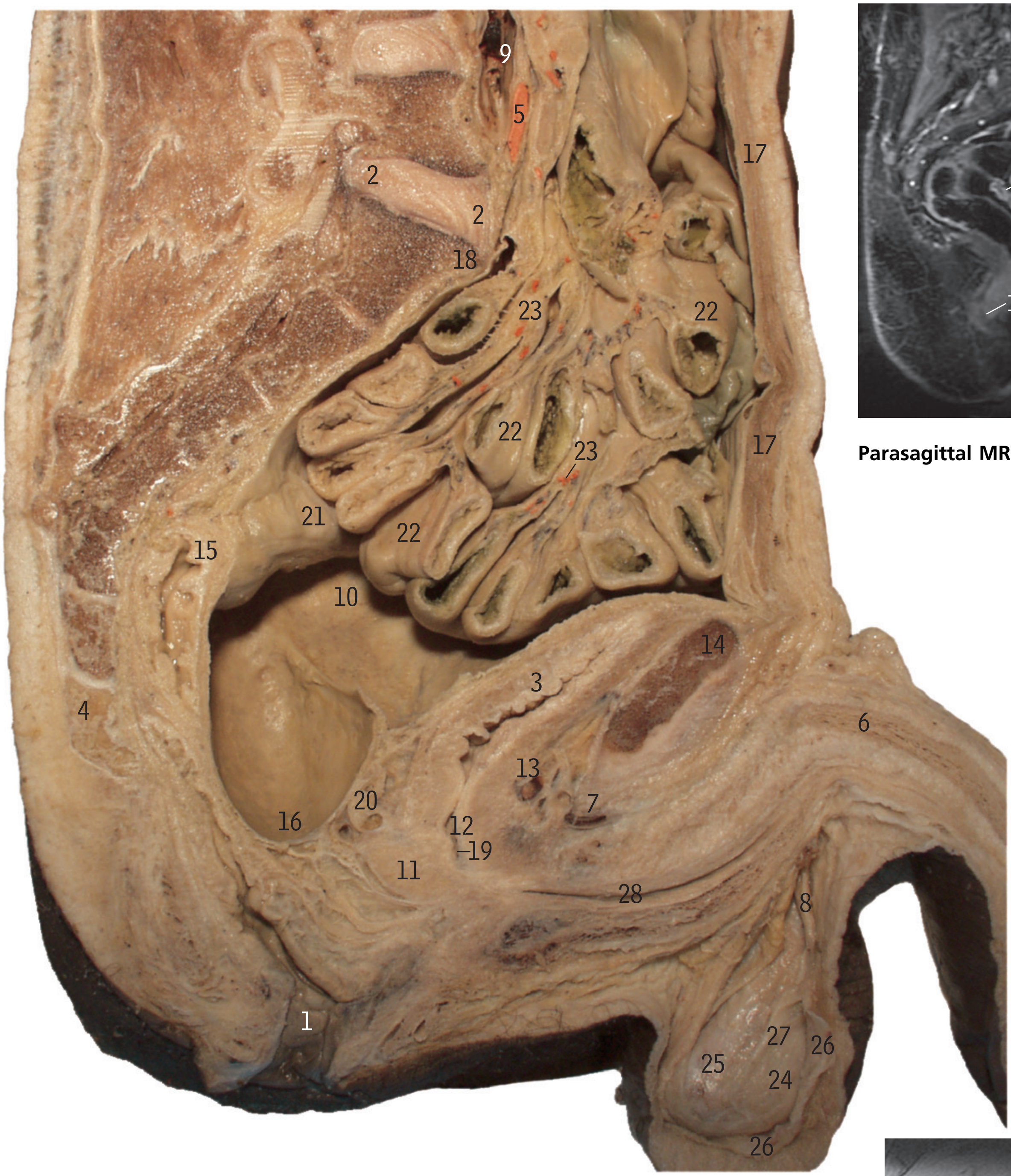

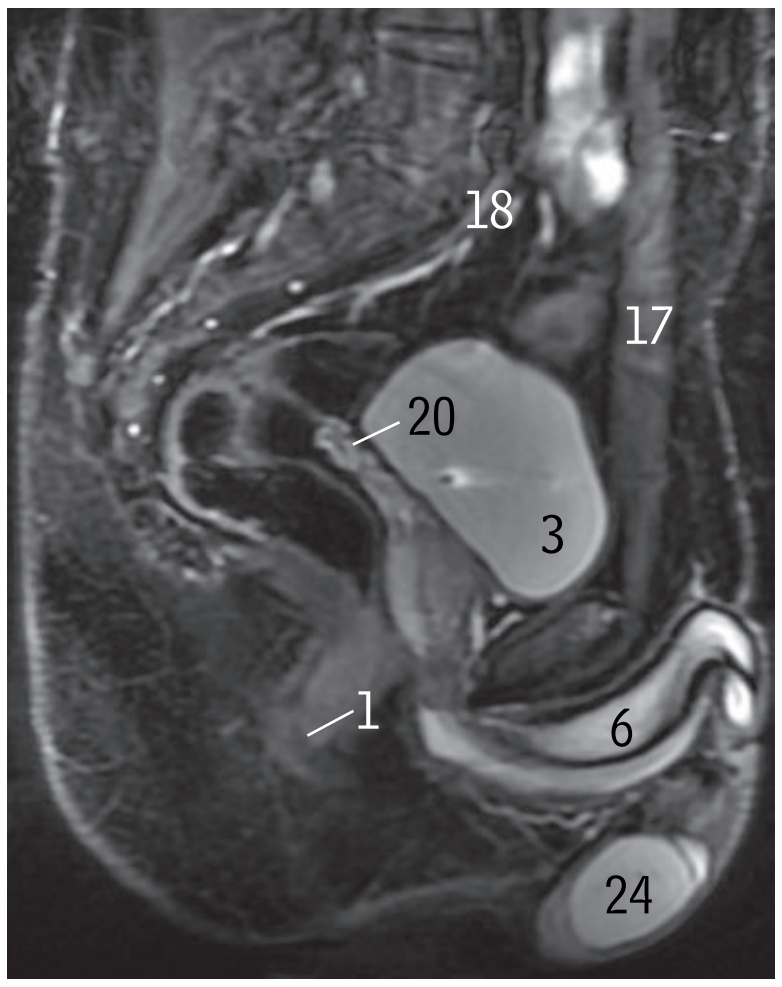

Parasagittal MRI, pelvis

1 Anal canal
2 Annulus fibrosus
3 Bladder
4 Coccyx
5 Common iliac artery
6 Corpus cavernosum
7 Deep dorsal vein of penis
8 Ductus deferens
9 Inferior vena cava
10 Parietal peritoneum
11 Prostate
12 Prostatic urethra
13 Prostatic venous plexus
14 Pubic symphysis
15 Rectosigmoid junction
16 Rectovesical pouch of pelvic peritoneum
17 Rectus abdominis
18 Sacral promontory
19 Seminal colliculus
20 Seminal vesicle
21 Sigmoid colon
22 Small intestine, multiple coils
23 Superior mesenteric vessels, jejunal and ileal branches
24 Testis
25 Tunica albuginea
26 Tunica vaginalis, parietal layer
27 Tunica vaginalis, visceral layer
28 Urethra, bulbous

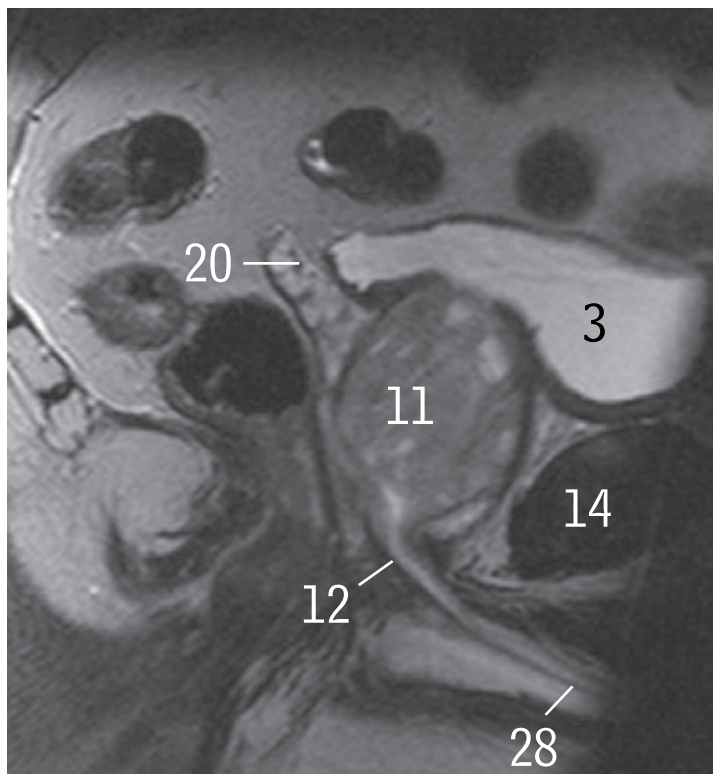

Sagittal MR imaging, pelvis

Extravasation of urine, proctoscopy and sigmoidoscopy, testicular torsion, see pages 280–284.

Pelvis, right inguinal region and penis *from above*

In the pelvis, most of the bladder (34) has been removed to show part of the basal surface of the prostate (2), and the left seminal vesicle (29) lying lateral to the ductus deferens (8). The ductus in the pelvis crosses superficial to the ureter (35). The external iliac artery (9) passes under the inguinal ligament (10) to become the femoral artery (11). On the dorsum of the penis, the fascia has been removed, showing the single midline deep dorsal vein (4) with a dorsal artery (6) and dorsal nerve (7) on each side.

The trigone of the bladder (34), at the lower part of the base or posterior surface, is the relatively fixed area with smooth mucous membrane between the internal urethral orifice (23) and the two ureteral openings (36 on the right side).

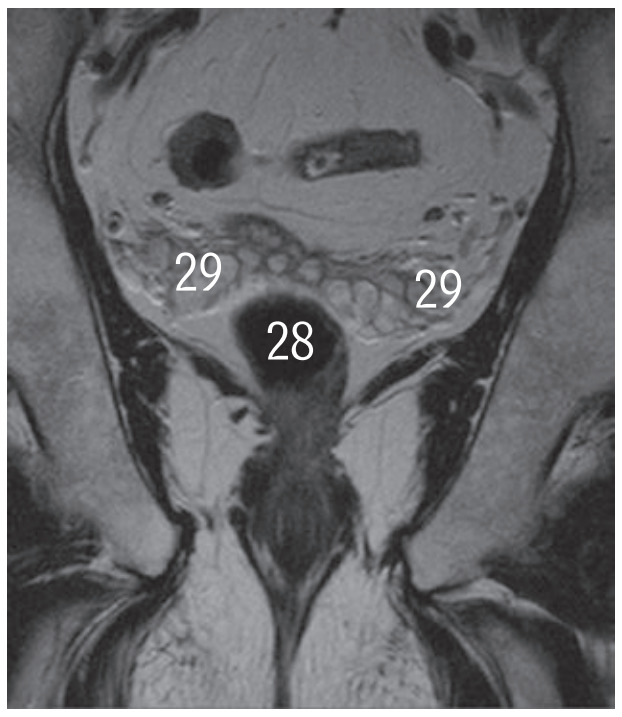

Coronal MR imaging, pelvis

1 Adductor longus
2 Base of prostate
3 Common iliac artery
4 Deep dorsal vein of penis
5 Deep external pudendal artery
6 Dorsal artery of penis
7 Dorsal nerve of penis
8 Ductus deferens
9 External iliac artery
10 External oblique aponeurosis and inguinal ligament
11 Femoral artery
12 Femoral branch of genitofemoral nerve
13 Femoral nerve
14 Femoral vein
15 Fifth lumbar intervertebral disc
16 Genital branch of genitofemoral nerve
17 Great saphenous vein
18 Iliacus
19 Inferior epigastric artery
20 Inferior vesical artery
21 Internal iliac artery
22 Internal oblique
23 Internal urethral orifice
24 Obturator artery
25 Obturator nerve
26 Pectineus
27 Psoas major
28 Rectum
29 Seminal vesicle
30 Sigmoid colon (cut lower end)
31 Spermatic cord
32 Superficial circumflex iliac vein
33 Superior vesical artery
34 Trigone of bladder
35 Ureter
36 Ureteral orifice

Carcinoma of the large bowel, cystitis, cystoscopy, ureteric variants, see pages 280–284.

A Bladder and prostate *from behind*

1 Base of bladder
2 Ductus deferens
3 Left ejaculatory duct
4 Posterior surface of prostate
5 Seminal vesicle
6 Ureter

B Left side of the male pelvis *from the right*

In this midline sagittal section, the prostate (24) is enlarged, lengthening the prostatic urethra (25) and accentuating the trabeculae of the bladder. The mucous membrane of the bladder (whose trigone is labelled at 36) has been removed to show muscular trabeculae in the wall. Variations in the branches of the internal iliac artery (14) are common, and here the obturator artery (22) gives origin to the superior vesical (34) and inferior vesical (13) as well as the middle rectal (20) arteries.

A

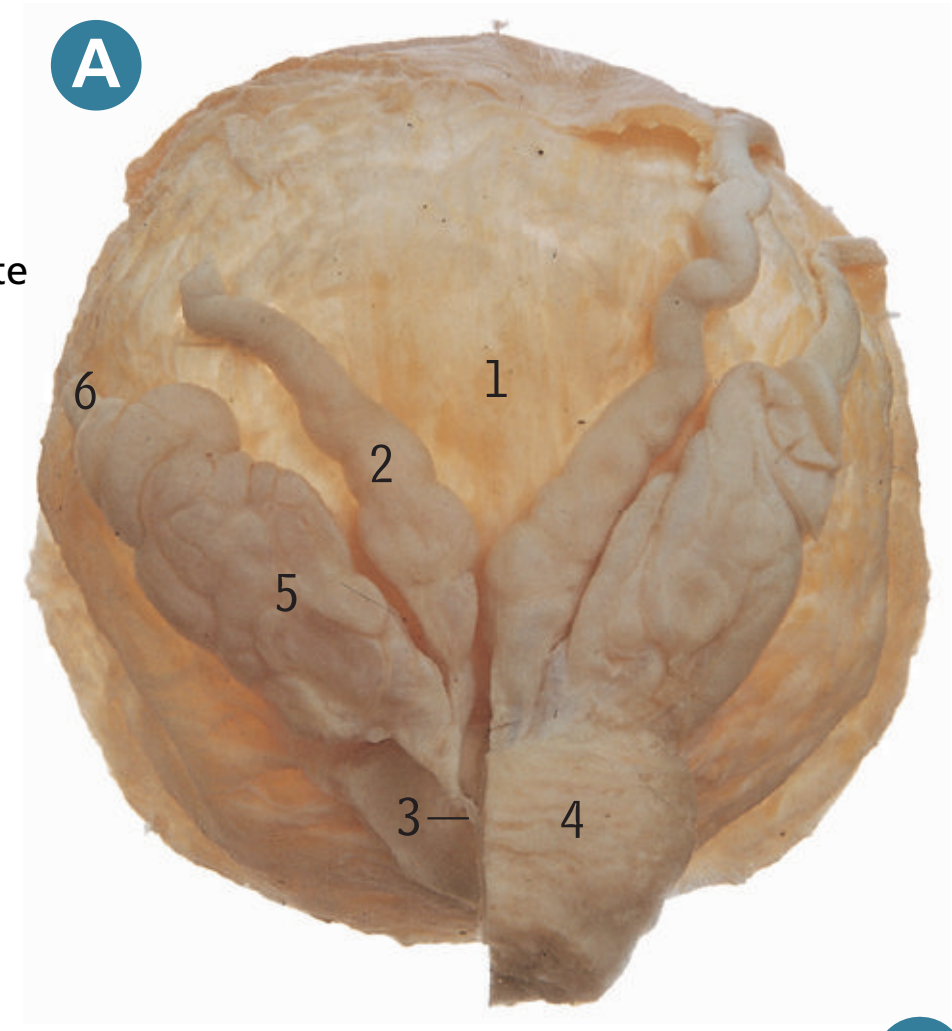

C Cytoscopy of bladder

C

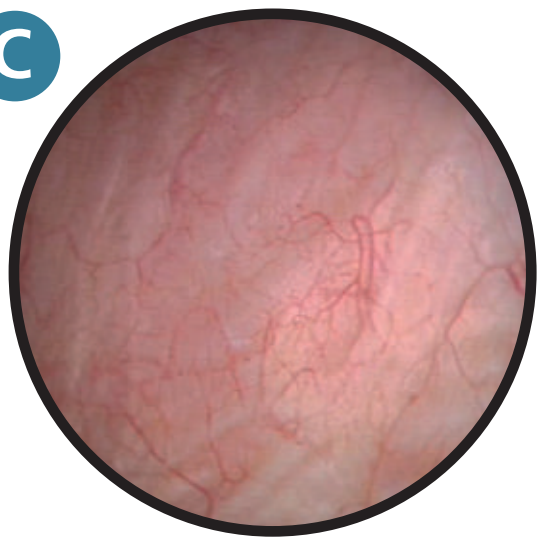

D Cytoscopy of prostate (TURP)

D

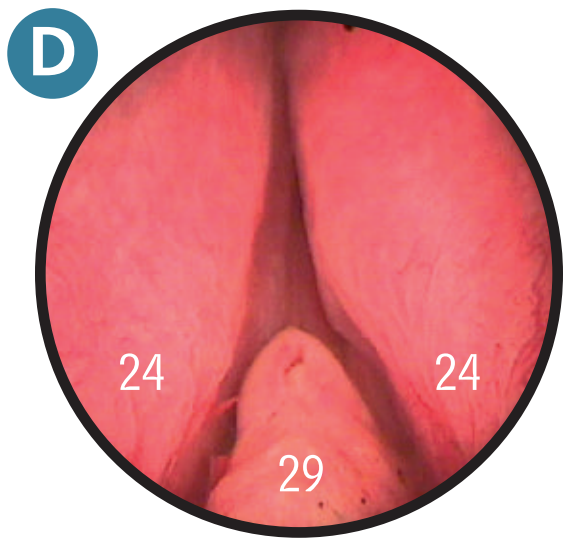

B

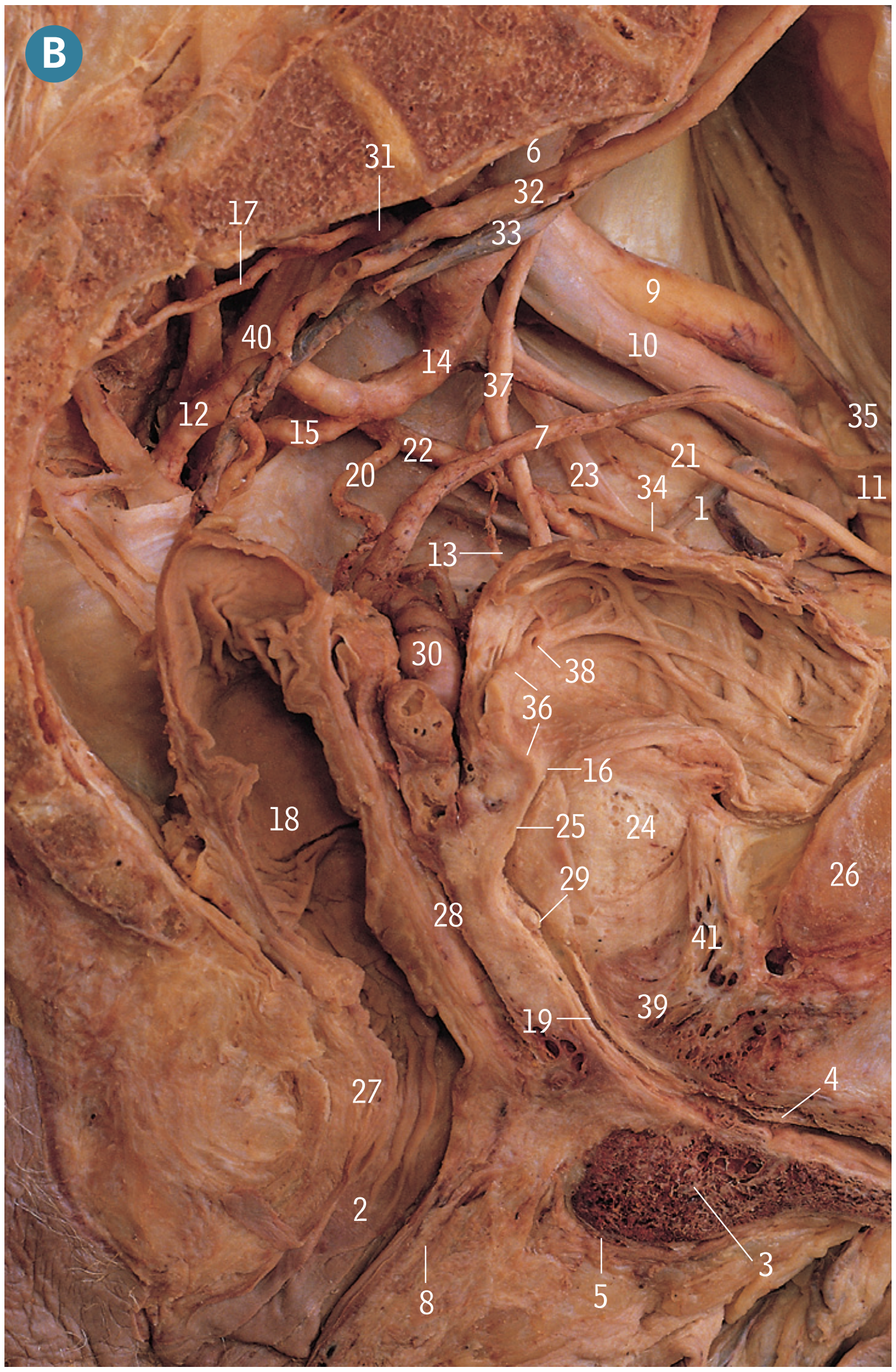

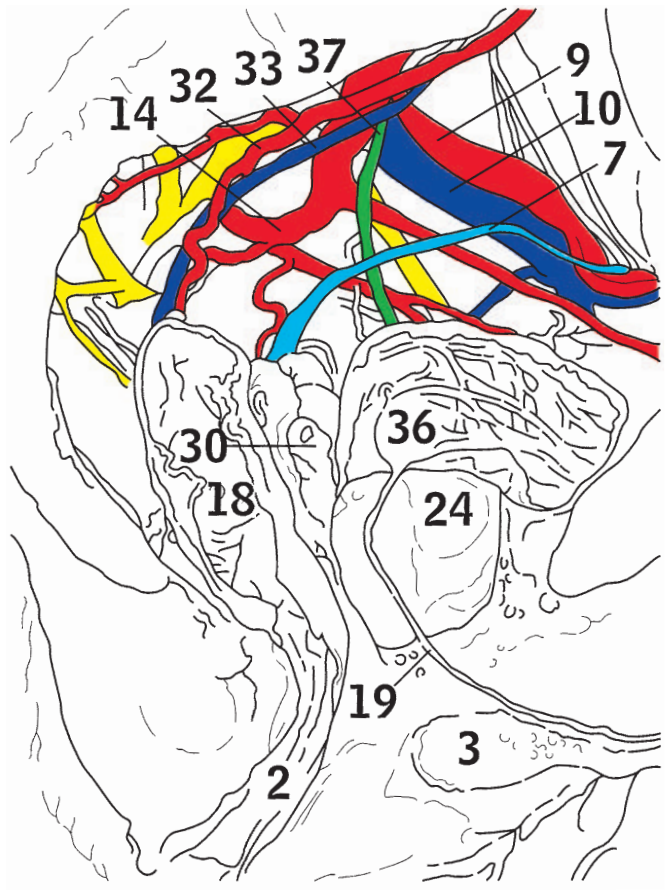

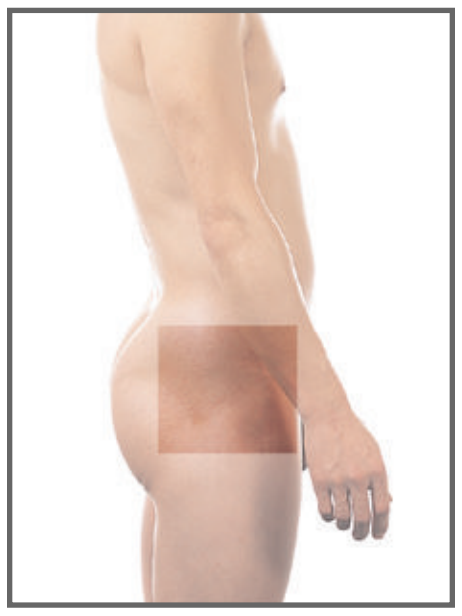

1 Accessory obturator vein
2 Anal canal
3 Bulb of penis
4 Bulbar part of spongy urethra
5 Bulbospongiosus
6 Common iliac artery
7 Ductus deferens
8 External anal sphincter
9 External iliac artery
10 External iliac vein
11 Inferior epigastric vessels
12 Inferior gluteal artery
13 Inferior vesical artery
14 Internal iliac artery
15 Internal pudendal artery
16 Internal urethral orifice
17 Lateral sacral artery
18 Lower end of rectum
19 Membranous part of urethra
20 Middle rectal artery
21 Obliterated umbilical artery
22 Obturator artery
23 Obturator nerve
24 Prostate (enlarged)
25 Prostatic part of urethra
26 Pubic symphysis
27 Puborectalis part of levator ani
28 Rectovesical fascia
29 Seminal colliculus
30 Seminal vesicle
31 Superior gluteal artery
32 Superior rectal artery
33 Superior rectal vein
34 Superior vesical artery
35 Testicular vessels and deep inguinal ring
36 Trigone of bladder
37 Ureter
38 Ureteral orifice
39 Urogenital diaphragm
40 Ventral ramus of first sacral nerve
41 Vesicoprostatic venous plexus

Benign prostatic hyperplasia, carcinoma of the prostate, transurethral resection of the prostate (TURP), urethral stricture, see pages 280–284.

A Arteries and nerves of the pelvis *from the right*

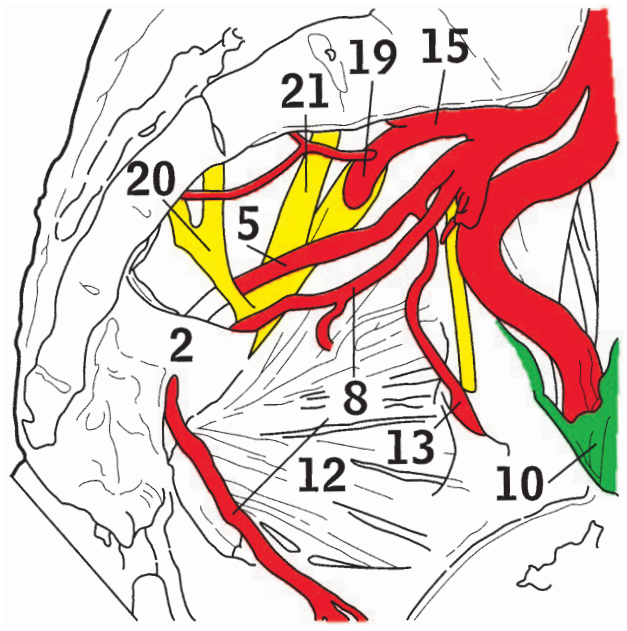

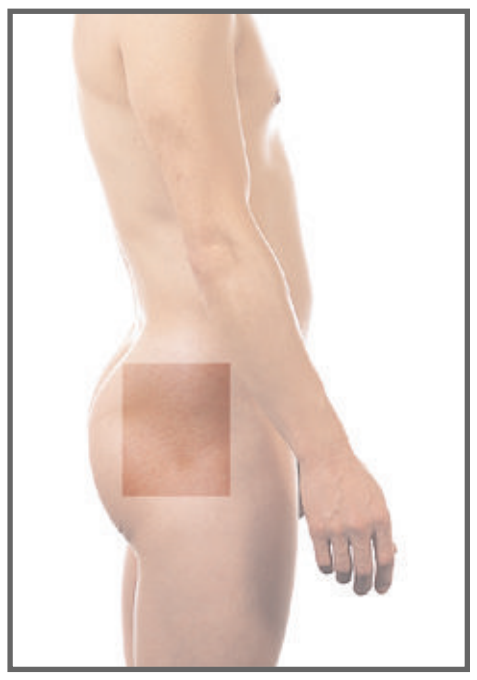

1 Anterior trunk of internal iliac artery
2 Coccygeus and sacrospinous ligament
3 External iliac artery
4 Inferior epigastric artery
5 Inferior gluteal artery
6 Inguinal ligament
7 Internal iliac artery
8 Internal pudendal artery
9 Ischial tuberosity
10 Lacunar ligament
11 Lateral sacral artery
12 Obturator internus
13 Obturator nerve and artery
14 Piriformis
15 Posterior trunk of internal iliac artery
16 Pubic symphysis
17 Sacral promontory
18 Sacrococcygeal joint
19 Superior gluteal artery piercing lumbosacral trunk
20 Union of ventral rami of second and third sacral nerves
21 Ventral ramus of first sacral nerve

In this left half section of the pelvis, all peritoneum, fascia, veins and visceral arteries have been removed together with the left levator ani, so displaying the whole of the internal surface of obturator internus (12). On the posterior pelvic wall, the vessels in general lie superficial to the nerves.

In this specimen, the external iliac artery (3) is unusually tortuous, and the anterior trunk of the internal iliac artery (1) has divided unusually high up into its terminal branches, the internal pudendal (8) and the inferior gluteal (5). The superior gluteal artery (19) has perforated the lumbosacral trunk.

B Left inferior hypogastric plexus *from the right*

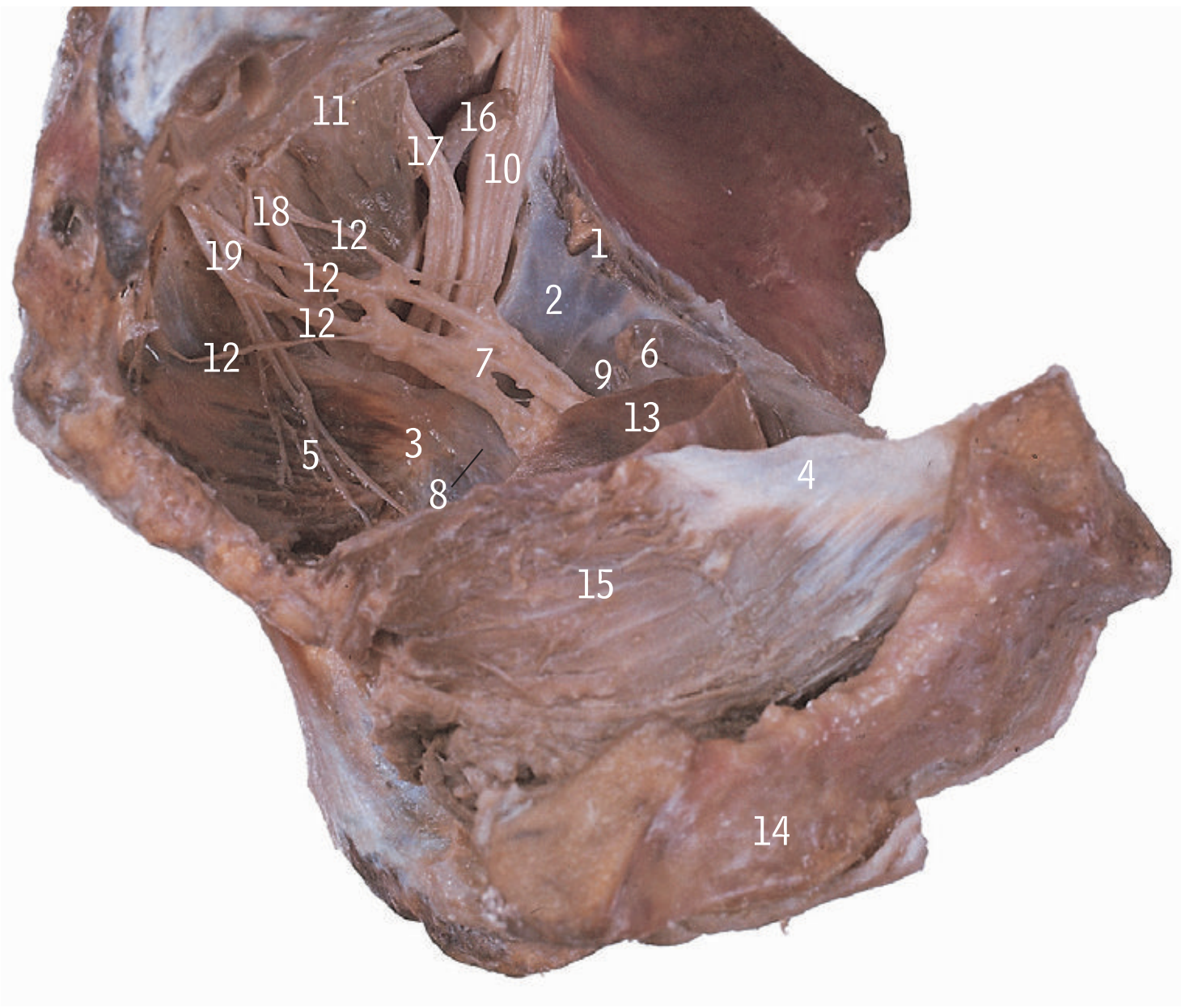

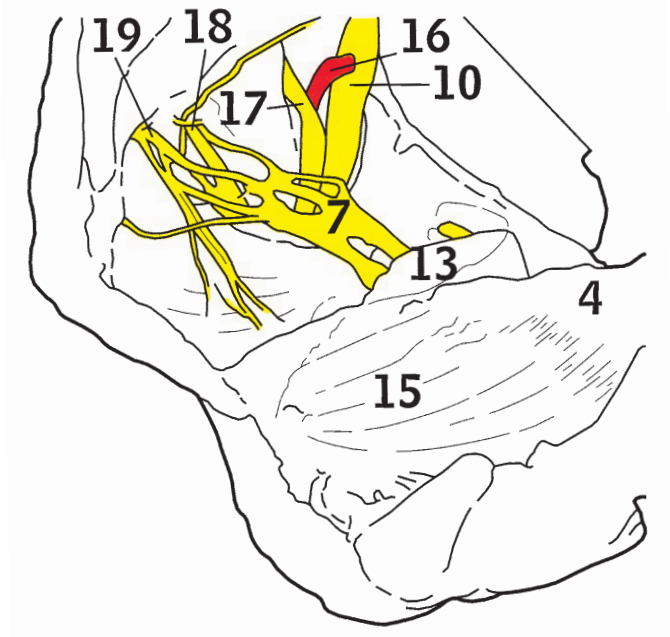

In this view of the left side of the pelvis from the right, the right pelvic wall has been removed but the right levator ani (15) forming part of the pelvic floor (pelvic diaphragm) has been preserved and is seen from its right (perineal) side. Pelvic splanchnic nerves (12) arise from the ventral rami of the second and third sacral nerves (18 and 19) and contribute to the inferior hypogastric plexus (7).

1 Arcuate line of ilium
2 Fascia overlying obturator internus
3 Ischial spine
4 Lateral surface of fascia overlying right obturator internus
5 Left coccygeus and nerves to levator ani
6 Left ductus deferens
7 Left inferior hypogastric plexus
8 Left levator ani
9 Left seminal vesicle
10 Lumbosacral trunk
11 Part of left sympathetic trunk
12 Pelvic splanchnic nerves (nervi erigentes)
13 Rectum
14 Right ischiopubic ramus
15 Right levator ani and ischio-anal (ischiorectal) fossa
16 Superior gluteal artery
17 Ventral ramus of first sacral nerve
18 Ventral ramus of second sacral nerve
19 Ventral ramus of third sacral nerve

Internal iliac artery *branches and relationships, left side female pelvis*

1 Artery to iliac nodes
2 Bladder
3 External iliac artery
4 External iliac lymph nodes (enlarged)
5 External iliac vein
6 Genitofemoral nerve, femoral branch
7 Genitofemoral nerve, genital branch
8 Iliolumbar artery
9 Inferior gluteal artery
10 Inferior vesical artery
11 Internal pudendal artery
12 Internal iliac artery
13 Internal iliac artery, anterior division
14 Internal iliac artery, posterior division
15 Lateral sacral artery, inferior
16 Lateral sacral artery, superior
17 Middle rectal artery
18 Obturator artery
19 Obturator nerve
20 Obturator veins
21 Round ligament of the uterus (reflected)
22 Superior gluteal artery
23 Superior vesical artery
24 Umbilical artery remnant
25 Ureter (retracted)
26 Uterine artery
27 Vaginal artery

Internal iliac embolisation, see pages 280–284.

A Pelvic skeleton and ligaments *left side*

In this mid-sagittal section, viewed from slightly above the midline, most soft tissues except ligaments have been removed.

1 Anterior inferior iliac spine and origin of straight head of rectus femoris
2 Anterior superior iliac spine
3 Falciform process of sacrotuberous ligament
4 Greater sciatic foramen
5 Iliac fossa
6 Inguinal ligament
7 Ischial spine
8 Ischial tuberosity
9 Lacunar ligament
10 Lesser sciatic foramen
11 Obturator foramen with obturator nerve and vessels
12 Obturator membrane
13 Pectineal ligament
14 Pubic symphysis
15 Sacral promontory
16 Sacrospinous ligament
17 Sacrotuberous ligament

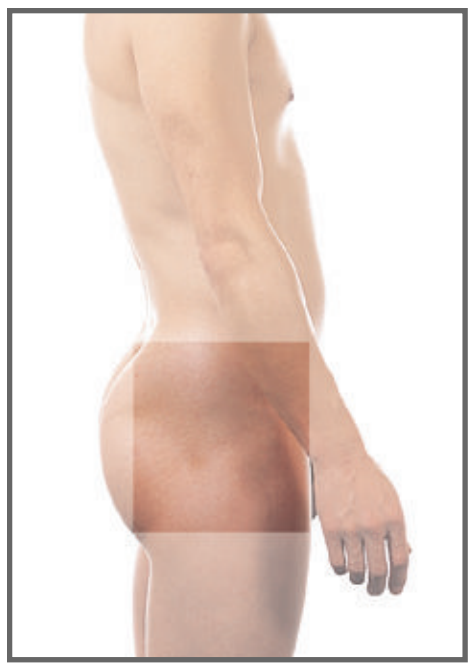

The ligaments classified as ‘the ligaments of the pelvis’ (vertebropelvic ligaments) are the sacrotuberous (17), sacrospinous (16) and iliolumbar (seen in the posterior view on page 325, C7).

The lacunar ligament (9) passes backwards from the medial end of the inguinal ligament (6) to the medial end of the pectineal line of the pubis, to which the pectineal ligament (13) is attached.

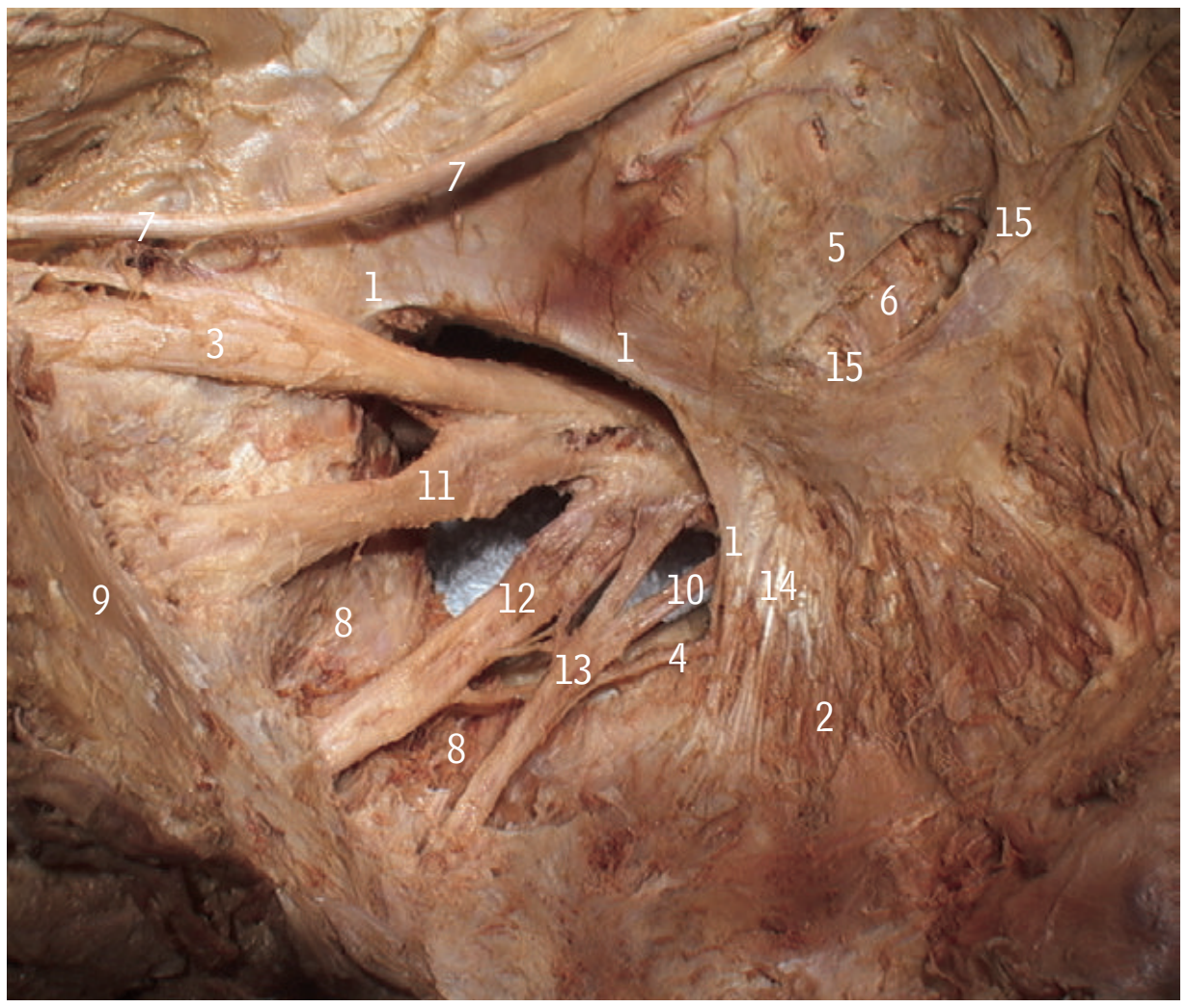

B Greater sciatic foramen, sacral plexus and levator ani *left side*

1 Greater sciatic foramen
2 Levator ani
3 Lumbosacral trunk (with S1)
4 Nerve to levator ani
5 Obturator internus fascia
6 Obturator internus muscle
7 Obturator nerve
8 Piriformis muscle fibres (muscle bulk removed)
9 Posterior longitudinal ligament, overlying sacrum
10 Pudendal nerve
11 Sacral nerve, S2
12 Sacral nerve, S3 and S4
13 Sacral nerve, S5
14 Sacrospinous ligament
15 Tendinous arch of levator ani, an origin of levator

Bone marrow aspiration, obturator hernia, sacral nerve stimulation, see pages 280–284.

Female pelvis *left half with arterial injection, viewed from right*

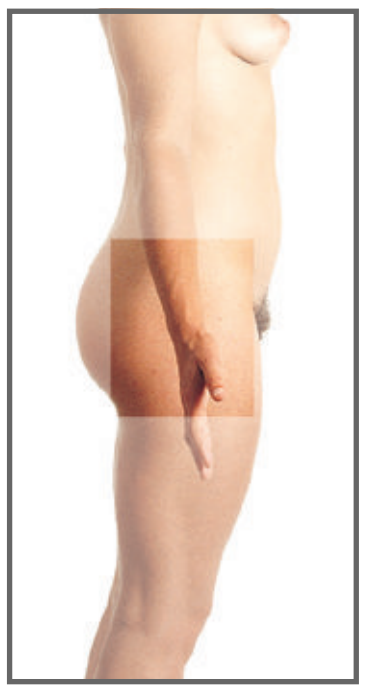

1 Anterior vaginal fornix
2 Bladder neck
3 Cervix
4 Cervix, external os
5 Cervix, internal os
6 Clitoris
7 Crus of clitoris
8 External iliac artery
9 External iliac vein
10 Fundus of uterus
11 Inferior epigastric vessels
12 Labium minus
13 Ligament of ovary
14 Medial umbilical ligament
15 Median umbilical ligament (urachus)
16 Obturator nerve
17 Obturator vessels
18 Posterior vaginal fornix
19 Pubic symphysis
20 Rectosigmoid junction
21 Rectouterine peritoneal space
22 Rectum
23 Rectus abdominis
24 Retropubic space
25 Round ligament of uterus
26 Sacral promontory
27 Sigmoid colon
28 Superior vesical artery
29 Trigone of bladder
30 Umbilical artery (remnant)
31 Ureter
32 Uterine cavity
33 Vagina
34 Vertebral body, L5
35 Vesicouterine peritoneal pouch
36 Vestibule of vagina

NB: retroverted uterus – a common normal variant.

Faecal continence, haemorrhoids, ligation–uterine tubes, rectal (PR) examination, rectal prolapse, uterine fibroids, uterine variants, *see pages 280–284.*

Female pelvis

A sagittal MR image during menstruation

B coronal MR image

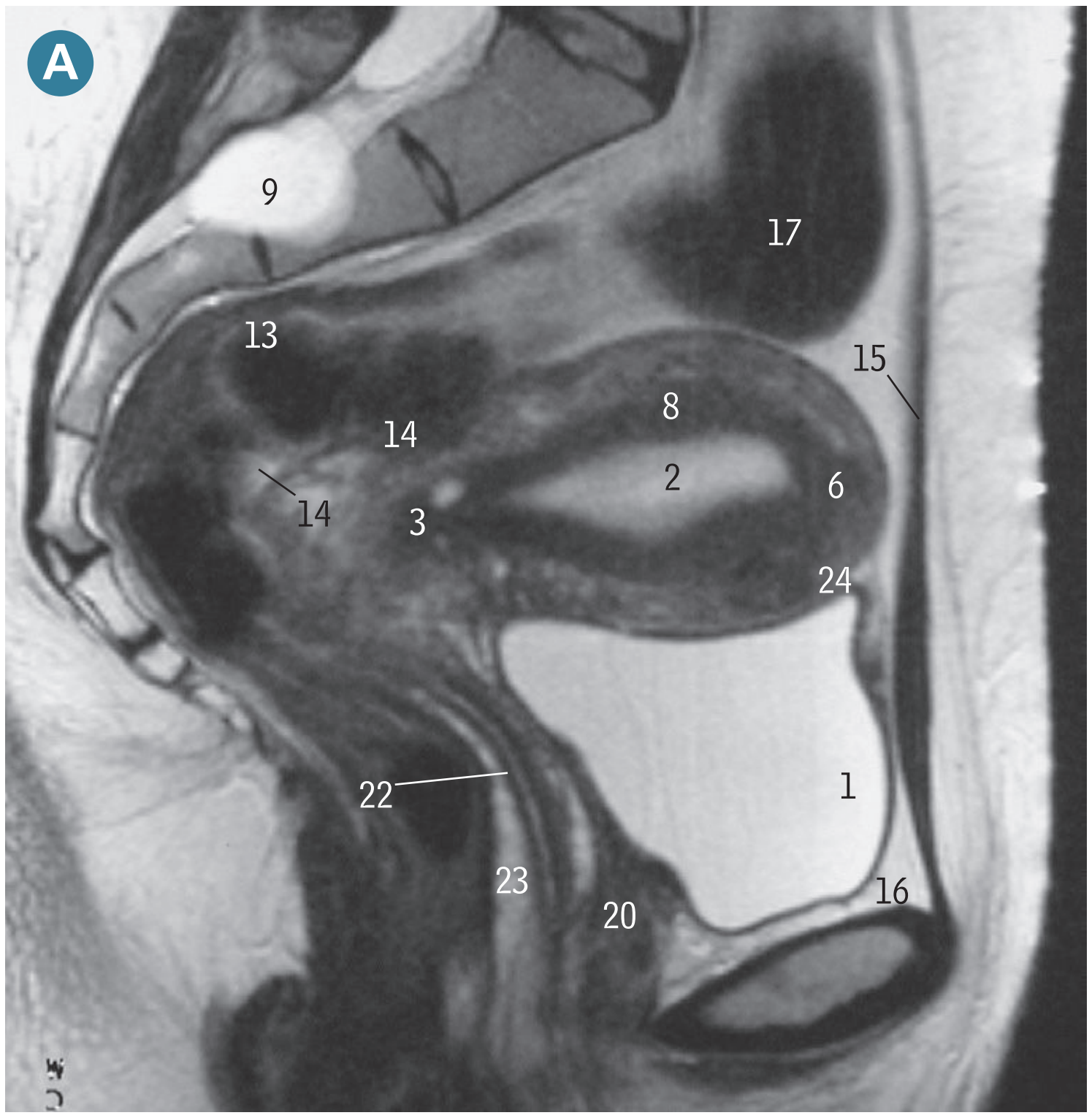

1 Bladder
2 Blood clot in endometrial cavity
3 Cervix of uterus
4 Corpus luteum
5 Endometrial cavity
6 Fundus of uterus
7 Levator ani
8 Myometrium
9 Nerve root cyst (Tarlov)
10 Ovary
11 Perineal muscles
12 Posterior fornix of vagina
13 Rectosigmoid junction
14 Recto-uterine pouch (Douglas)
15 Rectus abdominis muscle
16 Retropubic space (Retzius)
17 Sigmoid colon
18 Small intestine
19 Trigone
20 Urethra
21 Uterine (Fallopian) tube
22 Vaginal cavity
23 Vaginal wall
24 Vesico-uterine pouch

Looking down into the pelvis from the front, the fundus of the uterus (6) overlies the bladder (1) with the peritoneum of the vesico-uterine pouch (24) intervening. These relationships are seen in this MR image B.

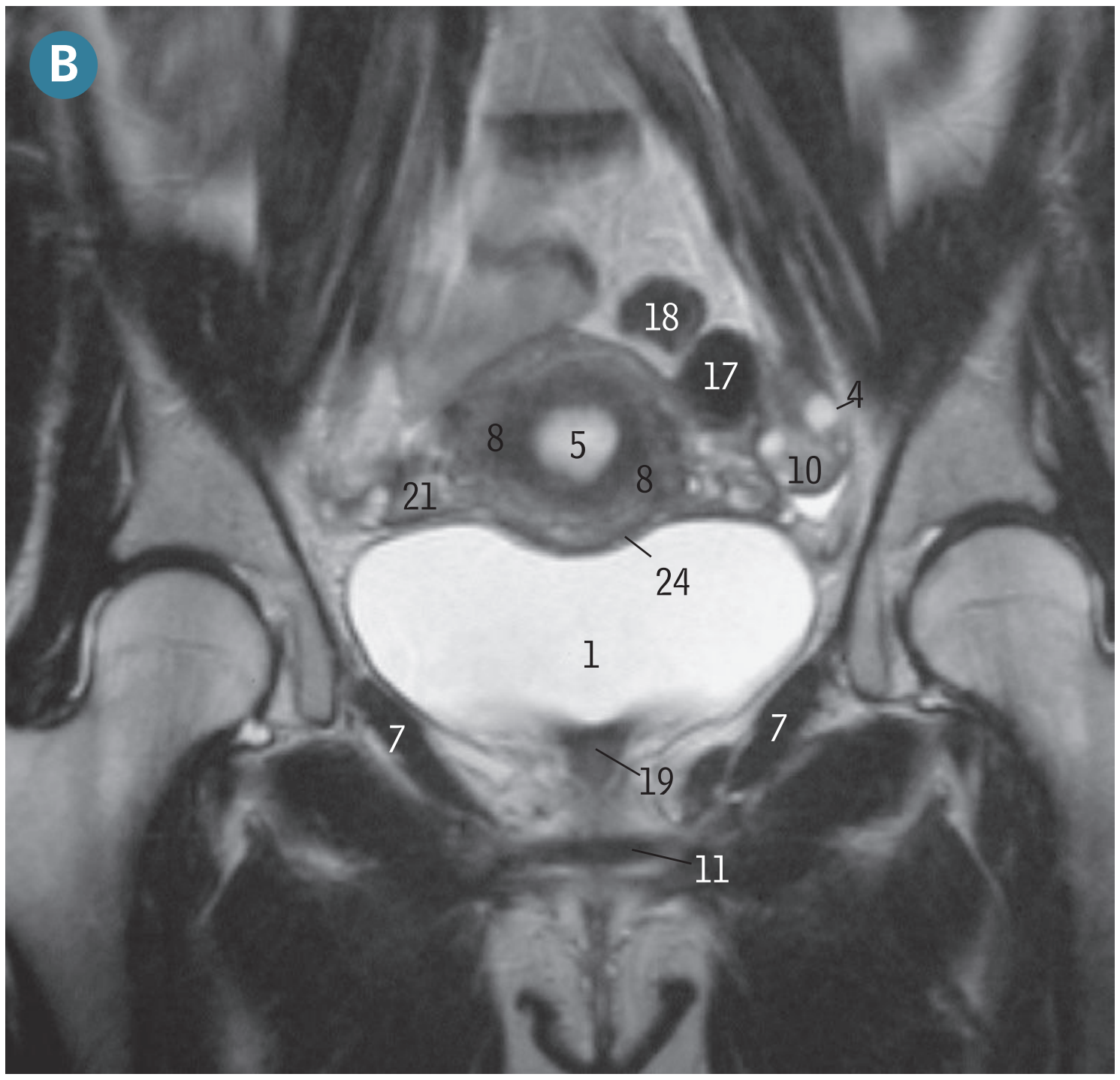

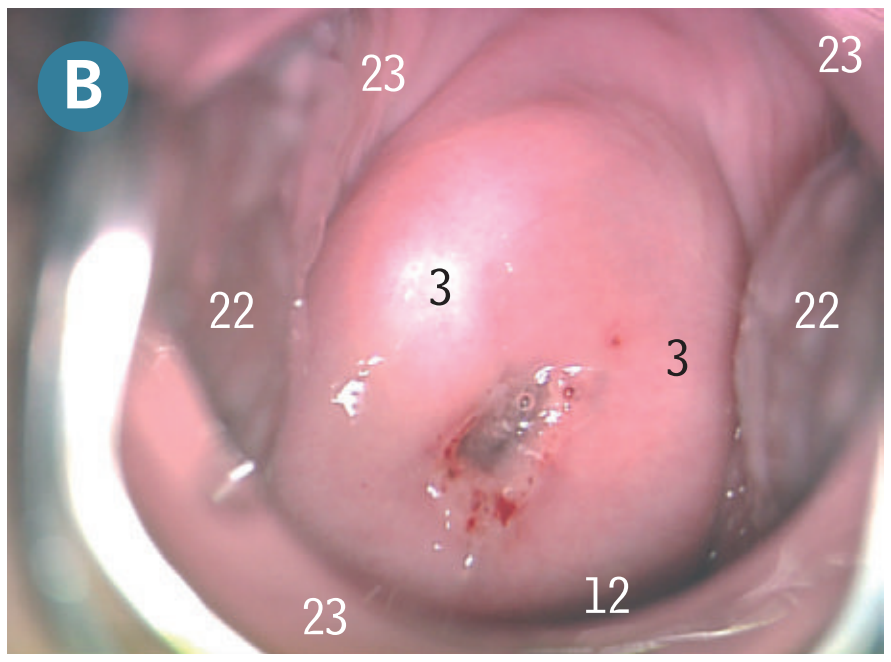

Speculum examination of cervix

Cervical smear, cystitis, ovarian dermoid, vaginal examination, see pages 280–284.

Female pelvis

A uterus and ovaries, from above and in front

B hysterosalpingogram (HSG)

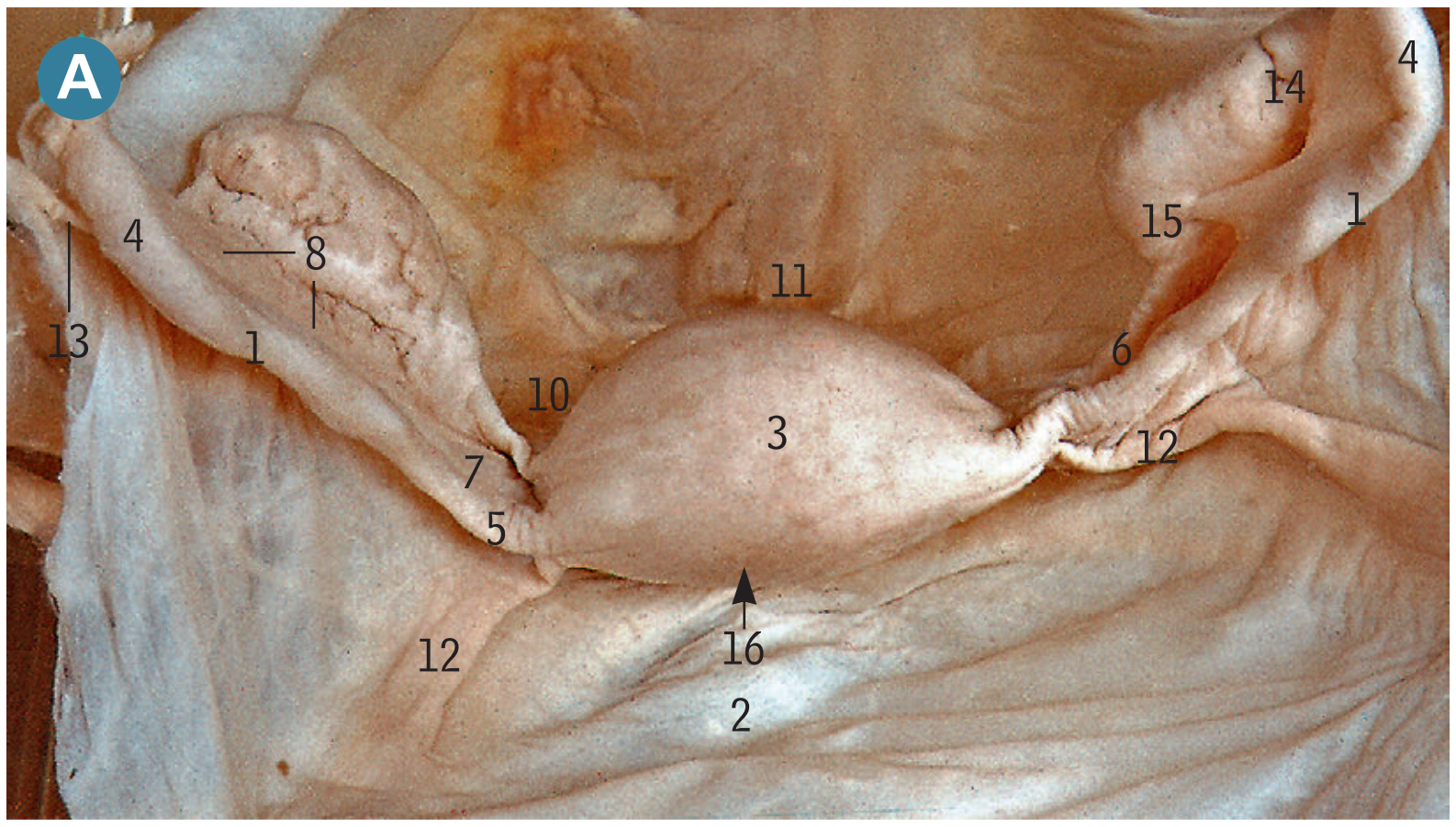

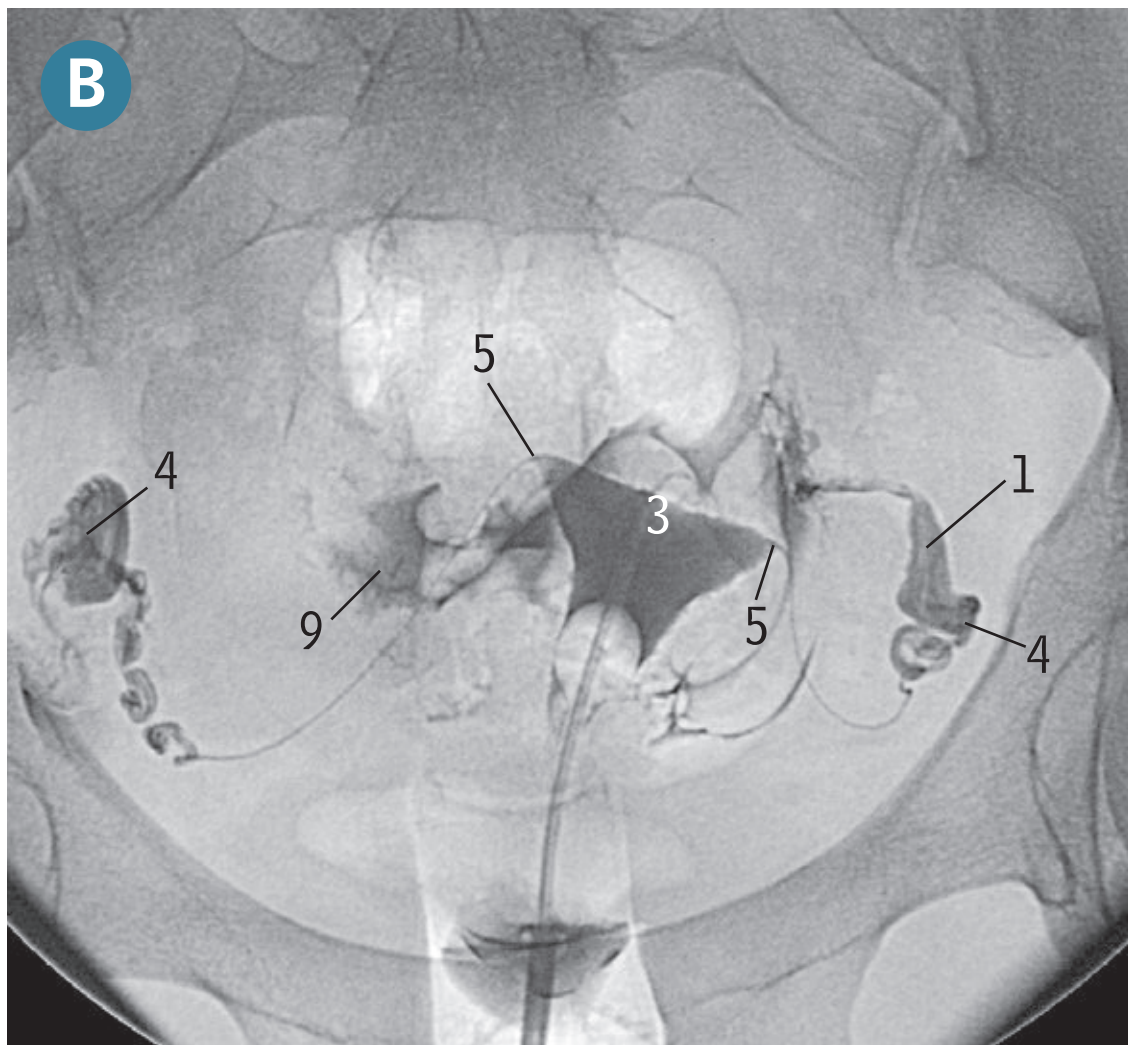

1 Ampulla of uterine tube
2 Bladder
3 Fundus of uterus
4 Infundibulum of uterine tube
5 Isthmus of uterine tube
6 Ligament of ovary
7 Mesosalpinx
8 Mesovarium
9 Overspill of contrast into the peritoneal cavity
10 Posterior surface of broad ligament
11 Recto-uterine space
12 Round ligament of uterus
13 Suspensory ligament of ovary with ovarian vessels
14 Tubal extremity of ovary
15 Uterine extremity of ovary
16 Vesico-uterine pouch

Looking down into the pelvis from the front in A, the fundus of the uterus (3) overlies the bladder (2) with the peritoneum of the vesico-uterine pouch (16) intervening. In B, contrast medium has filled the uterus and tubes (3, 5, 1 and 4) and spilled out into the peritoneal cavity (9).

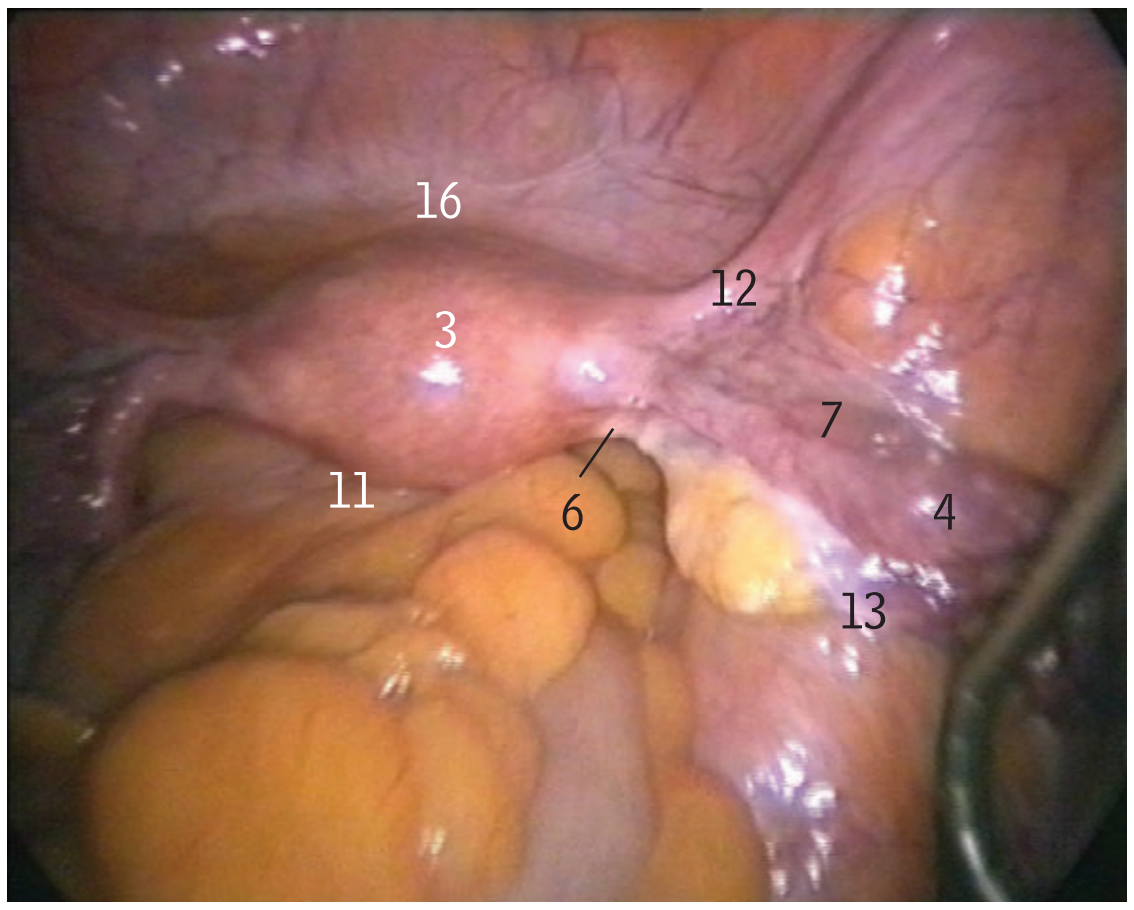

Laparoscopic view of female pelvis

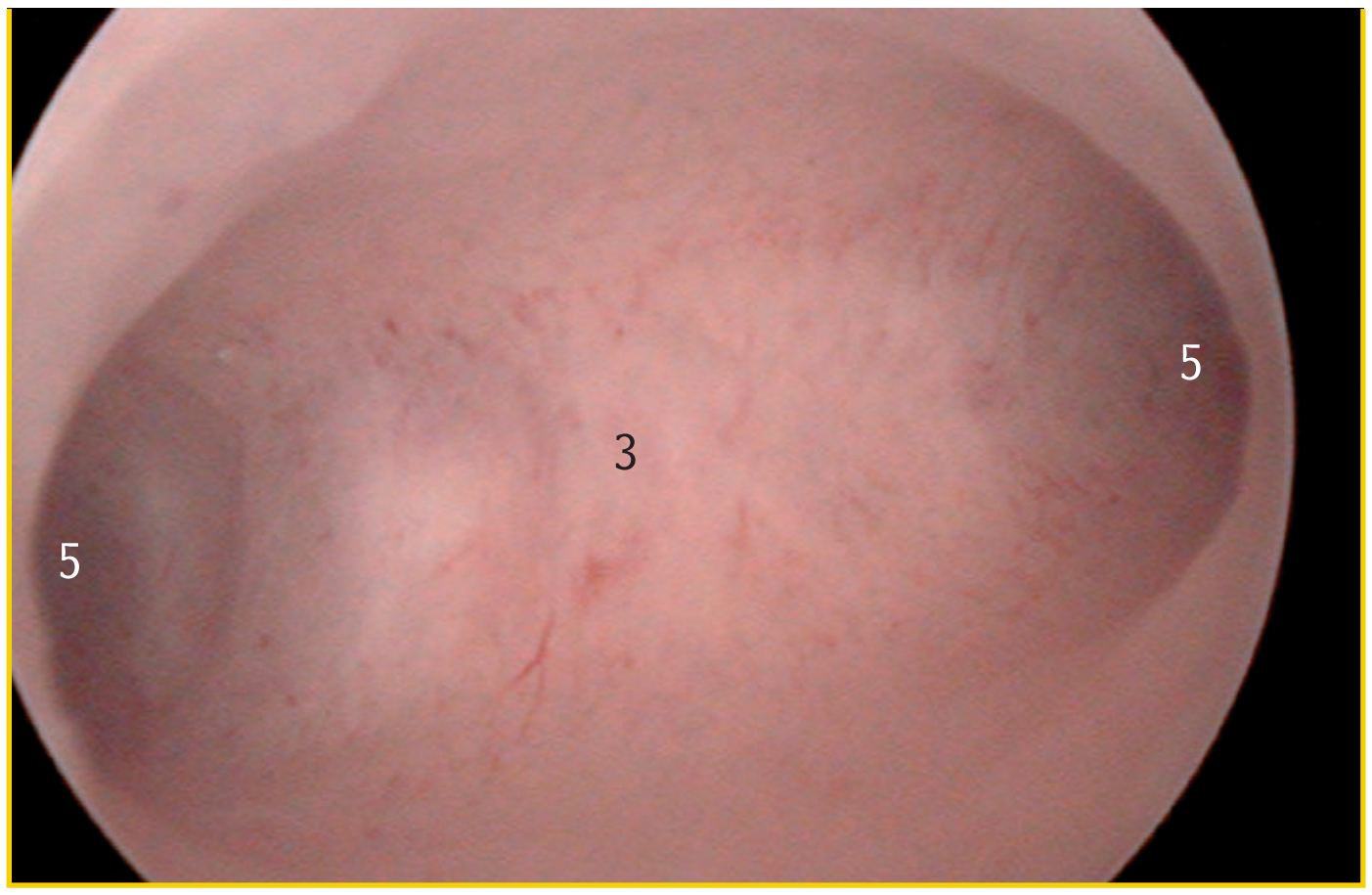

Hysteroscopic view of uterine cavity and uterine tubes

Acute salpingitis, carcinoma of the ovary, ectopic pregnancy rupture, intrauterine contraceptive devices (IUCDs), ligation–uterine tubes, see pages 280–284.

Female pelvis *left half, obliquely from the front*

1 Ampulla of uterine tube
2 Anterior fornix of vagina
3 Body of uterus
4 Cavity of vagina
5 Cervix of uterus
6 Fimbriated end of uterine tube
7 Fundus of uterus
8 Internal iliac artery
9 Internal iliac vein
10 Middle rectal artery
11 Obliterated umbilical artery
12 Obturator artery
13 Obturator nerve
14 Obturator vein
15 Peritoneum overlying bladder
16 Peritoneum overlying piriformis
17 Posterior fornix of vagina
18 Recto-vaginal pouch
19 Rectum
20 Round ligament of uterus
21 Sigmoid mesocolon
22 Superior vesical artery
23 Ureter
24 Uterine artery
25 Uterosacral ligament
26 Vaginal artery (double)
27 Vesico-uterine pouch

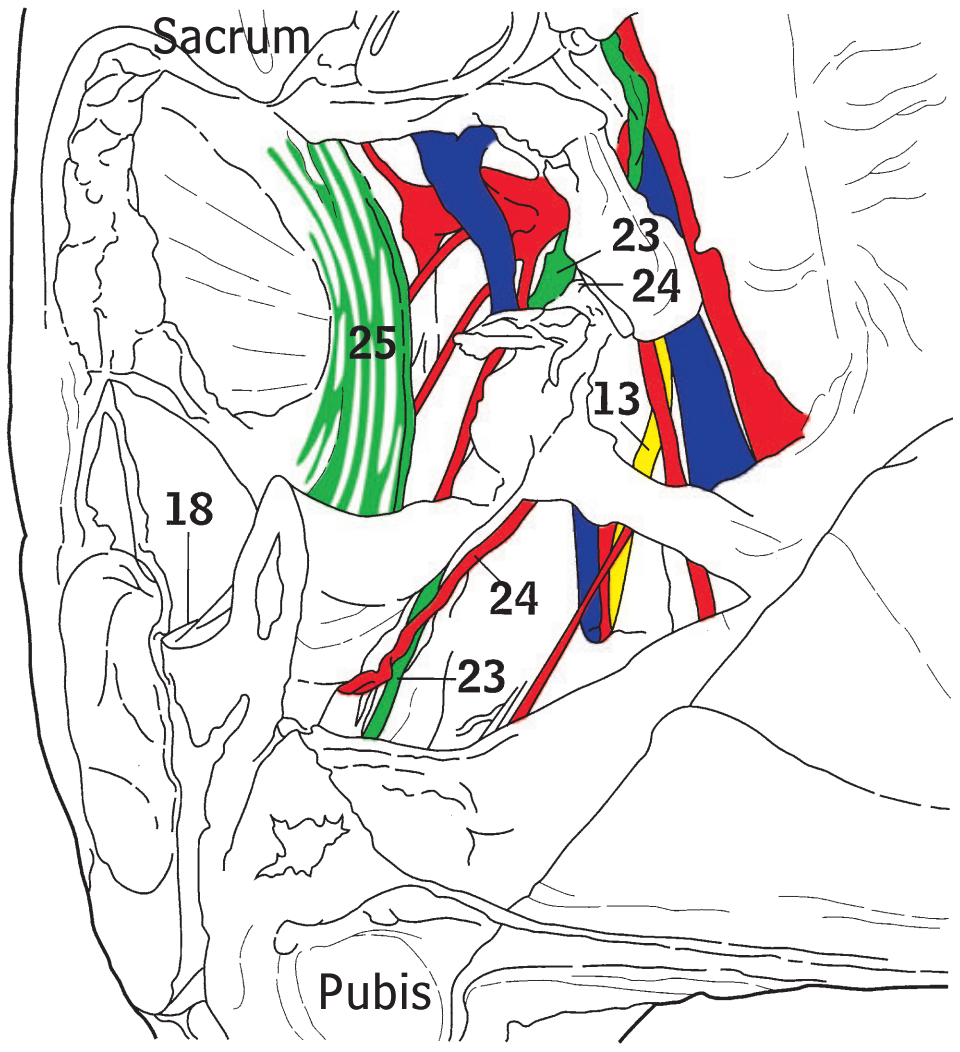

Looking obliquely into the left half of the pelvis from the front, with the anterior abdominal wall turned forwards, the peritoneum of the vesico-uterine pouch (27) has been incised and the uterus (3) displaced backwards. This shows the ureter (23) running towards the bladder and being crossed by the uterine artery (24). The uterosacral ligament (25) passes backwards at the side of the rectum (19) towards the pelvic surface of the sacrum. The root of the sigmoid mesocolon (21) has been left in place to emphasise that the left ureter (23) passes from the abdomen into the pelvis beneath it.

Anorectal abscesses, carcinoma of the uterus, hysterectomy, support of the pelvic viscera, unsafe abortion, see pages 280–284.

Female perineum

A Surface features

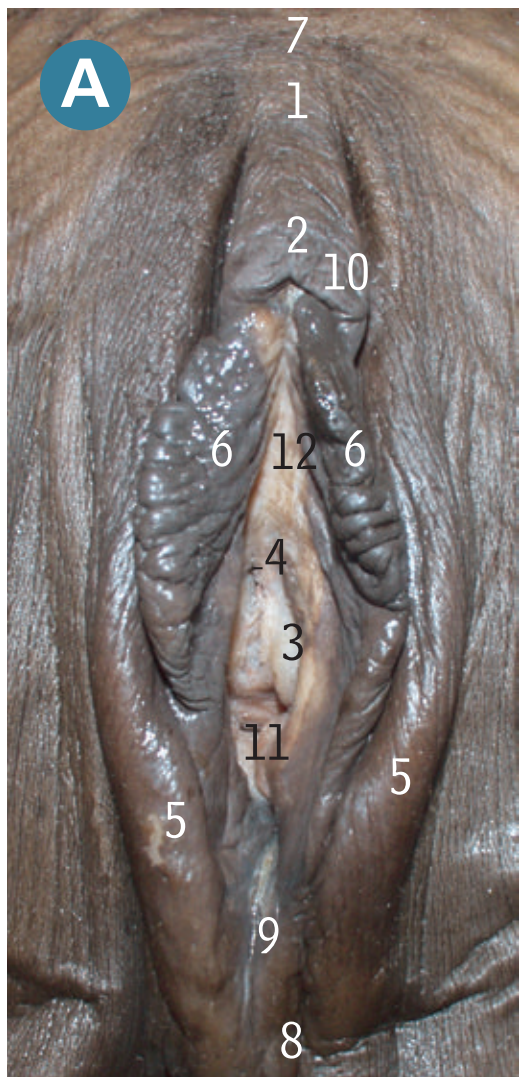

1 Anterior commissure of labia majora
2 Clitoris
3 Cystocele (prolapse of bladder)
4 External urethral orifice (urinary meatus)
5 Labium majus
6 Labium minus
7 Mons pubis
8 Perineal body
9 Posterior commissure of labia majora
10 Prepuce of clitoris
11 Vaginal orifice (introitus)
12 Vestibule

B Ischio-anal fossae from behind

1 Anal margin
2 Anococcygeal body
3 Biceps femoris, long head
4 Coccyx
5 External anal sphincter
6 Gluteal maximus
7 Gluteus medius
8 Gracilis
9 Inferior gemellus
10 Inferior gluteal artery
11 Inferior rectal nerve
12 Ischial tuberosity
13 Ischio-anal fossa, fat removed
14 Levator ani
15 Obturator internus and fascia
16 Obturator internus tendon
17 Piriformis
18 Posterior femoral cutaneous nerve, perineal branch
19 Posterior labial nerve
20 Pudendal artery
21 Pudendal nerve
22 Quadratus femoris
23 Sacrotuberous ligament
24 Sacrum
25 Sciatic nerve
26 Semimembranosus and semitendinosus
27 Superficial transverse perineal muscle
28 Superior gluteal artery

The ischiorectal fossa is now properly and more correctly called the ischio-anal fossa; the anal canal, not the rectum, is its lower medial boundary. The walls and contents are similar in both sexes.

Bartholin's abscess, episiotomy, female genital circumcision, pudendal block, see pages 280–284.

Female perineum and ischio-anal fossae *from below (lithotomy position)*

1 Adductor longus muscle
2 Adductor magnus muscle
3 Bulbspongiosus muscle
4 Clitoris (transected)
5 External anal sphincter
6 External urethral orifice (urinary meatus)
7 Gracilis
8 Internal pudendal artery passing superior to perineal membrane
9 Ischial tuberosity
10 Ischio-anal fossa
11 Ischiocavernosus muscle
12 Labium minus
13 Levator ani muscle
14 Margin of anus
15 Sacrotuberous ligament
16 Superficial transverse perineal muscle overlying posterior border of perineal membrane
17 Perineal membrane
18 Pubic symphysis
19 Pudendal nerve
20 Vaginal opening (introitus)
21 Vestibule of vagina (space between labium minus)

Gartner duct cyst in vaginal wall, genital ambiguous development, see pages 280–284.

A Male perineum

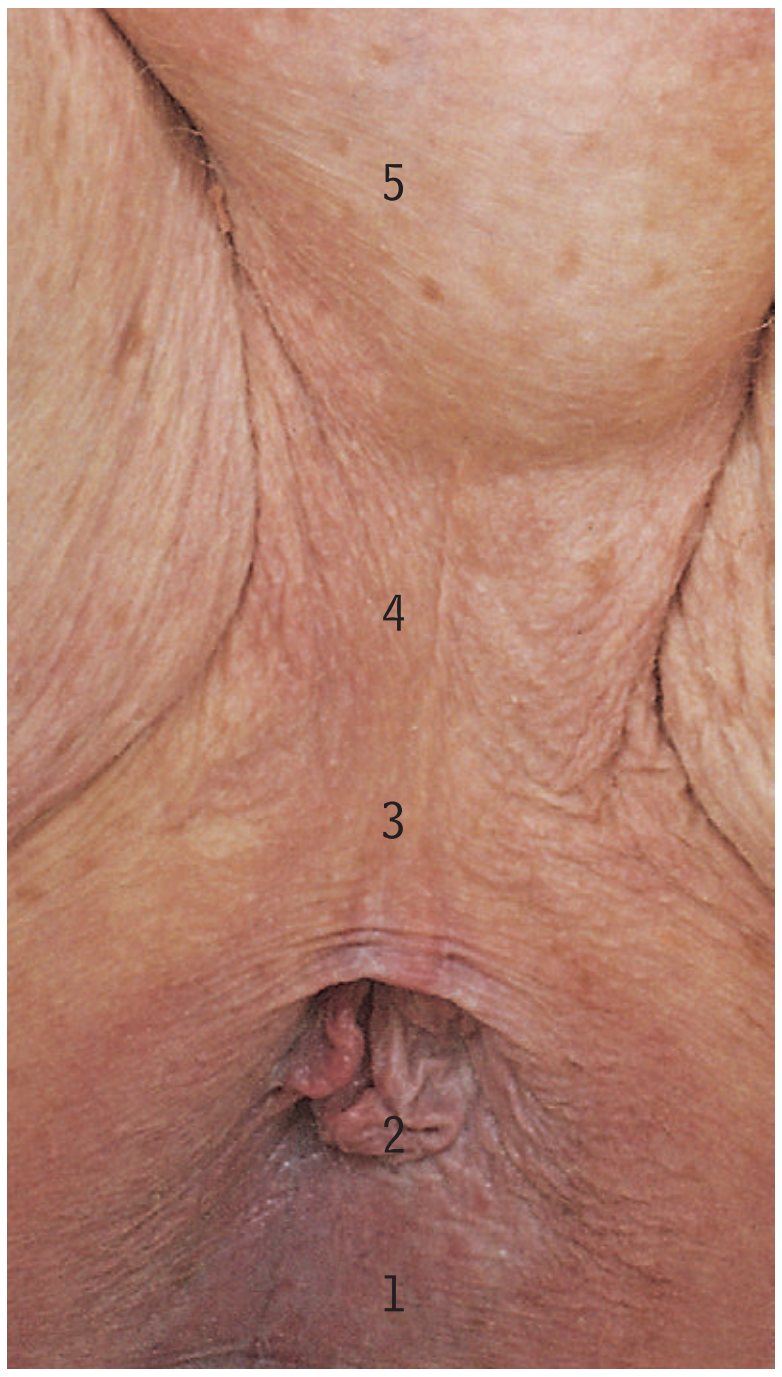

The central area is shown, with the scrotum (5) pulled upwards and forwards.

1 Anococcygeal body
2 Margin of anus, with skin tags
3 Perineal body
4 Raphe overlying bulb of penis
5 Scrotum overlying right testis

Skin tags are often the remnants of previous haemorrhoids.

B Root of the penis *from below and in front*

The front part of the penis has been removed to show the root, formed by the two corpora cavernosa dorsally (2) and the single corpus spongiosum ventrally (3) containing the urethra (14).

1 Bulbospongiosus
2 Corpus cavernosum
3 Corpus spongiosum
4 Deep dorsal vein of penis
5 Dorsal artery of penis
6 Dorsal nerve of penis
7 External anal sphincter
8 Inferior rectal vessels and nerve crossing ischio-anal fossa
9 Ischiocavernosus
10 Ischiopubic ramus
11 Perineal body
12 Pubic symphysis
13 Superficial transverse perineal muscle overlying perineal membrane
14 Urethra

Cytoscopic view of urethra

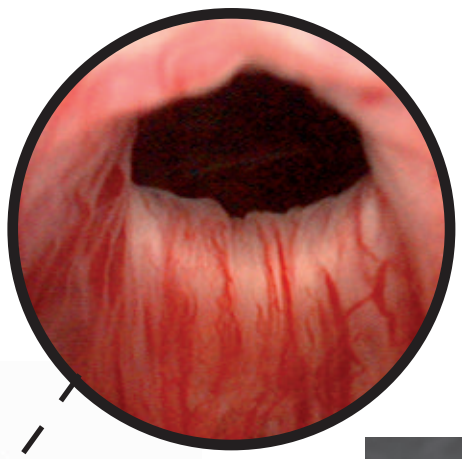

B

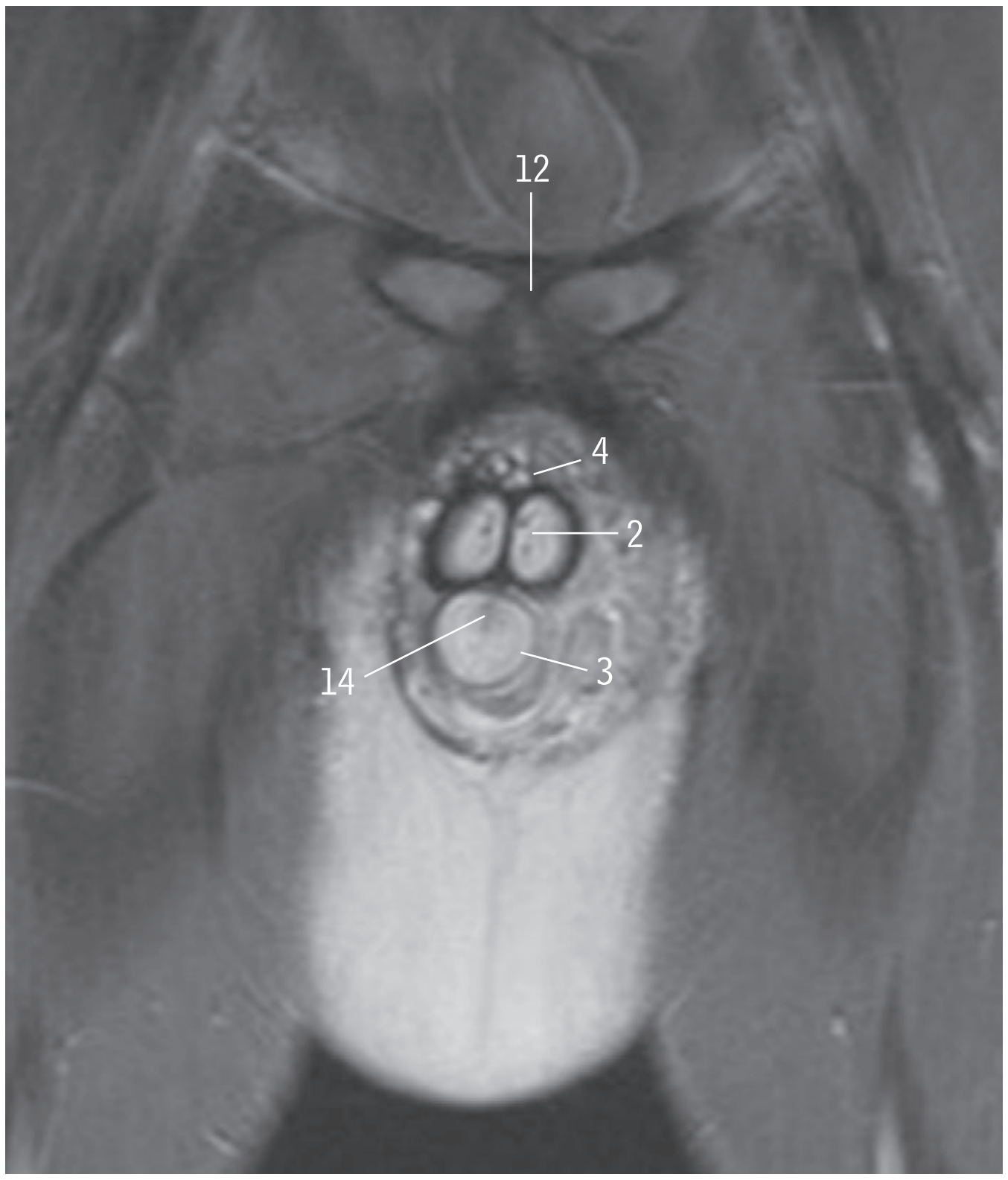

MR, penis

Bulbourethral glands, carcinoma of the anus, hydrocoele, hypospadias, imperforate anus, see *pages 280–284.*

Male perineum and ischio-anal (ischiorectal) fossae from below

All the fat has been removed from the ischio-anal fossae so that a clear view is obtained of the perineal surface of levator ani (14) and of the vessels and nerves within the fossae. On the left side (right of the picture) the perineal membrane (22) is intact but on the right side it, and the underlying muscle (urogenital diaphragm), have been removed.

1 Adductor longus
2 Adductor magnus
3 Anococcygeal body
4 Artery to bulb
5 Bulbospongiosus overlying bulb of penis
6 Corpus cavernosum of penis
7 Corpus spongiosum of penis
8 Dorsal nerve and artery of penis
9 Gluteus maximus
10 Gracilis
11 Inferior rectal vessels and nerve in ischio-anal fossa
12 Internal pudendal artery
13 Ischiocavernosus overlying crus of penis
14 Levator ani
15 Margin of anus
16 Perforating cutaneous nerve
17 Perineal artery
18 Perineal branch of posterior femoral cutaneous nerve
19 Perineal nerve
20 Posterior scrotal vessels and nerves
21 Sacrotuberous ligament
22 Superficial transverse perineal muscle overlying posterior border of perineal membrane

In both sexes, the ischio-anal (ischiorectal) fossa has the pudendal canal in its lateral wall. The canal has been opened up to display its contents: the internal pudendal artery (12) and the terminal branches of the pudendal nerve – the perineal nerve (19) and the dorsal nerve of the penis (8) or clitoris.

Lithotomy position

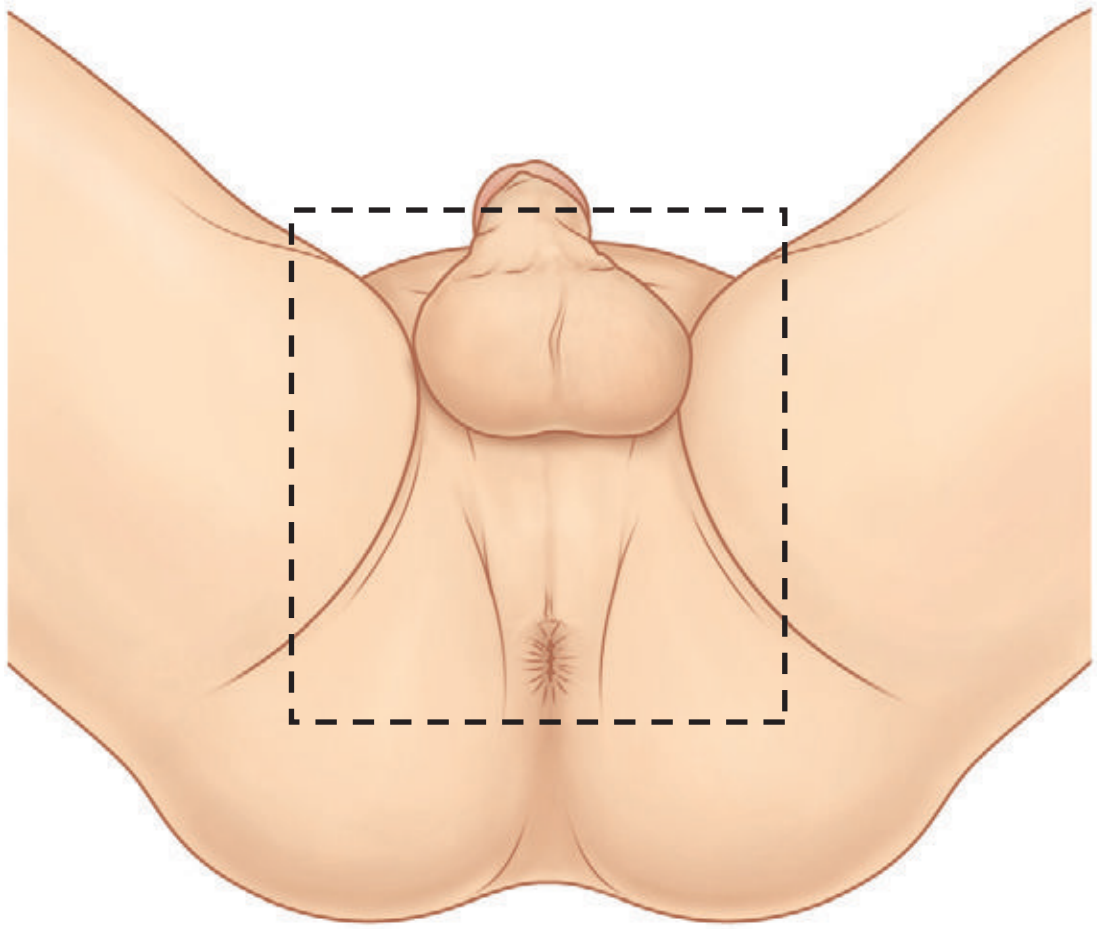

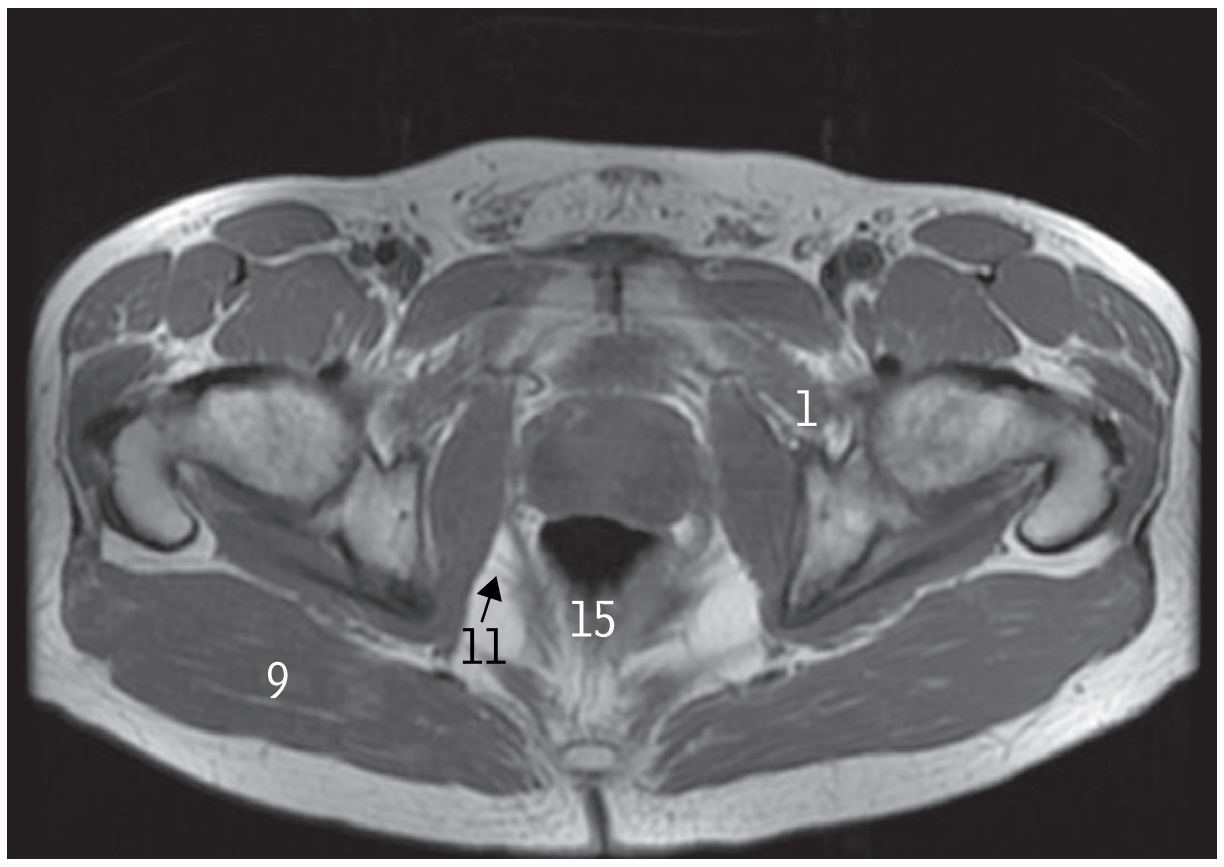

Axial MR, pelvis

Priapism, see pages 280–284.

Abdomen and pelvis

Clinical thumbnails, see website for details and further clinical images to download into your own notes.

Abdominal aortic aneurysm

Abdominal vasculature variations

Acute salpingitis

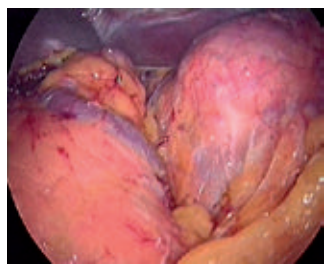
Adrenal gland pathology

Anorectal abscesses

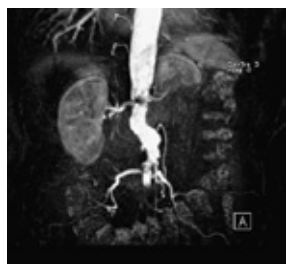
Aortic bruits

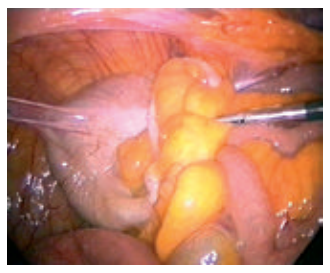
Appendicitis

Ascites

Bartholin's abscess

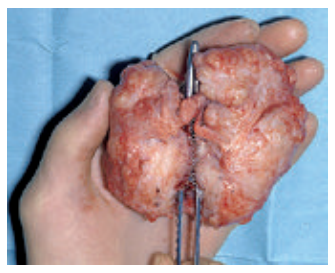
Benign prostatic hyperplasia

Bone marrow aspiration

Bowel ischaemia

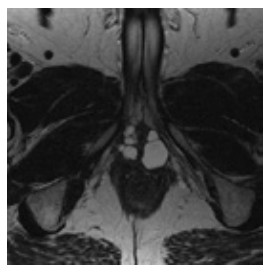
Bulbourethral glands

Caput medusae

Carcinoma of the anus

Carcinoma of the bladder

Carcinoma of the large bowel

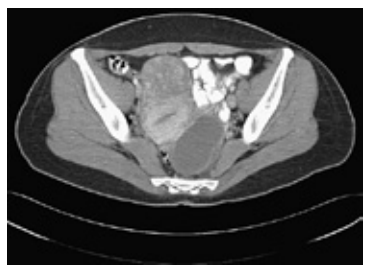
Carcinoma of the ovary

Carcinoma of the pancreas

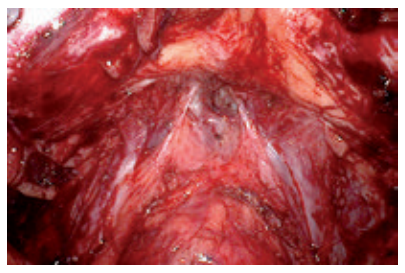
Carcinoma of the prostate

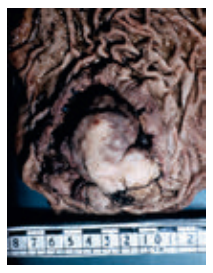
Carcinoma of the stomach

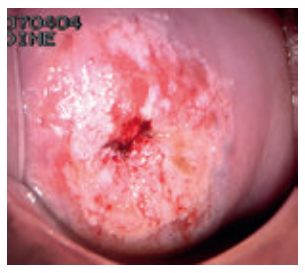
Carcinoma of the uterus

Cervical smear

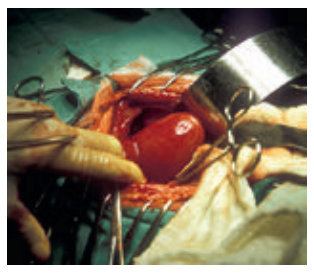
Cholecystectomy

Circumcision

Cirrhosis of liver

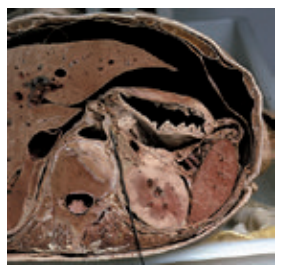
Coeliac plexus block

Colonic stents

Colostomy

Congenital kidney variants

Cushing striations

Cystitis

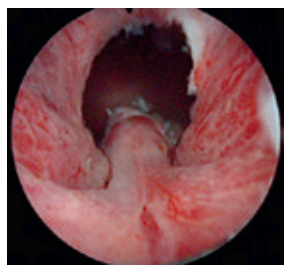
Cystoscopy

Diverticular disease

Drainage of subphrenic abscesses

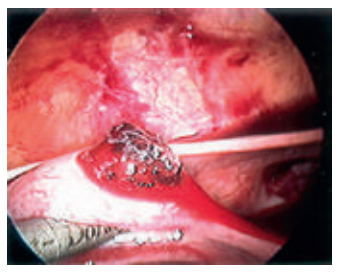
Ectopic pregnancy rupture

Episiotomy

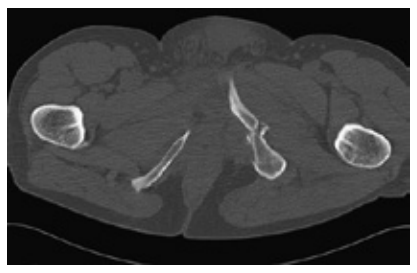
Extravasation of urine

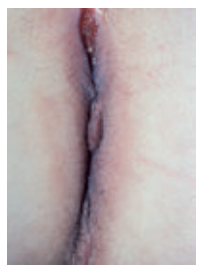
Faecal continence

Female genital circumcision

Femoral hernia

Fournier's gangrene

Gallstones

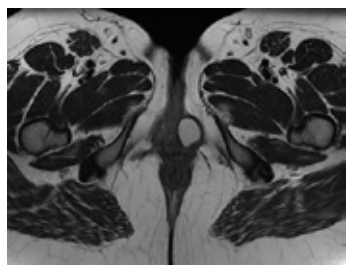
Gartner's duct cyst in vaginal wall

Gastric pacemaker

Genital ambiguous development

Haematoma of the rectus sheath

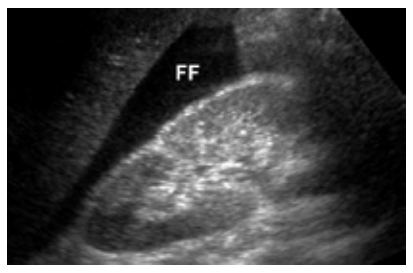

Haemoperitoneum

Haemorrhoids

Hiatus hernia

Hydrocele

Hypospadias

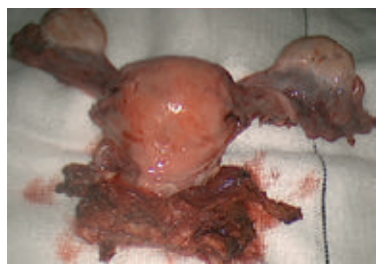
Hysterectomy

Imperforate anus

Indirect inguinal hernia

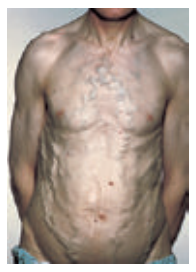
Inferior vena cava (IVC) obstruction

Inguinal hernia

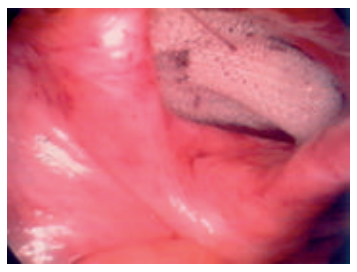
Inguinal hernia repair

Inguinal lymphadenopathy

Internal Iliac embolisation

Intrauterine contraceptive devices (IUCDs)

Intussusception

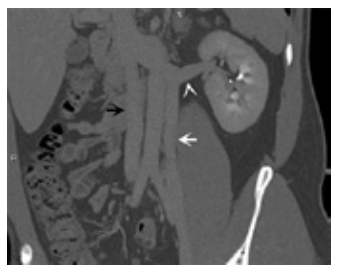
IVC duplication

Laparoscopy

Ligation–uterine tubes

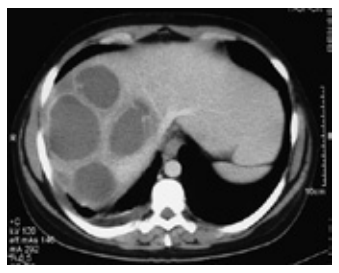
Liver abscess

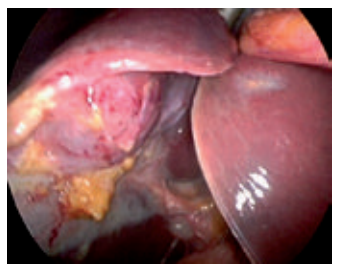
Liver biopsy

Liver trauma

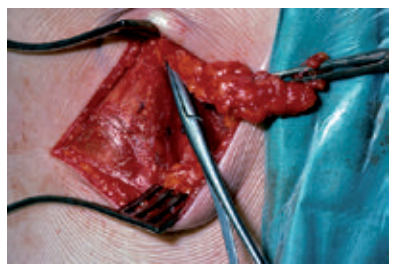
Lumbar hernia

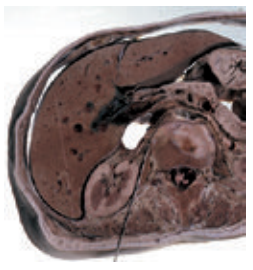
Lumbar sympathectomy

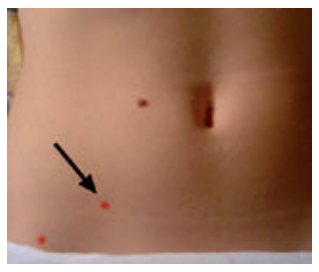
McBurney's point

Meckel's diverticulum

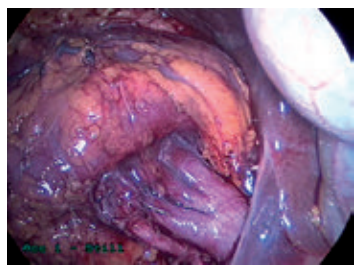
Nephrectomy

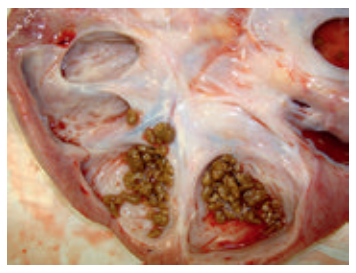
Nephrocalcinosis

Obturator hernia

Oesophageal varices

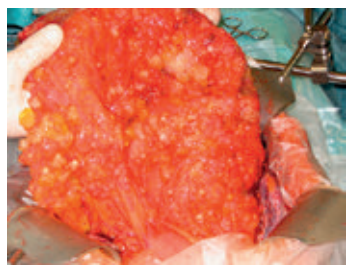
Omental cake

Omphalocele

Ovarian dermoid

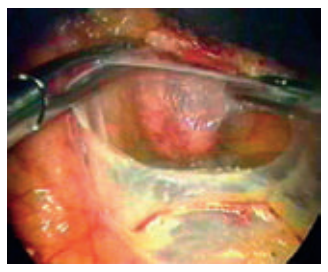
Pancreatic pathology

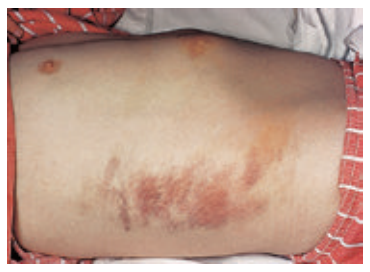
Pancreatitis

Peritoneal lavage

Peritonitis

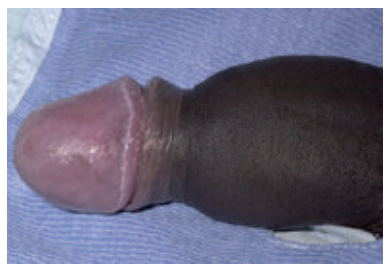
Phimosis and paraphimosis

Pneumoretroperi-toneum

Postnatal umbilical vein catheter

Priapism

Proctoscopy and sigmoidoscopy

Psoas abscess

Pudendal block

Pyloric stenosis (adult)

Rectal (PR) examination

Rectal prolapse

Rectosigmoid foreign bodies

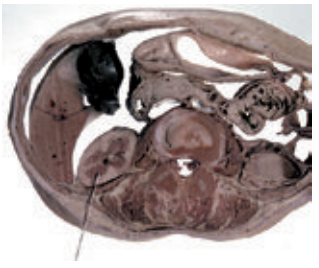
Renal biopsy

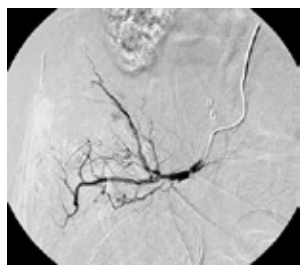
Renal carcinoma

Renal trauma

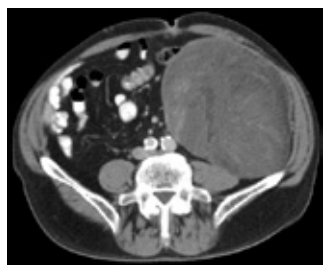
Retroperitoneal bleed

Retroperitoneal fibrosis

Riedel’s lobe

Ruptured spleen

Sacral nerve stimulation

Scrotal swellings

Situs inversus totalis

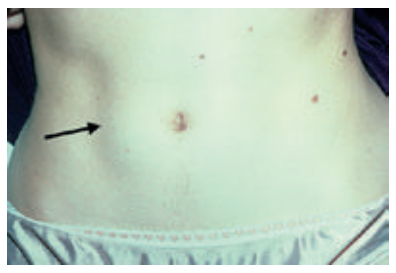
Spigelian hernia

Splenectomy

Splenic cysts

Splenic infarct

Splenomegaly

Splenunculi

Superior mesenteric artery syndrome

Support of the pelvic viscera

Testicular torsion

Transurethral resection of the prostate (TURP)

Umbilical and paraumbilical hernia

Unsafe abortion

Ureteric variants

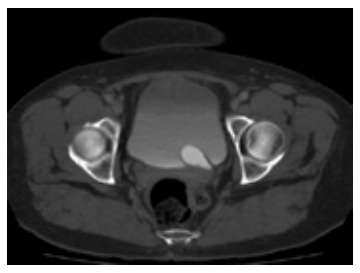
Ureterocele

Urethral stricture

Urinary tract calculi

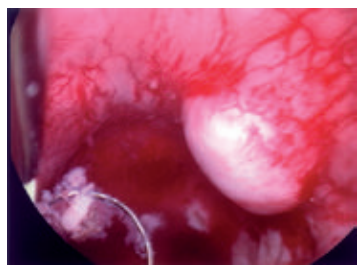
Uterine fibroids

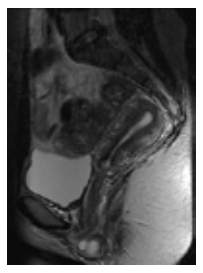
Uterine variants

Vaginal examination

Vagotomy

Varicella-zoster virus infection – abdominal wall

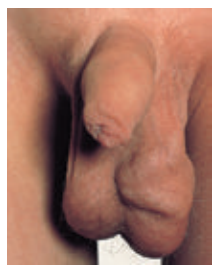
Varicocele


Vasectomy

Volvulus

Lower limb

6

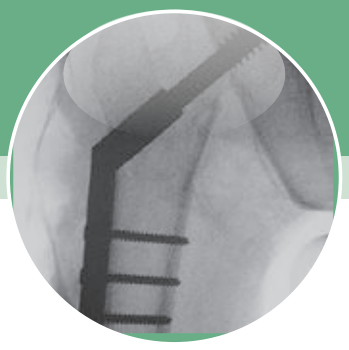

Lower limb Ⓐ *surface anatomy, from the front* Ⓑ *dissection, from the front* Ⓒ *dissection, from behind* Ⓓ *dissection, from the lateral side* Ⓔ *skeleton, from the lateral side*

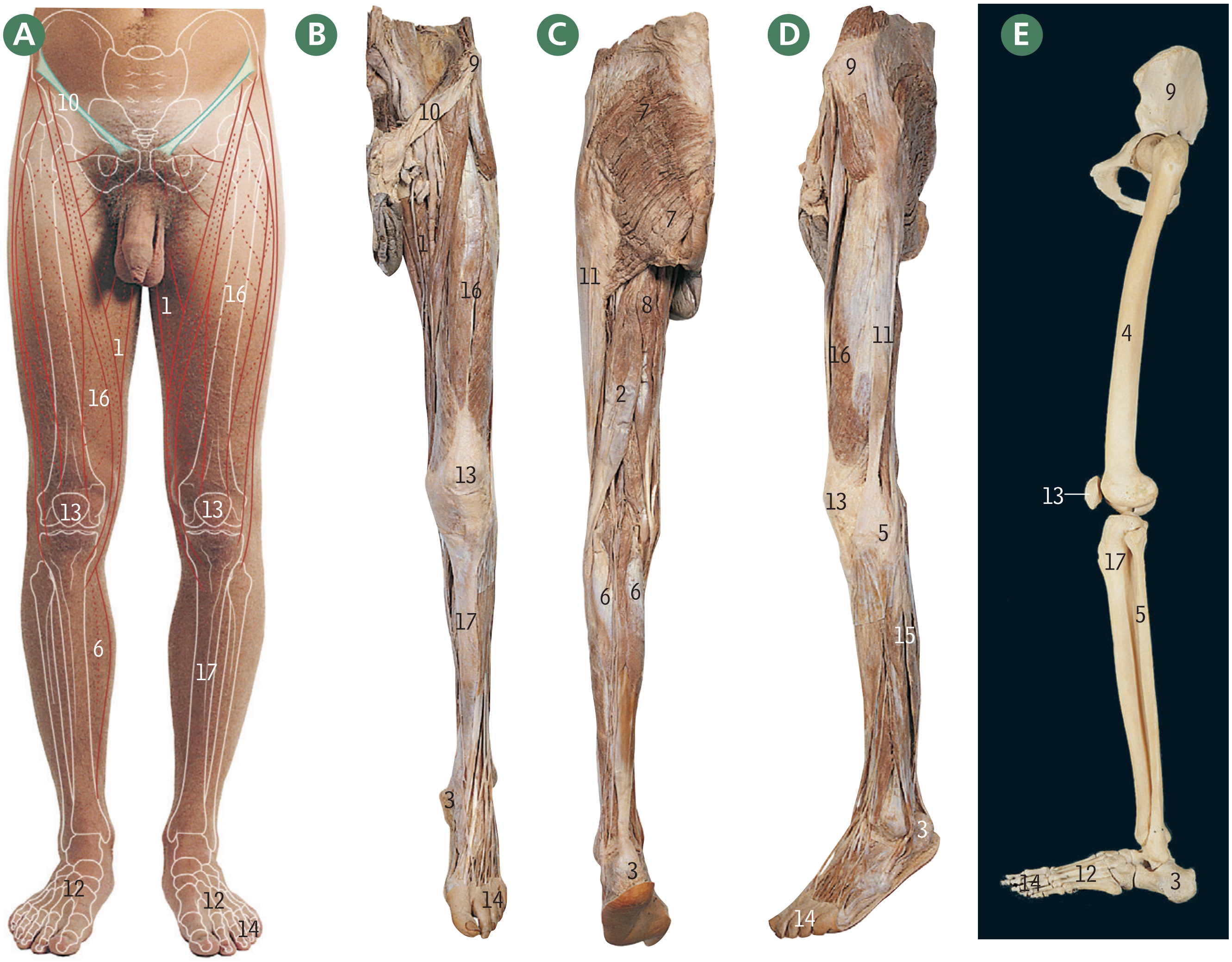

1 Adductors
2 Biceps femoris
3 Calcaneus
4 Femur
5 Fibula
6 Gastrocnemius
7 Gluteus maximus
8 Hamstrings
9 Hip bone
10 Inguinal ligament
11 Iliotibial tract
12 Metatarsal bones
13 Patella
14 Phalanges of toes
15 Peroneus (fibularis)
16 Quadriceps
17 Tibia

Left hip bone *lateral surface*

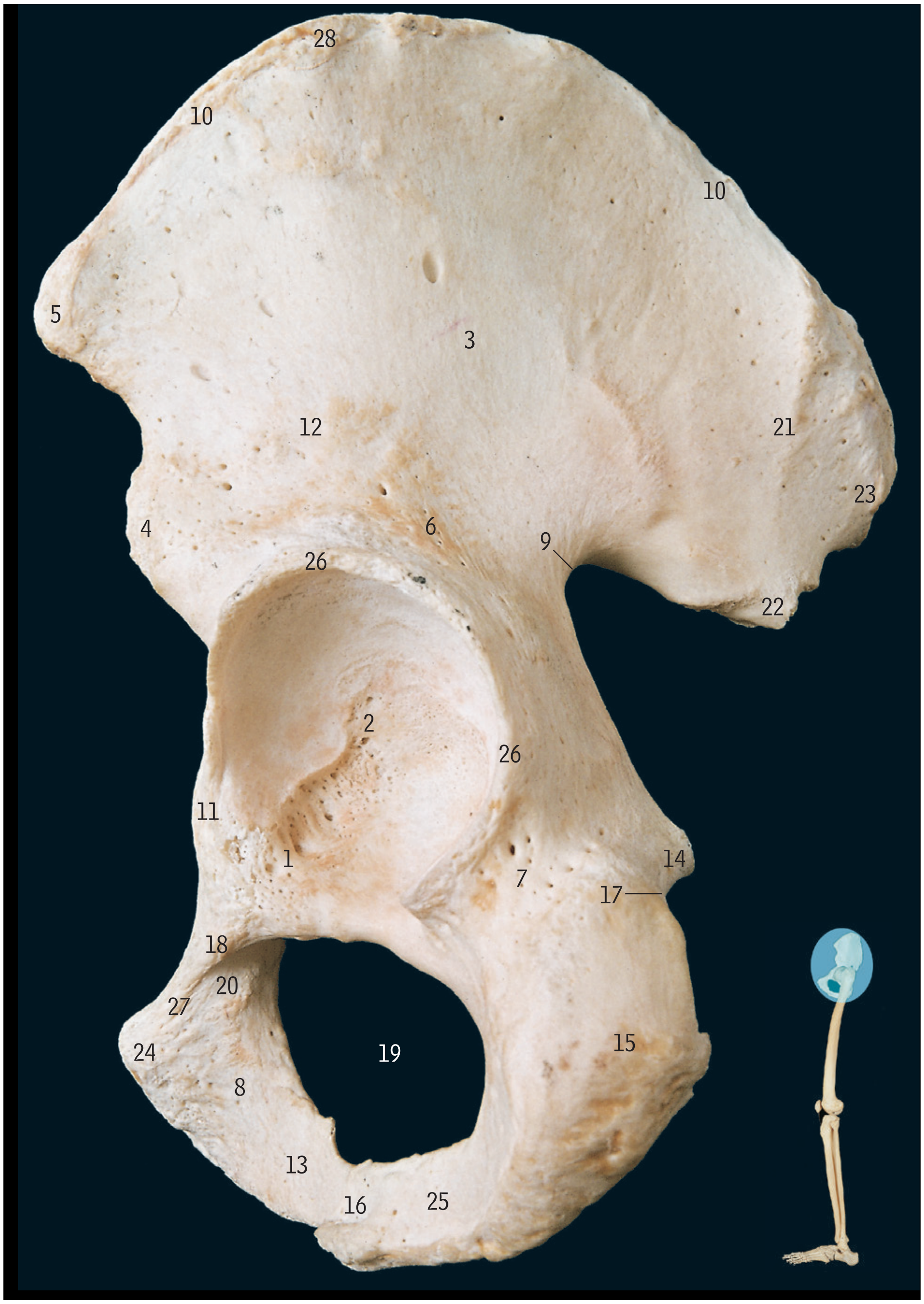

1 Acetabular notch
2 Acetabulum
3 Anterior gluteal line
4 Anterior inferior iliac spine
5 Anterior superior iliac spine
6 Body of ilium
7 Body of ischium
8 Body of pubis
9 Greater sciatic notch
10 Iliac crest
11 Iliopubic eminence
12 Inferior gluteal line
13 Inferior ramus of pubis
14 Ischial spine
15 Ischial tuberosity
16 Joint between 25 and 13
17 Lesser sciatic notch
18 Obturator crest
19 Obturator foramen
20 Obturator groove
21 Posterior gluteal line
22 Posterior inferior iliac spine
23 Posterior superior iliac spine
24 Pubic tubercle
25 Ramus of ischium
26 Rim of acetabulum
27 Superior ramus of pubis
28 Tubercle of iliac crest

The hip (innominate) bone is formed by the union of the ilium (6), ischium (7) and pubis (8).

The two hip bones articulate in the midline anteriorly at the pubic symphysis; posteriorly they are separated by the sacrum, forming the sacro-iliac joints. The two hip bones with the sacrum and coccyx constitute the pelvis (see page 92).

Left hip bone *attachments, lateral surface*

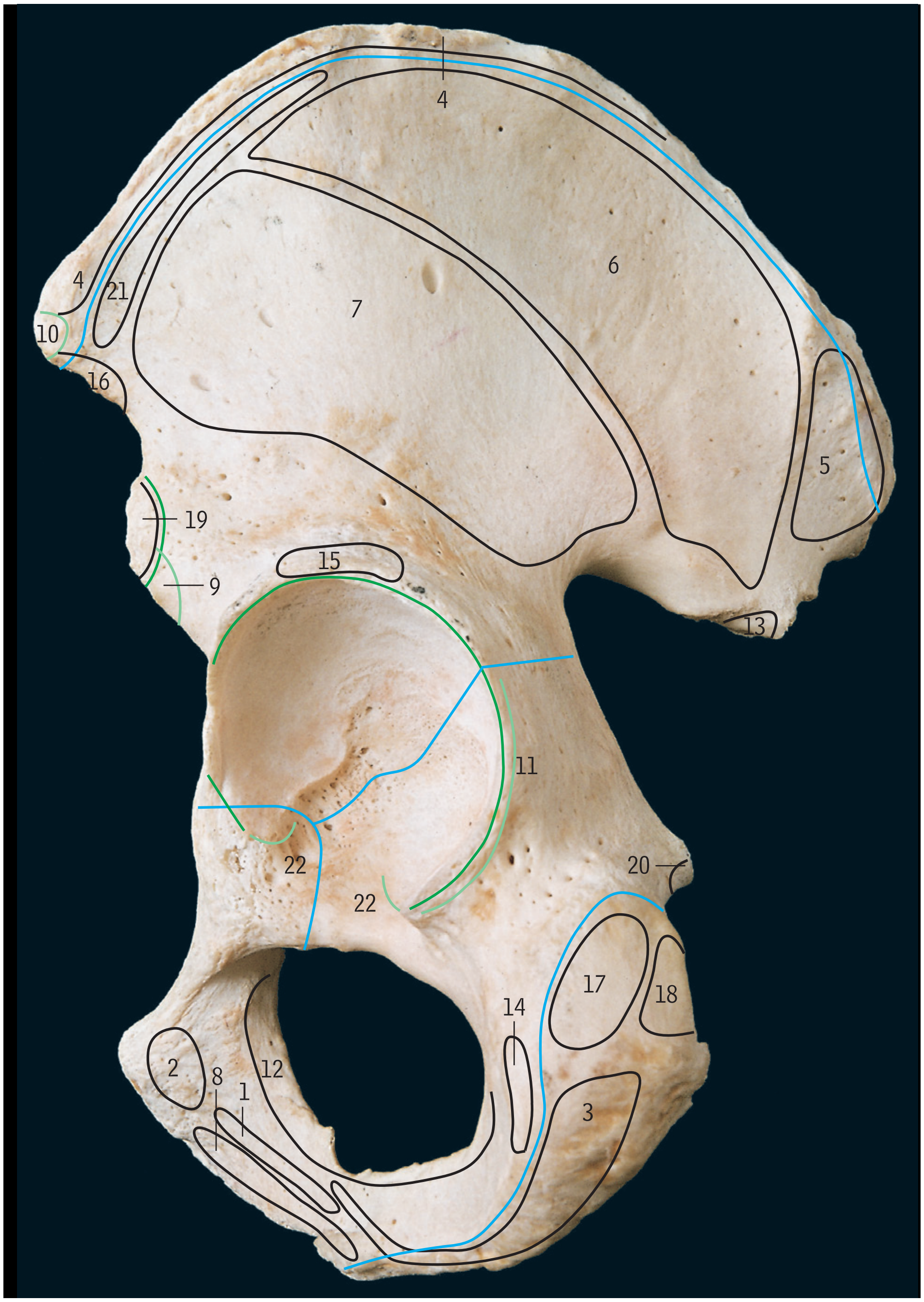

Blue lines, epiphysial lines
Green lines, capsular attachment of hip joint
Pale green lines, ligament attachments

1 Adductor brevis
2 Adductor longus
3 Adductor magnus
4 External oblique
5 Gluteus maximus
6 Gluteus medius
7 Gluteus minimus
8 Gracilis
9 Iliofemoral ligament
10 Inguinal ligament
11 Ischiofemoral ligament
12 Obturator externus
13 Piriformis
14 Quadratus femoris
15 Reflected head of rectus femoris
16 Sartorius
17 Semimembranosus
18 Semitendinosus and long head of biceps femoris
19 Straight head of rectus femoris
20 Superior gemellus
21 Tensor fasciae latae
22 Transverse ligament

Left hip bone *medial surface*

1 Anterior inferior iliac spine
2 Anterior superior iliac spine
3 Arcuate line
4 Auricular surface
5 Body of ischium
6 Body of pubis
7 Greater sciatic notch
8 Iliac crest
9 Iliac fossa
10 Iliac tuberosity
11 Iliopubic eminence
12 Ischial spine
13 Ischial tuberosity
14 Ischiopubic ramus
15 Lesser sciatic notch
16 Obturator foramen
17 Obturator groove
18 Pecten of pubis (pectineal line)
19 Posterior inferior iliac spine
20 Posterior superior iliac spine
21 Pubic crest
22 Pubic tubercle
23 Superior ramus of pubis

The auricular surface of the ilium (4) is the articular surface for the sacro-iliac joint.

The greater sciatic notch (7) is more hooked (J-shaped) in the male, whereas the female notch is more right-angled (L-shaped).

Left hip bone *attachments, medial surface*

Blue lines, epiphysial lines
Green line, capsular attachment of sacro-iliac joint
Pale green lines, ligament attachments

1 Coccygeus and sacrospinous ligament
2 Erector spinae
3 Falciform process of sacrotuberous ligament
4 Iliacus
5 Iliolumbar ligament
6 Inferior gemellus
7 Inguinal ligament
8 Interosseous sacro-iliac ligament
9 Levator ani
10 Obturator internus
11 Psoas minor
12 Pubic symphysis
13 Quadratus lumborum
14 Sacrotuberous ligament
15 Sartorius
16 Sphincter urethrae
17 Straight head of rectus femoris
18 Superficial transverse perineal and ischiocavernosus
19 Transversus abdominis

Left hip bone *from above*

1 Anterior inferior iliac spine
2 Anterior superior iliac spine
3 Arcuate line
4 Auricular surface
5 Iliac crest
6 Iliac fossa
7 Iliopubic eminence
8 Ischial spine
9 Pecten of pubis (pectineal line)
10 Posterior inferior iliac spine
11 Posterior superior iliac spine
12 Pubic crest
13 Pubic tubercle
14 Tubercle of iliac crest

The arcuate line on the ilium (3) and the pecten and crest of the pubis (9 and 12) form part of the brim of the pelvis (the rest of the brim being formed by the promontory and upper surface of the lateral part of the sacrum – see pages 90 and 92).

The pecten of the pubis (9) is more commonly called the pectineal line.

Left hip bone *attachments, from above*

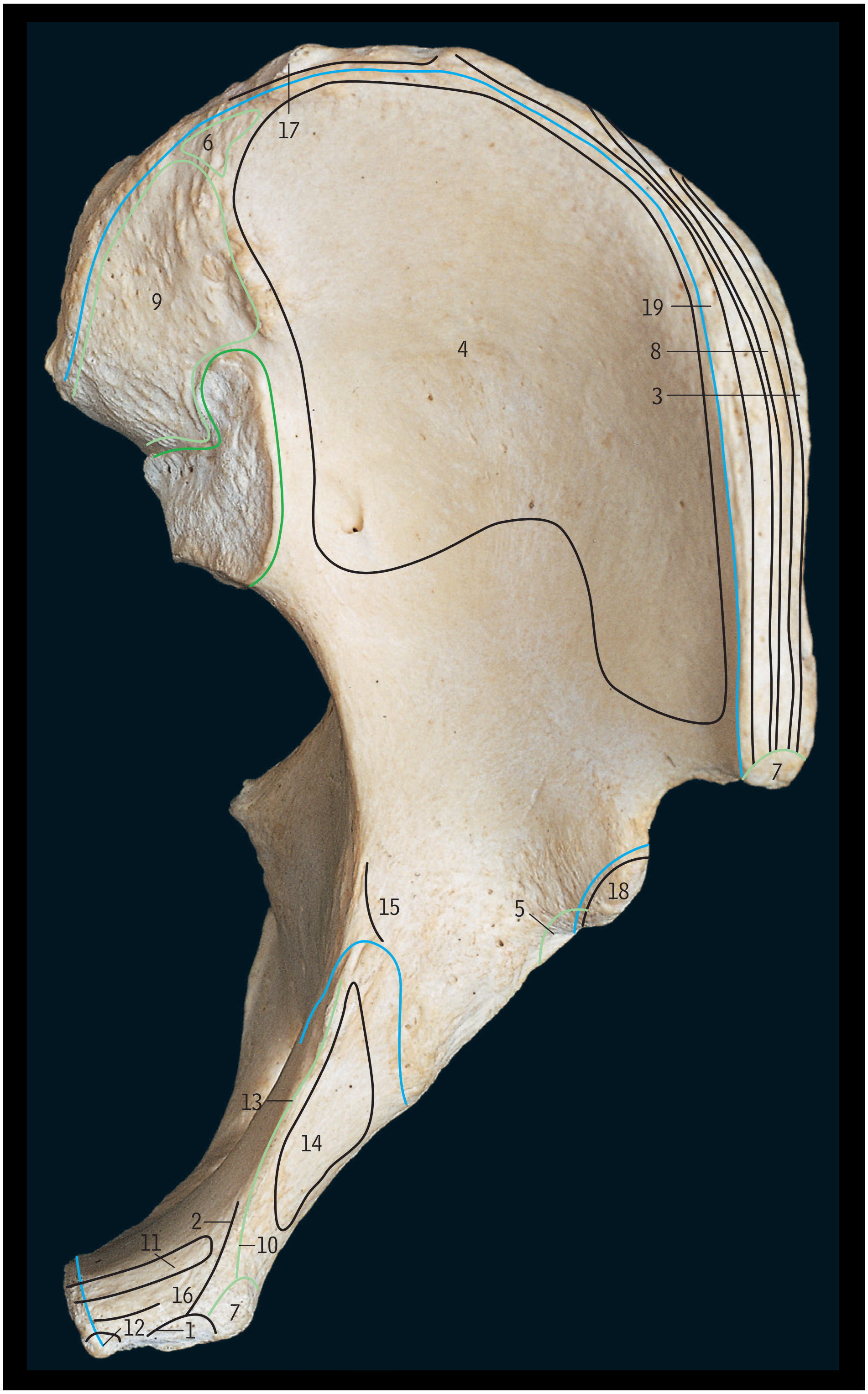

Blue lines, epiphysial lines
Green line, capsular attachment of sacro-iliac joint
Pale green lines, ligament attachments

1. Anterior wall of rectus sheath
2. Conjoint tendon
3. External oblique
4. Iliacus
5. Iliofemoral ligament
6. Iliolumbar ligament
7. Inguinal ligament
8. Internal oblique
9. Interosseous sacro-iliac ligament
10. Lacunar ligament
11. Lateral head of rectus abdominis
12. Medial head of rectus abdominis
13. Pectineal ligament
14. Pectineus
15. Psoas minor
16. Pyramidalis
17. Quadratus lumborum
18. Straight head of rectus femoris
19. Transversus abdominis

The inguinal ligament (7) is formed by the lower border of the aponeurosis of the external oblique muscle, and extends from the anterior superior iliac spine to the pubic tubercle.

The lacunar ligament (10, sometimes called the pectineal part of the inguinal ligament) is the part of the inguinal ligament that extends backwards from the medial end of the inguinal ligament to the pecten of the pubis.

The pectineal ligament (13) is the lateral extension of the lacunar ligament along the pecten. It is not classified as a part of the inguinal ligament, and must not be confused with the alternative name for the lacunar ligament, i.e. with the pectineal part of the inguinal ligament.

The conjoint tendon (2) is formed by the aponeuroses of the internal oblique and transversus muscles, and is attached to the pubic crest and the adjoining part of the pecten, blending medially with the anterior wall of the rectus sheath.

A Left hip bone *ischial tuberosity, from behind and below*

1 Acetabular notch
2 Acetabulum
3 Ischial spine
4 Ischiopubic ramus
5 Lesser sciatic notch
6 Longitudinal ridge
7 Lower part of tuberosity
8 Obturator groove
9 Rim of acetabulum
10 Transverse ridge
11 Upper part of tuberosity

B Left hip bone *from the front*

1 Acetabular notch
2 Anterior inferior iliac spine
3 Anterior superior iliac spine
4 Body of pubis
5 Iliac fossa
6 Iliopubic eminence
7 Ischial tuberosity
8 Ischiopubic ramus
9 Obturator crest
10 Obturator foramen
11 Obturator groove
12 Pecten of pubis (pectineal line)
13 Pubic crest
14 Pubic tubercle
15 Rim of acetabulum
16 Tubercle of iliac crest

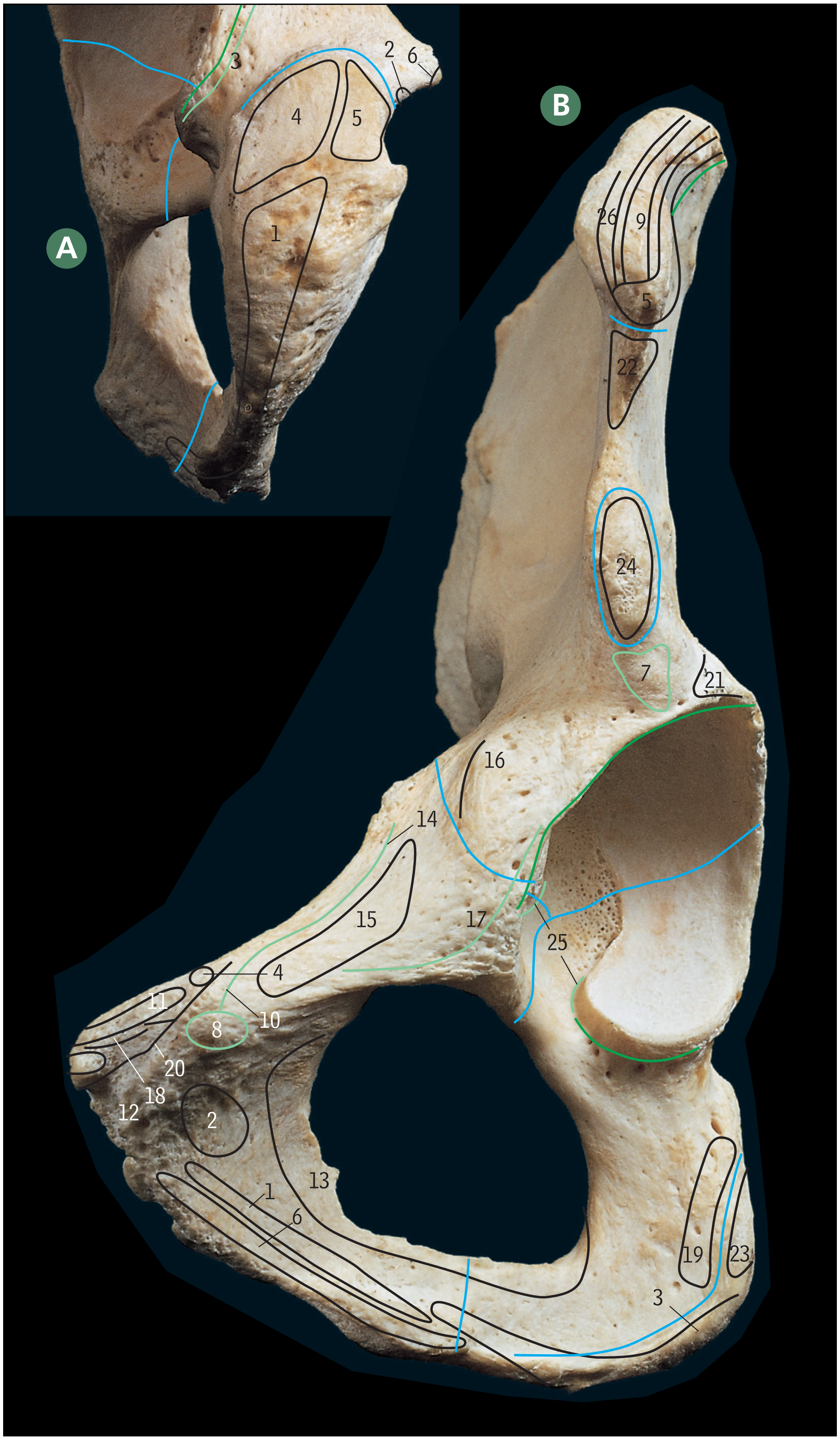

A Left hip bone *attachments, ischial tuberosity, from behind and below*

Blue lines, epiphysial lines
Green line, capsular attachment of hip joint
Pale green lines, ligament attachments

1 Adductor magnus
2 Inferior gemellus
3 Ischiofemoral ligament
4 Semimembranosus
5 Semitendinosus and long head of biceps femoris
6 Superior gemellus

The area on the ischial tuberosity medial to the adductor magnus attachment (1) is covered by fibrofatty tissue and the ischial bursa underlying gluteus maximus.

B Left hip bone *attachments, from the front*

Blue lines, epiphysial lines
Green line, capsular attachment of hip joint
Pale green lines, ligament attachments

1 Adductor brevis
2 Adductor longus
3 Adductor magnus
4 Conjoint tendon
5 External oblique and inguinal ligament
6 Gracilis
7 Iliofemoral ligament
8 Inguinal ligament
9 Internal oblique
10 Lacunar ligament
11 Lateral head of rectus abdominis
12 Medial head of rectus abdominis
13 Obturator externus
14 Pectineal ligament
15 Pectineus
16 Psoas minor
17 Pubofemoral ligament
18 Pyramidalis
19 Quadratus femoris
20 Rectus sheath
21 Reflected head of rectus femoris
22 Sartorius
23 Semimembranosus
24 Straight head of rectus femoris
25 Transverse ligament
26 Transversus abdominis

Left femur *proximal end*

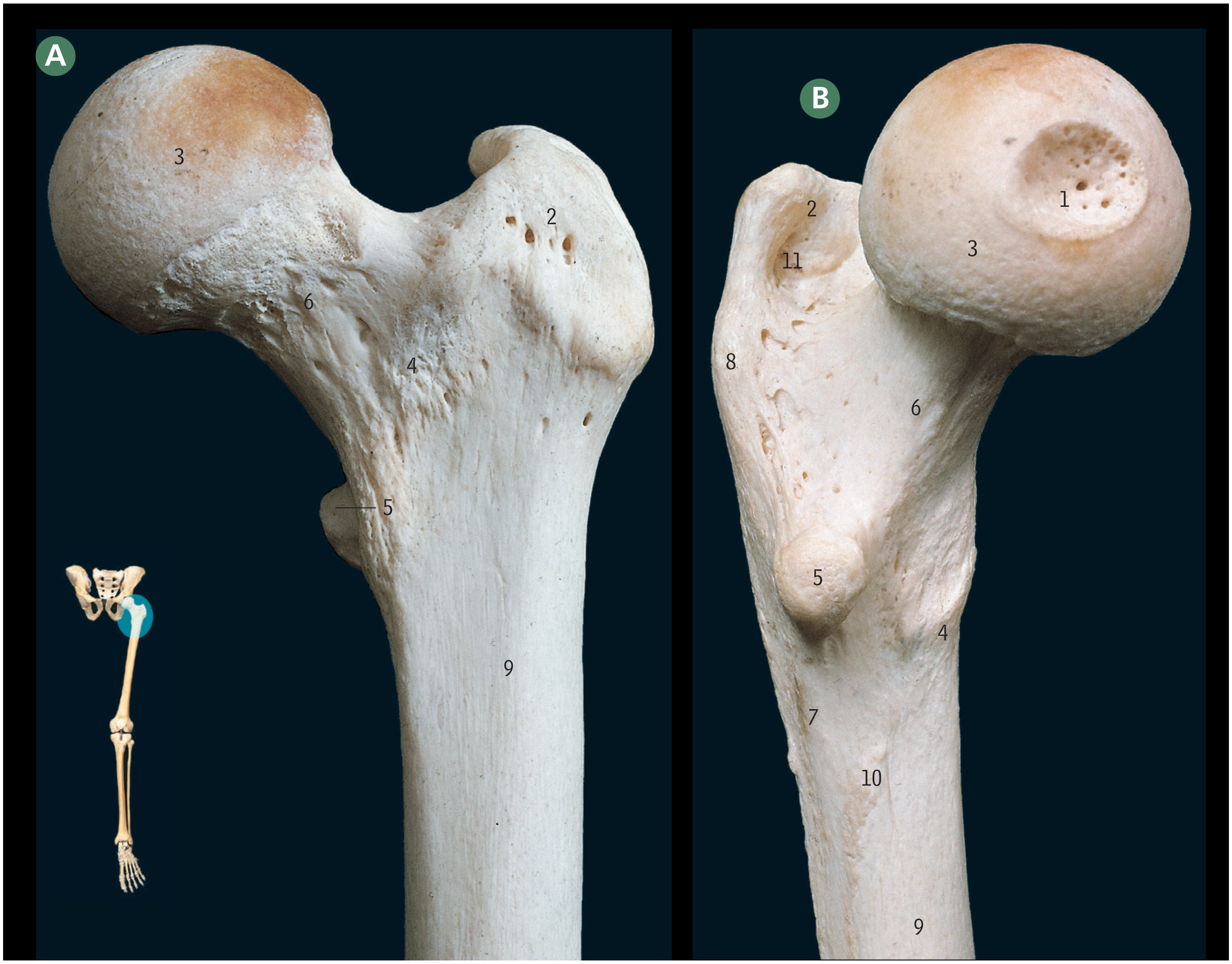

A from the front

B from the medial side

1 Fovea of head
2 Greater trochanter
3 Head
4 Intertrochanteric line
5 Lesser trochanter
6 Neck
7 Pectineal line
8 Quadrate tubercle on intertrochanteric crest
9 Shaft
10 Spiral line
11 Trochanteric fossa

The intertrochanteric *line* (4) is at the junction of the neck (6) and shaft (9) on the anterior surface; the intertrochanteric *crest* is in a similar position on the posterior surface (8, and page 296, A5).

The neck makes an angle with the shaft of about 125° in an adult.

The pectineal line of the femur (7) must not be confused with the pectineal line (pecten) of the pubis (9, page 290), nor with the spiral line of the femur (10) which is usually more prominent than the pectineal line.

Avulsion fractures, see pages 355–357.

Left femur *attachments, proximal end*

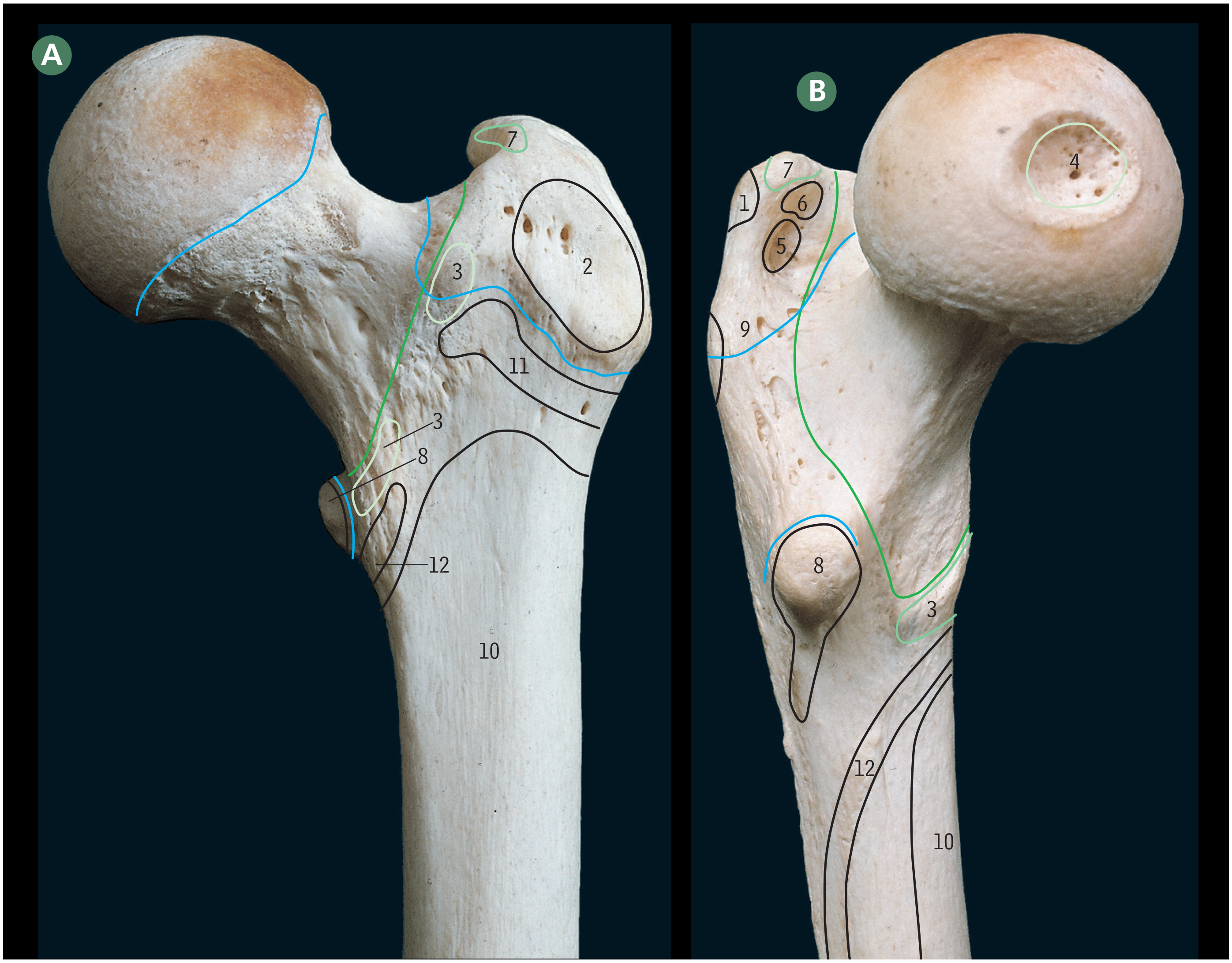

A from the front

B from the medial side

Blue lines, epiphysial lines
Green line, capsular attachment of hip joint
Pale green lines, ligament attachments

1 Gluteus medius
2 Gluteus minimus
3 Iliofemoral ligament
4 Ligament of head of femur
5 Obturator externus
6 Obturator internus and gemelli
7 Piriformis
8 Psoas major and iliacus
9 Quadratus femoris
10 Vastus intermedius
11 Vastus lateralis
12 Vastus medialis

The iliofemoral ligament has the shape of an inverted V, with the stem attached to the anterior inferior iliac spine of the hip bone (page 293, B7), and the lateral and medial bands attached to the upper (lateral) and lower (medial) ends of the intertrochanteric line (page 296, 6), blending with the capsule of the hip joint.

The tendon of psoas major is attached to the lesser trochanter (page 296, 8); many of the muscle fibres of iliacus are inserted into the psoas tendon but some reach the femur below the trochanter.

Intertrochanteric fracture–femur, slipped upper femoral epiphysis, see pages 355–357.

Left femur *proximal end*

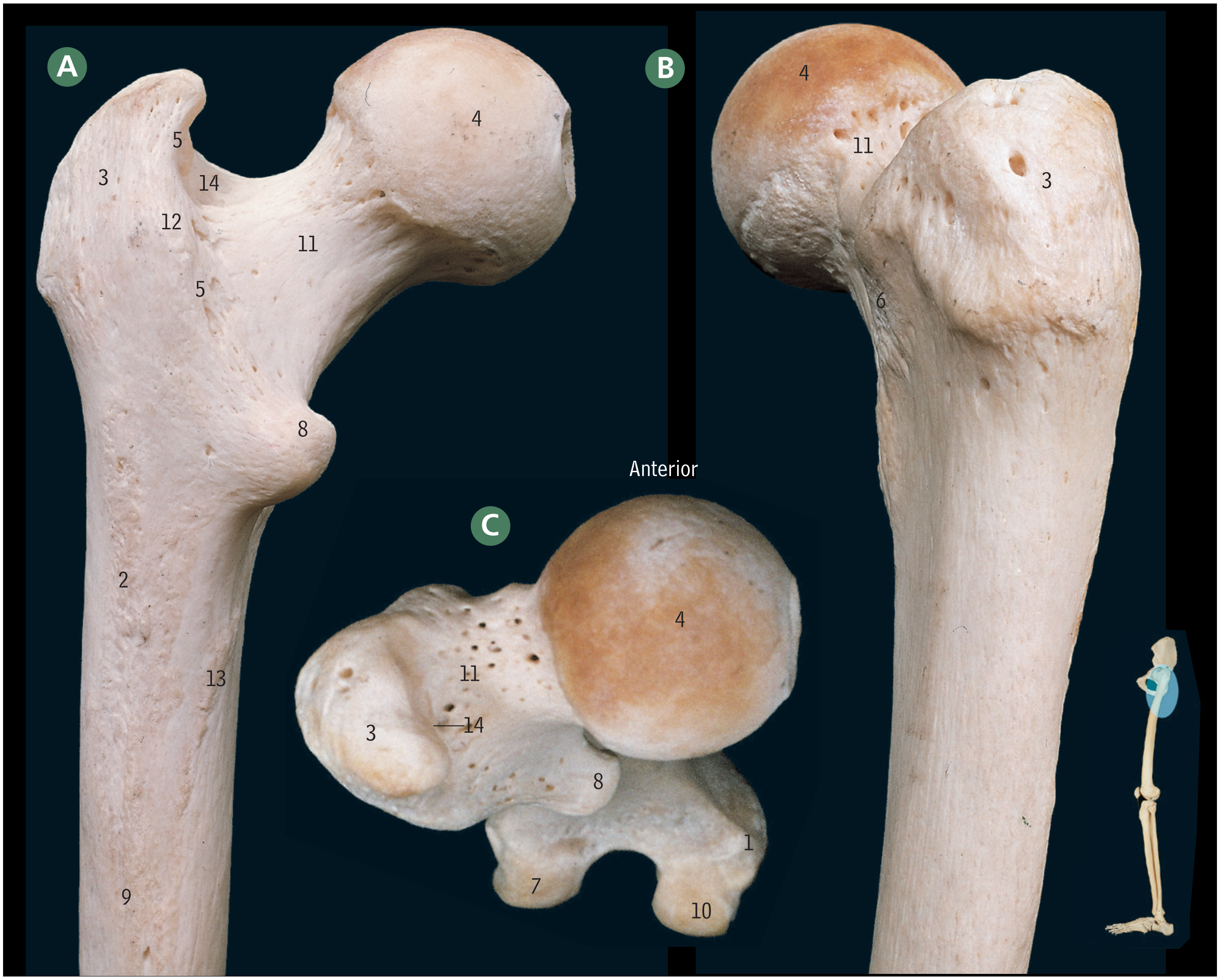

A **from behind**

B **from the lateral side**

C **from above**

1 Adductor tubercle at lower end
2 Gluteal tuberosity
3 Greater trochanter
4 Head
5 Intertrochanteric crest
6 Intertrochanteric line
7 Lateral condyle at lower end
8 Lesser trochanter
9 Linea aspera
10 Medial condyle at lower end
11 Neck
12 Quadrate tubercle
13 Spiral line
14 Trochanteric fossa

The neck of the femur passes forwards as well as upwards and medially (C11), making an angle of about 15° (in the adult) with the transverse axis of the lower end (the angle of femoral torsion or femoral anteversion).

The lesser trochanter (8) projects backwards and medially.

Fracture of the femoral neck, see pages 355–357.

Left femur *attachments, proximal end*

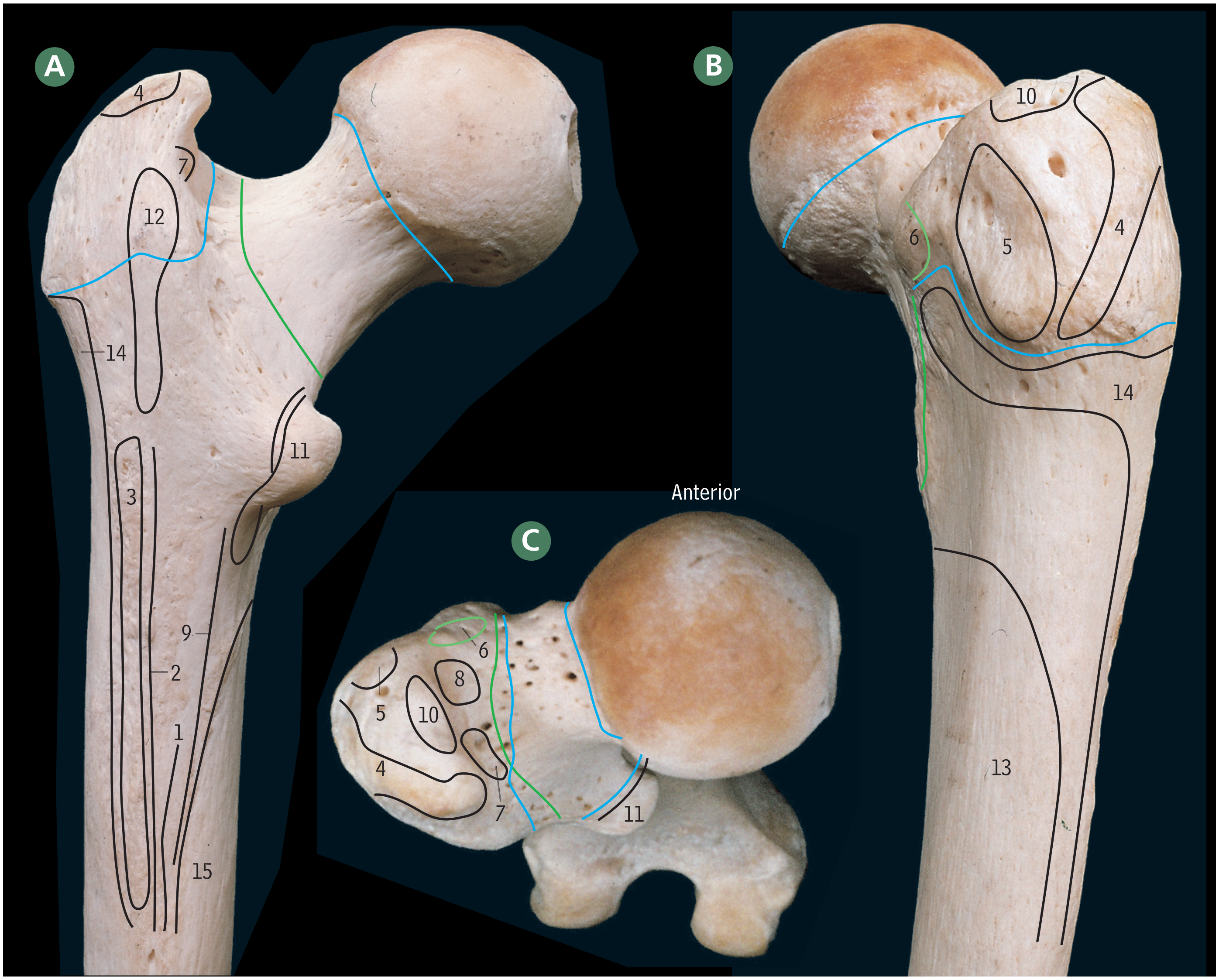

A from behind

B from the lateral side

C from above

Blue lines, epiphysial lines
Green line, capsular attachment of hip joint
Pale green lines, ligament attachments

1 Adductor brevis
2 Adductor magnus
3 Gluteus maximus
4 Gluteus medius
5 Gluteus minimus
6 Iliofemoral ligament (lateral band)
7 Obturator externus
8 Obturator internus and gemelli
9 Pectineus
10 Piriformis
11 Psoas major and iliacus
12 Quadratus femoris
13 Vastus intermedius
14 Vastus lateralis
15 Vastus medialis

On the front of the femur (page 295) the capsule of the hip joint is attached to the intertrochanteric line, but at the back the capsule is attached to the neck of the femur and does not extend as far laterally as the intertrochanteric crest (page 296, A5).

Exostoses femoral spurs, see pages 355–357.

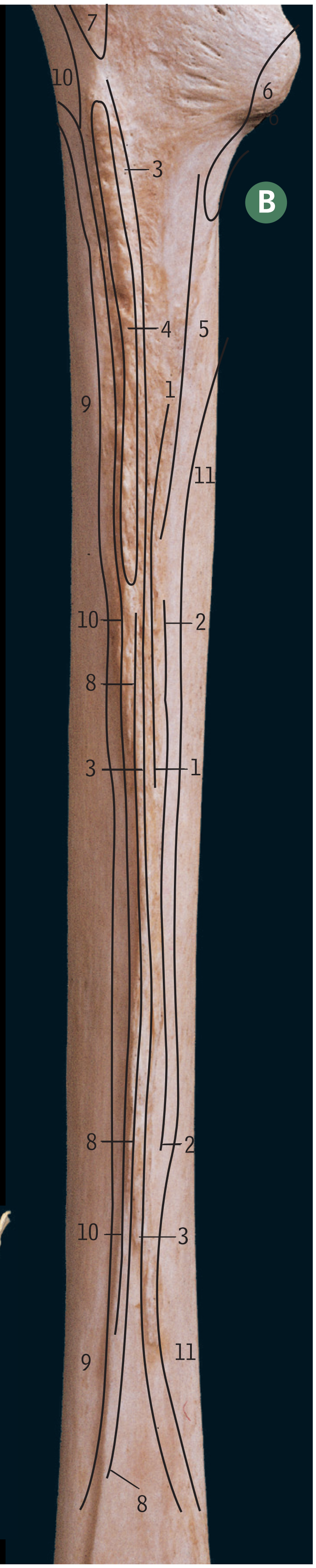

A Left femur *shaft, from behind*

1 Gluteal tuberosity
2 Lateral supracondylar line
3 Lesser trochanter
4 Linea aspera
5 Medial supracondylar line
6 Pectineal line

The rough linea aspera (4) often shows distinct medial and lateral lips; the lateral lip continues upwards as the gluteal tuberosity (1).

B Left femur *attachments, shaft, from behind*

1 Adductor brevis
2 Adductor longus
3 Adductor magnus
4 Gluteus maximus
5 Pectineus
6 Psoas major and iliacus
7 Quadratus femoris
8 Short head of biceps femoris
9 Vastus intermedius
10 Vastus lateralis
11 Vastus medialis

For diagrammatic clarity, the muscle attachments to the linea aspera have been slightly separated.

C Left femur *upper end, from the front*

This is the posterior half of a cleared and bisected specimen, to show the major groups of bone trabeculae.

1 Calcar femorale
2 From lateral surface of shaft to greater trochanter
3 From lateral surface of shaft to head
4 From medial surface of shaft to greater trochanter
5 From medial surface of shaft to head
6 Triangular area of few trabeculae

The calcar femorale (1) is a dense concentration of trabeculae passing from the region of the lesser trochanter to the under-surface of the neck.

Fracture–femoral shaft, see pages 355–357.

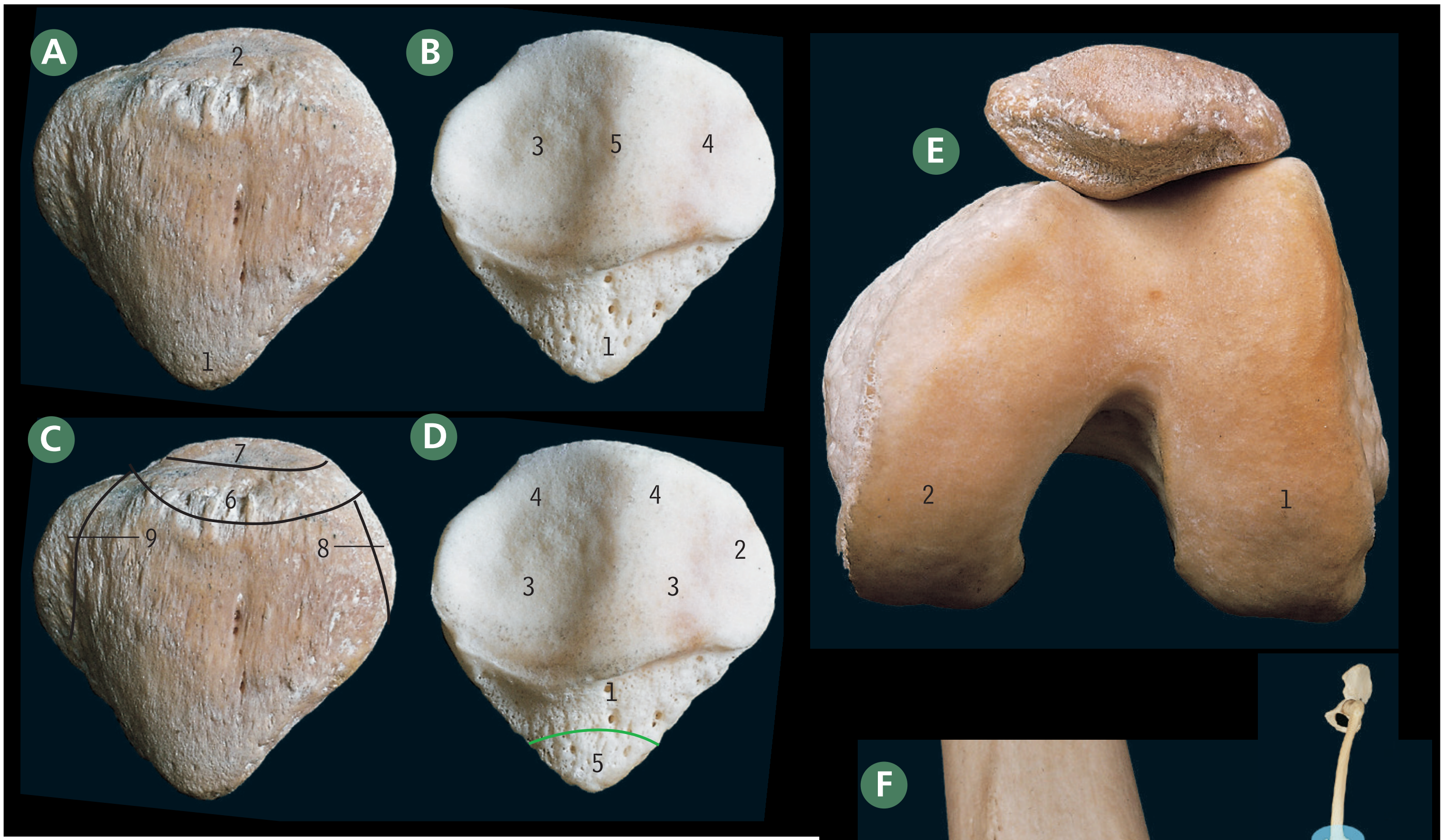

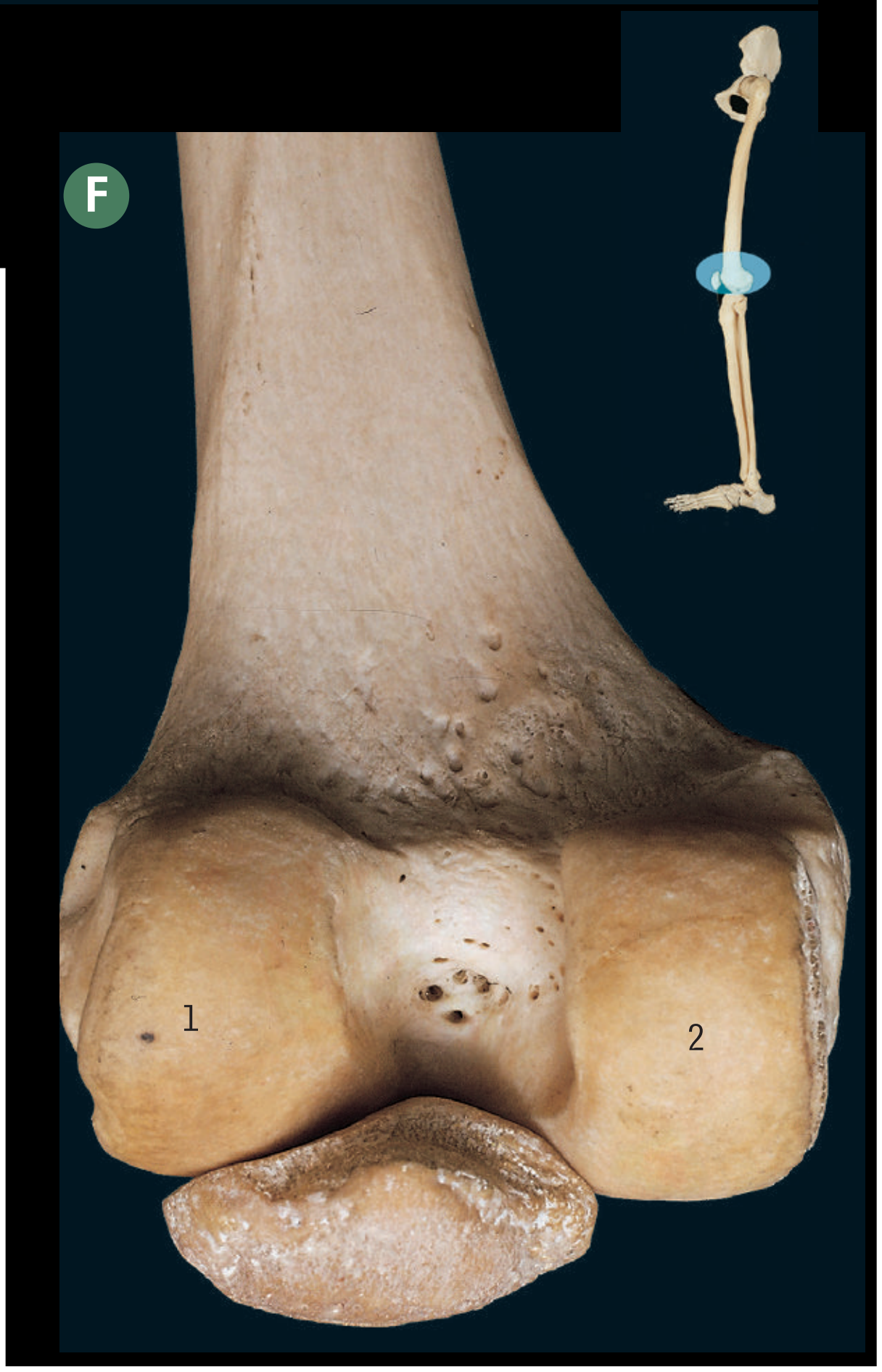

Left patella

A anterior surface **B articular (posterior) surface**

1 Apex
2 Base
3 Facet for lateral condyle of femur
4 Facet for medial condyle of femur
5 Vertical ridge

Left patella *attachments*

C anterior surface **D articular (posterior) surface**

Pale green line, ligament attachment

1 Area for infrapatellar fat pad
2 Area for medial condyle in extreme flexion
3 Facets for femur in extension
4 Facets for femur in flexion
5 Patellar ligament
6 Rectus femoris of quadriceps tendon
7 Vastus intermedius of quadriceps tendon
8 Vastus lateralis of quadriceps tendon
9 Vastus medialis of quadriceps tendon

Left femur and patella *articulated*

E from below with knee extended

F from below and behind with knee flexed

In flexion, note the increased area of contact between the medial condyle of the femur (2) and the patella.

1 Lateral condyle
2 Medial condyle

The most medial facet of the patella (D2) only comes into contact with the medial condyle in extreme flexion as in F.

Bipartite patella, dislocation of the patella, patellar fracture, see pages 355–357.

Left femur *distal end*

A **from the front**

B **from behind**

C **from the medial side**

D **from the lateral side**

1 Adductor tubercle
2 Groove for popliteus tendon
3 Impression for lateral head of gastrocnemius
4 Intercondylar fossa
5 Lateral condyle
6 Lateral epicondyle
7 Lateral supracondylar line
8 Medial condyle
9 Medial epicondyle
10 Medial supracondylar line
11 Patellar surface
12 Popliteal surface

Left femur *attachments, distal end*

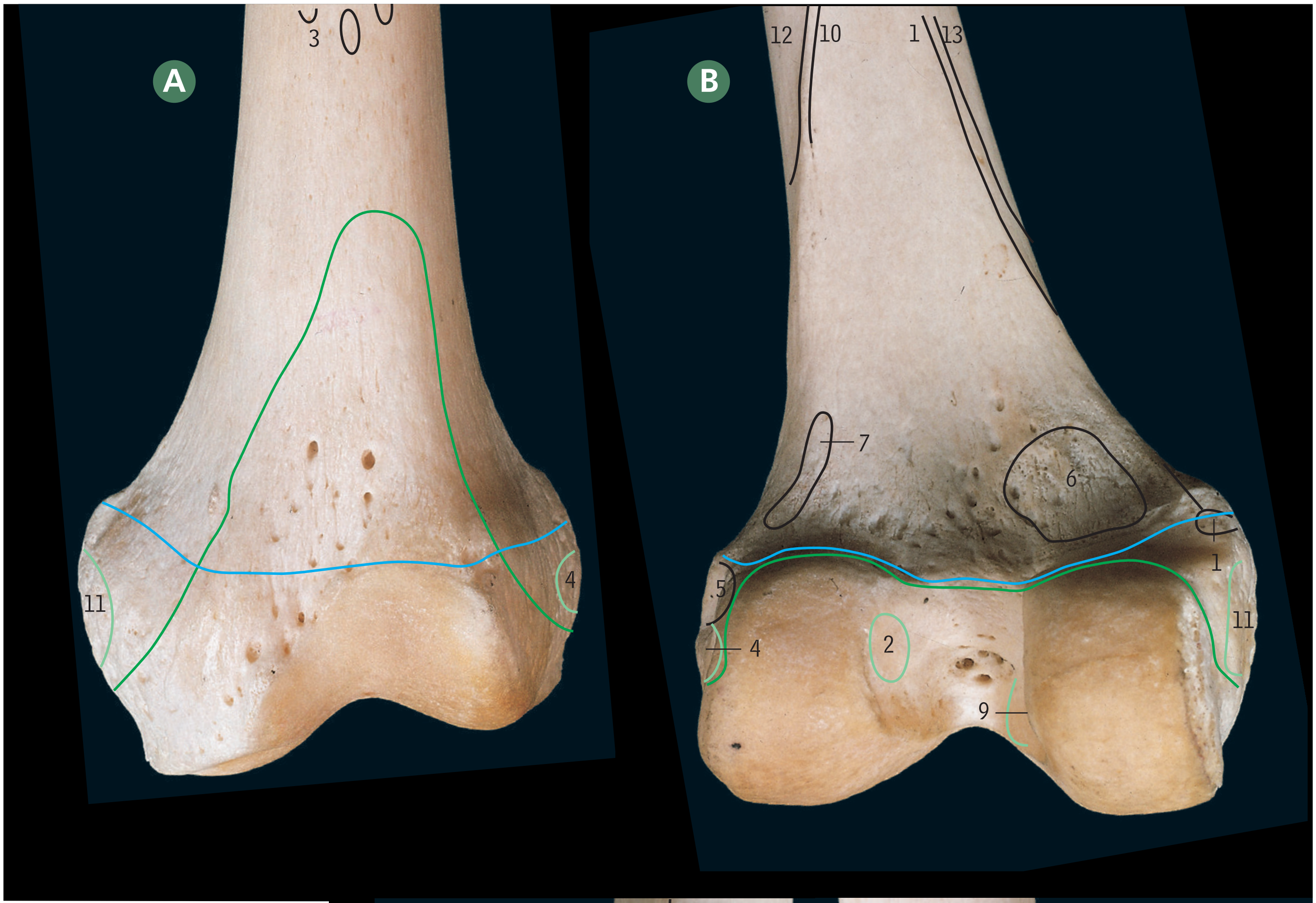

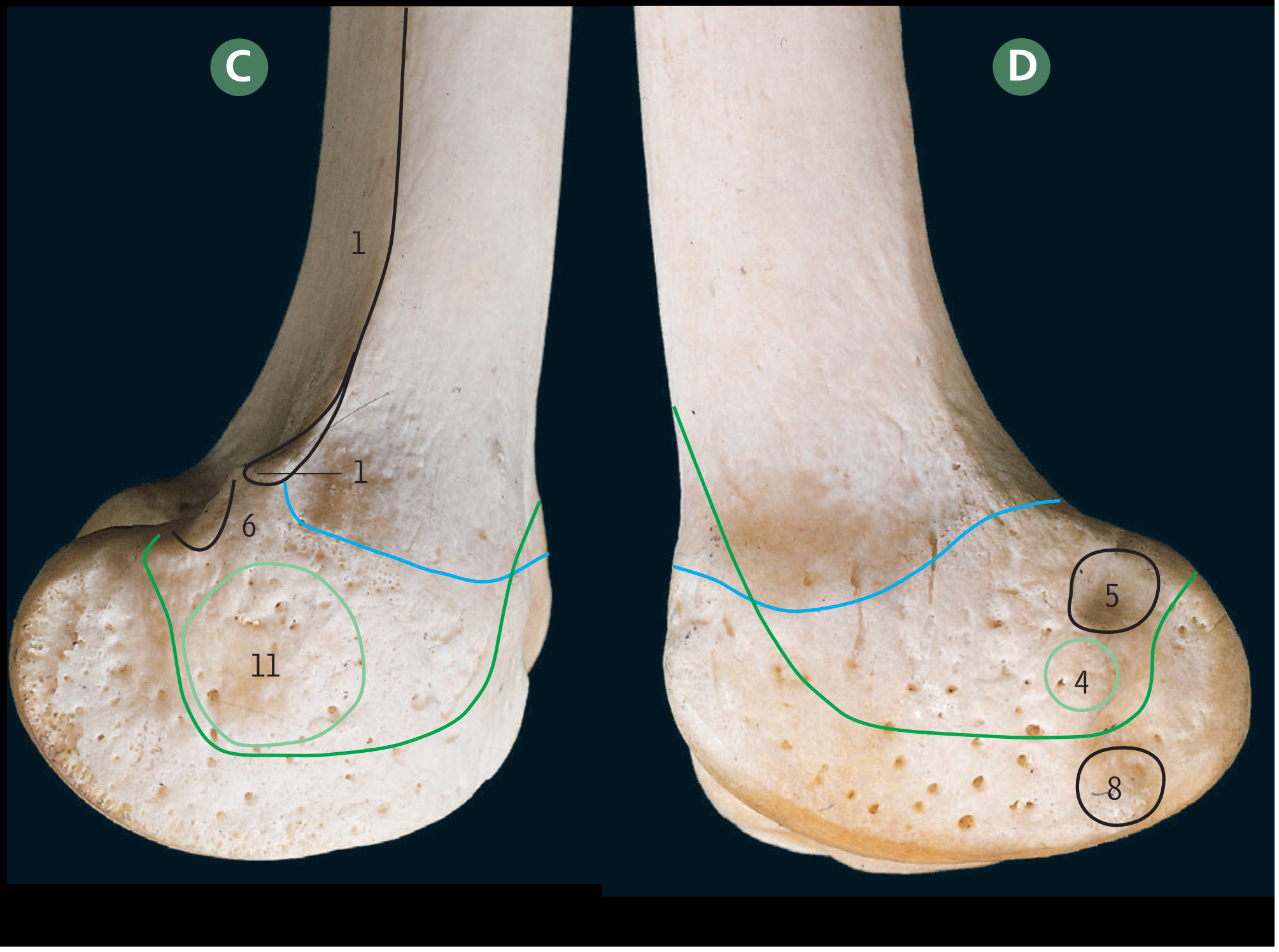

A from the front

B from behind

C from the medial side

D from the lateral side

Blue lines, epiphysial lines
Green line, capsular attachment of knee joint
Pale green lines, ligament attachments

1 Adductor magnus
2 Anterior cruciate ligament
3 Articularis genu
4 Fibular collateral ligament
5 Lateral head of gastrocnemius
6 Medial head of gastrocnemius
7 Plantaris
8 Popliteus
9 Posterior cruciate ligament
10 Short head of biceps femoris
11 Tibial (medial) collateral ligament
12 Vastus intermedius
13 Vastus medialis

Left tibia *proximal end*

A **from the front**

B **from behind**

1 Anterior border
2 Articular facet for fibula
3 Groove for semimembranosus
4 Impression for iliotibial tract
5 Interosseous border
6 Lateral condyle
7 Lateral surface
8 Medial border
9 Medial condyle
10 Medial surface
11 Posterior surface
12 Soleal line
13 Tubercles of intercondylar eminence
14 Tuberosity
15 Vertical line

The shaft of the tibia has three borders: anterior (1), medial (8) and interosseous (5) – and three surfaces: medial (10), lateral (7) and posterior (11).

Much of the anterior border (1) forms a slightly curved crest commonly known as the shin. Most of the smooth medial surface (10) is subcutaneous. The posterior surface contains the soleal and vertical lines (12 and 15).

The tuberosity (14) is at the upper end of the anterior border.

Left tibia *attachments, proximal end*

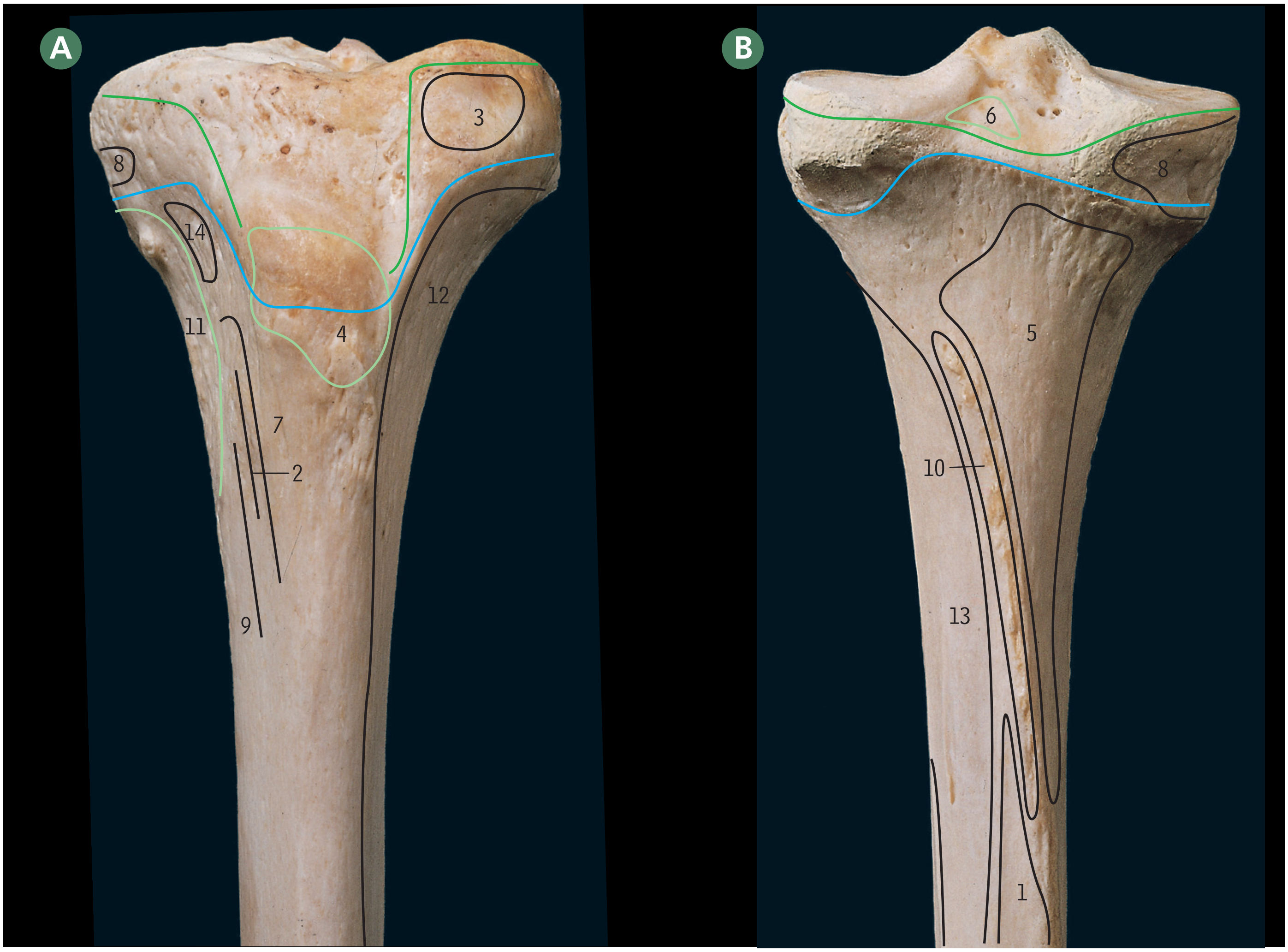

A from the front

B from behind

Blue lines, epiphysial lines
Green line, capsular attachment of knee joint
Pale green lines, ligament attachments

1. Flexor digitorum longus
2. Gracilis
3. Iliotibial tract
4. Patellar ligament
5. Popliteus
6. Posterior cruciate ligament
7. Sartorius
8. Semimembranosus
9. Semitendinosus
10. Soleus
11. Tibial (medial) collateral ligament
12. Tibialis anterior
13. Tibialis posterior
14. Vastus medialis

Left tibia *proximal end*

A **from the medial side**

B **from the lateral side**

C **from above (tibial plateau)**

1 Anterior border
2 Anterior intercondylar area
3 Articular facet for fibula
4 Groove for semimembranosus
5 Interosseous border
6 Lateral condyle
7 Lateral surface
8 Medial border
9 Medial condyle
10 Medial surface
11 Posterior intercondylar area
12 Posterior surface
13 Soleal line
14 Tubercles of intercondylar eminence
15 Tuberosity

The medial condyle (C9) is larger than the lateral condyle (C6).

The articular facet for the fibula is on the postero-inferior aspect of the lateral condyle (B3).

Osgood–Schlatter's disease, see pages 355–357.

Left tibia *attachments, proximal end*

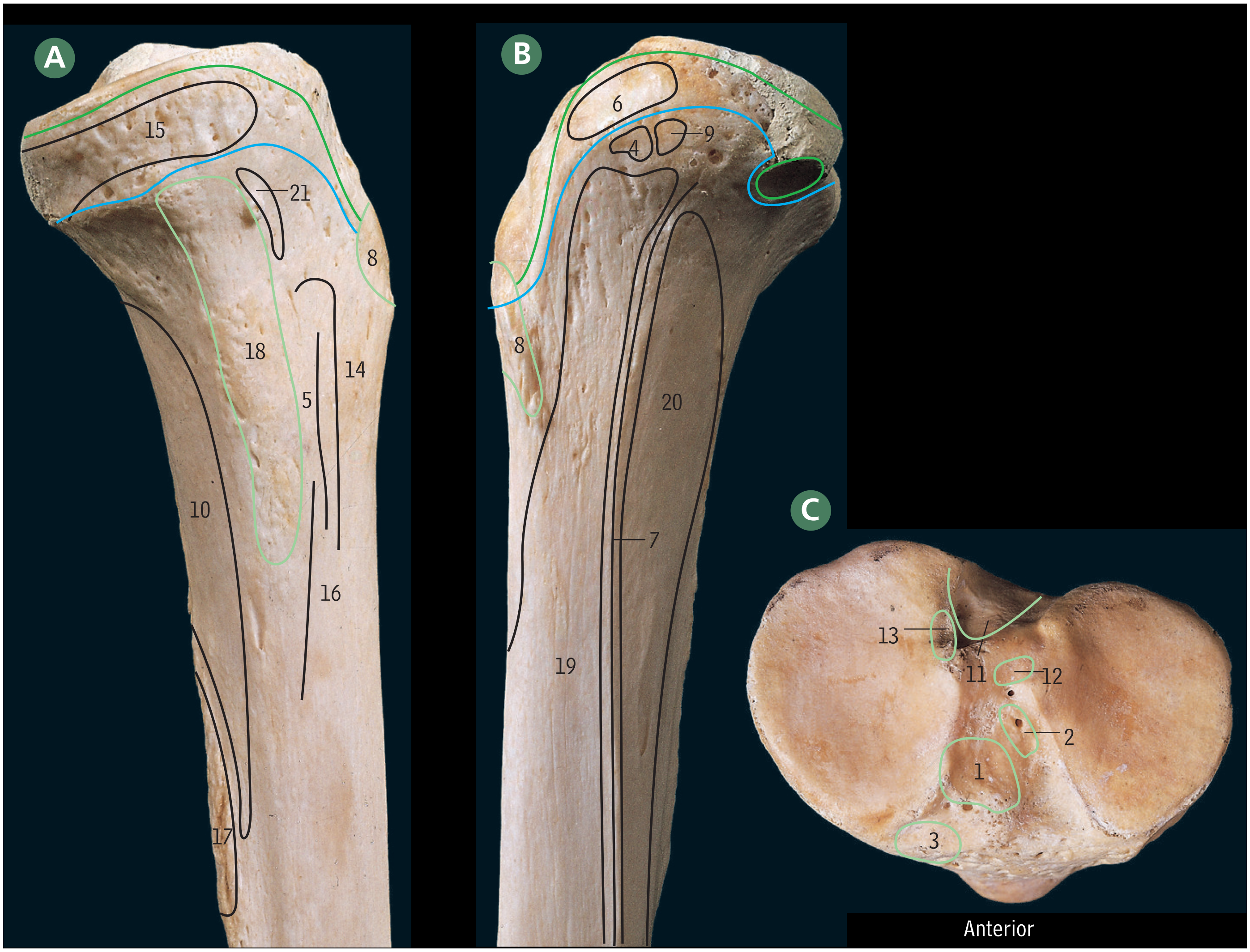

A **from the medial side**

B **from the lateral side**

C **from above (tibial plateau)**

Blue lines, epiphysial lines
Green lines, capsular attachments of knee joint and superior tibiofibular joint
Pale green lines, ligament attachments

1 Anterior cruciate ligament
2 Anterior horn of lateral meniscus
3 Anterior horn of medial meniscus
4 Extensor digitorum longus
5 Gracilis
6 Iliotibial tract
7 Interosseous membrane
8 Patellar ligament
9 Peroneus (fibularis) longus
10 Popliteus
11 Posterior cruciate ligament
12 Posterior horn of lateral meniscus
13 Posterior horn of medial meniscus
14 Sartorius
15 Semimembranosus
16 Semitendinosus
17 Soleus
18 Tibial (medial) collateral ligament
19 Tibialis anterior
20 Tibialis posterior
21 Vastus medialis

Left tibia *distal end*

A from the front

B from behind

C from the medial side

D from the lateral side

1 Anterior surface
2 Fibular notch
3 Groove for flexor hallucis longus
4 Groove for tibialis posterior
5 Interosseous border
6 Medial malleolus
7 Medial surface
8 Posterior surface

Left tibia *attachments, distal end*

E from the front

F from behind

G from the medial side

H from the lateral side

Blue line, epiphysial line
Green line, capsular attachment of ankle joint
Pale green lines, ligament attachment

1 Inferior transverse ligament
2 Interosseous ligament
3 Interosseous membrane
4 Medial collateral ligament
5 Posterior tibiofibular ligament

The medial collateral ligament (G4) is commonly known as the deltoid ligament.

Tibial fractures, see pages 355–357.

Left tibia and fibula *articulated*

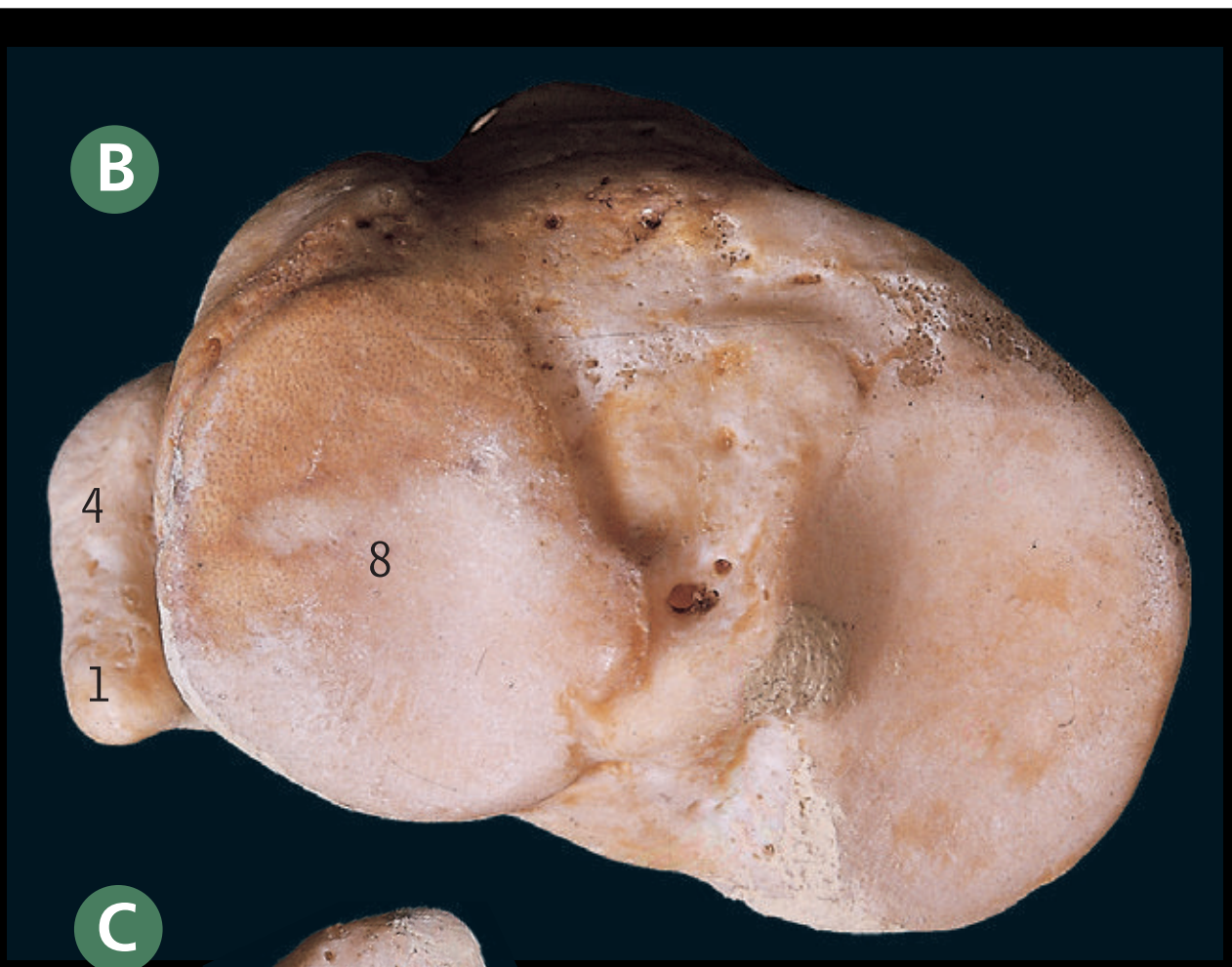

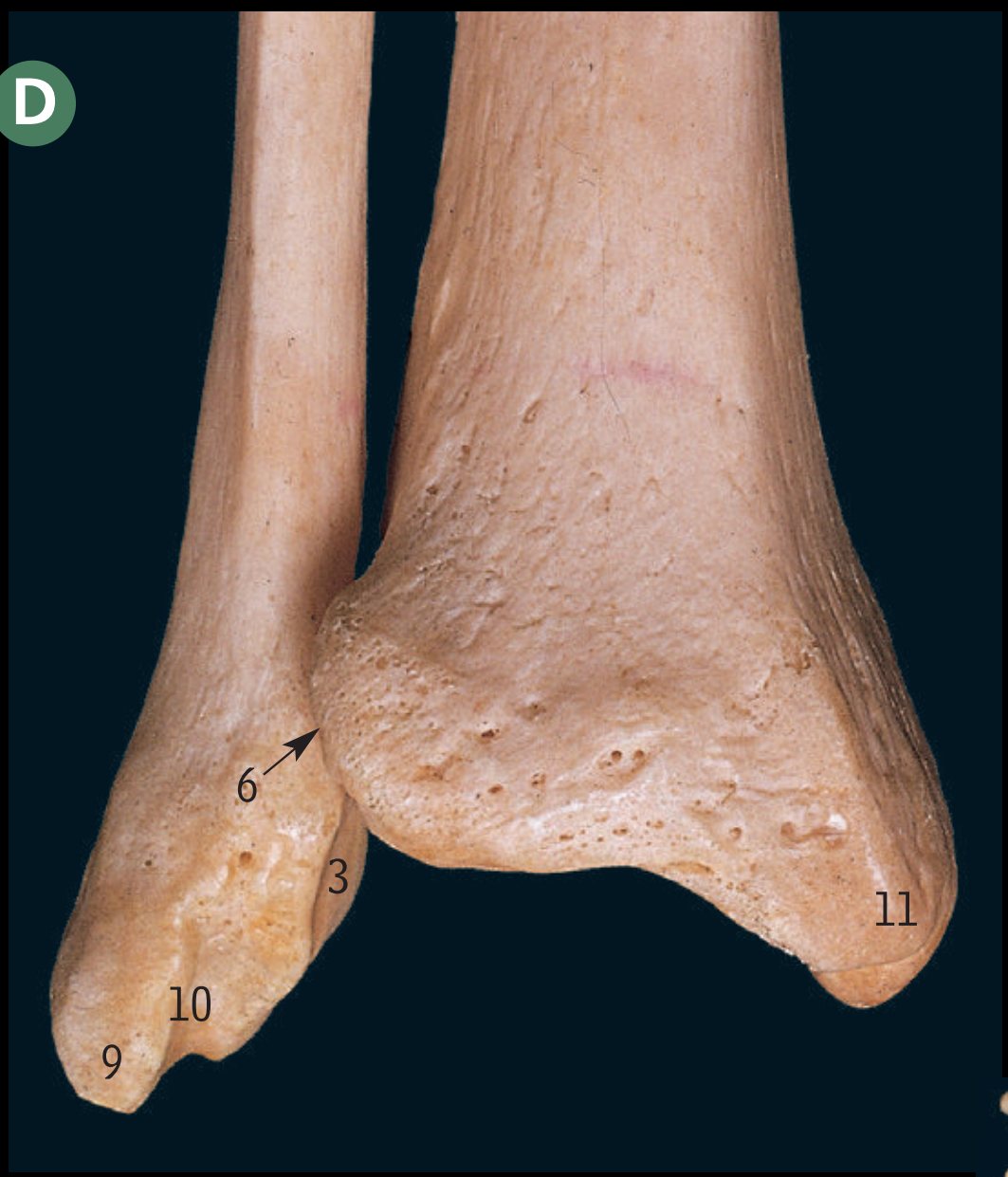

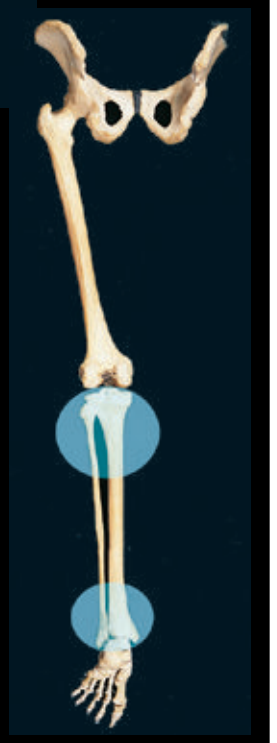

A **proximal ends from behind**

B **proximal ends from above**

C **proximal end of fibula from above**

D **distal ends from behind**

E **distal ends from below**

1 Apex of head (styloid process)
2 Articular facet (for superior tibiofibular joint)
3 Articular facet of lateral malleolus (for ankle joint)
4 Head of fibula
5 Inferior surface of tibia (for ankle joint)
6 Inferior tibiofibular joint
7 Lateral (articular) surface of medial malleolus (for ankle joint)
8 Lateral condyle of tibia
9 Lateral malleolus
10 Malleolar fossa
11 Medial malleolus
12 Superior tibiofibular joint

The superior tibiofibular joint (A12) is synovial.

The inferior tibiofibular joint (D6) is fibrous.

The lateral malleolus (D9) extends lower than the medial malleolus (D11).

Tarsal dislocations, see pages 355–357.

Left fibula *proximal end*

A **from the front**

B **from behind**

C **from the medial side**

D **from the lateral side**

1 Anterior border
2 Apex (styloid process)
3 Articular facet on upper surface
4 Head
5 Interosseous border
6 Lateral surface
7 Medial crest
8 Medial surface
9 Neck
10 Posterior border
11 Posterior surface

The fibula has three borders: anterior (A1), interosseous (A5) and posterior (B10) – and three surfaces: medial (A8), lateral (A6) and posterior (B11).

At first sight, much of the shaft appears to have four borders and four surfaces, but this is because the posterior surface (B11) is divided into two parts (medial and lateral) by the medial crest (B7).

Left fibula *distal end*

E **from the front**

F **from behind**

G **from the medial side**

H **from the lateral side**

1 Anterior border
2 Articular surface of lateral malleolus
3 Groove for peroneus (fibularis) brevis
4 Interosseous border
5 Lateral malleolus
6 Lateral surface
7 Malleolar fossa
8 Medial crest
9 Medial surface
10 Posterior border
11 Posterior surface
12 Surface for interosseous ligament
13 Triangular subcutaneous area

Left fibula
attachments, proximal end

A from the front

B from behind

C from the medial side

D from the lateral side

Blue line, epiphysial line
Green line, capsular attachment of superior tibiofibular joint
Pale green lines, ligament attachments

1 Biceps femoris
2 Extensor digitorum longus
3 Extensor hallucis longus
4 Fibular collateral ligament
5 Flexor hallucis longus
6 Interosseous membrane
7 Peroneus (fibularis) brevis
8 Peroneus (fibularis) longus
9 Soleus
10 Tibialis posterior

Left fibula
attachments, distal end

E from the front

F from behind

G from the medial side

H from the lateral side

Blue line, epiphysial line
Green line, capsular attachment of ankle joint
Pale green lines, ligament attachments

1 Anterior talofibular ligament
2 Calcaneofibular ligament
3 Extensor digitorum longus
4 Extensor hallucis longus
5 Flexor hallucis longus
6 Interosseous ligament
7 Interosseous membrane
8 Peroneus (fibularis) brevis
9 Peroneus (fibularis) tertius
10 Posterior talofibular ligament
11 Posterior tibiofibular ligament
12 Tibialis posterior

Bones of the left foot

A **from above (dorsum)**

B **from below (plantar surface)**

1 Anterior tubercle of calcaneus
2 Base of fifth metatarsal
3 Base of first metatarsal
4 Calcaneus
5 Cuboid
6 Distal phalanx of great toe
7 Distal phalanx of second toe
8 Groove on calcaneus for flexor hallucis longus
9 Groove on cuboid for peroneus (fibularis) longus
10 Groove on talus for flexor hallucis longus
11 Grooves for sesamoid bones in flexor hallucis brevis
12 Head of fifth metatarsal
13 Head of first metatarsal
14 Head of talus
15 Intermediate cuneiform
16 Lateral cuneiform
17 Lateral process of calcaneus
18 Lateral tubercle of talus
19 Medial cuneiform
20 Medial process of calcaneus
21 Medial tubercle of talus
22 Middle phalanx of second toe
23 Navicular
24 Neck of talus
25 Proximal phalanx of great toe
26 Proximal phalanx of second toe
27 Shaft of fifth metatarsal
28 Shaft of first metatarsal
29 Sustentaculum tali of calcaneus
30 Trochlear surface of body of talus
31 Tuberosity of base of fifth metatarsal
32 Tuberosity of cuboid
33 Tuberosity of navicular

Dislocation of the toe, hallux valgus, *see pages 355–357.*

Bones of the left foot *attachments*

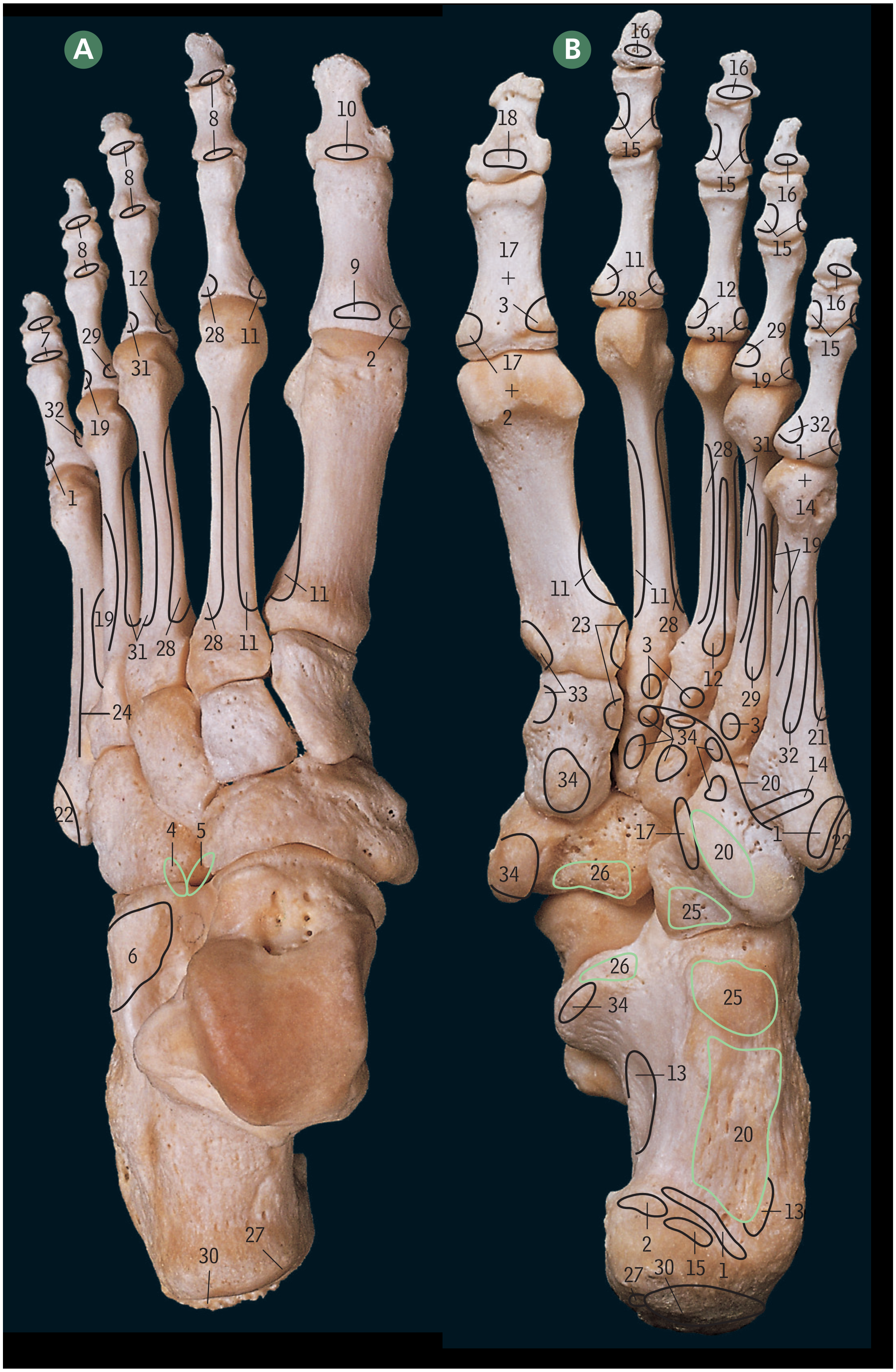

A from above

B from below

Joint capsules and minor ligaments have been omitted.

Pale green lines, ligament attachments

1 Abductor digiti minimi
2 Abductor hallucis
3 Adductor hallucis
4 Calcaneocuboid part of bifurcate ligament
5 Calcaneonavicular part of bifurcate ligament
6 Extensor digitorum brevis
7 Extensor digitorum longus
8 Extensor digitorum longus and brevis
9 Extensor hallucis brevis
10 Extensor hallucis longus
11 First dorsal interosseous
12 First plantar interosseous
13 Flexor accessorius
14 Flexor digiti minimi brevis
15 Flexor digitorum brevis
16 Flexor digitorum longus
17 Flexor hallucis brevis
18 Flexor hallucis longus
19 Fourth dorsal interosseous
20 Long plantar ligament
21 Opponens digiti minimi (part of 14)
22 Peroneus (fibularis) brevis
23 Peroneus (fibularis) longus
24 Peroneus (fibularis) tertius
25 Plantar calcaneocuboid (short plantar) ligament
26 Plantar calcaneonavicular (spring) ligament
27 Plantaris
28 Second dorsal interosseous
29 Second plantar interosseous
30 Tendo calcaneus (Achilles tendon)
31 Third dorsal interosseous
32 Third plantar interosseous
33 Tibialis anterior
34 Tibialis posterior

Hallux sesamoid fracture, metatarsal fractures, see pages 355–357.

Bones of the left foot

A **from the medial side**

B **from the lateral side**

- **1** Anterior tubercle of calcaneus
- **2** Cuboid
- **3** First metatarsal
- **4** Head of talus
- **5** Intermediate cuneiform
- **6** Lateral cuneiform
- **7** Lateral malleolar surface of talus
- **8** Lateral process of calcaneus
- **9** Lateral tubercle of talus
- **10** Medial cuneiform
- **11** Medial malleolar surface of talus
- **12** Medial process of calcaneus
- **13** Medial surface of calcaneus
- **14** Medial tubercle of talus
- **15** Navicular
- **16** Neck of talus
- **17** Peroneal (fibular) trochlea of calcaneus
- **18** Sustentaculum tali of calcaneus
- **19** Tarsal sinus
- **20** Tuberosity of base of fifth metatarsal
- **21** Tuberosity of navicular

Calcaneal fracture, hammer toe, os trigonum, see pages 355–357.

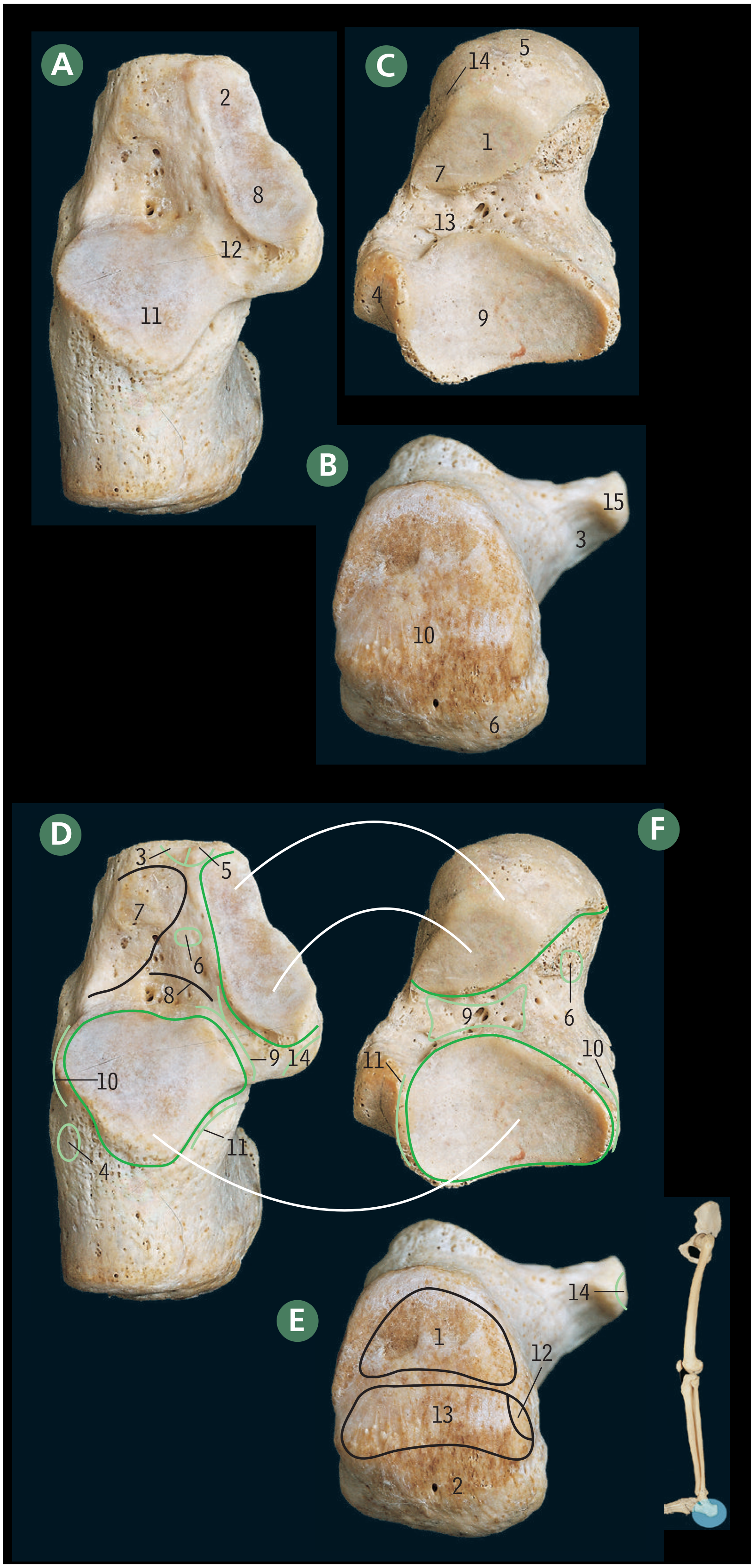

Bones of the left foot

Left calcaneus

A **from above** **B** **from behind**

Left talus

C **from below**

1 Anterior calcanean articular surface of talus
2 Anterior talar articular surface of calcaneus
3 Groove of calcaneus for flexor hallucis longus
4 Groove of talus for flexor hallucis longus
5 Head of talus
6 Medial process of calcaneus
7 Middle calcanean articular surface of talus
8 Middle talar articular surface of calcaneus
9 Posterior calcanean articular surface of talus
10 Posterior surface of calcaneus
11 Posterior talar articular surface of calcaneus
12 Sulcus of calcaneus
13 Sulcus of talus
14 Surface of talus for plantar calcaneonavicular (spring) ligament
15 Sustentaculum tali of calcaneus

Left calcaneus, attachments

D **from above** **E** **from behind**

Left talus, attachments

F **from below**

Curved lines indicate corresponding articular surfaces: green, capsular attachment of talocalcanean (subtalar) and talocalcaneonavicular joints; pale green lines, ligament attachments

1 Area for bursa
2 Area for fibrofatty tissue
3 Calcaneocuboid part of bifurcate ligament
4 Calcaneofibular ligament
5 Calcaneonavicular part of bifurcate ligament
6 Cervical ligament
7 Extensor digitorum brevis
8 Inferior extensor retinaculum
9 Interosseous talocalcanean (cervical) ligament
10 Lateral talocalcanean ligament
11 Medial talocalcanean ligament
12 Plantaris
13 Tendocalcaneus (Achilles tendon)
14 Tibiocalcanean part of deltoid ligament

The interosseous talocalcanean (cervical) ligament (9) is formed by thickening of the adjacent capsules of the talocalcanean and talocalcaneonavicular joints.

For different interpretations of the term 'subtalar joint' see the notes on page 348.

Left lower limb bones *secondary centres of ossification*

A **hip bone, lower lateral part**

B **C** **femur, proximal and distal ends**

D **E** **tibia, proximal and distal ends**

F **G** **fibula, proximal and distal ends**

H **calcaneus**

I **metatarsal and phalanges of second toe**

J **metatarsal and phalanges of great toe**

Figures in years, commencement of ossification → fusion.
P, puberty, B, ninth intra-uterine month.
See introduction on page 125.

Slipped upper femoral epiphysis, see pages 355–357.

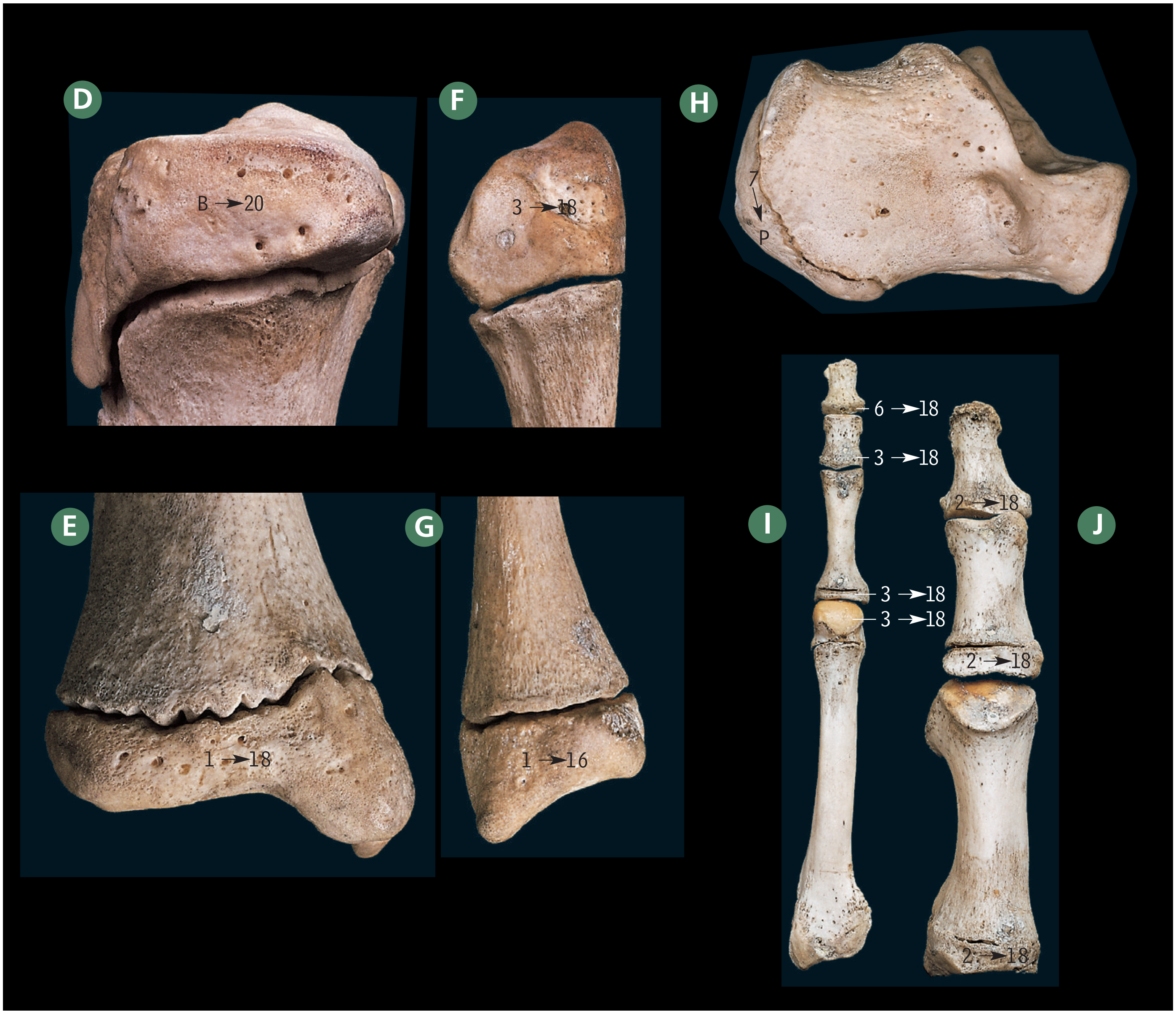

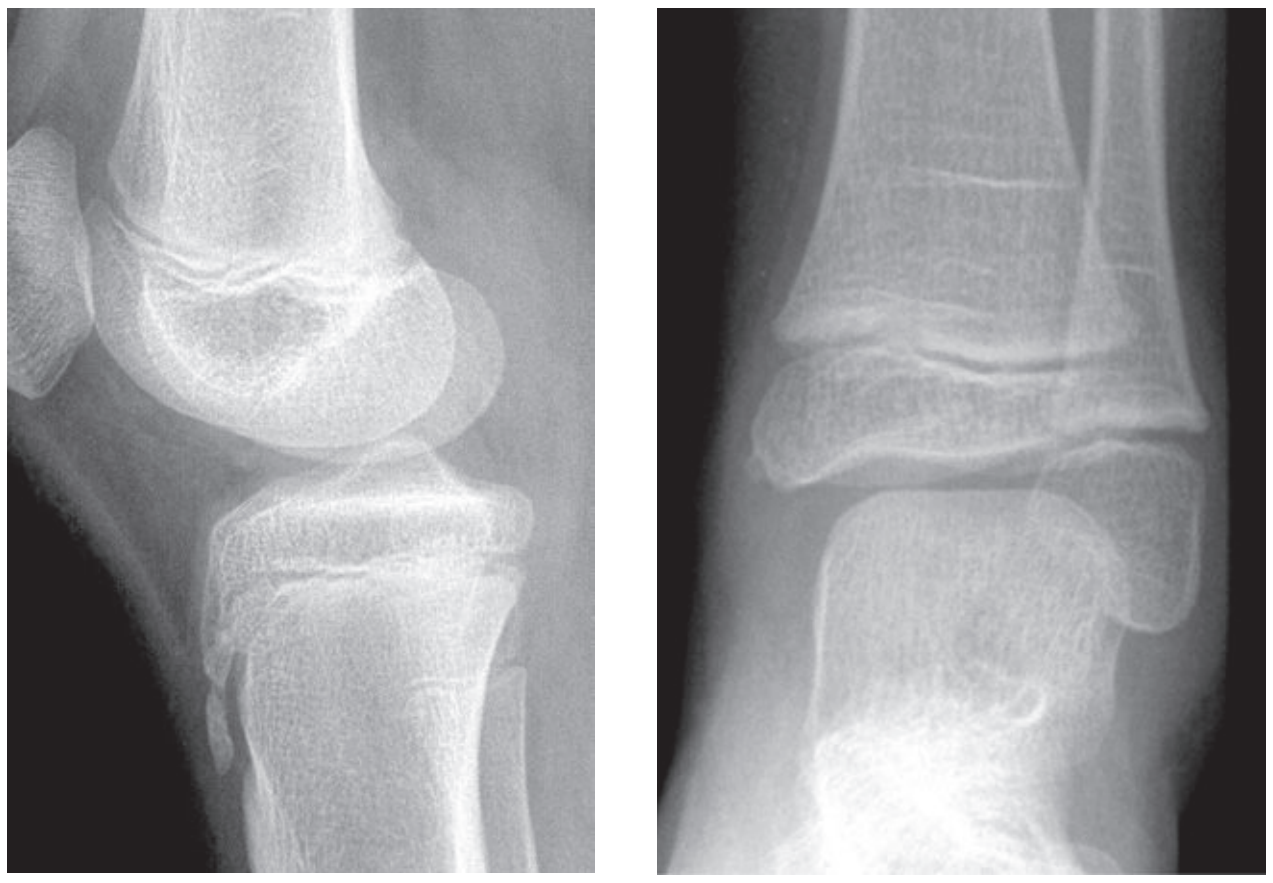

Note knee and ankle epiphyses as seen on plain x-rays

In the hip bone (A) one or more secondary centres appear in the Y-shaped cartilage between ilium, ischium and pubis. Other centres (not illustrated) are usually present for the iliac crest, anterior inferior iliac spine, and (possibly) the pubic tubercle and pubic crest (all P → 25).

The patella (not illustrated) begins to ossify from one or more centres between the third and sixth year.

All the phalanges, and the first metatarsal, have a secondary centre at their proximal ends; the other metatarsals have one at their distal ends.

Of the tarsal bones, the largest, the calcaneus, begins to ossify in the third intra-uterine month and the talus about three months later. The cuboid may begin to ossify either just before or just after birth, with the lateral cuneiform in the first year, medial cuneiform at two years and the intermediate cuneiform and navicular at three years.

The calcaneus (H) is the only tarsal bone to have a secondary centre.

A Gluteal region *surface features*

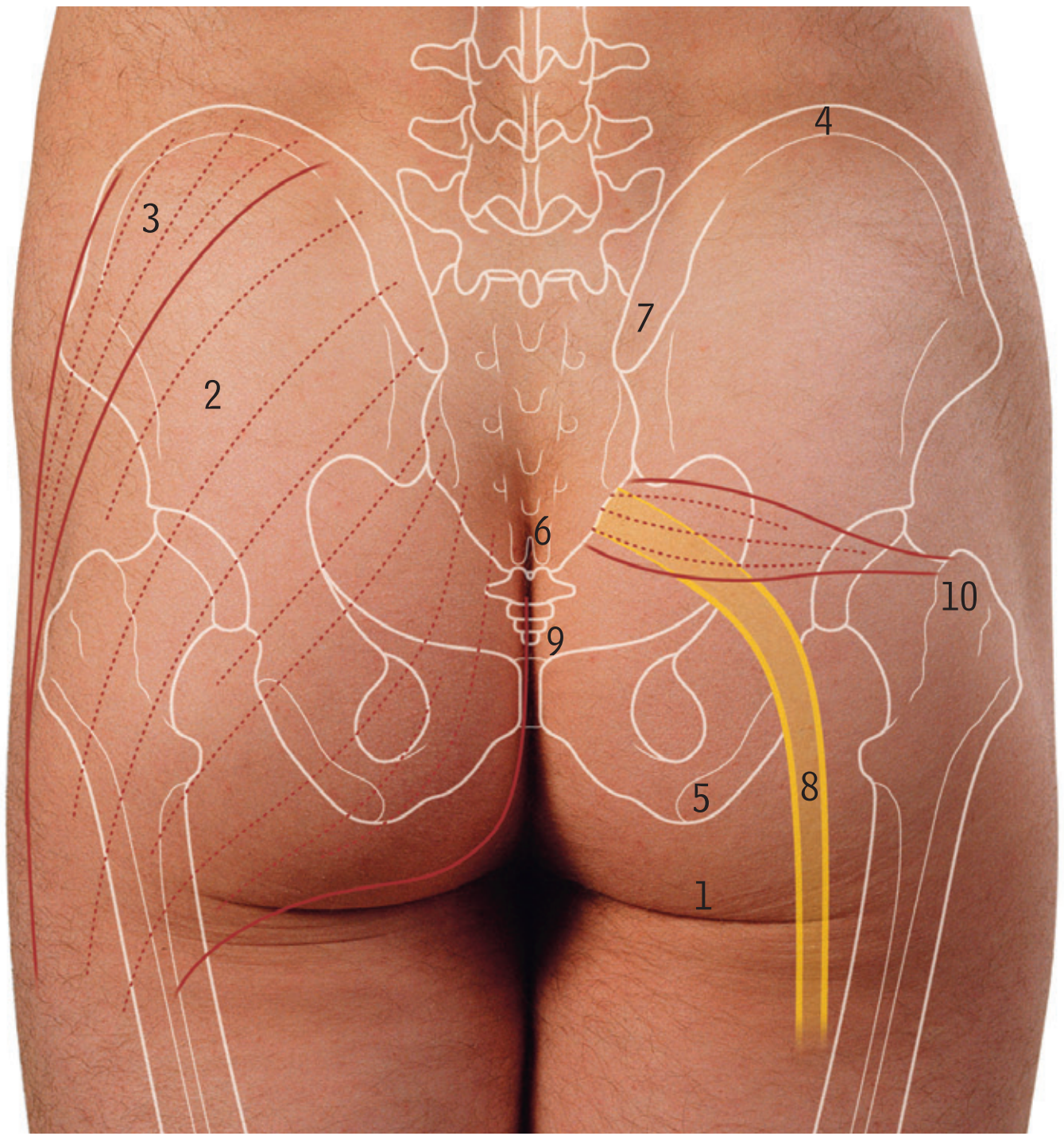

The iliac crest (4) with the posterior superior iliac spine (7), the tip of the coccyx (9), the ischial tuberosity (5) and the tip of the greater trochanter of the femur (10) are palpable landmarks. A line drawn from a point midway between the posterior superior iliac spine (7) and the tip of the coccyx (9) to the tip of the greater trochanter (10) marks the lower border of piriformis (illustrated on right buttock), which is a key feature of the gluteal region, where the most important structure is the sciatic nerve (indicated here in yellow, 8; see dissections and notes opposite).

1 Fold of buttock
2 Gluteus maximus
3 Gluteus medius
4 Iliac crest
5 Ischial tuberosity
6 Natal cleft
7 Posterior superior iliac spine
8 Sciatic nerve
9 Tip of coccyx
10 Tip of greater trochanter of femur

B Right gluteal region *superficial nerves*

Skin and subcutaneous tissue have been removed, preserving cutaneous branches from the first three lumbar (3) and first three sacral (4) nerves, the cutaneous branches of the posterior femoral cutaneous nerve (5) and the perforating cutaneous nerve (11). The curved line near the bottom of the picture indicates the position of the gluteal fold (fold of the buttock). The muscle fibres of gluteus maximus (7) run downwards and laterally, and its lower border does not correspond to the gluteal fold.

1 Adductor magnus
2 Coccyx
3 Cutaneous branches of dorsal rami of first three lumbar nerves
4 Gluteal branches of dorsal rami of first three sacral nerves
5 Gluteal branches of the posterior femoral cutaneous nerve
6 Gluteal fascia overlying gluteus medius
7 Gluteus maximus
8 Gracilis
9 Iliac crest
10 Ischio-anal fossa and levator ani
11 Perforating cutaneous nerve
12 Posterior layer of lumbar fascia overlying erector spinae
13 Semitendinosus

The gluteal region or buttock is sometimes used as a site for intramuscular injections. The correct site is in the upper outer quadrant of the buttock, and for delineating this quadrant, it is essential to remember that the upper boundary of the buttock is the uppermost part of the iliac crest. The lower boundary is the fold of the buttock. Dividing the area between these two boundaries by a vertical line midway between the midline and the lateral side of the body indicates that the upper outer quadrant is well above and to the right of the label 7 in B, and this is the safe site for injection – well above and to the right of the sciatic nerve which is displayed in the dissections opposite.

Intramuscular injection–gluteal region, see pages 355–357.

Left gluteal region

A superficial dissection

B deeper dissection

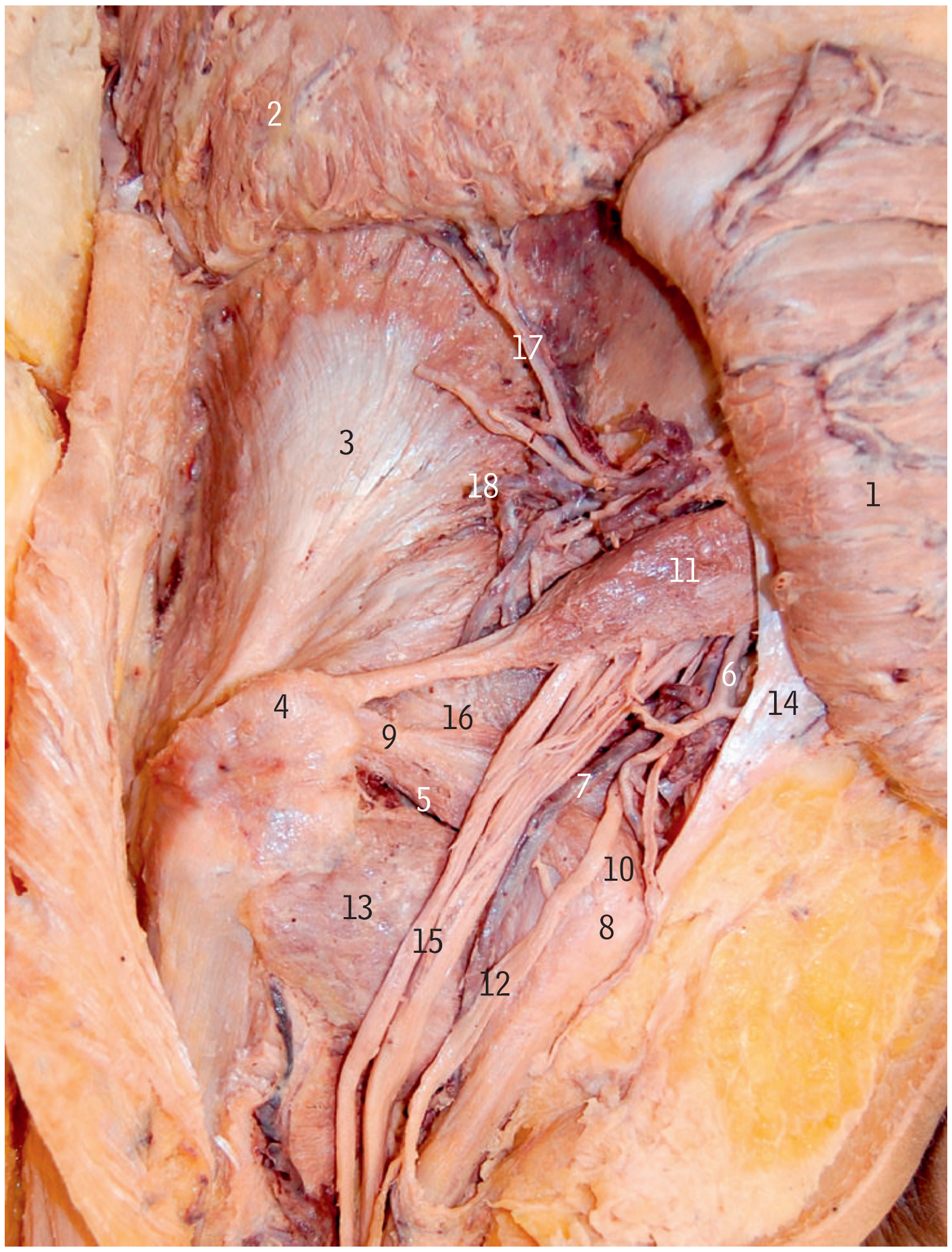

1 Gluteus maximus muscle, reflected
2 Gluteus medius muscle, reflected
3 Gluteus minimus muscle
4 Greater trochanter of femur
5 Inferior gemellus muscle
6 Inferior gluteal artery
7 Inferior gluteal vein
8 Ischial tuberosity
9 Obturator internus tendon
10 Obturator internus muscle
11 Piriformis
12 Posterior cutaneous nerve of thigh
13 Quadratus femoris muscle
14 Sacrotuberous ligament
15 Sciatic nerve
16 Superior gemellus muscle
17 Superior gluteal artery
18 Superior gluteal vein

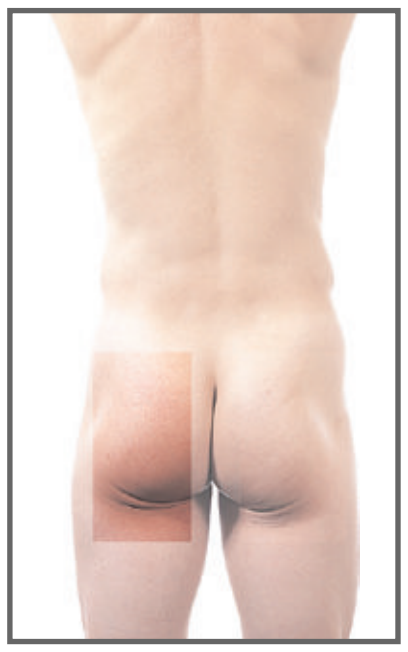

The two parts of the sciatic trunk (common peroneal [fibular] and tibial) usually divide from one another at the top of the popliteal fossa (page 330) but are sometimes separate as they emerge beneath piriformis, and the common peroneal (fibular) may even perforate piriformis.

Right thigh *posterior view*

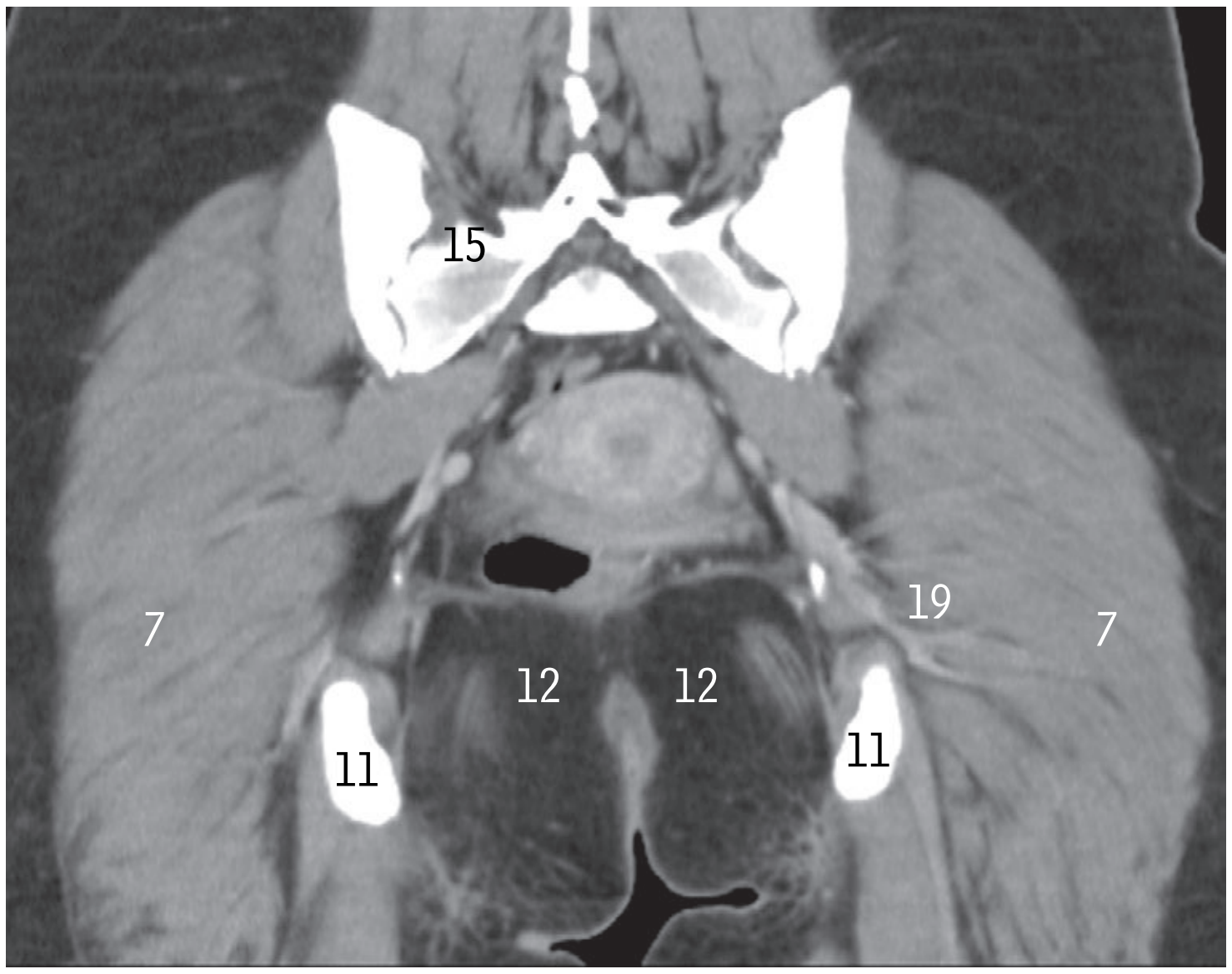

Coronal CT, posterior pelvic cavity, female

A Gluteal region and proximal hamstrings

B Deeper dissection revealing ischio-anal fossa

1 Adductor magnus, hamstring part
2 Anus
3 Biceps femoris
4 Biceps femoris, tendon of long head
5 External anal sphincter
6 Gluteal fascia
7 Gluteus maximus
8 Gluteus maximus, attachment to iliotibial tract
9 Iliotibial tract (thickened fascia lata)
10 Inferior rectal vessels
11 Ischial tuberosity
12 Ischio-anal fossa
13 Levator ani
14 Pudendal vessels and pudendal nerve
15 Sacrum, dorsal fascia
16 Sciatic nerve within fascial sheath
17 Scrotal skin
18 Semitendinosus
19 Superior gluteal vessels

Torn hamstrings, see pages 355–357.

C Right upper thigh *posterior view*

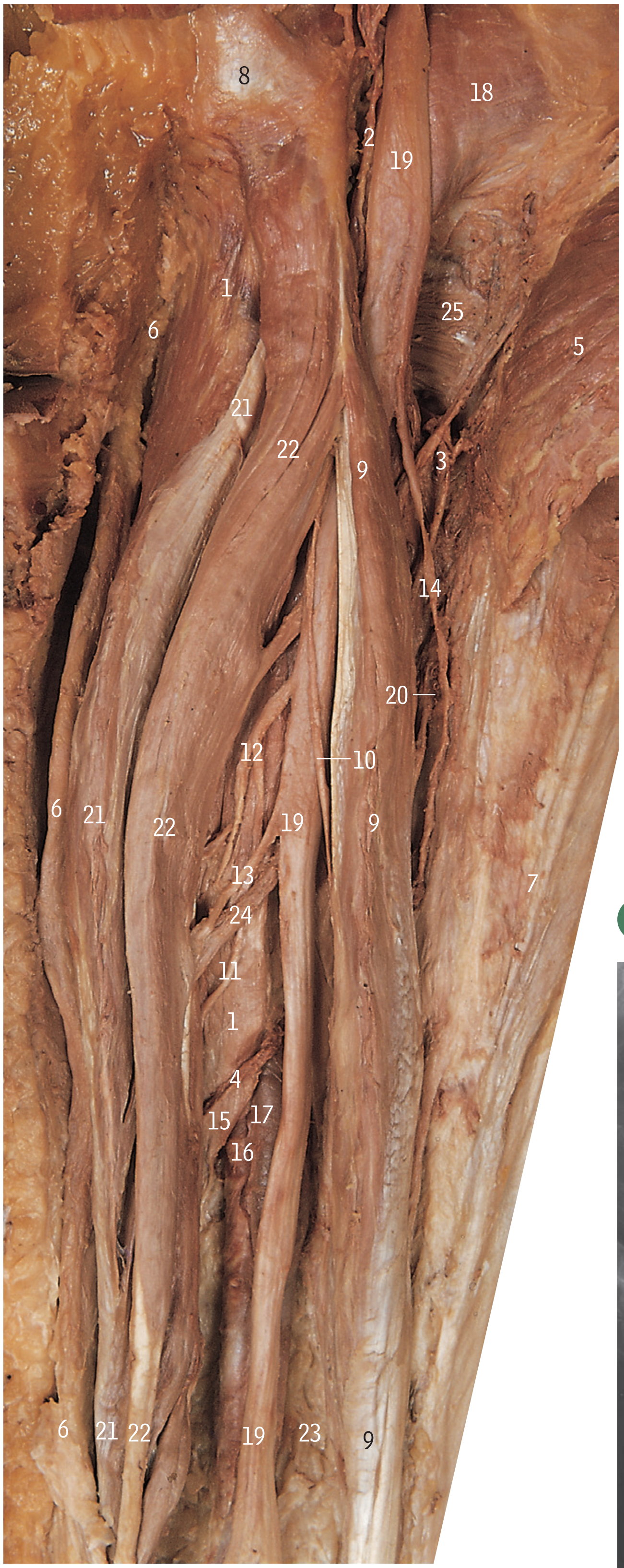

Gluteus maximus (5) has been reflected laterally and the gap between semitendinosus (22) and biceps femoris (9) has been opened up to show the sciatic trunk (19) and its muscular branches.

1 Adductor magnus
2 Anastomotic branch of inferior gluteal artery
3 First perforating artery
4 Fourth perforating artery
5 Gluteus maximus
6 Gracilis
7 Iliotibial tract overlying vastus lateralis
8 Ischial tuberosity
9 Long head of biceps femoris
10 Nerve to long head of biceps femoris
11 Nerve to semimembranosus
12 Nerve to semimembranosus and adductor magnus
13 Nerve to semitendinosus
14 Nerve to short head of biceps femoris
15 Opening in adductor magnus
16 Popliteal artery
17 Popliteal vein
18 Quadratus femoris
19 Sciatic trunk
20 Second perforating artery
21 Semimembranosus
22 Semitendinosus
23 Short head of biceps femoris
24 Third perforating artery
25 Upper part of adductor magnus ('adductor minimus')

The only muscular branch to arise from the lateral side of the sciatic trunk (i.e. from the common peroneal (fibular) part of the nerve (19), uppermost 19, near the top of the picture), is the nerve to the short head of biceps (14). All the other muscular branches – to the long head of biceps femoris (10), semimembranosus (11), semimembranosus and adductor magnus (12) and semitendinosus (13) – arise from the medial side of the sciatic trunk (19, near the centre of the picture) (i.e. from the tibial part of the nerve).

D Femoral arteriogram

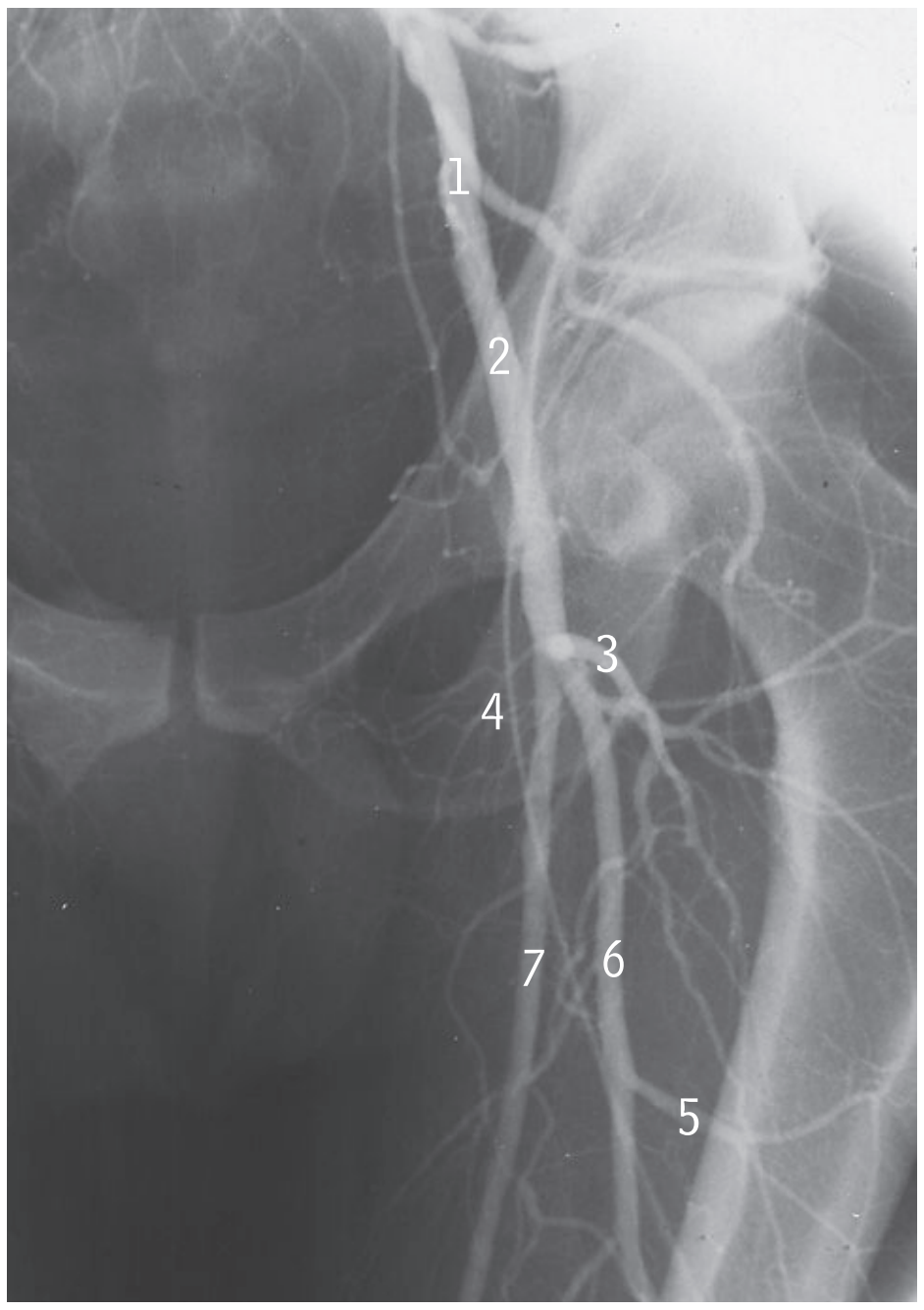

1 Catheter introduced into distal abdominal aorta via right common femoral artery
2 Common femoral artery
3 Lateral circumflex femoral artery
4 Medial circumflex femoral artery
5 Perforating artery
6 Profunda femoris artery
7 Superficial femoral artery

Anterior thigh and lower abdomen

The boundaries of the femoral triangle are the inguinal ligament (13), the medial border of sartorius (19) and the medial border of adductor longus (1).

The femoral canal is the medial compartment of the femoral sheath (removed), which contains in its middle compartment the femoral vein (8), and in the lateral compartment the femoral artery (6). The femoral nerve (7) is lateral to the sheath, not within it.

Lumbar plexus block, varicella-zoster virus infection–lower limb, see pages 355–357.

Proximal anterior thigh *Sartorius retracted medially to show subsartorial canal*

The boundaries of the femoral triangle are the inguinal ligament (13), the medial border of sartorius (19) and the medial border of adductor longus (1).

The femoral canal is the medial compartment of the femoral sheath (removed) which contains in its middle compartment the femoral vein (8), and in the lateral compartment the femoral artery (6). The femoral nerve (7) is lateral to the sheath, not within it.

A B

1 Adductor longus
2 Arterial branch to vastus medialis
3 Corona of glans penis
4 External oblique aponeurosis
5 Fascia lata (cut edge)
6 Femoral artery
7 Femoral nerve
8 Femoral vein
9 Gracilis
10 Great saphenous vein
11 Iliopsoas
12 Iliotibial tract
13 Inguinal ligament
14 Nerve to vastus medialis
15 Pectineus
16 Perforating branch of profunda femoris artery
17 Rectus femoris
18 Saphenous nerve
19 Sartorius
20 Subsartorial fascia (thickened aponeurosis)
21 Spermatic cord
22 Superficial circumflex iliac vein
23 Superficial epigastric vein
24 Superficial external pudendal vein
25 Superficial inguinal ring
26 Tensor fasciae latae deep to fascia lata
27 Valvular bulge in vein
28 Vastus lateralis
29 Vastus medialis

Femoral nerve paralysis, obturator nerve paralysis, see pages 355–357.

A Right femoral artery

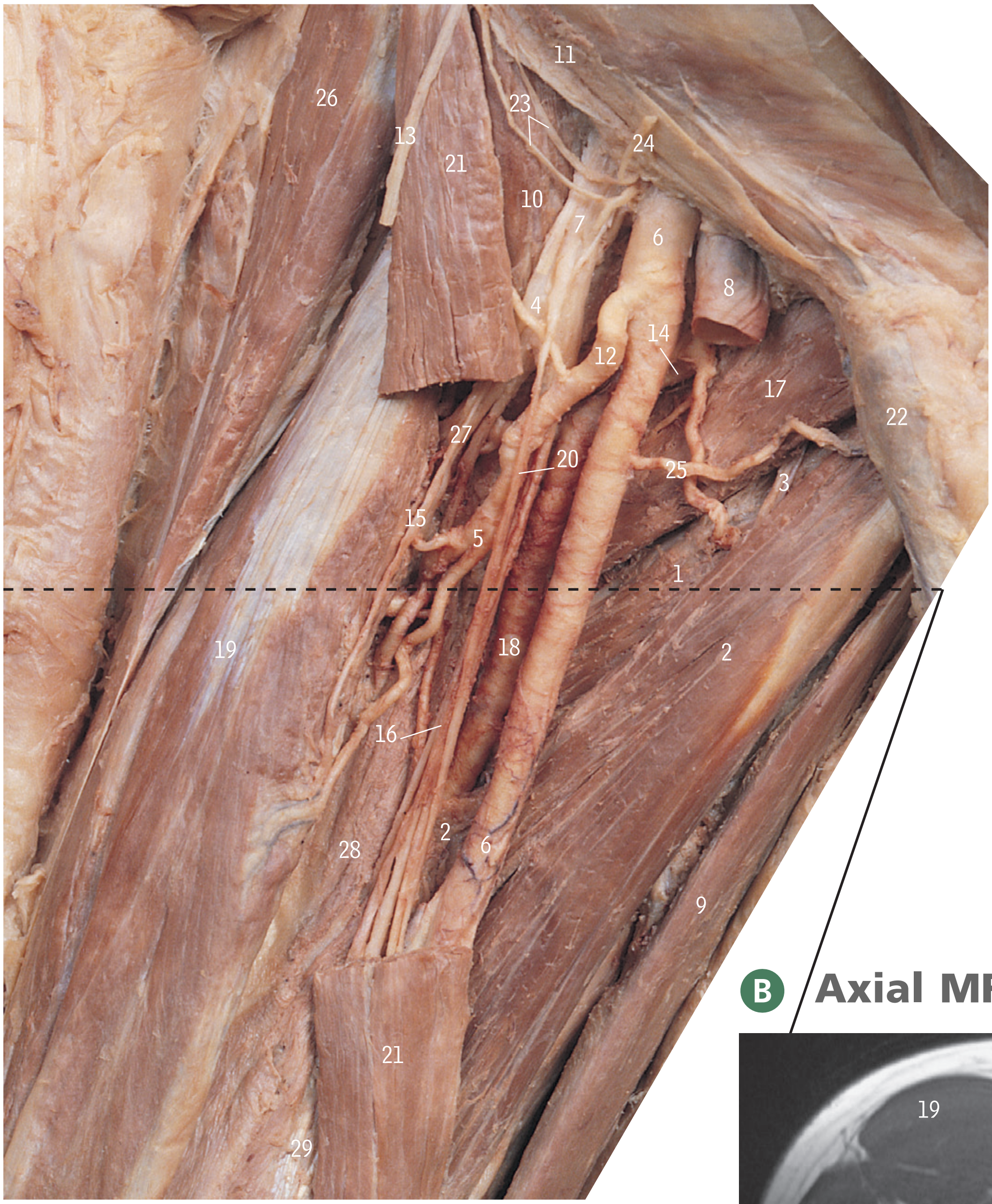

1 Adductor brevis
2 Adductor longus
3 Anterior branch of obturator nerve
4 Ascending branch of lateral circumflex femoral artery
5 Descending branch of lateral circumflex femoral artery
6 Femoral artery
7 Femoral nerve
8 Femoral vein
9 Gracilis
10 Iliacus
11 Inguinal ligament
12 Lateral circumflex femoral artery
13 Lateral femoral cutaneous nerve
14 Medial circumflex femoral artery
15 Nerve to rectus femoris
16 Nerve to vastus medialis
17 Pectineus
18 Profunda femoris artery
19 Rectus femoris
20 Saphenous nerve
21 Sartorius
22 Spermatic cord
23 Superficial circumflex iliac artery (double)
24 Superficial epigastric artery
25 Superficial external pudendal artery (low origin)
26 Tensor fasciae latae
27 Transverse branch of lateral circumflex femoral artery
28 Vastus intermedius
29 Vastus medialis

B Axial MR image of thigh

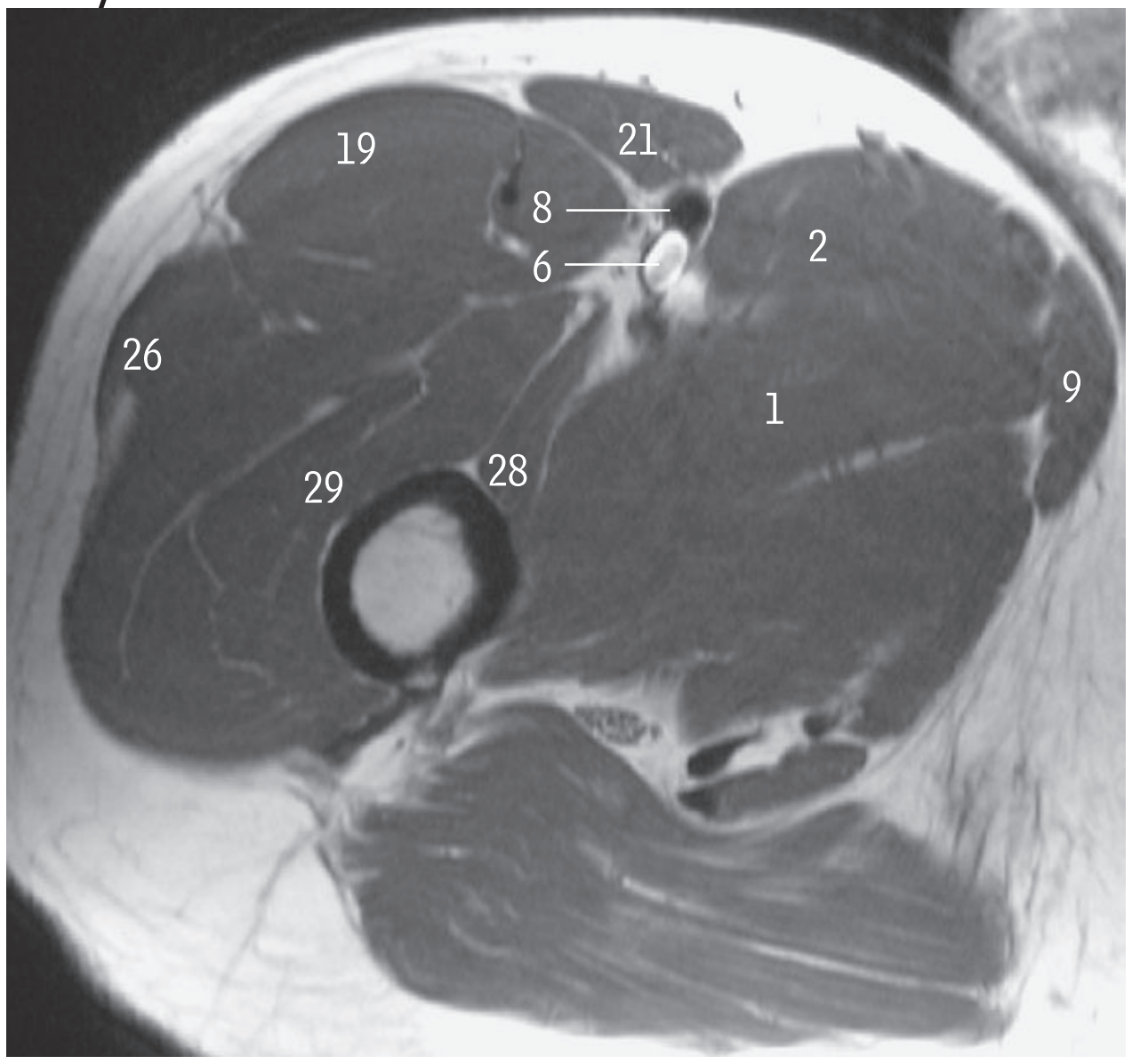

Femoral artery puncture, meralgia paraesthetica, see *pages 355–357.*

C Right distal thigh

from the front and medial side

The lower part of sartorius (13) has been displaced medially to open up the lower part of the adductor canal and expose the femoral artery (2) passing through the opening in adductor magnus (7) to enter the popliteal fossa behind the knee and become the popliteal artery (page 330).

1 Adductor magnus
2 Femoral artery
3 Gracilis
4 Iliotibial tract
5 Lowest (horizontal) fibres of vastus medialis
6 Medial patellar retinaculum
7 Opening in adductor magnus
8 Patella
9 Quadriceps tendon
10 Rectus femoris
11 Saphenous branch of descending genicular artery
12 Saphenous nerve
13 Sartorius
14 Vastus medialis and nerve



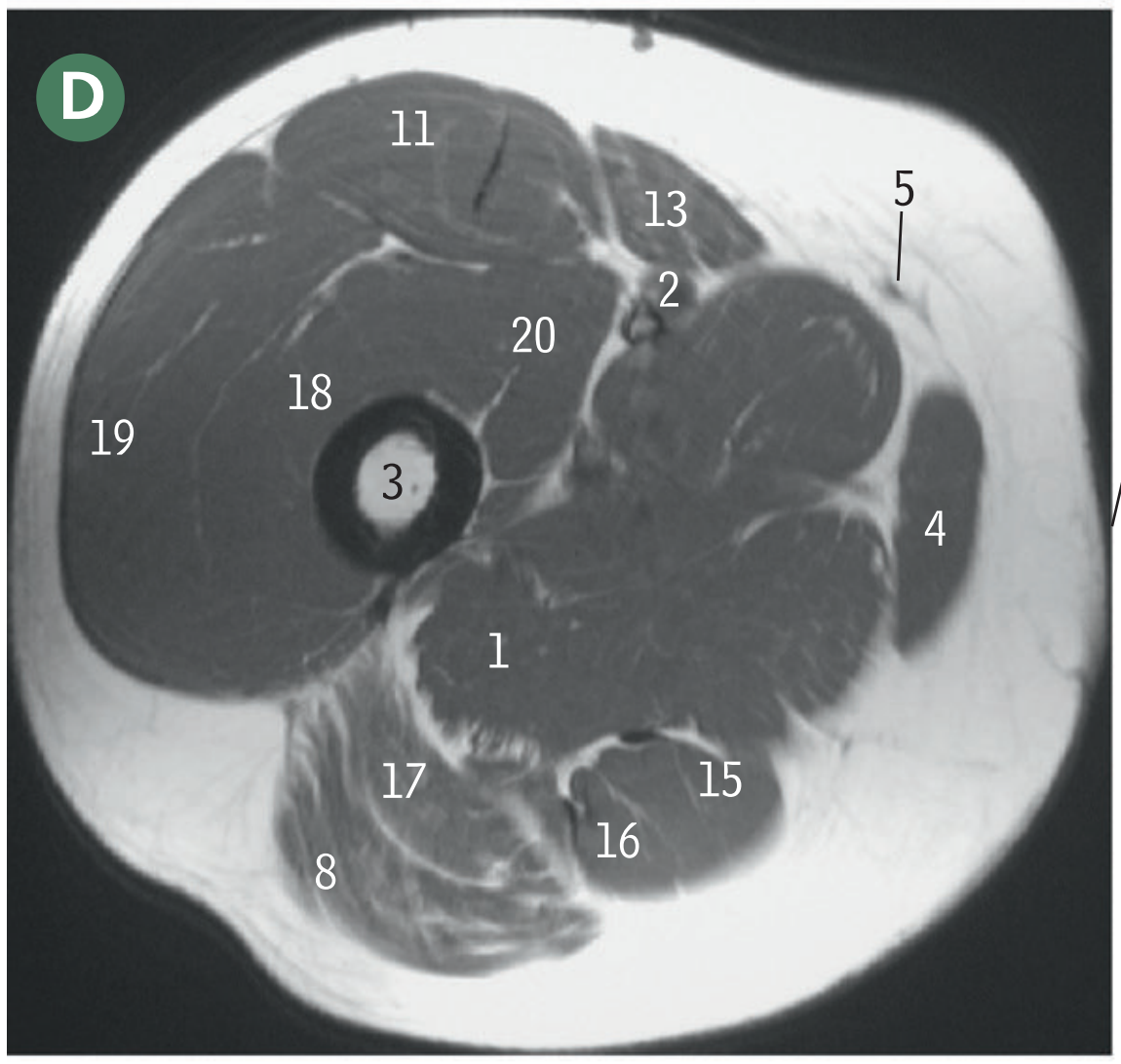

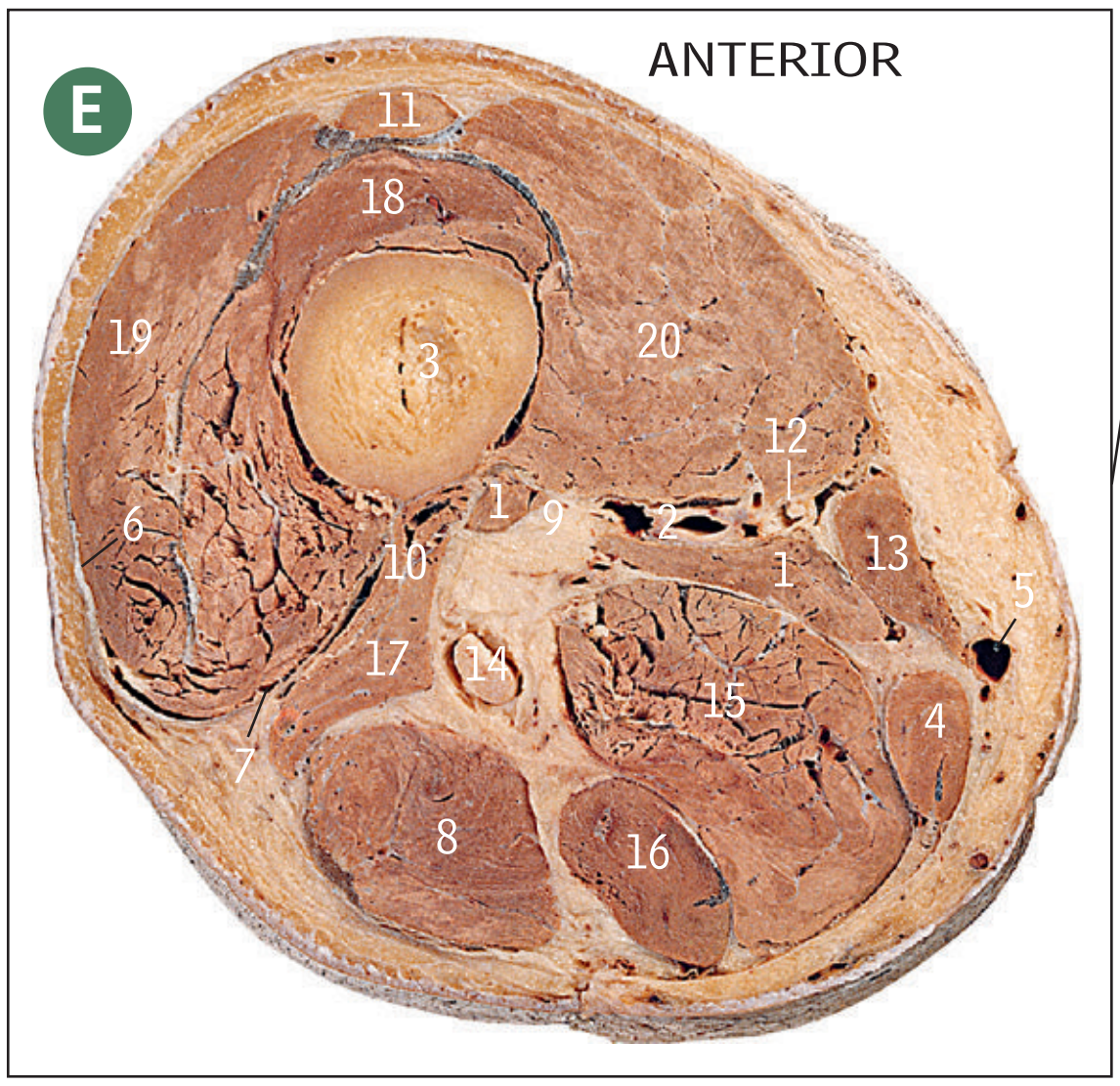

Right distal thigh

D *axial MR image* E *cross-section*

1 Adductor magnus
2 Femoral vessels
3 Femur
4 Gracilis
5 Great saphenous vein
6 Iliotibial tract
7 Lateral intermuscular septum
8 Long head of biceps femoris
9 Opening in adductor magnus
10 Profunda femoris vessels
11 Rectus femoris
12 Saphenous nerve
13 Sartorius
14 Sciatic nerve
15 Semimembranosus
16 Semitendinosus
17 Short head of biceps femoris
18 Vastus intermedius
19 Vastus lateralis
20 Vastus medialis

Femoropopliteal bypass, intermittent claudication, muscular transposition, rupture–quadriceps tendon, see pages 355–357.

Right hip joint

A from the front and below B from the front and above

Some of the fibres of the ischiofemoral ligament help to form the zona orbicularis – circular fibres of the capsule that form a collar around the neck of the femur.

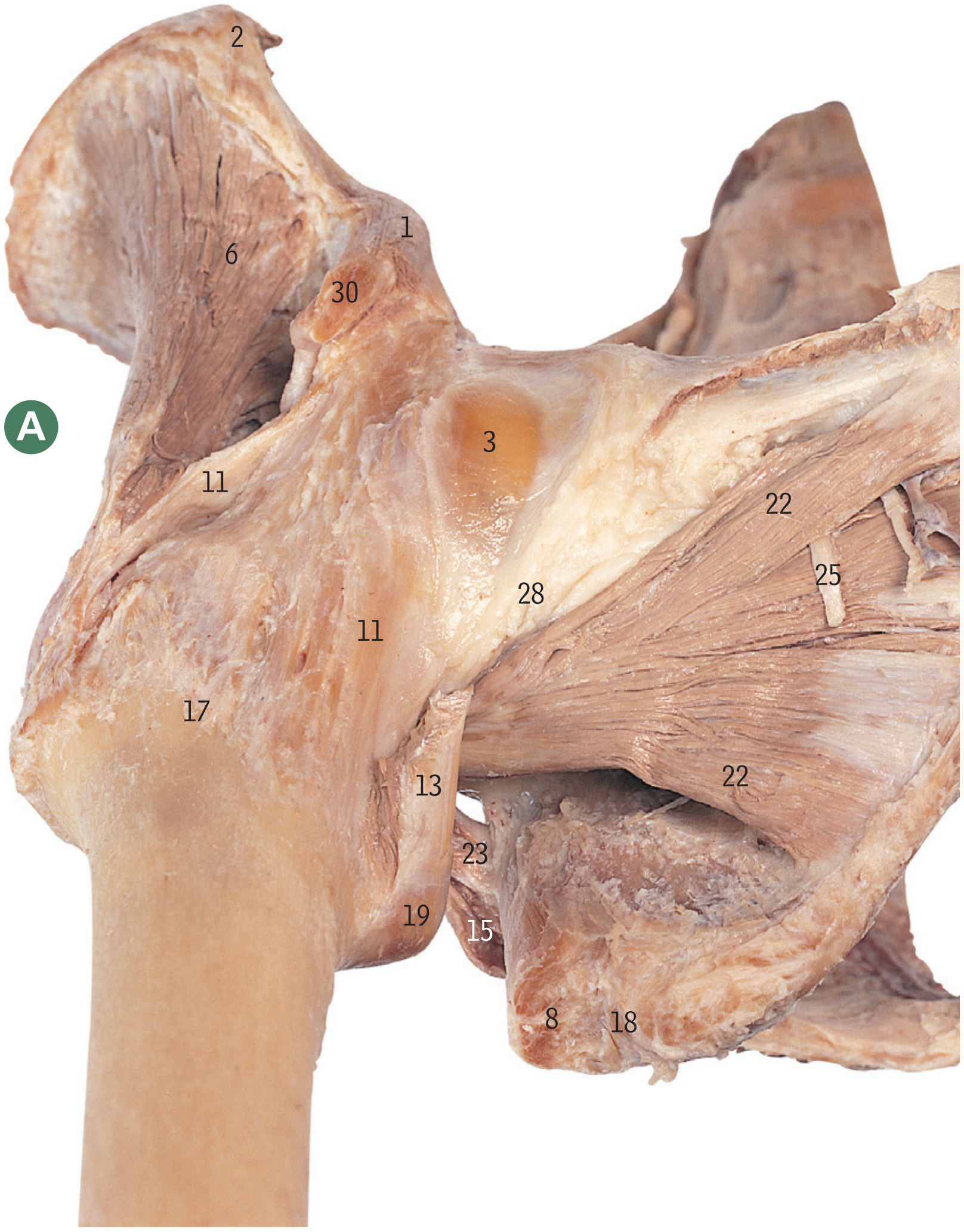

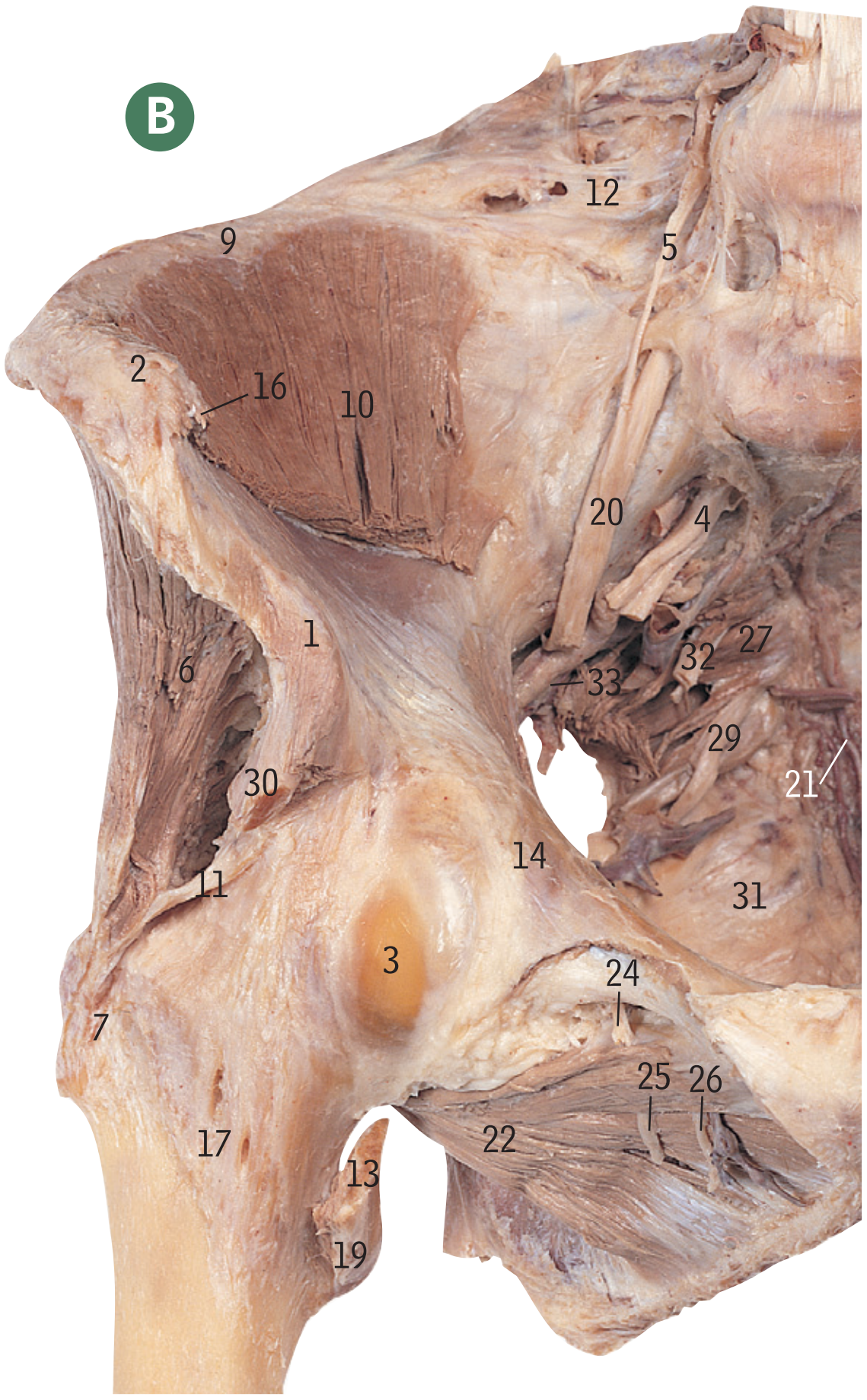

1 Anterior inferior iliac spine
2 Anterior superior iliac spine
3 Bursa for psoas tendon
4 First sacral nerve root
5 Fourth lumbar nerve root
6 Gluteus minimus muscle
7 Greater trochanter
8 Hamstring origin
9 Iliac crest
10 Iliacus muscle
11 Iliofemoral ligament
12 Iliolumbar ligament
13 Iliopsoas tendon
14 Iliopubic eminence
15 Inferior gemellus muscle
16 Inguinal ligament
17 Intertrochanteric line and capsule attachment
18 Ischial tuberosity
19 Lesser trochanter
20 Lumbosacral trunk
21 Median sacral artery
22 Obturator externus
23 Obturator internus tendon
24 Obturator nerve, anterior branch
25 Obturator nerve, posterior branch
26 Obturator vessels
27 Piriformis muscle
28 Pubofemoral ligament
29 Pudendal nerve
30 Rectus femoris muscle
31 Sacrospinous ligament
32 Second sacral nerve root
33 Superior gluteal artery

Trendelenburg's sign, see pages 355–357.

C Right vertebropelvic and sacro-iliac ligaments *from behind*

1 Acetabular labrum
2 Coccyx
3 Dorsal sacro-iliac ligaments
4 Falciform process of sacrotuberous ligament
5 Greater sciatic notch
6 Iliac crest
7 Iliolumbar ligament
8 Inferior articular process of fifth lumbar vertebra
9 Ischial tuberosity
10 Lesser sciatic notch
11 Posterior superior iliac spine
12 Sacrospinous ligament and ischial spine
13 Sacrotuberous ligament
14 Superior articular process of fifth lumbar vertebra
15 Transverse process of fifth lumbar vertebra

D Right hip joint with femur removed *from the right*

The femur has been disarticulated from the acetabulum and removed, leaving the acetabular labrum, transverse ligament and the ligament teres. Refer to page 293, B, for bony attachments and musculature.

1 Acetabular fossa
2 Acetabular labrum
3 Adductor brevis muscle
4 Adductor longus muscle
5 Adductor magnus muscle
6 Articular surface
7 Gracilis muscle
8 Ligamentum teres femoris
9 Obturator externus muscle
10 Pectineus muscle
11 Quadratus femoris muscle
12 Reflected head of rectus femoris muscle
13 Straight head of rectus femoris muscle
14 Transverse ligament

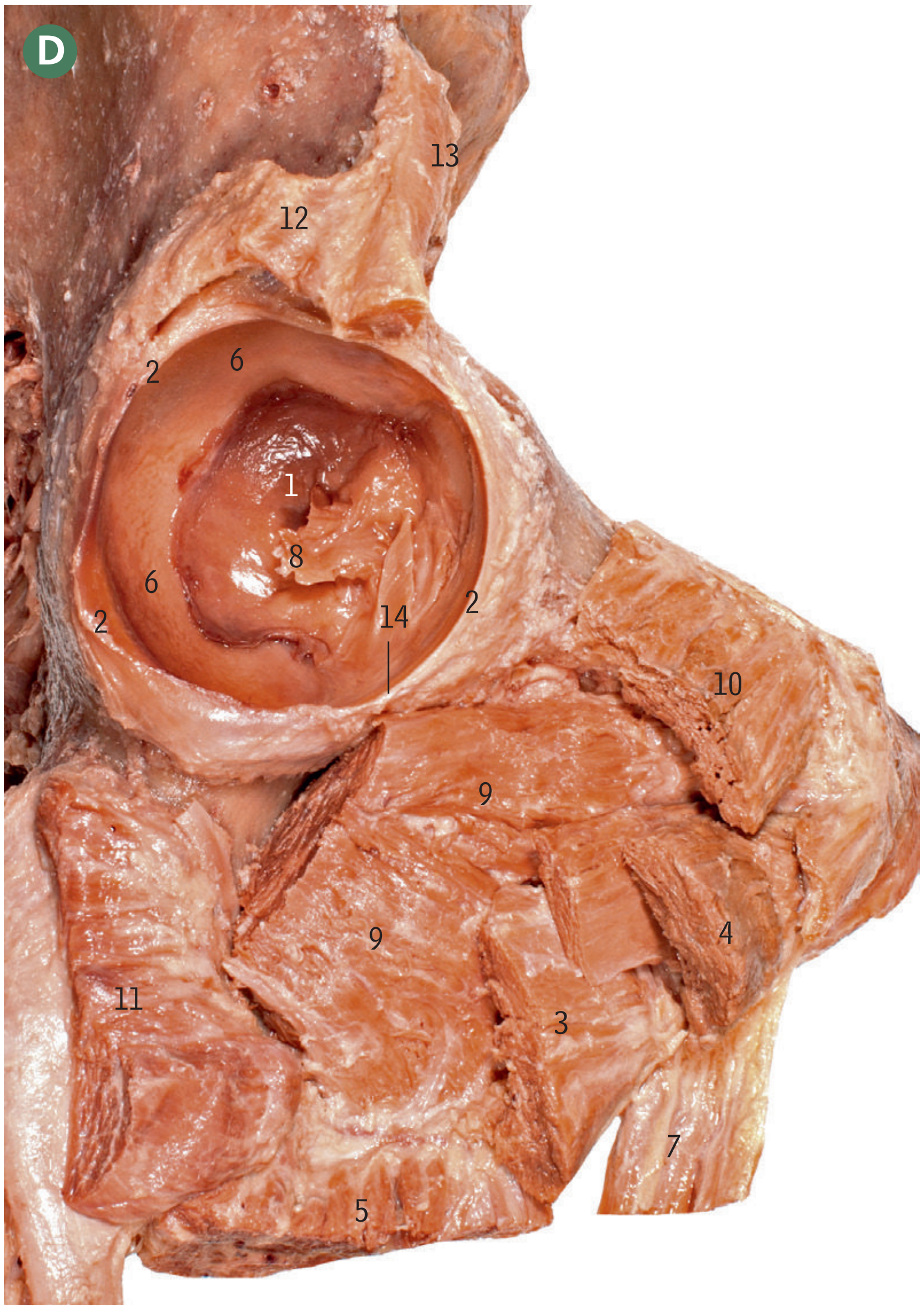

Avascular necrosis of the head of the femur, see pages 355–357.

Left hip joint A *coronal section, from the front*

The section has almost passed through the centre of the head (8) of the femur and the centre of the greater trochanter (7). Above the neck of the femur (14), gluteus minimus (6) with gluteus medius (5) above it run down to their attachments to the greater trochanter (7), while below the neck the tendon of psoas major (17) and muscle fibres of iliacus (12) pass backwards towards the lesser trochanter. The circular fibres of the zona orbicularis (22) constrict the capsule (3) around the intracapsular part of the neck of the femur.

1 Acetabular labrum
2 Adductor longus
3 Capsule of hip joint
4 External iliac artery
5 Gluteus medius
6 Gluteus minimus
7 Greater trochanter
8 Head of femur
9 Hyaline cartilage of acetabulum
10 Hyaline cartilage of head
11 Iliac crest
12 Iliacus
13 Medial circumflex femoral vessels
14 Neck of femur
15 Pectineus
16 Profunda femoris vessels
17 Psoas major
18 Rim of acetabulum
19 Shaft of femur
20 Vastus lateralis
21 Vastus medialis
22 Zona orbicularis of capsule

*Contrast outlines the joint cavity
** Ligamentum teres

B *coronal MR, arthrogram*

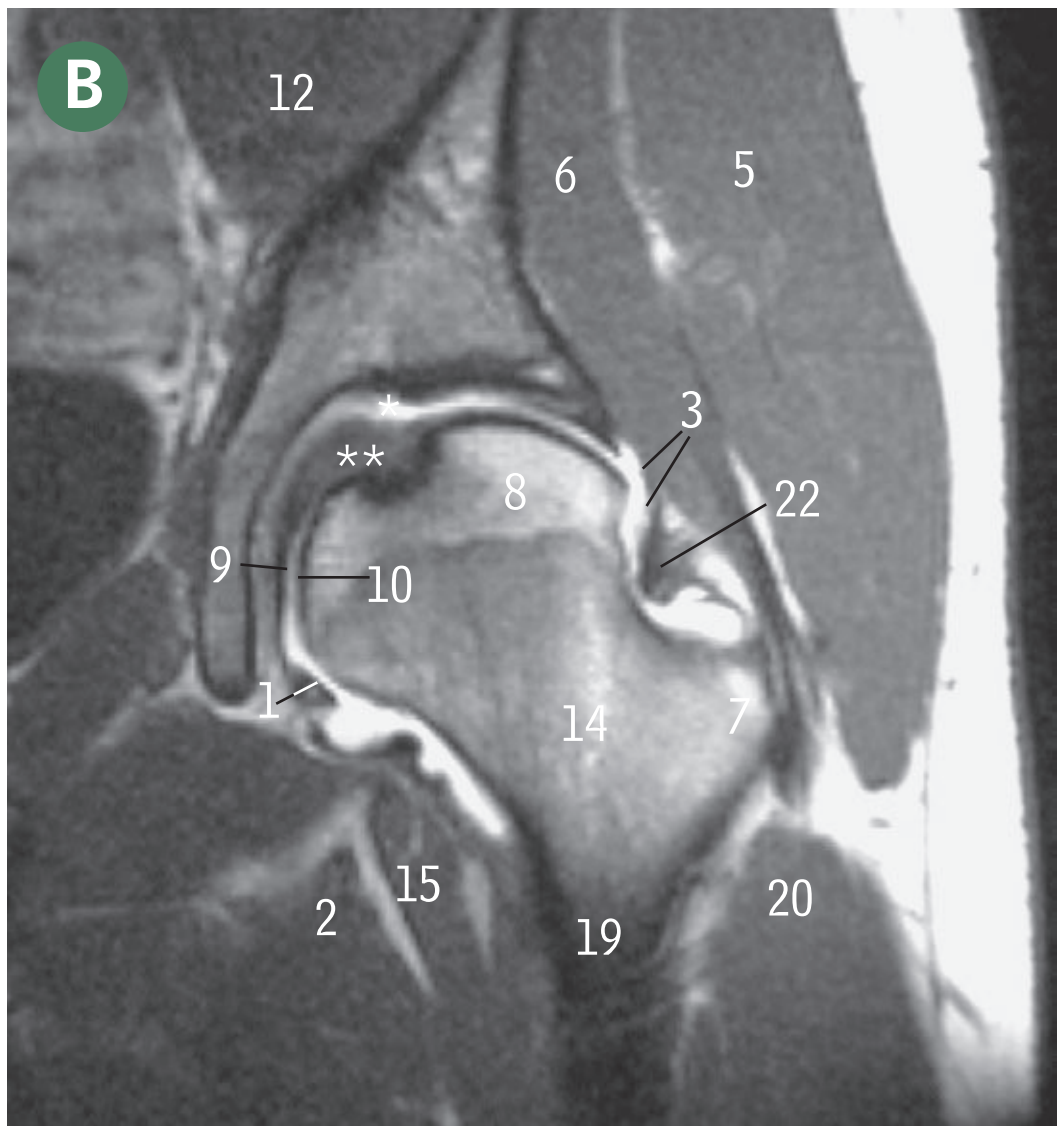

The convergence of gluteus medius and minimus (5 and 6) on to the greater trochanter is well displayed in this section. These muscles are classified as abductors of the femur at the hip joint, but their more important action is in walking, where they act to prevent adduction – preventing the pelvis from tilting to the opposite side when the opposite limb is off the ground (see Trendelenburg's sign, page 357).

Total hip replacement surgery, see pages 355–357.

C Left hip and sacro-iliac joint *3D surface rendered 64 slice CT*

1 Anterior superior iliac spine
2 First coccygeal vertebra
3 Greater trochanter of femur
4 Head of femur
5 Inferior pubic ramus
6 Ischium
7 Ischial tuberosity
8 Lesser trochanter of femur
9 Neck of femur
10 Obturator foramen
11 Pectineal line
12 Promontory of sacrum
13 Pubic symphysis
14 Pubic tubercle
15 Rim of acetabulum
16 Sacro-iliac joint
17 Sacrum
18 Superior pubic ramus
19 Transverse process of fifth lumbar vertebra

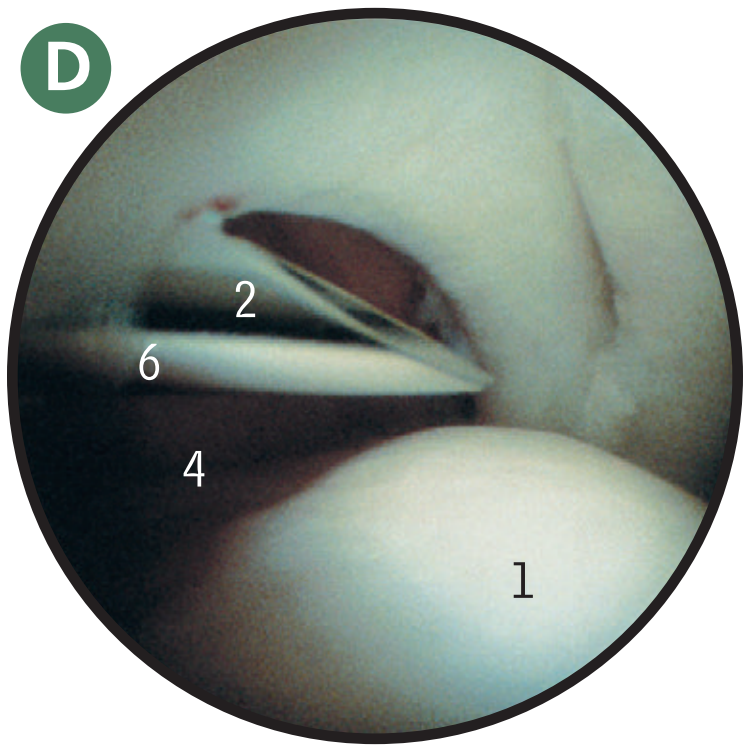

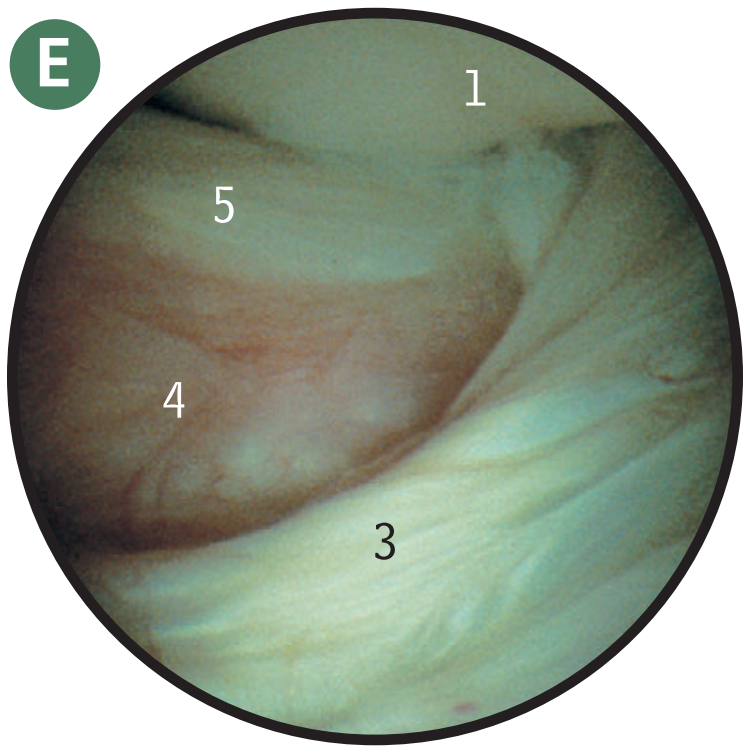

Hip joint

D E *arthroscopic views*

1 Femoral head
2 Irrigation needle
3 Ligamentum teres
4 Synovium
5 Transverse ligament
6 Zona orbicularis

Posterior hip dislocation, see pages 355–357.

Right knee
partially flexed

A from the lateral side

B from the medial side

1 Biceps femoris
2 Common peroneal (fibular) nerve
3 Head of fibula
4 Iliotibial tract
5 Lateral head of gastrocnemius
6 Margin of condyle of femur
7 Margin of condyle of tibia
8 Patella
9 Patellar ligament
10 Popliteal fossa
11 Semimembranosus
12 Semitendinosus
13 Tuberosity of tibia
14 Vastus medialis

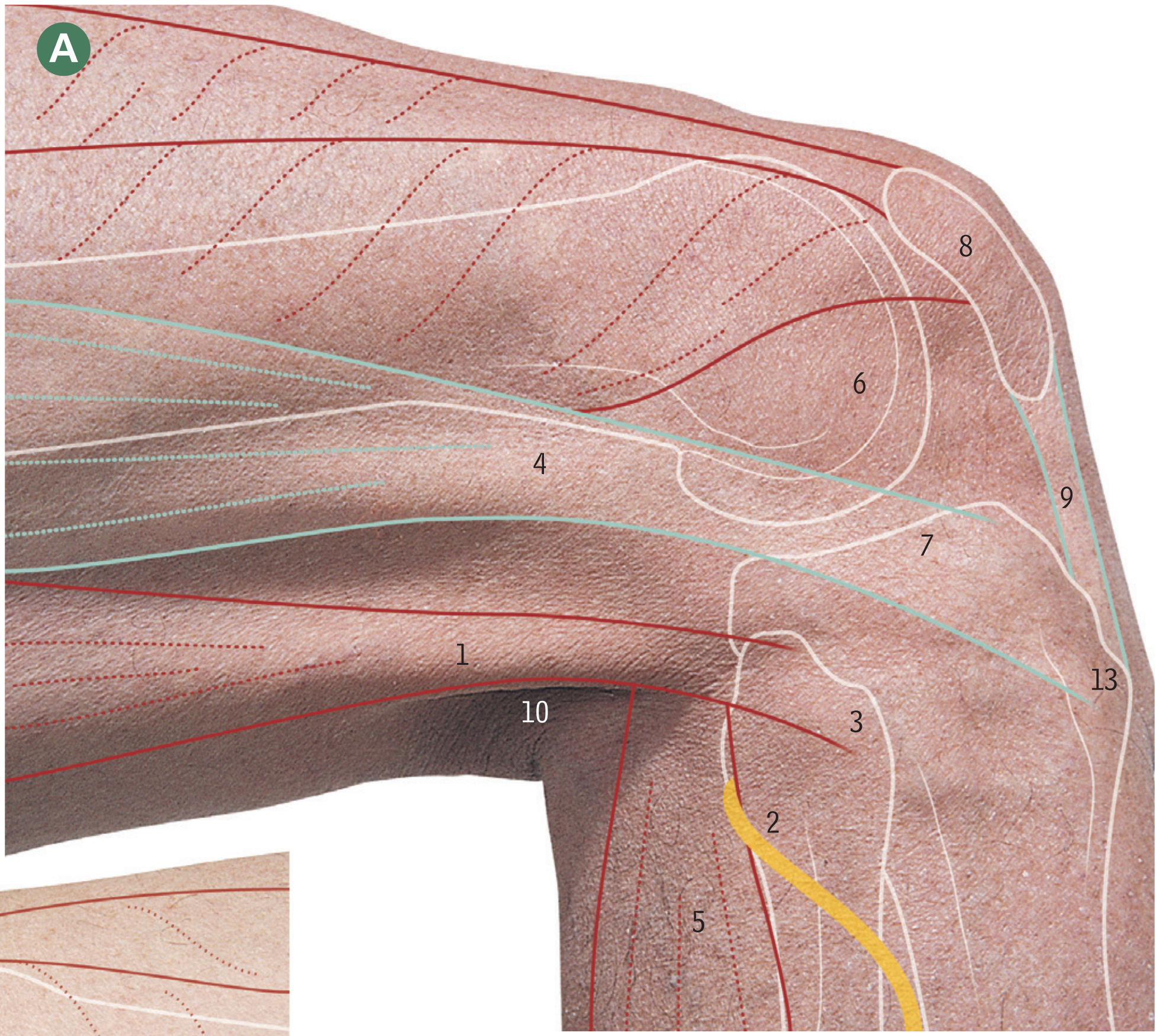

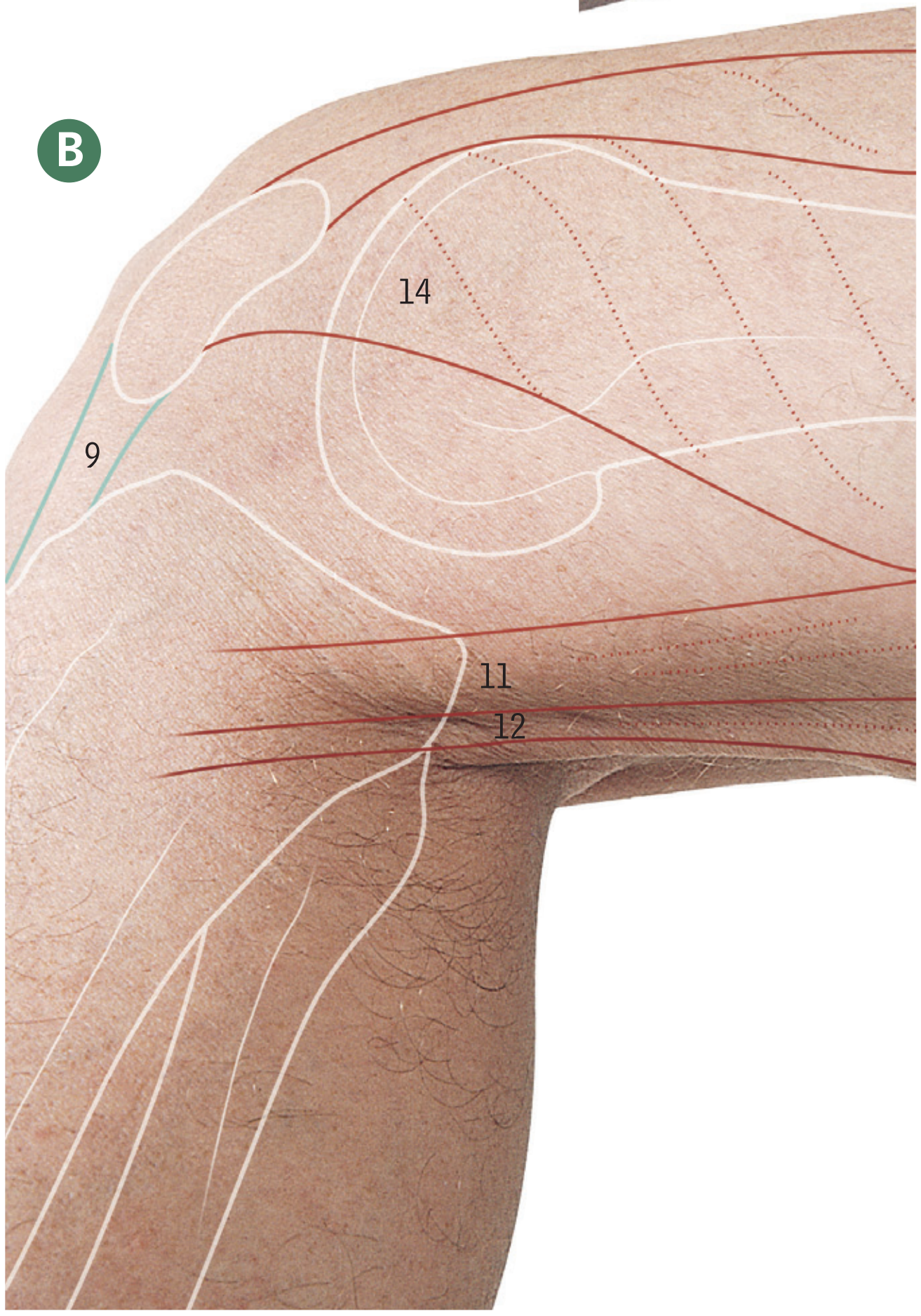

Behind the knee on the lateral side, the rounded tendon of biceps femoris (1) can be felt easily, with the broad strap-like iliotibial tract (4) in front of it, with a furrow between them. On the medial side, two tendons can be felt – the narrow rounded semitendinosus (12) just behind the broader semimembranosus (11). At the front, the patellar ligament (9) keeps the patella (8) at a constant distance from the tibial tuberosity (13), while at the side the adjacent margins of the femoral and tibial condyles (6 and 7) can be palpated.

Genu valgum, genu varum patellar tendon reflex, see pages 355–357.

C Right knee
superficial dissection, from the lateral side

The fascia behind biceps femoris (2) has been removed to show the common peroneal (fibular) nerve (3) passing downwards immediately behind the tendon, and then running between the adjacent borders of soleus (12) and peroneus (fibularis) longus (5), under cover of which it lies against the neck of the fibula. Minor superficial vessels and nerves have been removed.

1 Attachment of iliotibial tract to tibia
2 Biceps femoris
3 Common peroneal (fibular) nerve
4 Deep fascia overlying extensor muscles
5 Deep fascia overlying peroneus (fibularis) longus
6 Fascia lata
7 Head of fibula
8 Iliotibial tract
9 Lateral cutaneous nerve of calf
10 Lateral head of gastrocnemius
11 Patella
12 Soleus

The iliotibial tract (8) is the thickened lateral part of the fascia lata (6). At its upper part, the tensor fasciae latae and most of gluteus maximus are inserted into it.

Its subcutaneous position and contact with the neck of the fibula make the common peroneal (fibular) nerve (3) the most commonly injured nerve in the lower limb.

D Right knee
superficial dissection, from the medial side

The great saphenous vein (3) runs upwards about a hand's breadth behind the medial border of the patella (7). The saphenous nerve (8) becomes superficial between the tendons of sartorius (9) and gracilis (2), and its infrapatellar branch (4) curls forwards a little below the upper margin of the tibial condyle.

1 Branches of medial femoral cutaneous nerve
2 Gracilis
3 Great saphenous vein
4 Infrapatellar branch of saphenous nerve
5 Level of margin of medial condyle of tibia
6 Medial head of gastrocnemius
7 Patella
8 Saphenous nerve
9 Sartorius
10 Semitendinosus
11 Vastus medialis

Right popliteal fossa *superficial dissections*

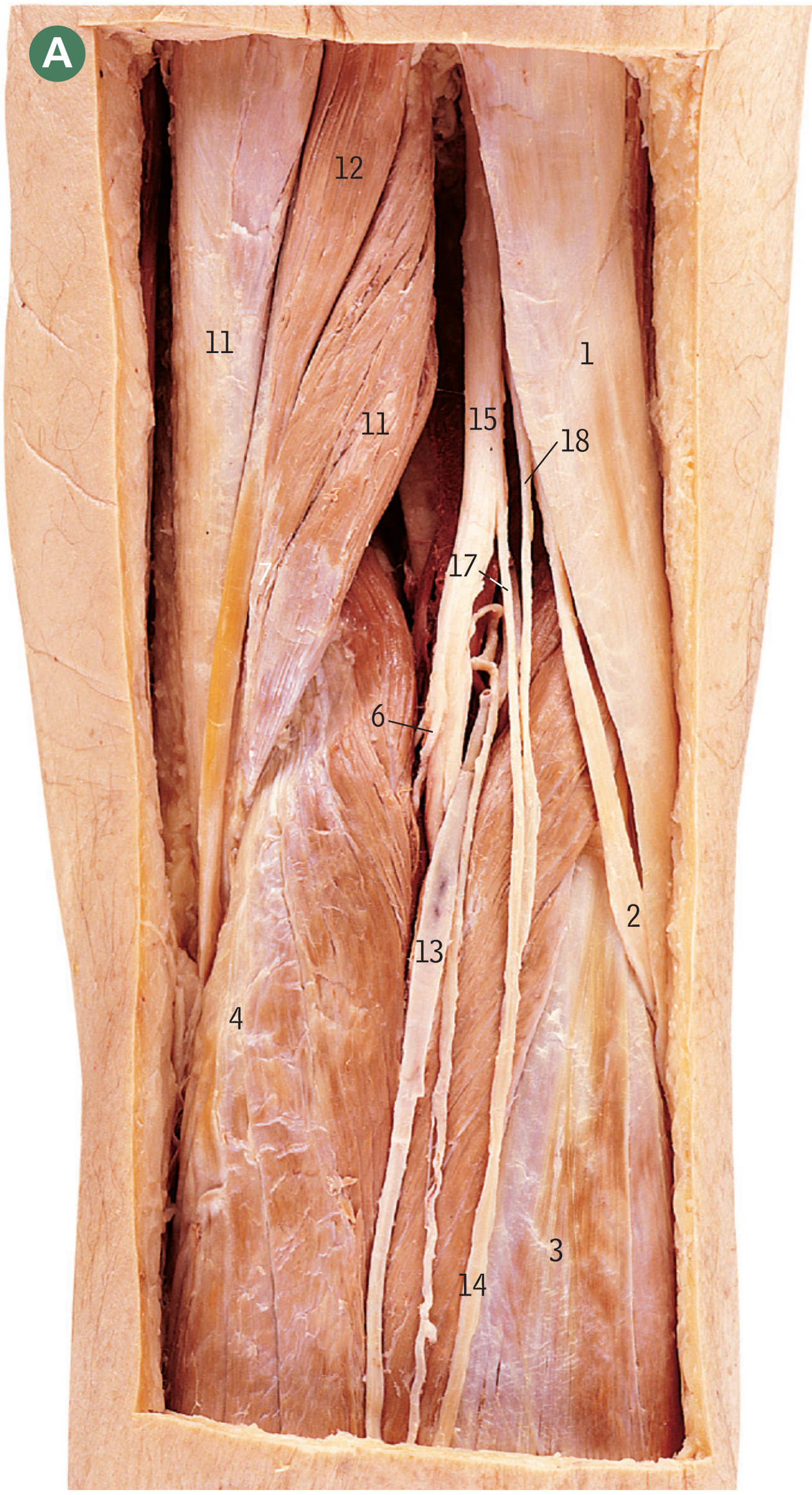

A **Skin and fascia forming the roof of the diamond-shaped popliteal fossa and the fat within it have been removed but the small saphenous vein which pierces the fascia has been preserved. A high (proximal) union of the lateral and medial sural cutaneous nerves places the sural nerve in this field.**

B **Heads of gastrocnemius have been separated to show deeper structures.**

1. Biceps femoris
2. Common peroneal (fibular) nerve
3. Gastrocnemius, lateral head
4. Gastrocnemius, medial head
5. Gracilis
6. Nerve to medial head of gastrocnemius
7. Plantaris
8. Popliteal artery
9. Popliteal vascular branches to gastrocnemius
10. Popliteal vein
11. Semimembranosus
12. Semitendinosus
13. Small saphenous vein
14. Sural nerve
15. Tibial nerve
16. Tibial nerve, muscular branches
17. Sural nerve, branch from tibial
18. Sural nerve, branch from common peroneal (fibular)

Popliteal fossa *progressive dissections*

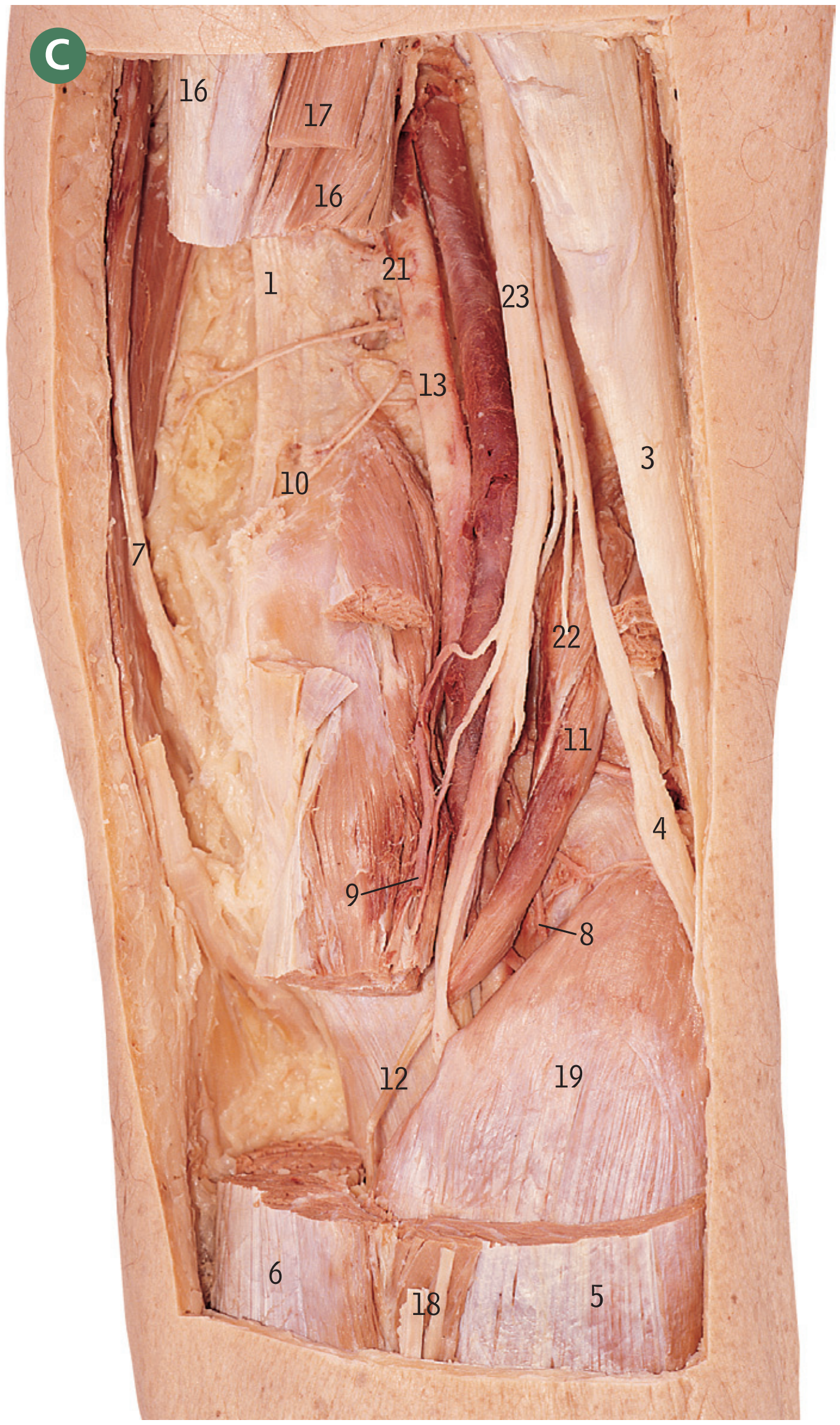

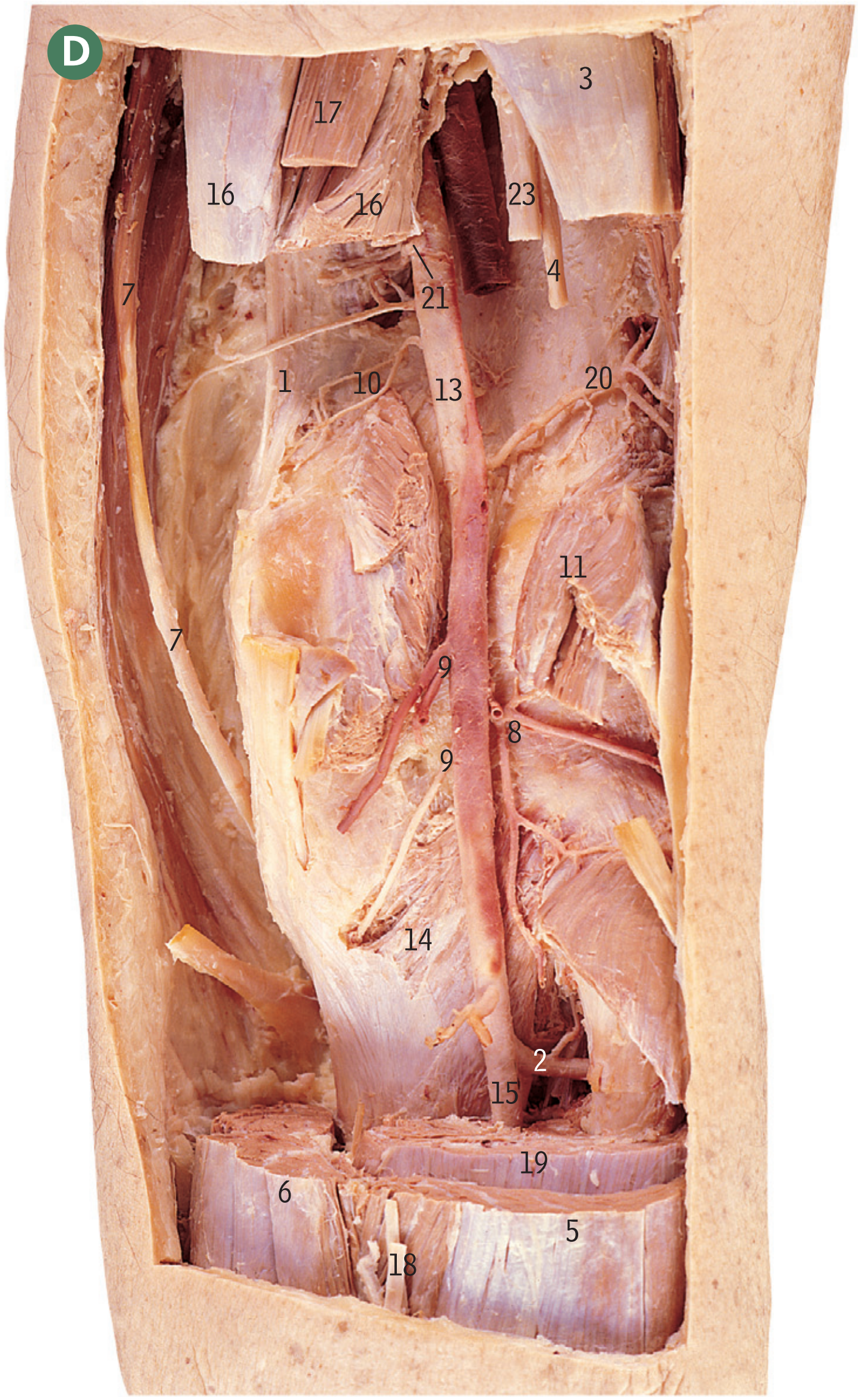

C **Removal of semitendinosus, semimembranosus and most of the origins of the gastrocnemius reveals plantaris and branches of the deeply situated popliteal artery and soleus.**

D **Removal of the muscular boundaries of the popliteal fossa shows the popliteal artery, its genicular anastomoses and its terminal branches, the anterior and posterior tibial arteries.**

1 Adductor magnus
2 Anterior tibial artery
3 Biceps femoris
4 Common peroneal (fibular) nerve
5 Gastrocnemius, lateral head
6 Gastrocnemius, medial head
7 Gracilis
8 Inferior lateral genicular artery
9 Inferior medial genicular artery
10 Middle genicular artery
11 Plantaris muscle
12 Plantaris tendon
13 Popliteal artery
14 Popliteus
15 Posterior tibial artery
16 Semimembranosus
17 Semitendinosus
18 Short saphenous vein
19 Soleus
20 Superior lateral genicular artery
21 Superior medial genicular artery
22 Sural nerve
23 Tibial nerve

Popliteal (Baker's) cyst, popliteal artery aneurysm, sural nerve graft, see pages 355–357.

Left knee joint *ligaments*

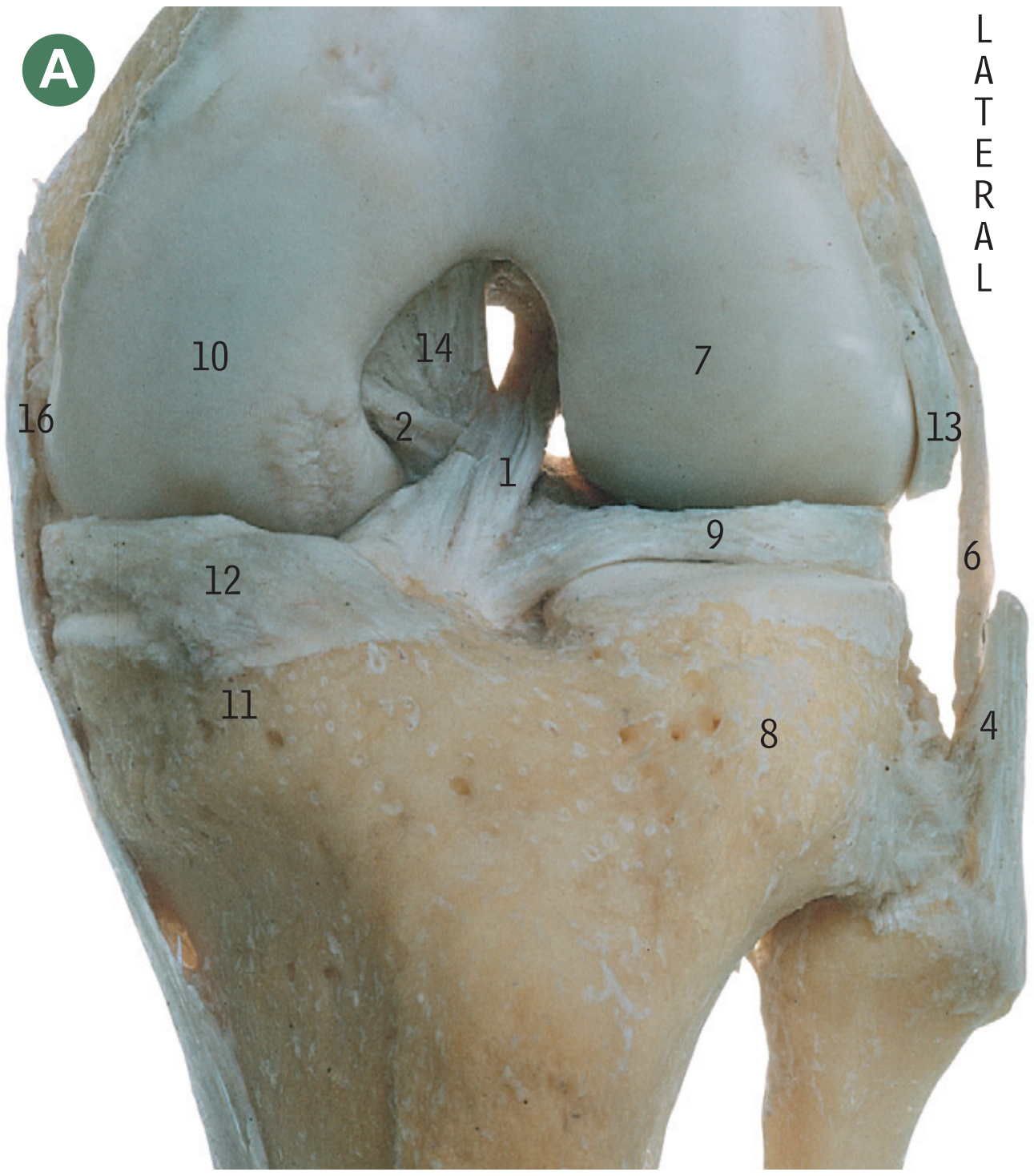

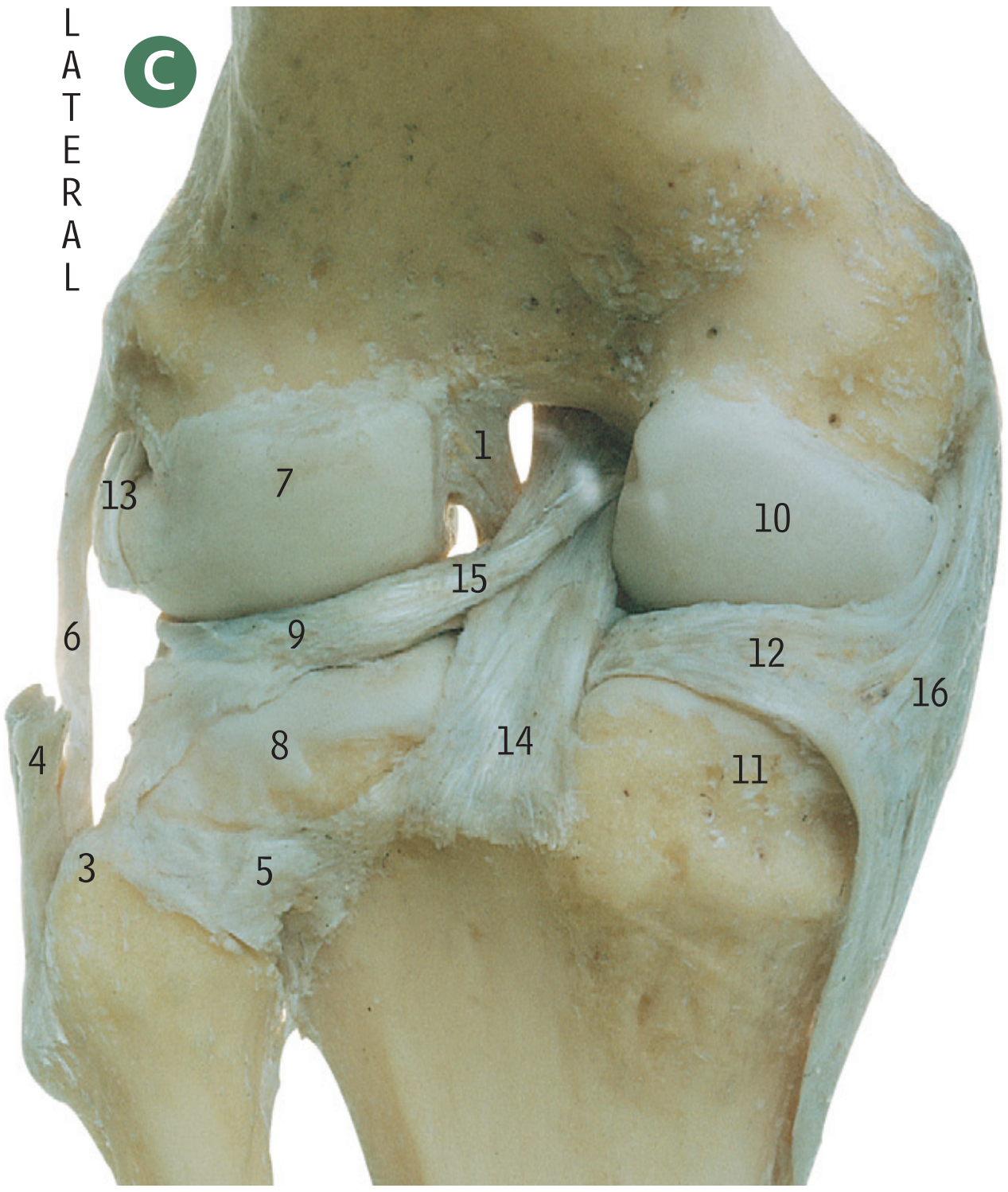

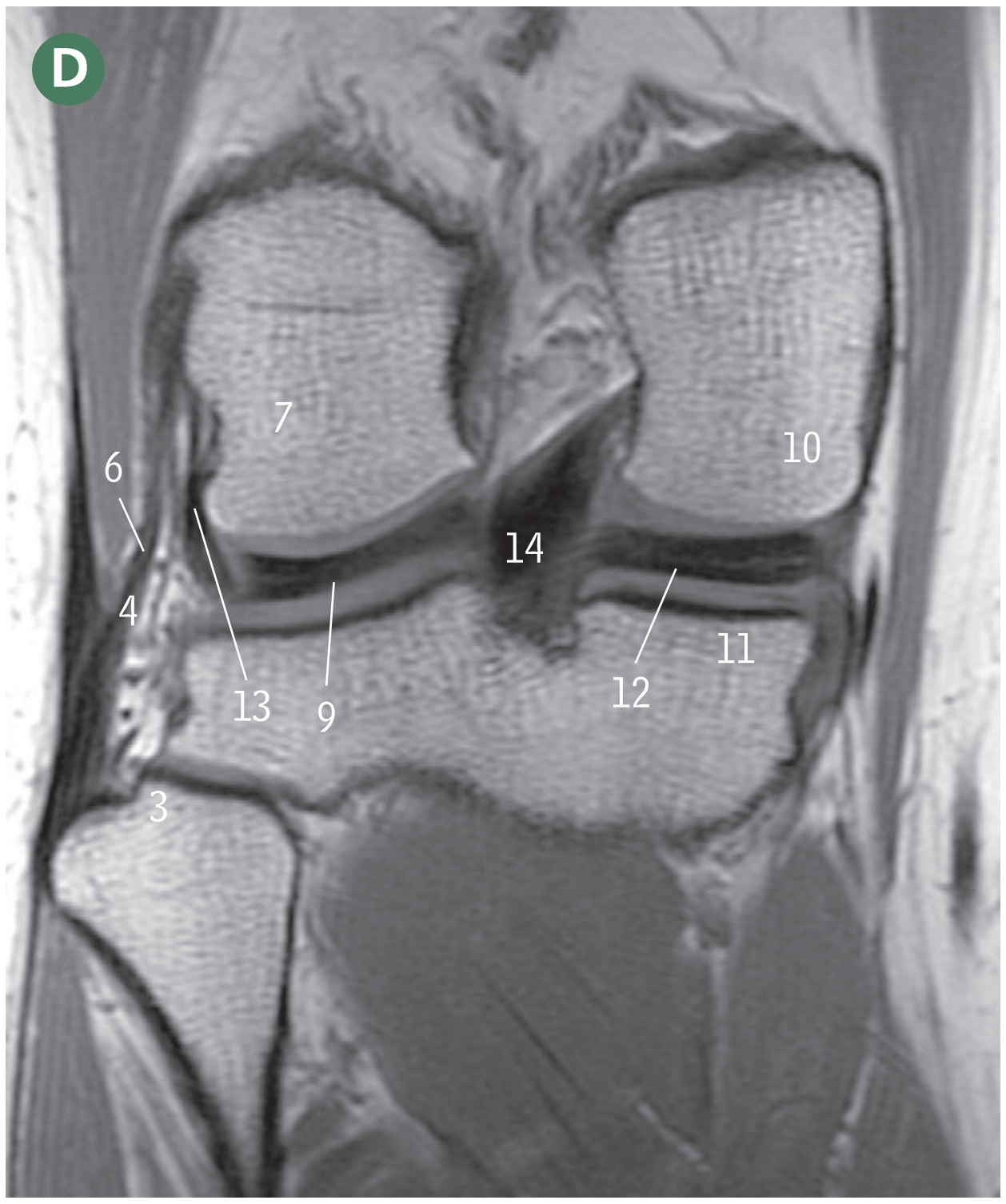

A from the front **C from behind**

The capsule of the knee joint and all surrounding tissues have been removed, leaving only the ligaments of the joint, which is partially flexed.

B coronal MR image **D coronal MR image**

1 Anterior cruciate ligament
2 Anterior meniscofemoral ligament
3 Apex of head of fibula
4 Biceps femoris tendon
5 Capsule of superior tibiofibular joint
6 Fibular (lateral) collateral ligament
7 Lateral condyle of femur
8 Lateral condyle of tibia
9 Lateral meniscus
10 Medial condyle of femur
11 Medial condyle of tibia
12 Medial meniscus
13 Popliteus tendon
14 Posterior cruciate ligament
15 Posterior meniscofemoral ligament
16 Tibial (medial) collateral ligament

The fibular collateral (lateral) ligament (A6) is a rounded cord about 5 cm long, passing from the lateral epicondyle of the femur to the head of the fibula just in front of its apex (C3), largely under cover of the tendon of biceps femoris (C4).

The medial meniscus is attached to the deep part of the tibial (medial) collateral ligament. This helps to anchor the meniscus but makes it liable to become trapped and torn by rotatory movements between the tibia and femur.

The lateral meniscus (A9) is not attached to the fibular (lateral) collateral ligament (A6), but is attached posteriorly to the popliteus muscle.

The tibial collateral (medial) ligament is a broad flat band about 12 cm long, passing from the medial epicondyle of the femur to the medial condyle of the tibia and an extensive area of the medial surface of the tibia below the condyle.

The cruciate ligaments are named from their attachments to the tibia.

The anterior cruciate ligament (A1) passes upwards, backwards and laterally to be attached to the medial side of the lateral condyle of the femur (C7).

The posterior cruciate ligament (C14) passes upwards, forwards and medially to be attached to the lateral surface of the medial condyle of the femur (A10).

Left knee tibial plateau *from above*

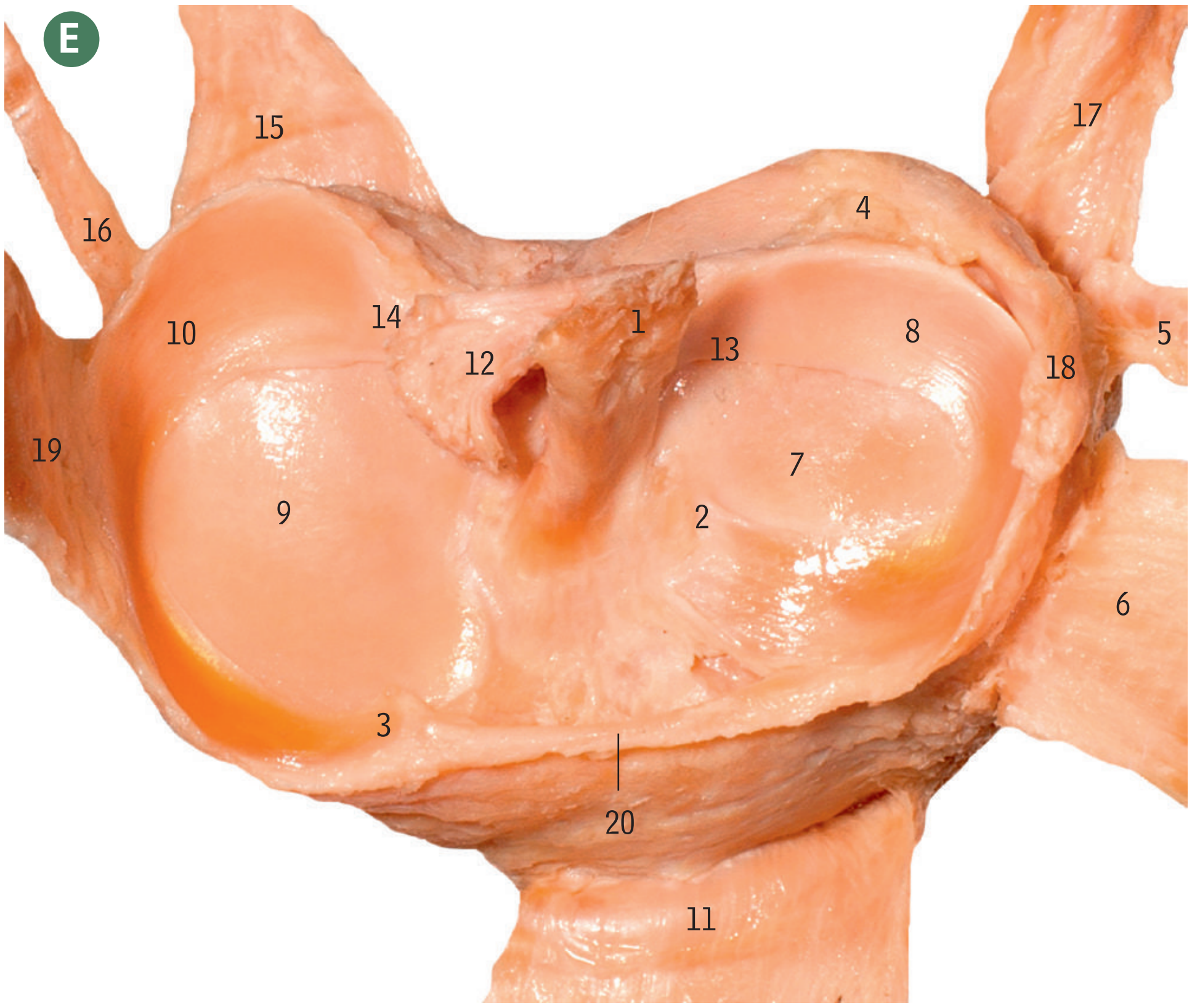

Axial MR, knee

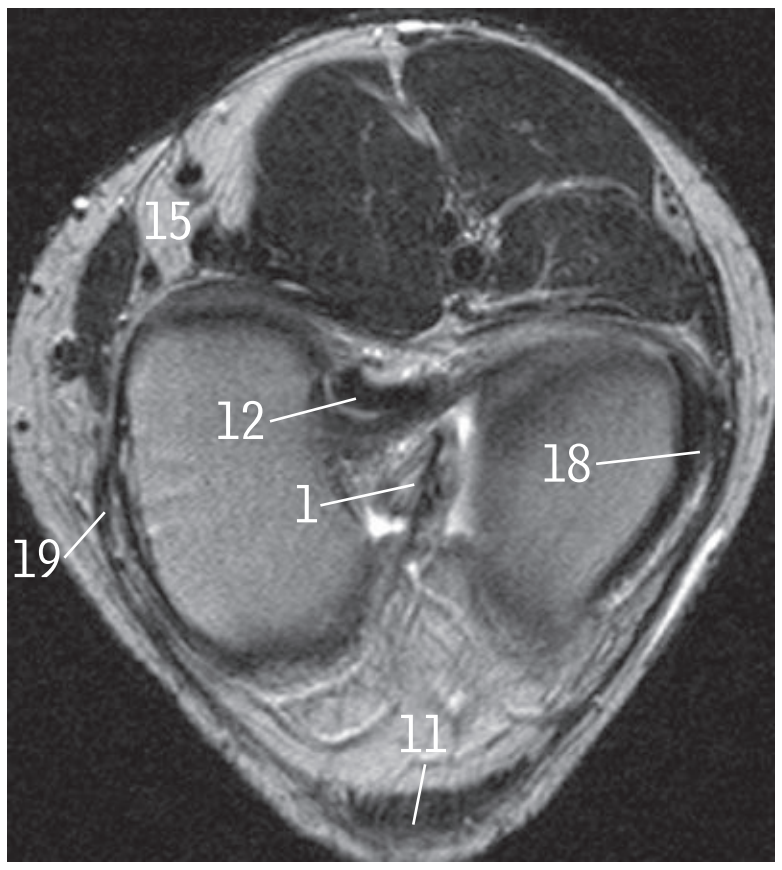

1 Anterior cruciate ligament
2 Anterior horn of lateral meniscus
3 Anterior horn of medial meniscus
4 Attachment of lateral meniscus to popliteus muscle
5 Fibular collateral ligament
6 Iliotibial tract
7 Lateral condyle of tibia
8 Lateral meniscus
9 Medial condyle of tibia
10 Medial meniscus
11 Patellar ligament (tendon)
12 Posterior cruciate ligament
13 Posterior horn of lateral meniscus
14 Posterior horn of medial meniscus
15 Semimembranosus (tendon)
16 Semitendinosus (tendon)
17 Tendon of biceps femoris muscle
18 Tendon of popliteus muscle
19 Tibial collateral ligament attachment to medial meniscus
20 Transverse ligament

Meniscal tears, rupture–anterior cruciate ligament, see pages 355–357.

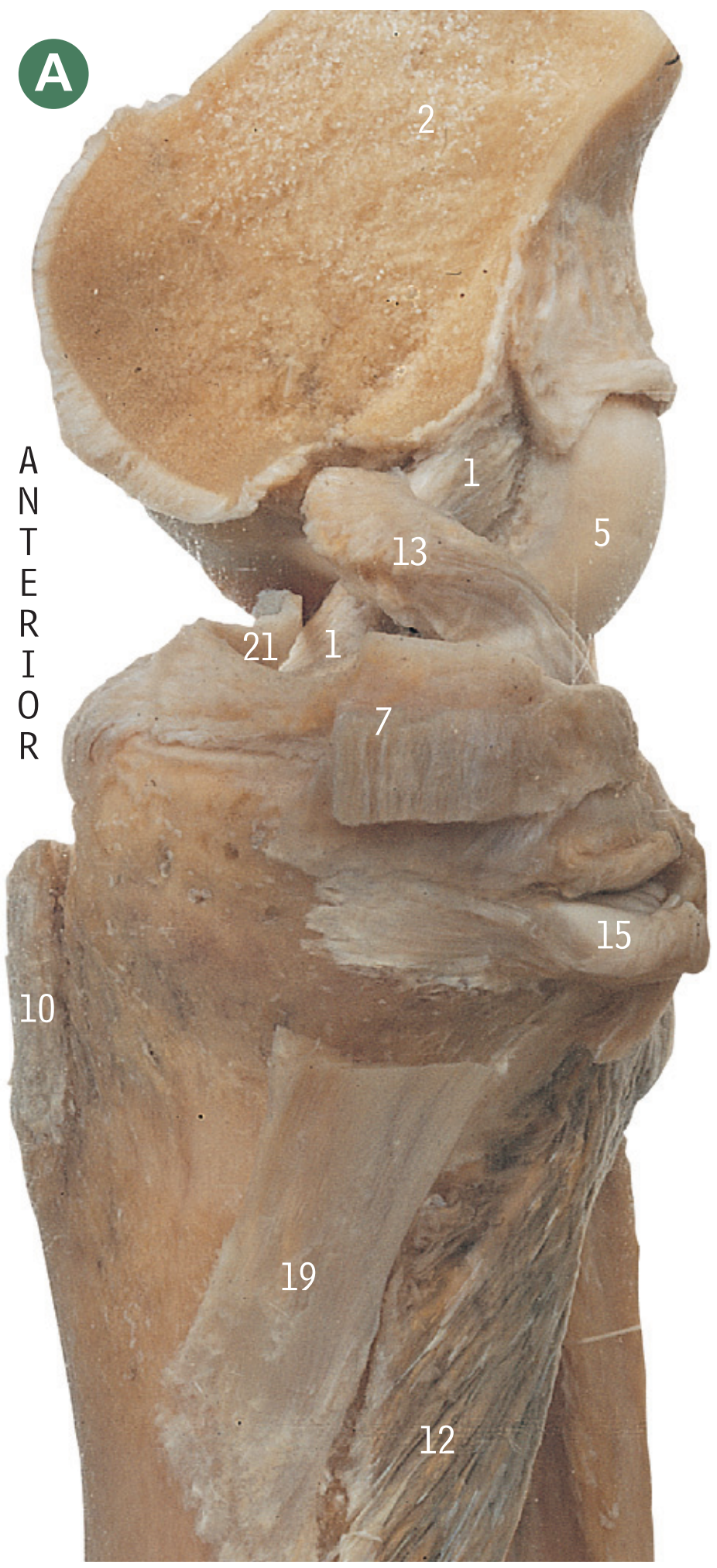

Right knee joint

A from the medial side with the medial femoral condyle removed

B sagittal MR image

Removal of the medial half of the lower end of the femur enables the X-shaped crossover of the cruciate ligaments to be seen; the anterior cruciate (1) is passing backwards and laterally, while the posterior cruciate (13) passes forwards and medially. The MR image in B shows the infrapatellar fat pad (3).

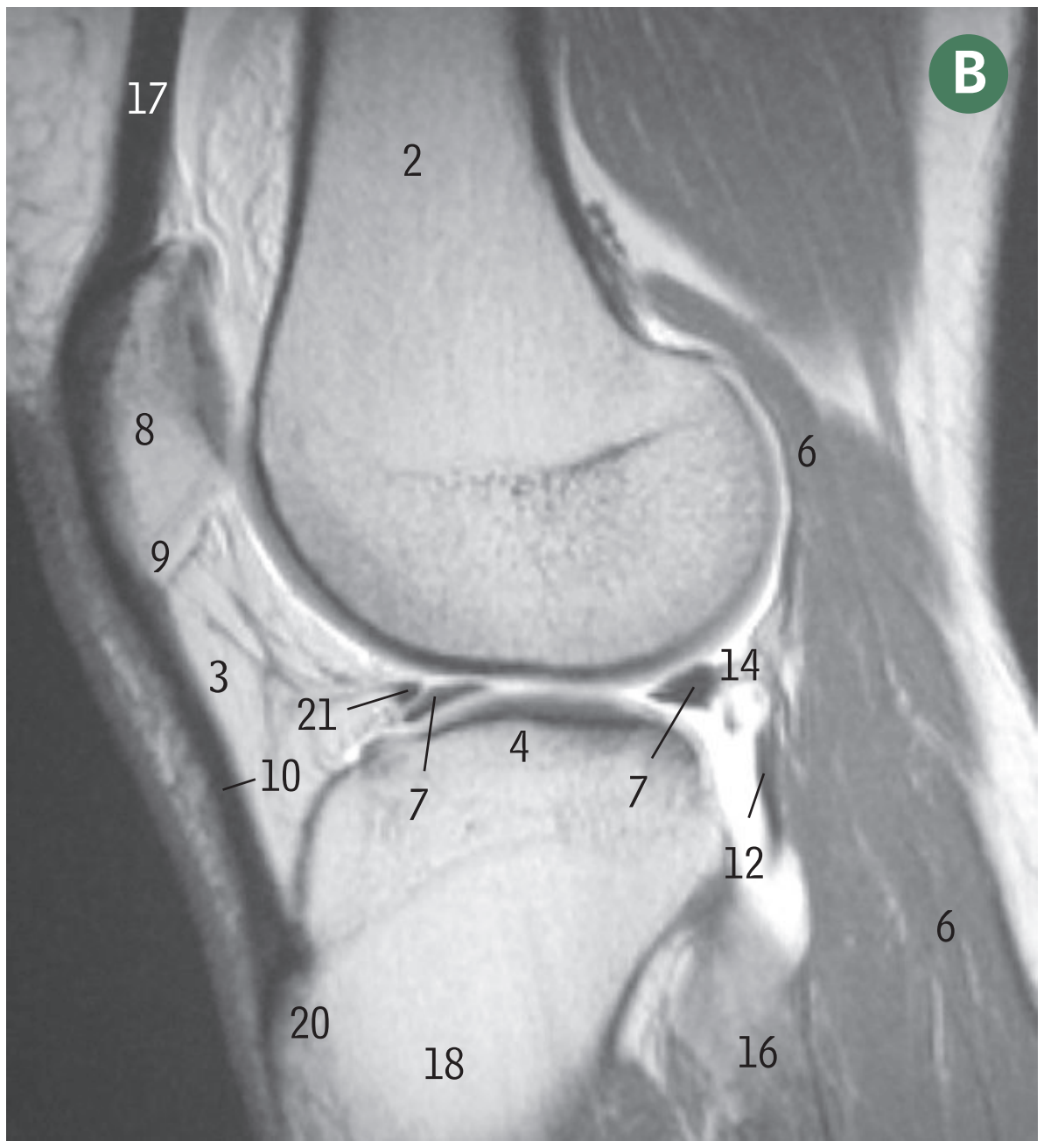

1 Anterior cruciate ligament
2 Femur
3 Infrapatellar fat pad (Hoffa)
4 Intercondylar notch
5 Lateral condyle of femur
6 Lateral head of gastrocnemius muscle
7 Lateral meniscus
8 Patella
9 Patellar apex
10 Patellar ligament (tendon)
11 Popliteal artery and vein
12 Popliteus
13 Posterior cruciate ligament
14 Posterior meniscofemoral ligament
15 Semimembranosus
16 Soleus
17 Tendon of quadriceps
18 Tibia
19 Tibial (medial) collateral ligament
20 Tibial tubercle
21 Transverse (intermeniscal) ligament

Left knee *arthroscopic views*

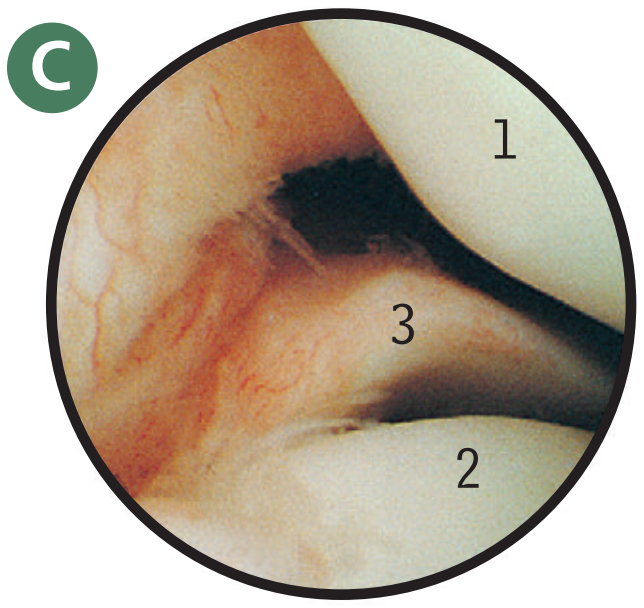

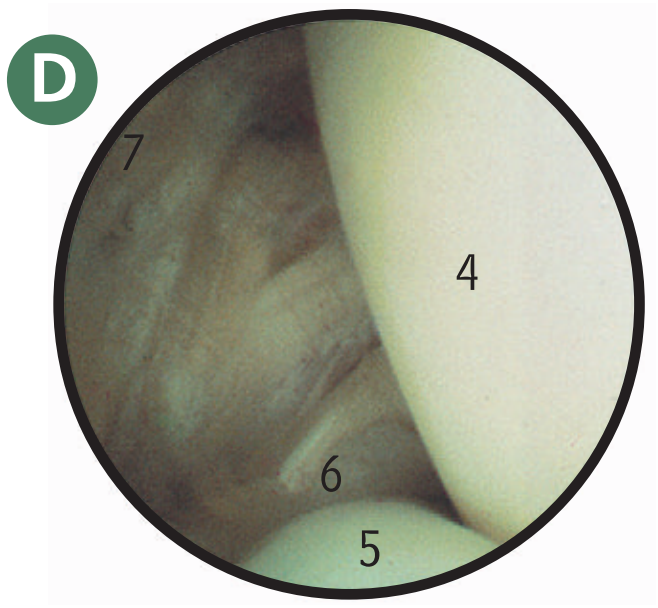

C anterolateral approach

D posteromedial approach

1 Lateral condyle of femur
2 Lateral condyle of tibia
3 Lateral meniscus
4 Medial condyle of femur
5 Medial meniscus
6 Posterior cruciate ligament
7 Posterior part of capsule

Rupture–posterior cruciate ligament, suprapatellar bursitis, see pages 355–357.

E

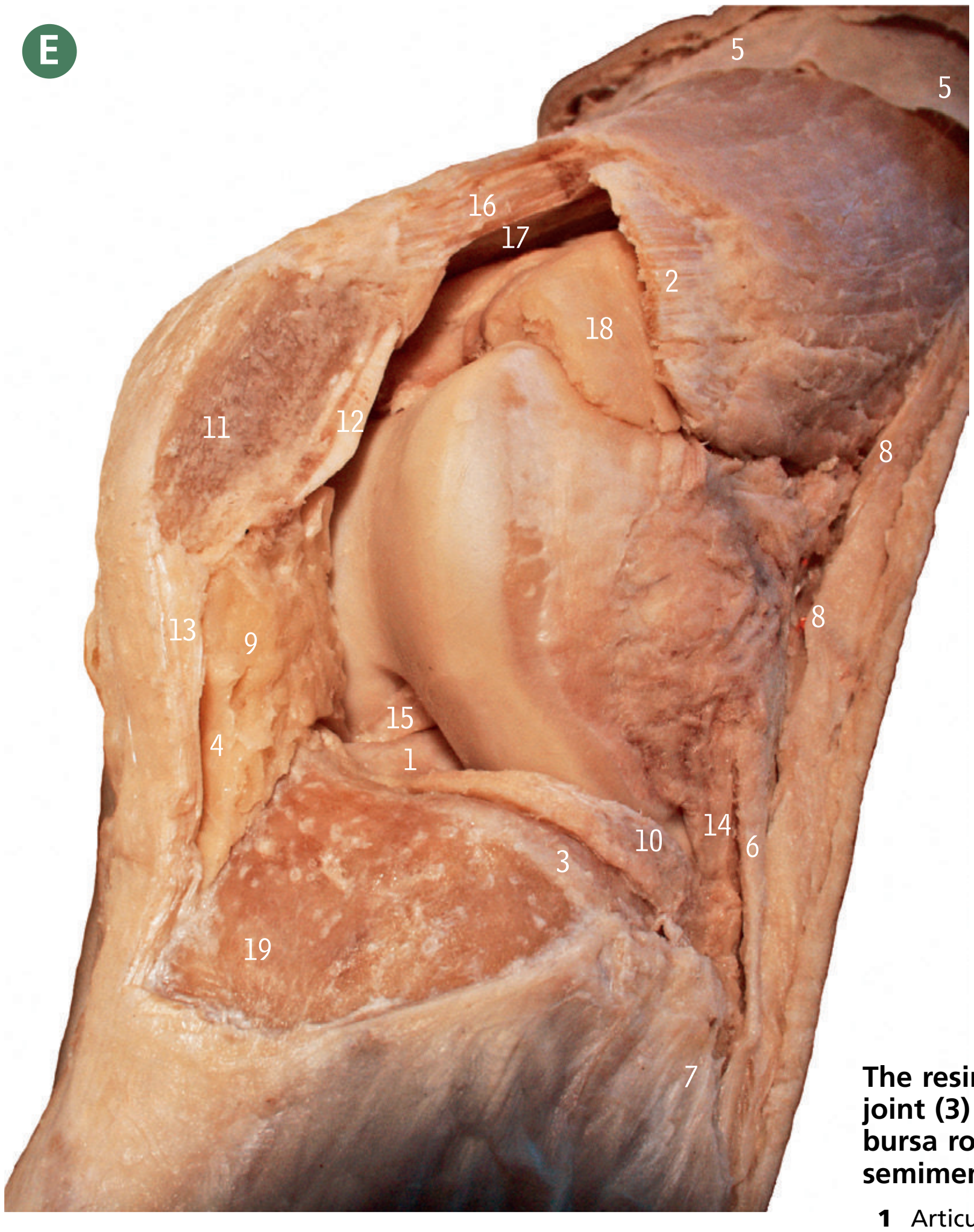

E Left knee joint

opened from the lateral side to reveal internal structures

1 Anterior cruciate ligament
2 Aponeurosis of vastus lateralis (cut edge)
3 Articular cartilage, tibial plateau
4 Deep infrapatellar bursa
5 Fascia lata (deep fascia)
6 Fibular collateral ligament
7 Head of fibula
8 Iliotibial tract (cut edge)
9 Infrapatellar fat pad (Hoffa)
10 Lateral meniscus
11 Patella
12 Patellar articular cartilage
13 Patellar ligament (tendon)
14 Popliteus tendon, attachment to lateral tibial epicondyle
15 Posterior cruciate ligament
16 Quadriceps tendon
17 Suprapatellar bursa
18 Suprapatellar fat pad
19 Tibial tuberosity

F Left knee joint

from the medial side, with synovial and bursal cavities injected

The resin injection has distended the synovial cavity of the joint (3) and extends into the suprapatellar bursa (10), the bursa round the popliteus tendon (2) and the semimembranosus bursa (9).

1 Articularis genu
2 Bursa of popliteus tendon
3 Capsule
4 Medial meniscus
5 Patella
6 Patellar ligament
7 Quadriceps tendon
8 Semimembranosus
9 Semimembranosus bursa
10 Suprapatellar bursa
11 Tibial (medial) collateral ligament

F

The suprapatellar bursa (F10) always communicates with the joint cavity. The bursa around the popliteus tendon (F2) usually does so. The semimembranosus bursa (F9) may do so.

G Anterior cruciate ligament

anterior arthroscopic view

G

Knee joint aspiration and injection, lower limb bursitis, prepatellar bursitis, see *pages 355–357.*

Knee *radiographs and arthroscopic views*

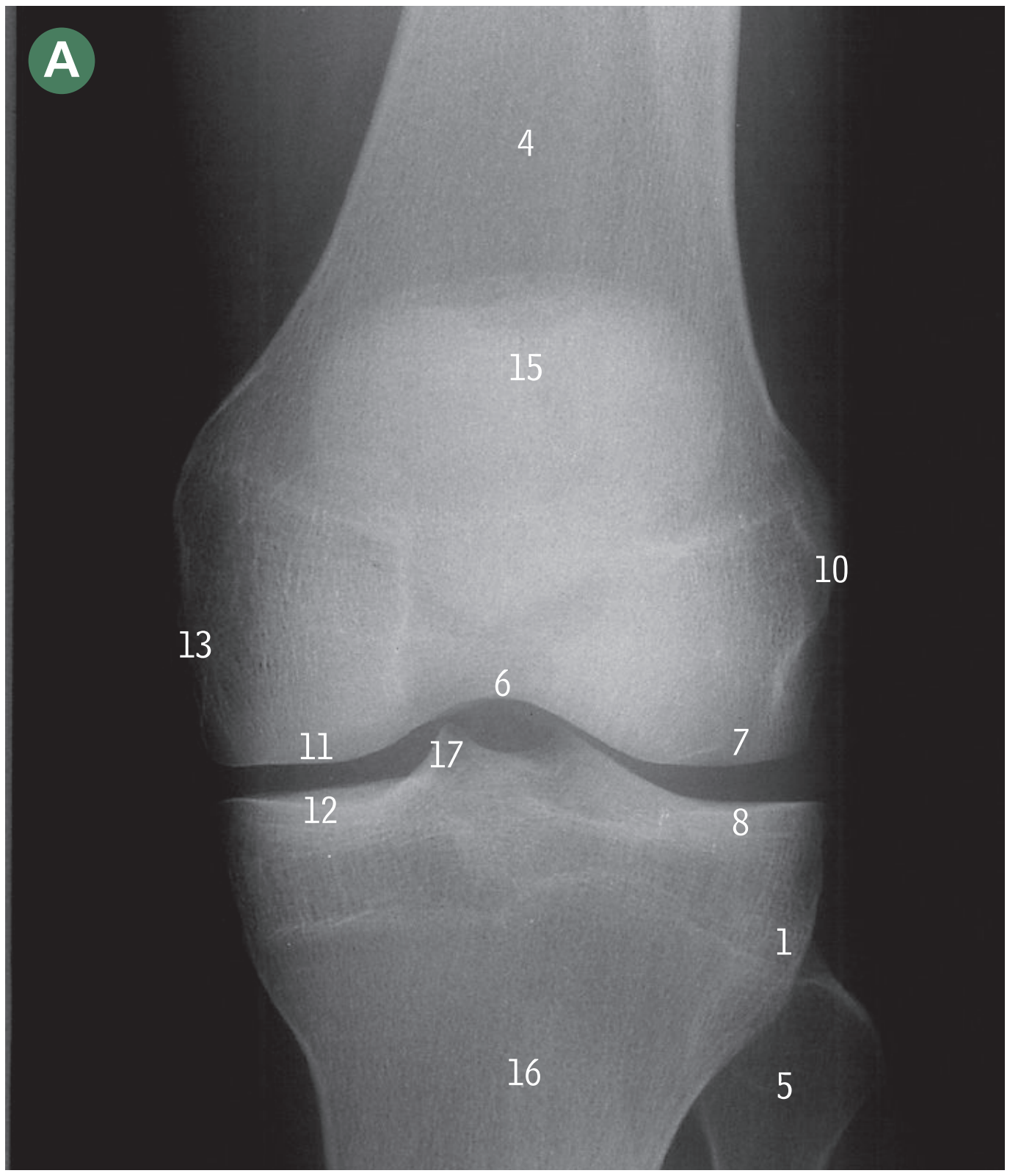

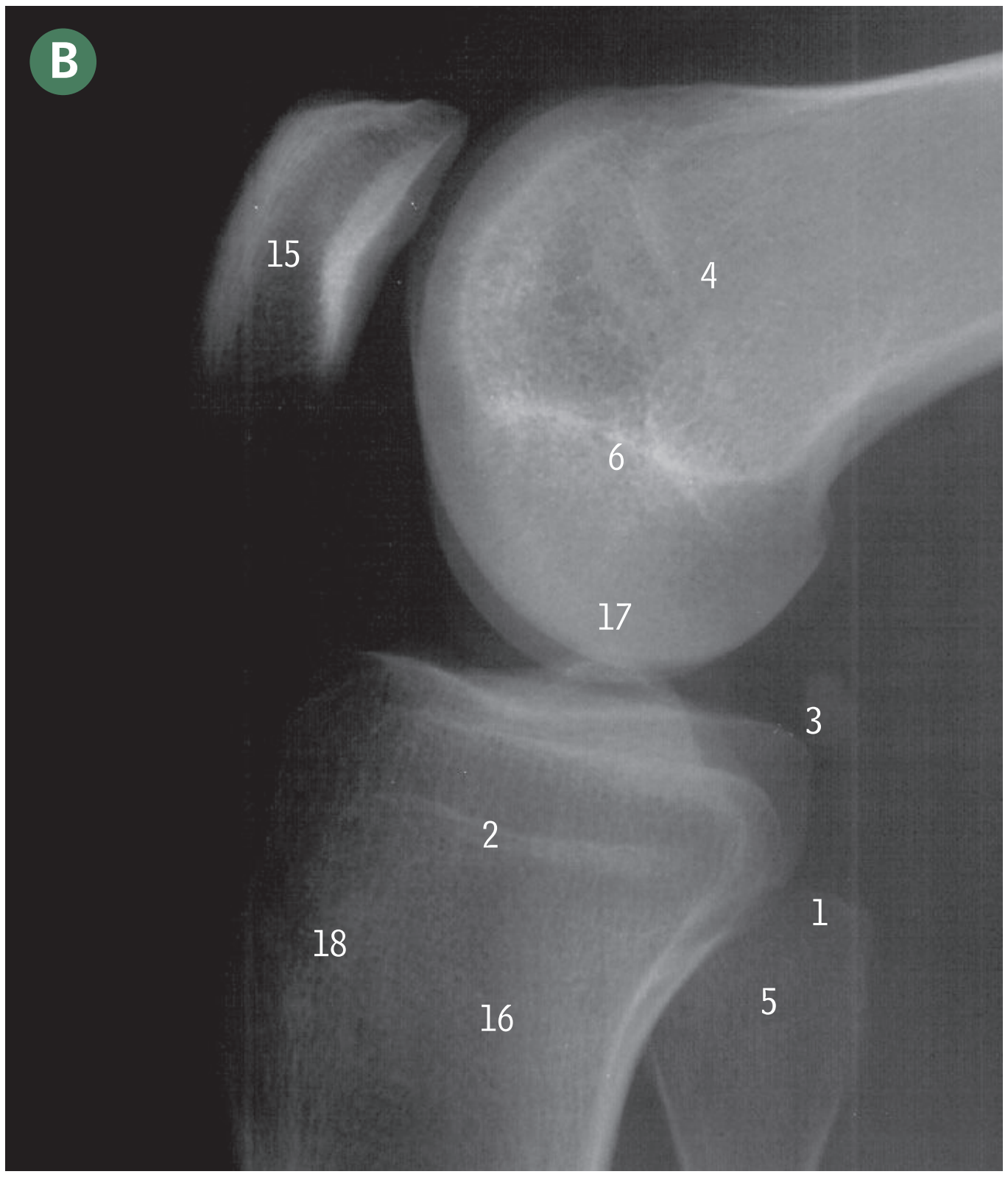

A **from the front**

B **from the lateral side in partial flexion**

C **skyline view projection**

D **anterolateral approach**

E **lateral view of patella**

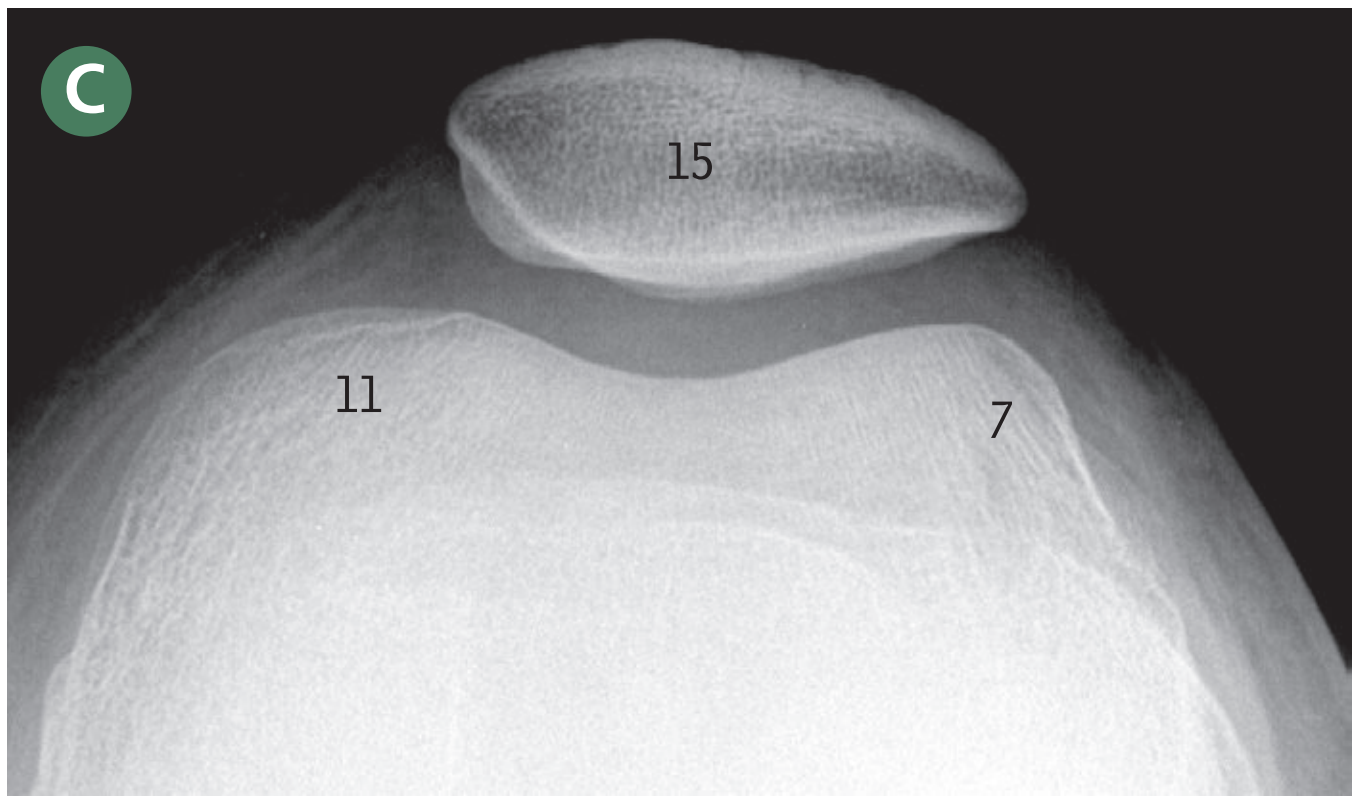

In A, the shadow of the patella (15) is superimposed on that of the femur. The regular space between the condyles of the femur and tibia (7 and 8, 11 and 12) is due to the thickness of the hyaline cartilage on the articulating surface, with the menisci at the periphery. In C, with the knee flexed, the view should be compared with the bones seen on page 299, E, and the lateral edge of the patella (9) is seen in the arthroscopic view in E.

1 Apex (styloid process) of fibula
2 Epiphysial line
3 Fabella
4 Femur
5 Head of fibula
6 Intercondylar fossa
7 Lateral condyle of femur
8 Lateral condyle of tibia
9 Lateral edge of patella
10 Lateral epicondyle of femur
11 Medial condyle of femur
12 Medial condyle of tibia
13 Medial epicondyle of femur
14 Medial meniscus
15 Patella
16 Tibia
17 Tubercles of intercondylar eminence
18 Tuberosity of tibia

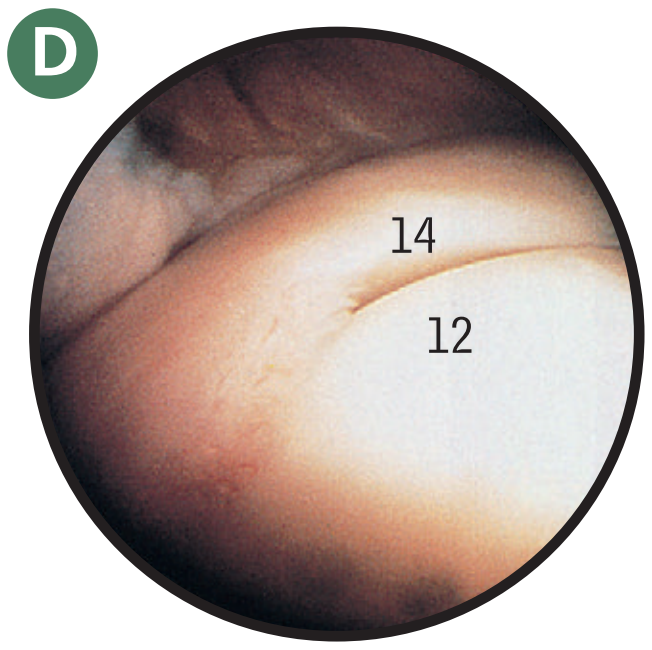

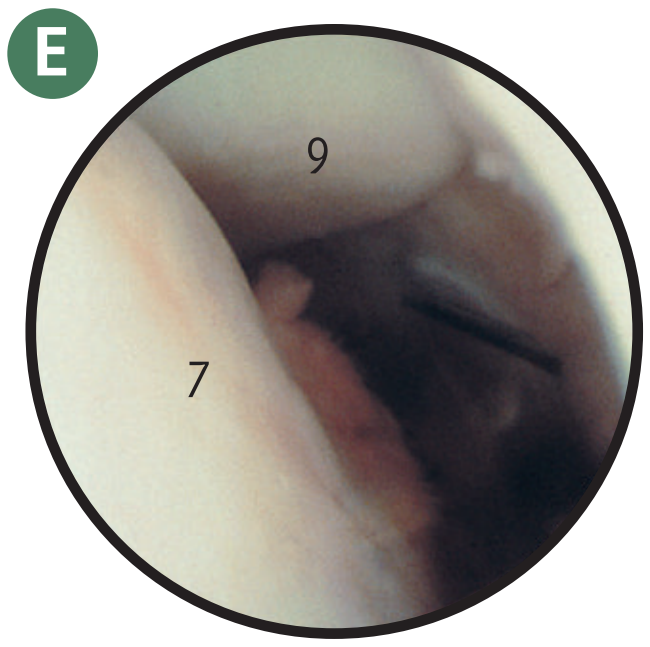

Knee joint replacement surgeries, see pages 355–357.

A Left leg *from the front and lateral side*

1 Anterior tibial artery overlying interosseous membrane
2 Branch of deep peroneal (fibular) nerve to tibialis anterior
3 Deep peroneal (fibular) nerve
4 Extensor digitorum longus
5 Extensor hallucis longus
6 Head of fibula
7 Lateral branch of superficial peroneal (fibular) nerve
8 Medial branch of superficial peroneal (fibular) nerve
9 Peroneus (fibularis) longus
10 Recurrent branch of common peroneal (fibular) nerve
11 Superficial peroneal (fibular) nerve
12 Tibialis anterior and overlying fascia
13 Tuberosity of tibia and patellar ligament

B Left knee *from the lateral side to show common peroneal (fibular) nerve and articular branches*

1 Anterior ligament of fibular head
2 Anterior tibial recurrent artery and vein
3 Articular branch from deep common peroneal (fibular) nerve
4 Articular vessels
5 Biceps femoris tendon
6 Common peroneal (fibular) nerve, deep branches
7 Common peroneal (fibular) nerve, overlying neck of fibula
8 Common peroneal (fibular) nerve, superficial branch
9 Extensor digitorum longus
10 Peroneus (fibularis) longus
11 Head of fibula
12 Iliotibial tract
13 Interosseous membrane
14 Lateral head, gastrocnemius muscle
15 Recurrent branch of deep peroneal (fibular) nerve
16 Tibialis anterior

Common peroneal (fibular) nerve paralysis, see pages 355–357.

Left knee and leg

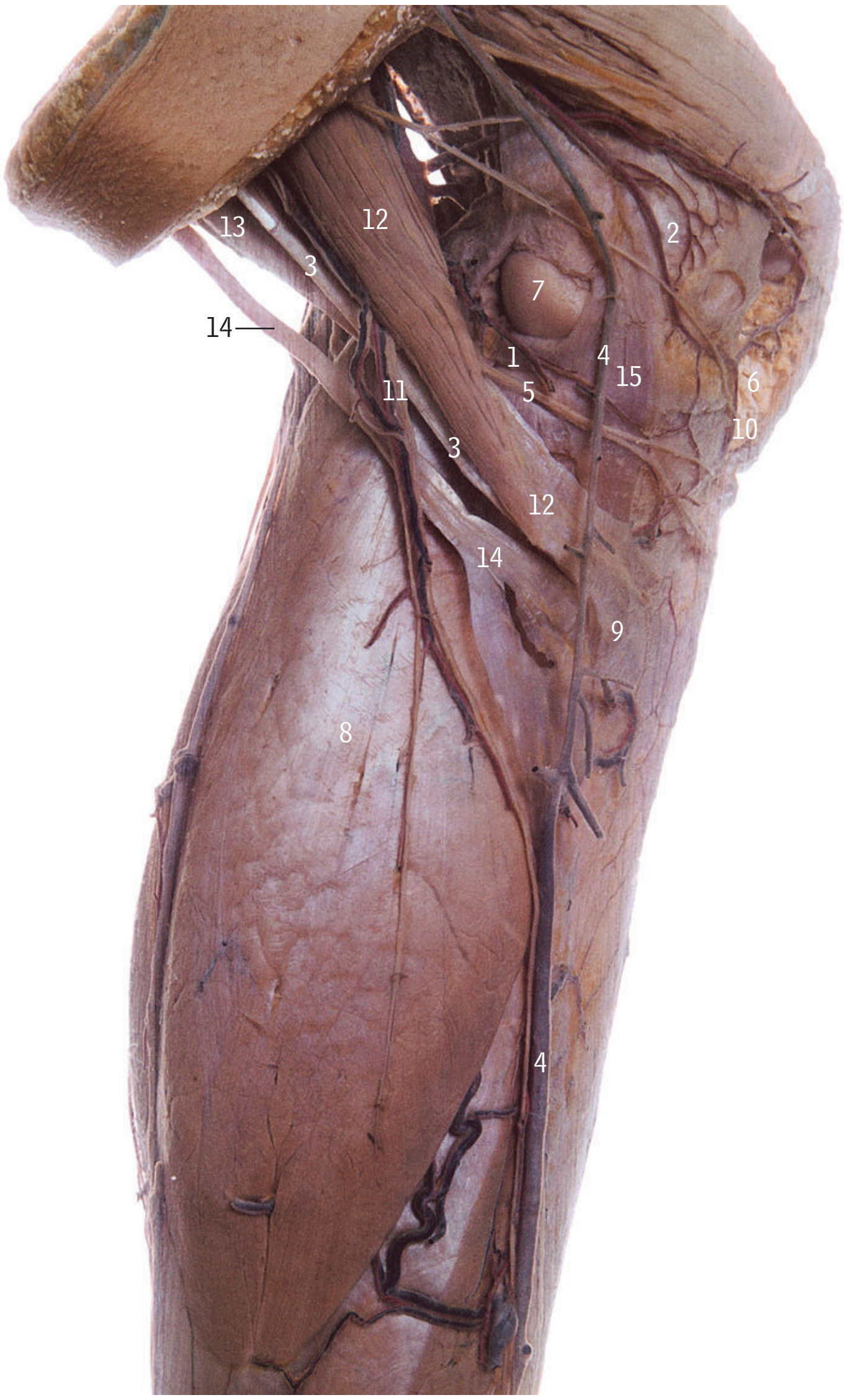

Left knee and leg A *from the medial side and behind*

A small window has been cut in the capsule of the knee joint to show part of the medial condyle of the femur (7) and the medial meniscus (1).

1. Branch of saphenous artery overlying medial meniscus
2. Branches of superior medial genicular artery
3. Gracilis
4. Great saphenous vein
5. Infrapatellar branch of saphenous nerve
6. Infrapatellar fat pad
7. Medial condyle of femur (part of capsule removed)
8. Medial head of gastrocnemius
9. Medial surface of tibia
10. Patellar ligament
11. Saphenous nerve and artery
12. Sartorius
13. Semimembranosus
14. Semitendinosus
15. Tibial (medial) collateral ligament

B *from the lateral side*

A small window has been cut in the capsule of the knee joint to show the tendon of popliteus (14) passing deep to the fibular (lateral) collateral ligament (5). The common peroneal (fibular) nerve (2) runs down behind biceps femoris (1) to pass through the gap between peroneus (fibularis) longus (13) and soleus (15). The superficial peroneal (fibular) nerve becomes superficial between peroneus (fibularis) longus (13) and extensor digitorum longus (3).

1. Biceps femoris
2. Common peroneal (fibular) nerve
3. Extensor digitorum longus
4. Fascia overlying tibialis anterior
5. Fibular (lateral) collateral ligament
6. Head of fibula
7. Iliotibial tract
8. Infrapatellar fat pad
9. Lateral cutaneous nerve of calf
10. Lateral head of gastrocnemius
11. Lateral meniscus
12. Patellar ligament
13. Peroneus (fibularis) longus
14. Popliteus
15. Soleus
16. Superficial peroneal (fibular) nerve

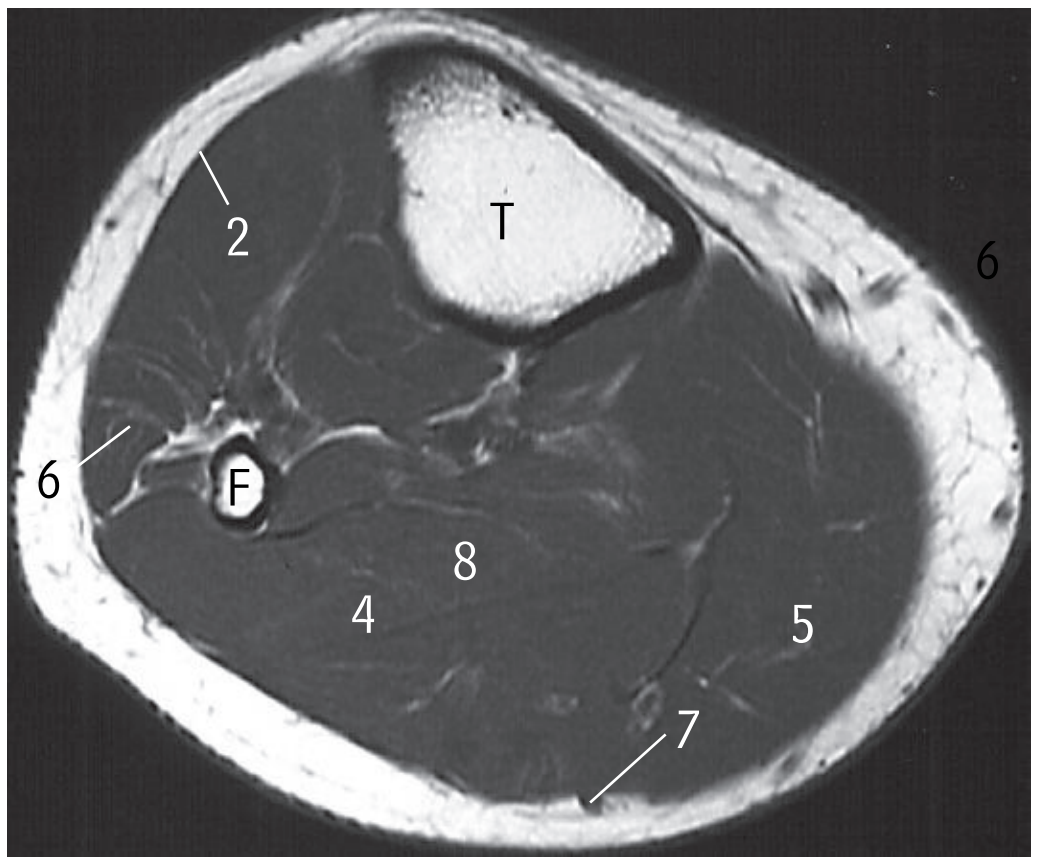

Axial T1w MR, calf

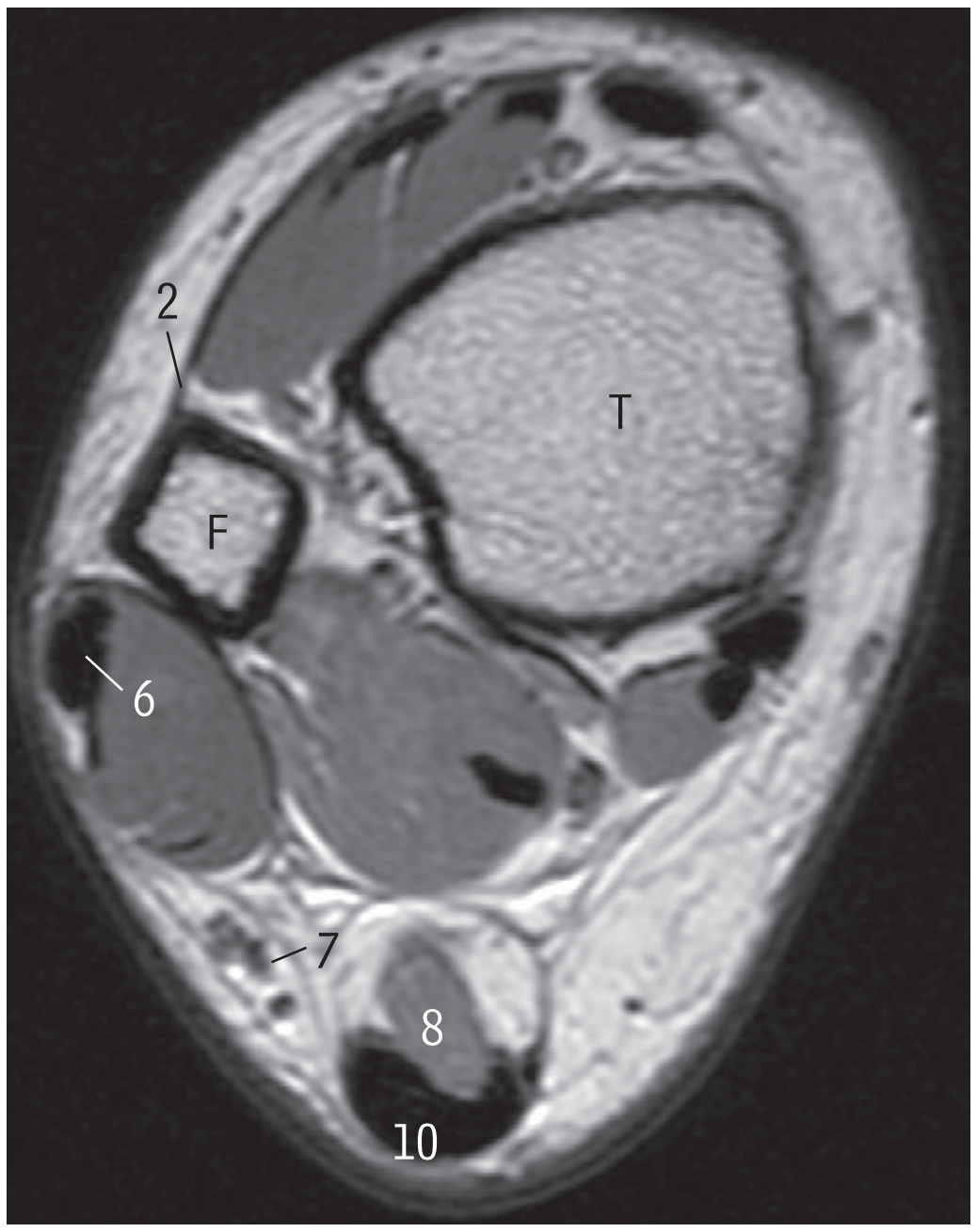

Axial T1w MR, lower leg

Below knee level, the great saphenous vein (A4) is accompanied by the saphenous nerve (A11).

In the calf, the small saphenous vein (C7) is accompanied by the sural nerve (C9).

C Left calf

superficial dissection, from behind

1. Aponeurosis of gastrocnemius
2. Deep fascia
3. Lateral cutaneous nerve of calf
4. Lateral head of gastrocnemius
5. Medial head of gastrocnemius
6. Peroneus (fibularis) longus
7. Small saphenous vein
8. Soleus
9. Sural nerve
10. Tendocalcaneus (Achilles tendon)

Vein harvest for coronary artery bypass grafting (CABG), see pages 355–357.

Left leg and ankle *superficial veins and nerves*

A *from the medial side* B *from behind*

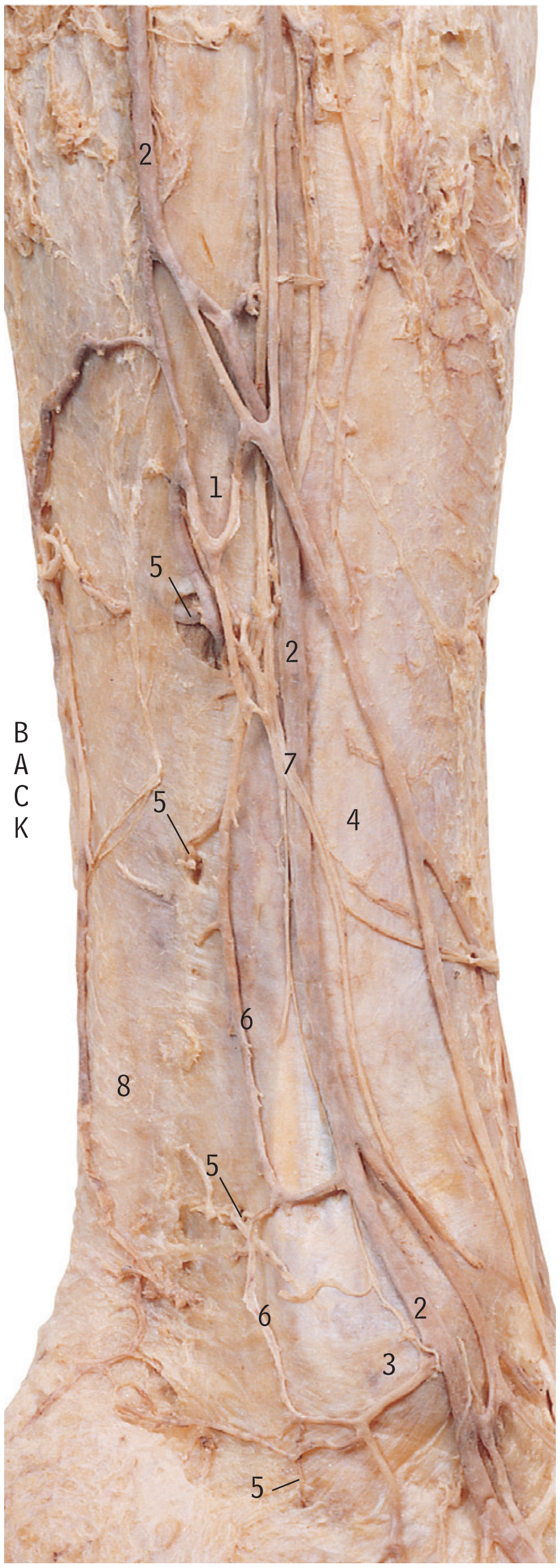

1 Deep fascia over soleus
2 Great saphenous vein
3 Medial malleolus
4 Medial (subcutaneous) surface of tibia
5 Perforating veins
6 Posterior arch vein
7 Saphenous nerve
8 Tendocalcaneus (Achilles tendon)

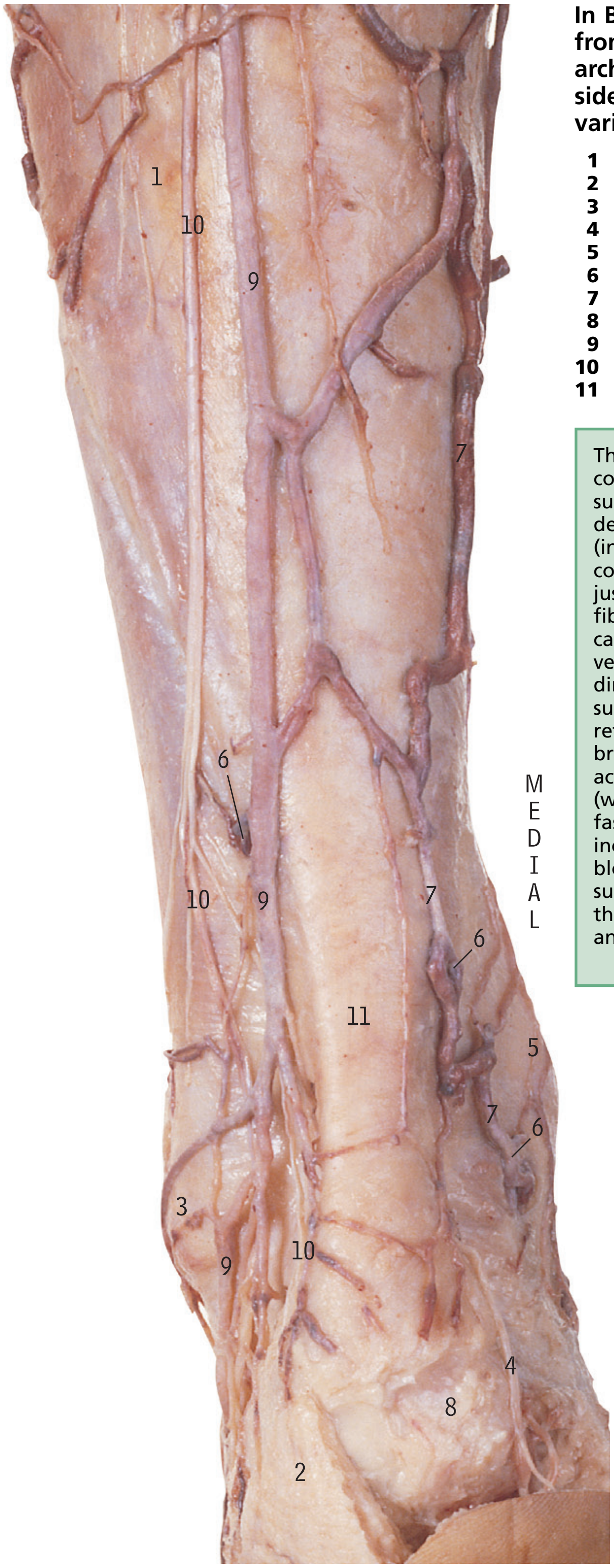

In B (a different specimen from that in A), the posterior arch vein (7) on the medial side is large and becoming varicose.

1 Deep fascia
2 Fibrofatty tissue of heel
3 Lateral malleolus
4 Medial calcanean nerve
5 Medial malleolus
6 Perforating vein
7 Posterior arch vein
8 Posterior surface of calcaneus
9 Small saphenous vein
10 Sural nerve
11 Tendocalcaneus (under fascia)

The perforating veins are communications between the superficial veins (outside the deep fascia) and the deep veins (inside the fascia). The commonest sites for them are just behind the tibia, behind the fibula and in the adductor canal. These communicating vessels possess valves which direct the blood flow from superficial to deep; venous return from the limb is then brought about by the pumping action of the deep muscles (which are all below the deep fascia). If the valves become incompetent or the deep veins blocked, pressure in the superficial veins increases and they become varicose (dilated and tortuous) (see page 357).

Ankle ulceration from varicose veins, deep vein thrombosis (DVT), see pages 355–357.

A Left popliteal fossa and proximal calf

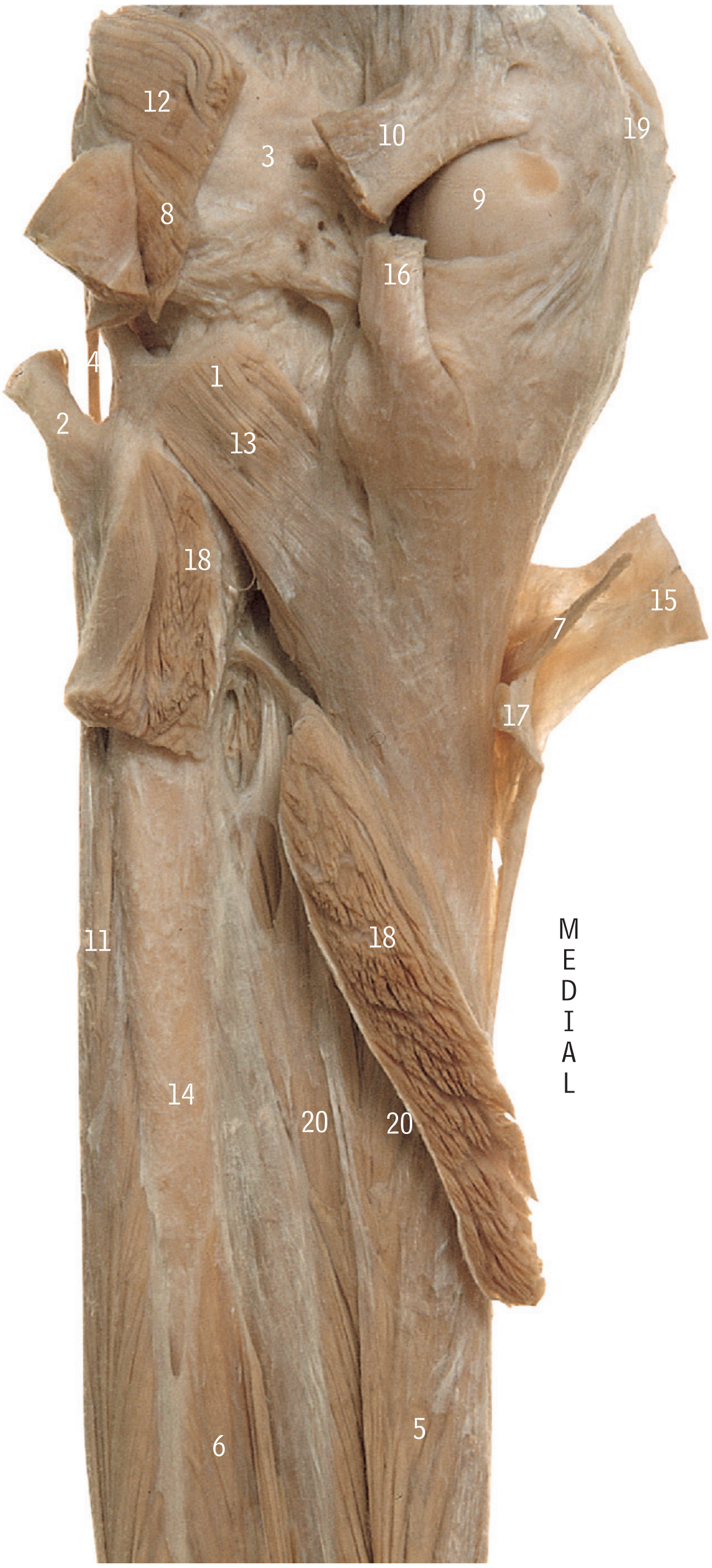

1 Attachment of popliteus to lateral meniscus
2 Biceps femoris
3 Capsule of knee joint
4 Fibular (lateral) collateral ligament
5 Flexor digitorum longus
6 Flexor hallucis longus
7 Gracilis
8 Lateral head of gastrocnemius
9 Medial condyle of femur
10 Medial head of gastrocnemius
11 Peroneus (fibularis) longus
12 Plantaris
13 Popliteus
14 Posterior surface of fibula (soleus removed)
15 Sartorius
16 Semimembranosus
17 Semitendinosus
18 Soleus
19 Tibial (medial) collateral ligament
20 Tibialis posterior

B Left distal calf and ankle

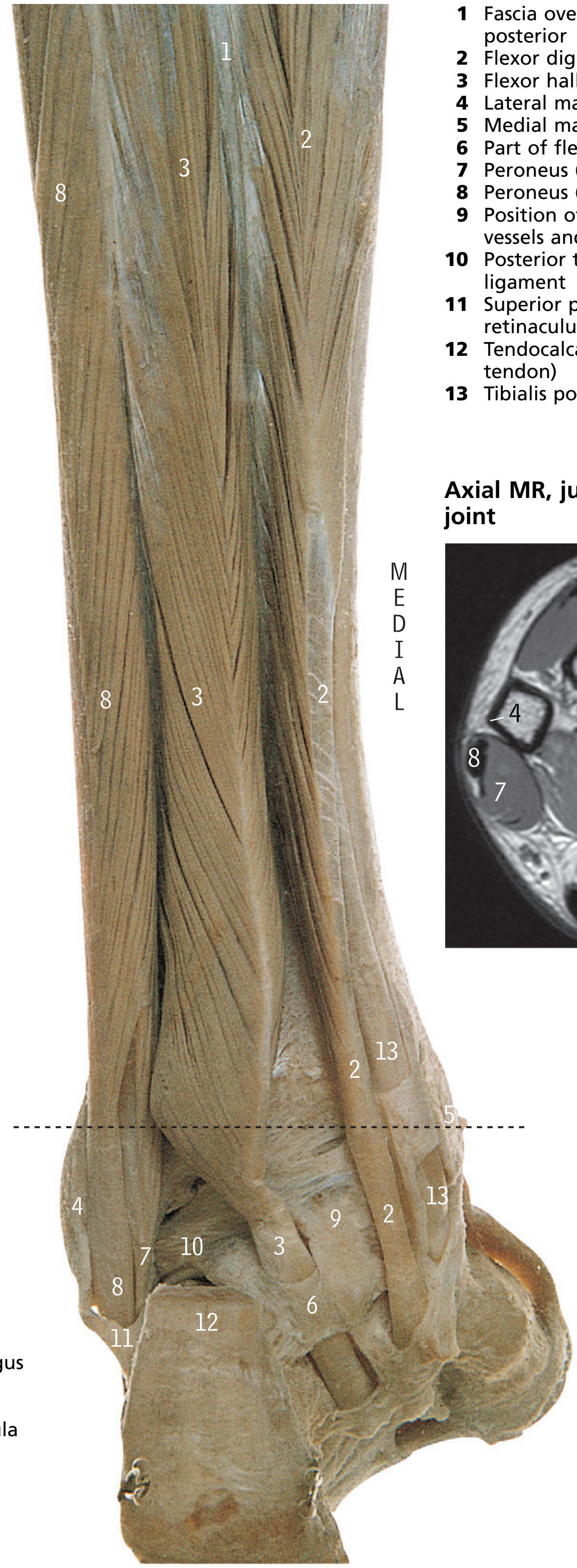

1 Fascia overlying tibialis posterior
2 Flexor digitorum longus
3 Flexor hallucis longus
4 Lateral malleolus
5 Medial malleolus
6 Part of flexor retinaculum
7 Peroneus (fibularis) brevis
8 Peroneus (fibularis) longus
9 Position of posterior tibial vessels and tibial nerve
10 Posterior talofibular ligament
11 Superior peroneal (fibular) retinaculum
12 Tendocalcaneus (Achilles tendon)
13 Tibialis posterior

Axial MR, just above ankle joint

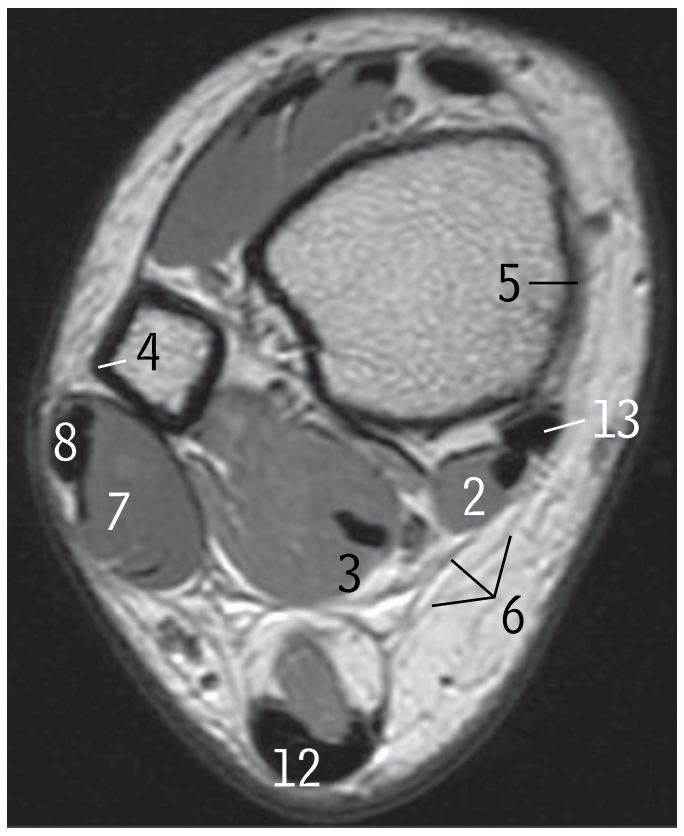

Tibialis posterior tendonitis, see pages 355–357.

A Right leg *posterior view*

1 Biceps femoris muscle
2 Common peroneal (fibular) nerve
3 Gastrocnemius muscle, lateral head
4 Gastrocnemius muscle, medial head
5 Gracilis muscle
6 Gracilis tendon
7 Great saphenous vein
8 Lateral sural cutaneous nerve
9 Medial sural cutaneous nerve
10 Popliteal vein
11 Sartorius muscle
12 Semimembranosus muscle
13 Semitendinosus muscle
14 Small saphenous vein
15 Soleus muscle
16 Tendocalcaneus (Achilles)
17 Tendocalcaneus (formation)
18 Tibial nerve
19 Venous network, formation of small saphenous vein

B Right calf *including muscles, nerves and veins*

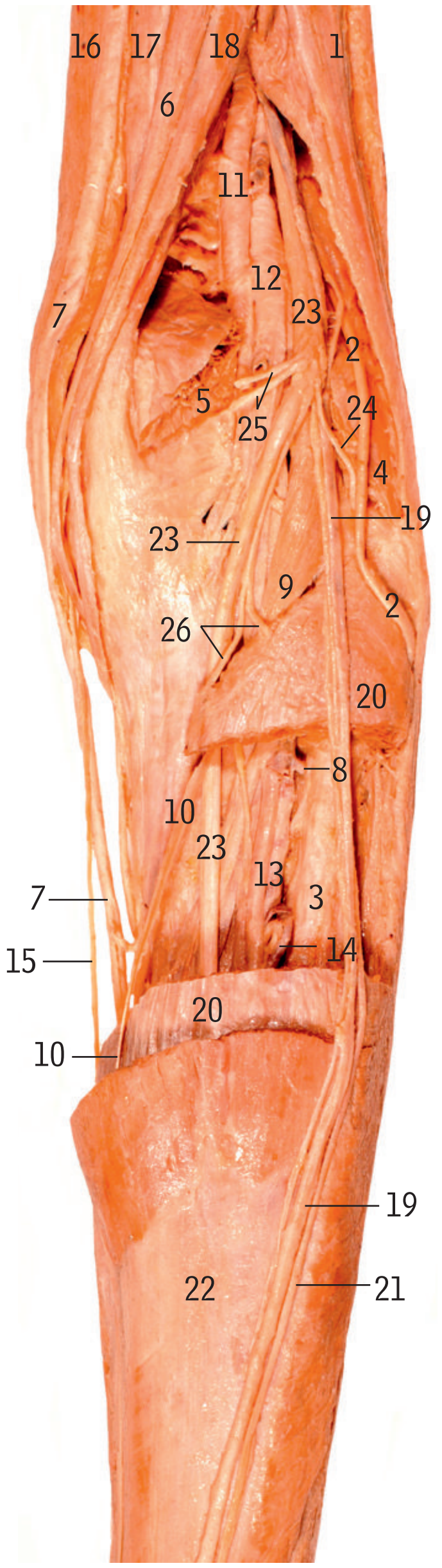

1 Biceps femoris muscle
2 Common peroneal (fibular) nerve
3 Fibula, posterior surface
4 Gastrocnemius muscle, lateral head
5 Gastrocnemius muscle, medial head
6 Gracilis muscle
7 Great saphenous vein
8 Peroneal (fibular) vein
9 Plantaris muscle
10 Plantaris tendon
11 Popliteal artery
12 Popliteal vein
13 Posterior tibial artery and vein
14 Posterior tibial artery and vein, soleal branches
15 Saphenous nerve
16 Sartorius muscle
17 Semimembranosus muscle
18 Semitendinosus muscle
19 Small saphenous veins, displaced laterally
20 Soleus muscle
21 Sural nerve, displaced laterally
22 Tendocalcaneus (formation)
23 Tibial nerve
24 Tibial nerve, muscular branches of lateral head of gastrocnemius
25 Tibial nerve, muscular branches of medial head of gastrocnemius
26 Tibial nerve, muscular branches of soleus

Compartment syndrome, see *pages 355–357.*

C Right lower leg *deep dissection*

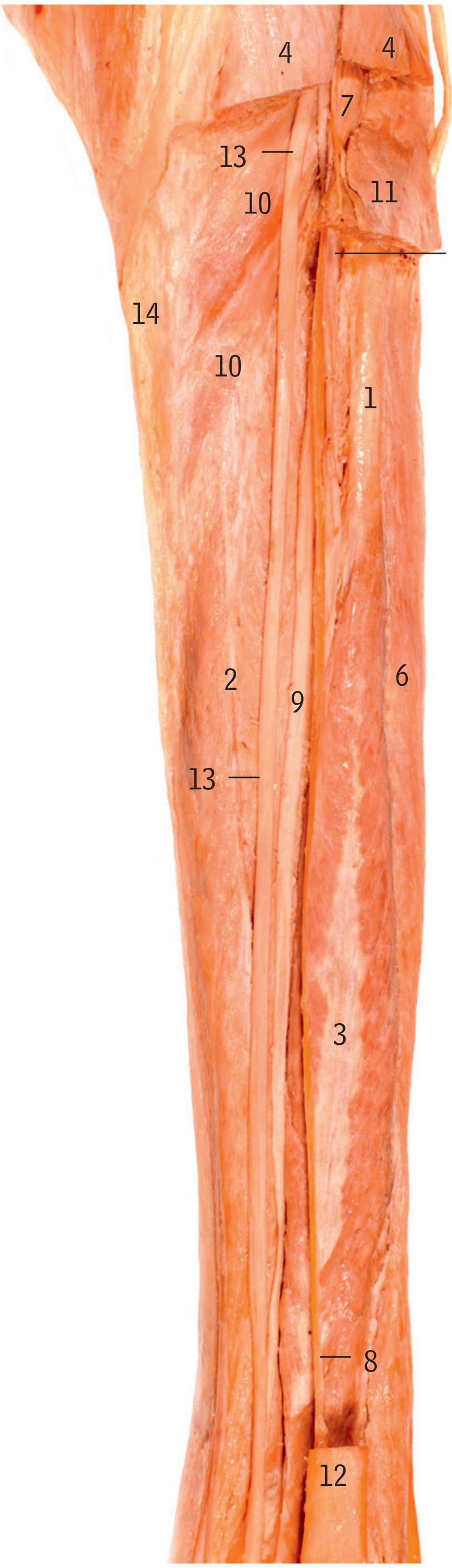

1 Fibula (posterior surface)
2 Flexor digitorum longus muscle
3 Flexor hallucis longus muscle
4 Gastrocnemius muscle
5 Peroneal (fibular) artery
6 Peroneus (fibularis) longus
7 Plantaris muscle
8 Plantaris tendon
9 Posterior tibial artery
10 Popliteus muscle
11 Soleus muscle
12 Tendocalcaneus (Achilles)
13 Tibial nerve
14 Tibia, posterior surface

D Popliteal angiogram

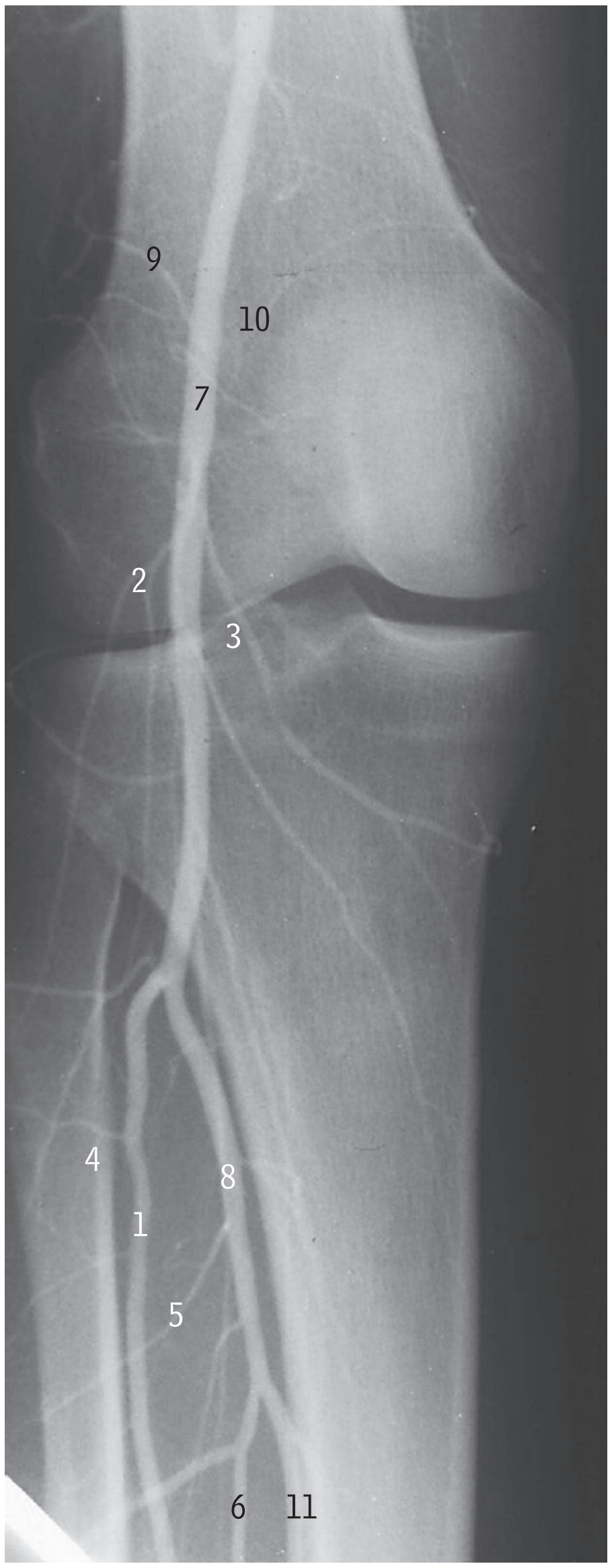

1 Anterior tibial artery
2 Inferior lateral genicular artery
3 Inferior medial genicular artery
4 Muscular branches of anterior tibial artery
5 Muscular branches of tibioperoneal trunk
6 Peroneal (fibular) artery
7 Popliteal artery
8 Tibioperoneal trunk
9 Superior lateral genicular artery
10 Superior medial genicular artery
11 Posterior tibial artery

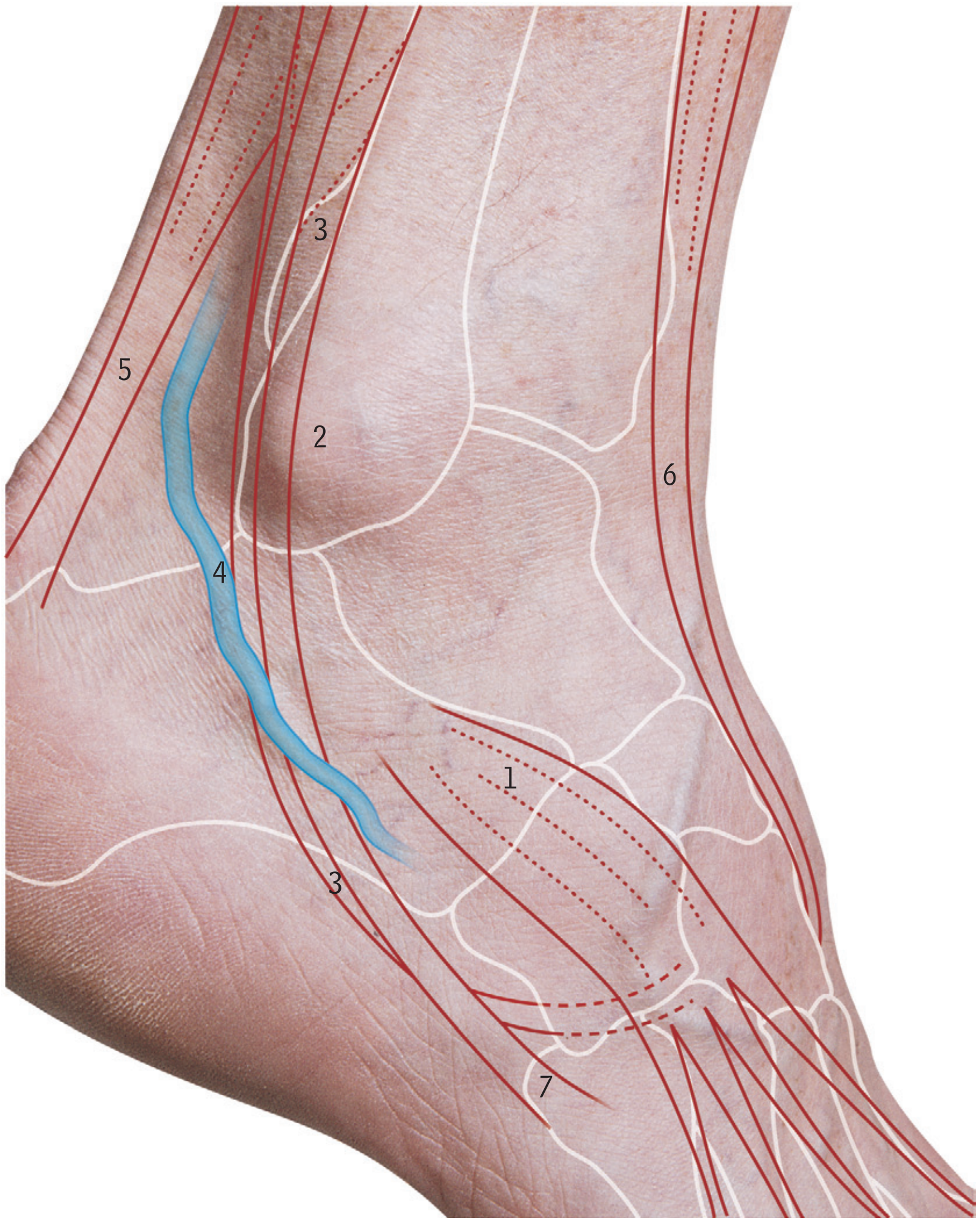

A Right ankle and foot

from the lateral side

1 Extensor digitorum brevis
2 Lateral malleolus
3 Peroneus (fibularis) longus and brevis
4 Small saphenous vein
5 Tendocalcaneus (Achilles tendon)
6 Tibialis anterior
7 Tuberosity of base of fifth metatarsal

The great saphenous vein (B7) runs upwards in front of the medial malleolus (B9).

The small saphenous vein (A4) runs upwards behind the lateral malleolus (A2).

B Right ankle and foot

from the front and medial side

The most prominent surface features are the medial malleolus (9), the tendocalcaneus (11) at the back and the tendons of tibialis anterior (12) and extensor hallucis longus (6) at the front. The dorsalis pedis artery (3) can be palpated where labelled, as may the long tendons.

1 Calcaneus
2 Dorsal venous arch
3 Dorsalis pedis artery
4 Extensor digitorum brevis
5 Extensor digitorum longus
6 Extensor hallucis longus
7 Great saphenous vein
8 Head of first metatarsal
9 Medial malleolus
10 Posterior tibial artery
11 Tendocalcaneus (Achilles tendon)
12 Tibialis anterior
13 Tibialis posterior
14 Tuberosity of navicular

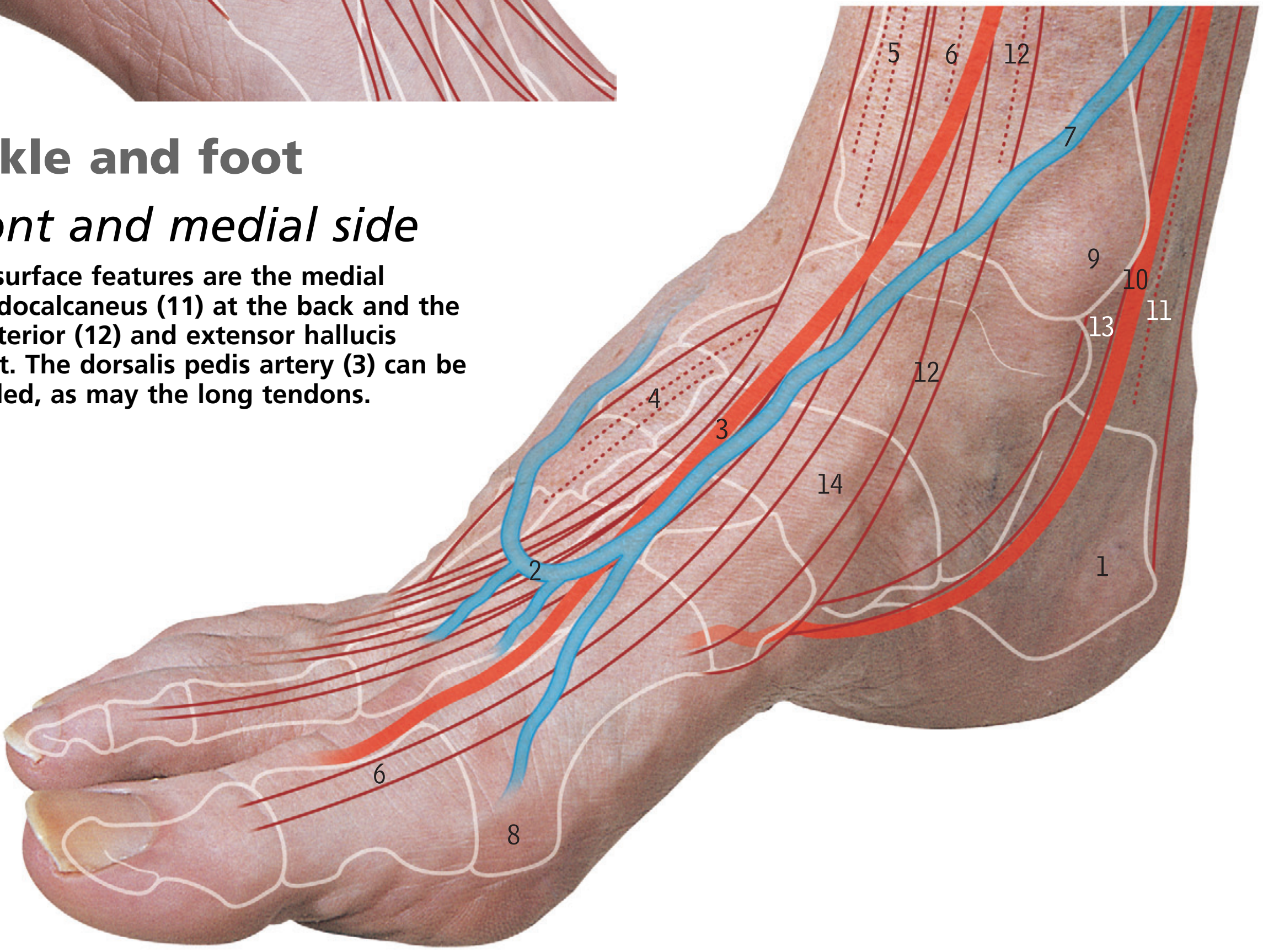

Achilles tendon tendocalcaneus reflex (ankle jerk), rupture – Achilles tendon, talipes equinovarus (club foot), venous cutdown, *see pages 355–357.*

C Right ankle and foot *from the lateral side*

Fascia has been removed but the thickenings that form the superior and inferior extensor retinacula (16 and 6) and the superior and inferior peroneal (fibular) retinacula (17 and 7) have been preserved. The synovial sheaths of tendons have been emphasised by blue tissue.

1 Abductor digiti minimi
2 Dorsal digital expansion
3 Extensor digitorum brevis
4 Extensor digitorum longus
5 Extensor hallucis longus
6 Inferior extensor retinaculum
7 Inferior peroneal (fibular) retinaculum
8 Lateral malleolus
9 Lateral surface of calcaneus
10 Medial and lateral branches of superficial peroneal (fibular) nerve
11 Peroneus (fibularis) brevis
12 Peroneus (fibularis) longus
13 Peroneus (fibularis) tertius
14 Soleus
15 Subcutaneous area of fibula
16 Superior extensor retinaculum
17 Superior peroneal (fibular) retinaculum
18 Sural nerve
19 Tendocalcaneus (Achilles tendon)
20 Tibialis anterior

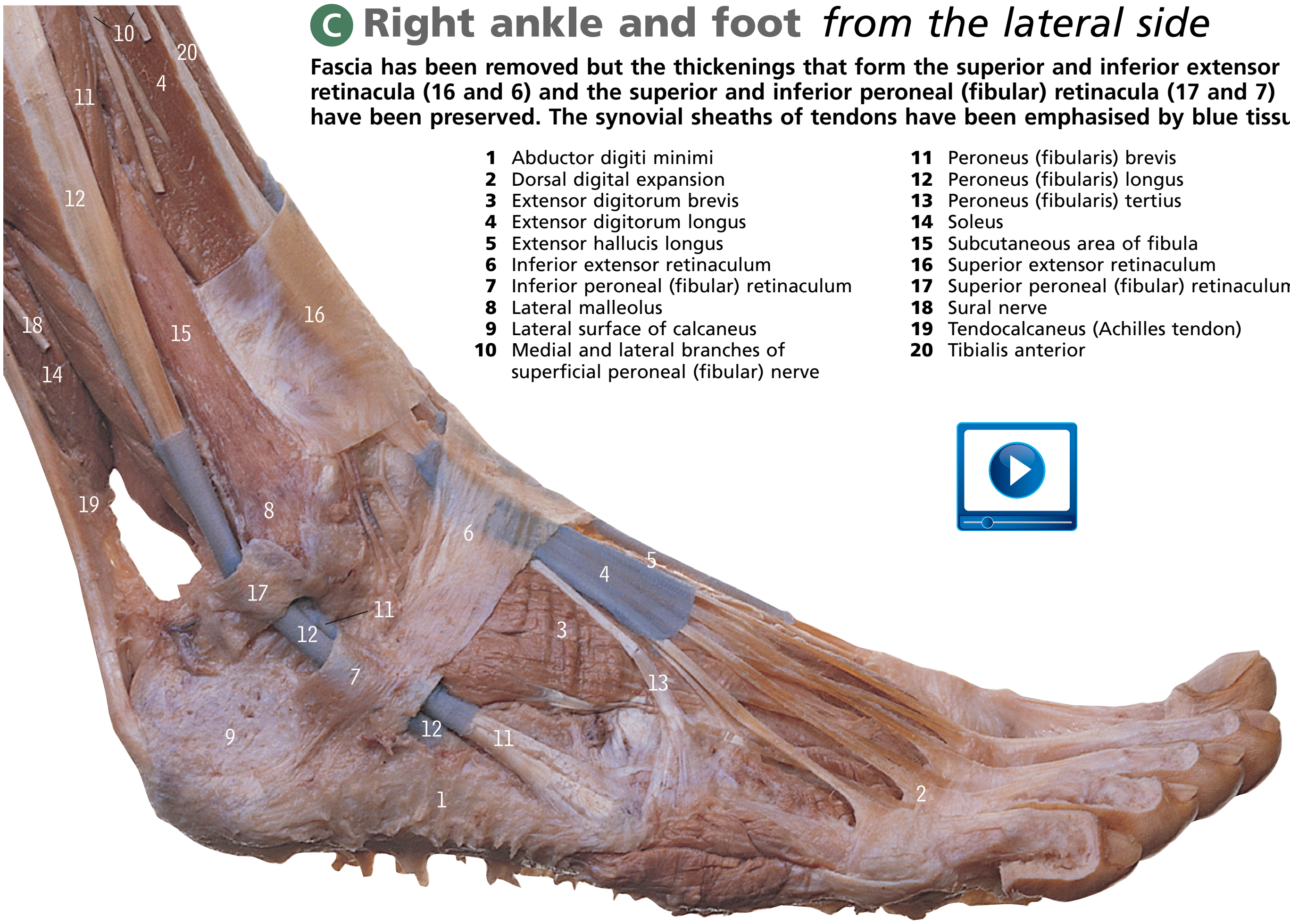

D Right ankle and foot *from the medial side*

1 Abductor hallucis
2 Extensor hallucis longus
3 Flexor digitorum longus
4 Flexor hallucis longus
5 Flexor retinaculum
6 Inferior extensor retinaculum (lower band)
7 Inferior extensor retinaculum (upper band)
8 Medial calcanean nerve
9 Medial malleolus
10 Medial surface of tibia
11 Plantaris tendon
12 Posterior surface of calcaneus
13 Posterior tibial artery and venae comitantes
14 Soleus
15 Tendocalcaneus (Achilles tendon)
16 Tibial nerve
17 Tibialis anterior
18 Tibialis posterior

Ankle arthroscopy, digital abnormalities, see pages 355–357.

A Right lower leg and ankle

from the medial side and behind

The deep fascia remains intact apart from a small window cut to show the position of the posterior tibial vessels and tibial nerve (6). The great saphenous vein (3) runs upwards in front of the medial malleolus (4) with the posterior arch vein (5) behind it. The arrows indicate common levels for perforating veins (page 340, A5 and B6).

1 Communication with small saphenous vein
2 Dorsal venous arch
3 Great saphenous vein and saphenous nerve
4 Medial malleolus
5 Posterior arch vein
6 Posterior tibial vessels and tibial nerve
7 Small saphenous vein
8 Tendocalcaneus (Achilles tendon)
9 Tibialis posterior and flexor digitorum longus underlying deep fascia

B Right ankle

from the medial side

1 Deep fascia of calf
2 Flexor digitorum longus
3 Flexor digitorum longus, tendon
4 Flexor hallucis longus
5 Flexor retinaculum
6 Heel
7 Medial calcanean nerve
8 Medial malleolus, tibia
9 Plantaris tendon
10 Posterior tibial artery
11 Tendocalcaneus (Achilles tendon)
12 Tibial nerve
13 Tibialis posterior tendon
14 Venae comitantes of posterior tibial artery

The deep veins of the calf, deep to and within soleus, are sites for potentially dangerous venous thrombosis (see page 355).

Ulceration of the foot, varicose veins, see pages 355–357.

C Left ankle and foot

from the front and lateral side

The foot is plantar flexed and part of the capsule of the ankle joint has been removed to show the talus (1). The tendons of peroneus (fibularis) tertius (12) and extensor digitorum longus (5) lie superficial to extensor digitorum brevis (4). The sural nerve and small saphenous vein (13) pass behind the lateral malleolus (8).

1 Anterior lateral malleolar artery overlying talus (ankle joint capsule removed)
2 Anterior tibial vessels and deep peroneal (fibular) nerve
3 Deep fascia forming superior extensor retinaculum
4 Extensor digitorum brevis
5 Extensor digitorum longus
6 Extensor hallucis longus
7 Inferior extensor retinaculum (partly removed)
8 Lateral malleolus
9 Perforating branch of peroneal (fibular) artery
10 Peroneus (fibularis) brevis
11 Peroneus (fibularis) longus
12 Peroneus (fibularis) tertius
13 Small saphenous vein and sural nerve
14 Superficial peroneal (fibular) nerve
15 Tarsal sinus
16 Tendocalcaneus (Achilles tendon)
17 Tibialis anterior

Left ankle

D *cross-section*

E *axial MR image*

This section, looking down from above, emphasises the positions of tendons, vessels and nerves in the ankle region. The talus (18) is in the centre, with the medial malleolus (9) on the left of the picture and the lateral malleolus (8) on the right. The great saphenous vein (7) and saphenous nerve (15) are in front of the medial malleolus, with the tendon of tibialis posterior (22) immediately behind it. The small saphenous vein (16) and the sural nerve (17) are behind the lateral malleolus, with the tendons of peroneus (fibularis) longus (11) and peroneus (fibularis) brevis (10) intervening. At the front of the ankle, the dorsalis pedis vessels (2) and deep peroneal (fibular) nerve (1) are between the tendons of extensor hallucis longus (4) and extensor digitorum longus (3). Behind the medial malleolus (9) and tibialis posterior (22), the posterior tibial vessels (14) and tibial nerve (20) are between the tendons of flexor digitorum longus (5) and flexor hallucis longus (6).

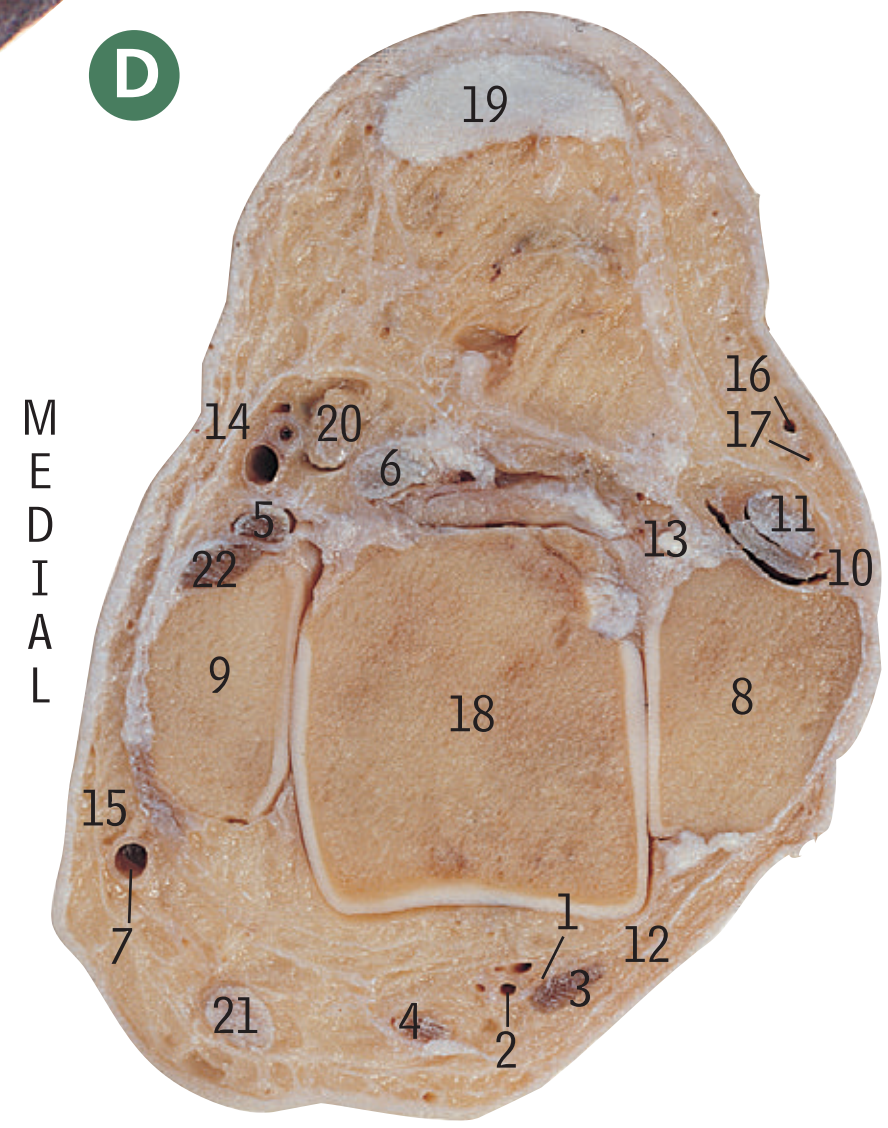

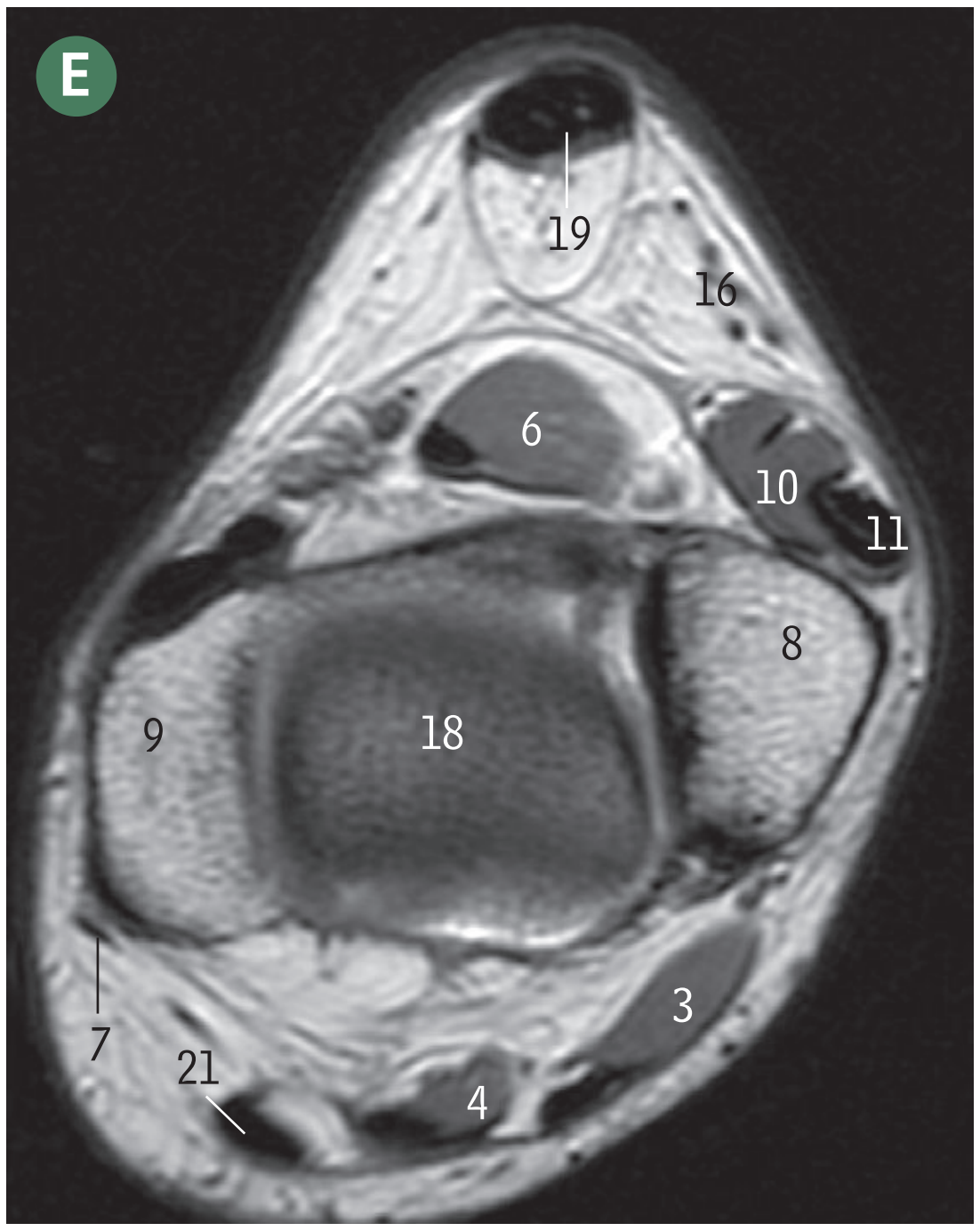

1 Deep peroneal (fibular) nerve
2 Dorsalis pedis artery and venae comitantes
3 Extensor digitorum longus
4 Extensor hallucis longus
5 Flexor digitorum longus
6 Flexor hallucis longus
7 Great saphenous vein
8 Lateral malleolus of fibula
9 Medial malleolus of tibia
10 Peroneus (fibularis) brevis
11 Peroneus (fibularis) longus
12 Peroneus (fibularis) tertius
13 Posterior talofibular ligament
14 Posterior tibial artery and venae comitantes
15 Saphenous nerve
16 Small saphenous vein
17 Sural nerve
18 Talus
19 Tendocalcaneus (Achilles tendon)
20 Tibial nerve
21 Tibialis anterior
22 Tibialis posterior

Charcot foot, see pages 355–357.

A Dorsum of the right foot

1 Arcuate artery
2 Digital arteries
3 Dorsalis pedis artery
4 Extensor digitorum brevis
5 Extensor digitorum longus
6 Extensor hallucis brevis
7 Extensor hallucis longus
8 First dorsal interosseous
9 First dorsal metatarsal artery
10 First metatarsophalangeal joint
11 Fourth dorsal interosseous
12 Peroneus (fibularis) tertius
13 Second dorsal interosseous
14 Second dorsal metatarsal artery
15 Tarsal arteries
16 Third dorsal interosseous
17 Tibialis anterior
18 Tuberosity of base of fifth metatarsal and peroneus (fibularis) brevis

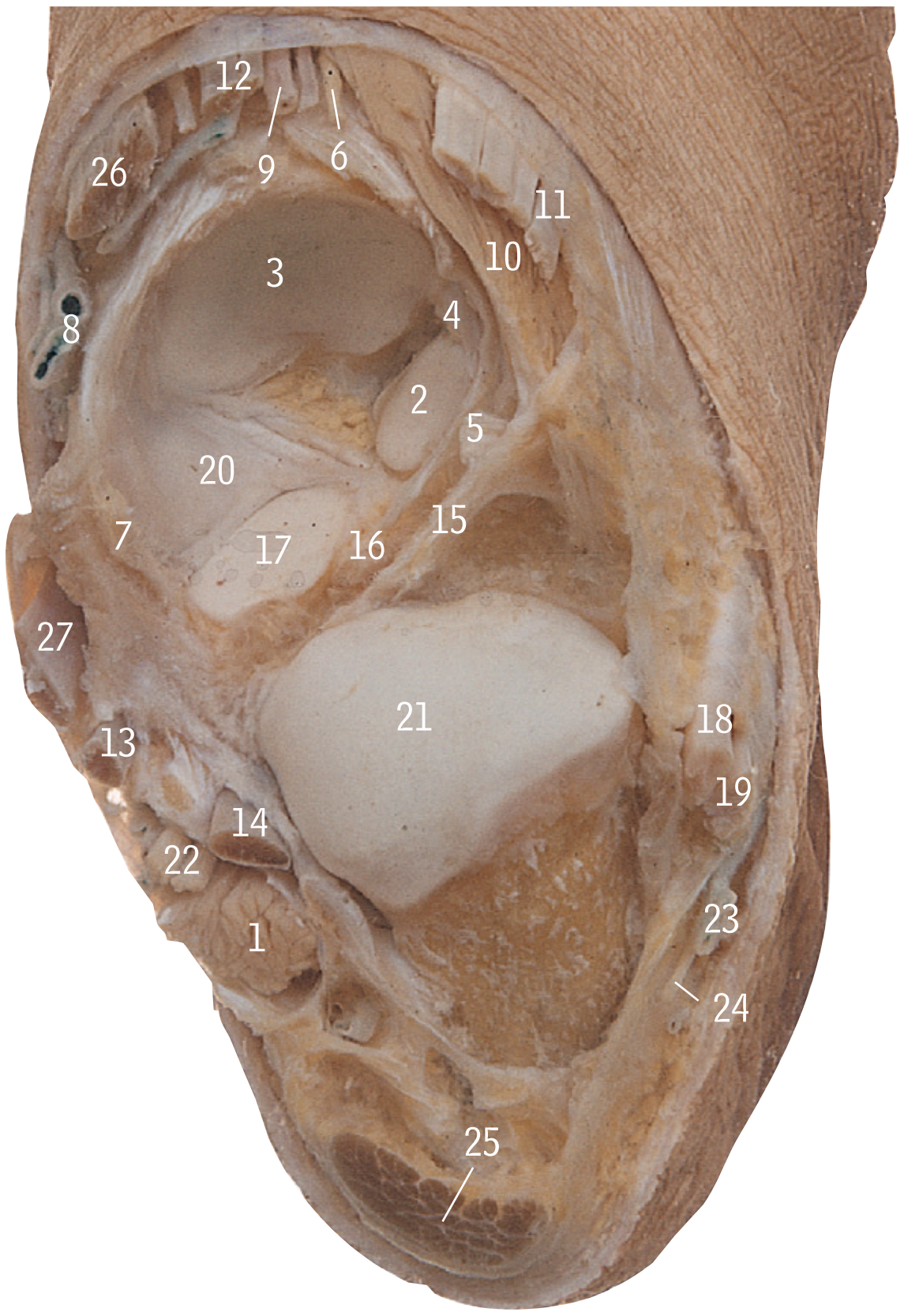

B Right talocalcanean and talocalcaneonavicular joints

The talus has been removed to show the articular surfaces of the calcaneus (21, 17 and 2), navicular (3) and plantar calcaneonavicular (spring) ligament (20).

1 Abductor hallucis
2 Anterior articular surface on calcaneus for talus
3 Articular surface on navicular for talus
4 Calcaneonavicular part of bifurcate ligament
5 Cervical ligament
6 Deep peroneal (fibular) nerve
7 Deltoid ligament
8 Dorsal venous arch
9 Dorsalis pedis artery and vena comitans
10 Extensor digitorum brevis
11 Extensor digitorum longus
12 Extensor hallucis longus
13 Flexor digitorum longus
14 Flexor hallucis longus
15 Inferior extensor retinaculum
16 Interosseous talocalcanean ligament
17 Middle articular surface on calcaneus for talus
18 Peroneus (fibularis) brevis
19 Peroneus (fibularis) longus
20 Plantar calcaneonavicular (spring) ligament
21 Posterior articular surface on calcaneus for talus
22 Posterior tibial vessels and medial and lateral plantar nerves
23 Small saphenous vein
24 Sural nerve
25 Tendocalcaneus (Achilles tendon)
26 Tibialis anterior
27 Tibialis posterior

Clinicians sometimes use the term subtalar joint as a combined name for both the talocalcanean joint and the talocalcanean part of the talocalcaneonavicular joint, because it is at both these joints beneath the talus that most of the movements of inversion and eversion of the foot occur, on the axis of the cervical ligament.

Ankle block, malignant melanoma, tarsal tunnel syndrome, see pages 355–357.

Left ankle and foot *ligaments*

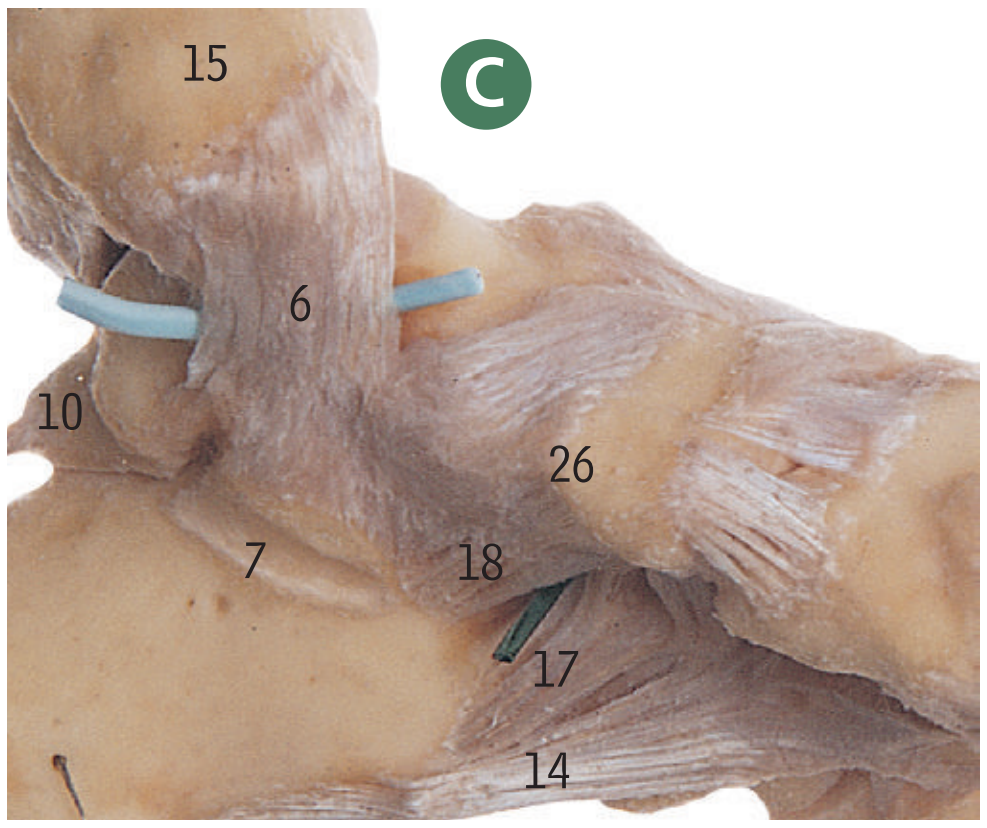

BACK

C from the medial side

D from the lateral side

E from behind

In C, the marker below the medial malleolus (15) passes between the superficial and deep parts of the deltoid ligament (6). The marker below the tuberosity of the navicular (26) passes between the plantar calcaneonavicular (spring) and calcaneocuboid (short plantar) ligaments (18 and 17).

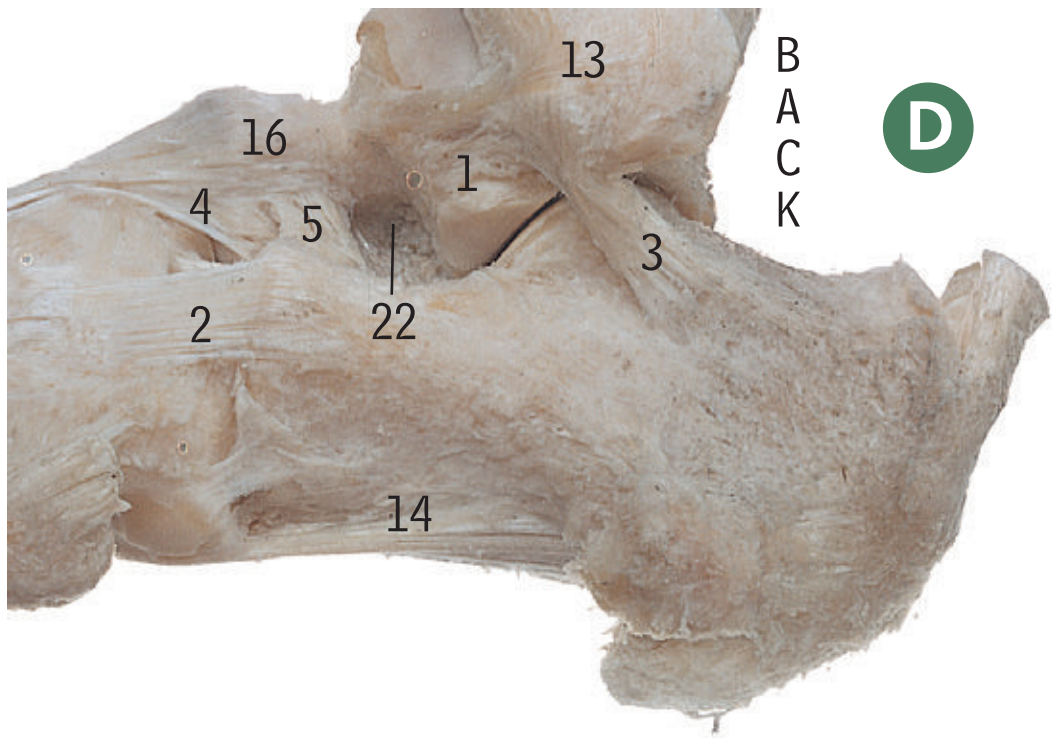

BACK

D

LATERAL

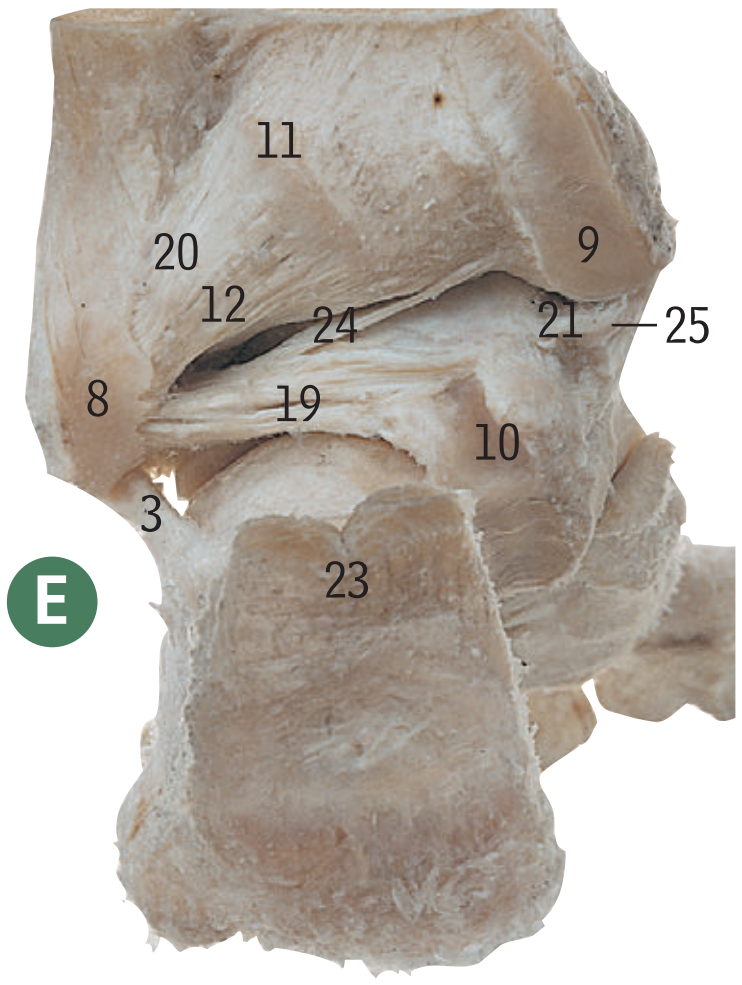

1 Anterior talofibular ligament
2 Calcaneocuboid part of bifurcate ligament
3 Calcaneofibular ligament
4 Calcaneonavicular part of bifurcate ligament
5 Cervical ligament
6 Deltoid ligament
7 Groove below sustentaculum tali for flexor hallucis longus
8 Groove on lateral malleolus for peroneus (fibularis) brevis
9 Groove on medial malleolus for tibialis posterior
10 Groove on talus for flexor hallucis longus
11 Groove on tibia for flexor hallucis longus
12 Inferior transverse ligament
13 Lateral malleolus
14 Long plantar ligament
15 Medial malleolus
16 Neck of talus
17 Plantar calcaneocuboid (short plantar) ligament
18 Plantar calcaneonavicular (spring) ligament
19 Posterior talofibular ligament
20 Posterior tibiofibular ligament
21 Posterior tibiotalar part of deltoid ligament
22 Tarsal sinus
23 Tendocalcaneus (Achilles tendon)
24 Tibial slip of posterior talofibular ligament
25 Tibiocalcanean part of deltoid ligament
26 Tuberosity of navicular

F Left foot *sagittal section, from the right*

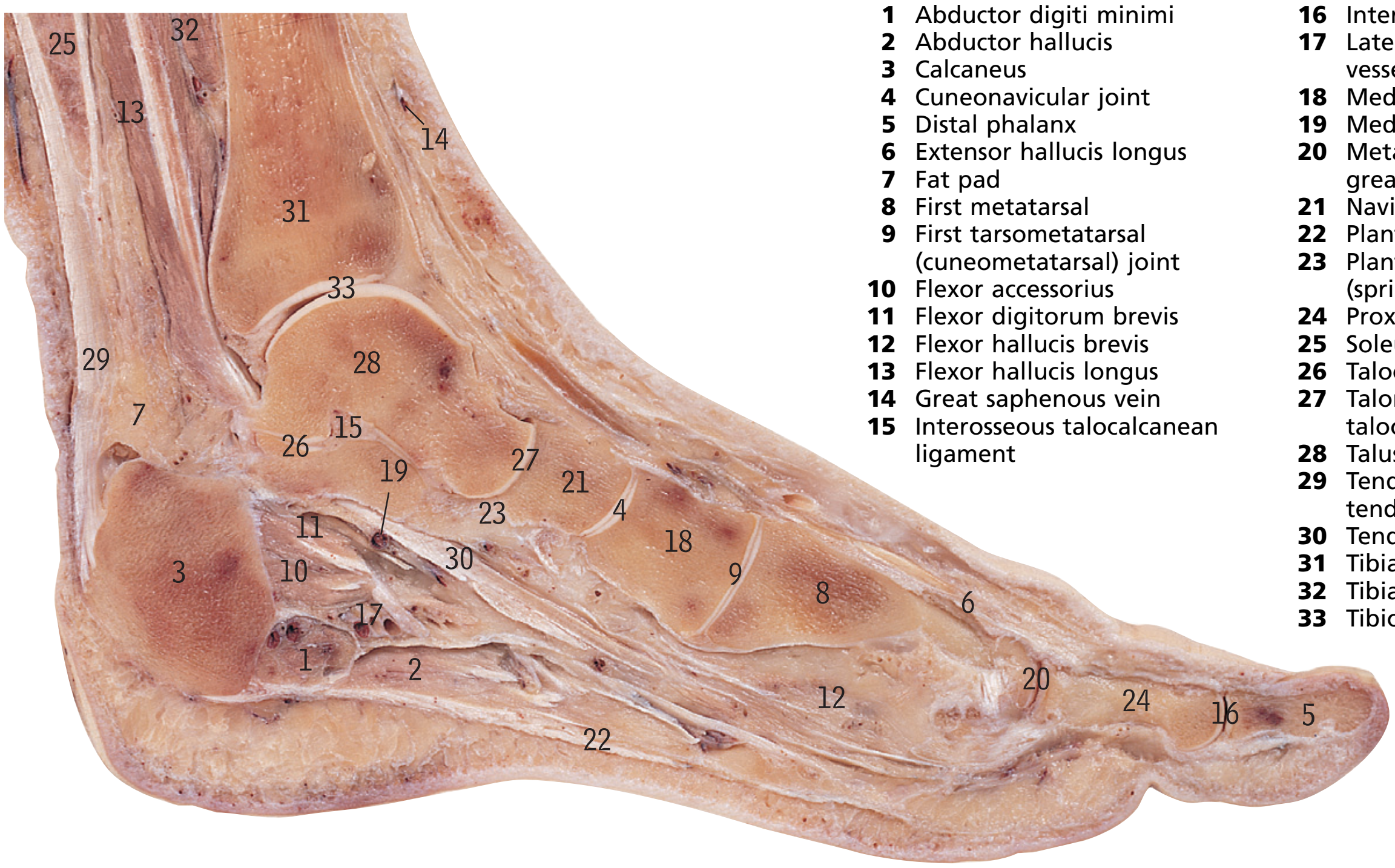

1 Abductor digiti minimi
2 Abductor hallucis
3 Calcaneus
4 Cuneonavicular joint
5 Distal phalanx
6 Extensor hallucis longus
7 Fat pad
8 First metatarsal
9 First tarsometatarsal (cuneometatarsal) joint
10 Flexor accessorius
11 Flexor digitorum brevis
12 Flexor hallucis brevis
13 Flexor hallucis longus
14 Great saphenous vein
15 Interosseous talocalcanean ligament
16 Interphalangeal joint
17 Lateral plantar nerve and vessels
18 Medial cuneiform
19 Medial plantar artery
20 Metatarsophalangeal joint of great toe
21 Navicular
22 Plantar aponeurosis
23 Plantar calcaneonavicular (spring) ligament
24 Proximal phalanx
25 Soleus muscle
26 Talocalcanean (subtalar) joint
27 Talonavicular part of talocalcaneonavicular joint
28 Talus
29 Tendocalcaneus (Achilles tendon)
30 Tendon of flexor hallucis
31 Tibia
32 Tibialis posterior muscle
33 Tibiotalar part of ankle joint

Sprained ankle, see pages 355–357.

Sole of the left foot

A plantar aponeurosis

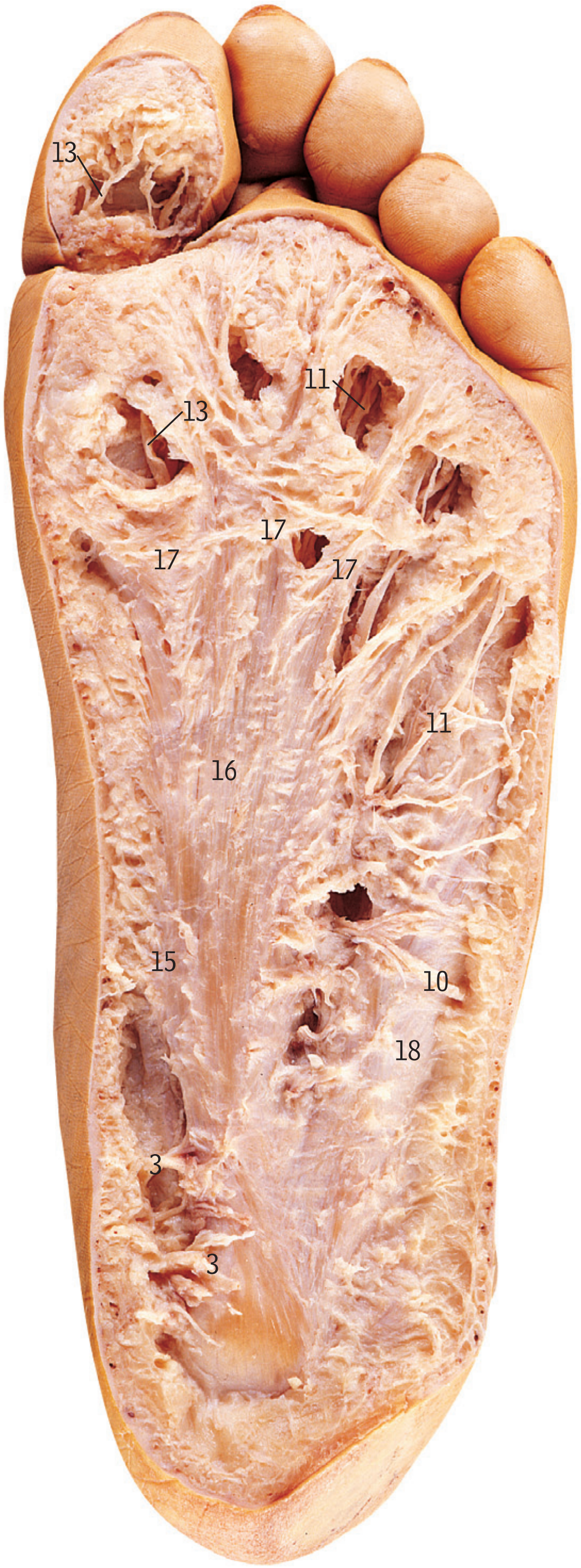

Removal of the plantar skin reveals the plantar aponeurosis with thick central and digital slips and thin lateral and medial parts.

B superficial neuromuscular layer

Deep to the plantar aponeurosis lie the superficial plantar nerves, arteries and muscles.

1 Abductor digiti minimi
2 Abductor hallucis
3 Calcaneal neurovascular bundle
4 Fibrous flexor sheath
5 Flexor digiti minimi brevis
6 Flexor digitorum brevis
7 Flexor hallucis brevis
8 Flexor hallucis longus
9 Lateral plantar artery
10 Lateral plantar nerve
11 Lateral plantar nerve, digital branches
12 Lumbrical
13 Medial plantar nerve, digital branches
14 Plantar aponeurosis
15 Plantar aponeurosis, overlying abductor hallucis
16 Plantar aponeurosis, overlying flexor digitorum brevis
17 Plantar aponeurosis, digital slips
18 Plantar aponeurosis, overlying abductor digiti minimi
19 Superficial transverse metatarsal ligament

Flat foot (pes planus), plantar fasciitis, see pages 355–357.

Sole of the left foot

C *after removal of flexor digitorum brevis*

D *after removal of flexor digitorum longus*

C

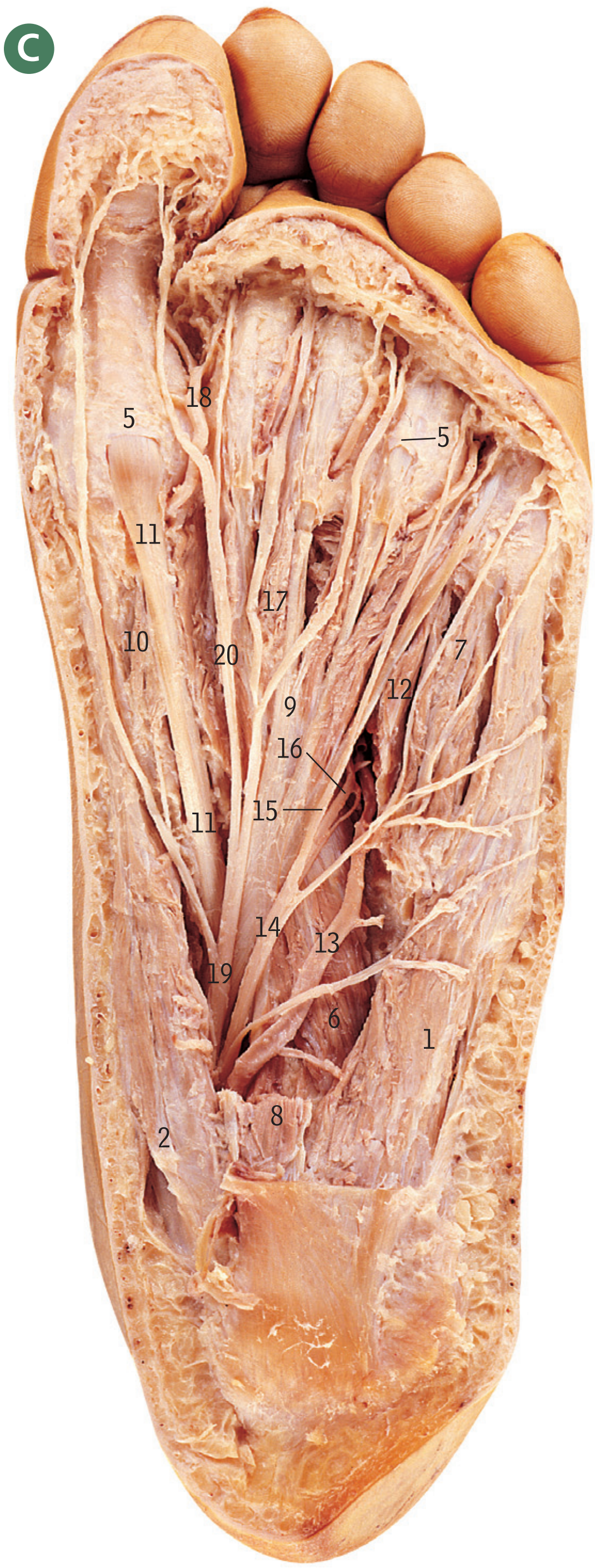

D

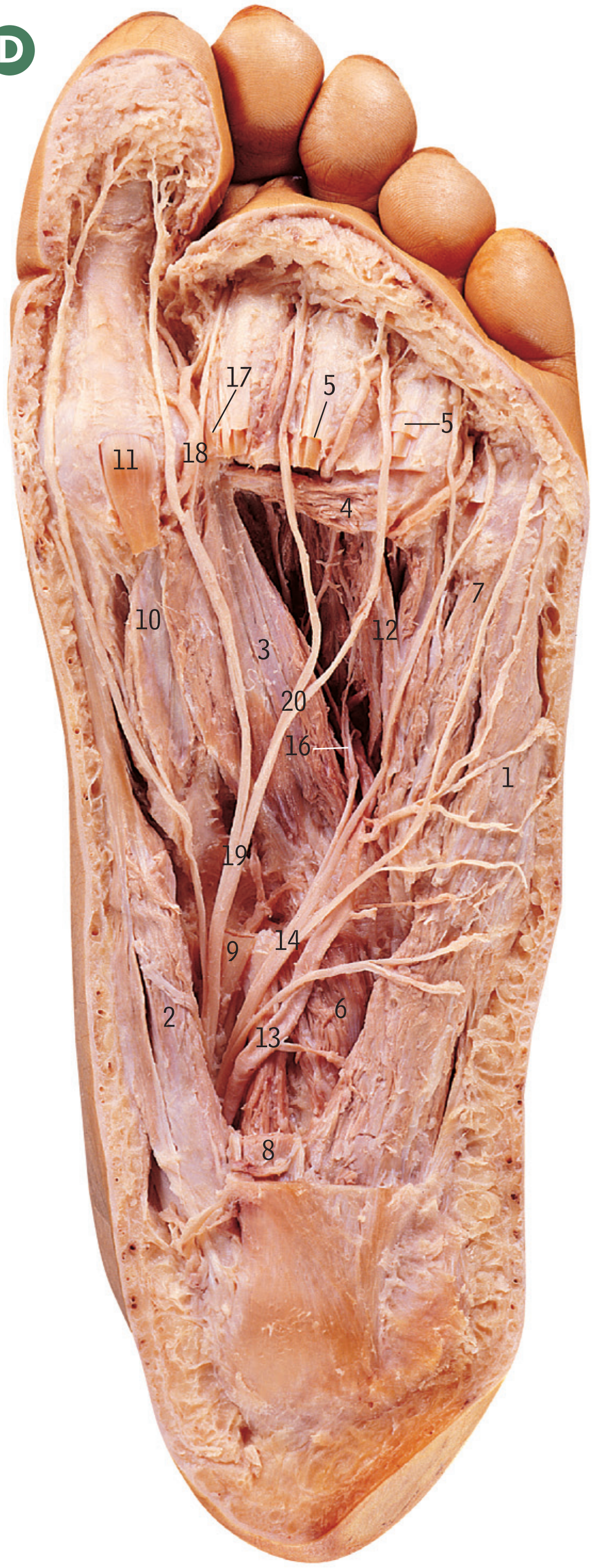

1 Abductor digiti minimi
2 Abductor hallucis
3 Adductor hallucis, oblique head
4 Adductor hallucis, transverse head
5 Fibrous sheath, flexors
6 Flexor accessorius (quadratus plantae)
7 Flexor digiti minimi brevis
8 Flexor digitorum brevis (cut)
9 Flexor digitorum longus
10 Flexor hallucis brevis
11 Flexor hallucis longus
12 Interossei
13 Lateral plantar artery
14 Lateral plantar nerve
15 Lateral plantar nerve, common digital branch
16 Lateral plantar nerve, deep branch
17 Lumbrical
18 Medial plantar artery
19 Medial plantar nerve
20 Medial plantar nerve, common digital branch

Extensor plantar response–Babinski sign, see pages 355–357.

(A) Sole of the left foot

deep muscles, interossei

1 Abductor digiti minimi
2 Abductor hallucis
3 Branches of deep branch of lateral plantar nerve
4 First dorsal interosseous
5 First lumbrical
6 First plantar interosseous
7 Flexor digiti minimi brevis
8 Flexor digitorum brevis
9 Flexor digitorum longus
10 Flexor hallucis brevis
11 Flexor hallucis longus
12 Fourth dorsal interosseous
13 Fourth lumbrical
14 Oblique head of adductor hallucis
15 Plantar digital nerve of great toe
16 Second dorsal interosseous
17 Second lumbrical
18 Second plantar interosseous
19 Third dorsal interosseous
20 Third lumbrical
21 Third plantar interosseous
22 Transverse head of adductor hallucis

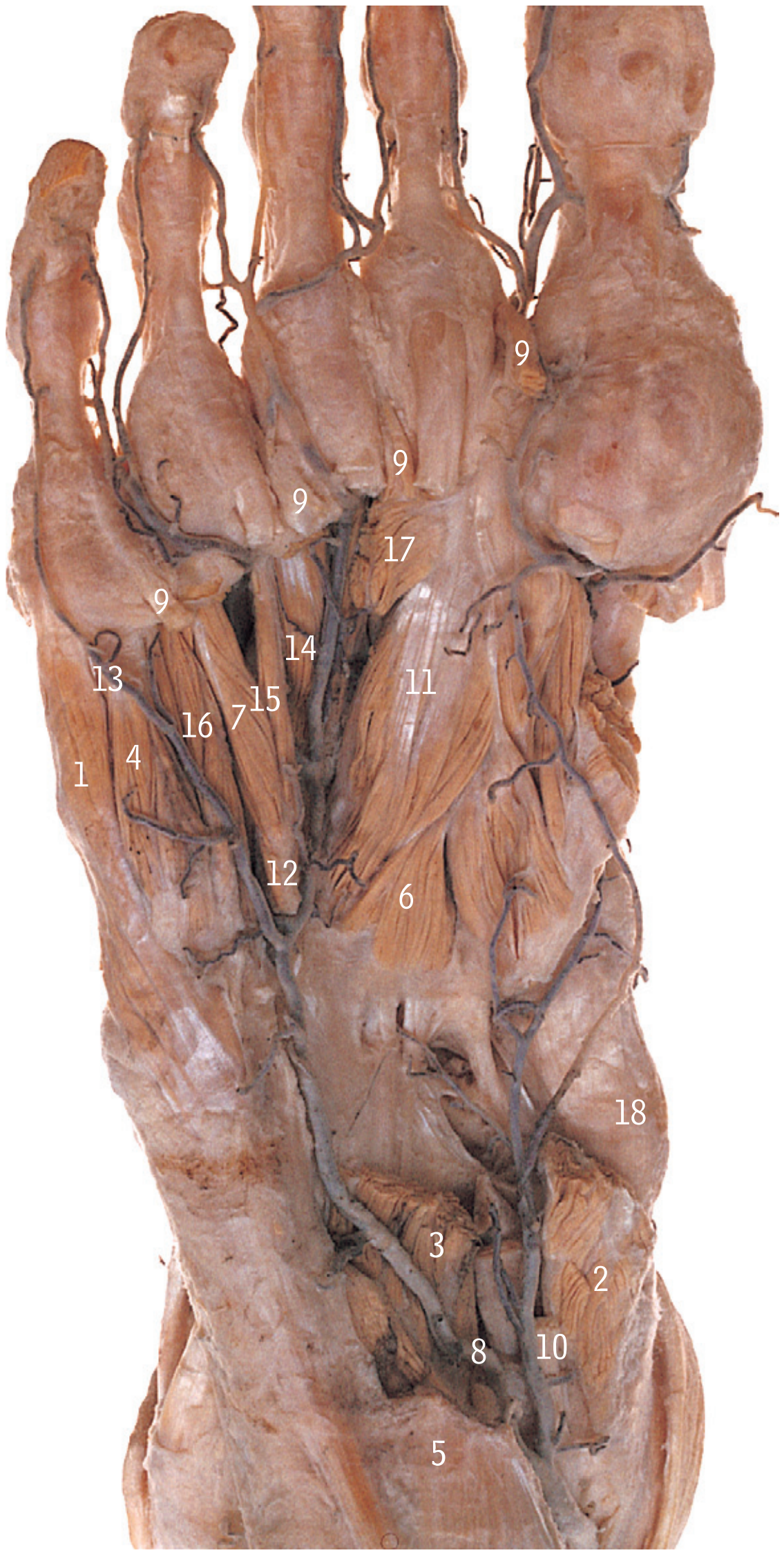

(B) Sole of the right foot

plantar arch

Most of the flexor muscles and tendons have been removed to show the lateral plantar artery (8) crossing flexor accessorius (quadratus plantae) (3) to become the plantar arch (12) which would lie deep to the flexor tendons.

1 Abductor digiti minimi
2 Abductor hallucis
3 Flexor accessorius (quadratus plantae)
4 Flexor digiti minimi brevis
5 Flexor digitorum brevis
6 Flexor hallucis brevis
7 Fourth dorsal interosseous
8 Lateral plantar artery
9 Lumbrical
10 Medial plantar artery and nerve
11 Oblique head of adductor hallucis
12 Plantar arch
13 Plantar digital artery
14 Plantar metatarsal artery
15 Second plantar interosseous
16 Third plantar interosseous
17 Transverse head of adductor hallucis
18 Tuberosity of navicular

Sole of the left foot C *ligaments and tendons* D *ligaments*

C

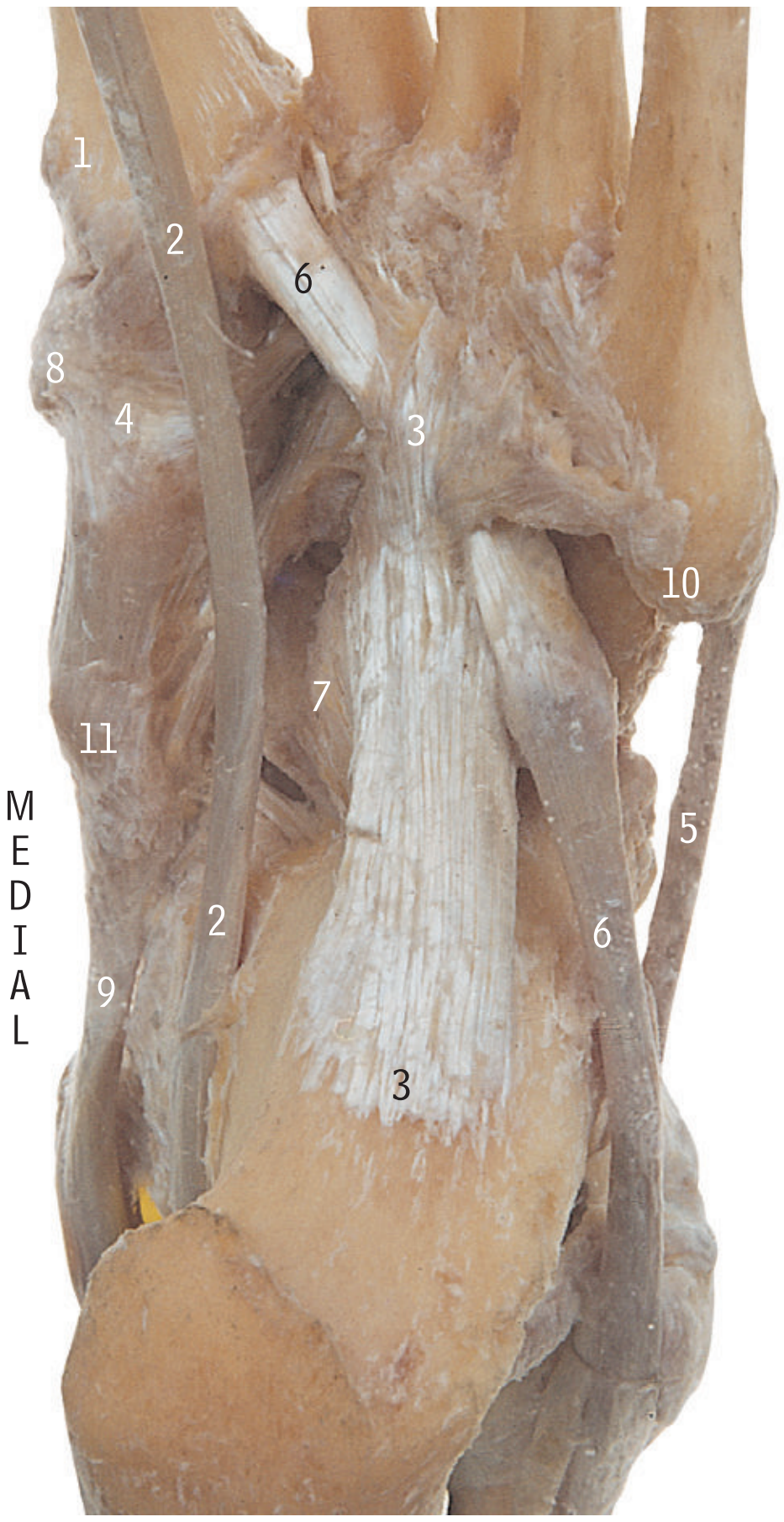

The anterior end of the long plantar ligament (3) forms with the groove of the cuboid (D6) a tunnel for the peroneus (fibularis) longus tendon (6) which runs to the medial cuneiform (4) and the base of the first metatarsal (1).

1 Base of first metatarsal
2 Flexor hallucis longus
3 Long plantar ligament
4 Medial cuneiform
5 Peroneus (fibularis) brevis
6 Peroneus (fibularis) longus
7 Plantar calcaneocuboid (short plantar) ligament
8 Tibialis anterior
9 Tibialis posterior
10 Tuberosity of base of fifth metatarsal
11 Tuberosity of navicular

The plantar calcaneonavicular ligament (D9), commonly called the spring ligament, is one of the most important in the foot. It stretches between the sustentaculum tali (D7) and the tuberosity of the navicular (D16), blending on its medial side with the deltoid ligament of the ankle joint and supporting the upper surface part of the head of the talus.

D

The anterior end of the long plantar ligament (3) has been removed to show the groove for peroneus (fibularis) longus on the cuboid (6).

1 Base of proximal phalanx
2 Collateral ligament of metatarsophalangeal joint
3 Deep fibres of long plantar ligament
4 Deltoid ligament
5 Fibrous slip from tibialis posterior
6 Groove on cuboid for peroneus (fibularis) longus
7 Groove on sustentaculum tali for flexor hallucis longus
8 Head of second metatarsal
9 Plantar calcaneonavicular (spring) ligament
10 Plantar cuboideonavicular ligament
11 Plantar cuneonavicular ligament
12 Plantar metatarsal ligament
13 Sesamoid bone
14 Tibialis posterior
15 Tuberosity of base of fifth metatarsal
16 Tuberosity of navicular

Ankle (A) anteroposterior projection (B) lateral projection

1 Calcaneus
2 Cuboid
3 Fibula
4 Head of talus
5 Lateral cuneiform
6 Lateral malleolus of fibula
7 Posterior talar process
8 Medial malleolus of tibia
9 Medial tubercle of talus
10 Navicular
11 Region of inferior tibiofibular joint
12 Sustentaculum tali of calcaneus
13 Talus
14 Tibia
15 Tuberosity of base of fifth metatarsal

* The side view in B shows a small calcaneal spur.

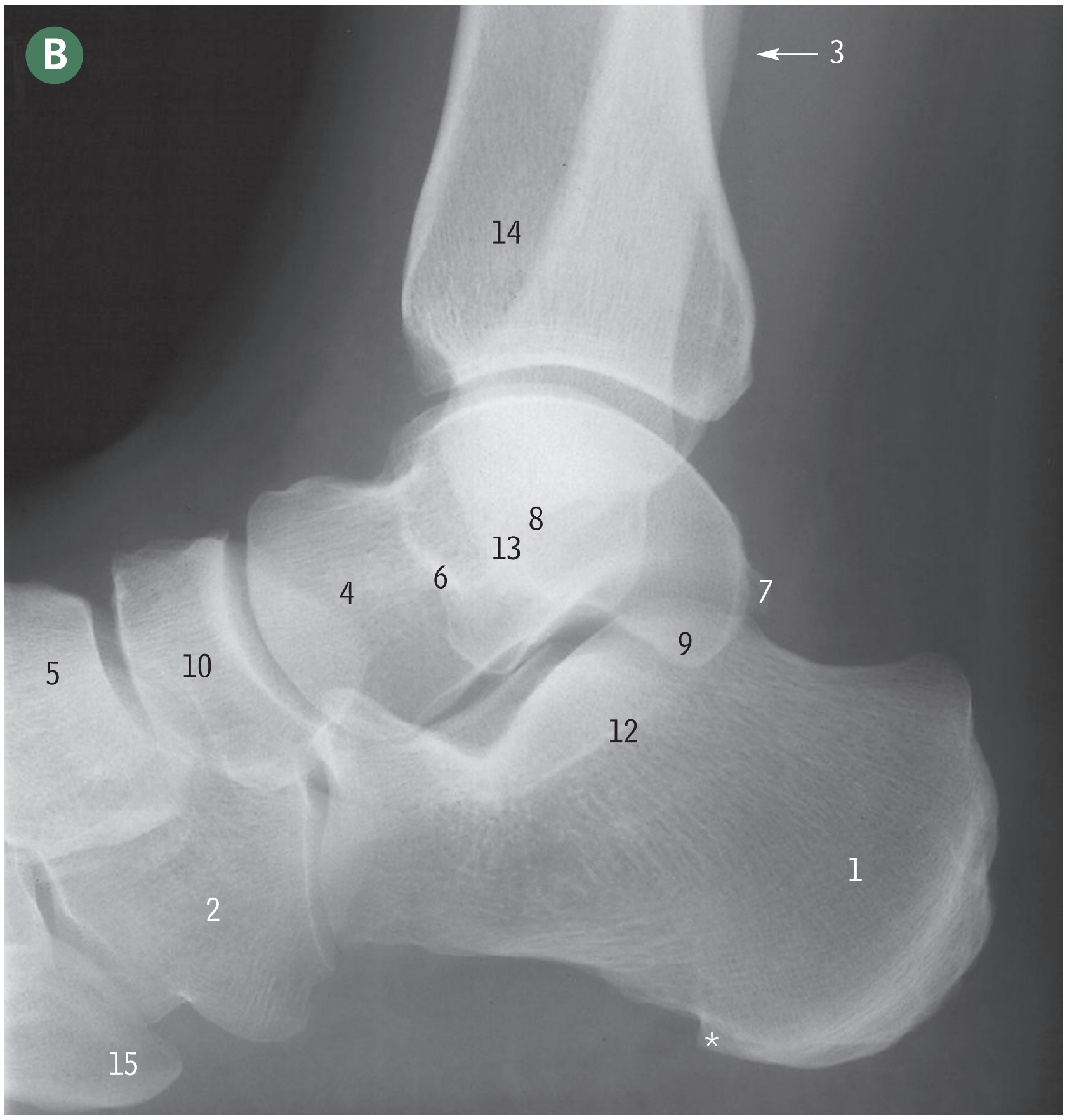

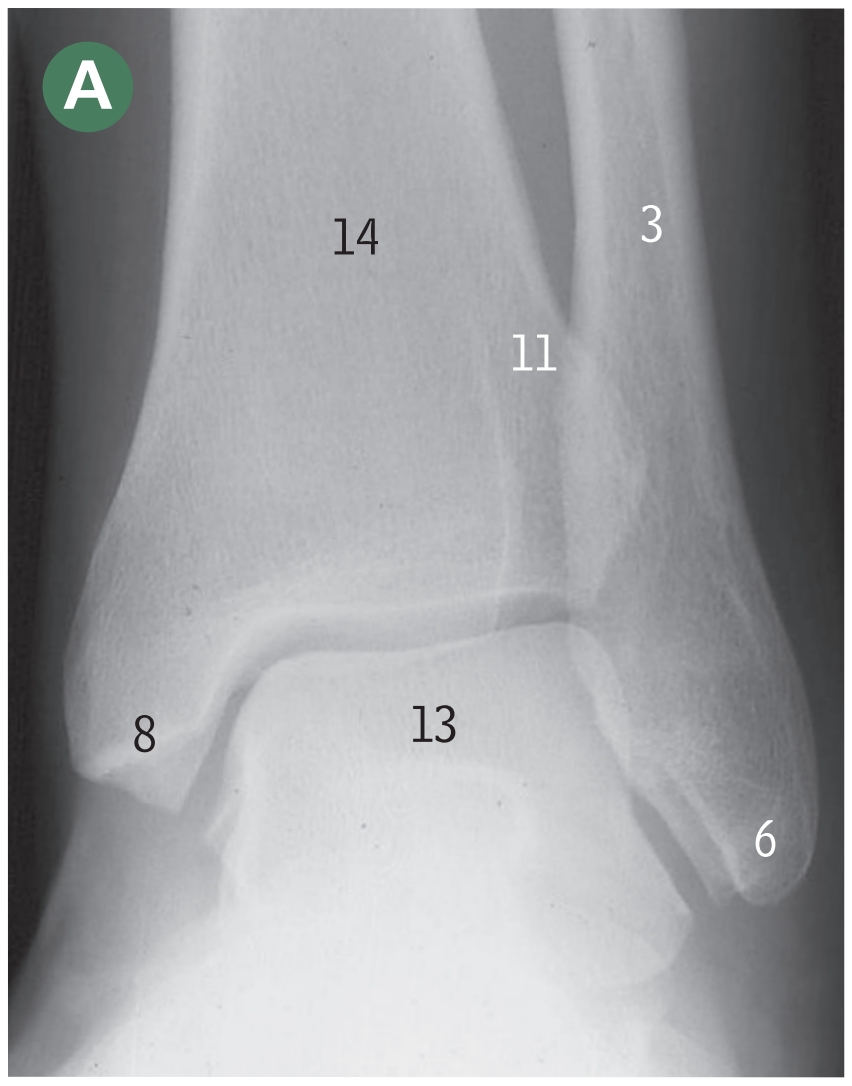

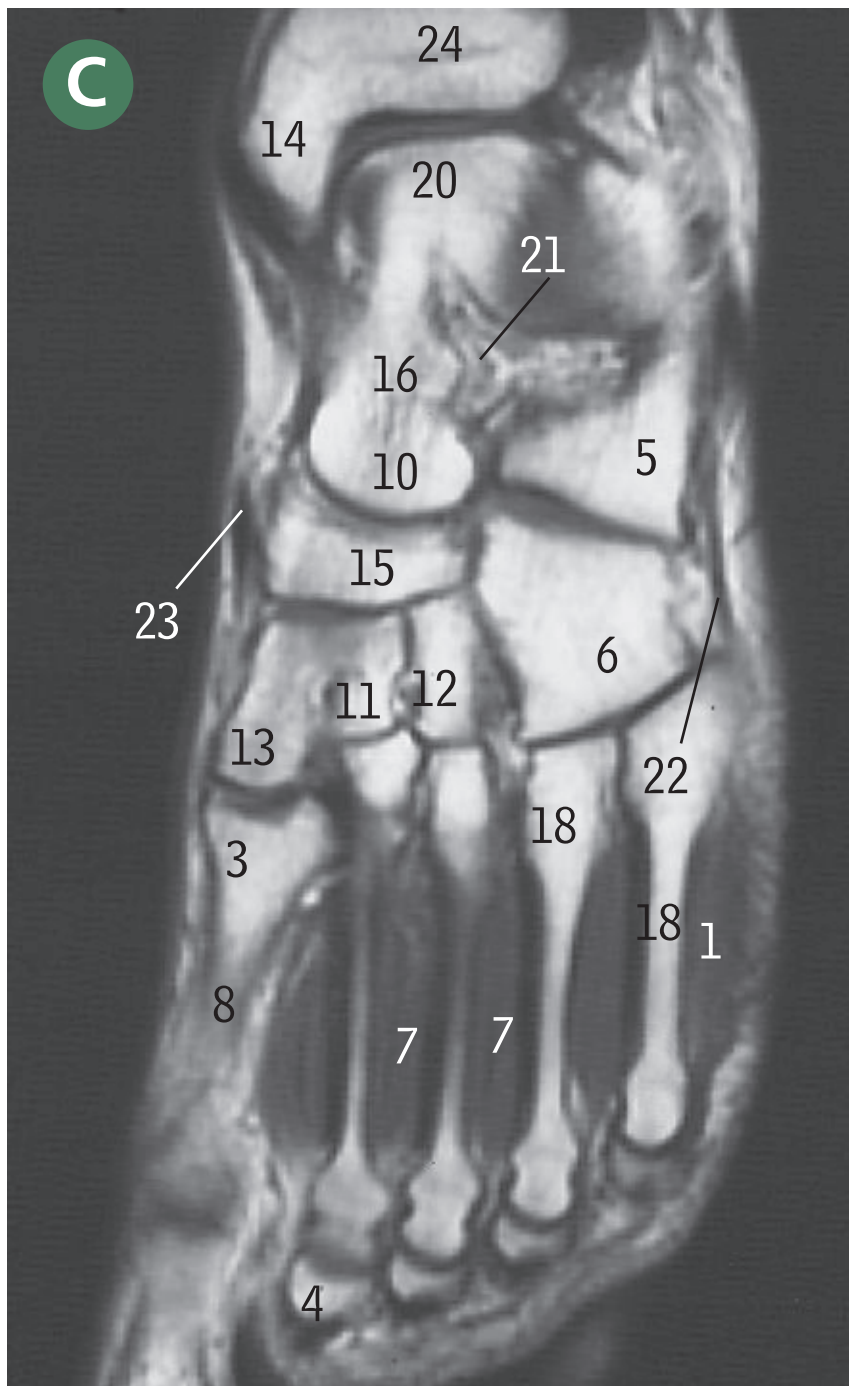

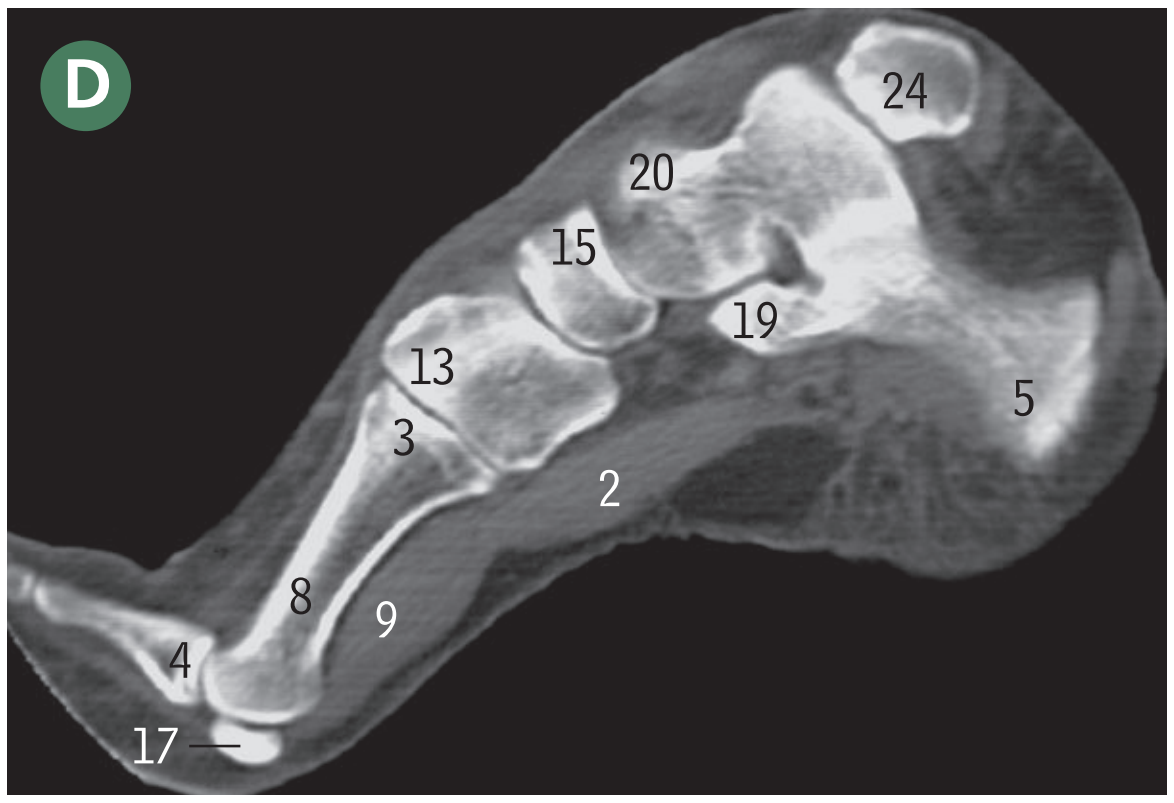

Foot

(C) long axis MR image

(D) sagittal CT through hallux

1 Abductor digiti minimi
2 Abductor hallucis
3 Base of metatarsal
4 Base of proximal phalanx
5 Calcaneus
6 Cuboid
7 Dorsal interossei muscle
8 First metatarsal
9 Flexor digitorum brevis
10 Head of talus
11 Intermediate cuneiform
12 Lateral cuneiform
13 Medial cuneiform
14 Medial malleolus
15 Navicular
16 Neck of talus
17 Sesamoid bone in flexor hallucis brevis
18 Shaft of metatarsal
19 Sustentaculum tali of calcaneus
20 Talus
21 Tarsal sinus (talocalcaneal cervical ligament)
22 Tendon of peroneus (fibularis) brevis muscle
23 Tendon of tibialis anterior
24 Tibia

Pott's and other fractures of the ankle, see pages 355–357.

Lower limb

Clinical thumbnails, see website for details and further clinical images to download into your own notes.

Achilles tendon tendocalcaneus reflex (ankle jerk)

Ankle arthroscopy

Ankle block

Ankle ulceration from varicose veins

Avascular necrosis of the head of the femur

Avulsion fractures

Bipartite patella

Calcaneal fracture

Charcot foot

Common peroneal (fibular) nerve paralysis

Compartment syndrome

Deep vein thrombosis (DVT)

Digital abnormalities

Dislocation of the patella

Dislocation of the toe

Exostoses femoral spurs

Extensor plantar response – Babinski sign

Femoral artery puncture

Femoral nerve paralysis

Femoropopliteal bypass

Flat foot (pes planus)

Fracture – femoral neck

Fracture – femoral shaft

Genu valgum, genu varum

Hallux sesamoid fracture

Hallux valgus

Hammer toe

Intermittent claudication

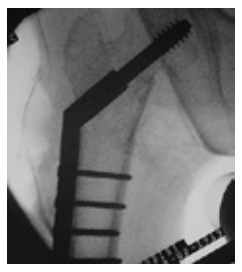
Intertrochanteric fracture – femur

Intramuscular injection – gluteal region

Knee joint aspiration and injection

Knee joint replacement surgeries

Lower limb bursitis

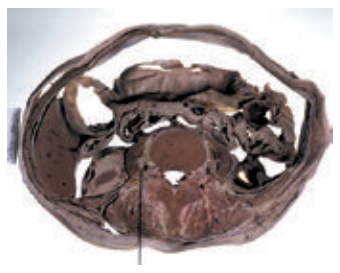
Lumbar plexus block

Malignant melanoma

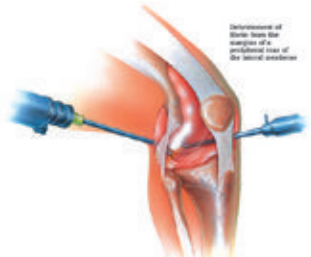
Meniscal tears

Meralgia paraesthetica

Metatarsal fractures

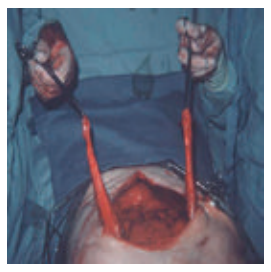
Muscular transposition

Obturator nerve paralysis

Os trigonum

Osgood–Schlatter's disease

Patellar fracture

Patellar tendon reflex

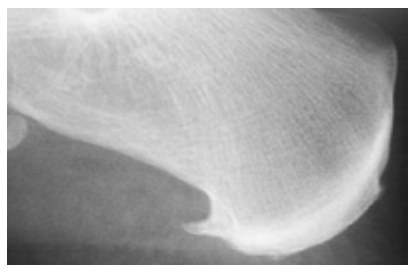
Plantar fasciitis

Popliteal artery aneurysm

Popliteal (Baker's) cyst

Posterior hip dislocation

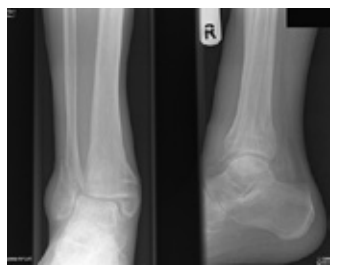
Pott's and other fractures of the ankle

Prepatellar bursitis

Rupture – Achilles tendon

Rupture – anterior cruciate ligament

Rupture – posterior cruciate ligament

Rupture – quadriceps tendon

Slipped upper femoral epiphysis

Sprained ankle

Suprapatellar bursitis

Sural nerve graft

Talipes equinovarus (club foot)

Tarsal dislocations

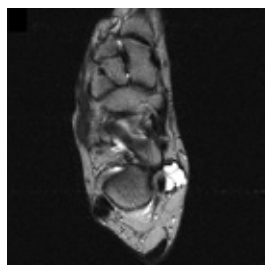
Tarsal tunnel syndrome

Tibial fractures

Tibialis posterior tendonitis

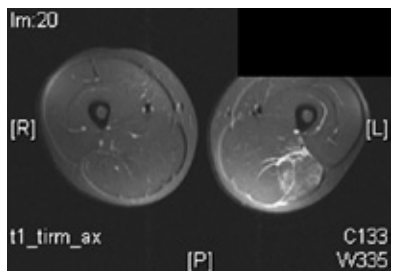
Torn hamstrings

Total hip replacement surgery

Trendelenburg's sign

Ulceration of the leg

Varicella-zoster virus infection – lower limb

Varicose veins

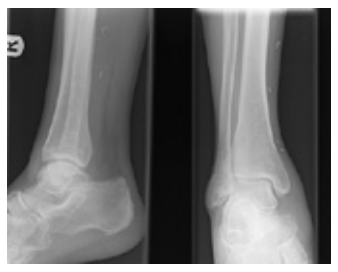
Vein harvest for coronary artery bypass grafting (CABG)

Venous cutdown

This page intentionally left blank

Lymphatics

7

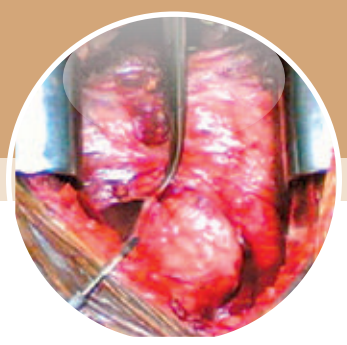

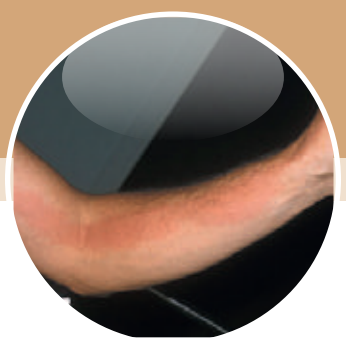

Lymphatic system

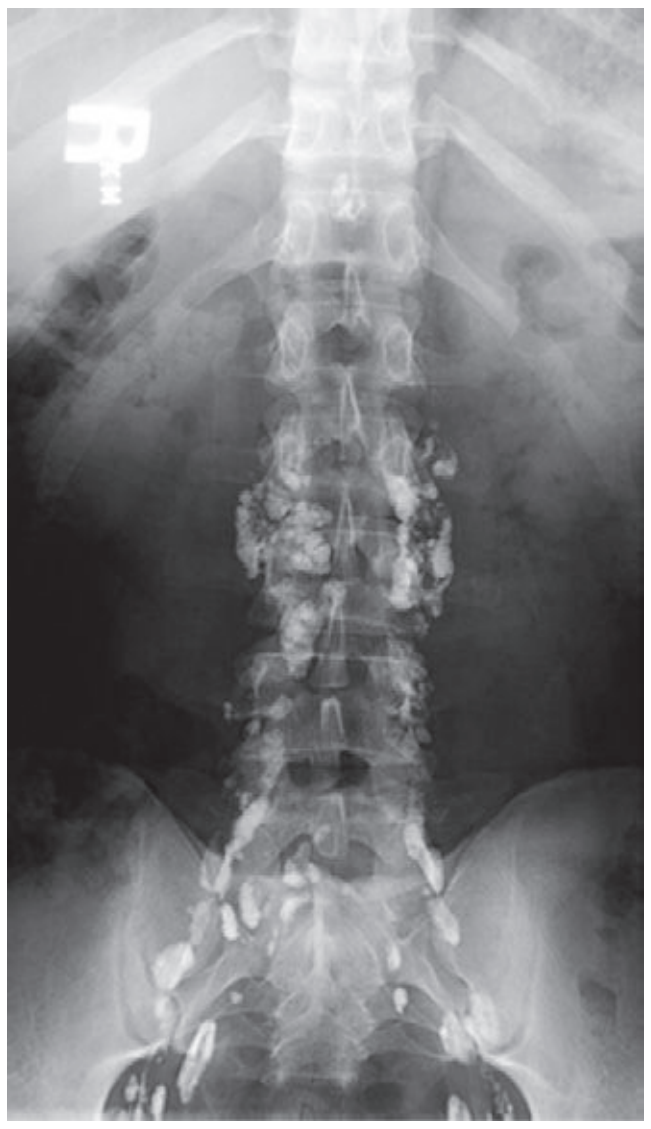

Lumbar spine - AP phase 2

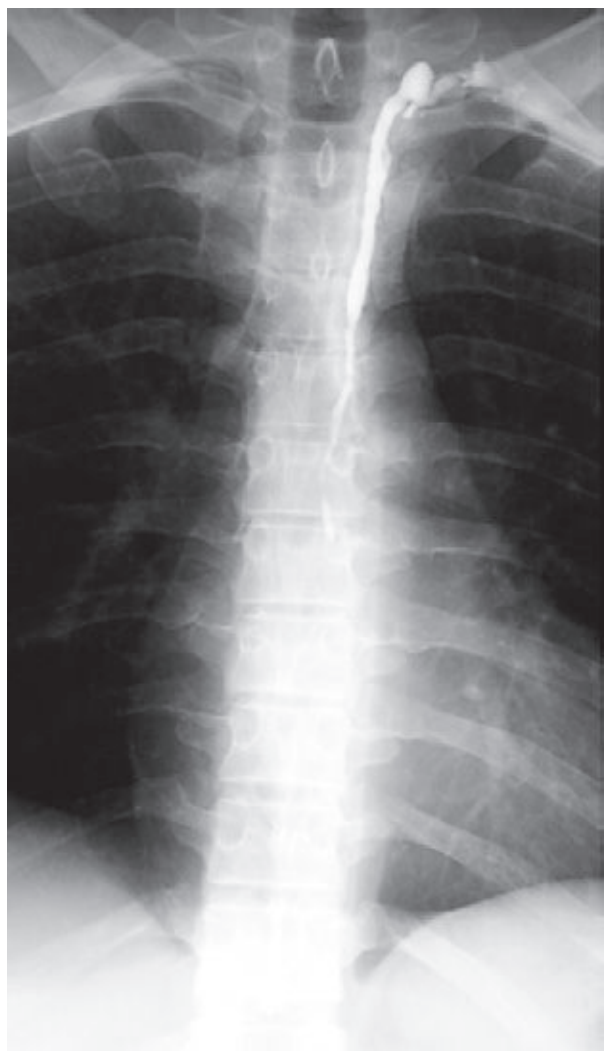

Thoracic duct termination in neck

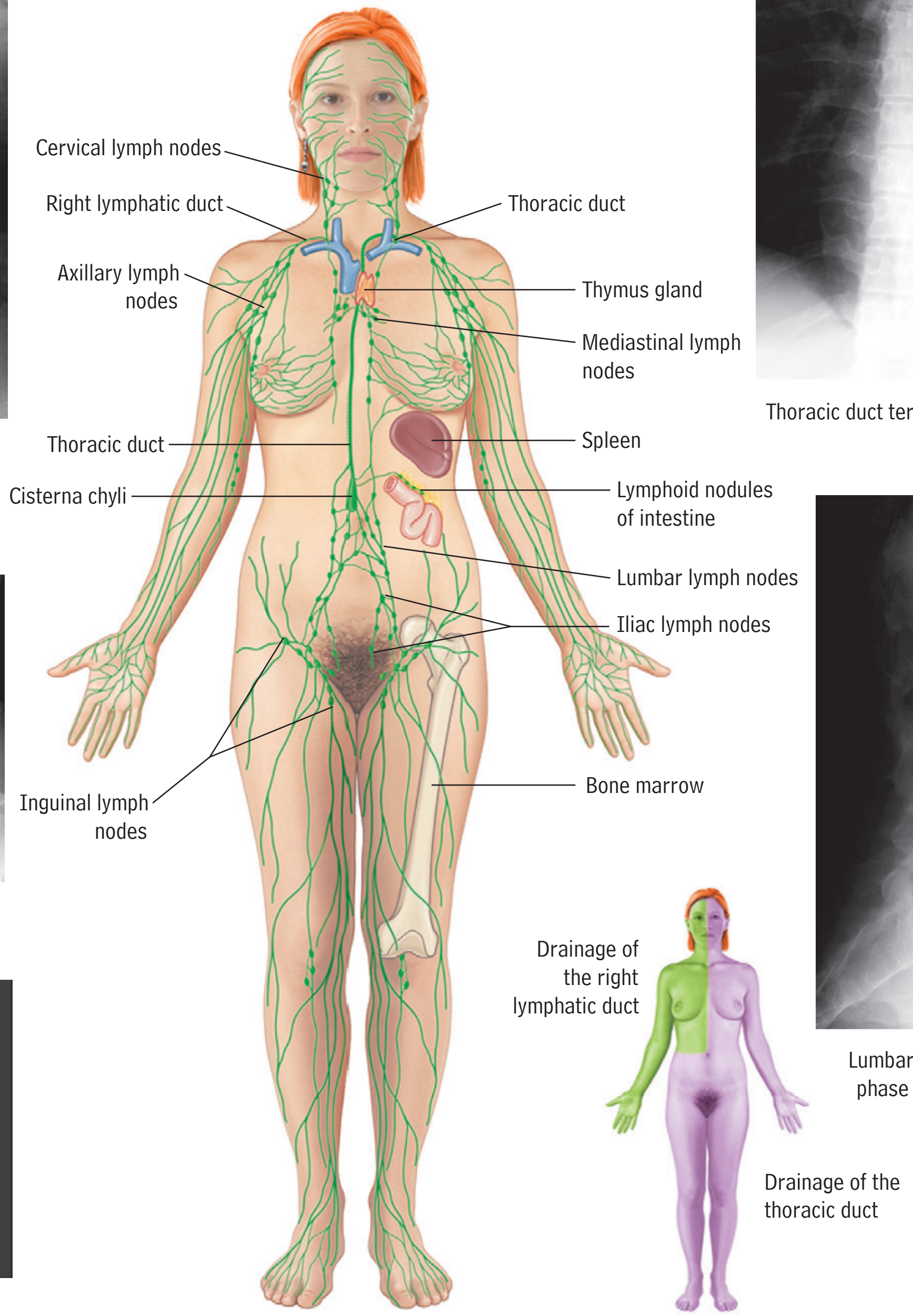

Pelvis - AP phase 2, NB nodes

Lumbar spine - lateral phase 1, NB vessels

Pelvis - AP phase 1, NB vessels

The lymphangiograms shown on this page are rarely performed clinically due to advances in CT scanning; however they do illustrate perfectly the detailed anatomy. Phase 1 images are taken on day one and best show the vessels whereas phase 2 are taken at about 48 hours and best image the lymph nodes.

Lymphatic system–methylene blue test, see page 369.

A Thymus

lying in the superior and anterior mediastinum as seen through a split-sternal approach

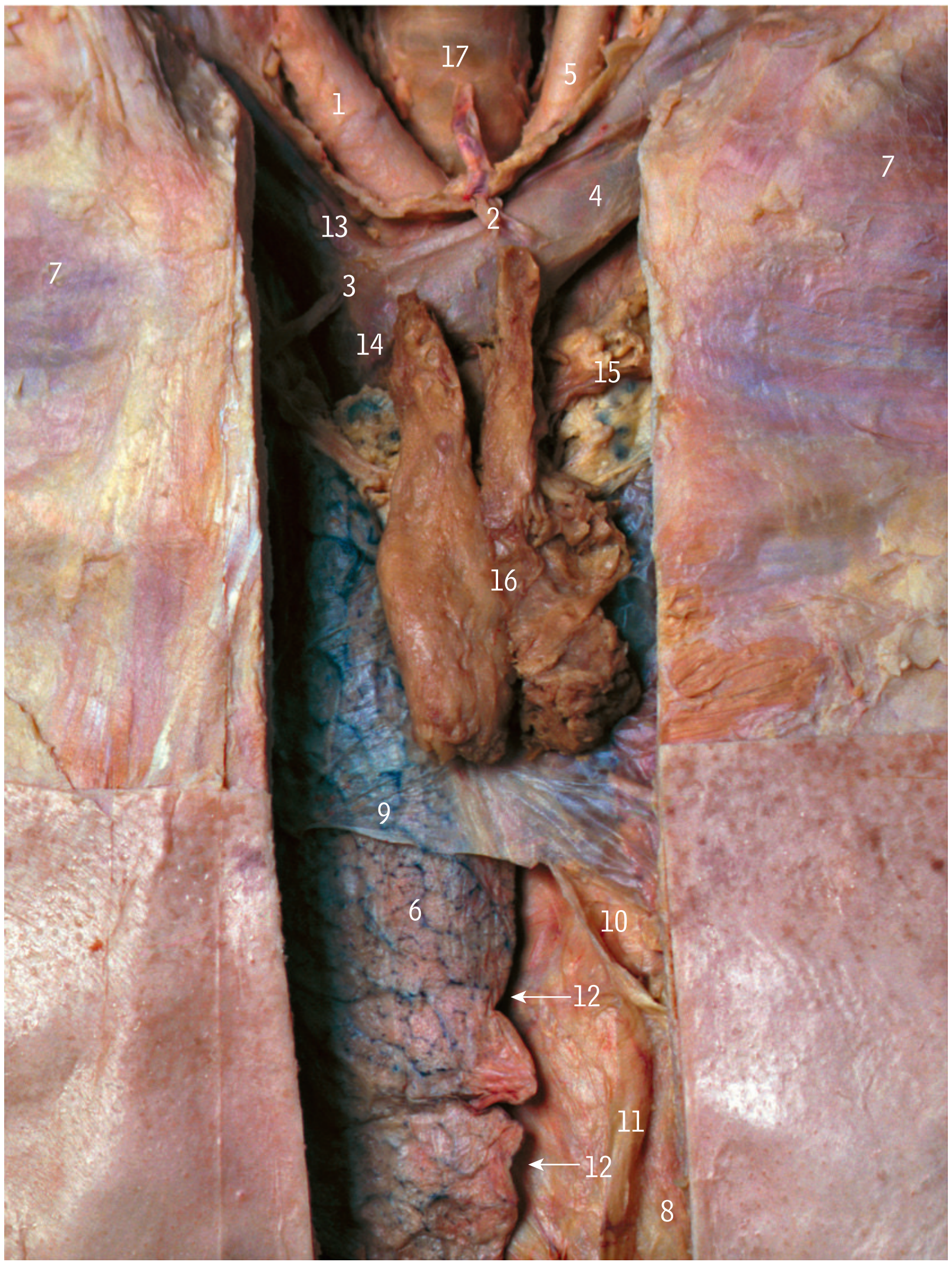

B Chest radiograph of a child

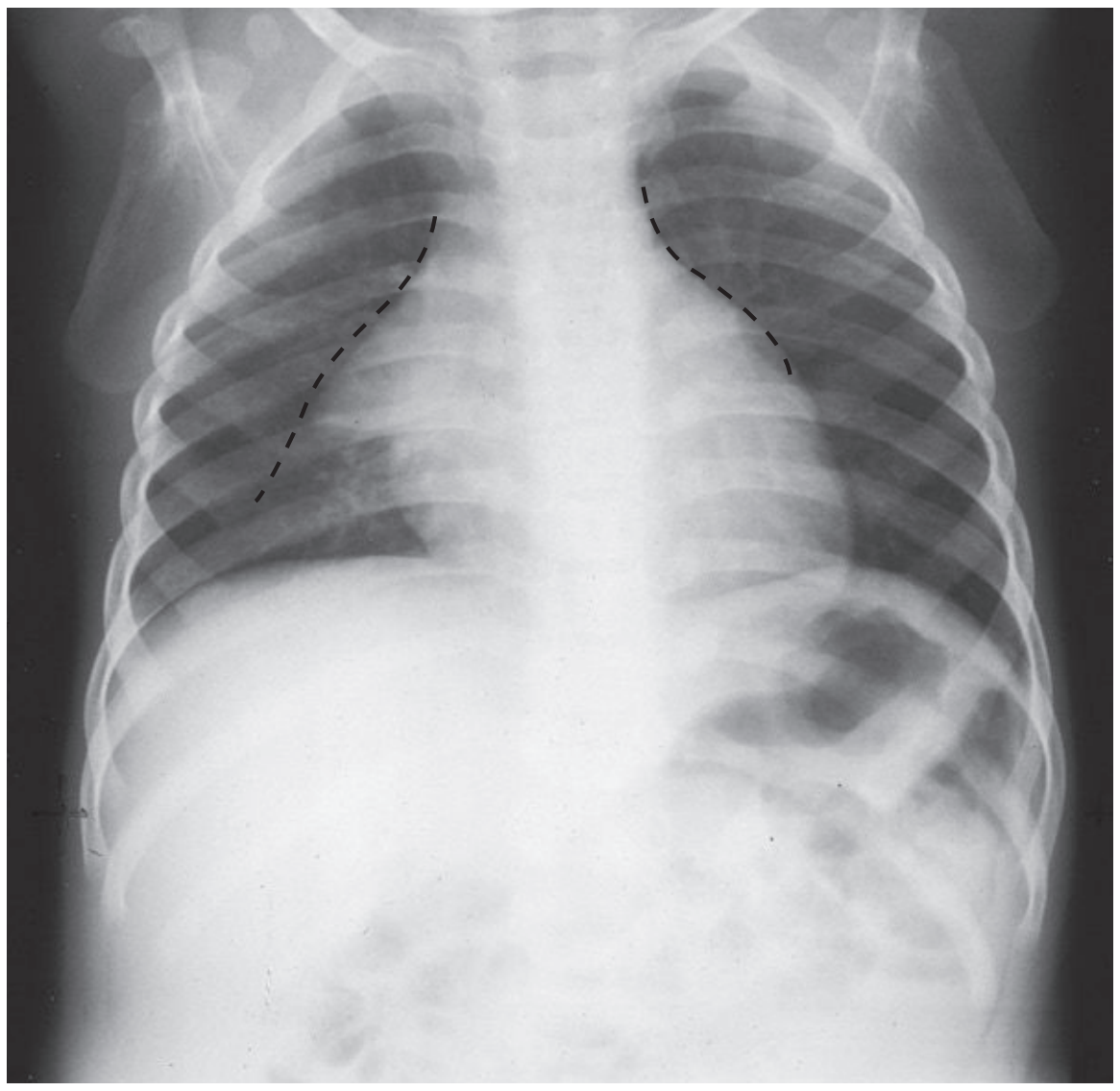

Child's thymus can normally be seen under the age of 2 on a plain chest radiograph, appearing as a spinnaker sail (sail sign), as outlined by the interrupted line.

C Palatine tonsils

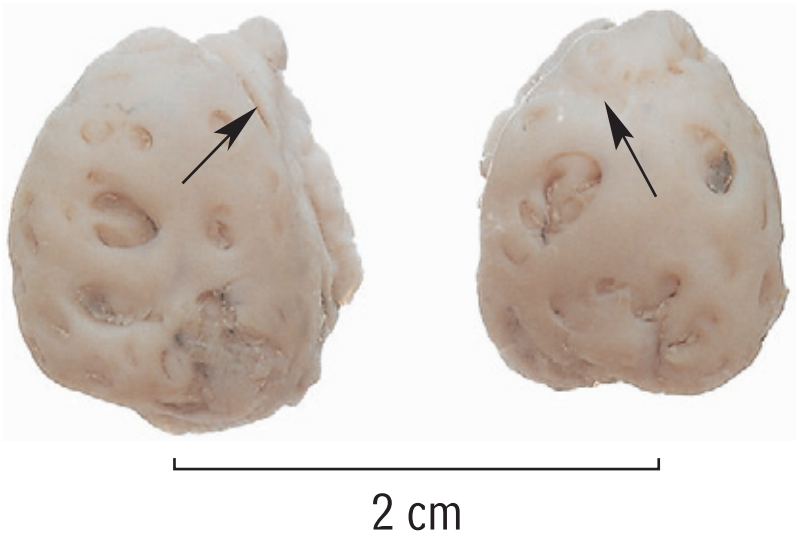

The pits on the medial surfaces of these operation specimens from a child aged 14 years are the openings of the tonsillar crypts. The arrows indicate the intratonsillar clefts (the remains of the embryonic second pharyngeal pouch).

The palatine tonsils (commonly referred to as 'the tonsils') are masses of lymphoid tissue that are frequently enlarged in childhood but become much reduced in size in later life. Together with the lymphoid tissue in the posterior part of the tongue (lingual tonsil) and in the posterior wall of the nasopharynx (pharyngeal tonsil) and the tubal tonsil they form a protective 'ring' of lymphoid tissue (Waldeyer's ring) at the upper end of the respiratory and alimentary tracts.

1 Brachiocephalic trunk (artery)
2 Inferior thyroid vein
3 Internal thoracic vein, right
4 Left brachiocephalic vein
5 Left common carotid artery
6 Lung, upper lobe right
7 Pectoralis major
8 Pericardium, fibrous
9 Pleura
10 Pleura (cut edge of left sac)
11 Pleura (cut edge of right sac)
12 Pleural cavity
13 Right brachiocephalic vein
14 Superior vena cava
15 Thymic vein draining into internal thoracic vein
16 Thymus gland (bilobed)
17 Trachea

Thymus, tonsillitis, see page 369.

A **Neck dissection** *termination of the thoracic duct into the left subclavian vein in the root of neck – as seen from left side*

SUPERIOR

RIGHT/ANTERIOR

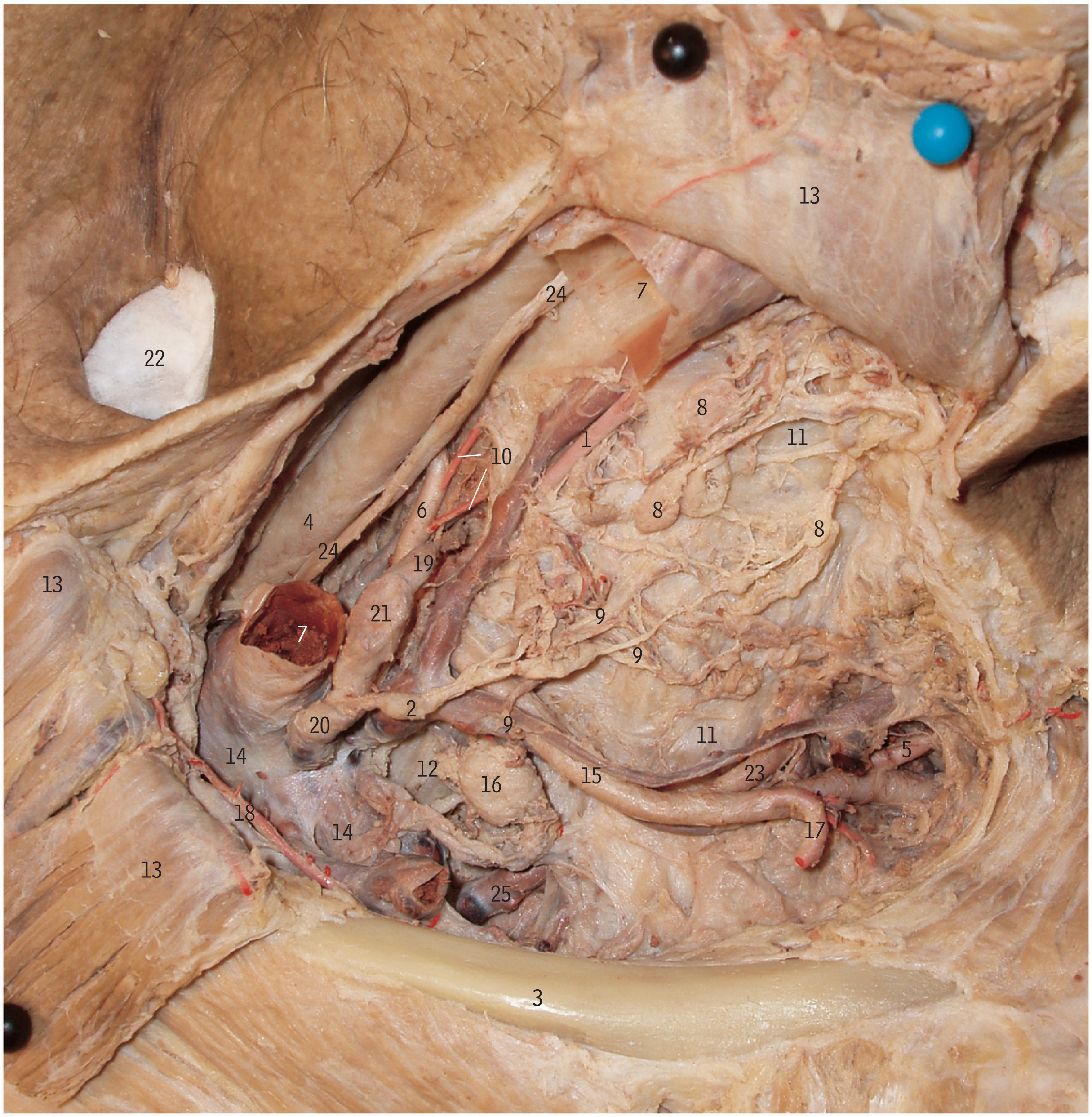

LEFT/POSTERIOR

INFERIOR

1 Ascending cervical artery and vein
2 Cervical lymphatic trunk
3 Clavicle (left)
4 Common carotid artery
5 Dorsal scapular artery
6 Inferior thyroid artery
7 Internal jugular vein
8 Lymph nodes, deep cervical chain
9 Lymph vessel from node to cervical trunk
10 Muscular arterial branches to longus colli
11 Prevertebral fascia
12 Scalenus anterior
13 Sternocleidomastoid (reflected and pinned)
14 Subclavian vein
15 Superficial cervical artery
16 Supraclavicular node (Virchow – enlarged)
17 Suprascapular artery
18 Thoraco-acromial artery, clavicular branch
19 Thoracic duct
20 Thoracic duct, termination
21 Thoracic duct, ampulla
22 Tracheostomy site (midline)
23 Transverse cervical artery and vein
24 Vagus nerve
25 Vertebral vein

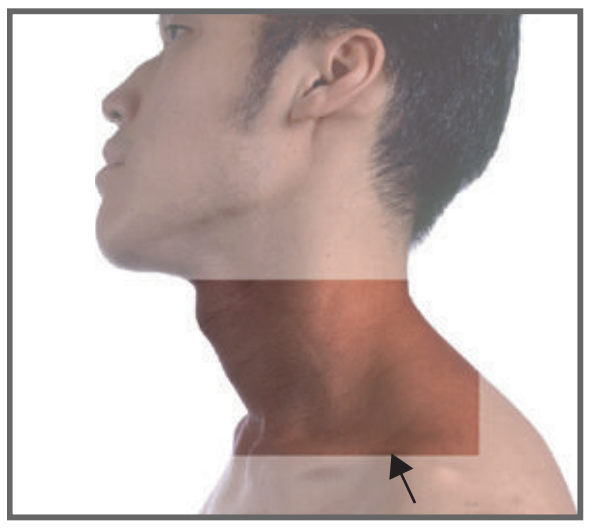

A Thoracic duct *cervical part*

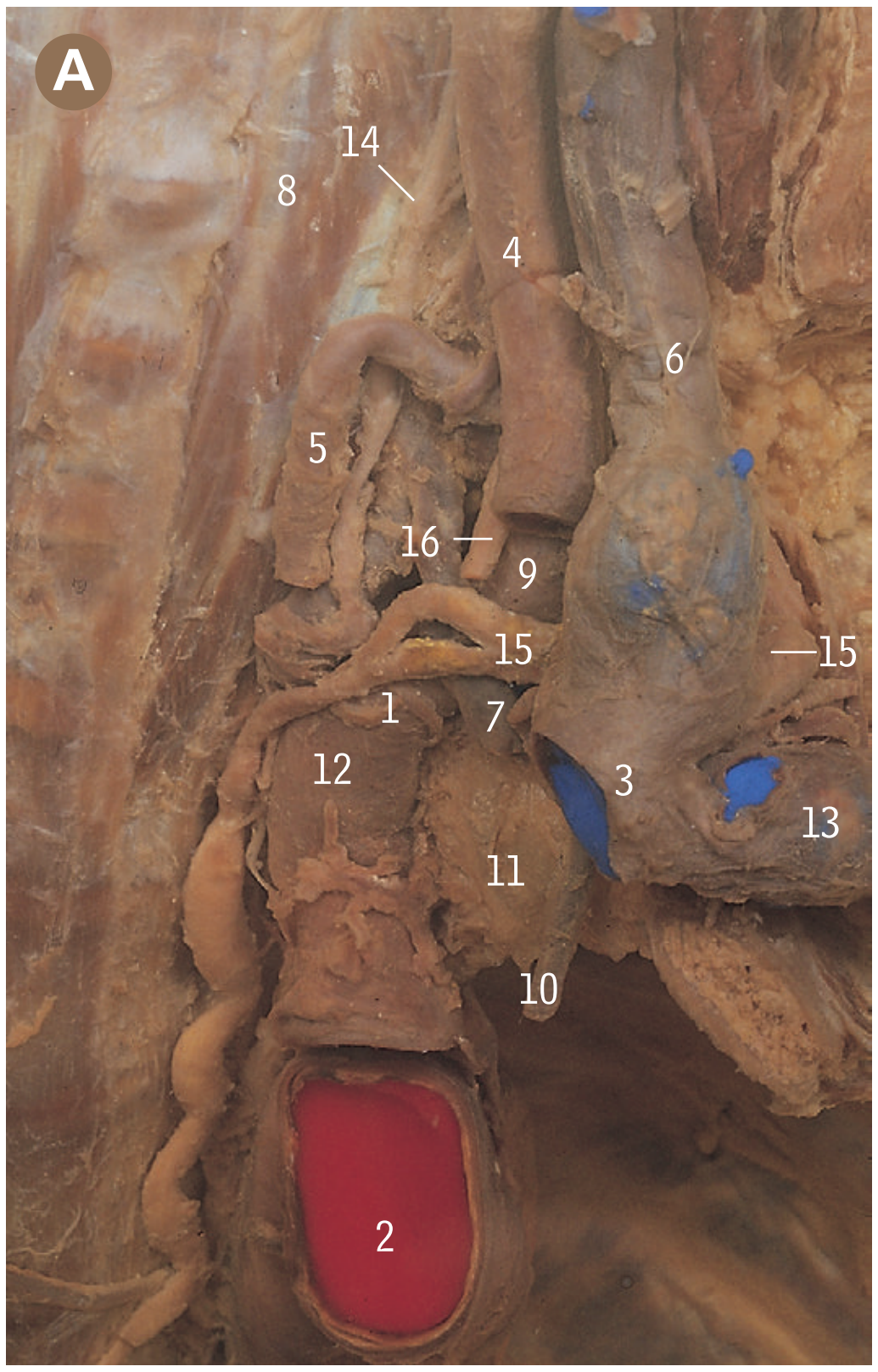

In this deep dissection of the left side of the root of the neck and upper thorax, the internal jugular vein (6) joins the subclavian vein (13) to form the left brachiocephalic vein (3). The thoracic duct (15) is double for a short distance just before passing in front of the vertebral artery (9) and behind the common carotid artery (4), whose lower end has been cut away to show the duct). The duct then runs behind the internal jugular vein (6) before draining into the junction of that vein with the subclavian vein (13).

1 Ansa subclavia
2 Arch of aorta
3 Brachiocephalic vein
4 Common carotid artery
5 Inferior thyroid artery
6 Internal jugular vein
7 Internal thoracic artery
8 Longus colli
9 Origin of vertebral artery
10 Phrenic nerve
11 Pleura
12 Subclavian artery
13 Subclavian vein
14 Sympathetic trunk
15 Thoracic duct
16 Vagus nerve

B First day lymphangiogram

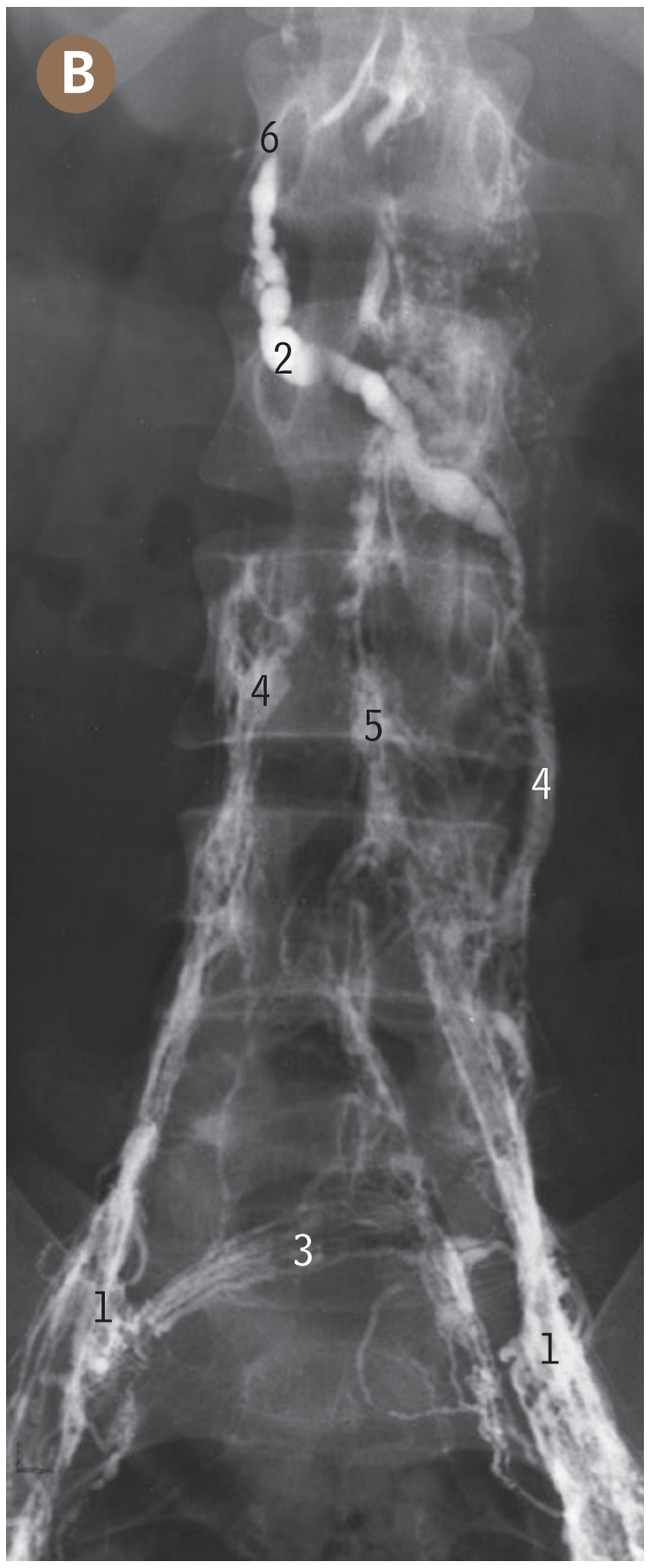

1 Common iliac vessels
2 Cisterna chyli
3 Lumbar crossover
4 Para-aortic vessels
5 Pre-aortic vessels
6 Thoracic duct

C Lymphangiogram of thorax

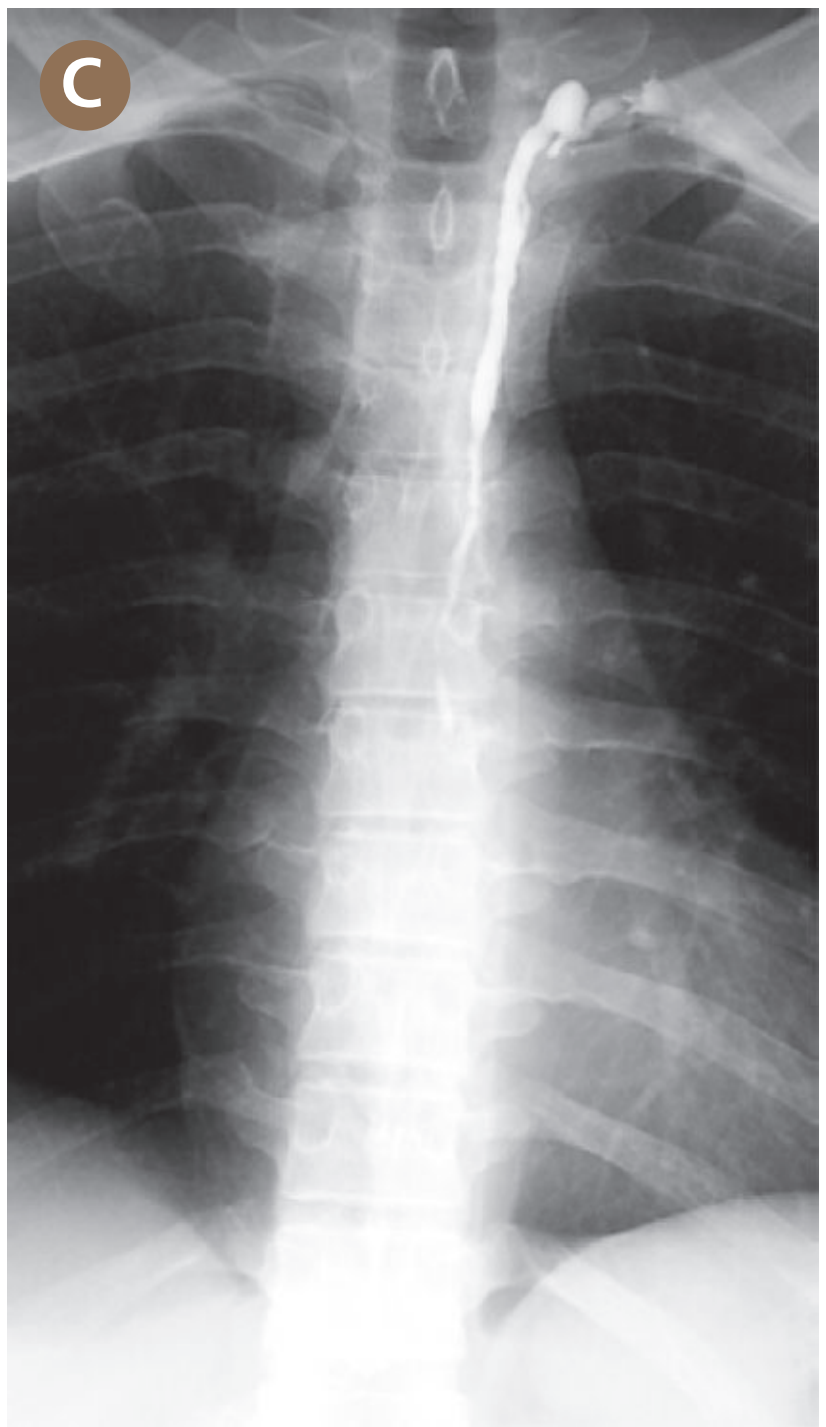

Thoracic duct termination in neck
(Here seen superiorly at venous confluence of left internal jugular vein and subclavian vein.)

Virchow's node, see page 369.

Right axilla with moderate lymphadenopathy

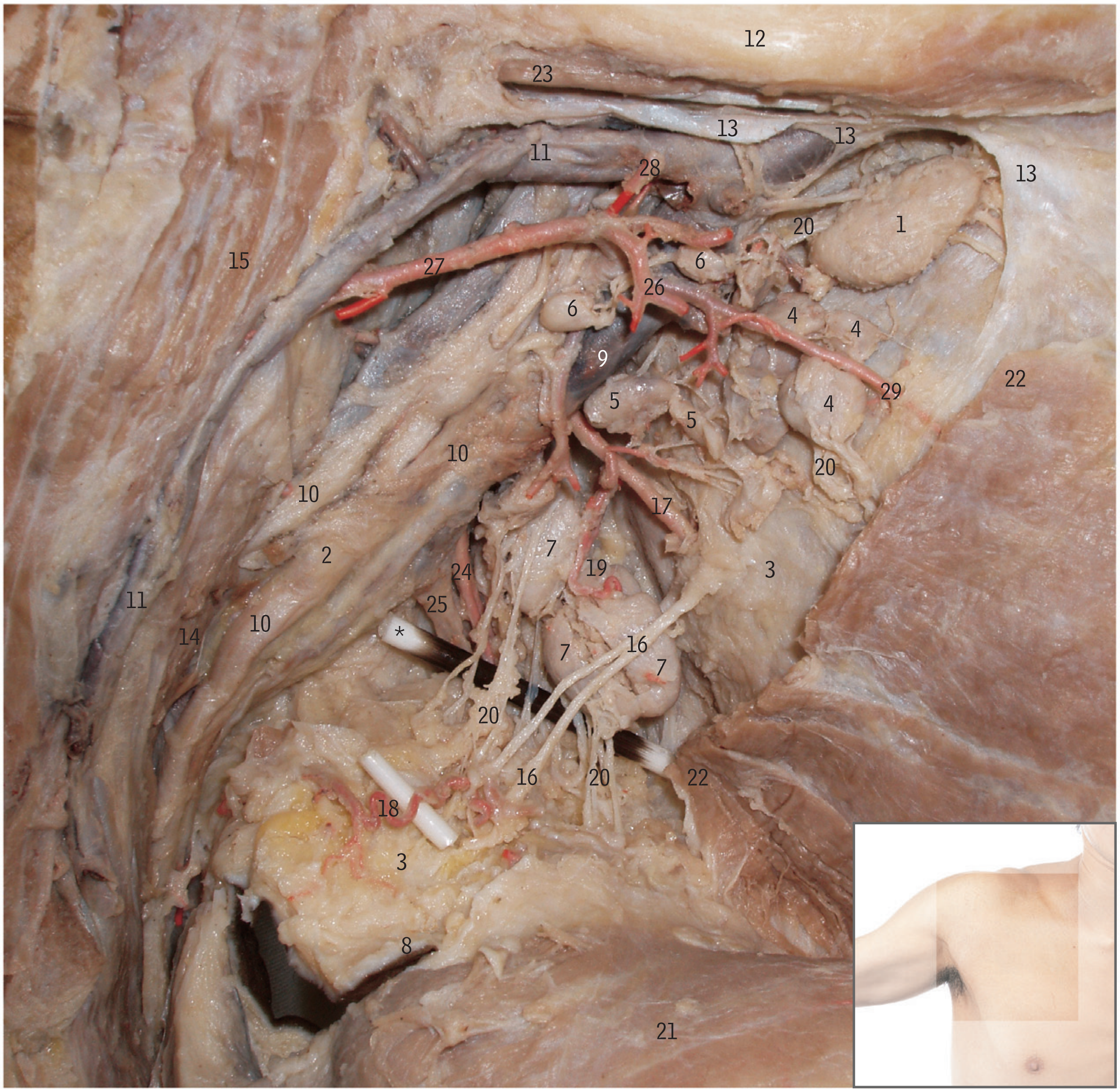

1 Apical node (infraclavicular – enlarged)
2 Axillary fascial sheath
3 Axillary fat
4 Axillary nodes, anterior or pectoral group
5 Axillary nodes, central group
6 Axillary nodes, lateral group (normal)
7 Axillary nodes, posterior group (enlarged)
8 Axillary skin
9 Axillary vein
10 Brachial plexus within axillary sheath
11 Cephalic vein
12 Clavicle
13 Clavipectoral fascia (cut)
14 Coracobrachialis
15 Deltoid
16 Intercostobrachial nerve
17 Lateral thoracic artery
18 Lateral thoracic, axillary skin and sweat gland branches
19 Lateral thoracic, nodal arterial branch
20 Lymphatic vessels
21 Pectoralis major (reflected)
22 Pectoralis minor
23 Subclavius
24 Subscapular artery
25 Subscapular vein
26 Thoraco-acromial artery
27 Thoraco-acromial artery, deltoid branch
28 Thoraco-acromial artery, clavicular branch
29 Thoraco-acromial artery, pectoral branch

***** Quill placed to lift vessels and nerves

Axial CT, axilla*

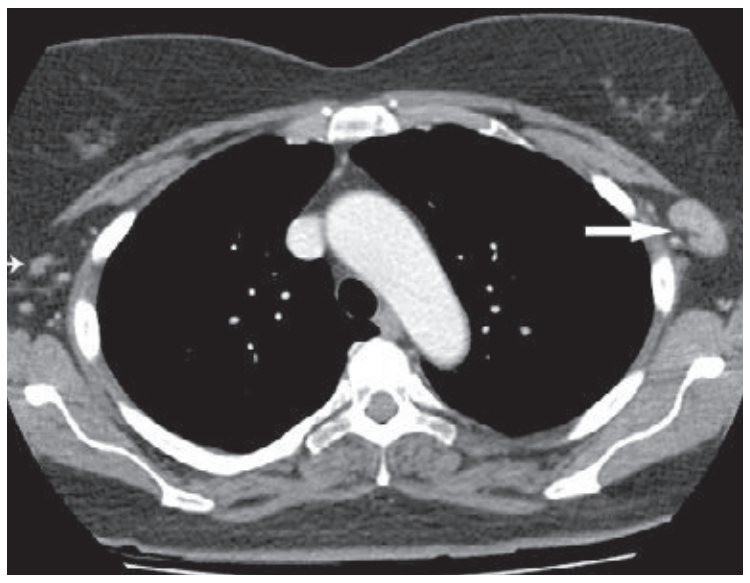

*Arrow points to enlarged axillary node

Axillary lymph node (sentinel node) dissection for breast cancer, lymphangitis, lymphoedema, see page 369.

A Right axilla and lymph nodes *from the front*

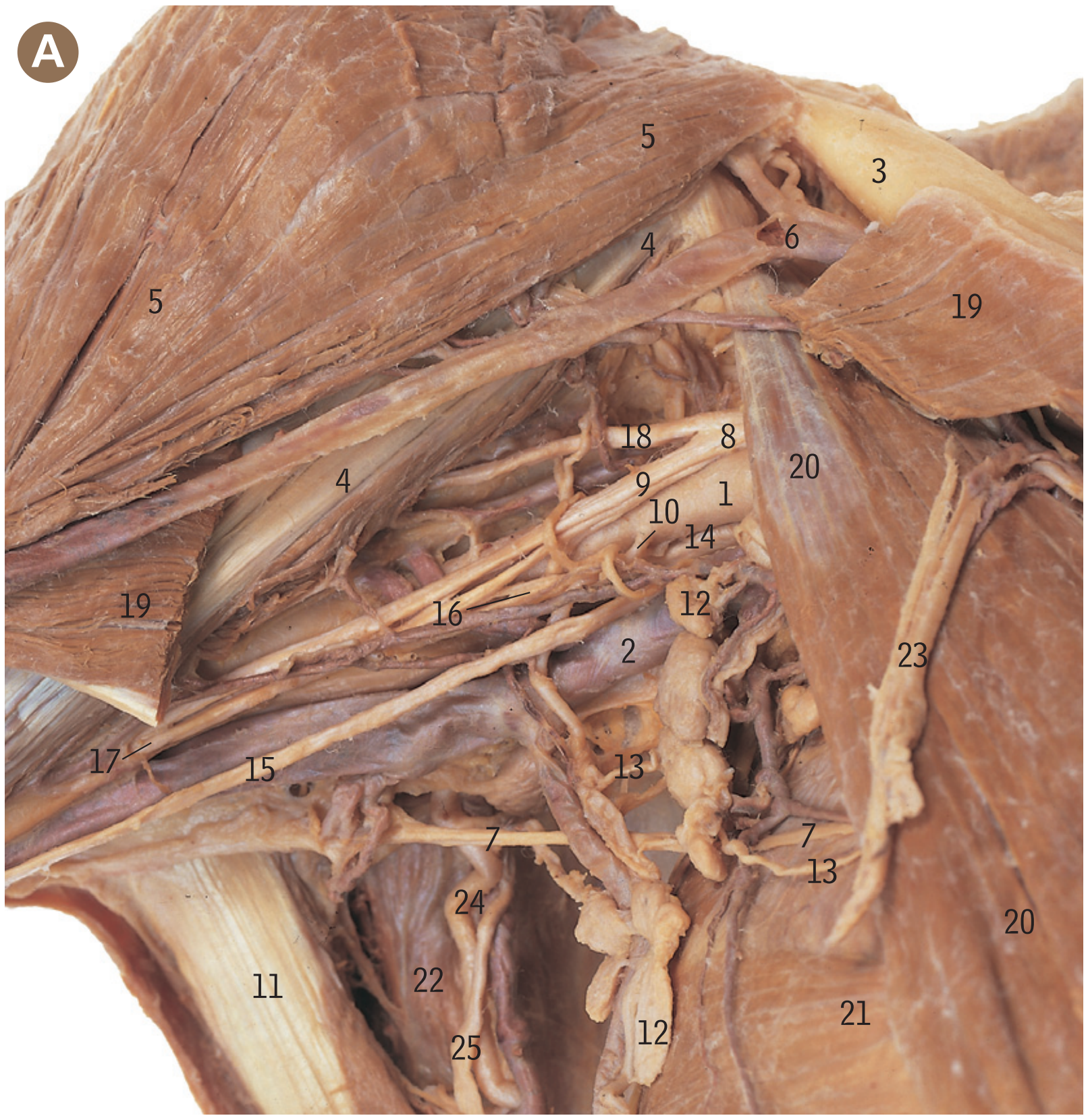

Pectoralis major (19) has been reflected and the clavipectoral fascia removed, together with the axillary sheath which surrounded the axillary artery and brachial plexus.

1 Axillary artery
2 Axillary vein
3 Clavicle
4 Coracobrachialis
5 Deltoid
6 Entry of cephalic vein into deltoid vein
7 Intercostobrachial nerve
8 Lateral cord of brachial plexus
9 Lateral root of median nerve
10 Lateral thoracic artery
11 Latissimus dorsi
12 Lymph nodes
13 Lymph vessels
14 Medial cord of the brachial plexus
15 Medial cutaneous nerve of arm
16 Medial root of median nerve
17 Median nerve
18 Musculocutaneous nerve
19 Pectoralis major
20 Pectoralis minor
21 Serratus anterior
22 Subscapularis
23 Thoracoacromial vessels and lateral pectoral nerve
24 Thoracodorsal artery
25 Thoracodorsal nerve

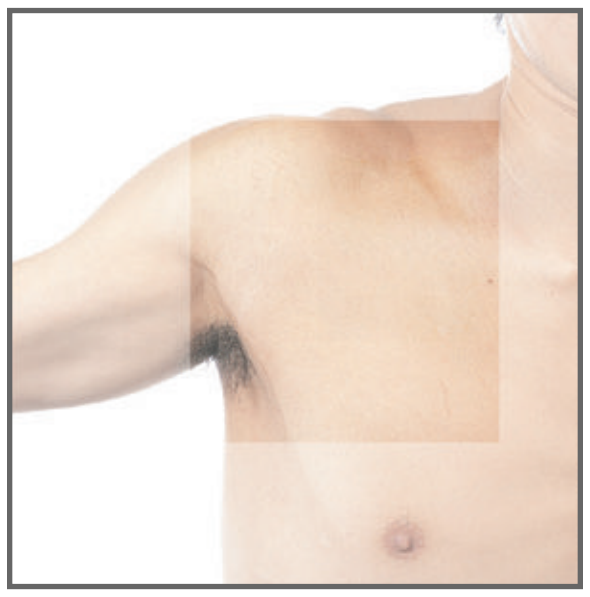

B Right cubital fossa *lymph nodes*

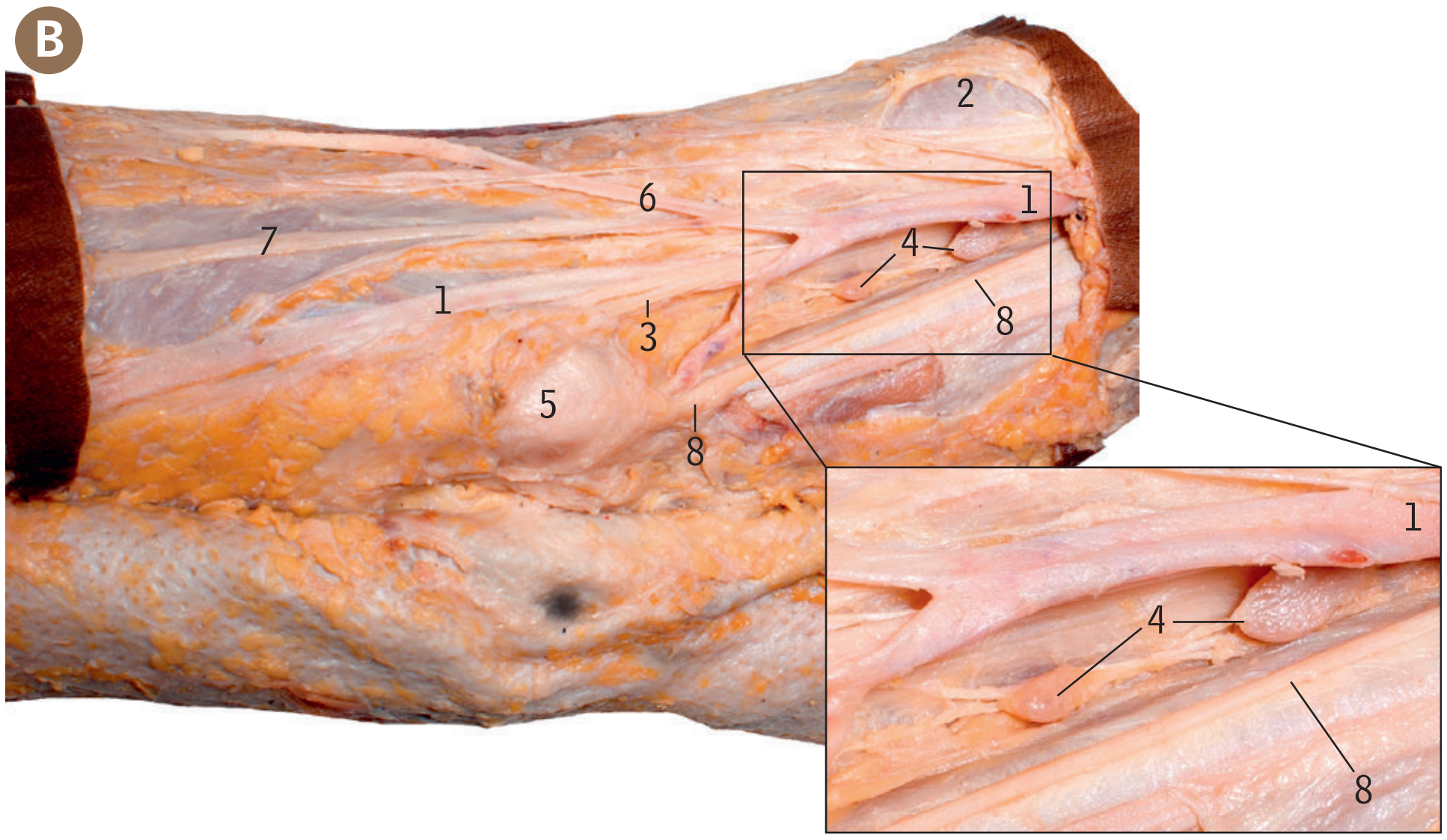

1 Basilic vein
2 Biceps brachii
3 Branches of medial cutaneous nerve of forearm
4 Cubital lymph nodes
5 Medial epicondyle of humerus
6 Median cubital vein
7 Median forearm vein
8 Ulnar nerve

Coronal CT*

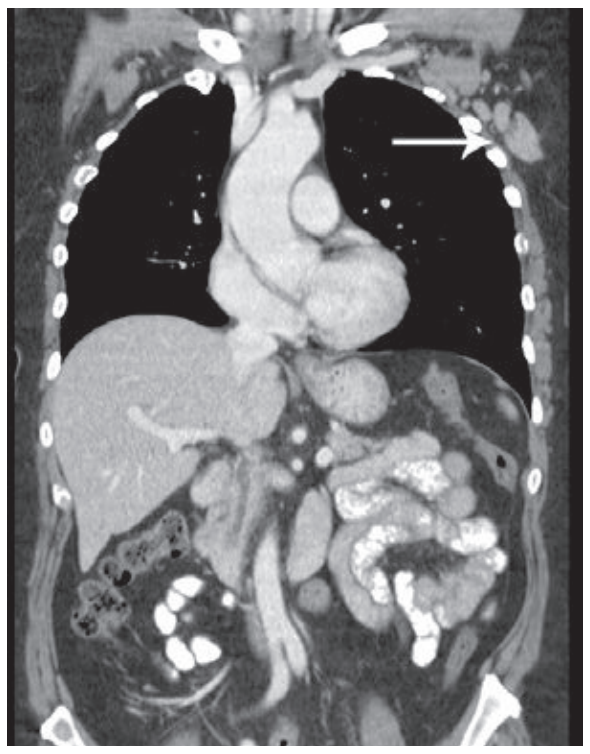

Parasagittal CT*

*Arrows indicate axillary lymphadenopathy

Cisterna chyli in posterior upper abdominal wall

Note split right crus

LEFT

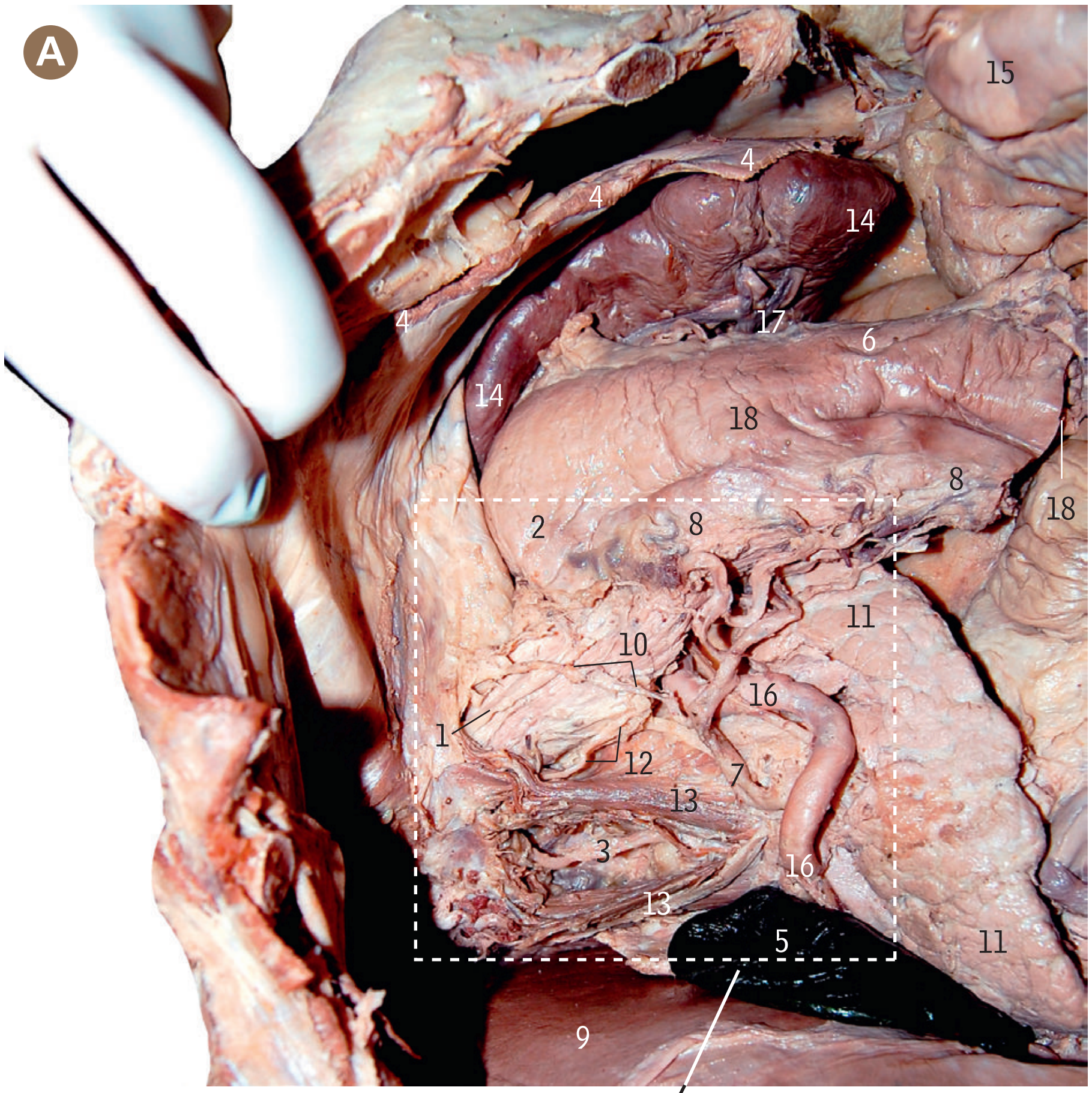

S U P E R I O R

I N F E R I O R

RIGHT

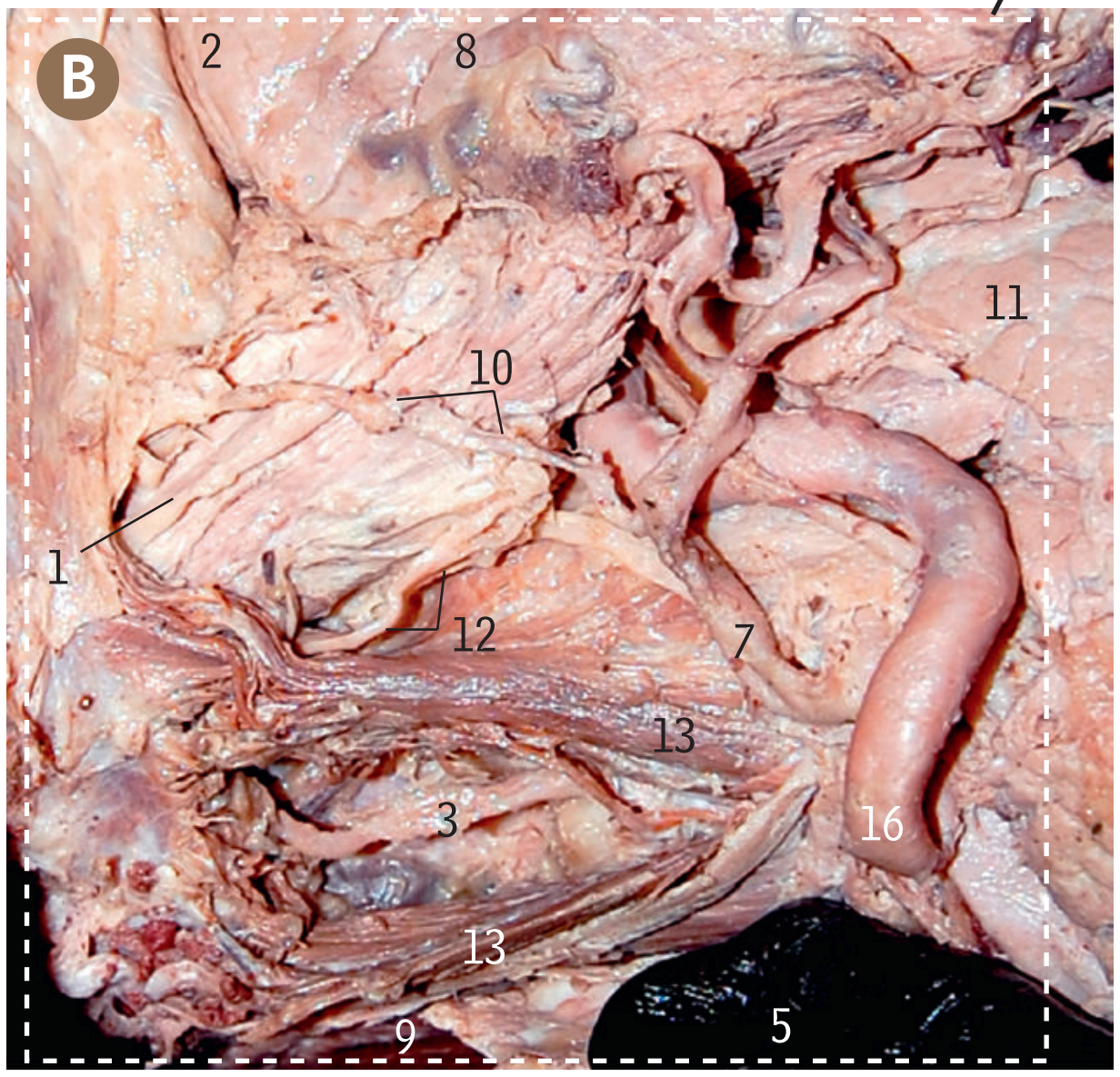

1 Anterior vagal trunk
2 Cardia of stomach
3 Cisterna chyli
4 Diaphragm
5 Gall bladder
6 Greater curvature of stomach
7 Left gastric artery
8 Lesser curvature of stomach
9 Liver
10 Oesophageal artery
11 Pancreas
12 Posterior vagal trunk
13 Right crus of the diaphragm (split)
14 Spleen
15 Splenic flexure
16 Splenic artery
17 Splenic hilum with splenic artery and vein
18 Stomach (cut)

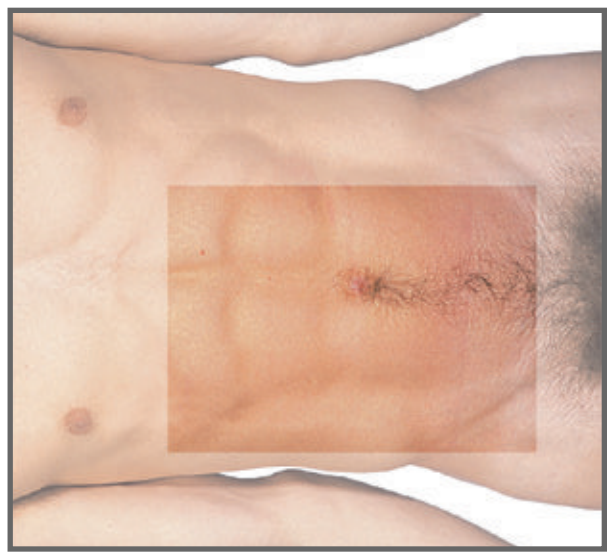

Female pelvis *left half of midline sagittal section with lymphadenopathy*

Retroverted uterus – a normal variant

1 Anterior vaginal fornix
2 Arterial supply to lymph node
3 Bladder neck
4 Cervix
5 External iliac artery
6 External iliac lymph node (enlarged)
7 External iliac vein
8 Fundus of uterus
9 Inferior epigastric vessels
10 Lateral cutaneous nerve of thigh
11 Medial umbilical ligament
12 Obturator nerve
13 Obturator vessels
14 Posterior vaginal fornix
15 Rectouterine peritoneal pouch (Douglas)
16 Rectus abdominis
17 Round ligament of uterus
18 Superior vesical artery
19 Trigone of bladder
20 Umbilical artery (remnant)
21 Ureter
22 Uterine cavity
23 Uterine tube (Fallopian)
24 Vagina
25 Vesicouterine peritoneal pouch

Gross lymphadenopathy of the pelvis *relationship of nodal groups*

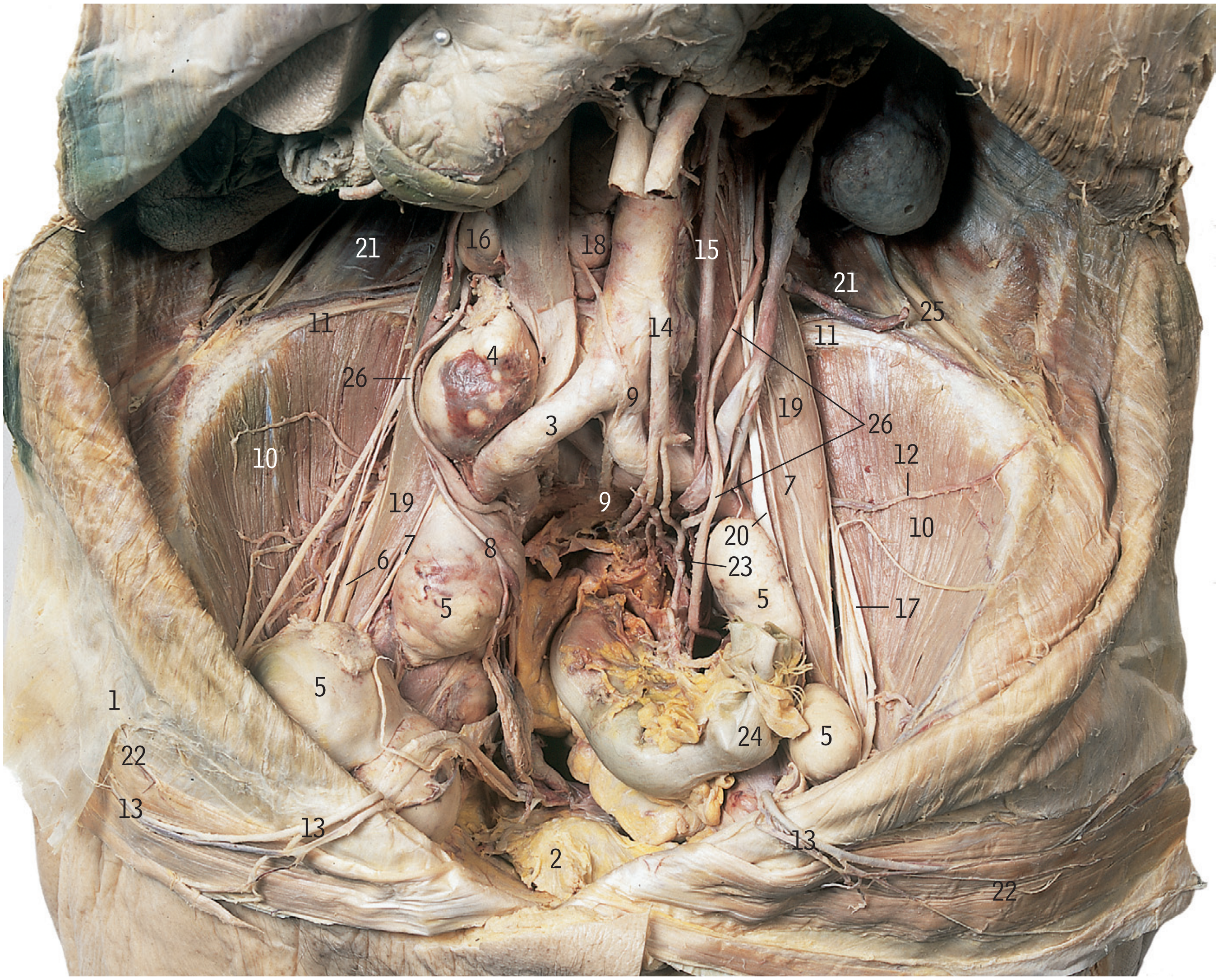

1 Arcuate line of posterior rectus sheath
2 Bladder
3 Common iliac artery
4 Common iliac node (grossly enlarged)
5 External iliac node (grossly enlarged)
6 Femoral nerve
7 Genitofemoral nerve
8 Gonadal vein
9 Hypogastric plexus, superior
10 Iliacus
11 Iliolumbar ligament
12 Iliolumbar vein
13 Inferior epigastric vessels
14 Inferior mesenteric artery
15 Inferior mesenteric vein
16 Lateral aortic (right chain) node (enlarged)
17 Lateral cutaneous nerve of thigh
18 Pre-aortic (aortocaval) node (enlarged)
19 Psoas major
20 Psoas minor
21 Quadratus lumborum
22 Rectus abdominis
23 Sigmoid branches of left colic artery
24 Sigmoid colon
25 Subcostal nerve
26 Ureter

Lymphadenopathy, lymphoma and splenomegaly, see page 369.

Lymphatics of thigh and superficial inguinal lymph nodes

A minor lymphadenopathy

LATERAL

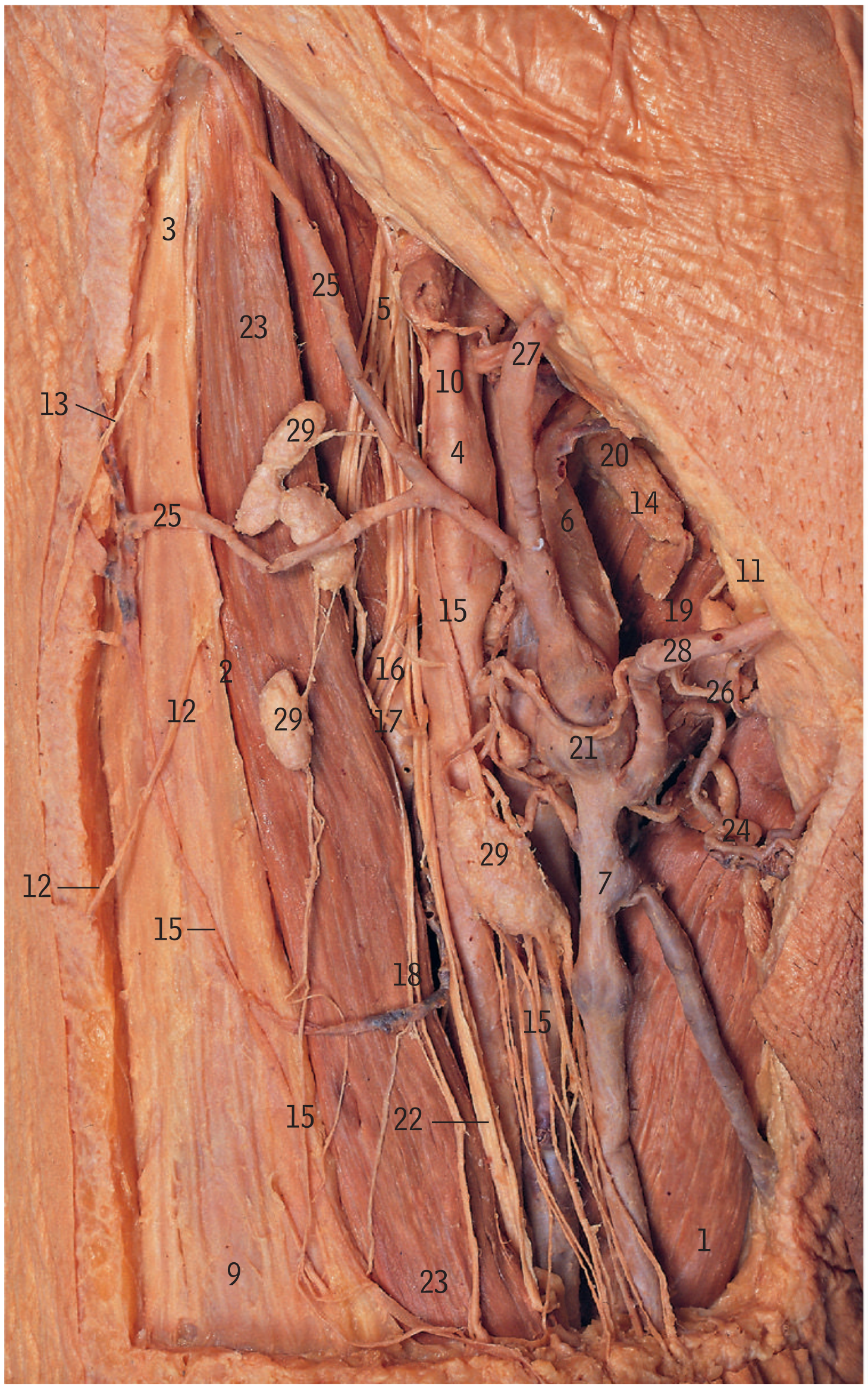

B moderate lymphadenopathy

* Marker quill is in the right anterior superior iliac spine

The boundaries of the femoral triangle are the inguinal ligament (11), the medial border of sartorius (23) and the medial border of adductor longus (1).

The femoral canal (20) is the medial compartment of the femoral sheath (removed) which contains in its middle compartment the femoral vein (6) and in the lateral compartment the femoral artery (4). The femoral nerve (5) is lateral to the sheath, not within it.

1 Adductor longus
2 Fascia lata, cut edge
3 Fascia lata overlying tensor fasciae latae
4 Femoral artery
5 Femoral nerve
6 Femoral vein
7 Great saphenous vein
8 Horizontal chain of superficial inguinal nodes
9 Iliotibial tract overlying vastus lateralis
10 Inferior epigastric vessels
11 Inguinal ligament
12 Intermediate cutaneous nerve of thigh
13 Lateral cutaneous nerve of thigh
14 Lymph node (Cloquet)
15 Lymph vessels
16 Muscular branches of femoral nerve overlying lateral circumflex femoral vessels
17 Nerve to sartorius
18 Nerve to vastus lateralis
19 Pectineus
20 Position of femoral canal
21 Saphena varix
22 Saphenous nerve
23 Sartorius
24 Scrotal veins
25 Superficial circumflex iliac vein
26 Superficial external pudendal artery
27 Superficial epigastric vein
28 Superficial external pudendal vein
29 Vertical chain of superficial inguinal lymph nodes

Milroy's disease, lymphangioma circumscriptum, lymphogranuloma venereum (LGV), elephantiasis, see page 369.

Lymphatics

Clinical thumbnails, see website for details and further clinical images to download into your own notes.

Axillary lymph node (sentinel node) dissection for breast cancer

Axillary node enlargement

Elephantiasis

Lymphadenopathy

Lymphangioma circumscriptum

Lymphangitis

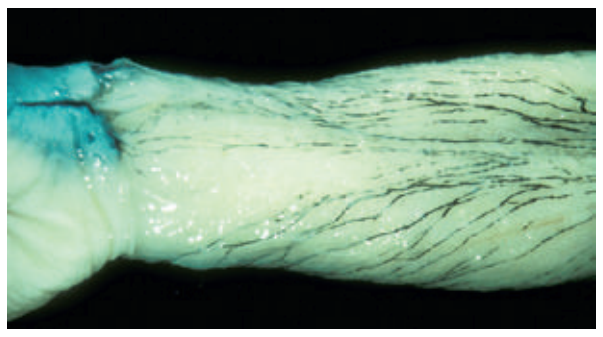
Lymphatic system – methylene blue test

Lymphoedema

Lymphogranuloma venereum (LGV)

Lymphoma and splenomegaly

Milroy's disease

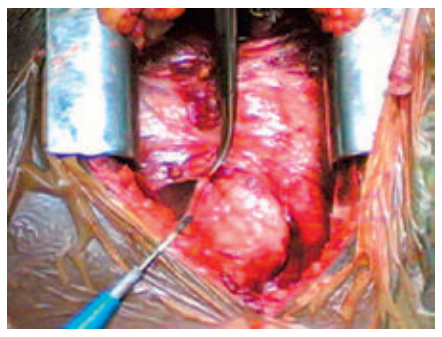
Thymus

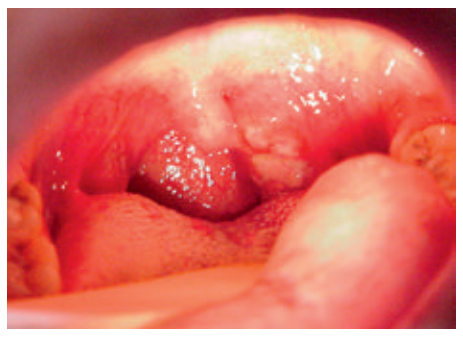
Tonsillitis

Virchow's node

This page intentionally left blank

Systemic review

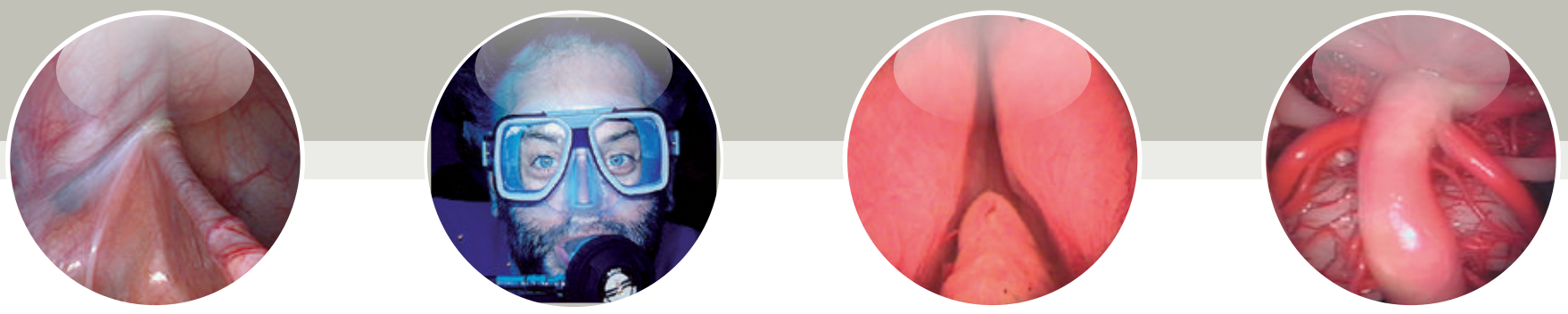

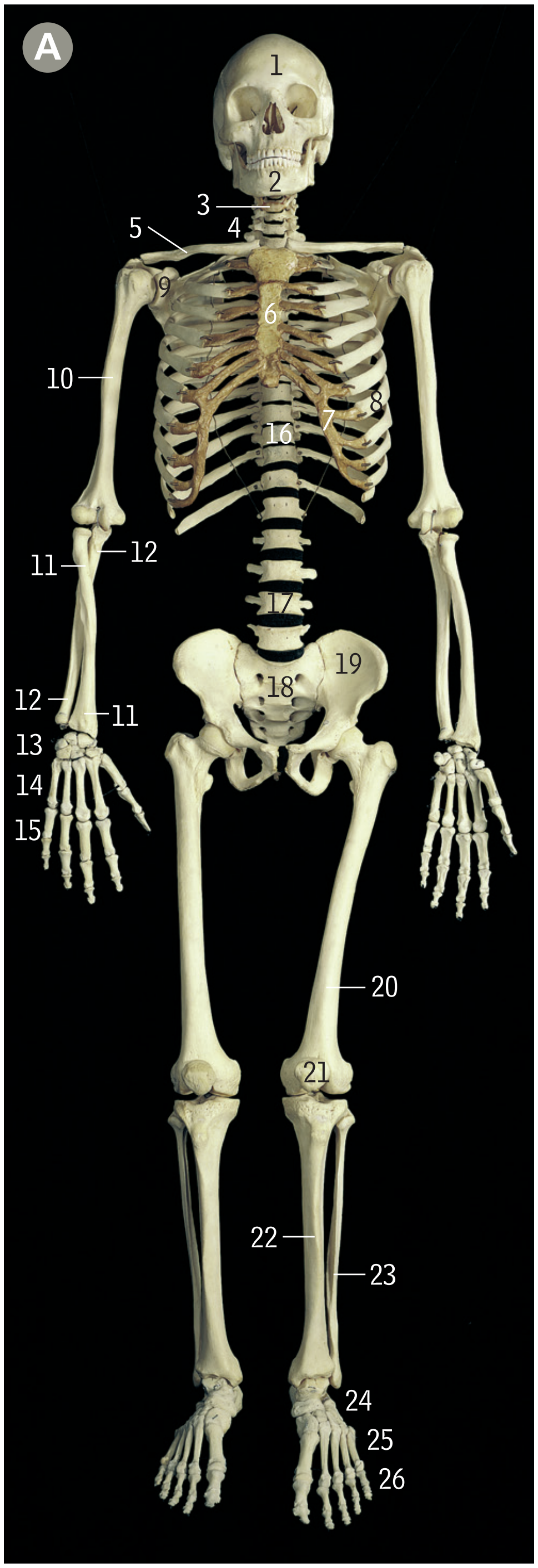

Skeleton

A *from the front*

B *from behind*

The left forearm is in the position of supination, the right in pronation in A.

1 Skull
2 Mandible
3 Hyoid bone
4 Cervical vertebrae
5 Clavicle
6 Sternum
7 Costal arch cartilages
8 Ribs
9 Scapula
10 Humerus
11 Radius
12 Ulna
13 Carpal bones
14 Metacarpal bones
15 Phalanges of thumb and fingers
16 Thoracic vertebrae
17 Lumbar vertebrae
18 Sacrum
19 Hip bone
20 Femur
21 Patella
22 Tibia
23 Fibula
24 Tarsal bones
25 Metatarsal bones
26 Phalanges of toes
27 Coccyx

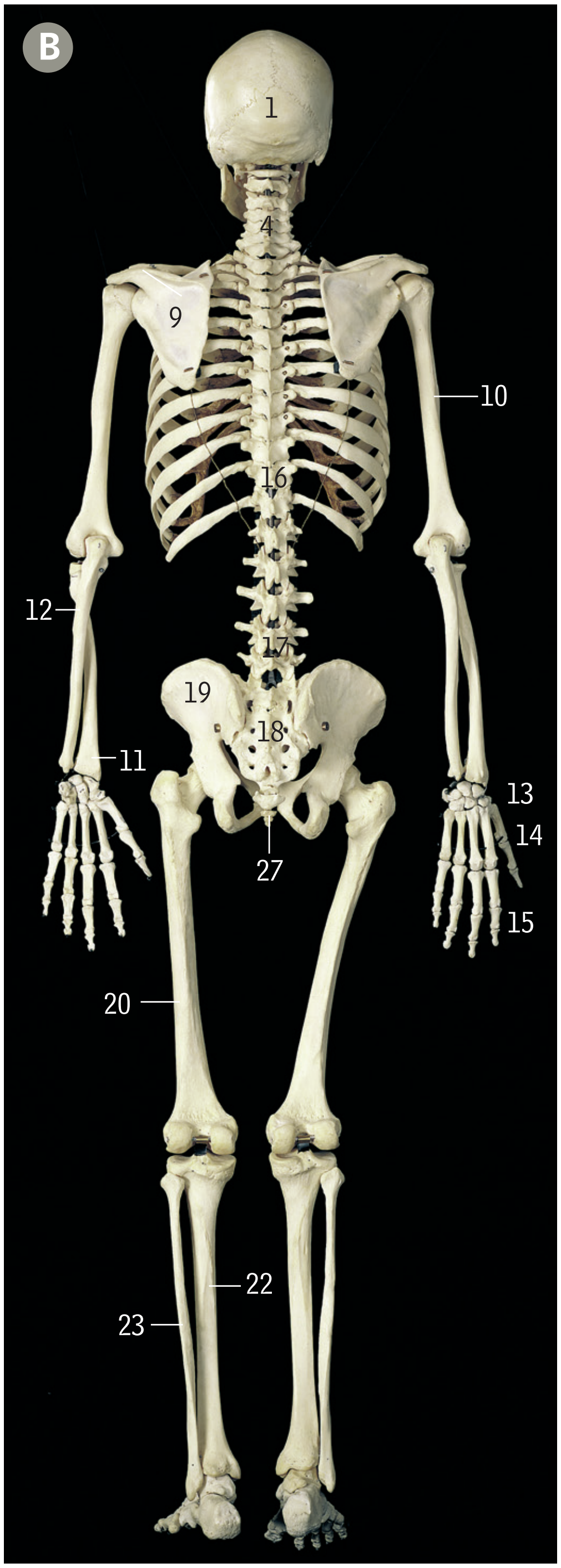

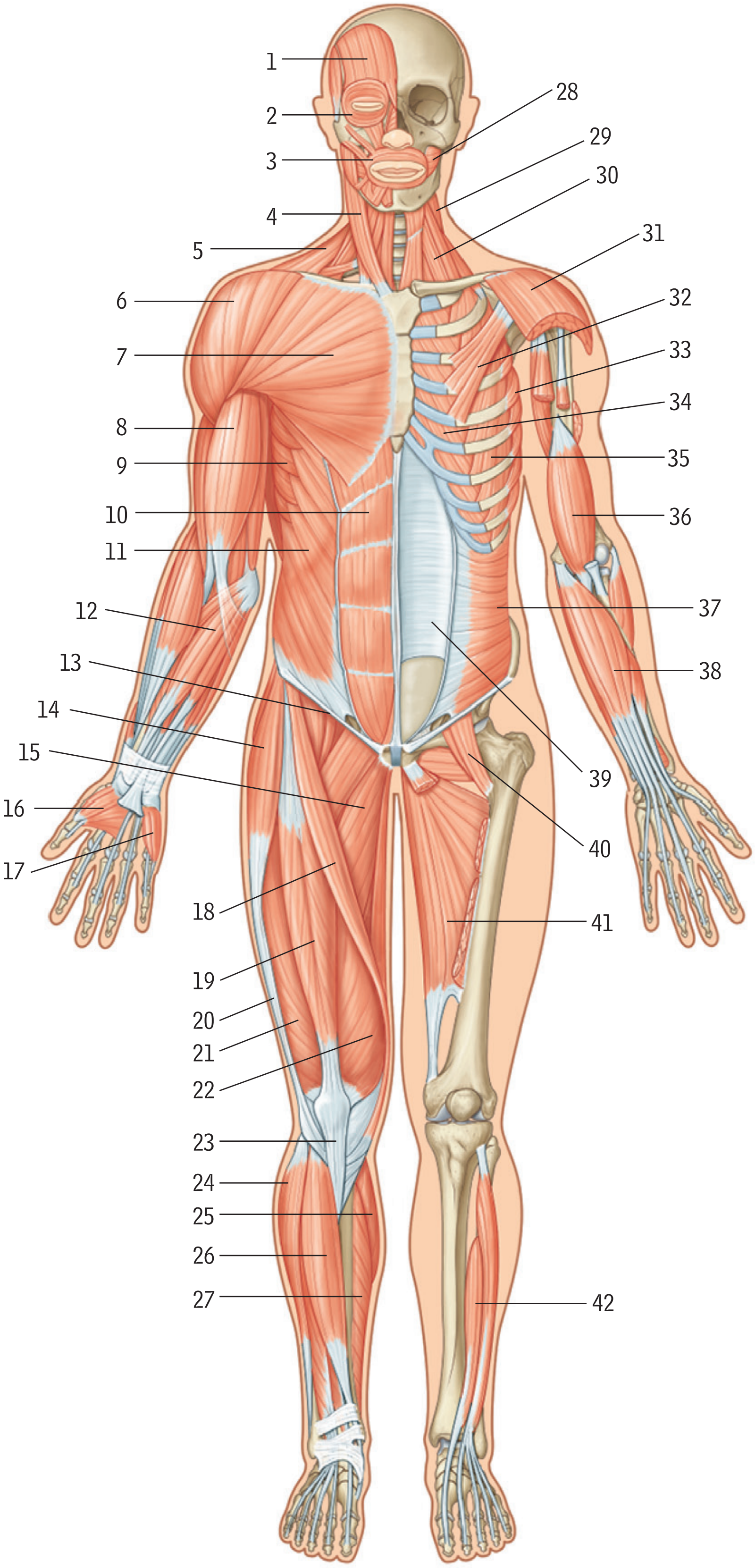

Muscles *from the front*

Superficial muscles on the right side the body, deep muscles on the left side.

1 Frontalis part of occipitofrontalis
2 Orbicularis oculi
3 Orbicularis oris
4 Sternocleidomastoid
5 Trapezius
6 Deltoid
7 Pectoralis major
8 Biceps brachii
9 Serratus anterior
10 Rectus abdominis
11 External oblique
12 Superficial flexor muscles of forearm
13 Inguinal ligament
14 Tensor fasciae latae
15 Adductor muscles of hip
16 Thenar muscles
17 Hypothenar muscles
18 Sartorius
19 Rectus femoris
20 Iliotibial tract
21 Vastus lateralis
22 Vastus medialis
23 Patellar ligament
24 Peroneal (fibular) muscles
25 Gastrocnemius
26 Extensor compartment muscles of leg
27 Soleus
28 Buccinator
29 Levator scapulae
30 Scalenus anterior
31 Deltoid
32 Pectoralis minor
33 Serratus anterior, rib insertion
34 Internal intercostal
35 External intercostal
36 Brachialis
37 Internal oblique
38 Deep flexor muscles of forearm
39 Rectus sheath (posterior wall)
40 Psoas major and iliacus
41 Adductor magnus
42 Extensor hallucis longus

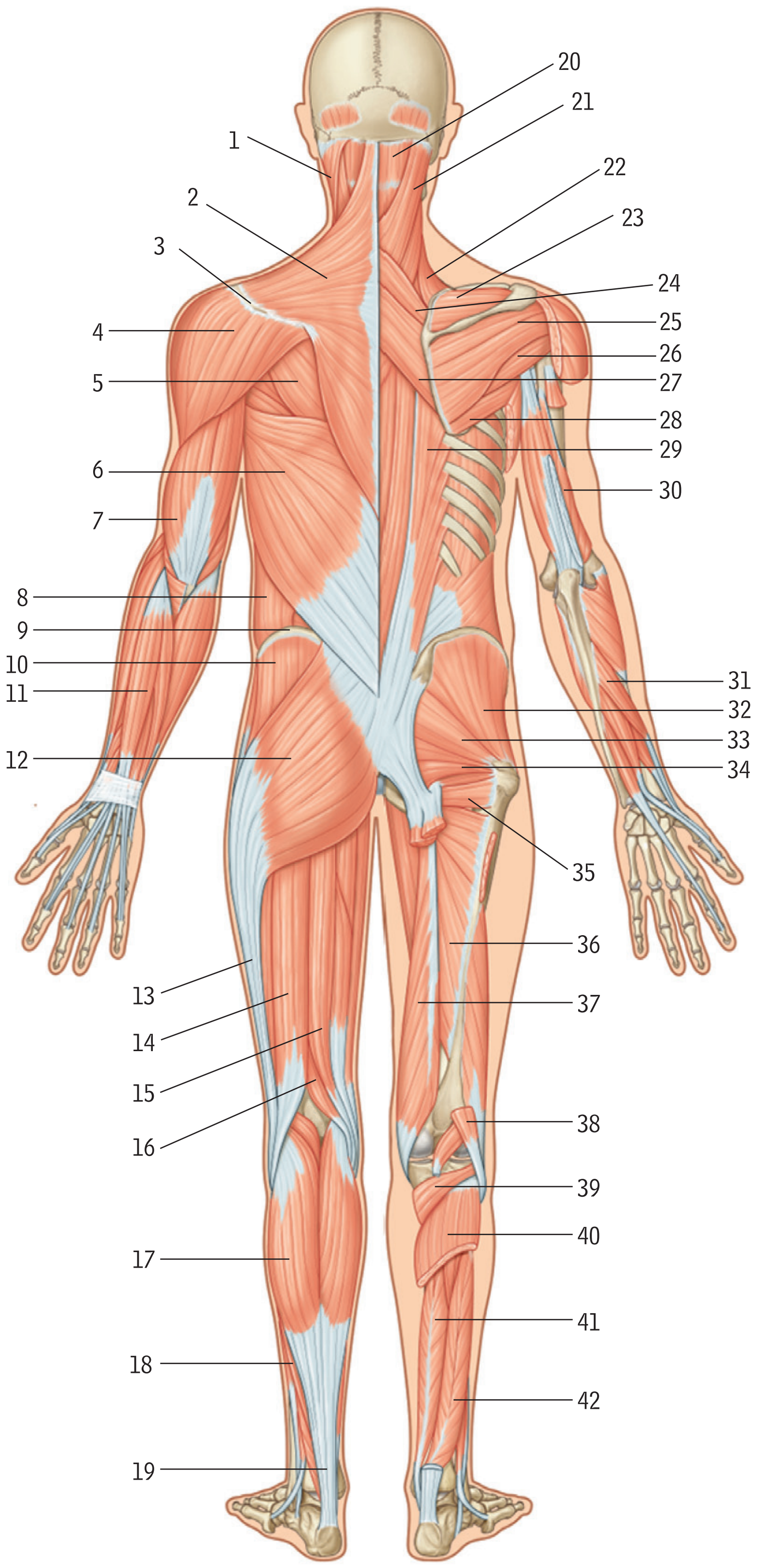

Muscles *from behind*

Superficial muscles on the left side of the body, deep muscles on the right side.

1 Sternocleidomastoid
2 Trapezius
3 Spine of scapula
4 Deltoid
5 Infraspinatus
6 Latissimus dorsi
7 Triceps
8 External oblique
9 Iliac crest
10 Gluteus medius
11 Superficial extensor muscles of forearm
12 Gluteus maximus
13 Iliotibial tract
14 Biceps femoris
15 Semimembranosus
16 Semitendinosus
17 Gastrocnemius
18 Soleus
19 Tendocalcaneus (Achilles tendon)
20 Semispinalis capitis
21 Splenius
22 Levator scapulae
23 Supraspinatus
24 Rhomboid minor
25 Infraspinatus
26 Teres minor
27 Rhomboid major
28 Teres major
29 Erector spinae
30 Triceps
31 Deep extensor muscles of forearm
32 Gluteus medius
33 Piriformis
34 Obturator internus
35 Quadratus femoris
36 Adductor magnus
37 Semimembranosus
38 Biceps femoris
39 Popliteus
40 Soleus
41 Flexor digitorum longus
42 Flexor hallucis longus

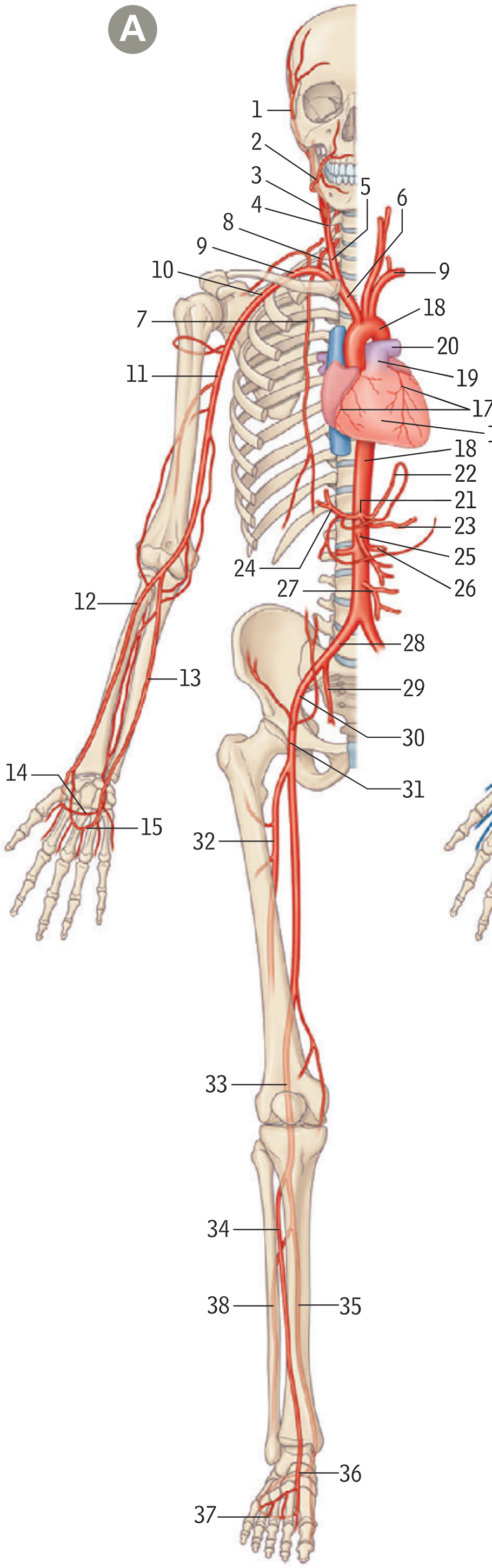

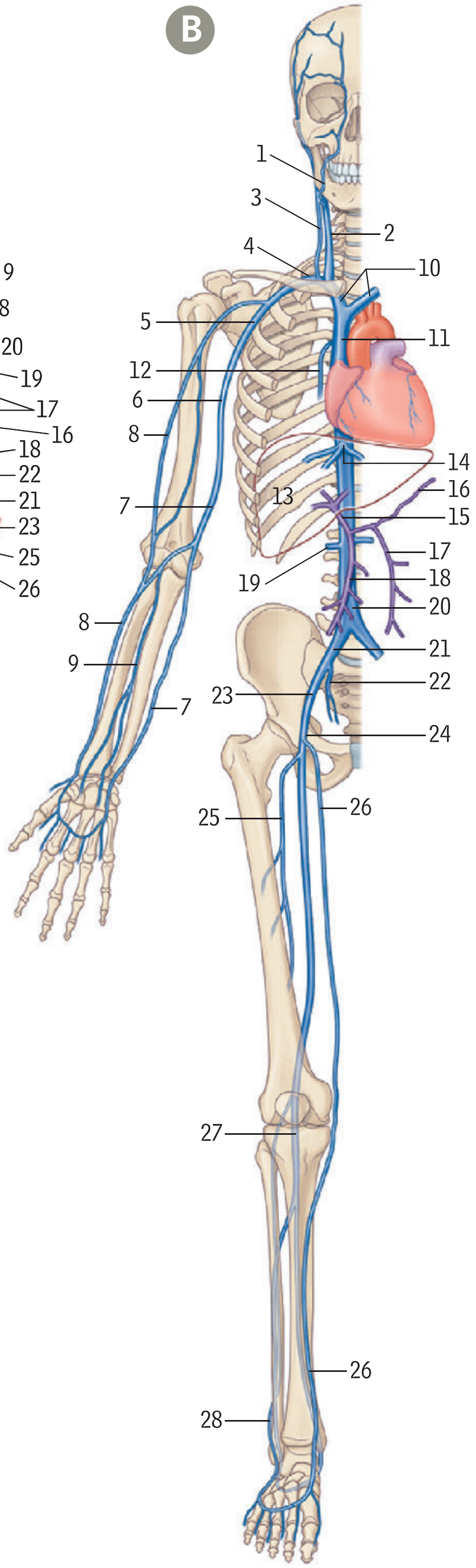

A Arteries

major arteries (a.), from the front

1. Superficial temporal a.
2. Facial a.
3. Internal carotid a.
4. External carotid a.
5. Common carotid a.
6. Brachiocephalic trunk
7. Internal thoracic a.
8. Vertebral a.
9. Subclavian a.
10. Axillary a.
11. Brachial a.
12. Radial a.
13. Ulnar a.
14. Deep palmar arch
15. Superficial palmar arch
16. Heart
17. Coronary aa.
18. Aorta
19. Pulmonary trunk
20. Pulmonary a.
21. Coeliac trunk
22. Left gastric a.
23. Splenic a.
24. Common hepatic a.
25. Superior mesenteric a.
26. Renal a.
27. Inferior mesenteric a.
28. Common iliac a.
29. Internal iliac a.
30. External iliac a.
31. Common femoral a.
32. Profunda femoris a.
33. Popliteal a.
34. Anterior tibial a.
35. Posterior tibial a.
36. Dorsalis pedis a.
37. Plantar arch
38. Peroneal (fibular) a.

B Veins

major veins (v.), from the front

(The pulmonary veins enter the left atrium at the back of the heart and are not shown.)

1. Facial v.
2. Internal jugular v.
3. External jugular v.
4. Subclavian v.
5. Axillary v.
6. Brachial v.
7. Basilic v.
8. Cephalic v.
9. Median forearm v.
10. Brachiocephalic vv.
11. Superior vena cava
12. Azygos v.
13. Liver
14. Hepatic vv.
15. Portal v.
16. Splenic v.
17. Inferior mesenteric v.
18. Superior mesenteric v.
19. Renal v.
20. Inferior vena cava
21. Common iliac v.
22. Internal iliac v.
23. External iliac v.
24. Common femoral v.
25. Profunda femoris v.
26. Great saphenous v.
27. Popliteal v.
28. Small saphenous v.

Nerves

main nerves (n.) including the facial nerve and major branches of the brachial, lumbar and sacral plexi

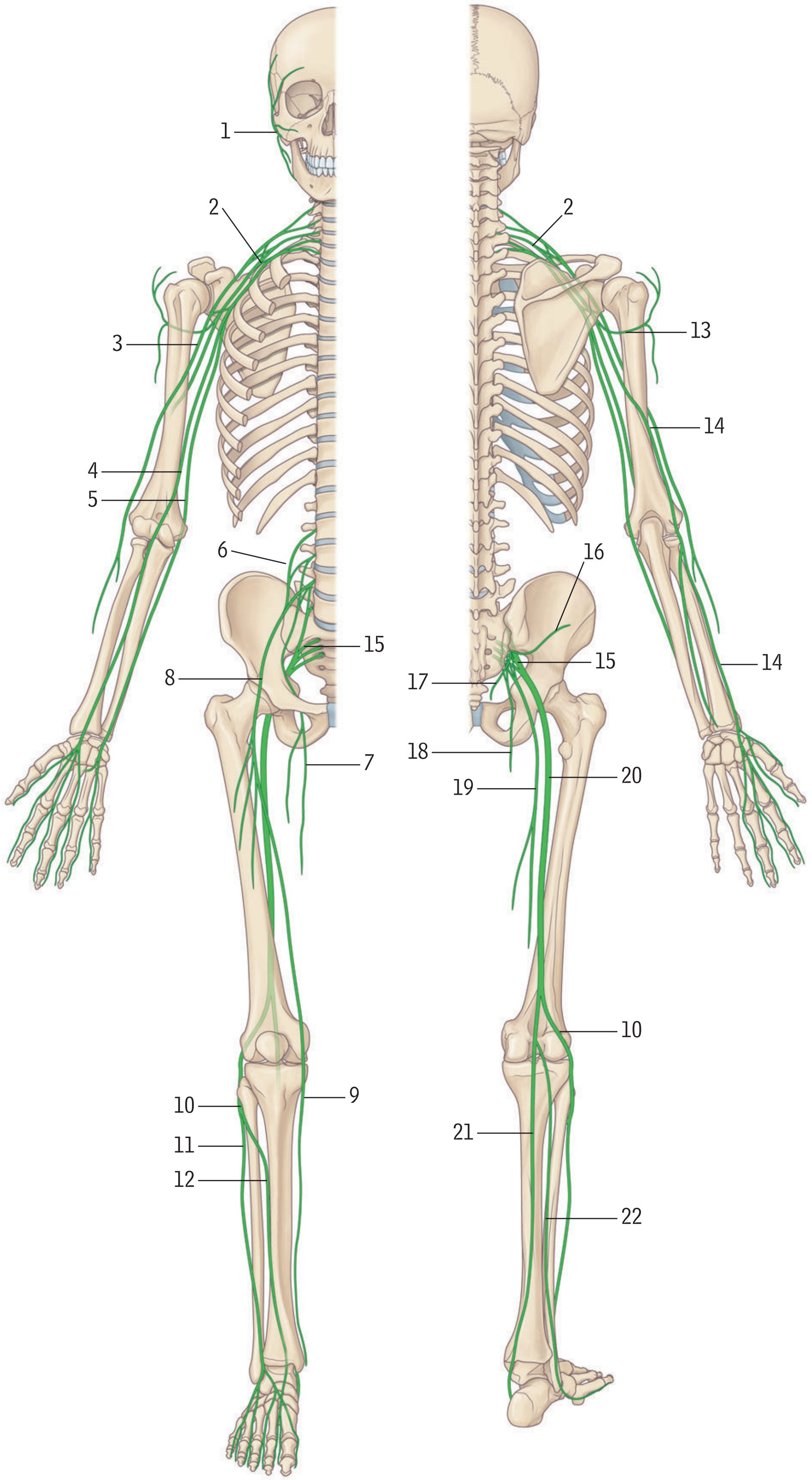

A from the front

B from the back

1 Facial n.
2 Brachial plexus (divisions)
3 Musculocutaneous n.
4 Median n.
5 Ulnar n.
6 Lumbar plexus
7 Obturator n.
8 Femoral n.
9 Saphenous n.
10 Common peroneal (fibular) n.
11 Superficial peroneal (fibular) n.
12 Deep peroneal (fibular) n.
13 Axillary n.
14 Radial n.
15 Sacral plexus
16 Superior gluteal n.
17 Inferior gluteal n.
18 Pudendal n.
19 Posterior femoral cutaneous n.
20 Sciatic n.
21 Tibial n.
22 Sural n.

Dermatomes of cranial, spinal and peripheral nerves

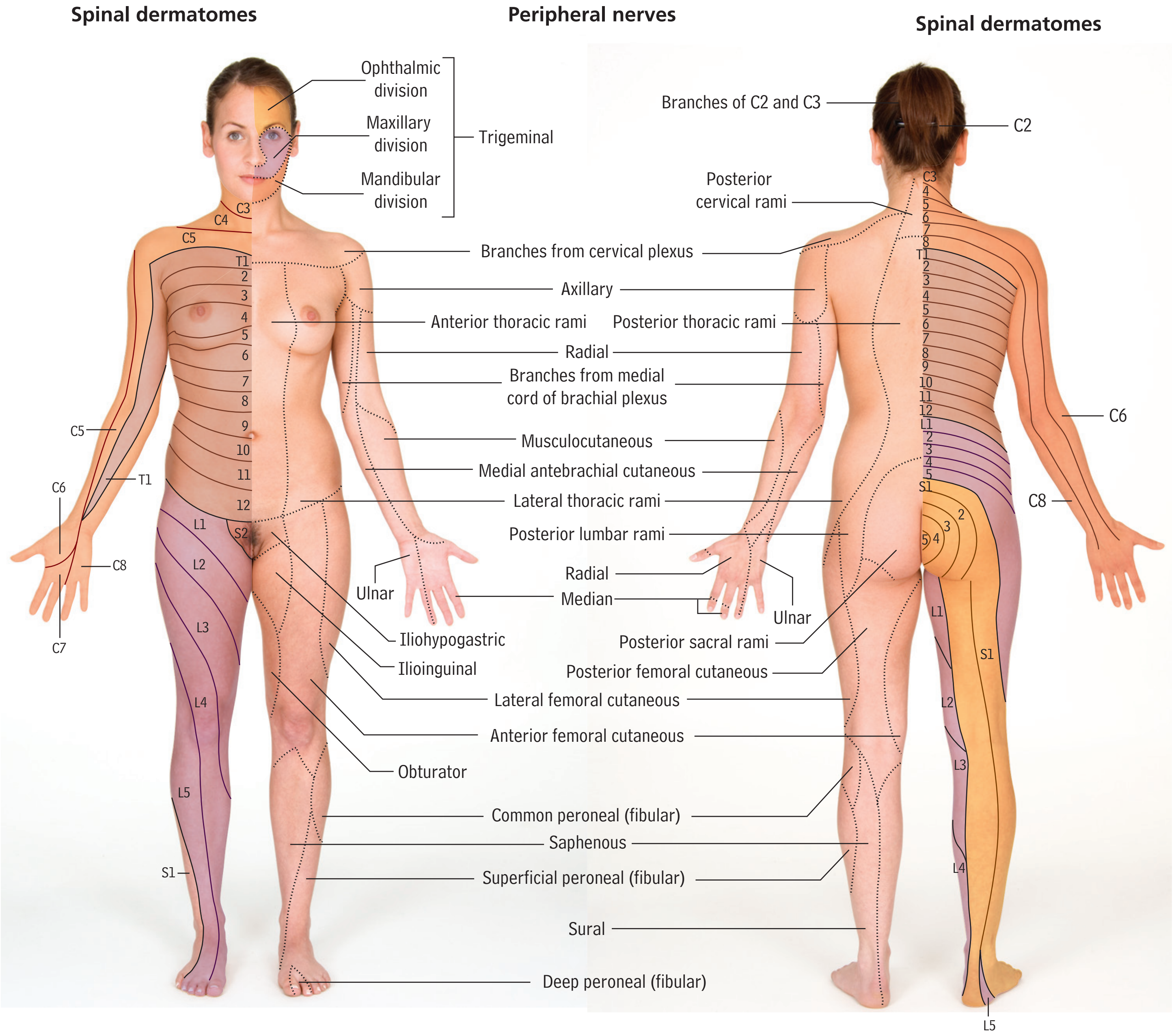

After Keegan et al. 1948 Anatomical Record 102; 409–437. There is great personal variation; see Foerster 1933 Brain 56; 1–39. Overlap of dermatomes occurs over 2–3 spinal root levels.

Cross-sections of the human body
Head and neck *cross-sections*

A **section at level of optic chiasma**

B **section at level of vocal cords**

1 Arytenoid cartilage
2 Claustrum
3 Common carotid artery
4 Ethmoidal air cells
5 Head of caudate nucleus
6 Internal capsule of cerebrum
7 Internal jugular vein
8 Lamina of vertebra
9 Lateral rectus muscle
10 Lens
11 Lentiform nucleus
12 Levator scapulae muscle
13 Ligamentum nuchae
14 Longus colli muscle
15 Medial rectus muscle
16 Nasal cavity
17 Optic canal
18 Optic chiasma
19 Optic nerve
20 Optic radiation
21 Orbital fat
22 Piriform fossa, pharynx
23 Platysma muscle
24 Scalenus anterior muscle
25 Scalenus medius and scalenus posterior
26 Semispinalis capitis muscle
27 Spinal cord
28 Spinalis muscle
29 Splenius capitis muscle
30 Sternocleidomastoid muscle
31 Superior sagittal sinus
32 Temporal lobe, cerebrum
33 Temporalis muscle
34 Thalamus
35 Thyroid cartilage
36 Thyroid gland, lateral lobe
37 Trapezius muscle
38 Vertebral artery in transverse foramen
39 Vertebral body
40 Vertebral canal
41 Vocal cord
42 Zygomatic bone

A

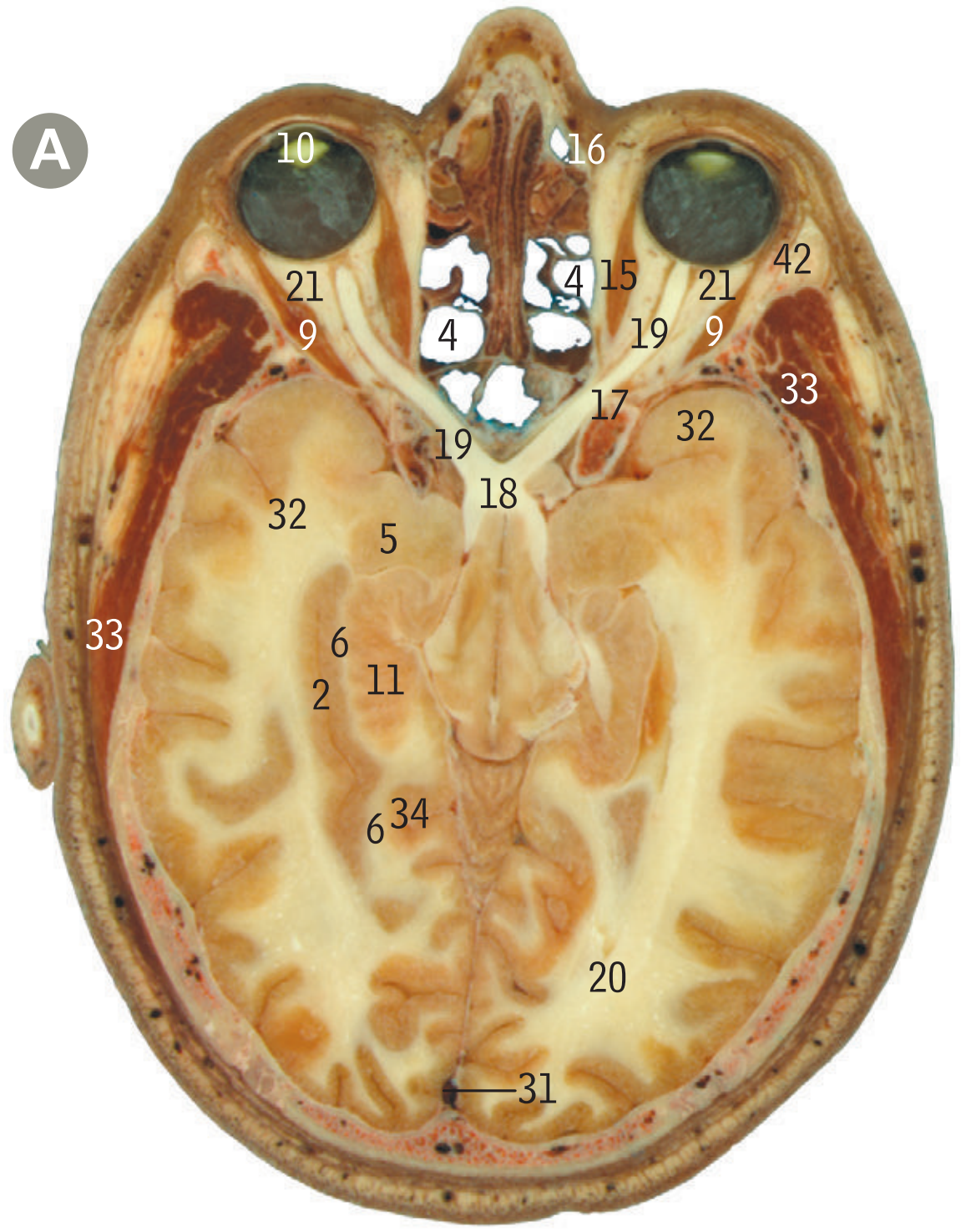

B

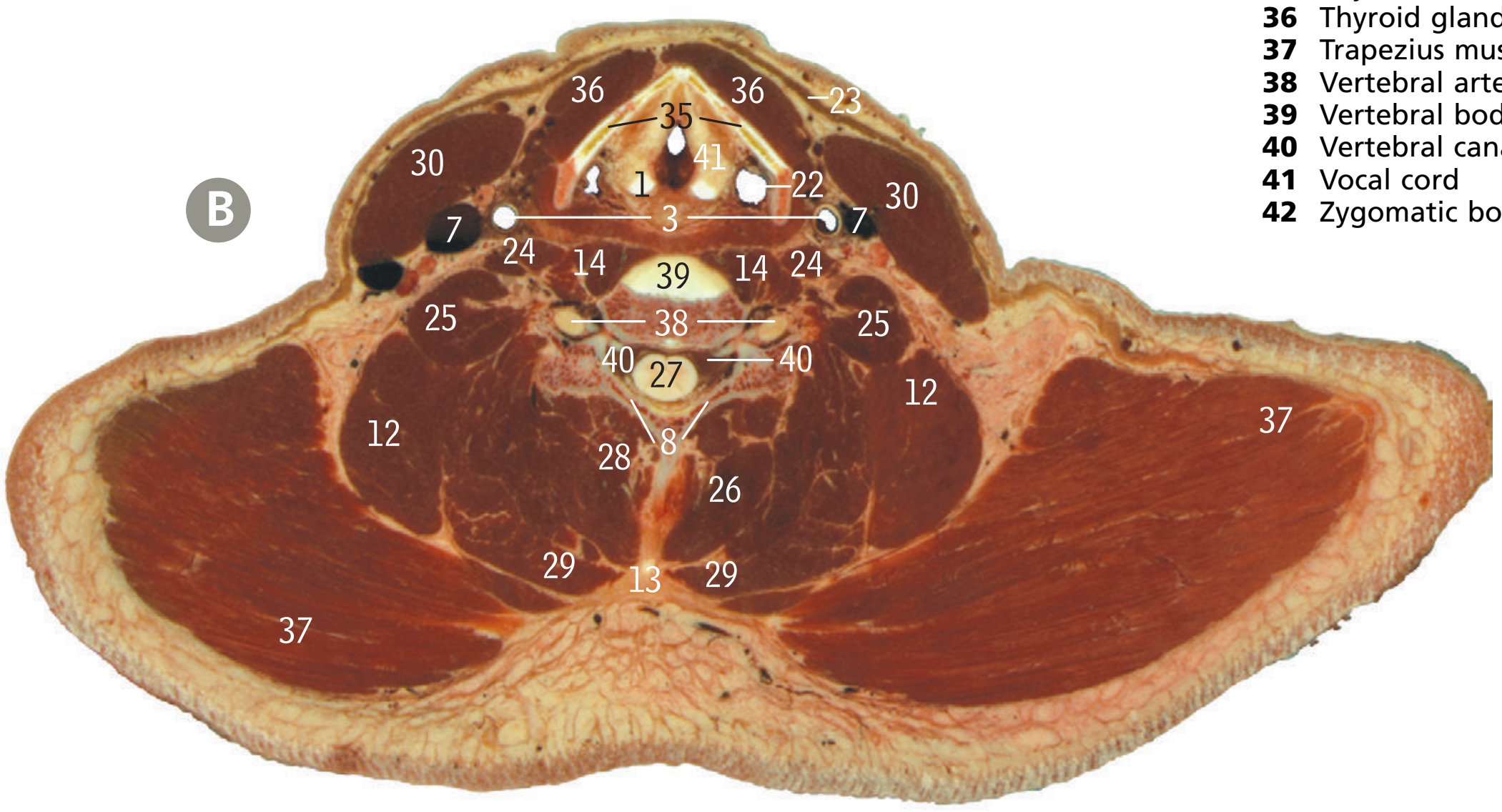

Images on **pages 7–10** **inclusive are from the National Library of Medicine (USA), Visible Human Data Set.**

Thorax *cross-sections*

C

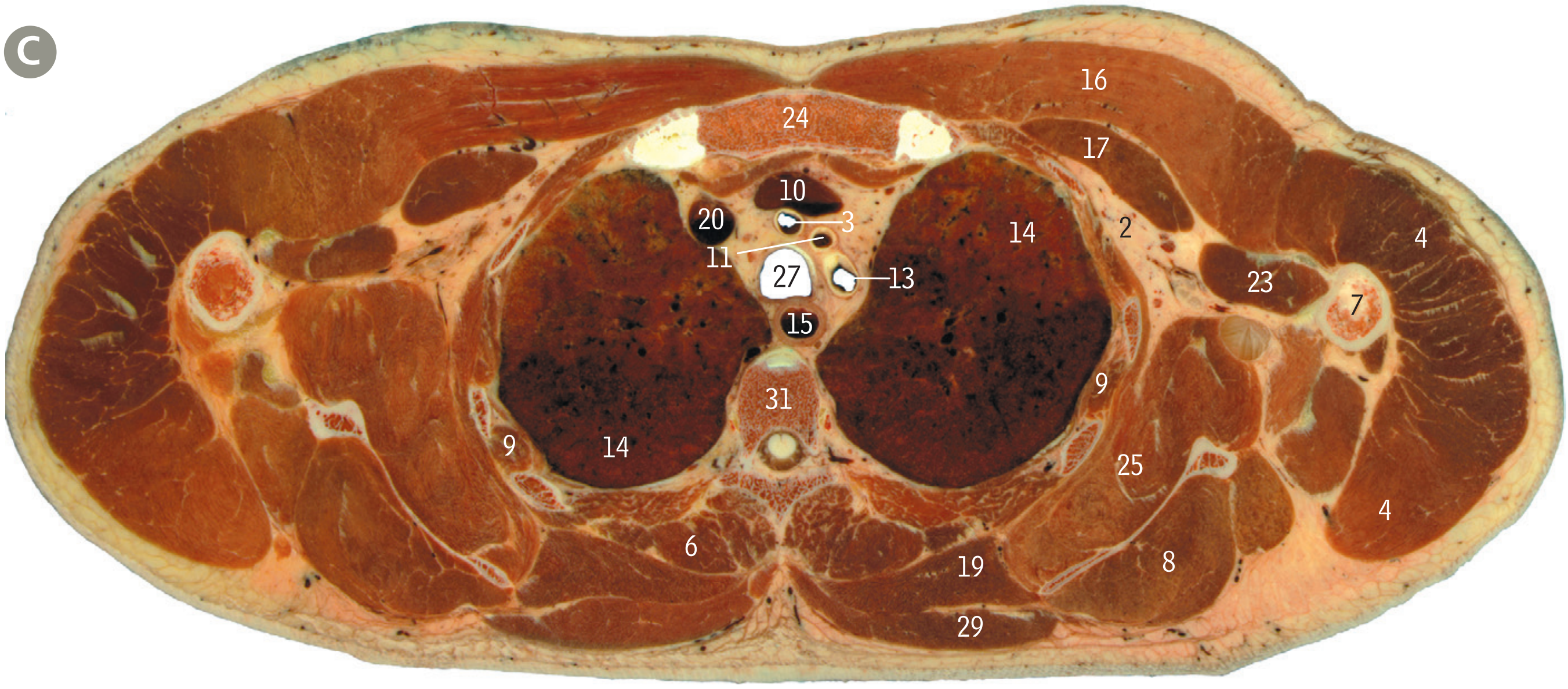

D

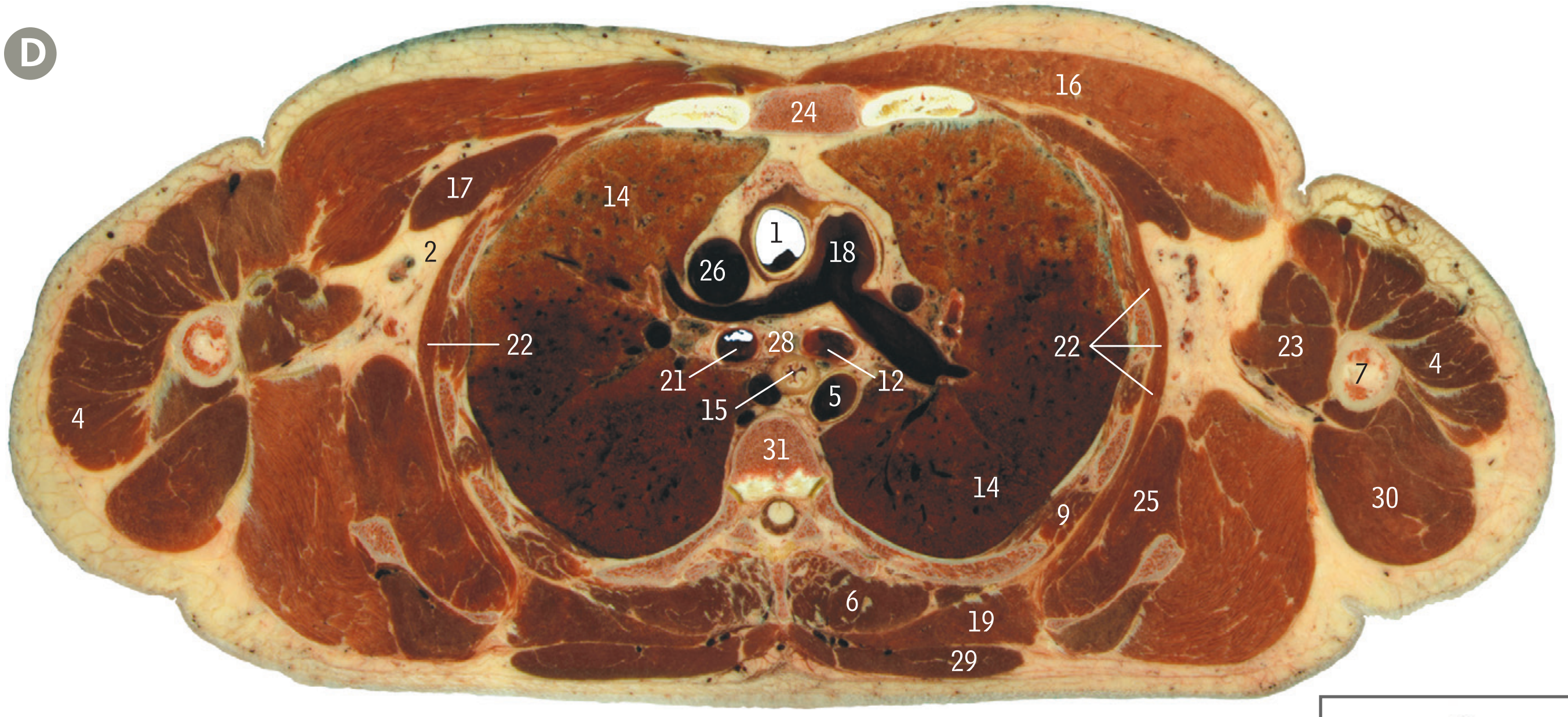

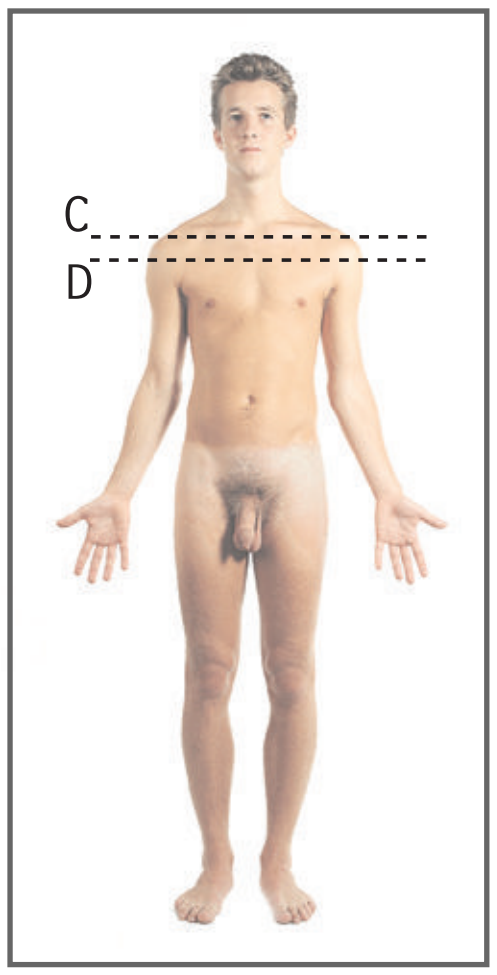

C section at T2 vertebral level

D section at T4/5 vertebral level

1 Ascending aorta
2 Axillary fat with brachial plexus
3 Brachiocephalic artery
4 Deltoid muscle
5 Descending aorta
6 Erector spinae muscle
7 Humerus
8 Infraspinatus muscle
9 Intercostal muscles
10 Left brachiocephalic vein
11 Left common carotid artery
12 Left main bronchus
13 Left subclavian artery
14 Lung
15 Oesophagus
16 Pectoralis major muscle
17 Pectoralis minor muscle
18 Pulmonary trunk
19 Rhomboid major muscle
20 Right brachiocephalic vein
21 Right main bronchus
22 Serratus anterior muscle
23 Short head of biceps brachii and coracobrachialis muscles
24 Sternal marrow
25 Subscapularis muscle
26 Superior vena cava
27 Trachea
28 Tracheobronchial lymph nodes (subcarinal nodes)
29 Trapezius muscle
30 Triceps muscle
31 Vertebral body

Abdomen *cross-sections*

E

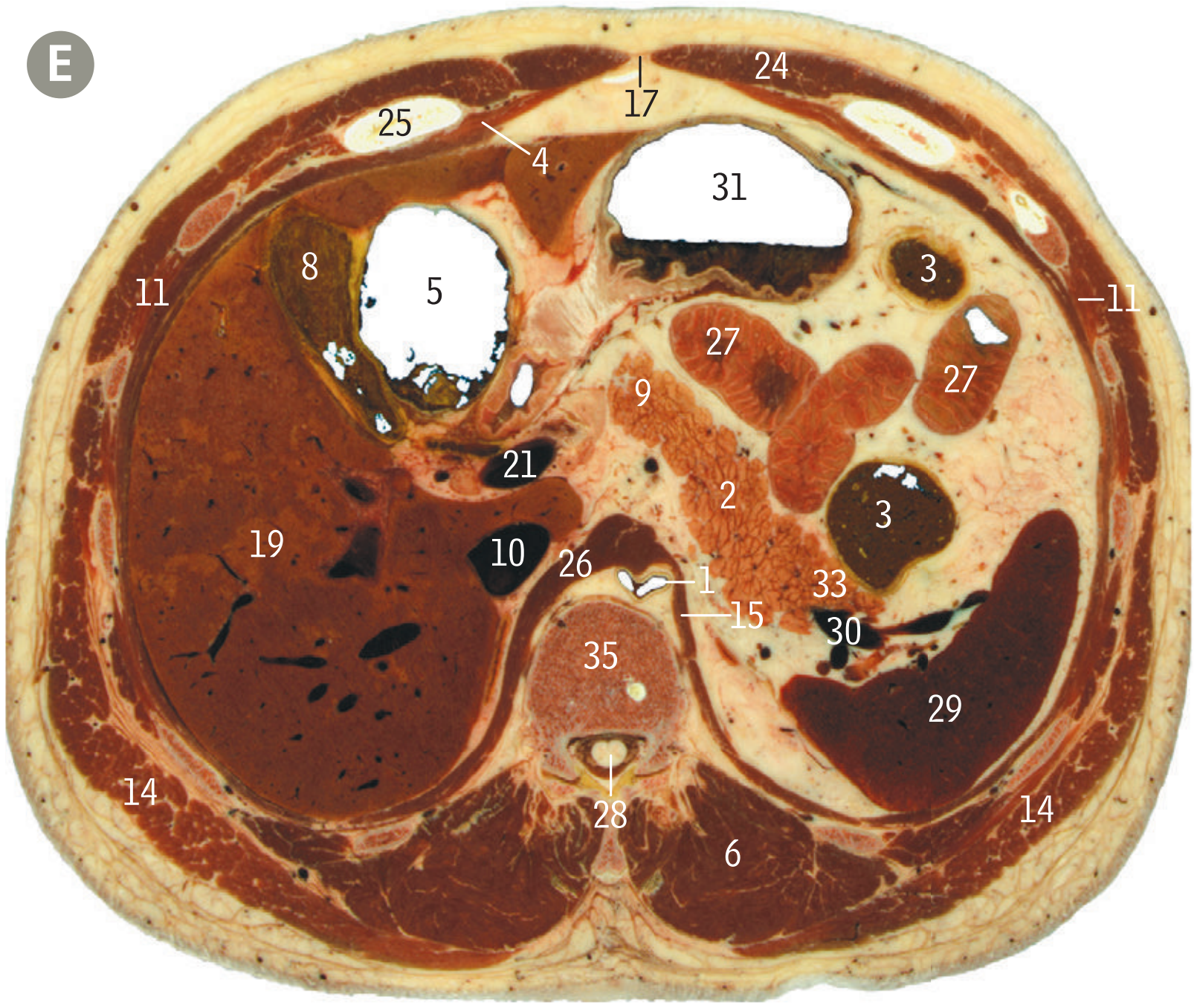

F

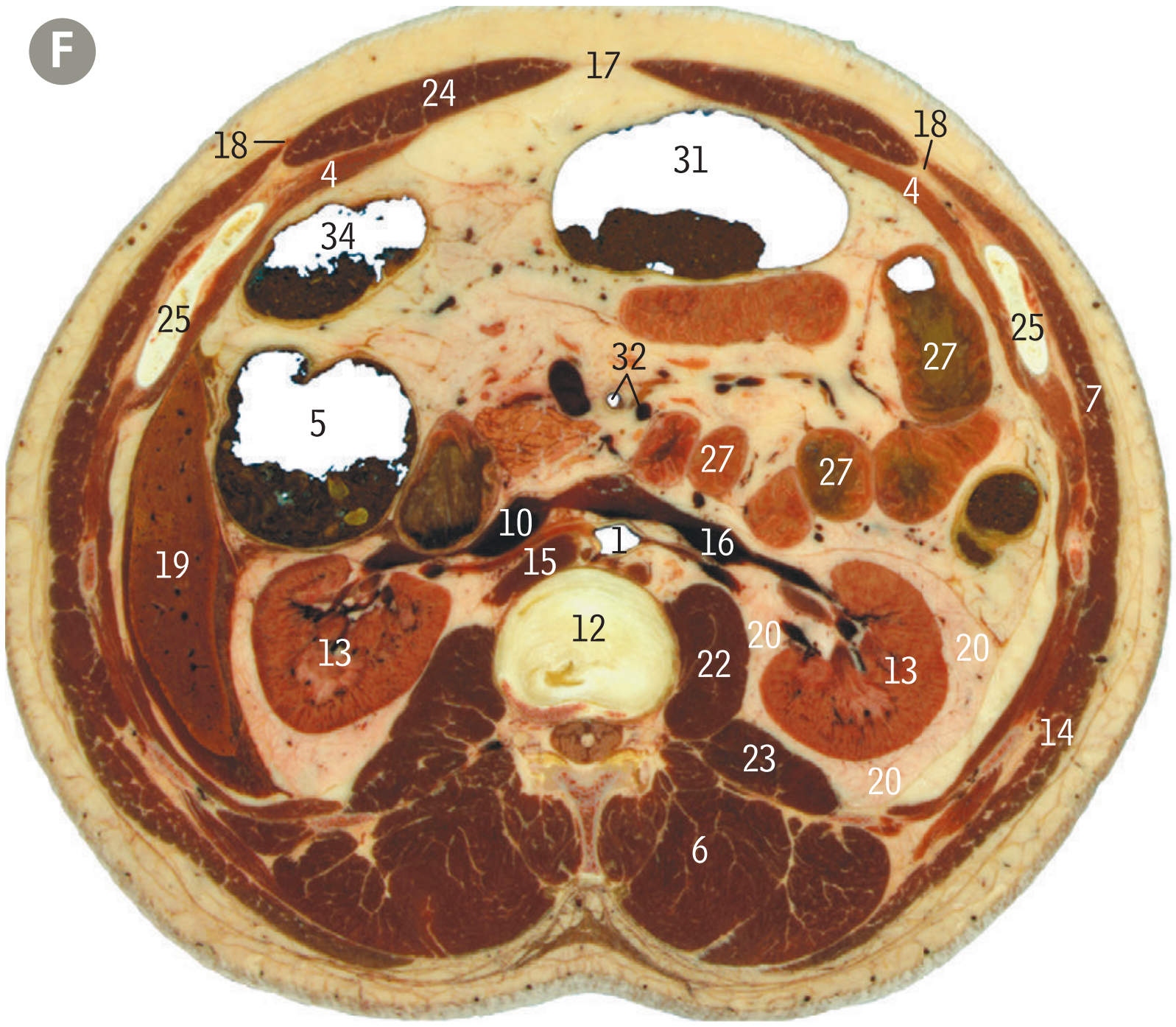

E section at L1 vertebral level

F section at L2 vertebral level

1 Aorta
2 Body of pancreas
3 Descending colon
4 Diaphragm
5 Duodenum
6 Erector spinae muscle
7 External oblique muscle
8 Gall bladder
9 Head of pancreas
10 Inferior vena cava
11 Intercostal muscle
12 Intervertebral disc
13 Kidney
14 Latissimus dorsi muscle
15 Left crus of diaphragm
16 Left renal vein
17 Linea alba
18 Linea semilunaris
19 Liver
20 Perirenal fat
21 Portal vein
22 Psoas major muscle
23 Quadratus lumborum muscle
24 Rectus abdominis muscle
25 Rib
26 Right crus of diaphragm
27 Small intestine
28 Spinal cord
29 Spleen
30 Splenic artery and vein
31 Stomach
32 Superior mesenteric vessels
33 Tail of pancreas
34 Transverse colon
35 Vertebral body

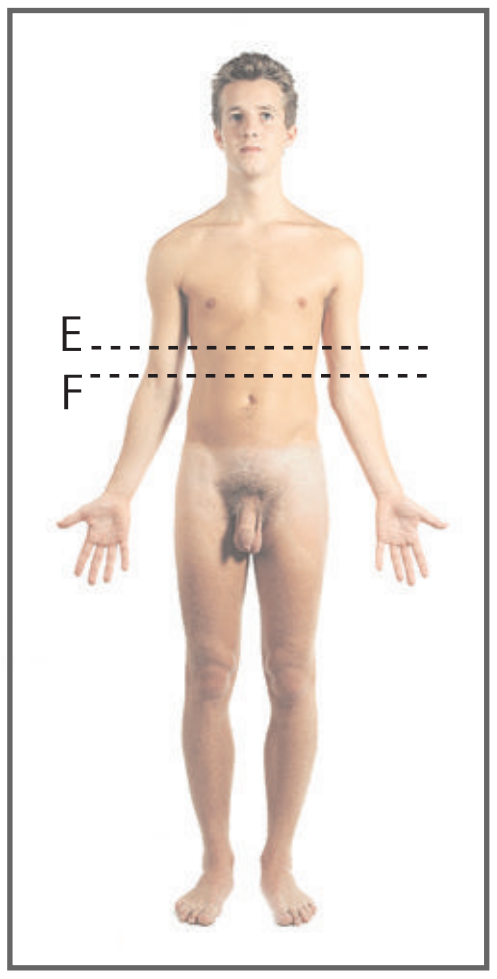

Pelvic region *cross-sections*

G

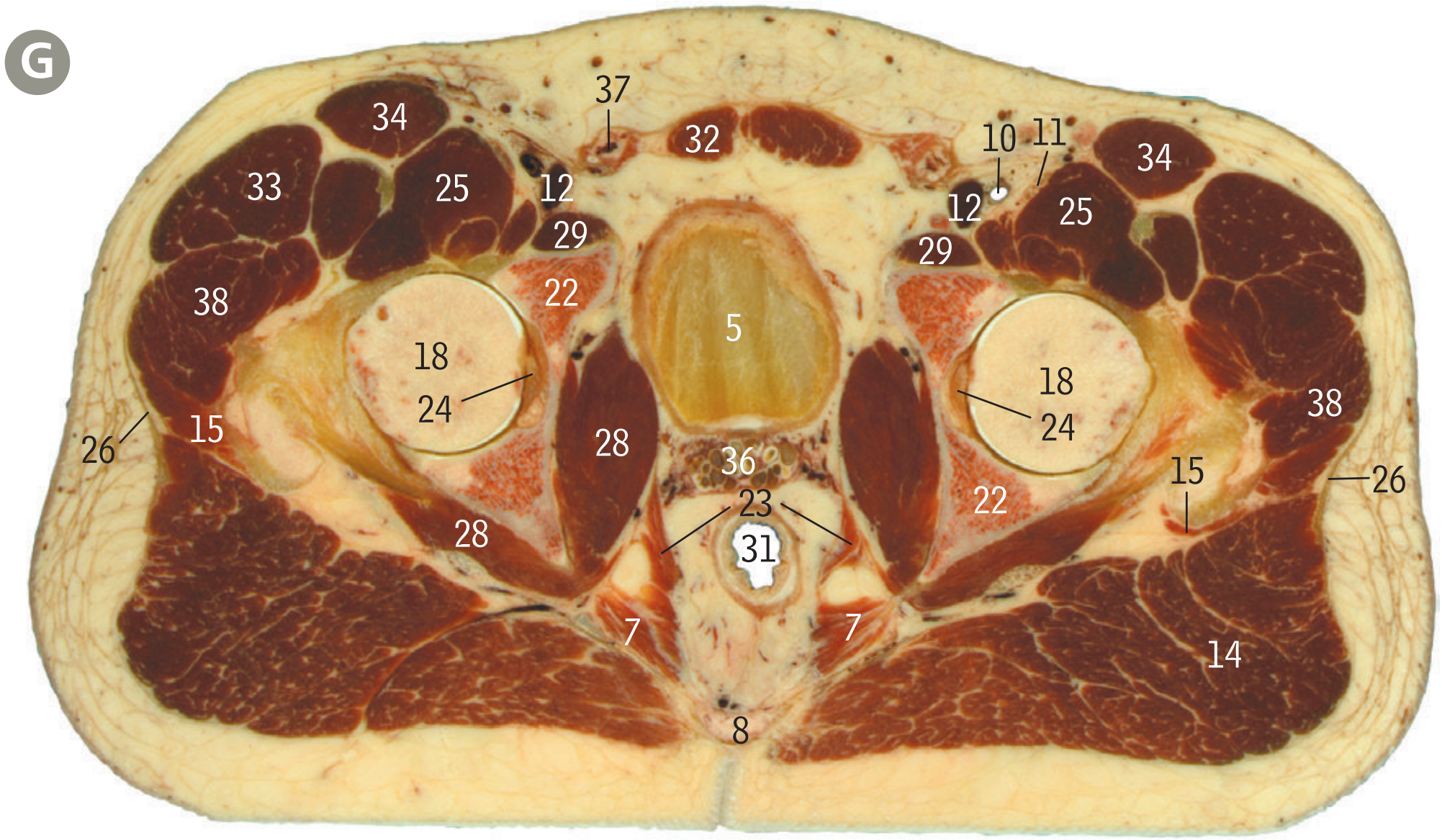

H

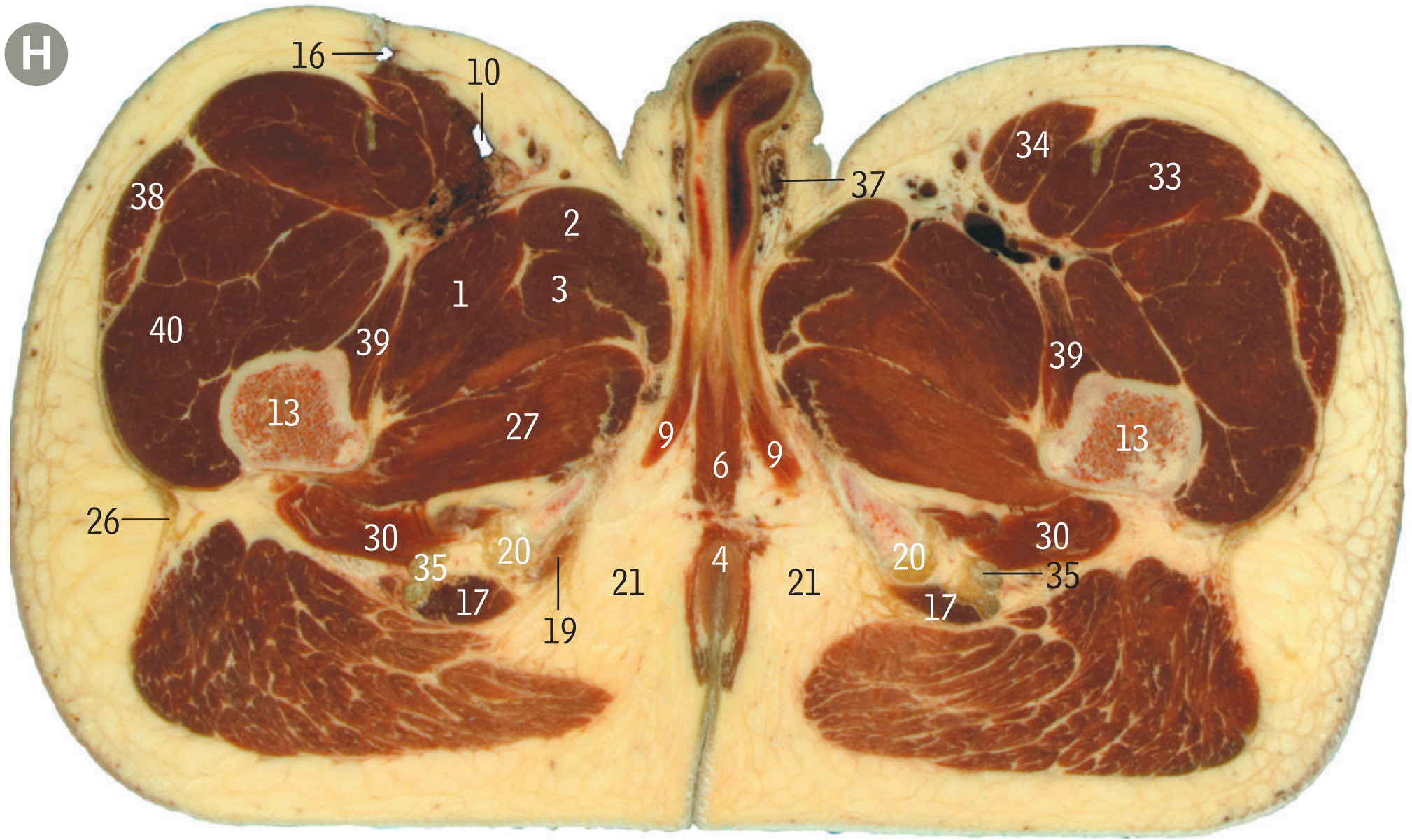

G **section at level of the hip joint in a male pelvis**

H **section at level of the upper thigh in a male pelvis**

1 Adductor brevis muscle
2 Adductor longus muscle
3 Adductor magnus muscle
4 Anal canal
5 Bladder
6 Bulb of penis
7 Coccygeus part of levator ani muscle
8 Coccyx
9 Crus of penis
10 Femoral artery
11 Femoral nerve
12 Femoral vein
13 Femur
14 Gluteus maximus muscle
15 Gluteus minimus muscle
16 Great saphenous vein
17 Hamstring origin
18 Head of femur
19 Ischiocavernosus muscle
20 Ischial tuberosity
21 Ischioanal fossa
22 Ischium
23 Levator ani muscle
24 Ligament of head of femur
25 Iliopsoas muscle
26 Iliotibial tract
27 Obturator externus muscle
28 Obturator internus muscle
29 Pectineus muscle
30 Quadratus femoris muscle
31 Rectum
32 Rectus abdominis muscle
33 Rectus femoris muscle
34 Sartorius muscle
35 Sciatic nerve
36 Seminal vesicles
37 Spermatic cord
38 Tensor fasciae latae muscle
39 Vastus intermedius muscle
40 Vastus lateralis muscle

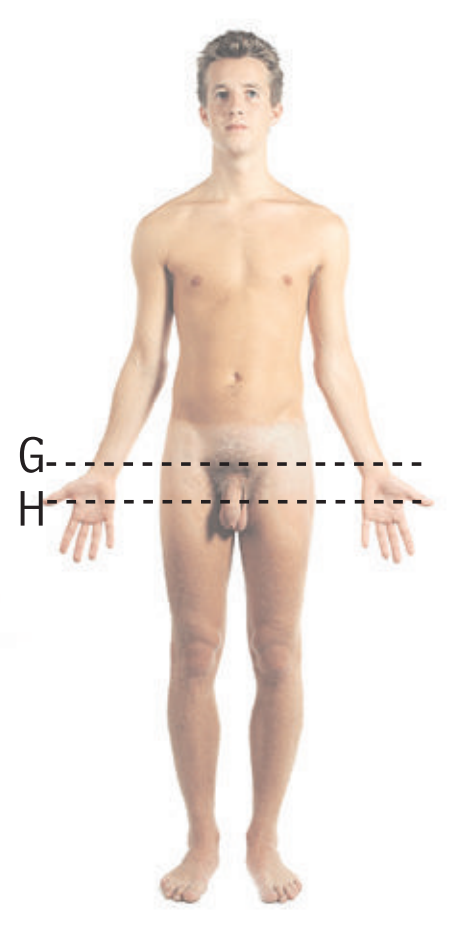

Index

Page numbers followed by "f" indicate figures, "t" indicate tables, and "b" indicate boxes. Page numbers preceded by "e" indicate online material.

A

Abdomen, 217–280
  clinical thumbnails of, 280
  cross-sections of, e9
  diaphragm of, 260
  gall bladder of, 247
  intestines of, 240, 250–252
  kidneys and suprarenal glands of, 253–259
  liver of, 244–246, 248
  lymph nodes of, 179
  peritoneal folds of, 226
  regions of, 217
  spleen of, 249–250
  thigh and lower, 320
  upper, 227–243
  vasculature variations in, 280f
  viscera of, 227–229, 231, 244f
Abdominal wall
  anterior, 217–224
  posterior, 260–262, 365
Abducent nerve (VI), 67, 74, 77
  brain and, 64–65, 68
  cranial cavity and, 51, 53
  orbit and, 55–57
  palsy of, 80f
Abduction, finger/thumb, 155–156
Abductor digiti minimi
  foot and, 311, 345, 349–350
  hand and, 124, 157–159
Abductor hallucis, 345, 348–349, 354
  attachments for, 311
  plantar view of, 350–351
Abductor pollicis brevis, 157–159
  attachments for, 124
  surface marking of, 154
Abductor pollicis longus, 154, 159–161
  attachments for, 121, 124
  forearm and, 150, 152–153
  tendon of, 159
Abortion, unsafe, 283f
Accessory basilic vein, 148
Accessory nerve (XI), 44, 65, 78–79
  cranial root of, 67, 69, 79
  neck and, 29–32
  palsy of, 80f
  spinal root of. *See* Spinal accessory nerve.
  surface marking of, 28
Accessory ossicles, 170f
Accommodation reflex, 80f
Acetabular fossa, 325
Acetabular labrum, 325–326
Acetabular notch, 286, 292
Acetabulum, 92, 286, 292, 326
Achilles tendon. *See* Tendocalcaneus.
Acoustic neuroma, 80f
Acromial angle, 110
Acromioclavicular joint, 112, 128, 136–137
  separation of, 170f
  surface marking of, 126, 130, 178
Acromion, 110, 112, 128
  shoulder and, 131–134
  surface marking of, 126, 130
Adam's apple. *See* Laryngeal prominence.
Adduction, finger/thumb, 155–156
Adductor brevis, 263, 322, 325
  attachments for, 287, 293, 297–298
  cross-section of, e10
Adductor hallucis, 311, 351–352
Adductor longus, 263–264, 321–322
  attachments for, 287, 293, 298
  cross-section of, e10
Adductor magnus, 323, e2–e3
  attachments for, 287, 293, 297
  cross-section of, e10
  nerve to, 319
Adductor minimus, 319
Adductor pollicis, 124, 154, 157, 159
Adenoids, 52, 80f
Adrenal glands. *See* Suprarenal glands.
Ala, 25–26, 38
Alar groove, 38
Alar ligament, 85, 94
Ampulla (Vater), 247
Anal canal, 266, 268, e10
Anatomical snuffbox, 121–122, 154, 164
Anconeus, 117, 121, 133, 145
Angina pectoris, 215f
Angiogram. *See* Arteriogram.
Angle of Louis, 176–177, 181, 183
Ankle, 341, 344–349
  arthroscopy of, 355f
  bones of, 312–313
  cross-section of, 347
  fractures of, 356f
  imaging of, 347, 354
  ligaments of, 349
  sprained, 356f
  superficial veins and nerves of, 340
  surface features of, 344
  tibiotalar part of, 349
  ulceration of, 355f
Ankle block, 355f
Ankle jerk, 355f
Ankylosing spondylitis, 108f
Annular ligament, 146–147, 152
Annulus fibrosus, 99, 266
Anococcygeal body, 276, 278–279
Anorectal abscesses, 280f
Anosmia, 80f
Ansa cervicalis, 29, 31
Ansa subclavia, 37, 195, 362
Anterior cardiac vein, 185
Anterior cerebral artery, 51–52, 54, 65
Anterior choroidal artery, 68, 72
Anterior circumflex humeral artery, 129
Anterior clinoid process, 11, 25, 51
Anterior commissure, 66
Anterior communicating artery, 54, 68
Anterior cranial fossa, 11, 51, 74
Anterior cruciate ligament, 332–335
  arthroscopic view of, 335
  attachments for, 301, 305
  rupture of, 356f
Anterior cutaneous nerves, 218–220
Anterior ethmoidal artery, 54–56
Anterior ethmoidal canal, 20
Anterior ethmoidal foramen, 12
Anterior ethmoidal groove, 11, 26
Anterior ethmoidal nerve, 54–56, 75
Anterior femoral cutaneous nerve, e6
Anterior fontanelle, 2, 8, 15
Anterior gluteal line, 286
Anterior inferior cerebellar artery, 65, 68
Anterior inferior iliac spine
  hip bone and, 286, 288, 290, 292
  pelvis and, 92, 271
Anterior intercostal membranes, 181
Anterior interosseous artery, 149, 151, 166
Anterior interosseous nerve, 151
Anterior interosseous nerve entrapment, 170f
Anterior jugular vein, 28, 32–33, 43
Anterior lacrimal crest, 4, 12, 21
Anterior lateral malleolar artery, 347
Anterior ligament of fibular head, 337
Anterior longitudinal ligament, 36, 94, 98, 195
Anterior meniscofemoral ligament, 332
Anterior nasal spine, 1, 4, 21
Anterior perforated substance, 64–65
Anterior spinal artery, 68, 212
Anterior superior iliac spine, 221
  hip bone and, 286, 288, 290, 292
  pelvis and, 92, 271
Anterior talofibular ligament, 309, 349
Anterior tibial artery, 331, 337, 343, e4
Anterior tibial recurrent artery, 337
Anterior tibial vessels, 347
Anterior ulnar recurrent artery/vein, 151
Anterior (left) vagal trunk, 241, 257, 365
Antihelix, 60
Antitragus, 60
Anus
  carcinoma of, 280f
  imperforate, 281f
  margin of, 276–279
Aorta, 212, 256, e4, e9
  abdominal, 239, 250
    aneurysm of, 280f
    kidney and, 254, 257–258
  arch of, 212, 214, 362
    lungs and, 202–203
    mediastinum and, 194–196, 207
  ascending, 185–186, 190, e8
    coronary arteries and, 191
    heart and, 187–189, 191
  bifurcation of, 221
  bruits in, 280f
  coarctation of, 215f
  diaphragm and, 260
  groove for, 204
  thoracic (descending), 183, 203, 212–213
    aneurysm of, 216f
    cross-section of, e8
    mediastinum and, 194–196
Aortic dissection, 215f
Aortic plexus, 258, 261
Aortic sinus, 191
Aortic valve, 178, 188–189
Aorto-renal ganglion, 242
Apical nodes, 179, 363
Aponeurosis, palmar, 157
Appendices epiploicae, 227–229, 232
Appendicitis, 280f
Appendicular artery, 238, 251
Appendix, 232, 238, 251
Appendix epididymis, 265
Aqueduct of midbrain, 64, 66, 72
Arachnoid granulations, 8, 52–53, 62
Arachnoid mater
  cerebral, 62–64
  spinal, 69, 94, 96
Arcuate artery, 348
Arcuate eminence, 11, 23
Arcuate line, 92, 222, 288, 290
Arcus tendineus, 264

Areola of breast, 126, 178–179
Areolar glands of breast, 178
Arm (upper), 109, 143–144
  cross-section of, 143
  shoulder and, 133
  vessels and nerves of, 143
Arterial circle (Willis), 68
Arterial puncture, 170f
Arteries, e4. *See also specific artery.*
Arteriogram
  of arterial circle (Willis), 68
  carotid, 66
  coronary, 190, 215f
  femoral, 319
  of palmar arteries, 161
  popliteal, 343
  pulmonary, 203
Arteriovenous fistulae, 80f, 170f
Arthrogram
  shoulder, 136
  wrist, 167
Arthroscopy
  ankle, 355f
  elbow, 147, 170f
  hip, 327
  knee, 334–336
  shoulder, 129, 137
  wrist, 172f
Articular disc
  of elbow joint, 120
  of wrist joint, 167–168
Articular tubercle, 7, 9, 23
Articularis genu, 301, 335
Aryepiglottic fold, 49–50
Aryepiglottic muscle, 49
Arytenoid cartilages, 48, 50, e7
Ascending cervical artery, 36–37, 206, 361
Ascending cervical vein, 36, 361
Ascending colon, 226, 250–251
  radiograph of, 240
  upper abdomen and, 227–229, 238
Ascending palatine artery, 29, 35
Ascending pharyngeal artery, 34–36, 45
Ascites, 280f
Atlanto-axial instability, 108f
Atlanto-axial joint, 94–95, 106–107
Atlanto-occipital joint, 10, 69, 94
Atlas, 83, 85, 94–95
  anterior arch of, 52, 58, 85
  ossification of, 93
  posterior arch of, 52, 85, 95–96
  radiographs of, 106
Atria of heart. *See* Left atrium; Right atrium.
Atrioventricular bundle, 187
Atrioventricular groove, 185–186, 191
Atrioventricular nodal artery, 190–191
Atrioventricular node, 187
Auditory tube, 52, 58, 60–61
Auriculotemporal nerve, 59, 75–76
  face and, 39–40, 42
  neck and, 29
  surface marking of, 38, 60
Auriscopy, 60
Auscultation
  of brachial pulse, 170f
  of heart sounds, 178, 215f
  triangle of, 101–102, 131
Avascular necrosis, 122, 170f, 355f
Avulsion fractures, 355f
Avulsion of medial epicondyle, 170f
Axial skeleton, 83, 173
Axilla, 138–142, 207
  lymphadenopathy of, 363
  surface marking of, 180
Axillary artery, 136, 138, 141, e4
  aneurysm of, 170f
  mediastinum and, 196, 207
Axillary fat, 363, e8
Axillary lymph nodes, 179, 359, 363–364
  dissection of, 369f
  enlarged, 129, 369f
Axillary nerve, 130, 133, e5–e6
  axilla and, 139–142
  shoulder and, 136, 144
Axillary nerve *(Continued)*
  surface marking of, 130
Axillary sheath, 363
Axillary vein, 129, 196, 207, e4
Axillary-subclavian vein thrombosis, 170f
Axis, 83, 85, 94
  dens of, 52, 85, 106–107
  ossification of, 93
  radiographs of, 106–107
Azygos arch, 209
Azygos lobe, 215f
Azygos vein, 202, 212, e4
  diaphragm and, 213, 260
  groove for, 204
  mediastinum and, 192–193, 196, 209

B

Babinski sign, 355f
Back, 83–84, 100–105
  muscles of, 84, 101–105
  surface features of, 83–84, 100
Baker’s (popliteal) cyst, 356f
Bar room fracture, 170f
Barium enema, 240
Barium meal, 242
Barium swallow, 214
Bartholin’s abscess, 280f
Basilar artery, 64–67
Basilic vein, 143, 147–148, e4
Basi-occiput, 3, 106
Bell’s palsy, 80f
Benign prostatic hyperplasia, 280f
Berry aneurysm, 80f
Biceps brachii, 149–150, e2, e8
  attachments for, 111, 113, 121
  long head of, 127, 137, 143
  nerve to, 143
  short head of, 129, 136, 143
  surface marking of, 126
  tendon of, 143, 146–148
Biceps femoris, 285, 318, 342, e3
  attachment to fibula, 309
  long head of, 276, 319
    attachments for, 287, 293
    nerve to, 319
  short head of, 319
    attachments for, 298, 301
    nerve to, 319
  surface features of, 328
  tendon of, 318, 332–333, 337
Biceps tendon reflex, 170f
Bicipital aponeurosis, 145, 149–150
Bicipital tendinitis and rupture, 170f
Bifurcate ligament
  calcaneocuboid part of, 311, 313, 349
  calcaneonavicular part of, 311, 313, 348–349
Bile duct, 237, 246–248
Biliary tract, extrahepatic, 246
Bladder, 223, 250, 261, e10
  carcinoma of, 280f
  female, 270, 272–274
  fetal, 222
  intravenous urogram of, 259
  male, 225, 266, 268
  prolapse of, 276
  trigone of, 267–268, 272–273
Blow-out fractures of orbit, 80f
Bone marrow, 359
Bone marrow aspiration, 280f
Bowel ischaemia, 280f
Brachial artery, 143, 145, e4
  auscultation of pulse in, 170f
  forearm and, 148–149, 151
  vena comitans of, 143
Brachial plexus, 37, 139–142, e5, e8
  block of, 170f
  dermatome for, e6
  lateral cord of, 138–140, 142
  medial cord of, 139, 142, 207
  palpation of, 28
  posterior cord of, 139–140, 142
  roots of, 30, 33
  trunks of, 129
  upper trunk of, 28, 31–32, 36
Brachial vein, 143, e4
Brachialis, 143, 150–151, e2
  attachments for, 115, 117, 121
  nerve to, 143
Brachiocephalic trunk (artery), 208, 212, e4, e8
  imaging of, 196
  mediastinum and, 196, 206–207
  neck and, 36–37
Brachiocephalic vein, 28, 205, e4, e8
  left, 36–37, 195, 212
  right, 30, 37, 196, 212
Brachioradialis, 127, 143, 149–150
  attachments for, 117, 121
  surface marking of, 145, 148
Brain, 62–72
  arteries of base of, 68
  brainstem of, 69, 71
  cisterns of, 65
  clinical thumbnails for, 80
  endoscopy at base of, 67–68
  hemispheres of, 62–63, 70–72
  magnetic resonance images of, 65, 67, 70
  ventricles of, 72
Brainstem, 66, 69
Branchial cysts, 80f
Breast, 178–179
  abnormalities of, 215f
  axillary tail of, 178
  carcinoma of, 179, 215f, 369f
  examination of, 215f
  orange-peel texture of skin on, 216f
Bregma, 8
Broad ligament, 274
Bronchi, 197–198, 203, e8
  apicoposterior, 197, 197t
  lobar, 197, 197t
  principal, 192, 194, 197, 202
  segmental, 197, 197t
  subapical (subsuperior) segmental, 199
  superior lobe, 192–193, 201
Bronchial arteries, 202–203
Bronchial tree, 198, 202
Bronchiectasis, 215f
Bronchograms, 200–201
Bronchopulmonary segments, 197–201
Bronchoscopy, 197f, 215f
Buccal fat pad, 32, 40
Buccal nerve, 40, 42, 75
Buccinator, 39–40, 43, e2
  attachments for, 2, 6, 19
  neck and, 29, 33
Bulbocavernosus, 264
Bulbospongiosus, 268, 277–279
Bulbourethral glands, 280f
Burr holes, 80f
Bursitis, 356f
Buttock. *See* Gluteal region.

C

Caecal vessels, 251
Caecum, 232, 238, 250–251
  laparoscopic view of, 220
  radiograph of, 240
Calcaneal neurovascular bundle, 350
Calcaneofibular ligament, 309, 313, 349
Calcaneus, 285, 310, 312–313
  articular surfaces of, 348
  fracture of, 355f
  imaging of, 354
  ossification of, 314–315
  surface marking of, 344
  sustentaculum tali of, 310, 312–313, 354
Calcar avis, 70, 72
Calcar femorale, 298
Calcarine sulcus, 66–67
Calcific tendinitis, 170f
Calf, 339, 341–342
  deep fascia of, 346
  deep veins of, 346
Calvarium, 1
Canine fossa, 21
Canine teeth, 13
Capitate, 122–123, 167–168
Caput medusae, 280f

Cardiac cycle, venous phase of, 196
Cardiac pacemaker, 215f
Cardiac tamponade, 215f
Cardiac veins, 186
Cardiopulmonary resuscitation (CPR), 215f
Carina, 197f
Carotid arteries. *See also* Common carotid artery; External carotid artery; Internal carotid artery.
  bruits of, 80f
  stenosis of, 80f
  variants of, 80f
Carotid arteriogram, 66
Carotid canal, 9, 23, 60
Carotid endarterectomy, 80f
Carotid groove, 11, 25
Carotid sinus, 35, 45
Carotid tubercle, 86
Carpal bones, 122–123, 125, e1. *See also specific bone.*
Carpal tunnel, 158, 162
Carpal tunnel syndrome, 170f
Carpometacarpal joint of thumb, 123, 163
Cauda equina, 97, 250, 260
Caudal anaesthesia, 108f
Caudate nucleus, 65, 71–72, e7
Cavernous sinus, 47, 51
Cavernous sinus thrombosis, 80f
Central retinal artery, 73, 80f
Central retinal vein, 73
Central sulcus, 62–63, 66
Cephalic vein, 147, e4
  arm and, 133, 143, 148, 150
  hand and, 164–165
  shoulder and, 127–129, 136
  surface marking of, 28, 126
Cerebellar fossa, 11, 27
Cerebellar hemisphere, 63–64
Cerebellar peduncles, 69
Cerebellomedullary cistern, 52
Cerebellum, 52, 65–66
Cerebral cortex, 63
Cerebral fossa, 27
Cerebral haemorrhage or thrombosis, 70
Cerebral hemispheres, 62–63, 67, 70, 72
  medial surface of, 52, 66
  structures separating, 52
Cerebral peduncle, 64–65, 67
Cerebral ventricles, 72
Cerebrum, e7
Cervical ligament, 313, 348–349
Cervical lymph nodes, 80f, 359, 361
Cervical lymphatic trunk, 361
Cervical nerves, 95–96, e6
  first, 34, 68–69, 95
  rami of, 69, 94–96
  roots of, 69, 94–96
  to trapezius, 29–30, 32, 128
Cervical plexus, 34, 79, e6
Cervical rib, 170f
Cervical smear, 280f
Cervical spine, 94–96
  immobilisation of, 108f
Cervical vertebrae, 83, 85–86, e1. *See also* Atlas; Axis.
  developmental origins of, 93
  radiographs of, 106–107
  spinal cord and, 94–96
Cervicothoracic ganglion, 208
Cervix of uterus, 272–273, 275
Chalazion, 81f
Charcot foot, 355f
Chest radiograph of child, 360
Chest wall, 138, 181. *See also* Thorax.
Child
  chest radiograph of, 360
  ossification of vertebrae in, 93
  teeth and jaw of, 13
  thymus of, 206
Choana, 9, 17
  cranial cavity and, 52–53
  endoscopic view of, 43, 47
Cholecystectomy, 280f
Chorda tympani, 42, 44, 60–61
Chordae tendineae, 187–188
Choroid plexus, 65–66, 69–70
Ciliary arteries, 56
Ciliary ganglion, 44, 74–76
Cingulate gyrus, 66
Circle of Willis, 68
Circumcision, 280f
Circumflex scapular artery, 140–141, 144
  branches of, 131–134
  groove for, 111, 113
Circumflex scapular vessels, 137
Cirrhosis of liver, 280f
Cisterna chyli, 359, 362, 365
Cisterna hili, 365
Cisterna magna, 52
Cisterns, brain, 65
Claustrum, 70, e7
Clavicle, 112–113, 173, e1
  fractured, 171f
  ossification of, 125
  shoulder and, 127–129, 136
  surface features of, 28, 48, 126, 205
Clavicular notch, 176
Clavipectoral fascia, 113, 128, 363
Cleft lip and palate, 80f
Clitoris, 272, 276–277
Clivus, 11–12, 17, 58
Cloquet node, 368
Club foot, 356f
Coccydynia, 108f
Coccygeus, 91, 263–264, 269
Coccyx, 83, 90, e1, e10
  pelvis and, 92, 264, 266
  surface features of, 84, 316
Cochlea, 61, 77
Cochlear canaliculus, 23
Cochlear nerve, 61, 77. *See also* Vestibulocochlear nerve (VIII).
Coeliac arterial trunk, 242
Coeliac ganglion, 78, 242, 257
Coeliac plexus, 257
Coeliac plexus block, 280f
Coeliac trunk, 212, 234, 236–237, 248, e4
Colic artery
  left, 238–239, 367
  middle, 238, 243
  right, 243, 251
Colic flexure
  left (splenic), 240, 249, 365
  right (hepatic), 226, 233, 240
Colic vein, 260
Colic vessels, 248
Collateral eminence, 72
Collateral ligament. *See also* Deltoid ligament; Fibular collateral ligament; Tibial collateral ligament.
  of interphalangeal joint, 163
  of metacarpophalangeal joint, 163
  of metatarsophalangeal joint, 353
  radial, 146, 152, 167
  ulnar, 146, 163
Collateral sulcus, 65, 67
Collateral trigone, 72
Colles' fracture, 121, 170f
Colon, 229, 240. *See also* Ascending colon; Descending colon; Sigmoid colon; Transverse colon.
Colonic stents, 280f
Colonoscopy, "virtual", 240
Colostomy, 280f
Common bile duct, 237, 247
Common carotid artery, 212, e4, e7–e8
  mediastinum and, 195–196, 206
  neck and, 29–32
  palpation site for, 28
  pharynx and, 45, 47
Common extensor origin, 117
Common extensor tendon, 166
Common femoral artery, 319, e4
Common femoral vein, e4
Common flexor origin, 117, 145, 149–150
Common hepatic artery, 234, 236, 257, e4
Common hepatic duct, 245–247
Common iliac artery, 239, 267–268, e4
Common iliac node, enlarged, 367
Common iliac vein, 261, e4
Common interosseous artery, 149, 151
Common palmar digital arteries, 160–162
Common peroneal (fibular) nerve, 317, e5–e6
  branches of, 337
  knee and, 329–331, 337
  leg and, 338, 342
  surface marking of, 328
Computed tomography (CT)
  of coronary arteries, 191
  of foot, 354
  of hip joint, 327
  of inner ear, 61
  of mediastinum, 196
  of urinary tract, 259
  in "virtual colonoscopy", 240
Concha, 60
Conchal crest, 21–22
Condylar canal, 9, 27
Condylar fossa, 27
Cone of light (light reflex), 60
Conjoint extensor tendon, 166
Conjoint tendon, 224–225, 291, 293
Conoid ligament, 111, 113, 136
Conoid tubercle, 112
Conus artery, 190–191
Conus medullaris, 97
Coracoacromial ligament, 111, 113, 136
Coracobrachialis, 129, 136, 143, e8
  attachments for, 111, 113, 115
  axilla and, 139–142
Coracoclavicular ligament, 111
Coracohumeral ligament, 113
Coracoid process, 110, 112, 129
Cornea, 54
Corneal arcus, 80f
Corneal reflex, 80f
Corniculate cartilage, 49–50
Coronal suture, 4, 8, 14, 17
Coronary angiography, 190, 215f
Coronary arteries, 186, 190–191, e4. *See also* Left coronary artery; Right coronary artery.
  imaging of, 190–191, 215f
  interventricular branches of, 190
Coronary artery bypass grafting (CABG), 215f, 357f
Coronary ligament, 245
Coronary sinus, 186, 191
  opening of, 187–188
  valve of, 187
Coronoid fossa, 116–117
Corpus callosum, 52, 66–67, 70
Corpus cavernosum, 266, 278–279
Corpus luteum, 273
Corpus spongiosum, 278–279
Corrugator supercilii, 2, 6
Corticonuclear (motor) fibres, 70
Corticospinal (motor) fibres, 70–71
Costal cartilages, 177, 181, e1
  notches for, 176
  surface marking of, 178, 205, 217
Costal facets, 86–87, 175
Costal groove, 175
Costal margin, 173, 178, 180–181
Costocervical trunk, 195
Costochondral joints, 177
Costochondral pathology, 215f
Costoclavicular ligament, 112–113, 175
Costodiaphragmatic recess, 184, 213, 249, 253
Costomediastinal recess, 213
Costotransverse joints, 211
Costotransverse ligament, 175, 211
Costovertebral joints, 175, 211
Cranial cavity, 51–53
Cranial fossae, 11, 51, 53
Cranial nerves, 53, 67, 73–79. *See also specific nerve.*
  autonomic, 79
  dermatomes of, e6
Cranial vault, 8, 62
Craniotomy, 80f
Cranium, 1. *See also* Skull.
Cremaster muscle, 224
Cremasteric fascia, 224, 265
Cribriform fascia, 224
Cribriform plate, 11–12, 26, 51
Cricoid cartilage, 28, 48–50
  endoscopic view of, 50
  surface marking of, 28, 48, 205

Cricothyroid artery, 34
Cricothyroid joint, 49
Cricothyroid ligament, 48
Cricothyroid membrane, 48
Cricothyroid muscle, 30, 37, 48–49
Crista galli, 3, 11, 17, 26
Crista terminalis, 187, 189
Cross-sections, human body, e7–e10, e8–e9, e10
Cruciate ligaments, 333. *See also* Anterior cruciate ligament; Posterior cruciate ligament.
Cruciform ligament, 94
CT. *See* Computed tomography (CT).
Cubital fossa, 148, 151, 364
Cubital lymph nodes, 364
Cuboid, 310, 312
  imaging of, 354
  ossification of, 315
Cuneate tubercle, 69
Cuneiform bones. *See* Intermediate cuneiform; Lateral cuneiform; Medial cuneiform.
Cuneiform cartilage, 49
Cuneonavicular joint, 349
Cushing striations, 281f
Cystic artery, 236, 246
Cystic duct, 236–237, 246–247
Cystic vein, 246
Cystitis, 281f
Cystocele, 276
Cystoscopy, 259, 268, 278, 281f

D

Dartos muscle, 265
Deciduous teeth, 2
Deep circumflex iliac artery, 261
Deep common peroneal (fibular) nerve, 337
Deep dorsal vein of penis, 266–267, 278
Deep external pudendal artery, 267
Deep infrapatellar bursa, 335
Deep inguinal ring, 223–225
  laparoscopic view of, 223
  in male, 225, 268
  surface marking of, 221
Deep lingual artery, 29
Deep palmar arch, 160–162, e4
Deep peroneal (fibular) nerve, 337, 347, e5–e6
Deep temporal artery, 42
Deep temporal nerve, 42, 76
Deep transverse metacarpal ligament, 163, 166
Deep vein thrombosis (DVT), 346, 355f
Deltoid, 109, e2–e3, e8
  attachments for, 111, 113, 115
  injections into, 130, 171f
  shoulder and, 127–129, 131
  surface marking of, 28, 84, 126, 130
Deltoid ligament, 306, 348–349, 353
  attachments for, 306, 313
  posterior tibiotalar part of, 349
Deltoid tuberosity, 114–115
Deltoid vein, 364
Deltopectoral groove, 126–128, 173
Denticulate ligament, 67, 69, 94, 96
Depressor anguli oris, 2, 33
  attachments for, 6, 19
  face and, 39–40
Depressor labii inferioris, 2, 6, 19, 39
Dermatomes, e6
Descending colon, 232, e9
  radiograph of, 240
  upper abdomen and, 227–229, 239
Descending genicular artery, saphenous branch of, 323
Dextrocardia, 215f
Diagonal artery, 190–191
Diaphragm, 184, 213, 260, e9
  attachments for, 175, 177
  laparoscopic view of, 220
  mediastinum and, 192–194
  oesophageal opening in, 217, 241
  surface marking of, 217
  tendon of, 185, 213, 260
Diaphragmatic hernia, 215f
Digastric fossa, 18
Digastric muscle
  anterior belly of, 29–30, 32–33
  attachments for, 10, 19
  posterior belly of, 29, 31–33
Digastric nerve, 29
Digital abnormality, 355f
Digital arteries of foot, 348
Digital nerve block, 170f
Diploë, 11
Direct inguinal hernia, 222, 225
Diverticular disease, 281f
Dorsal carpal arch, 164, 166
Dorsal digital artery/vein, 164
Dorsal digital expansion, 166, 345
Dorsal interossei
  of foot, 311, 348, 352, 354
  of hand, 124, 154, 162, 166
Dorsal interosseous artery, 164
Dorsal metacarpal arteries, 164, 166
Dorsal metatarsal arteries, 348
Dorsal nasal artery, 54
Dorsal nerve roots/rootlets, 69, 96
Dorsal pedis artery, 348
Dorsal radiocarpal ligament, 167
Dorsal root ganglion, 94
Dorsal sacro-iliac ligaments, 325
Dorsal scapular artery, 36, 361
Dorsal scapular nerve, 31–32
Dorsal venous arch
  of foot, 344, 346, 348
  of hand, 159
Dorsalis pedis artery, 344, 347–348, e4
Dorsum sellae, 11–12, 17, 25
Ductus deferens, 265, 268–269
  abdominal walls and, 220, 223–224, 261
  pelvis and, 225, 266–268
Duodenal papilla, 243
Duodenojejunal flexure, 231–232
Duodenum, 231, 233, 235, 243
  cross-section of, e9
  enema via tube in, 240
  radiography of, 242
  surface marking of, 217
Dupuytren's contracture, 170f
Dura mater
  cerebral, 5, 53, 62, 76
  cervical, 69, 94, 96
  lumbar, 97
  thoracic, 95, 97

E

Ear, 60–61
  external, 60
  inner, 60–61
  middle, 60–61
Ectopic pregnancy, ruptured, 281f
Edinger-Westphal nucleus, 79
Ejaculatory duct, 268
Elbow, 145–147
  arterial puncture at, 170f
  arthroscopy of, 147, 170f
  cubital fossa of, 148, 151, 364
  dislocation of, 170f
  forearm and, 149, 151–152
  golfer's, 171f
  imaging of, 146–147
  joint of, 109, 121, 147
  radio-ulnar joint and, 120, 146
  surface markings on, 145
  tennis, 171f
Elephantiasis, 369f
Emphysema, surgical, 216f
Empyema, 215f
Endometrial cavity, 273
Endoscopic retrograde cholangiopancreatogram (ERCP), 247
Endoscopy
  at base of brain, 67–68
  of larynx, 50
  of nasal septum (choanae), 43, 47
  of nasopharynx, 52
  of olfactory mucosa, 73
Endotracheal intubation, 80f
Epididymis, 265
Epidural anaesthesia, 108f
Epigastric region, 217
Epiglottis, 47–50
Epiphysis, 115, 169
Epiploic foramen (of Winslow), 230, 233–234
Episiotomy, 281f
Epistaxis, 80f
Epitympanic recess, 60–61
Erb's palsy, 170f
Erector spinae, 101–102, e3
  attachments for, 91, 175, 289
  cross-section of, e8–e9
  shoulder and, 132–135
  surface features of, 100
  tendon of, 101–102
Ethmoid bone, 12, 26
  cribriform plate of, 11–12, 26, 51
  orbital plate of, 4, 12, 26
  perpendicular plate of, 17, 26
  uncinate process of, 12, 26
Ethmoidal air cells, 3, 12, 16, e7
Ethmoidal bulla, 12, 26, 58
Ethmoidal crest, 21–22
Ethmoidal infundibulum, 58
Ethmoidal labyrinth, 26
Ethmoidal notch, 20
Ethmoidal process, 26
Ethmoidal spine, 25
Eustachian tube, 52, 58, 60–61
Exostoses, femoral, 355f
Extension, finger/thumb, 155–156
Extensor carpi radialis brevis, 150–153
  attachments for, 118, 120, 124
  hand and, 164–166, 168
  tendon of, 159
Extensor carpi radialis longus, 117, 145
  attachments for, 118, 120, 124
  forearm and, 149–152
  hand and, 164–166, 168
  tendon of, 159
Extensor carpi ulnaris, 152–153
  attachments for, 119–121, 124
  hand and, 164–166, 168
  tendon of, 159
Extensor compartment muscles, e2
Extensor digiti minimi, 153
  hand and, 154, 164–165, 168
  tendon of, 159
Extensor digitorum, 152–153
  attachments for, 118, 120
  hand and, 154, 164–165, 168
  tendon of, 159
Extensor digitorum brevis
  ankle/foot and, 344–345, 347–348
  attachments for, 311, 313
Extensor digitorum longus, 337–338
  ankle/foot and, 344–345, 347–348
  attachments for, 305, 309, 311
Extensor expansion, 124, 166
Extensor hallucis brevis, 311, 348
Extensor hallucis longus, 337, e2
  ankle/foot and, 344–345, 347–348
  attachments for, 309, 311
Extensor indicis, 152–153
  attachments for, 118, 120–121
  hand and, 154, 164–165
Extensor muscles of forearm, 145, e3
Extensor plantar response, 355f
Extensor pollicis brevis, 152–153
  attachments for, 118, 121, 124
  hand and, 154, 164–166
  tendon of, 159
Extensor pollicis longus, 152–153
  attachments for, 118, 120–121, 124
  hand and, 154, 164–166
  tendon of, 159
Extensor retinaculum, 152–154, 164
External acoustic meatus, 4, 7, 60–61
External anal sphincter, 268, 276–278
External aperture (anterior naris), 38
External auditory canal, 47
External carotid artery, 69, e4
  face and, 44, 59
  neck and, 29–32
External iliac artery, e4
  abdominal walls and, 223, 261
  pelvis and, 267–270
External iliac lymph nodes, 366–367
External iliac vein, 366, e4
  abdominal walls and, 223, 261
  pelvis and, 225, 268, 270, 272

External intercostal membrane, 181
External intercostal muscles, 181–182, e2
attachments for, 175
back and, 102–103
External jugular vein, 28, 32–33, e4
External laryngeal nerve, 29, 31–32, 78
External oblique aponeurosis, 218–220, 224
External oblique muscle, 218–219, e2, e9
attachments for, 175, 287, 291, 293
back and, 101–103, e3
surface features of, 84, 180
External occipital crest, 9, 27
External occipital protuberance, 4, 7, 9, 17
External spermatic fascia, 265
External urethral orifice, 265, 276–277
Extradural haemorrhage, 80f
Extravasation of urine, 281f
Eye, 54
fundus of, 73
orbits of, 54–57
Eyeball, 54, 56–57, 74
Eyelids, 54

F

Fabella, 336
Face, 30–35, 38–40
at birth, 15
bones of, 1, 16
coronal section of, 43
imaging of, 15–16, 58
intracranial infection spread to, 81f
surface markings on, 38
Facial artery, 28, e4
face and, 39–40, 43
neck and, 29–32
palpation of, 38
Facial colliculus, 69
Facial nerve (VII), 40, 44, 77, e5
brain and, 64–65, 67–68
buccal branches of, 39–40, 77
canal for, 60
cervical branch of, 32, 40, 42, 77
ear and, 61
mandibular branch of, 77
marginal mandibular branch of, 31–32, 34, 39
motor root of, 53
palsy of, 80f
posterior auricular branch of, 77
sensory root of, 53
temporal branch of, 39–40, 77
zygomatic branch of, 39–40, 77
Facial vein, e4
face and, 39–40, 42
neck and, 30–33
Faecal continence, 281f
Falciform ligament, 222, 226–227, 229
laparoscopic view of, 220
ligamentum teres in, 228, 231, 234
upper abdomen and, 230, 233, 235
Fallopian tube. *See* Uterine tube.
Falx cerebri, 51–53, 62
Fascia lata, 321, 329, 335
Female
breast of, 178–179
genital cutting in, 281f
heart, pleura, and lung of, 178
inguinal region of, 224
pelvis of, 92, 270, 272–275, 366
perineum of, 276–277
sacrum of, 89
Femoral arteriogram, 319
Femoral artery, 263, 267, 322, e10
abdominal walls and, 220, 261
puncture of, 319, 355f
surface marking of, 221
thigh and, 321–323
Femoral canal, 221, 261, 320, 368
Femoral epiphysis, slipped upper, 356f
Femoral hernia, 281f
Femoral neck fractures, 327, 355f
Femoral nerve, 263, 267, e5–e6
abdominal walls and, 220, 223, 261–262
paralysis of, 355f
surface marking of, 221
thigh and, 321–322
Femoral ring, 225
Femoral sheath, 320, 368
Femoral spurs, 355f
Femoral triangle, 320, 368
Femoral vein, 263–264, 267, e10
abdominal walls and, 220, 261
surface marking of, 221
thigh and, 321–322
Femoropopliteal bypass, 355f
Femur, 285, 294–301, e1, e10
articulation with patella, 299
attachments of, 295, 297–298, 301
bone trabeculae of, 298
condyles of, 296, 299–300, 334
epicondyles of, 300, 336
fractures of, 327, 355f
greater trochanter of, 294, 296, 317, 326
head of, 294, 296, 326–327
knee and, 332, 334
lesser trochanter of, 294, 296, 298, 327
neck of, 294, 296, 326–327
ossification of, 314
radiographs of, 336
shaft of, 294, 298, 326
surface marking of, 328
Fetus
abdominal wall of, 222
head and neck arteries of, 15
skull of, 8, 14–15
vertebra of, 93
Fibroids, uterine, 250, 284f
Fibrous flexor sheaths
of foot, 350–351
of hand, 158–159, 162–163
Fibrous trigone, 189
Fibula, 285, 307–309, 343, e1
articulation with tibia, 307
attachments of, 309
knee and, 328–329, 332, 337
ossification of, 314
radiograph of, 354
Fibular collateral ligament, 301, 309, 333, 335
Filum terminale, 97
Fingers
bones of, 122–123, 125
dislocation of, 170f
extensor expansion of, 166
ligaments and joints of, 163
mallet, 171f
movements of, 155
synovial sheaths and tendons of, 158, 338
trigger, 171f
Flail chest, 215f
Flat foot, 355f
Flexion, finger/thumb, 155–156
Flexor accessorius, 311, 349, 351–352
Flexor carpi radialis, 150, 157–159
attachments for, 124
surface marking of, 154
Flexor carpi ulnaris, 157–160
attachments for, 121, 124
forearm and, 149–151
nerve to, 149
surface marking of, 154
Flexor digiti minimi brevis
foot and, 311, 350–352
hand and, 124, 154, 157–158
Flexor digitorum brevis, 311, 349–350, 352
Flexor digitorum longus, 341, 343, e3
ankle/foot and, 345–348
attachments for, 303, 311
tendon of, 346
Flexor digitorum profundus, 158–160, 162
attachments for, 121, 124
forearm and, 149–151
tendon of, 159
Flexor digitorum superficialis, 158–160, 162
attachments for, 121, 124
forearm and, 150–151
tendon of, 159
Flexor hallucis brevis, 349–352
attachments for, 311
sesamoid bones in, 310, 354
Flexor hallucis longus, 341, 343, e3
ankle/foot and, 345–348
attachments for, 309, 311
grooves for, 306, 310, 349, 353
sole of foot and, 350–353
Flexor pollicis brevis, 157–160
attachments for, 124
sesamoid bones of, 163
surface marking of, 154
Flexor pollicis longus, 158–160, 162
attachments for, 121, 124
forearm and, 150–152
tendon of, 159
Flexor retinaculum
of lower limb, 341, 345–346
of upper limb, 150, 157–159
Fontanelles, 8, 14–15
Foot, 344–354
bones of, 310–315
Charcot, 355f
club, 356f
dorsum of, 348
flat, 355f
imaging of, 354
ligaments of, 349
sole of, 350–353
surface features of, 344
Foramen caecum, 11, 20, 49
Foramen lacerum, 9, 11, 61
Foramen magnum, 9, 11, 27, 79
margin of, 17, 52–53, 69
vertebral column and, 96
Foramen ovale, 9, 11, 25, 75
Foramen rotundum, 3, 11, 25, 75
Foramen spinosum, 9, 11, 25, 61
Forceps major, 72
Forceps minor, 70–72
Forearm, 109, 148–153
arteries of, 149, 151
muscles of, 150, 152, e2–e3
nerves of, 149, 151–152
traction of fractures of, 171f
Foreskin, 265
Fornix, 66, 72
anterior column of, 65–67
body of, 65, 71
Fossa ovalis, 187
Fournier's gangrene, 281f
Fourth ventricle, 52, 66, 72
choroid plexus from, 65, 69
floor of, 53, 69, 71
Frontal bone, 1, 4, 8, 20
fetal, 14
nasal spine of, 12, 20
orbital part of, 11–12, 17, 20
squamous part of, 17
Frontal crest, 8, 11, 16, 20
Frontal lobe, 63–64
Frontal nerve, 44, 54–56
Frontal notch (foramen), 1, 12, 20, 38
Frontal pole of brain, 62–64
Frontal sinus, 11–12, 16–17
nasal cavity and, 58
radiograph of, 3
sagittal section of, 52
Frontal suture, 8, 14
Frontal tuberosity, 14, 20
Frontalis muscle, 5
Frontopolar artery, 66
Frontozygomatic suture, 4
Fungiform papilla, 49

G

Gag reflex, 80f
Gall bladder, 230–231, 233–234
cross-section of, e9
fundus of, 235, 246
imaging of, 247
laparoscopic view of, 231f
liver and, 244–246
surface marking of, 217
Gallstones, 281f
Gamekeeper's thumb, 171f
Gartner's duct cyst, 281f

Gastric artery
left, 241, 248, 365, e4
right, 234, 236, 241
Gastric pacemaker, 281f
Gastric vein
left, 241, 246, 248
right, 246
Gastric vessels, 241, 249
Gastrocnemius, 285, 343, e2–e3
aponeurosis of, 339
lateral head of, 338–339, 341–342
attachments for, 301
impression for, 300
surface marking of, 328
medial head of, 338–339, 341–342
attachments for, 301
nerve to, 330
Gastrocolic omentum, 233
Gastroduodenal artery, 234, 236–237
Gastroduodenal junction, 233
Gastro-epiploic artery, 236
Gastro-epiploic veins, 231, 236
Gastro-epiploic vessels
left, 234, 241, 249
right, 241, 243
Gastro-oesophageal junction, 214
Gastro-oesophageal reflux, 215f
Gastro-omental artery/vein, 237
Gastrosplenic ligament, 226, 249–250
Geniculate bodies, 64
Geniculate ganglion, 44, 61
Genioglossus, 19, 48
Geniohyoid, 19, 29, 48, 59
Genitalia
ambiguous development of, 281f
male external, 265
Genitofemoral nerve, 251, 261–262, 367
femoral branch of, 223, 261, 267, 270
genital branch of, 223, 261, 267, 270
Genu valgum, 355f
Genu varum, 355f
Glabella, 1, 4, 20, 38
Glans penis, 265, 321
Glaucoma, 80f
Glenohumeral ligaments, 137
Glenoid cavity, 110, 112, 136–137
Glenoid labrum, 129, 136–137
Globus pallidus, 70–71
Glossopharyngeal nerve (IX), 44, 67, 78
neck and, 29, 35–36
pharyngeal branch of, 45
roots of, 65, 69
tympanic branch of, 23, 60
Glottis, 50
Gluteal fascia, 316, 318
Gluteal fold, 316f
Gluteal region, 316–317
injection into, 316, 355f
thigh and, 318
Gluteus maximus, 285, 317–318, e3
attachments for, 91, 287, 297–298
cross-section of, e10
nerves of, 316
surface features of, 84, 100, 316
Gluteus medius, 317, e3
attachments for, 287, 295, 297
surface features of, 316
Gluteus minimus, 317, 324, 326, e10
attachments for, 287, 295, 297
Goitre, 80f
Golfer's elbow, 171f
Gonadal vein, 235, 257–258, 367
Gracile tubercle, 69
Gracilis, 319, 321–323
attachments for, 287, 293, 303, 305
knee and, 329–331
lower leg and, 338, 341–342
tendon of, 342
Great auricular nerve, 29–32
Great cardiac vein, 185–186, 188, 191
Great cerebral artery, 52
Great cerebral vein, 66
Great saphenous vein, 220, 267, e4, e10
ankle/foot and, 344, 346–347, 349
Great saphenous vein *(Continued)*
inguinal region and, 224
knee and, 329
leg and, 338–340, 342
thigh and, 321, 323
Great vessels, 185, 191, 216f, 256
Greater occipital nerve, 104–105
Greater omentum, 228, 231–233
diagram of, 227
laparoscopic view of, 220
liver and, 244
Greater palatine canal, 21
Greater palatine foramen, 9
Greater palatine groove, 22
Greater palatine nerve, 44, 58
Greater petrosal nerve, 44, 61, 79
groove for, 11, 23, 60
hiatus for, 11, 23, 51
Greater sac, 230, 250
Greater sciatic foramen, 271
Greater sciatic notch, 286, 288, 325
Greater splanchnic nerve, 195, 209–211
Groin, male, 220. *See also* Inguinal region.
Guyon's canal syndrome, 171f
Gyri, 62–63
Gyrus rectus, 64–65

H

Haemoperitoneum, 281f
Haemorrhoids, 278, 281f
Haemothorax, 215f
Hallux, 354
Hallux sesamoid fracture, 355f
Hallux valgus, 355f
Hamate, 122–123, 159, 167
fractured, 171f
hook of, 122, 154, 159, 163
Hammer toe, 355f
Hamstrings, 285, 318
origin of, 324, e10
torn, 357f
Hand, 109, 154–169
arteries of, 166
bones of, 122–125
dorsum of, 154, 164–167
imaging of, 159, 161, 169
infections of, 171f
ligaments and joints of, 163, 167
movements of, 155–156
palm of, 154, 157–163
Haustrations, 240
Head, 1–80
brain of, 62–72
clinical thumbnails for, 80
cranial cavity of, 51–53
cranial nerves of, 67, 73–79
cross-section of, e7
ear of, 60–61
eye of, 54–57
face of, 33–34, 38–40, 43
fetal, 15
larynx of, 48–50
neck and neck root of, 28–37
nose of, 58–59
pharynx of, 45–47
skull bones (individual) of, 18–27
skull of, 1–17
temporal and infratemporal fossae of, 41–44
tongue of, 58
Heart, 185–191, e4
abnormalities of, 215f
apex of, 178, 186, 196, 217
base of, 186, 191
blood vessels of, 186, 190–191
borders of, 185
diaphragmatic (inferior) surface of, 186
fibrous framework of, 189
pericardium and, 185
right atrium of, 187
sternocostal (anterior) surface of, 186
surface markings of, 178
valves of, 178, 189
ventricles of, 187–188
Heart sounds, auscultation of, 178, 215f
Heel, 340, 346
Helix, 60
Hemi-azygos vein, 195–196, 212
accessory, 212
diaphragm and, 213, 260
Hepatic artery, 245–246
left, 236–237, 246, 248
right, 236–237, 246, 248
Hepatic ducts, 236–237, 246–247
Hepatic flexure, 226, 233, 240
Hepatic veins, 246, e4
Hepatopancreatic ampulla, 236
Hepatorenal (Morison's) pouch, 233
Hesselbach's triangle (inguinal triangle), 222–223, 225
Hiatus hernia, 281f
Hip adductors, 285, e2
Hip bone, 285–293, e1
attachments of, 287, 289, 291, 293
ossification of, 314–315
Hip joint, 324–327
arthroscopic views of, 327
capsule of, 326
imaging of, 240, 326–327
posterior dislocation of, 356f
replacement surgery for, 357f
Hippocampus, 71–72
Horner's syndrome, 81f
Humerus, 114–117, e1
articulation of, 120
capitulum of, 116, 145–147
cross-section of, 143, e8
dislocation of, 170f
elbow and, 146–147
epicondyles of, 116, 120, 145–146
head of, 114, 136–137
ossification of, 125
shoulder and, 136
supracondylar fracture of, 171f
trochlea of, 116, 120, 146–147
Hydrocele, 281f
Hydrocephalus, 81f
Hyoepiglottic ligament, 50
Hyoglossus, 29, 32, 35, 48
Hyoid arch, 50
Hyoid bone, 31, 33, 48, e1
radiograph of, 107
surface marking of, 28, 48
Hyperacusis, 81f
Hypochondrium, 217
Hypogastric nerve, 261
Hypogastric plexus, 260, 367
Hypogastrium, 217
Hypoglossal canal, 9, 11, 17, 27
Hypoglossal nerve (XII), 44, 67, 79
neck and, 29, 31–33
palsy of, 81f
surface marking of, 28
vena comitans of, 31
Hypoglossal triangle, 69
Hypospadias, 281f
Hypothalamic sulcus, 66
Hypothalamus, 66–67
Hypothenar muscles, e2
Hysterectomy, 281f
Hysterosalpingogram, 274
Hysteroscopy, 274

I

Ileal vessels, 251–252, 266
Ileocaecal junction, 232, 238, 240
Ileocaecal valve, 250
Ileocolic artery, 238, 243, 251
Ileocolic vessels, 238, 248
Ileum, 229, 232, 238, 252
laparoscopic view of, 220
terminal, 240, 251
Iliac crest, 92, 286, 288, e3
surface features of, 84, 100, 221, 316
tubercle of, 221, 286, 290, 292
Iliac fossa, 92, 288, 290, 292
abdominal region of, 217
surface marking of, 221
Iliac lymph nodes, 270, 359, 366–367

Iliacus, 321, 324, 326, e2
  attachments for, 289, 291, 295, 297
  pelvis and, 263–264, 267
Iliococcygeus, 264
Iliocostalis, 101–103
Iliofemoral ligament, 287, 291, 293, 324
Iliohypogastric nerve, 224, 253, 260, e6
Ilio-inguinal nerve, 218–220, e6
Iliolumbar artery, 261, 270
Iliolumbar ligaments, 261–262, 271
  attachments for, 289, 291
  hip joint and, 324–325
Iliolumbar vein, 367
Iliopsoas tendon, 324, e10
Iliopubic eminence, 286, 288, 290, 292
Iliotibial tract, 285, e2–e3, e10
  attachments for, 303, 305, 329
  impression for, 302
  knee and, 329, 333, 335, 337
  surface marking of, 328
  thigh and, 318–319, 321, 323
Ilium, 286, 288, 290
Incisive canal, 12, 17, 21
Incisive foramen, 58
Incisive fossa, 9, 21
Incisor teeth, 13, 16
Incudomalleolar joint, 61
Incudostapedial joint, 61
Incus, 60–61
Indirect inguinal hernia, 220, 225, 281f
Inferior alveolar artery, 42
Inferior alveolar nerve, 42, 59, 75–76
  block of, 81f
  neck and, 29
Inferior articular facets, 85
Inferior articular process, 86–88
Inferior cerebral veins, 63
Inferior cervical ganglion, 36
Inferior colliculus, 66, 69, 71
Inferior constrictor of pharynx, 45, 47
  attachments for, 48
  neck and, 31–32, 35
Inferior epigastric vessels, 219, 223, 225, 263
  pelvis and, 267–269, 272
  surface marking of, 221
Inferior extensor retinaculum, 313, 345, 347–348
Inferior frontal gyrus, 63
Inferior gemellus, 276, 317, 324
  attachments for, 289, 293
Inferior gluteal artery, 276, 317
  anastomotic branch of, 319
  pelvis and, 268–270
Inferior gluteal line, 286
Inferior gluteal nerve, e5
Inferior gluteal vein, 317
Inferior hypogastric plexus, 261, 269
Inferior ileocaecal recess, 251
Inferior lateral genicular artery, 331, 343
Inferior meatus, 12, 21, 58
Inferior medial genicular artery, 331, 343
Inferior mesenteric artery, 235, 239, 248, e4
Inferior mesenteric plexus, 261
Inferior mesenteric vein, 235, 248, e4
Inferior mesenteric vessels, 239
Inferior nasal concha, 1, 12, 16, 26
Inferior oblique muscle, 54–55, 57, 74
  ciliary ganglion and, 74
  nerve to, 55, 57
Inferior orbital fissure, 1, 7, 9, 12
Inferior peroneal (fibular) retinaculum, 345
Inferior petrosal sinus, groove for, 11, 27
Inferior phrenic vessels, 242, 257–258, 260
Inferior pubic ramus, 327
Inferior pulmonary veins
  left, 185–186, 191, 202
  right, 185–186, 191, 202
Inferior rectal nerve, 276, 279
Inferior rectal vessels, 278–279, 318
Inferior rectus, 44, 55, 57, 74
  ciliary ganglion and, 74
  nerve to, 55, 57, 74
Inferior sagittal sinus, 53
Inferior salivatory nucleus, 79
Inferior suprarenal artery, 242
Inferior temporal gyrus, 63
Inferior temporal line, 4, 20, 24
Inferior temporal sulcus, 63
Inferior thyroid artery, 31, 35–37
Inferior thyroid vein, 30, 32, 37, 206
Inferior transverse ligament, 306, 349
Inferior vagal ganglion, 36
Inferior vena cava, 235, 246, e4, e9
  diaphragm and, 213, 217, 260
  duplication of, 282f
  heart and, 186–188
  mediastinum and, 192, 196, 210
  obstruction of, 281f
  valve of, 187
Inferior vesical artery, 267–268, 270
Infraclavicular fossa, 28, 126, 205
Infraclavicular nodes, 179, 363
Infraglenoid tubercle, 112
Infra-orbital artery, 55, 57, 74
Infra-orbital foramen, 1, 12, 21, 38
Infra-orbital groove, 12, 21
Infra-orbital margin, 1, 16, 21, 38
Infra-orbital nerve, 40, 74–76
  eye and, 54–57
  surface marking of, 38
Infra-orbital vessels, 38
Infrapatellar fat pad, 335, 338
Infraspinatus, 101–102, e3, e8
  attachments for, 111, 113, 115
  shoulder and, 132–135
  surface marking of, 100, 130
Infraspinous fossa, 110, 112
Infratemporal crest, 7, 9, 25
Infratemporal fossa, 42
Infratemporal region, 7
Infratrochlear nerve, 54–55, 75
Inguinal canal, 224
Inguinal hernia, 281f
  direct, 222, 225
  indirect, 220, 225, 281f
  repair of, 281f
Inguinal ligament, 285, 321–322, e2
  attachments for, 287, 289, 291, 293
  in female, 224, 368
  in male, 224–225, 264, 267
  pectineal part of, 291. *See also* Lacunar ligament.
  surface marking of, 221
Inguinal lymph nodes, 359
  enlargement of, 281f
  superficial, 218–220, 368
Inguinal region, 263
  female, 224
  male, 224, 267
Inguinal ring. *See* Deep inguinal ring; Superficial inguinal ring.
Inguinal triangle (Hesselbach), 222–223, 225
Inion, 4, 7
Inner ear, 60–61
Innermost intercostal muscles (intercostales intimi), 182–183
Innominate bone. *See* Hip bone.
Insula, 70–71
Interatrial septum, 187, 189
Intercostal arteries, 182, 195, 209, 212
Intercostal drainage, 215f
Intercostal muscles, 181–184. *See also* External intercostal muscles; Internal intercostal muscles.
  attachments for, 175
  cross-section of, e8–e9
Intercostal nerves, 182, 208
  anterior abdominal, 218–220
  block of, 215f
  mediastinum and, 209
Intercostal neurovascular bundle, 127, 183
Intercostal spaces, 180, 210
Intercostal veins, 182, 195, 209, 212
Intercostobrachial nerve, 129, 138, 140–141
Intermediate cuneiform, 310, 312, 315, 354
Intermediate cutaneous nerve of thigh, 368
Intermittent claudication, 355f
Internal acoustic meatus, 11, 17, 23, 61
Internal capsule of cerebrum, 70–72, e7
Internal carotid artery, 44–45, 47, e4
  brain and, 64–66, 68
  neck and, 31–32, 34–35
Internal carotid nerve, 36
Internal cerebral vein, 71
Internal iliac artery, 261, 269–270, e4
  embolisation of, 281f
  pelvis and, 267–268, 275
Internal iliac vein, 275, e4
Internal intercostal muscles, 181–183, e2
  attachments for, 175
  axilla and, 139
Internal jugular vein, e4, e7
  catheterisation of, 81f
  mediastinum and, 206–207
  neck and, 29–31, 33
  surface marking of, 28, 205
Internal laryngeal nerve, 49–50, 78
  neck and, 29, 31–33
  surface marking of, 28
Internal oblique aponeurosis, 218–219
Internal oblique muscle, 219–220, 262, e2
  attachments for, 291, 293
Internal occipital crest, 27
Internal occipital protuberance, 11, 17, 27
Internal pudendal artery, 268–270, 279
Internal thoracic artery, 183, 208, e4
  mediastinum and, 193, 195–196, 206
  root of neck and, 36–37
Internal thoracic vein, 37, 183, 195, 206
Internal urethral orifice, 267–268
Interosseous ligament, 306, 308–309
Interosseous membrane
  of forearm, 146, 151–152
  of lower leg, 305–306, 309, 337
Interosseous metacarpal ligament, 163
Interosseous sacro-iliac ligament, 289, 291
Interosseous talocalcanean ligament, 313, 348–349
Interpectoral nodes, 179
Interphalangeal joints
  of foot, 349
  of hand, 109, 124, 155, 163
    collateral ligament of, 163
    movements of, 155, 155b
Interspinous ligament, 98–99
Intertrochanteric crest, 294, 296, 324
Intertrochanteric line, 294, 296, 324
Intertubercular groove, 114, 136
Intervenous tubercle, 187
Interventricular foramen, 66–67, 70
Interventricular groove, 185–186
Interventricular septum, 187–188, 196
Intervertebral disc, e9
  cervical, 52, 94–95
  lumbar, 97–99, 260
  thoracic, 98, 213
Intervertebral foramen, 95, 98
Intestines, 229, 250–252. *See also* Large intestine; Small intestine.
  imaging of, 240
  lymphoid nodules of, 359
Intracranial spread of infection, 81f
Intramuscular injections, 130, 171f, 316, 355f
Intratonsillar clefts, 360
Intrauterine contraceptive devices (IUCDs), 282f
Intravenous urogram (IVU), 259
Intussusception, 282f
Iris, 54
Ischial spine, 92, 286, 288, 290
Ischial tuberosity, 286, 288, 292–293, e10
  pelvis and, 269, 271
  surface features of, 316
Ischio-anal (ischiorectal) fossae, 263, 276–277, 279, e10
Ischiocavernosus, 277–279, e10
Ischiofemoral ligament, 287, 293, 324
Ischiopubic ramus, 278, 288, 292
Ischiorectal fossa, 263, 276, 279
Ischium, 286, 288, e10

J

Jaws, 13. *See also* Mandible; Maxilla.
Jejunal vessels, 238, 252, 266
Jejunum, 229, 231–232, 252
Jugular bulb, 59–60
Jugular foramen, 9, 11, 78–79
Jugular fossa, 23

Jugular lymphatic trunk, 36–37
Jugular notch, 176–178, 205
Jugular vein. *See* Anterior jugular vein; External jugular vein; Internal jugular vein.
Jugulodigastric lymph nodes, 32
Jugum, 11, 25

K

Kidneys, 253–259, e9
  calices of, 250, 255, 259
  congenital variants of, 280f
  hilum of, 217, 250, 254
  laparoscopic view of, 255
  pelvis of, 254–255, 259
  surface markings of, 217, 253
Klumpke's paralysis, 171f
Knee, 328–337
  arthroscopic views of, 334–336
  aspiration from/injection into, 355f
  dislocation of, 355f
  imaging of, 332, 334
  joint of, 332–335
  ligaments of, 332, 334–335
  radiographs of, 336
  replacement surgeries for, 355f
  surface features of, 328
Kyphosis, 83

L

Labium majus, 224, 276
Labium minus, 272, 276–277
Labyrinthine artery, 69
Labyrinthitis, 81f
Lacrimal artery, 54, 56–57, 74
Lacrimal bone, 1, 4, 12, 21
Lacrimal canaliculus, 44, 54
Lacrimal caruncle, 54
Lacrimal catheters, 54
Lacrimal gland, 54–57
Lacrimal groove, 21
Lacrimal hamulus, 21
Lacrimal nerve, 54–56, 75
Lacrimal papilla, 54
Lacrimal process, 26
Lacrimal punctum, 54
Lacrimal sac, 4, 12, 54
Lactiferous duct, 179
Lacunar ligament, 261, 264, 269, 271
  attachments for, 291, 293
Lambda, 7–8
Lambdoid suture, 3–4, 7–8
Lamina terminalis, 66
Laminae, vertebral, e7
  cervical, 69, 85–86, 107
  lumbar, 88, 99
  sacral, 89, 91
  thoracic, 86–87, 211
Laminectomy, 108f
Laparoscopy, 282f
  of abdominal cavity, 220
  of abdominal viscera, 227, 229f, 244f
  of appendix, 252
  of deep inguinal ring, 223, 225
  of female pelvis, 274
  of gall bladder, 231f
  of kidney, 255, 258
  of lesser omentum, 230f
  of small intestine, 252
  of spleen, 249f
Large intestine
  carcinoma of, 280f
  radiograph of, 240
Laryngeal nerve palsy, recurrent, 82f
Laryngeal prominence, 30, 48
  surface marking of, 28, 205
Laryngeal ventricle, 50
Larynx, 48–50
  inlet of, 49–50, 52
  intrinsic muscles of, 49–50
  sinus of, 50
  vestibule of, 50
Lateral aortic lymph node, 367
Lateral circumflex femoral artery, 220, 319, 322
Lateral costotransverse ligament, 175, 211
Lateral crico-arytenoid muscle, 49
Lateral cuneiform, 310, 312, 315, 354
Lateral cutaneous nerve
  of calf, 329, 338–339
  of forearm, 143, 147–149
  of thigh, 223, 366–368
Lateral femoral cutaneous nerve, 261–262, 322, e6
Lateral geniculate body, 64
Lateral glosso-epiglottic fold, 49
Lateral ligament of carpometacarpal joint, 163
Lateral malleolus, 307, 340–341, 344
Lateral meniscus, 332–333, 335, 338
  attachments of, 305, 341
  laparoscopic view of, 334
Lateral pectoral nerve, 129, 138–140
Lateral plantar artery, 350–352
Lateral plantar nerve, 348–351
Lateral pterygoid muscle, 42–44
  attachments for, 10, 19
  nerve to, 75–76
Lateral pterygoid plate, 7, 9–10, 12
Lateral rectus, 56–57, 74, e7
Lateral sacral artery, 268–270
Lateral sulcus, 63
Lateral superficial vein of penis, 265
Lateral sural cutaneous nerve, 342
Lateral talocalcanean ligament, 313
Lateral tendon ("wing tendon"), 166
Lateral thoracic artery, 129, 139–140, 363
Lateral umbilical fold, 222–223
Lateral ventricle, 65, 67, 71–72
Latissimus dorsi, 101–103, e3
  attachments for, 111, 115, 175
  cross-section of, e9
  surface marking of, 84, 130, 180
Left atrium, 186, 189, 191, 202
  auricle of, 185–186, 191
  radiographs of, 214
Left coronary artery, 188, 191
  anterior interventricular (descending) branch of, 185–186, 190
  circumflex branch of, 186, 190–191
  imaging of, 190–191
  marginal branch of, 190–191
  ostium of, 189
Left ventricle, 185–186, 188, 191
  enlargement of, 215f
  imaging of, 196
Leg, lower, 337–357
  ankle and, 346
  calf of, 339, 341–342
  knee and, 338–357
  popliteal fossa and, 341–343
  ulceration of, 357f
  veins and nerves of, 340
Lens, e7
Lentiform nucleus, 70–72, e7
Lesser occipital nerve, 29, 31–33
Lesser omentum, 230, 233–234, 245
Lesser palatine foramina, 9
Lesser palatine nerves, 44, 58
Lesser petrosal nerve, 44, 78–79
  groove for, 11, 23
  hiatus for, 11, 23, 51
Lesser sac, 226, 230–231, 233
Lesser sciatic foramen, 271
Lesser sciatic notch, 286, 288, 292, 325
Levator anguli oris, 2, 6, 39
Levator ani, 269, 271, 318
  attachments for, 289
  cross-section of, e10
  in female, 273, 276–277
  in male, 225, 264, 268
  nerves to, 269, 271
Levator costae, 175
Levator labii superioris, 2, 6, 39
Levator labii superioris alaeque nasi, 2, 6, 39
Levator palpebrae superioris, 54–56, 74
Levator scapulae, 102, e2–e3, e7
  attachments for, 111, 113
  neck and, 29, 31, 33, 36
  shoulder and, 132–135
Levator veli palatini, 10, 47
Lienorenal ligament, 226, 249–250
Ligamentum arteriosum, 195
Ligamentum flavum, 99
Ligamentum nuchae, 104–105, e7
Ligamentum teres, 227–229, 245
Ligamentum teres femoris, 325–327
Ligamentum venosum, 241, 245–246
Light reflex (cone of light), 60
Limbs. *See* Lower limb; Upper limb.
Limbus
  corneal, 54
  right atrial, 187
Linea alba, 218–220, e9
Linea aspera, 296, 298
Linea semilunaris, 218, 220, 222, e9
Lingual artery, 31–32, 34–35
Lingual gyrus, 66–67
Lingual nerve, 29, 35, 75–76
Lingual tonsil, 360
Lingual vein, 31–32
Lingula, 17–18
Linguofacial trunk, 29
Lithotomy position, 277, 279
Liver, 227, 244–248, e4, e9
  abscess of, 282f
  biopsy of, 282f
  caudate lobe of, 234, 237, 241, 245
  cirrhosis of, 280f
  laparoscopic view of, 220
  left lobe of, 228, 230, 233–234
  portal venous system of, 248
  quadrate lobe of, 230, 234, 236, 245
  Riedel's lobe of, 235
  right lobe of, 229–231, 233
  surface marking of, 217
  trauma to, 282f
Long ciliary nerve, 56–57, 75
Long plantar ligament, 311, 349, 353
Long thoracic nerve, 129, 138, 140–141
Longissimus, 101–103
Longissimus capitis, 10
Longitudinal fissure, 62, 64
Longus capitis, 10, 36, 69
Longus colli, 36, 361–362, e7
Lordosis, 83
Lower limb, 285–357
  ankle and foot of, 344–349
  bones of, 285–337
  clinical thumbnails for, 355–357
  gluteal region of, 316–317
  hip joint of, 324–327
  knee of, 328–337
  leg of, 337–357
  surface features of, 285–337
  thigh of, 318–323
Lower subscapular nerve, 141–142
Lumbar crossover, 362
Lumbar fascia, 257, 260
Lumbar hernia, 282f
Lumbar lymph nodes, 359
Lumbar nerves, 95, 97–98, e6
  cutaneous branches of, 316
  dorsal rami of, 91, 98, 102
  roots of, 97, 324
  ventral rami of, 91, 98, 262
Lumbar plexus, 262, e5
Lumbar plexus block, 356f
Lumbar puncture, 108f
Lumbar region, 217
Lumbar spine, 97–99
  lymphatics of, 359
  stenosis of, 108f
Lumbar sympathectomy, 282f
Lumbar triangle, 101–102
Lumbar vertebrae, 83, 88, e1
  developmental origins of, 93
  fracture of, 108f
  imaging of, 97, 106–107
  intervertebral discs of, 97–99
  lordosis of, 83
  sacralization of fifth, 91, 108f
  spinal cord and, 97–99
  surface marking of, 217
Lumbosacral trunk, 262–263, 269, 271

Lumbricals
of foot, 350–352
of hand, 157–160
Lunate, 122–123, 163, 167
dislocation of, 170f
joint surfaces of, 120, 122, 168
Lunate sulcus, 63, 70
Lung, 184, 197–204, e8
apex of, 37, 205
bronchogram of, 200–201
carcinoma of, 215f
inferior lobe of, 180, 184, 197t–198t, 199–200
middle lobe of, 180, 184, 197t–198t, 199–201
oblique fissure of, 180, 184, 201
roots of, 192, 194–195, 202
superior lobe of, 180, 184, 197t–198t, 199–201
surface markings of, 178
transverse fissure of, 180, 184, 204
Lymph nodes, 359. *See also* Inguinal lymph nodes.
arterial supply to, 366
axillary, 129, 179, 363–364, 369f
cervical, 80f, 361
Cloquet, 368
cubital, 364
enlarged coeliac, 234
iliac, 270, 359, 366–367
inguinal, 368
jugulodigastric, 32
pre- and para-aortic, 235, 258, 260, 367
tracheobronchial (subcarinal), e8
Lymphadenopathy, 369f
inguinal, 281f
pelvic, 366–367
thigh, 368
Lymphangiogram, 362
Lymphangioma circumscriptum, 369f
Lymphangitis, 369f
Lymphatic ducts, 31, 36, 359
Lymphatic system, 359, 369f
Lymphatic vessels, 220, 258
axillary, 363–364
cervical, 361
inguinal or thigh, 368
Lymphatics, 359–369
axillary, 363–364
breast, 179
cisterna chyli of, 365
clinical thumbnails for, 369
cubital fossa, 364
palatine tonsils of, 360
pelvic, 366–367
thigh, 368
thoracic duct of, 361–362
thymus of, 360
Lymphoedema, 369f
Lymphogranuloma venereum, 369f
Lymphoma, 369f

M

Macrodacryocystogram, 54
Macula, 73
Magnetic resonance (MR) images
of ankle/foot, 347, 354
of brain, 65, 68, 71
of elbow, 147
of face, 43, 58
of head, 52
of hip joint, 326
of knee, 332, 334
of liver, 244f
of lumbar region, 97
of pelvis, 273
of shoulder, 136
of thigh, 322–323
of wrist/hand, 159, 167
Male
abdominal wall of, 221
genitalia of, 265
groin of, 220
inguinal region of, 224–225, 265, 267
nipple of, 126
pelvis of, 92, 225, 264, 266–268, e10
perineum of, 278–279
sacrum of, 89
Malignant melanoma, 356f
Mallet finger, 171f
Malleus, 60–61
Mamillary bodies, 64–66
Mamillary process, 88
Mammary gland, 179. *See also* Breast.
Mandible, 18, 30, e1
alveolar part of, 13, 18
angle of, 17–18, 28, 38
base of, 18
body of, 1, 4, 16–17
condyle of, 4, 18
coronoid process of, 4, 18
edentulous, 13
fetal, 14
fractured, 80f
head of, 18, 38
imaging of, 43
muscle attachments of, 19
ramus of, 1, 4, 16–17
teeth of, 13
Mandibular canal, 42
Mandibular foramen, 17–18
Mandibular fossa, 7, 9, 23
Mandibular nerve, 42, 44, 75–76
dermatome for, e6
pharynx and, 47
Mandibular notch, 18
Manubriosternal joint, 176–178, 205
Manubrium, 173, 176–177, 205
Marginal artery, 239
Marginal tubercle, 12, 24
Masseter, 32–34, 39
attachments for, 2, 6, 10, 19
nerves to, 75–76
Mastectomy, 216f
Mastication, muscles of, 43
Mastoid air cells, 60–61
Mastoid antrum, 60–61
Mastoid fontanelle, 14
Mastoid foramen, 9
Mastoid notch, 7, 9, 23
Mastoid process, 4, 7, 9, 16
Mastoiditis, 81f
Maxilla, 1, 4, 21, 26
alveolar process of, 17, 21
articulations of, 22, 26
fetal, 14
frontal process of, 1, 4, 12, 21
infratemporal surface of, 7, 21
orbital surface of, 12, 21
palatine process of, 9, 12, 17, 21
teeth of, 13
tuberosity of, 7, 9, 21
Maxillary artery, 42, 47, 59, 74
Maxillary nerve, 44, 74–76
dermatome for, e6
orbit and, 57
Maxillary process, 26
Maxillary sinus, 3, 16, 44
imaging of, 43, 58
opening of, 12, 58
McBurney's point, 221, 282f
Meckel's diverticulum, 282f
Medial antebrachial cutaneous nerve, e6
Medial calcanean nerve, 340, 345–346
Medial circumflex femoral artery, 319, 322
Medial collateral ligament. *See* Deltoid ligament.
Medial cuneiform, 310, 312, 315, 354
Medial cutaneous nerve
to arm, 141–142, 148–149
to forearm, 138–139, 141–142
Medial femoral cutaneous nerve, 329
Medial geniculate body, 64
Medial malleolus, 306–307, 340–341
Medial meniscus, 332–333, 335–336
attachments of, 305
laparoscopic view of, 334
Medial palpebral ligament, 38, 54
Medial patellar retinaculum, 323
Medial pectoral nerve, 129, 138–139
Medial plantar artery, 349, 351–352
Medial plantar nerve, 348, 350–352
Medial pterygoid muscle, 42, 44, 47, 59
attachments for, 10, 19
nerve to, 59, 75
Medial pterygoid plate, 7, 9–10, 12
Medial rectus, 55–56, 74, e7
imaging of, 58
nerve to, 55, 57
Medial sural cutaneous nerve, 342
Medial talocalcanean ligament, 313
Medial umbilical fold, 222–223, 225
Medial umbilical ligament, 225, 272, 366
Median arcuate ligament, 260
Median artery, 145, 149
Median basilic vein, 147
Median cephalic vein, 147
Median cubital vein, 148, 150, 364
Median eminence, 65–66
Median forearm vein, 148, 150, 364, e4
Median nerve, 129, e5–e6
arm (upper) and, 143
axilla and, 138, 140–142
digital branches of, 159–160
elbow and, 145, 147
forearm and, 148–151
hand and, 154, 157–159
palmar branch of, 150, 157–159
palsy of, 171f
recurrent (muscular) branch of, 157–160
roots of, 142, 364
wrist and, 168
Median palatine (intermaxillary) suture, 9
Median pectoral nerve, 141
Median sacral artery, 324
Median sulcus, 69
Median umbilical fold, 222–223
Median umbilical ligament, 225, 272
Mediastinal lymph nodes, 179, 359
Mediastinal lymphatic trunk, 36
Mediastinum, 192–196
imaging of, 196
lung roots and pleura of, 192, 194–195
posterior, 209–210
superior, 205–207
Medulla oblongata, 63–66
imaging of, 52
olive of, 65, 67–68, 71
pyramid of, 65, 67–68, 71
Meibomian cyst, 81f
Melanoma, malignant, 356f
Meniscal tears, 356f. *See also* Lateral meniscus; Medial meniscus.
Menstruation, imaging during, 273
Mental foramen
skull and, 1, 4, 13, 16
surface marking of, 38
Mental nerve, 38, 40, 75–76
Mental protuberance, 1, 4, 17–18
Mental spines, 18
Mental tubercle, 18
Mental vessels, 38
Mentalis, 2, 19, 40
Meralgia paraesthetica, tears of, 356f
Mesenteric vessels, 248
Mesentery, 226, 231–233
jejunal and ileal areas of, 238, 251–252
of small intestine, 232, 250
Mesoappendix, 232, 251
Mesocolon, 231, 233, 275
Mesosalpinx, 274
Mesothelioma, 216f
Mesovarium, 274
Metacarpal arterial branch, 158
Metacarpals, 122–123, 167, e1
base of, 122–123, 155, 163
head of, 122–123, 154–155
ossification of, 125
Metacarpophalangeal joints, 124, 163
movements at, 155, 155b
palmar ligament of, 163
Metatarsal bones, 285, 310, 348, e1
first, 312, 344, 349, 353
fractures of, 356f
imaging of, 354

Metatarsal bones *(Continued)*
ossification of, 314–315
surface features of, 344
Metatarsophalangeal joints, 348–349, 353
Midaxillary line, 178
Midbrain, 51–52, 64, 66
aqueduct of, 64, 66, 72
imaging of, 65, 67
Midcarpal joint, 123, 167–168
Midclavicular line, 178
Middle cardiac vein, 186, 191
Middle cerebral artery, 65–66, 68
Middle cervical ganglion, 35–36
Middle colic artery/vessels, 238, 243, 248
Middle constrictor of pharynx, 45, 47–48
Middle cranial fossa, 11, 51
Middle ear, 60–61, 81f
Middle frontal gyrus, 63
Middle genicular artery, 331
Middle meningeal artery, 4, 42, 47, 76
Middle meningeal vessels, 51
branches of, 24
grooves for, 8, 11, 17, 23
Middle nasal concha, 1, 16, 26, 43
Middle rectal artery, 268, 270, 275
Middle temporal artery, groove for, 23
Middle temporal gyrus, 63
Middle thyroid vein, 29, 37
Midinguinal points, 217, 221
Milroy's disease, 369f
Mitral valve, 188–189
disease of, 216f
surface marking of, 178
Moderator band, 187
Molar salivary glands, 29
Molar teeth, 6–7, 13, 21
Mons pubis, 218–219, 276
Morison's pouch, 233
Mouth, lateral angle of, 38
MR images. *See* Magnetic resonance (MR) images.
Multifidus, 103
Mumps, 81f
Muscles, e2–e3. *See also specific muscle.*
Muscular transposition, 356f
Musculocutaneous nerve, e5–e6
arm and, 143
axilla and, 138–140, 142
shoulder and, 129, 136
Musculophrenic artery, 213
Musculus uvulae, 10
Mylohyoid, 29, 32–34
anomalous fibres of, 30
attachments for, 19, 48
nerve to, 29, 42, 59, 75
Mylohyoid line, 17–18
Mylohyoid nerve, 17, 29
Myocardial infarction, 216f
Myometrium, 273

N

Nail abnormalities, 171f
Naris, 38
Nasal bone, 1, 4, 12, 21
Nasal cartilage, 77
Nasal cavity, 12, 58, e7
Nasal conchae, 58–59. *See also* Inferior nasal concha; Middle nasal concha; Superior nasal concha.
Nasal crest, 21–22
Nasal polyps, 81f
Nasal septum, 17, 43
bony part of, 1, 12, 52–53
cartilaginous part of, 59
endoscopic views of, 43, 47
imaging of, 3, 16, 58
Nasal spine, 20
anterior, 1, 4, 21
posterior, 9, 22
Nasalis, 2, 6, 39
Nasion, 1, 4
Nasociliary nerve, 44, 54, 74–75
Nasogastric intubation, 81f
Nasolabial groove, 38
Nasolacrimal canal, 12, 54
Nasolacrimal duct, 54, 58
Nasopalatine nerve/vessels, 25
Nasopharyngeal tonsil, 52, 360
Nasopharynx, 52
Natal cleft, 101, 316
Navicular, 310, 312, 348–349
imaging of, 354
tuberosity of, 344, 352–353
Neck, 28–35, e7
arteries of, fetal, 15
clinical thumbnails for, 80
root of, 36–37, 207
surface markings of, 28, 205
thoracic duct termination in, 359, 361–362
Nephrectomy, 282f
Nephrocalcinosis, 282f
Nerve root cyst (Tarlov), 273
Nerves, e5. *See also specific nerve.*
Nervi erigentes (pelvic splanchnic nerves), 78, 261, 269
Nervus intermedius, 53, 79
Newborn infant, jaws of, 13
Nipple of breast, 179
retraction of, 216f
surface marking of, 126, 178
Nose, 38, 58–59
Nuchal lines
highest, 7, 27
inferior, 7, 9, 27
superior, 7, 9, 27
Nucleus pulposus, 99

O

Obex, 69
Oblique arytenoid, 47, 49
Oblique sinus, 185
Obliquus capitis inferior, 105
Obliquus capitis superior, 105
Obturator artery, 225, 269
accessory, 223
pelvis and, 267–268, 270, 275
Obturator crest, 286, 292
Obturator externus, 324–325, e10
attachments for, 287, 293, 295, 297
Obturator foramen, 286, 288, 292
imaging of, 327
pelvis and, 92, 271
Obturator groove, 286, 288, 292
Obturator hernia, 282f
Obturator internus, 276, 317, e3, e10
attachments for, 289, 295, 297
fascia of, 269, 271, 276
pelvis and, 263–264, 269, 271
tendon of, 276, 317, 324
Obturator membrane, 271
Obturator nerve, 261–262, e5–e6
anterior branch of, 322, 324
female pelvis and, 270, 272, 275
male pelvis and, 263–264, 267–268
paralysis of, 356f
posterior branch of, 324
Obturator veins, 225, 270, 275
aberrant, 225
accessory, 268
Obturator vessels, 261, 271–272, 324
Occipital artery, 29, 34–36
Occipital bone, 4, 7–8, 27
cervical region and, 94, 96
fetal, 14
Occipital condyle, 7, 9, 17, 27
Occipital groove, 7, 9, 23
Occipital lobe, 63
Occipital pole, 62–63
Occipitofrontalis
aponeurosis of, 5
frontalis part of, 39, e2
occipital part of, 6, 10, 104
Oculomotor nerve (III), 44, 59, 74
brain and, 64–65, 67–68
cranial cavity and, 51, 53
inferior division of, 57
orbit and, 55
palsy of, 81f
Odontoid peg (dens)
fracture of, 108f
spinous process of, 106
Oesophageal artery, 365
Oesophageal groove, 245
Oesophageal plexus, 209
Oesophageal varices, 282f
Oesophagus, 192–193, 210, e8
carcinoma of, 215f
cervical part of, 36, 214
diaphragm and, 213, 217, 260
imaging of, 196, 214
stomach and, 241
tendon of, 48
thoracic part of, 210, 214
Olecranon, 119–120, 145
Olecranon bursa, 145
Olecranon bursitis, 171f
Olecranon fossa, 117, 146–147
Olecranon process, 116, 146–147
Olfactory bulb, 51, 64–65, 73
Olfactory mucosa, 73
Olfactory nerve (I), 58, 73
Olfactory tract, 43, 51, 53, 64
Omental bursa, 230–231
Omental cake, 282f
Omental tuberosity, 245
Omentum. *See* Greater omentum; Lesser omentum.
Omohyoid, 133, 135, 139–140
attachments for, 48, 111, 113
inferior belly of, 28–31
superior belly of, 29–32
tendon of, 31, 138
Omphalocele, 282f
Ophthalmic artery, 54, 56–57, 66
Ophthalmic herpes zoster, 81f
Ophthalmic nerve, 44, 59, 75, e6
Ophthalmoscopy, 73, 81f
Opponens digiti minimi
of foot, 311
of hand, 124, 160, 162
Opponens pollicis, 124, 158, 162
Opposition, thumb, 156, 163
Optic canal, 11–12, 25, e7
Optic chiasma, 51, 64–65, e7
Optic disc, 73
Optic nerve (II), 43–44, 73, e7
brain and, 64–65, 67, 72
ciliary ganglion and, 74
cranial cavity and, 51, 53
orbit and, 54–57
trigeminal nerve and, 59, 75
Optic radiation, 70, 72, e7
Optic tract, 51, 64–65, 71
Oral cavity, 43
Oral pathology, 81f
Orbicularis oculi, 2, 6, 39, e2
Orbicularis oris, 39–40, e2
Orbit, 1, 44, 54–57, 74
blow-out fractures of, 80f
bones of, 12
cellulitis of, 81f
Orbital fat, 54, e7
Orbital sulcus, 65
Oropharynx, 52, 73, 214
Os trigonum, 356f
Osgood–Schlatter's disease, 356f
Ossification
of lower limb bones, 314–315
of upper limb bones, 125
of vertebrae, ribs, and sternum, 93
Otalgia, 81f
Otic ganglion, 44, 76, 78
Oval window, 60–61
Ovarian vessels, 99, 260, 274
Ovary, 273–274
carcinoma of, 280f
dermoid of, 282f
ligament of, 272, 274

P

Pacemaker
cardiac, 215f
gastric, 281f
Painful arc syndrome, 171f
Palate, 43
cleft, 80f

Palate *(Continued)*
hard, 9, 43, 52, 54
soft, 47, 52
Palatine bone, 12, 16, 22, 26
horizontal plate of, 7, 9, 12, 17
orbital process of, 12, 22
perpendicular plate of, 12, 22, 26
pyramidal process of, 7, 9, 22
Palatine grooves and spines, 9
Palatine tonsils, 360
Palatinovaginal canal, 9
Palatopharyngeus, 10, 47
Palm of hand, 154, 157–163
Palmar aponeurosis, 157
Palmar arteries, arteriogram of, 161
Palmar digital arteries, 158, 160–161
Palmar digital nerves, 157–158, 160, 162
Palmar interossei, 124, 162, 166
attachments for, 124
Palmar ligament
of carpometacarpal joint of thumb, 163
of metacarpophalangeal joint, 163
Palmar metacarpal arteries, 161–162
Palmar radiocarpal ligament, 163
Palmar ulnocarpal ligament, 163
Palmaris brevis, 154, 157–159
Palmaris longus, 150, 154, 158, 168
Pampiniform venous plexus, 265
Pancoast tumour, 216f
Pancreas, 233, 243, e9
body of, 235, 247, 260
carcinoma of, 280f
head of, 235, 243, 247–248
neck of, 243
pathology of, 282f
surface marking of, 217
tail of, 235, 243, 247, 249
uncinate process of, 235, 243
Pancreatic duct
accessory (Santorini), 247
of Wirsung, 236, 247–248
Pancreaticoduodenal vessels, 248
Pancreatitis, 282f
Papillary muscles, 187–188
Para-aortic lymph nodes, 235, 258, 260
Para-aortic lymph vessels, 362
Paracolic gutter, 226
Parahippocampal gyrus, 65, 67
Paraphimosis, 282f
Parasternal nodes, 179
Parasympathetic ganglia, 76
Para-umbilical hernia, 283f
Parietal bone, 24
mastoid angle of, 17, 24
skull and, 4, 7–8, 17
Parietal eminence, 8
Parietal foramina, 7–8, 24
Parietal lobe, 63
Parietal notch, 23
Parietal tuberosity, 14, 24
Parieto-occipital sulcus, 62–63, 66–67
Parotid duct, 29, 38, 40
Parotid gland, 30, 32–34
accessory, 39
face and, 39–40
Parotid plexus, 77
Parotid tumours, 81f
Parotidectomy, 81f
Pars flaccida, 60
Pars interarticularis, 107
Pars tensa, 60
Pars triangularis, 63
Patella, 285, 299, 334, e1
bipartite, 355f
dislocation of, 355f
fracture of, 356f
ossification of, 315
radiographs of, 336
surface marking of, 328
Patellar ligament (tendon), 333–335, e2
attachments for, 299, 303, 305
surface marking of, 328
Patellar tendon reflex, 356f
Pectinate muscles, 187, 189
Pectineal ligament, 261, 271, 291, 293
Pectineal line, 327
of femur, 294, 298
of pubis, 92, 288, 290, 292, 294
Pectineus, 321–322, 326, e10
attachments for, 291, 293, 297–298
pelvis and, 263, 267
Pectoralis major, 127–128, 138, e2
attachments for, 113, 115, 177
cross-section of, e8
surface marking of, 28, 126, 180
Pectoralis minor, 129, 138, 140, e2
attachments for, 111
cross-section of, e8
Pelvic brim (inlet), 92, 223, 290
Pelvic splanchnic nerves, 78, 261, 269
Pelvic walls, 261–264
Pelvis
bony, 92, 271, 286
clinical thumbnails of, 280
cross-sections of, e10
female, 270, 273–277, 366
ligaments of, 271
lymphatics of, 359, 366
male, 225, 264–268, 278–279
muscles of, 263–264
renal, 254–255, 259
vessels and nerves of, 269–270
Pelvi-ureteric junction, 255, 259
Penis, 220, 265, 267, e10
glans of, 265, 321
root of, 278
Perforating arteries, 319
Perforating cutaneous nerve, 279, 316
Perforating veins, 340
Pericallosal artery, 66
Pericardial cavity (space), 185, 195
Pericardial effusion, 216f
Pericardial fat, 244
Pericardiophrenic vessels, 194–195
Pericardium, 184–185
fibrous, 184–185, 207, 213
mediastinum and, 192–195
parietal, 184
serous, 185
sternal contact with, 177
visceral, 184
Perineal artery, 279
Perineal body, 276, 278
Perineal membrane, 277–279
Perineal muscles, 273
Perineal nerve, 279
Perineum
female, 276–277
male, 278–279
Periorbital haemorrhage, 81f
Periosteum, 5
Peripheral nerves, e6
Perirenal fat, 257, e9
Peritoneal folds, abdominal, 226
Peritoneal lavage, 282f
Peritoneum, 251, 257, 275
diagram of, 233
of greater sac, 250
hepatorenal pouch of, 233
parietal, 223, 227, 231–232
visceral, 223, 234
Peritonitis, 282f
Peroneal (fibular) artery, 343, 347, e4
Peroneal (tibial) muscles, e2
Peroneal (fibular) nerves, e6
Peroneal (fibular) vein, 342
Peroneus (fibularis) brevis, 341
ankle/foot and, 345, 347–348
attachments for, 309, 311
groove for, 308, 349
surface features of, 344
Peroneus (fibularis) longus, 337–339, 341
ankle/foot and, 345, 347–348, 353
attachments for, 305, 309, 311
groove for, 310, 353
surface features of, 344
Peroneus (fibularis) tertius, 345, 347–348
attachments for, 309, 311
Pes hippocampi, 72
Pes planus, 355f
Petrosal nerves, 11, 44
Petrosquamous fissure, 9, 23
Petrotympanic fissure, 9, 23
Phalanges
of thumb and fingers, 122, 124, 155, e1
ossification of, 125
radiographs of, 169
of toes, 285, 310, 349, e1
ossification of, 314–315
radiographs of, 354
Pharyngeal plexus branches, 78
Pharyngeal pouch, 81f
Pharyngeal raphe, 10, 45
Pharyngeal tonsil, 52, 360
Pharyngeal tubercle, 9, 27, 45
Pharyngeal veins, 45, 47
Pharyngitis, 81f
Pharyngobasilar fascia, 45
Pharynx, 45–47
laryngeal part of, 50, 52
'opened', 47
oral part of, 52
posterior surface/wall of, 45–46, 49
radiograph of, 30
Philtrum, 38
Phimosis, 282f
Phrenic artery, 254
Phrenic nerve, 36–37, 129, 138
accessory, 37
mediastinum and, 192–195
neck and, 29–30, 32, 35
palsy of, 216f
Phrenicocolic ligament, 226
Pia mater, 96
Pineal body, 66–67
Piriform fossa (recess), 47, 50, 214, e7
Piriformis, 263–264, 317, e3
attachments for, 91, 287, 295, 297
gluteal region and, 316f, 317
Pisiform, 122, 124, 154, 163
Pisohamate ligament, 124, 163
Pisometacarpal ligament, 124, 163
Pituitary apoplexy, 81f
Pituitary fossa (sella turcica), 4, 11–12, 17
Pituitary gland, 52–53, 58
Pituitary stalk (infundibulum), 51, 64–65, 67
Pituitary tumour, 82f
Plantar aponeurosis, 349–350
Plantar arch, 352, e4
Plantar calcaneocuboid (short plantar) ligament, 311, 349, 353
Plantar calcaneonavicular (spring) ligament, 311, 348–349, 353
Plantar cuboideonavicular ligament, 353
Plantar cuneonavicular ligament, 353
Plantar digital artery, 352
Plantar digital nerve of great toe, 352
Plantar fasciitis, 356f
Plantar interossei, 311, 352
Plantar metatarsal artery, 352
Plantar metatarsal ligament, 353
Plantaris, 330–331, 341–342
attachments for, 301, 311, 313
tendon of, 331, 342–343, 345
Platysma, 30, 33, 40, 43
attachments for, 2, 6, 19
cross-section of, e7
Pleura, 182, 184, 213
bony contacts of, 175, 177
costodiaphragmatic recess of, 250, 253
mediastinal, 192, 194–195
parietal, 192, 206–207
surface markings of, 178, 205
thoracoscopy of, 193
visceral, 184, 207
Pleural cavity, 360
Pleural effusion, 216f
Plica semilunaris, 54
Pneumoretroperitoneum, 282f
Pneumothorax, 216f
Pons, 52, 65–67

Popliteal artery, 319, 330–331, e4
aneurysm of, 356f
imaging of, 334, 343
Popliteal (Baker's) cyst, 356f
Popliteal fossa, 328, 330–331, 341–343
Popliteal vein, 319, 330, 334, e4
Popliteus, 331, 334, e3
attachments for, 301, 303, 305, 341
leg and, 338, 341, 343
tendon of, 300, 332–333, 335
Porta hepatis, 245
Portal vein, 248, e4, e9
branches of, 246, 248
liver and, 245–246
Postcentral gyrus, 62–63, 66
Postcentral sulcus, 62–63
Postcricoid venous plexus, 214
Posterior arch vein, 340, 346
Posterior auricular artery, 29
Posterior auricular vein, 32
Posterior cerebral artery, 51, 65, 67, 71
Posterior ciliary artery, 54, 56
Posterior circumflex humeral vessels, 137, 144
Posterior clinoid process, 25, 51
Posterior commissure, 66
Posterior communicating artery, 51, 64–66
Posterior cranial fossa, 11, 53
Posterior crico-arytenoid, 47–49
Posterior cruciate ligament, 332–335
attachments for, 301, 303, 305
laparoscopic view of, 334
rupture of, 356f
Posterior cutaneous nerve
of arm, 131, 133–134
of thigh, 317
Posterior ethmoidal canal, 20
Posterior ethmoidal foramen, 12
Posterior ethmoidal groove, 26
Posterior ethmoidal nerve, 75
Posterior femoral cutaneous nerve, e5–e6
gluteal branches of, 316
perineal branch of, 276, 279
Posterior fontanelle, 8, 14–15
Posterior gluteal line, 286
Posterior humeral circumflex artery, 139–140
Posterior inferior cerebellar artery, 65, 68–69
Posterior inferior iliac spine, 286, 288, 290
Posterior intercostal membranes, 181–182
Posterior interosseous artery, 152, 166
Posterior interosseous nerve, 147, 152
entrapment of, 171f
Posterior labial nerve, 276
Posterior lacrimal crest, 4, 12, 21
Posterior longitudinal ligament, 94, 98, 271
Posterior meningeal artery, 45
Posterior meniscofemoral ligament, 332, 334
Posterior nasal aperture. *See* Choana.
Posterior nasal spine, 9, 22
Posterior perforated substance, 64–66
Posterior scrotal vessels/nerves, 279
Posterior spinal arteries, 69, 94
Posterior superior alveolar nerves, 75–76
Posterior superior iliac spine, 101, 286, 288, 290
surface features of, 100, 316
Posterior talofibular ligament, 309, 341, 347, 349
Posterior tibial artery, 331, 343, e4
ankle/foot and, 344–347
venae comitantes of, 345–347
Posterior tibial vessels, 342, 346, 348
Posterior tibiofibular ligament, 306, 309, 349
Posterior ulnar recurrent artery, 145, 149, 151
Posterior (right) vagal trunk, 241, 257, 365
Postglenoid tubercle, 23
Pott's fracture, 356f
Pre-aortic lymph nodes, 235, 258, 367
Pre-aortic lymph vessels, 362
Precentral gyrus, 62–63, 66
Precentral sulcus, 62–63
Prechiasmatic groove, 11, 25
Pregnancy, ruptured ectopic, 281f
Premaxilla, 58
Premolar teeth, 13
Pre-occipital notch, 63
Prepatellar bursitis, 356f
Prevertebral fascia, 361
Prevertebral region, 36
Priapism, 282f
Princeps pollicis artery, 158, 160–161, 166
Procerus, 2, 6, 39
Processus vaginalis (canal of Nuck), 224
Proctoscopy, 282f
Profunda brachii vessels, 137, 143–144
Profunda femoris artery, 319, 321–322, e4
Profunda femoris vessels, 326, e4
Profundus tendon, 158
Pronator quadratus, 121, 150–151, 162
Pronator teres, 148–150
attachments for, 117, 121
rough area for, 118
Proper hepatic artery, 234, 236–237
Prostate, 266–268
carcinoma of, 280f
enlarged, 268
transurethral resection of, 283f
Prostatic hyperplasia, benign, 280f
Prostatic venous plexus, 266
Psoas abscess, 282f
Psoas major, 263–264, e2, e9
attachments for, 295, 297–298
hip joint and, 326
Psoas minor, 289, 291, 293, 367
Psoas tendon, bursa for, 324
Pterion, 4, 17
Pterygoid canal, 25
nerve of, 44, 58
Pterygoid hamulus, 7, 9, 12, 17
Pterygoid notch, 25
Pterygoid process, 25
Pterygomandibular raphe, 19
Pterygomaxillary fissure, 7
Pterygopalatine fossa, 7
Pterygopalatine ganglion, 44, 58, 75
Pubic crest, 288, 290, 292
Pubic symphysis, 92, 269, 271, 327
female, 272, 277
male, 266, 268, 278
surface marking of, 221
Pubic tubercle, 92, 263, 286, 288
hip joint and, 327
surface marking of, 221
Pubis, 286, 288, 292
pecten of, 288, 290, 292, 294
rami of, 286, 288
Pubococcygeus, 264
Pubofemoral ligament, 293, 324
Puborectalis, 268
Pudendal block, 282f
Pudendal canal, 279
Pudendal nerve, 271, 276–277, e5
Pudendal vessels, 276, 318
Pulmonary arteries, 202–203, e4
left, 186, 196, 202, 204
right, 186, 202–204
Pulmonary arteriogram, 203
Pulmonary embolism, 216f
Pulmonary ligament, 204
Pulmonary trunk, 185, 196, e4, e8
heart and, 186–187, 189, 191
lungs and, 202–203
Pulmonary valve, 178, 188t, 189
Pulmonary veins, 185–186, 191, 202
Pulmonary vessels, 202
Pupil, 54
Pupillary reflex, 82f
Putamen, 70–71
Pyloric antrum, 241–242
Pyloric canal, 241–242
Pyloric stenosis, adult, 283f
Pylorus, 236
Pyramidalis, 218, 224, 291, 293

Q

Quadrangular ligament, 49
Quadrangular membrane, 50
Quadrangular space, 144
Quadratus femoris, 317, 319, e3, e10
attachments for, 287, 293, 295, 297
hip joint and, 325
Quadratus lumborum, 260–262, e9
attachments for, 175, 289, 291
Quadratus plantae (flexor accessorius), 311, 349, 351–352
Quadriceps, 285
Quadriceps tendon, 323, 334–335
attachments for, 299
rupture of, 356f
Quadrigeminal cistern, 65

R

Radial artery, 150–151, e4
dorsal branch of, 164
elbow and, 147
hand and, 157–159, 161
superficial palmar branch of, 160–161
surface marking of, 154
Radial bursa, 158
Radial collateral ligament, 146, 152, 167
Radial fossa, 116–117
Radial head, dislocation of, 170f
Radial nerve, 139, 142, e5–e6
arm (upper) and, 133, 143
branches of, 142, 165
elbow and, 147
groove for, 114, 144
palsy of, 171f
superficial, 151, 164
Radial notch, 119–120
Radial recurrent artery, 149, 151
Radialis indicis artery, 158, 160–161, 164
Radiate ligament, 211
Radicular vessels, 94, 96
Radiocarpal joint, 167. *See also* Wrist.
Radiographs
ankle, 354
breast, 179
chest, 360
elbow, 146
intestinal, 240
knee, 336
oesophageal, 214
shoulder, 137
skull, 3, 5, 15–16
stomach, 242
vertebral, 106–107
wrist/hand, 169
Radio-ulnar joint, 120, 146
distal, 163, 167
proximal, 147
Radius, 118, 120–121, 146, e1
head of, 118, 120, 145, 147
neck of, 118, 120, 146
ossification of, 125
styloid process of, 118, 120, 123, 154
Rami communicantes, 98, 193, 195, 211
Rectosigmoid foreign bodies, 283f
Rectosigmoid junction, 266, 272–273
Recto-uterine pouch (of Douglas), 250, 272–274
Rectovesical fascia, 268
Rectovesical pouch, 266
Rectum, 240, 261, e10
examination of, 283f
female pelvis and, 250, 272, 275
male pelvis and, 264, 267–268
prolapse of, 283f
Rectus abdominis, 218–220, e2
attachments for, 177, 291, 293
cross-sections of, e9–e10
pelvis and, 266, 272–273
Rectus capitis anterior, 10
Rectus capitis lateralis, 10, 36, 44, 69
Rectus capitis posterior major, 10, 105
Rectus capitis posterior minor, 10
Rectus femoris, 263, 321, 323, e2
attachments for, 287, 289, 291, 293
cross-section of, e10
nerve to, 322
Rectus sheath, 217, 219, 224
anterior, 127, 218–220
attachments for, 291, 293
haematoma of, 281f
posterior, 219, 223, e2

Recurrent laryngeal nerve, 47, 49–50, 78
  mediastinum and, 192, 195, 206
  neck and, 35–36
Renal artery, 239, 255, 260, e4
  accessory, 256
  anterior/posterior divisions of, 255
  left, 235, 254, 256–257
  right, 242, 254, 256
Renal biopsy, 283f
Renal capsule, 257
Renal carcinoma, 283f
Renal column, 250
Renal cyst, 235
Renal fascia, 257
Renal medulla, 250
Renal papilla, 250
Renal stone obstruction, 255
Renal trauma, 283f
Renal vein, 239, 260, e4, e9
  left, 235, 254, 256–257
  right, 242, 256, 258
Retina, 73
Retinacular ligament, 166
Retrocaecal recess, 251
Retromammary space, 179
Retromandibular vein, 32–33, 40, 42
Retroperitoneal bleed, 283f
Retroperitoneal fibrosis, 283f
Retropubic space (Retzius), 272–273
Rhomboid major, 101–103, e3
  attachments for, 111
  cross-section of, e8
  surface features of, 84, 100
Rhomboid minor, 102–103, 134, e3
  attachments for, 111
  shoulder and, 132–133, 135
  surface features of, 84, 100
Ribs, 173–175, e1, e9
  first, 37, 129, 175
  joints of, 94, 211
  muscles of, 181–183
  ossification of, 93
  radiographs of, 107, 170f
  second, 173, 175, 177, 181
  twelfth, 98, 173, 175, 183, 253
Riedel's lobe, liver, 235, 283f
Right atrium, 185–187
  auricle of, 185–186, 189
  tricuspid valve from, 189
Right coronary artery, 185–186, 189–190
  imaging of, 190–191
  marginal branch of, 185–186, 190
  posterior interventricular (descending) branch of, 186, 190–191
  right ventricular branch of, 190–191
Right ventricle, 185–188
  infundibulum of, 186–187, 189
Risorius, 40
Rostrum, 25
Rotator cuff tear, 171f
Round ligament of uterus, 218–219, 224, 366

S

Sacculations, 240
Saccule
  inner ear, 77
  laryngeal, 50
Sacral canal, 89–91, 264
Sacral foramina, 90–91
Sacral hiatus, 90
Sacral nerves, 264, 271, e6
  gluteal branches of, 316
  roots of, 97, 324
  stimulation of, 283f
  ventral rami of, 262, 268–269
Sacral plexus, 263, 271, e5
Sacral promontory, 89–90, 92, 271
Sacral vertebrae, 89–90, 93, 97
Sacralisation of fifth lumbar vertebra, 91, 108f
Sacrococcygeal joint, 269
Sacro-iliac joint, 92, 286, 288, 327
Sacro-iliac ligaments, 325
Sacrospinous ligaments, 271, 324–325
  attachments for, 289
  pelvis and, 269, 271
Sacrotuberous ligaments, 271, 317, 325
  attachments for, 289
  falciform process of, 271, 289, 325
  perineum and, 276–277, 279
Sacrum, 83, 89–92, e1
  in female, 92, 276
  ossification of, 93
  surface features of, 84
Sagittal crest, 20
Sagittal suture, 7–8, 14
Sail sign, 360
Salpingitis, acute, 280f
Saphena varix, 368
Saphenous artery, 338
Saphenous nerve, 329, 368, e5–e6
  ankle/foot and, 346–347
  infrapatellar branch of, 329, 338
  leg and, 338–340, 342
  thigh and, 321–323
Saphenous vein. *See* Great saphenous vein; Small saphenous vein.
Sarcoidosis, 216f
Sartorius, 321–323, e2
  attachments for, 287, 289, 293, 303
  cross-section of, e10
  leg and, 338, 341–342
  nerve to, 368
  pelvis/thigh and, 263–264
Scalenus anterior, 29–31, e2
  attachments for, 175
  cross-section of, e7
  shoulder/axilla and, 129, 138, 140
  tendon of, 30
Scalenus medius, 29–31, 129
  attachments for, 175
  cross-section of, e7
Scalenus posterior, 34, 175, e7
Scalp, 5
  infection of, 81f
  surgical flaps of, 82f
  wounds to, 82f
Scaphoid, 122–123, 163, 167
  articular surfaces for, 120, 168
  avascular necrosis of, 170f
  imaging of, 167, 169
Scaphoid fossa, 9, 25, 60
Scapula, 109–113, e1
  attachments for, 111, 113
  fractured, 171f
  ossification of, 125
  shoulder and, 132–135, 137
  spine of, 110, 112, 133, e3
  surface features of, 84, 100, 130, 180
  winging of, 172f
Scapular arterial anastomoses, 171f
Sciatic nerve, 317–318, e5, e10
  intramuscular injections and, 316
  surface marking of, 316
Sciatic trunk, 317, 319
Sclera, 54
Scottie dog sign, 107
Scrotal sac, 265
Scrotal swellings, 283f
Scrotal veins, 220, 368
Scrotum, 278
Sella turcica, 4, 11–12, 17
Semicircular canals, 14, 60–61
Semilunar ganglion, 74
Semilunar hiatus, 12, 58
Semimembranosus, 319, 323, e3
  attachments for, 287, 293, 303, 305
  groove for, 302, 304
  knee and, 330–331, 334–335
  nerve to, 319
  surface marking of, 328
  tendon of, 333
Seminal colliculus, 266, 268
Seminal vesicles, 266–268, e10
Semispinalis, 103
Semispinalis capitis, 10, 105, e3, e7
Semispinalis cervicis, 105
Semitendinosus, 318–319, 323, e3
  attachments for, 287, 293, 303, 305
  knee and, 329–331
  nerve to, 319
  surface marking of, 328
  tendon of, 333
Septomarginal trabecula, 187
Septum pellucidum, 66, 71
Serratus anterior, 127, 218, e2, e8
  attachments for, 111, 113, 175
  axilla and, 138–141
  back and, 102–103
  long thoracic nerve to, 129
  surface marking of, 126, 180
Serratus posterior inferior, 175
Serratus posterior superior, 133, 135, 175
Sesamoid bones
  of foot, 310, 353–354
  of hand, 163
Shenton's line, 327
Shin, 302
Short ciliary arteries, 57, 74
Short ciliary nerves, 56–57, 74–75
Short saphenous vein, 331
Shoulder, 126–137
  arthroscopy of, 129, 137
  imaging of, 136–137
  joint of, 109, 136–137
    injection into, 171f
    posterior dislocation of, 171f
  surface features of, 84, 126, 130
Sialectasis, 82f
Sigmoid colon, 250, 367
  pelvis and, 266–267, 272–273
  radiograph of, 240
Sigmoid mesocolon, 275
Sigmoid sinus, 69
  groove for, 11, 17, 23–24
Sigmoid vessels, 239, 248
Sigmoidoscopy, 282f
Sinu-atrial nodal artery, 190
Sinu-atrial node, 187
Sinus nerve, 34, 78
Sinus pathology, 82f
Situs inversus totalis, 283f
Skeleton, e1–e6
Skin
  orange peel texture of, 216f
  of scalp, 5
Skin tags, anal, 278
Skull, 1–17
  base of, 9–11, 82f
  bones of, 18–27
  cranial vault of, 8
  definition of, 1
  fetal, 8, 14–15
  fractures of, 82f
  infratemporal region of, 7
  muscle attachments of, 2, 6, 10
  nasal cavity of, 12
  orbit of, 8, 12
  pepperpot, 81f
  radiographs of, 3, 5, 15–16
  teeth and jaw of, 13
Slipped upper femoral epiphysis, 356f
Small cardiac vein, 185, 191
Small intestine, 227–228, 233, 252. *See also* Duodenum; Ileum; Jejunum.
  coils of, 231–232, 257, 266
  cross-section of, e9
  mesentery of, 232, 250
  radiograph of, 240
Small saphenous vein, 330, e4
  ankle/foot and, 344, 346–348
  leg and, 339–340, 342
Smith's fracture, 171f
Soleal line, 302, 304
Soleus, e2–e3
  attachments for, 303, 305, 309
  leg and, 338–339, 341–342
  tibial nerve branches to, 342
Somatic afferent nerves, 79
Speculum examination of cervix, 273
Spermatic cord, 220, 224, 265, e10

Sphenoethmoidal recess, 58
Sphenoid bone, 3, 12, 25
greater wing of, 1, 3–4, 7
jugum of, 11, 25
lesser wing of, 1, 3, 11–12
spine of, 7, 9, 25, 36
Sphenoidal fontanelle, 14
Sphenoidal sinus, 43, 47, 58, 73
cranial cavity and, 52–53
skull and, 12, 17, 25
Sphenomandibular ligament, 19, 59
Sphenomandibularis, 42–43
Sphenopalatine foramen, 12
Sphenopalatine nerve, 74–75
Sphenopalatine notch, 22
Sphenoparietal sinus, 51, 53
Sphincter urethrae, 289
Spigelian hernia, 283f
Spina bifida, 89
Spinal accessory nerve, 36, 67, 79, 96
brain and, 64–65, 68–69
cranial cavity and, 53
Spinal anaesthesia, 108f
Spinal cord, 94–99, e7, e9
brain and, 68–69
cervical region of, 94–96
clinical thumbnails for, 108
cranial cavity and, 52–53
lumbar region of, 97–99
thoracic region of, 95–97
Spinal nerves, e6. *See also* Cervical nerves; Lumbar nerves; Sacral nerves; Thoracic nerves.
compression of, 108f
roots and rootlets of, 96
Spinal vessels, 95–96
Spinalis, 101–102, e7
Spinalis cervicis, 105
Spine. *See also* Vertebral column.
malformations of, 108f
radiographs of, 107
Spinnaker sail (sail sign), 360
Spinous process
cervical, 85–86, 95–96
lumbar, 88, 91, 98
thoracic, 86–87, 97–98
Spleen, 235, 239, 249–250, e9
cysts of, 283f
infarct of, 283f
laparoscopic view of, 249f
lymphatics and, 359, 365
ruptured, 283f
Splenectomy, 283f
Splenic artery, 248, 250, e4, e9
Splenic flexure, 240, 249, 365
Splenic vein, 248, 250, e4, e9
Splenius capitis, 29, 104–105, e7
attachments for, 10
shoulder and, 132–133, 135
Splenius muscles, e3
Splenomegaly, 283f
Splenunculi, 283f
Spondylolisthesis, 108f
Spring ligament, 353
Squamotympanic fissure, 9, 23
Stapedius, 60–61
nerve to, 61
tendon of, 61
Stapes, 60–61
Stellate ganglion, 195, 208
Sternal angle, 176–177, 181, 183
Sternebrae, 176
Sternoclavicular joint, 37, 177, 196
attachments for, 113
dislocation of, 171f
surface marking of, 28, 178, 205
Sternocleidomastoid, 36, e2–e3, e7
attachments for, 6, 10, 113, 177
clavicular head of, 28, 30, 32, 128
neck and, 29, 31–33
sternal head of, 30, 32, 128, 205
surface marking of, 28, 178, 205
Sternocostal joints, 177
Sternohyoid, 29–31
attachments for, 48, 113, 177
Sternomastoid, 48
Sternothyroid, 29, 31–33
attachments for, 48, 177
nerve to, 129
Sternotomy, median, 216f
Sternum, 173, 176–177, e1, e8
manubrium of, 173, 176–177, 205
ossification of, 93
variants of, 216f
Stomach, 228, 233, 236, 241–243
body of, 241–243
carcinoma of, 280f
cross-section of, e9
fundus of, 237, 241
greater curvature of, 228, 231, 233–234
lesser curvature of, 230, 233–234, 237
radiography of, 214, 240, 242
Straight arteries (vasa recta), 238
Straight sinus, 51–53
Stroke, 70
Styloglossus, 10, 29, 35, 47
Stylohyoid, 29, 31–32, 34
attachments for, 10, 48
Stylohyoid ligament, 29, 35, 48
Stylomandibular ligament, 19
Stylomastoid foramen, 9, 14, 23, 60
Stylopharyngeus, 10, 35, 45, 47
Subacromial bursa, 136
Subarachnoid haemorrhage, 82f
Subarachnoid space, 55, 62, 97
Subarcuate fossa, 23
Subclavian artery, 30, 37, 207, e4
axilla and, 138–140
cross-section of, e8
groove for, 175, 204
left, 36, 195–196, 202
right, 36, 192–193, 206
stent in, 216f
Subclavian vein, 30–31, 206, e4
axilla and, 141, 207
catheterisation of, 82f, 215f
groove for, 175, 204
lymphatics and, 361–362
surface marking of, 28
Subclavius, 30, 129, 141, 363
attachments for, 113, 175
groove for, 112
Subconjunctival haemorrhage, 81f
Subcostal nerve, 235, 253, 258, 367
Subcostal vessels, 212, 253
Subdural haemorrhage, 82f
Sublingual fossa, 18
Sublingual gland, 29, 35
Submandibular duct, 29, 35, 59
Submandibular fossa, 18
Submandibular ganglion, 35, 59
Submandibular gland, 30, 32–33, 40
deep part of, 29
surface marking of, 28
Submandibular tumour, 82f
Submental artery, 31–32, 34
Submental vein, 32
Sub-occipital nerve, 105
Sub-occipital triangle, 104–105
Subphrenic abscesses, drainage of, 281f
Subpubic angle, 92
Subsartorial canal, 321
Subsartorial fascia, 321
Subscapular artery/vein, 363
Subscapular fossa, 110
Subscapular nodes, 179
Subscapular trunk, 139–141
Subscapularis, 129, 136–137, e8
attachments for, 113, 115, e2
axilla and, 139–142
Subscapularis bursa, 136–137
Substantia nigra, 64, 71
Subtalar joint, 313, 348
Sulci, 62–63
Sulcus terminalis, 49
Superciliary arch, 20
Superficial cervical artery, 29, 32, 36–37
Superficial cervical ganglion, 36
Superficial cervical vein, 32
Superficial circumflex iliac artery, 322
Superficial circumflex iliac vein, 267, 321, 368
Superficial dorsal nerve of penis, 265
Superficial dorsal vessels of penis, 265
Superficial epigastric artery, 322
Superficial epigastric vein, 321, 368
Superficial external pudendal artery, 322, 368
Superficial external pudendal vein, 321, 368
Superficial femoral artery, 319
Superficial inguinal ring, 218, 224, 262, 321
in male, 224, 265
surface marking of, 221
Superficial inguinal veins, 218
Superficial middle cerebral vein, 63
Superficial palmar arch, 154, 157–158, 160
Superficial peroneal (fibular) nerve, 337–338, 347, e5
branches of, 337, 345
dermatome for, e6
Superficial scrotal (dartos) fascia, 265
Superficial temporal artery, 29, e4
branches of, 5, 39
palpation of, 38
Superficial temporal vessels, 38–40
Superficial transverse metacarpal ligaments, 157
Superficial transverse metatarsal ligament, 350
Superficial transverse perineal muscle, 276–279
Superior articular facets, 85
Superior articular process, 86–89
Superior cerebellar artery, 51, 65, 67–68
Superior cerebral veins, 62–63
Superior cervical ganglion, 45, 47, 79
Superior colliculus, 66, 69
Superior constrictor of pharynx, 10, 19, 45, 47
Superior costotransverse ligament, 175, 211
Superior extensor retinaculum, 345, 347
Superior frontal gyrus, 62–63
Superior gemellus, 287, 293, 317
Superior gluteal artery, 268–270, 276
Superior gluteal nerve, e5
Superior gluteal vessels, 317–318
Superior hypogastric plexus, 239, 261
Superior ileocaecal recess, 251
Superior intercostal artery, 193, 195, 208
Superior intercostal vein, 193–195, 208
Superior labial artery, 40
Superior laryngeal artery, 29–32
Superior laryngeal nerve, 47, 78
Superior lateral genicular artery, 331, 343
Superior medial genicular artery, 331, 338, 343
Superior medullary velum, 69
Superior mesenteric artery, 235, 242–243, e4
cross-section of, e9
kidney and, 254, 256–258
Superior mesenteric artery syndrome, 283f
Superior mesenteric ganglion, 242
Superior mesenteric vein, 235–236, 243, e9
Superior mesenteric vessels, 235, 238, 243, 266
Superior nasal concha, 16, 26, 58–59
Superior oblique, 54–56, 74
attachments for, 10
tendon of, 54–56
Superior orbital fissure, 1, 11–12, 74
Superior peroneal (fibular) retinaculum, 341, 345
Superior petrosal sinus, 51
groove for, 11, 17, 23
Superior pubic ramus, 225, 327
Superior pulmonary veins
left, 185–186, 191, 202
right, 185–186, 191, 202
Superior rectal artery/vein, 239, 268
Superior rectus, 54–56, 74
nerve to, 55–57
Superior sagittal sinus, 47, 52–53, 62
groove for, 8, 11, 27
Superior salivatory nucleus, 79
Superior suprarenal artery, 242
Superior temporal gyrus, 63
Superior temporal line, 4, 20, 23
Superior temporal sulcus, 63
Superior thoracic artery, 139–141
Superior thyroid artery, 29–32
Superior thyroid vein, 29–30, 37

Superior transverse scapular ligament, 111, 113, 133, 135
Superior ulnar collateral artery, 143, 145, 149
Superior vena cava, 202, 212, e4, e8
groove for, 204
heart and, 185–187, 189
mediastinum and, 192–193, 196, 206
obstruction of, 216f
Superior vesical artery, 267–268, 270, 272
Supinator, 150–153
attachments for, 121
Suprachiasmatic cistern, 65
Supraclavicular fossa, 126, 205
Supraclavicular nerve, 30, 32, 128
Supraclavicular (Virchow) node, 179, 361, 369f
Supracondylar fracture and spur, 171f
Supracristal plane, 217
Supraglenoid tubercle, 112
Suprahyoid artery, 31–32
Supramarginal gyrus, 63
Suprameatal triangle, 23
Supra-orbital artery, 54–55
Supra-orbital foramen (notch), 1, 12, 20, 38
Supra-orbital margin, 1, 16, 20, 38
Supra-orbital nerve, 39, 74–76
eye and, 54–57
surface marking of, 38
Supra-orbital vessels, 38
Suprapatellar bursa, 335, 356f
Suprapatellar fat pad, 335
Suprapineal recess, 66, 72
Suprapleural membrane, 175
Suprapubic region, 217
Suprarenal arteries, 254
Suprarenal glands, 242, 250, 260
kidneys and, 254, 256f, 257–258
pathology of, 280f
Suprarenal veins, 254, 256–258
Suprascapular artery, 138, 140, 206–207
neck and, 30–33
shoulder and, 133–135
Suprascapular nerve, 138, 207
neck and, 31–32
shoulder and, 129, 133–135
Suprascapular notch, 110–111
Suprascapular vessels, 30, 136–137
Supraspinatus, e3
attachments for, 111, 113, 115
shoulder and, 132–135
tendon of, 129, 136–137
Supraspinous fossa, 110, 112
Supraspinous ligament, 97–99
Suprasternal notch, 173
Supratrochlear artery, 56
Supratrochlear nerve, 39–40, 74–75
orbit and, 54–57
surface marking of, 38
Supratrochlear vessels, 38
Supreme intercostal vein, 193, 208
Supreme nasal concha, 59
Sural nerve, 330–331, e5–e6
ankle/foot and, 345, 347–348
graft of, 356f
leg and, 339–340, 342
Sympathectomy, transthoracic, 216f
Sympathetic trunk (and ganglia), 206, 208, 211, 362
branches to greater splanchnic nerve, 192–193
mediastinum and, 192–193, 195, 209
neck and, 36, 45
pelvis and, 261–262, 269
vertebral column and, 96–98
Symphysis menti, 14
Synovial sheaths, wrist/hand, 158, 165
Systemic review, e1–e10

T

Taenia coli, 251
Talipes equinovarus, 356f
Talocalcanean joint, 313, 348–349
Talocalcaneonavicular joint, 313, 348–349
Talus, 312–313, 347, 349
attachments of, 313
head of, 310, 312–313
Talus *(Continued)*
imaging of, 354
neck of, 310, 312, 349
ossification of, 315
Tapetum, 72
Tarlov cyst, 273
Tarsal arteries, 348
Tarsal bones, 315, e1. *See also specific bone.*
Tarsal dislocations, 357f
Tarsal sinus, 312, 347, 354
Tarsal tunnel syndrome, 357f
Tarsometatarsal joint, first, 349
Tectorial membrane, 94
Teeth, 13
Tegmen tympani, 9, 11, 23, 60
Tela choroidea, 71
Temporal bone, 5, 23, 43, 60–61
mastoid process of, 4, 7, 9, 16
petrous part of, 9, 11, 17, 23
squamous part of, 4, 9, 11, 17
styloid process of, 4, 7, 9, 23
tympanic part of, 4, 9, 23, 36
zygomatic process of, 4, 23–24
Temporal fascia, 5, 39–40
Temporal fossae, 6, 41–42
Temporal lines, 40
Temporal lobe, 43, 64, 72, e7
Temporal pole, 63–64, 72
Temporal vessels, superficial, 60
Temporalis, 5, 40, 43, e7
attachments for, 2, 6, 19
deep head of, 42–43
nerves to, 75
Temporomandibular joint, 42
attachments for, 6, 10, 19
capsule of, 29, 40, 42
dislocation of, 82f
Tendocalcaneus, e3
ankle/foot and, 344–347
attachments for, 311, 313
leg and, 339–342
rupture of, 356f
Tendocalcaneus reflex, 355f
Tennis elbow, 171f
Tensor fasciae latae, 263, 321–322, e2
attachments for, 287
cross-section of, e10
Tensor tympani, 10, 23, 60
Tensor veli palatini, 10, 44, 59
Tentorium cerebelli, 44, 51–53
Teres major, 102, 131–132, e3
attachments for, 111, 113, 115
surface marking of, 130, 180
Teres minor, 102, 131–132, e3
attachments for, 111, 113, 115
Testicular artery, 251, 265
Testicular torsion, 283f
Testicular vein, 251
Testicular vessels, 223, 225, 261, 268
Testis, 265–266, 278
Thalamostriate vein, 70–71
Thalamus, 66, 70–71, e7
Thecal sac, 97, 250
Thenar eminence, 154
Thenar muscles, e2
Thigh, 318–323
anterior, 320–323
lymphatics of, 368
muscles of, 263
posterior, 318–319
Third occipital nerve, 104–105
Third ventricle, 70–72
lateral wall of, 66–67
suprapineal recess of, 66, 72
Thoracic cage, 173
Thoracic duct, 36, 202, 359
cervical part of, 362
mediastinum and, 195–196, 206, 209
termination of, 359, 361–362
Thoracic inlet (or outlet), 177, 206–208
Thoracic nerves, 95, 97, 138, e6
dorsal rami of, 95, 103, 131, 211
ventral rami of, 95, 211
Thoracic outlet syndromes, 216f
Thoracic spine, 95–98
Thoracic sympathectomy, 216f
Thoracic vertebrae, 86–87, 173, 202, e1
cleared specimens of, 98
developmental origins of, 93
joints with ribs of, 211
kyphosis of, 83
radiograph of, 106
spinal cord and, 95–97
surface marking of, 180
Thoracic wall, 178–183, 249
Thoraco-acromial artery, 129, 361, 363
Thoraco-acromial trunk, 138–139
Thoracodorsal artery, 139–141, 364
Thoracodorsal nerve, 138, 140–142
Thoracodorsal vein, 207
Thoracolumbar fascia, 84, 101–103
Thoracoscopies, 193, 216f
Thorax, 173–216
aorta and associated vessels of, 212
bones of, 173–177
breast of, 178–179
clinical thumbnails for, 215
cross-sections of, e8
diaphragm of, 213
heart of, 185–191
intercostal structures of, 210–211
lungs of, 197–204
lymphatics of upper, 362
mediastinum of, 192–196, 205–207, 209–210
muscles of, 181–183
oesophagus of, 210, 214
surface features of, 173–175, 178–180, 205
thoracic inlet of, 206–208
viscera of, 184
Thumb, 158
bones of, 122–125
carpometacarpal joint of, 163
gamekeeper's, 171f
movements of, 156, 163
tendons to, 166
Thymic artery, 206
Thymic veins, 195, 206, 360
Thymus, 206, 359–360
clinical thumbnails of, 216f, 369f
remnants of, 184, 206
Thyro-arytenoid muscle, 49
Thyrocervical trunk, 31, 36–37, 206
Thyro-epiglottic muscle, 49
Thyrohyoid, 29–32
attachments for, 48
nerve to, 32
Thyrohyoid membrane, 29, 31–33
Thyrohyoid nerve, 29, 31, 35
Thyroid cartilage, 33, 47–48, e7
articular site for, 50
surface marking of, 48, 205
Thyroid gland, 32–33, 138, e7
isthmus of, 28, 37, 50, 206
lateral lobe of, 29–30, 34, 206
surface marking of, 48, 205
Tibia, 285, 302–307, 343, e1
articulation with fibula, 307
attachments of, 303, 305–306
condyles of, 302, 304, 329, 333
fractures of, 357f
imaging of, 336, 354
knee and, 328, 332, 334
ossification of, 314
Tibial collateral ligament, 332, 334–335
attachments for, 301, 303, 305, 333
leg and, 338, 341
Tibial nerve, 317, 342–343, e5
ankle/foot and, 345–347
knee and, 330–331
Tibial plateau, 333, 335
Tibial tuberosity, 335–337
Tibialis anterior, 337, 353
ankle/foot and, 344–345, 347–348
attachments for, 303, 305, 311
nerve to, 337
tendon of, 354
Tibialis posterior, 341, 353
ankle/foot and, 344–347

Tibialis posterior *(Continued)*
  attachments for, 303, 305, 309, 311
  groove for, 306, 349
  tendonitis of, 357f
  tendon of, 346
Tibiofibular joint, 354
  inferior, 307, 354
  superior, 307, 332
Tibioperoneal trunk, 343
Toes, 285, 310–311
  abnormality of, 355f
  dislocation of, 355f
  hammer, 355f
  ossification of, 314–315
Tongue, 43, 47, 49, 59
  carcinoma of, 82f
  imaging of, 52, 58, 214
  lymphoid tissue in, 360
Tonsillectomy, 82f
Tonsillitis, 82f, 369f
Tonsils
  cerebellar, 65
  palatine, 360
Torticollis, 82f
Total hip replacement surgery, 357f
Trachea, 36–37, 197, e8
  imaging of, 106, 196, 214
  larynx and, 49–50
  lungs and, 202–204
  surface marking of, 28, 205
Tracheal ring, 48, 50
Tracheobronchial lymph nodes, e8
Tracheostomy, 82f, 361
Tragus, 38, 40, 42, 60
Transpyloric plane, 217
Transtubercular plane, 217
Transurethral resection of prostate (TURP), 268, 283f
Transversalis fascia, 225
Transverse arytenoid muscle, 49–50
Transverse cervical artery, 31, 132, 207, 361
Transverse cervical vein, 361
Transverse colon, 233, 236–237, e9
  radiograph of, 240
  upper abdomen and, 227–229, 231
Transverse facial artery, 40
Transverse ligament
  of atlas, 94
  of hand, 166
  of hip, 287, 293, 325, 327
  of knee, 333–334
Transverse mesocolon, 231, 233
Transverse myelitis, 108f
Transverse palatine (palatomaxillary) suture, 9
Transverse process
  cervical, 85–86, 94–95
  coccygeal, 90
  lumbar, 88, 99, 107
  thoracic, 86–87, 98, 211
Transverse sinus
  cerebral, 11, 17, 51, 53
  pericardial, 185
Transversus abdominis, 219, 223, 260
  attachments for, 289, 291, 293
Transversus thoracis, 177, 183
Trapezium, 122–123, 163, 167
Trapezius, 101, 173, e2–e3
  attachments for, 10, 111, 113
  cervical nerves to, 29–30, 32, 128
  cross-sections of, e7–e8
  neck and, 29–30, 32–33
  shoulder and, 128–129, 131, 133
  surface marking of, 84, 100, 126, 130
Trapezoid, 122–123, 159, 167
Trapezoid ligament, 111, 113, 136
Trapezoid line, 112
Trendelenburg's sign, 326, 357f
Triangle of auscultation, 101–102, 131
Triangular fibrocartilage of wrist, 167
Triangular ligaments
  of hand, 166
  left, 245
  right, 226, 245
Triangular space, 144
Triceps, 138, e3
  attachments for, 111, 113, 115, 117
  cross-section of, 143, e8
  lateral head of, 127, 133, 137, 142
  long head of, 102–103, 131, 133
  medial head of, 142, 147
  surface marking of, 130, 145
Triceps tendon reflex, 171f
Tricuspid valve, 178, 187–189
Trigeminal ganglion, 44, 51, 59
Trigeminal impression, 11, 23
Trigeminal nerve (V), 44, 53, 58, e6. *See also* Mandibular nerve; Maxillary nerve; Ophthalmic nerve.
  brain and, 64–65, 67–68
  branches of, 59, 75–76
  parasympathetic ganglia associated with, 76
Trigger finger, 171f
Tripod fracture, 82f
Triquetral, 122–123, 167–168
Trochlea
  of eye, 54–55
  of humerus, 116, 120, 146–147
Trochlear fovea (tubercle), 20
Trochlear nerve (IV), 53, 59, 74
  brain and, 65, 67, 69, 71
  orbit and, 54–57
  palsy of, 82f
Trochlear notch, 119–120, 146–147
Tuber cinereum, 64–66
Tuberculosis, 216f
Tuberculum sellae, 11, 25
Tunica albuginea, 265–266
Tunica vaginalis, 265–266
Tympanic membrane, 44, 60–61
  perforation of, 81f
Tympanic nerve, 78
Tympanic plexus, 60
Tympanic ring, 14

U

Ulna, 119–121, e1
  coronoid process of, 119–120, 146–147
  head of, 119, 154, 161, 167
  ossification of, 125
  radiograph of, 146
  styloid process of, 120, 123
  surface marking of, 145
Ulnar artery, e4
  deep branch of, 159–162
  elbow and, 145, 147
  forearm and, 149–151
  hand and, 157–158, 160–161
Ulnar bursa, 158
Ulnar collateral ligament, 146, 163
Ulnar nerve, e5–e6
  arm and, 143–144
  axilla and, 139–142
  deep branch of, 159–160, 162
  digital branch of, 159–160, 162
  dorsal cutaneous branch of, 164
  elbow and, 145
  forearm and, 149–151
  groove for, 122
  hand and, 158–160
  muscular branch of, 159
  palmar branch of, 150, 157–158
  palsy of, 171f
  superficial branch of, 162
Ulnar notch, 118
Umbilical artery, 222
  obliterated, 268, 275
  remnant of, 223, 270, 272
Umbilical folds, 222–223
Umbilical hernia, 283f
Umbilical region, 217
Umbilical veins, 222, 282f
Umbilicus, 218–221
Umbo, 60
Uncovertebral joint, 106
Uncus, 64–65, 67
Upper limb, 109–172
  arm of, 133, 143–144
  axilla of, 138–142
Upper limb *(Continued)*
  bones of, 109–125
  clinical thumbnails for, 170
  elbow of, 145–147
  forearm of, 148–153
  hand of, 154–169
  ligaments and joints of, 167
  muscles of, 109
  shoulder of, 126–137
  surface features of, 109
  wrist/hand radiographs of, 169
Upper subscapular nerves, 141–142
Urachus (median umbilical fold), 223, 272
Ureter, 254–255, 257–258
  female pelvis and, 270, 272, 275
  intravenous urogram of, 259
  kinking of, 259
  male pelvis and, 267–268
  orifice of, 259, 267–268
  surface markings of, 253
  variants of, 256f, 283f
Ureterocele, 283f
Urethra
  cystoscopic view of, 278
  female, 273
  male, 266, 268, 278
  stricture of, 283f
Urinary bladder. *See* Bladder.
Urinary meatus, 265, 276–277
Urinary tract calculi, 283f
Urine, extravasation of, 281f
Urogenital diaphragm, 268
Uterine artery, 270, 275
Uterine cavity, 250, 272, 274, 366
Uterine tube, 274–275
  hysteroscopy of, 274
  imaging of, 273
  ligation of, 282f
Uterosacral ligament, 275
Uterus, 274
  body of, 275
  carcinoma of, 280f
  cervix of, 272–273, 275
  fibroids in, 250, 284f
  fundus of, 272–275
  retroverted, 272f
  round ligament of, 270, 272, 274–275
  variants of, 284f
Utricle, 77
Uvula, 47

V

Vagal triangle, 69
Vagina, 272, 275, 366
  anterior fornix of, 272, 275, 366
  examination of, 284f
  posterior fornix of, 272–273, 275, 366
Vaginal artery, 270, 275
Vaginal cavity, 273
Vaginal orifice (introitus), 276–277
Vaginal process, 25
Vaginal wall, 273, 281f
Vagotomy, 284f
Vagus nerve (X), 47, 78, 207
  auricular branch of, 23, 78
  brain and, 67–69
  cardiac branches of, 78, 193
  cranial cavity and, 53
  inferior ganglion of, 45
  laryngeal branch of, 45
  left, 36, 194–195, 206
  neck and, 29–30, 34–35
  pharyngeal branch of, 45, 47, 78
  right, 36, 192–193, 206
  roots of, 65, 69
  stomach with, 241
  trunks of, 210, 213
Vallate papilla, 49
Vallecula, 47, 49–50, 52
Valvulae conniventes, 240, 250
Varicella-zoster virus infection, 82f, 216f, 284f, 357f
Varicoceles, 284f
Varicose veins, 340, 355f, 357f

Vas deferens. *See* Ductus deferens.
Vascular abnormalities, 171f
Vasectomy, 284f
Vastus intermedius, 322
  attachments for, 295, 297–298, 301
  cross-section of, e10
Vastus lateralis, 263, 321, 326, e2
  attachments for, 295, 297–299
  cross-section of, e10
  nerve to, 368
Vastus medialis, 321–323, e2
  attachments for, 295, 297–298, 301
  nerve to, 321–323
  surface marking of, 328
Veins, e4. *See also specific vein.*
  for coronary artery bypass graft, 357f
  varicose, 340, 355f, 357f
Vena caval foramen, 213
Vena comitans (venae comitantes)
  of brachial artery, 143
  of dorsalis pedis artery, 347–348
  of hypoglossal nerve, 31
  of posterior tibial artery, 345–347
Venepuncture, 172f
Venous cutdown, 172f, 357f
Venous foramen, 11
Venous thrombosis, 346, 355f
Ventral nerve roots/rootlets, 69, 96
Ventricles. *See also specific ventricle.*
  cardiac, 187–188
  cerebral, 72
  laryngeal, 50
Vertebra prominens, 86
Vertebrae, 85–88, e7. *See also* Cervical vertebrae; Lumbar vertebrae; Thoracic vertebrae.
  coccygeal, 90–91
  developmental origins of, 93
  fractures of, 108f
  ossification of, 93
  sacral, 89–90, 97
Vertebral artery, 362, e4, e7
  brain and, 63–65, 69
  groove for, 85
  vertebral column and, 94–95
Vertebral body, e7–e8, e9
  cervical, 85–86, 95
Vertebral body *(Continued)*
  lumbar, 88, 91
  sacral, 89
  thoracic, 86–87
Vertebral canal, e7
Vertebral column, 83, 85–91, 173
  clinical thumbnails for, 108
  pelvis and, 92
  radiographs of, 106–107
  sacrum and coccyx of, 89–91
  spinal cord and, 94–99
  surface features of, 83
  vertebrae of, 85–88
Vertebral foramen
  cervical, 85–86
  lumbar, 88
  thoracic, 86–87
Vertebral vein, 36–37, 206, 212
Vertebral venous plexus, 69, 108f
Vertebropelvic ligaments, 271, 325
Vesicoprostatic venous plexus, 268
Vesico-uterine pouch, 250, 273–275
Vestibular fold, 49–50
Vestibular nerve, 61, 77. *See also* Vestibulocochlear nerve (VIII).
Vestibule
  of inner ear, 61
  of larynx, 50
  of nose, 58
  of oral cavity, 43
  of temporal bone, 23
  of vagina, 276–277
Vestibulocochlear nerve (VIII), 61, 77
  brain and, 64–65, 67–68
  brainstem and, 69
  cranial cavity and, 51, 53
Vincula, finger, 158
Virchow's node, 179, 361, 369f
"Virtual colonoscopy", 240
Viscera
  abdominal, 227–229, 231, 244f
  thoracic, 184
Visual cortex, 70
Vocal cord, 28, e7
  false, 49–50
  true (vocal fold), 49–50
Volkmann's contracture, 172f
Volvulus, 284f
Vomer, 7, 9, 17, 25
Vomerovaginal canal, 9

W

Waldeyer's ring, 360
Wisdom tooth (third molar), 7, 13
  impacted, 81f
  unerupted, 21
Wrist, 159, 167–169
  arterial puncture at, 170f
  arthroscopy of, 172f
  ganglion of, 172f
  joint of, 109, 168
    bones of, 122–123
    capsular attachments of, 121
    ligaments of, 163, 167
    movements of, 155b
  radiographs of, 169
Wrist drop, 172f

X

Xiphisternal joint, 176, 178
Xiphisternum, 173
Xiphoid process, 176, 181, 183, 217
X-rays. *See* Radiographs.

Z

Zona orbicularis, 324, 326–327
Zygapophyseal joint, 95, 98–99, 107
Zygoma, 43
Zygomatic arch, 4, 7, 9, 16
  bones of, 24
  face and, 40, 42
  surface marking of, 38
Zygomatic bone, 1, 4, 24, e7
  orbital surface of, 12, 24
  temporal process of, 24
Zygomatic nerve, 75
Zygomatic process, 4, 20, 23–24
Zygomaticofacial foramen, 24
Zygomatico-orbital foramen, 12, 24
Zygomaticotemporal foramen, 24
Zygomaticus major, 2, 6, 39–40
Zygomaticus minor, 2, 6, 39

This page intentionally left blank

CLINICAL KEY™

Smarter search. Faster answers.

Smarter, Faster Search for Better Patient Care

Unlike a conventional search engine, ClinicalKey is specifically designed to serve doctors by providing three core components:

1 Comprehensive Content

The most current, evidence-based answers available for every medical and surgical specialty.

2 Trusted Answers

Content supplied by Elsevier, the world's leading provider of health and science information.

3 Unrivaled Speed to Answer

Faster, more relevant clinical answers, so you can spend less time searching and more time caring for patients.

Start searching with ClinicalKey today!

Visit ***ClinicalKey.com*** for more information and subscription options.

ELSEVIER

UPLOADED BY [STORMRG]